nature REVIEWS
CARDIOLOGY

A history of balloon angioplasty

Robert A. Byrne and Adnan Kastrati

Cardiovascular disease remains the leading cause of death around the world. However, progress in medical knowledge and technology over the past 50–60 years has led to a substantial reduction in rates of cardiovascular-related death. A number of factors contributed to this decline, including the identification of cardiovascular risk factors, the advent of coronary care units, surgical myocardial revascularization, and the availability of new therapies that modify blood-pressure and cholesterol levels. However, the pioneering of transcatheter coronary balloon angioplasty by Andreas Grüntzig in 1977 has undoubtedly had an important role in reducing the morbidity and mortality of patients with obstructive coronary artery disease. Percutaneous coronary intervention has become one of the most commonly performed medical procedures worldwide, and balloon angioplasty is now the dominant mechanism of revascularization in patients with peripheral arterial disease. In this poster, we outline the major milestones in the development of balloon angioplasty and important treatment modalities that have emerged as a result of this technology.

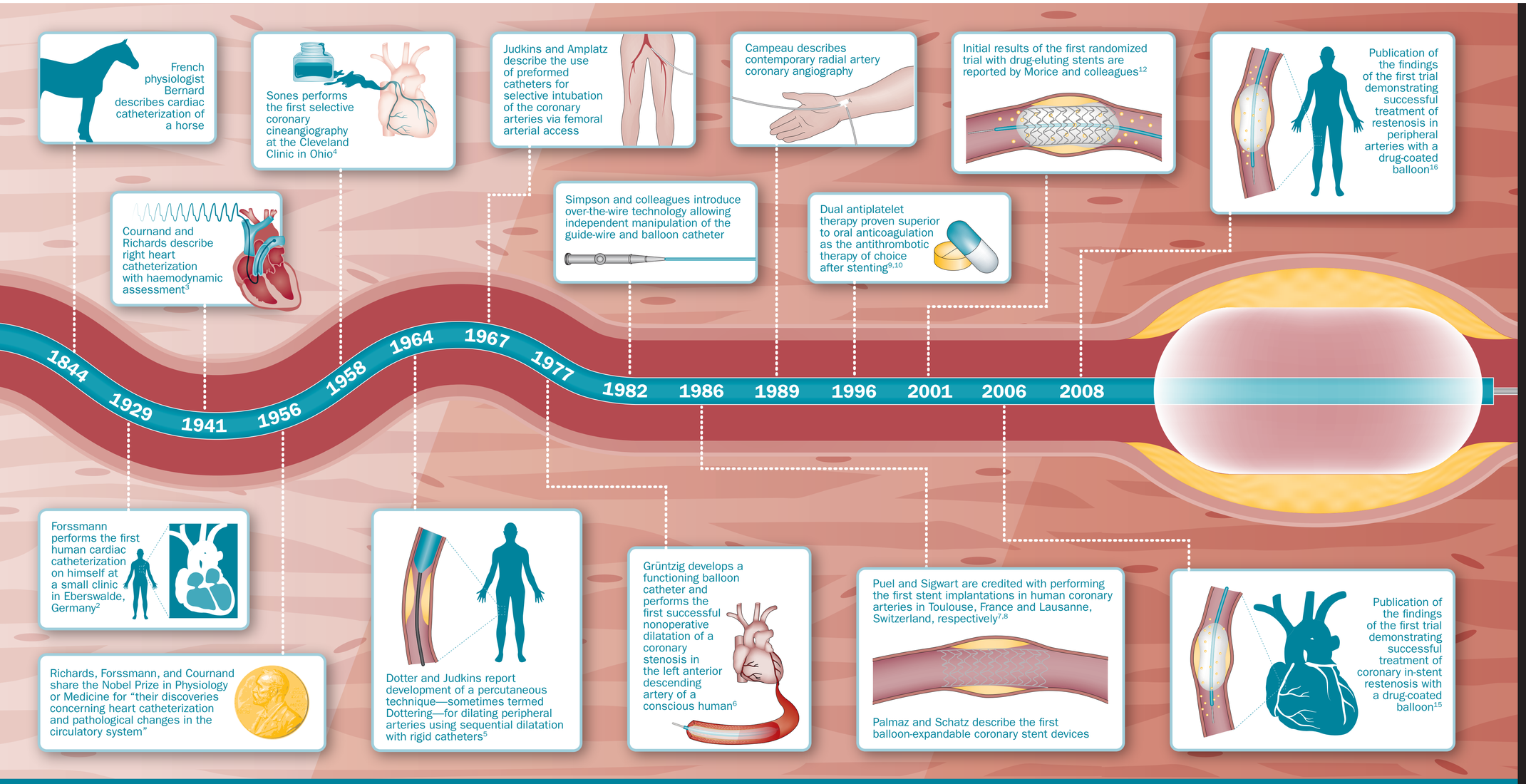

The history of catheter-based intervention is one of serial innovation and technological refinement—developments that have revolutionized the treatment of cardiovascular disease.[1] The foundations of catheter-based intervention were laid by a number of pioneers. Werner Forssmann was a 25-year-old German medical resident who performed the first human cardiac catheterization on himself at a small clinic in Eberswalde, Germany in 1929.[2] Although this daring act precipitated his own academic downfall, he subsequently shared the 1956 Nobel Prize in Physiology or Medicine with fellow innovators Dickinson Richards and André Cournand, who developed right heart haemodynamic assessment at Bellevue Hospital in NY, USA.[3] Mason Sones was a radiologist at the Cleveland Clinic, OH, USA, who performed the first selective coronary cineangiography—albeit inadvertently when the catheter meant to inject dye into a man's aorta entered a coronary artery—on 30 October 1958.[4] Charles Dotter was a vascular radiologist in Portland, OR, USA, who developed a percutaneous technique—sometimes termed Dottering—for dilating peripheral arteries using sequential dilatation with rigid catheters.[5] Ultimately, it was Andreas Grüntzig, a German cardiologist, who developed a functioning balloon catheter and performed the first successful nonoperative dilatation of a coronary stenosis in a 38-year-old Swiss man on 16 September 1977 at the University Hospital in Zürich, Switzerland.[6] This procedure became known as balloon angioplasty. This technique was limited by a high incidence of abrupt vessel closure after dilatation and requirement for reintervention owing to restenosis. A solution to these problems was the implantation of an expandable metal mesh to maintain vessel patency after balloon dilatation. Jacques Puel and Ulrich Sigwart are credited with performing the first stent implantations in human coronary arteries in Toulouse, France and Lausanne, Switzerland, respectively, in 1986.[7,8] However, the inherent thrombogenicity of metal stents that were in contact with circulating blood resulted in a restrictive rate of thrombotic stent occlusion despite aggressive anticoagulant therapy. A strategy based on dual antiplatelet therapy with aspirin and a thienopyridine was substantially more efficacious and better tolerated than anticoagulation,[9,10] thereby facilitating a widespread adoption of stenting in clinical practice. Indeed, percutaneous coronary intervention has now become one of the most commonly performed medical procedures worldwide.[11] The remaining Achilles' heel of catheter-based intervention with uncoated or bare-metal stents was neointimal hyperplasia—a process of scar tissue formation at the stented segment that often necessitates repeat intervention. Drug-eluting stent therapy was developed to target this pathophysiological process and involves coating of the stent backbone with antimitotic or immunosuppressive agents, which inhibits smooth muscle cell proliferation, a central component of neointimal hyperplasia. Drug release is typically controlled by polymer coatings. In 2001, the first positive results with drug-eluting stents were reported, indicating a considerable reduction in the rate of restenosis after stenting.[12] These results enabled the expansion of coronary angioplasty to patients with increasingly complex disease. In the past decade, technological development has focused on drug-coated balloons, which are advantageous in settings in which stent implantation is undesirable,[13] and on resorbable drug-eluting stents, which are ultimately absorbed into the vessel wall after their useful function has been served.[14] Findings from the first clinical trials demonstrating successful use of drug-eluting balloons to treat restenosis in coronary[15] and peripheral[16] arteries were published in 2006 and 2008, respectively.

References

1. Mueller, R. L. & Sanborn, T. A. The history of interventional cardiology: cardiac catheterization, angioplasty, and related interventions. *Am. Heart J.* **129**, 146–172 (1995).
2. Forssmann, W. Contrast representation of the cavities of the living right half of the heart [German]. *MMW Munch. Med. Wochenschr.* **78**, 489–492 (1931).
3. Cournand, A. et al. Measurement of cardiac output in man using the technique of catheterization of the right auricle or ventricle. *J. Clin. Invest.* **24**, 106–116 (1945).
4. Sones, F. M. Jr & Shirey, E. K. Cine coronary arteriography. *Mod. Concepts Cardiovasc. Dis.* **31**, 735–738 (1962).
5. Dotter, C. T. Transluminally-placed coilspring endarterial tube grafts: long-term patency in canine popliteal artery. *Invest. Radiol.* **4**, 329–332 (1969).
6. Grüntzig, A. Transluminal dilatation of coronary artery stenosis. *Lancet* **311**, 263 (1986).
7. Puel, J. *et al.* Self-expanding coronary endoprosthesis in the prevention of restenosis following transluminal angioplasty. Preliminary clinical study [French]. *Arch. Mal. Coeur Vaiss.* **80**, 1311–1312 (1987).
8. Sigwart, U., Puel, J., Mirkovitch, V., Joffre, F. & Kappenberger, L. Intravascular stents to prevent occlusion and restenosis after transluminal angioplasty. *N. Engl. J. Med.* **316**, 701–706 (1987).
9. Schömig, A. *et al.* A randomized comparison of antiplatelet and anticoagulant therapy after the placement of coronary artery stents. *N. Engl. J. Med.* **334**, 1084–1089 (1996).
10. Leon, M. B. *et al.* A clinical trial comparing three antithrombotic-drug regimens after coronary-artery stenting. *N. Engl. J. Med.* **339**, 1665–1671 (1998).
11. Mozaffarian, D. *et al.* Heart disease and stroke statistics–2015 update: a report from the American Heart Association. *Circulation* **131**, e29–e322 (2015).
12. Morice, M. C. *et al.* A randomized comparison of a sirolimus-eluting stent with a standard stent for coronary revascularization. *N. Engl. J. Med.* **346**, 1773–1780 (2002)
13. Byrne, R. A., Joner, M., Alfonso, F. & Kastrati, A. Drug-coated balloon therapy in coronary and peripheral artery disease. *Nat. Rev. Cardiol.* **11**, 13–23 (2014).
14. Iqbal, J. *et al.* Bioresorbable scaffolds: rationale, current status, challenges, and future. *Eur. Heart J.* **35**, 765–776 (2014).
15. Scheller, B. *et al.* Treatment of coronary in-stent restenosis with a paclitaxel-coated balloon catheter. *N. Engl. J. Med.* **355**, 2113–2124 (2006).
16. Tepe, G. *et al.* Local delivery of paclitaxel to inhibit restenosis during angioplasty of the leg. *N. Engl. J. Med.* **358**, 689–699 (2008).

Affiliations and competing interests

Deutsches Herzzentrum München, Technische Universität München, Lazarettstrasse 36, D-80636 Munich, Germany (R.A.B., A.K.).
R.A.B. declares that he has received lecture fees from B. Braun, Biotronik, and Boston Scientific. A.K. reports patent applications related to drug-eluting stent coatings.

Edited by Tim Geach and Karina Huynh.
Designed by Laura Marshall and Kirsten Lee.
The poster content is peer-reviewed, editorially independent, and the sole responsibility of Nature Publishing Group.