

Periodontal diagnosis in the context of the BSP implementation plan for the 2017 classification system of periodontal diseases and conditions: presentation of a pair of young siblings with periodontitis

C. Walter,¹ I. L. C. Chapple,² P. Ower,³ M. Tank,⁴ N. X. West,⁵ I. Needleman,⁶ F. J. Hughes,⁷ R. Wadia,⁸ M. R. Milward,² P. J. Hodge,⁹ T. Dietrich,^{*10} on behalf of the British Society of Periodontology

Key points

Illustrates the application of the BSP implementation plan for diagnosing periodontitis patients according to the 2017 classification.

Highlights the potential for aggregation of periodontitis in families.

Suggests that relatives of young patients with severe periodontitis are also examined.

The objective of this case report is to illustrate the diagnosis and classification of periodontitis according to the 2017 classification system as recommended in the British Society of Periodontology (BSP) implementation plan. We describe two cases in the form of a pair of siblings, who developed periodontitis very early in life. A 19-year-old female was diagnosed with 'generalised periodontitis; stage III/grade C; currently unstable'. Her 14-year-old sister was diagnosed with 'localised periodontitis; stage II, grade C; currently unstable'. The present case report presents an example for the application of the new classification system and illustrates the importance of a periodontal check for children and adolescents and/or their relatives.

Introduction

The aetiology and pathogenesis of periodontitis in adolescents and young adults has been the subject of much debate in recent decades.¹⁻³ Formerly known as 'early onset periodontitis', 'rapidly progressive

periodontitis', 'localised juvenile periodontitis' or 'generalised juvenile periodontitis', these disease forms were collectively renamed as 'aggressive periodontitis' in the 1999 classification system.³ However, clear evidence that the aetiology or pathogenesis of periodontitis in adolescents or young adults is fundamentally different from that occurring in older adults is lacking. Therefore, the 2017 classification does not distinguish different types of periodontitis based on age at diagnosis or rate of disease progression.⁴ Rather, the introduction of a staging and grading system provides for an explicit distinction of the presenting severity/extent (stage) and disease susceptibility/progression (grade),⁵ in the absence of therapeutic intervention.

In this case presentation we report on a pair of siblings with periodontitis formerly classified as localised and generalised aggressive periodontitis. We demonstrate, step-by-step, how the BSP recommendations for

implementation of the 2017 classification system can be applied in practice to reach an appropriate periodontal diagnosis.⁶

Case reports

Patient 1

A 19-year-old female presented in good general health. The patient was a never-smoker. Intraoral clinical inspection revealed moderate levels of oral hygiene and signs of gingival inflammation, that is, redness, and oedema (Fig. 1). The patient did not present with overt interproximal recession or clinical attachment loss.

As part of the initial patient assessment a BPE screening examination was indicated (Table 1). The BPE codes of 4 in all sextants were, in the absence of pseudopockets, consistent with a provisional diagnosis of periodontitis and triggered a full periodontal assessment including a six point pocket chart, bleeding

¹Department of Periodontology, Endodontology and Cariology, University of Basel, Basel, Switzerland; ²Department of Periodontology; ¹⁰Department of Oral Surgery, The School of Dentistry, University of Birmingham, Birmingham, UK; ³Specialist in Periodontology, Periocourses Ltd., Alton, UK; ⁴Specialist in Periodontology, UK; ⁵Periodontology Clinical Trials Group, University of Bristol, Bristol, UK; ⁶Department of Periodontology, Eastman Dental Institute, University College London, London, UK; ⁷Centre for Host Microbial Interactions, Dental Institute, Kings College London, London, UK; ⁸RW Perio and King's College London, London, UK; ⁹Department of Periodontology, Dental School, University of Glasgow, Glasgow, UK
*Correspondence to: Thomas Dietrich
Email: t.dietrich@bham.ac.uk

Refereed Paper. Accepted 20 November 2018
DOI: 10.1038/sj.bdj.2019.2

on probing measures and appropriate radiographs. The full periodontal chart demonstrated deep pockets up to 8 mm in all sextants, and all molars exhibited furcation involvement (grade II furcations in all maxillary molars and 46) (Fig. 2). In addition, there were several pockets >4 mm that bled on probing, indicating unstable periodontitis. The periapical radiographs show evidence of significant bone loss due to periodontitis on all teeth, with the possible exception of 23, 24, 44 and 45 (Fig. 3).

Hence, given the history (that is, lack of systemic disease explaining loss of periodontal tissues, for example, Papillon-Lefèvre-Syndrome) and the clinical and radiological findings (interproximal attachment loss/alveolar bone loss due to periodontitis, no papillary necrosis consistent with necrotising periodontal disease), a diagnosis of periodontitis was made.

For every patient diagnosed with periodontitis, staging and grading should be performed as the next step.^{4,6} Bone loss reached into the middle third of the root in many teeth, but did not extend into the apical third on any tooth. Hence, the patient is a patient with stage III periodontitis. Maximum bone loss of approximately 60% is seen at 14, 15 and 16. As the patient is 19 years of age, the numerical value of the highest percentage of bone loss exceeds the numerical value of her age (percentage of bone loss/age ratio >1), which results in an assignment of grade C. At least 24 out of 28 teeth (>30%) are affected by bone loss due to periodontitis, resulting in an extent classification of 'generalised' periodontitis.

Therefore, the definitive diagnosis according to the 2017 classification is:

Generalised periodontitis; stage III/grade C; currently unstable.

Systematic periodontal treatment needed to be initiated. Note that the outcome of treatment will not result in a change of the initial disease classification as 'generalised periodontitis; stage III/grade C'. This patient will always be a periodontitis patient, with evidence of high disease susceptibility (as indicated by grade C), requiring careful and intensive periodontal maintenance, risk factor control and monitoring.

Following a diagnosis of stage III/grade C periodontitis in this young patient, the patient should be questioned about any siblings. She stated that she had a 14-year-old sister, who was invited to attend for an examination.

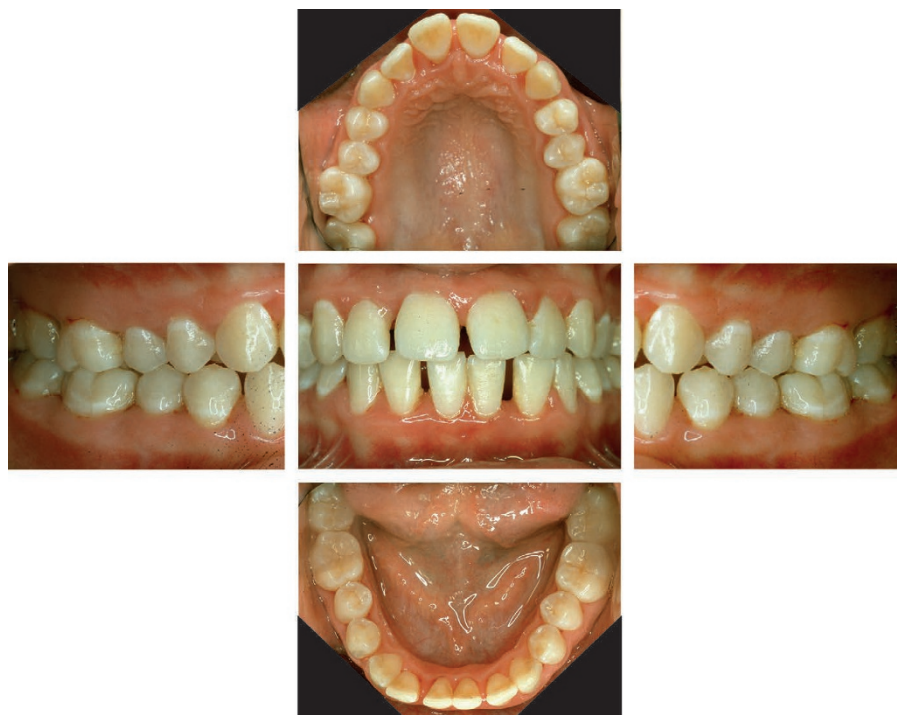

Fig. 1 Patient 1 – Initial intraoral view of the older sister

Table 1 Patient 1 – BPE examination

4*	4	4*
4*	4	4*

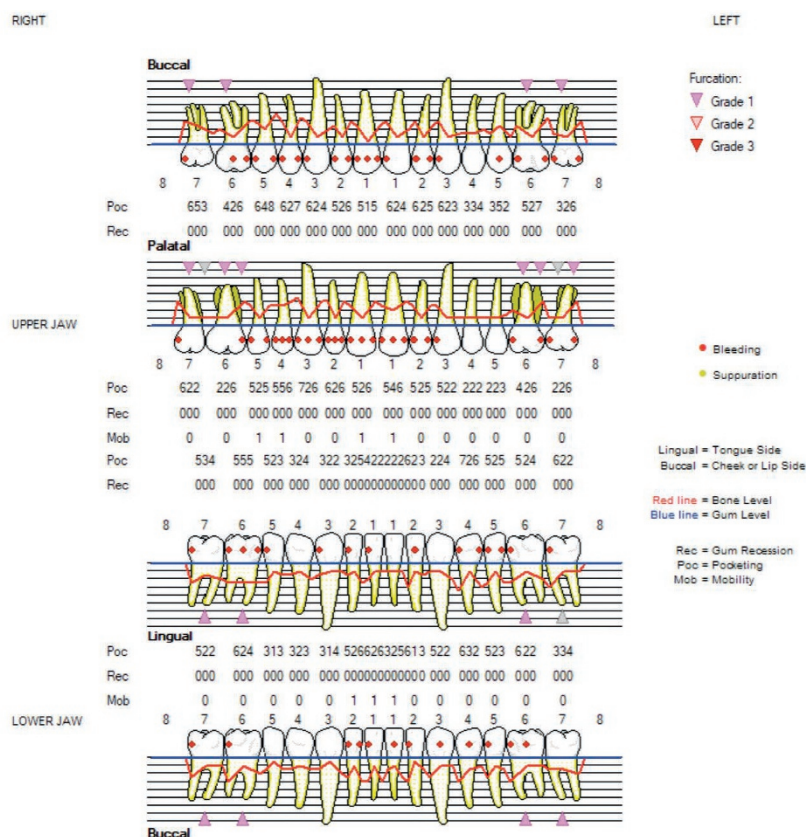


Fig. 2 Patient 1 – Detailed periodontal chart (DPC)

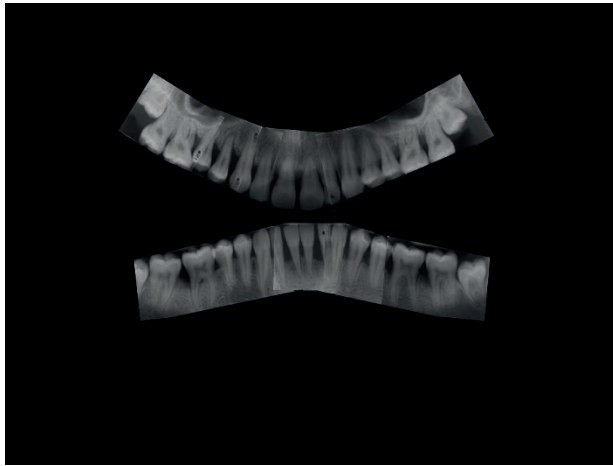


Fig. 3 Patient 1 – Periapical intraoral radiographs

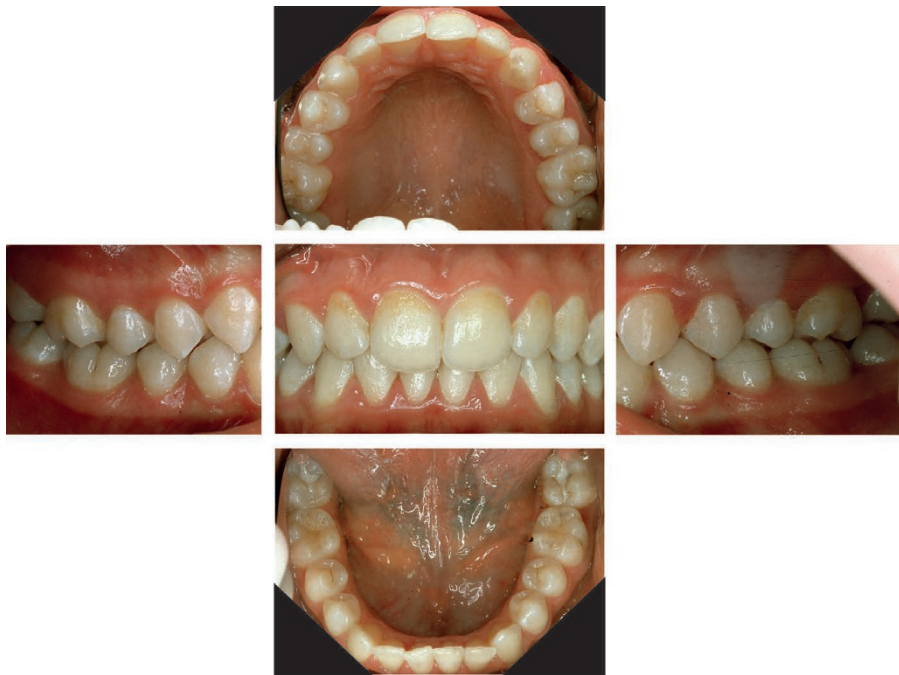

Fig. 4 Patient 2 – Initial intraoral view of the younger sister

Table 2 Patient 2 – BPE examination

4	3	1
4	4	1

Patient 2

The 14-year-old female patient was a never-smoker and in good general health. She had not experienced periodontal therapy. An intraoral examination revealed moderate levels of oral hygiene and some signs of minor gingival inflammation (Fig. 4). There was no overt interproximal recession or clinical attachment

loss. A periodontal screening examination (BPE) was indicated and performed (Table 2). The BPE revealed codes of 4 in three sextants, which were, in the absence of pseudopockets, consistent with a provisional diagnosis of periodontitis and triggered a full periodontal assessment including a six point pocket chart with bleeding on probing and appropriate

radiographs (Figs 5 and 6). The periodontal charting revealed a maximum PPD of 7 mm buccally on the 14 and disto-lingually 46 and mesio-lingually 47. Furthermore, 17, 16 and 32 had PPDs of 6 mm and PPDs of 4 mm and 5 mm were evident which bled on probing on 13, 31, 41 and 42.

A panoramic radiograph and selective periapical radiographs demonstrated bone loss on 14, 15, 16, 46, 47, 32, 31 and 41. The medical history and results of the clinical and radiological examination therefore led to a diagnosis of periodontitis. There was evidence of bone loss exceeding 15% of the root length, but not extending into the middle third of the root length (stage II periodontitis). The maximum bone loss is estimated as 20% (14, 15, 16, 32, 31, 41). As the patient is 14 years old, the numerical value of her maximum amount of bone loss in percentage terms is greater than her age in years ($20 > 14$). Therefore, this case would be classified as grade C periodontitis. Bone loss due to periodontitis was evident on eight out of 28 teeth ($\leq 30\%$), resulting in an extent classification of 'localised' periodontitis. Finally, as this was a patient with untreated periodontitis and there was bleeding on probing at sites with pockets equal to and over 4 mm, it is classed as 'currently unstable'.

Hence, the final diagnosis was:

Localised periodontitis; stage II, grade C; currently unstable.

A systematic periodontal treatment was initiated.

Discussion and summary

This case report provides an example of how to diagnose a pair of siblings according to the 2017 classification of periodontal and peri-implant diseases by following the BSP implementation plan.⁶ In the new system, these two young patients are diagnosed as patients with periodontitis. The 19-year-old older sister, who would have been diagnosed with generalised aggressive periodontitis under the 1999 classification, was diagnosed with 'generalised periodontitis; stage III/grade C; currently unstable.' Her 14-year-old sister, who would have been diagnosed with localised aggressive periodontitis under the 1999 classification, was diagnosed with 'localised periodontitis; stage II, grade C; currently unstable.' The grade C assignment to both patients indicates high disease susceptibility and the need for careful and intensive

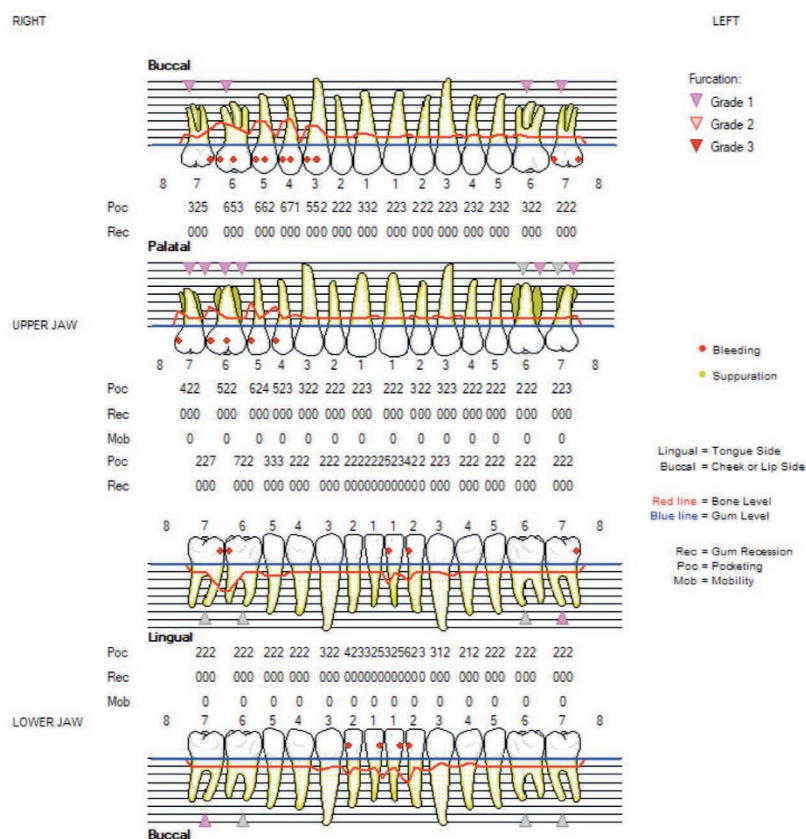


Fig. 5 Patient 2 – Detailed periodontal chart

treatment and maintenance, however, the distinction between stage II and stage III disease appropriately differentiates between the different levels of tissue destruction that has already occurred, which is relevant for the management of these patients. This paper is not aimed at discussing treatment, but decisions on the use of systemic antibiotics as an adjunct in the management of grade C cases must be taken on a case-by-case basis, accounting for levels of oral hygiene and local risk factors.

1. Meyer J, Lallam-Laroye C, Dridi M. Aggressive periodontitis- what exactly is it? *J Clin Periodontol* 2004; **31**: 586–587.
2. Lang N P, Bartold P M, Cullinan M *et al*. International Classification Workshop. Consensus report: Aggressive periodontitis. *Ann Periodontol* 1999 **4**: 53.
3. Armitage GC. Development of a classification system for periodontal diseases and conditions. *Ann Periodontol* 1999; **4**: 1–6.
4. Papapanou P N, Sanz M, Buduneli N *et al*. Periodontitis: Consensus report of workgroup 2 of the 2017 World Workshop on the Classification of Periodontal and Peri-Implant Diseases and Conditions. *J Clin Periodontol* 2018; **45 Suppl 20**: S162–S170.
5. Tonetti M S, Greenwell H, Kornman K S. Staging and grading of periodontitis: Framework and proposal of a new classification and case definition. *J Clin Periodontol* 2018; **45 Suppl 20**: S149–S161.
6. Dietrich T, Ower P, Tank M *et al*. Periodontal diagnosis in the context of the 2017 classification system of periodontal diseases and conditions – Implementation in Clinical Practice. *Br Dent J* 2019; **226**: 16–22.

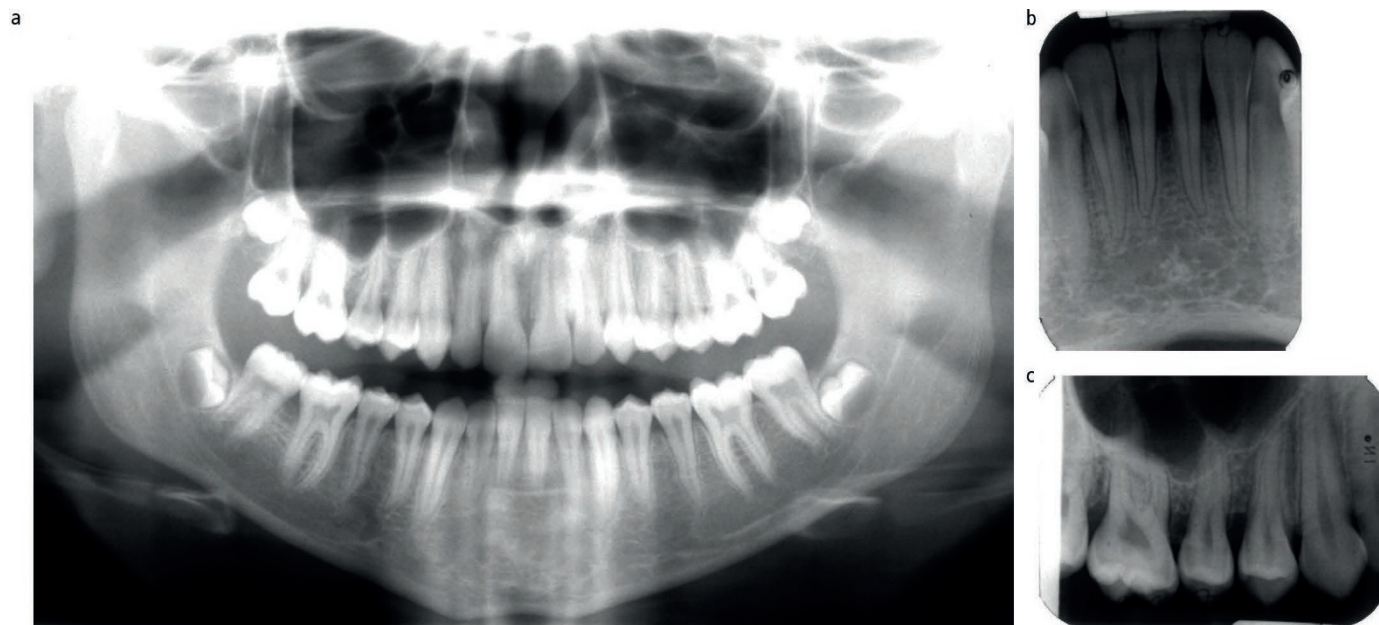


Fig. 6 Patient 2 – a) Panoramic radiograph. b and c) selective periapical radiographs