Restorative aspects of oral cancer reconstruction

C. W. Barclay,*[1] E. C. Foster[1] and C. L. Taylor[1]

Key points

- Discusses oral rehabilitation, with a focus on primary management.
- Outlines dental rehabilitation for oral cancer patients.
- Considers the risks versus benefits of oral reconstruction.

The oral rehabilitation of head and neck cancer patients is a vital and pivotal part of their care pathway, helping to restore function, aesthetics and improve patient well-being and quality of life. Patient-reported outcome data demonstrates that such patients consider that many of their continued and unmet needs relate to their oral and dental rehabilitation. It is therefore incumbent on all dental team members to be aware of the entire spectrum of restorative management options that can be utilised in both the prevention and rehabilitation of this patient cohort. The literature highlights that maxillary and mid-face tumours are challenging, as patients often suffer both profound functional and aesthetic consequences with significant physiological and psychological impact. Conversely, mandibular and floor of mouth tumours often result in issues primarily affecting oral function. This paper will summarise commonly encountered functional and aesthetic issues facing the restorative dental team and highlight widespread preventive challenges.

Introduction

Oral cancer no longer predominates in the older male, who traditionally would have been a heavy smoker and drinker.[1] This shift in demographics has resulted in a more variable cohort of patients requiring oral rehabilitation, necessitating consideration of a wide range of treatment modalities appropriate for their care and management.[2] The primary aim of oral rehabilitation is to attempt to return the patient to their previous orofacial aesthetics, function and ultimately wellbeing, although this is often not possible.[3] Clearly a patient's primary concern at diagnosis is survival, however, once concerns regarding mortality have eased, their attention turns to issues they encounter on a daily basis which have a negative impact on their quality of life.[4,5] The Patient Concerns Inventory (PCI) is a clinical tool designed to identify individual patient concerns and needs that they wish to discuss during their consultation. It was developed by interviewing patients who had been treated for head and neck cancer, utilising quality of life questionnaires.[6] Of the top sixteen commonly raised items using PCI, six are related to dental issues, namely dry mouth, chewing/eating, dental health/teeth, speech, saliva (too much or too thick) and taste loss.[7] Many of these issues are magnified and quality of life further reduced when radiotherapy is used in cancer management.[5] Poor quality of life and social isolation can also be a direct result of the physical and psychological effects of oral cancer.[8,9] It is therefore incumbent upon the restorative consultant (sub-specialising in oral rehabilitation) to appreciate the significance of oral rehabilitation of such patients and its widespread impact, aiming to provide bespoke rehabilitations of the highest quality with robust long-term maintenance programmes.

This paper considers the outcomes of the primary management of oral cancer and considers various oral rehabilitation techniques that can be employed.

[1]University Dental Hospital of Manchester, Higher Cambridge Street, Manchester, M15 6FH
*Correspondence to: Craig Barclay
Email: craig.barclay@manchester.ac.uk

Refereed Paper. Accepted 6 August 2018
DOI: 10.1038/sj.bdj.2018.927

Primary management of oral cancer

Where possible a single modality treatment is preferred, with surgery frequently the first choice for oral cancer.[10] Often, however, this is not possible or appropriate; for example, a small tumour of the soft palate may be better managed by radiotherapy than a surgical approach which may lead to more challenging functional issues. Oral cancer is managed with surgical resection, (chemo)radiotherapy or a combination of these, all of which have profound adverse short and long-term side effects.[4] Although this paper will focus on the reconstructive aspects of oral cancer management, the pre-treatment assessment and preventive aspects of care (as outlined in the Head and Neck Cancer Multidisciplinary Management National Guidelines) are of paramount importance to the long-term physiological and psychological patient outcomes.[11]

A thorough dental assessment of all soft and hard tissues before cancer treatment must be undertaken. Teeth may be lost due to the surgical resection, by virtue of having poor long-term prognosis, their position and condition in relation to the planned radiotherapy fields or potential access issues in the future due to trismus caused by surgery and/or radiotherapy.[12] The prevention of future dental disease by optimising oral hygiene, addressing dietary issues particularly with regard to sugar intake and fluoride and calcium/phosphate replacement therapy must also be

Fig. 1 Radiotherapy caries which primarily affects root surfaces and spreads circumferentially around the teeth, making operative intervention very challenging

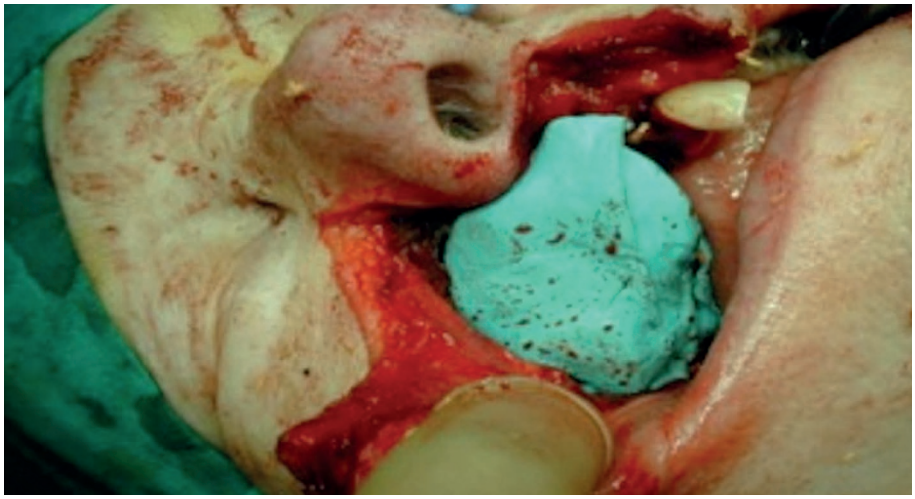

Fig. 2 First stage of surgical obturator placement immediately following resection of the tumour. Prior to surgery, an impression is taken and the likely resection outlined on the cast along with removal of any teeth planned for simultaneous extraction. A clear acrylic plate is constructed with a retentive wire loop which extends into the planned defect. This is then relined with silicone putty following the resection as shown below. The obturator is then secured in place using long screws drilled into the residual palatal bone and occasionally wires which are passed through holes drilled into the zygomatic buttress

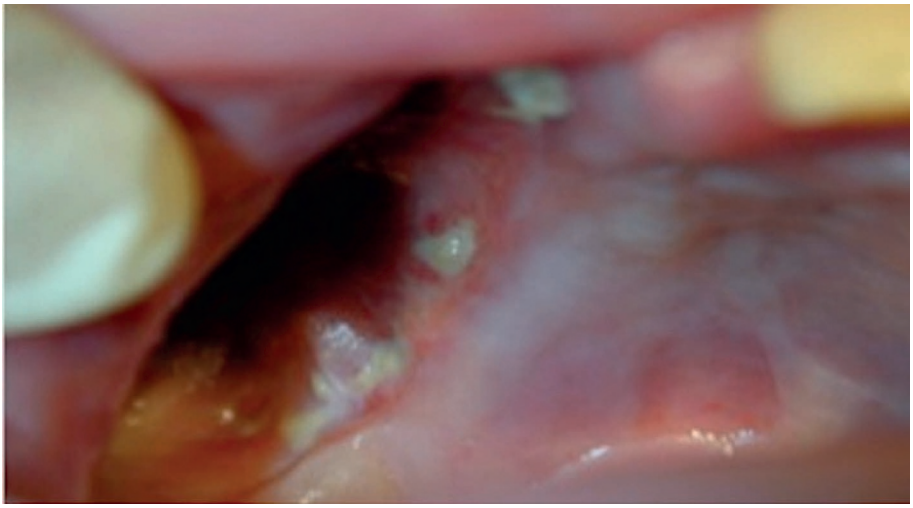

Fig. 3 Hemi-maxillectomy patient with a split thickness skin graft on the right lateral aspect of the defect

instigated as patients often suffer debilitating and permanent xerostomia following radiotherapy (Fig. 1).[13–15]

Dental rehabilitation

Maintenance of the natural dentition is always the preferred option where feasible. Pre-treatment assessment of the existing dentition before cancer treatment is essential to ensure maintenance of teeth with a favourable long-term prognosis which can be maintained by conventional restorative treatment.

Reconstructing the soft and hard tissue that is lost as a direct result of the primary cancer management will now be discussed.

Maxillary reconstruction

A partial /complete maxillectomy is one of the few defects created in the treatment of head and neck cancer that may result in both facial disfigurement and severely compromised oral function.[16] When surgery and/or radiotherapy of this area is planned, it is essential to carefully develop a holistic rehabilitative plan, considering the likely short and long-term issues the patient could encounter. Issues relating to the local area and the patient as a whole need to be considered as well as the anticipated complications the patient may encounter several years into the future. Local factors include the tumour site, size (including horizontal and vertical extent), the need for facial support, if the treatment is curative or palliative and the likelihood of adjuvant radiotherapy. Patient-related factors include their motivation, age, general health, likely coping ability and social support, dental history and overall health. The risks and benefits of the procedure also need to be considered and communicated to the patient.

If the surgical defect is not planned for immediate reconstruction with a free flap, then provision of a surgical obturator is essential.[17,18] There are various methods and materials that can be used, but the void left by the resection needs to be peripherally sealed as a minimum, using a material such as silicone putty. Cheek architecture must be restored; preferably slightly over supported before radiotherapy to prevent skin shrinkage and a cheek concavity developing following irradiation (Fig. 2). It is often preferable to use a split thickness skin graft in the defect to provide both a fibrous band and also a lining of the cheek soft issue (Fig. 3).[19] The prosthetic rehabilitation of this defect can either be done by a one or two part

prosthesis dependent on the height and complexity of the defect and oral access.[20,21] Figure 4 shows a single piece hollow acrylic obturator which is used when access is favourable.

Definitive maxillary prosthetic obturation may have some potential advantages for select patients. The surgery is quick and relatively straightforward and there is the potential benefit of visual defect surveillance.

For most extensive maxillary defects, particularly in young and healthy patients, free flap reconstruction is considered the gold standard.[16] A free flap refers to the tissue being harvested with its own artery and vein that are then anastomosed to local vessels which are branches of the external carotid artery and vein. Free flap reconstruction can occur at the time of resection or be delayed to ensure clear margins at the primary site and allow time to plan the rehabilitation, or until the patient has finished growing (Fig. 5a). Brown and Shaw's classification of maxillary defects (2010) is widely used in the UK and encompasses both the horizontal and vertical extent of a defect which is particularly useful from a rehabilitative standpoint.[16] For low level defects extending into the sinus or nasal cavity the horizontal element requires greater consideration. For defects that have a greater vertical extent involving the floor of the orbit for example, the need for facial support and the vertical element takes precedence.

If closure of the defect is planned, the choice of free flap will be determined by numerous factors. Free flaps can consist of skin and/or muscle (soft tissue) plus underlying bone (termed composite free flap). Flaps can be harvested from several areas of the body with arms, legs and the upper back being common sites. Along with numerous other factors, the choice of free flap depends on the size of the defect, the length of paedicle required and the amount of bone required if a fixed implant solution is sought.[22,23] Following placement, the nasal cavity and maxillary sinuses are then once again separated from the oral cavity improving speech, function, control of secretions and often aesthetics (Fig. 5b). Composite free flaps frequently used to repair such defects, include the scapula (shoulder blade), deep circumflex iliac artery (DCIA) flap (hip) and fibula (lower leg). Placement of dental implants into such free flaps can either be done as a primary procedure or delayed to ensure flap survival and allow for 3D planning (Fig. 5c).[24] The prosthetic management often involves either fixed or removable hybrid implant-supported prostheses to replace teeth, hard and soft tissues, negating the need for extensive bone and soft tissue grafting. Figure 5d shows an implant-supported

Fig. 4 Hollow box obturator

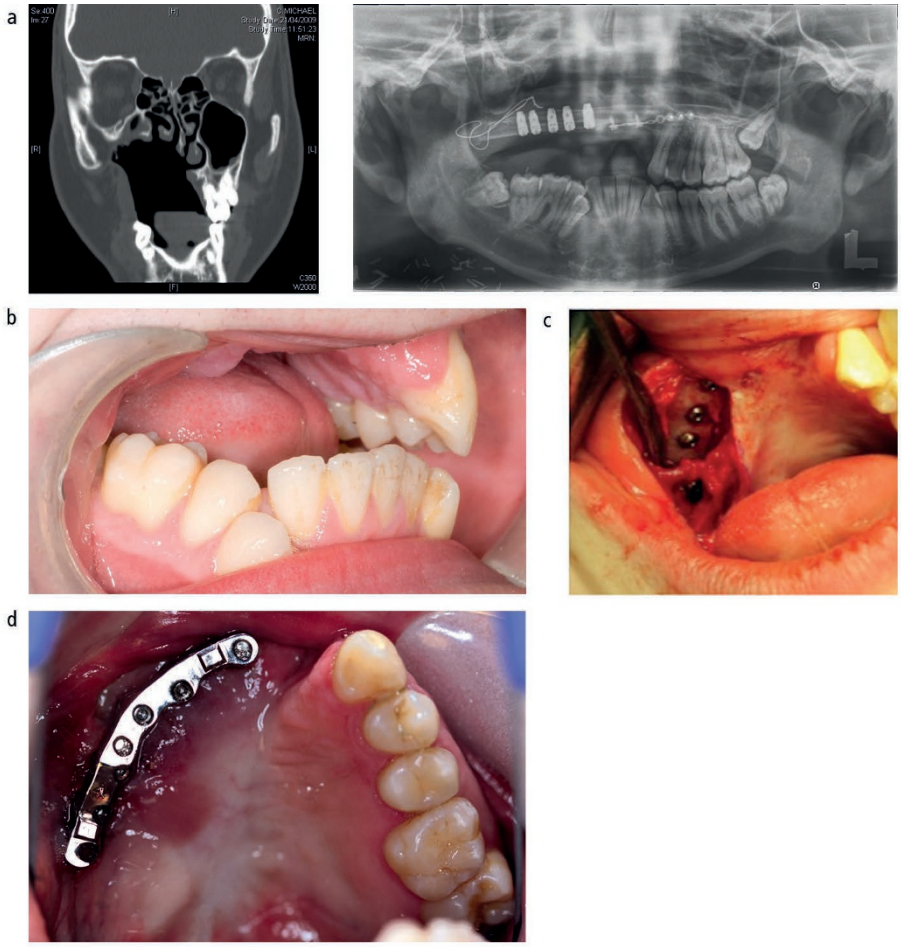

Fig. 5 Radiographs of a young patient following a hemi-maxillectomy. (a) Free flap inserted at completion of growth; (b) Photograph taken immediately following implant placement in the same patient; note the challenging soft tissue anatomy; (c) Photograph taken of implant-supported CADCAM milled titanium beam; (d) Following placement of the scapula free flap, a 3D lithographic model was printed from the patient's CT scan replicating the bony anatomy. Implant planning and surgical stent construction was undertaken on the lithographic model and the CT images used in implant planning software. Following implant placement and exposure, an implant retained pressure plate was used to create more favourable soft tissue contour. This is a clear plate whereby the master model has been relieved in specified areas, such that when it is inserted it exerts pressure on the tissues and causes pressure necrosis to create a buccal sulcus

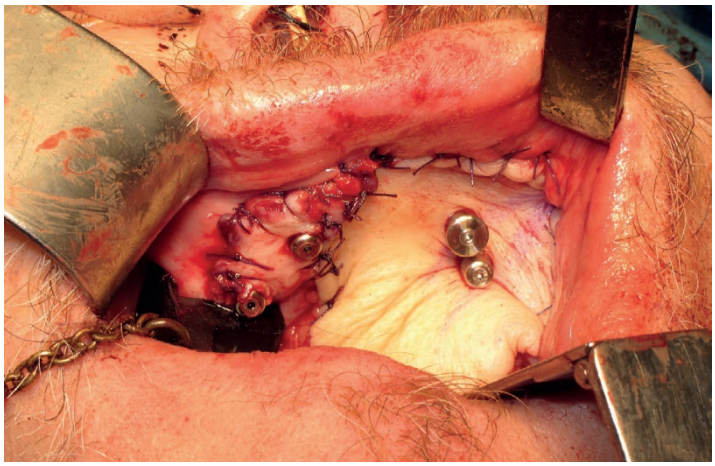

Fig. 6 ZIP flap with zygomatic implants

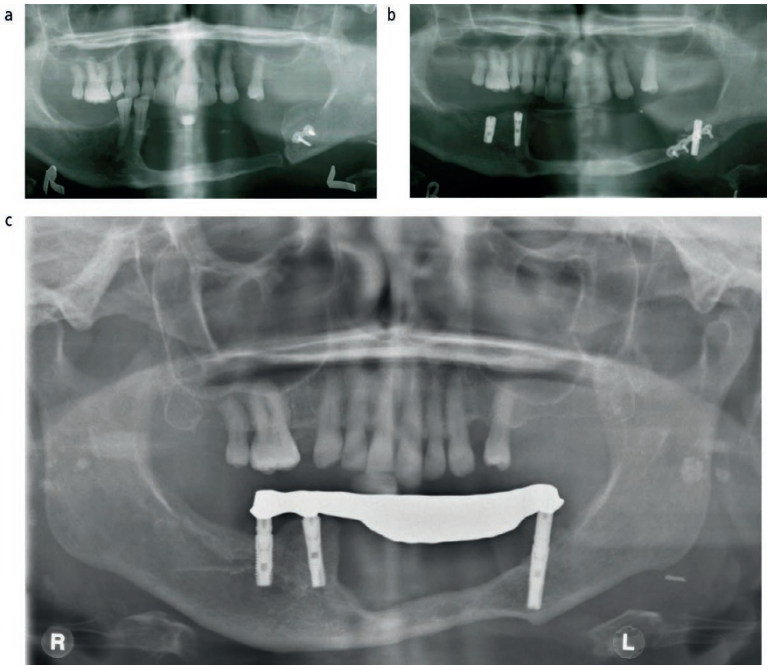

Fig. 7 Three radiographs over a 12-year period reconstructed with a composite radial free flap

Fig. 8 Radial forearm repair of squamous cell carcinoma of right tonsil/retromolar region. A conventional mandibular complete denture was provided

CADCAM milled titanium beam which supports a hybrid superstructure replacing soft and hard tissue. When *in situ* the prosthesis acts like a fixed prosthesis with no mobility, yet allows access for cleaning.

A novel maxillary reconstructive approach has been described by Butterworth and Rogers, placing zygomatic implants at primary surgery into the malar buttresses in conjunction with a soft tissue radial forearm free flap, termed the zygomatic implant perforated (ZIP) flap.[25] This results in surgical closure of the defect at resection and rapid rehabilitation with a fixed implant-supported prosthesis (Fig. 6).

Midface defects can sometimes encompass both maxillectomy and craniofacial elements which are very challenging for both surgeons and prosthodontists, involving not only the replacement of oral structures but sometimes an eye and/or nose.

Mandibular reconstruction

Mandibular reconstruction often involves floor of mouth and tongue resections. Excision of these highly mobile tissues can cause significant functional problems if the tissues are not replaced. The fascio-cutaneous radial forearm free flap is most commonly used to reconstruct these soft tissues, with reported success rates of 94.5%.[10] Figure 7 shows an anterior floor of mouth reconstruction for a squamous cell carcinoma resected in 1995 using a composite radial forearm flap to replace the lost bone and mandible. Unfortunately, as evidenced on the radiograph, the plate uniting the pieces of bone had fractured and this has resulted in fibrous union. From a rehabilitative perspective, the radius has insufficient bone volume of poor quality to preclude implant placement and even support a removable prosthesis. A novel approach was used in this case where the remaining mandibular teeth were sacrificed and three dental implants placed. As the inferior dental nerve was sacrificed at primary surgery, this allowed the distal implant to be placed at this location and depth. The implants were restored by a milled gold bar technique outlined in the article by Ali *et al.*, and the patient followed up for the next sixteen years, during which time complete function was maintained.[26] The final radiograph (Fig. 7) taken appears to show radius bone growth within the free flap and this may be due to Wolff's Law, which states that bone adapts in response to changes in functional forces placed upon it in a healthy individual.[27]

If the surgical resection does not involve mandibular bone or only a partial thickness of bone is removed maintaining inferior border continuity (termed a rim resection) and the soft tissue contour is favourable, then a conventional removable approach to rehabilitation can often be utilised with good success (Fig. 8). If this is not the case then the use of mandibular implants can often assist in the construction of a functional and aesthetic prosthesis. Rogers demonstrated that oral cancer patients with implant-retained overdentures are more satisfied with their prostheses than those with just conventional dentures.[9] The placement of dental implants to retain a mandibular prosthesis must take into account whether radiotherapy has been given (including the dose and fractionation), whether there is anatomical hard and soft tissue alteration and therefore whether a fixed or removable prosthesis is indicated. It is the opinion of the authors that where possible a removable prosthesis is often preferred as this not only affords the patient better access for maintenance but also better surveillance for recurrence (Fig. 9).[26] If recurrence does occur within the vicinity of a dental implant, progression to bone is hastened by direct access down the side of the fixture.

If placing dental implants into irradiated tissue then the potential risk of osteoradionecrosis and associated potential complications must be considered. The literature would suggest the risk of developing subsequent osteoradionecrosis is around 8% (Figs 10 and 11).[28,29]

Several studies have tried to quantify the risk associated with placing implants into a previously irradiated field using a matched case-control analysis, which suggested there is a statistically significant risk difference between 50 Gy and 60 Gy.[30,31] It is suggested that following radiotherapy to the mandible that the blood supply to the bone alters from centripetal, due to damage to the inferior alveolar artery, to centrifugal, mainly through the overlying periosteum.[32] Therefore, the use of less invasive and flapless techniques to maintain or reduce the trauma and removal of the blood supply to the irradiated bone should be considered where possible and the use of mini dental implants may provide an alternative treatment modality for such patients (Fig. 12).

If a segmental resection of part of the mandible is indicated then the rehabilitation of such a defect, unless contra-indicated on health grounds, would normally involve the

Fig. 9 Squamous cell carcinoma recurrence around most distal left implant

Fig. 10 Osteoradionecrosis lingual to mandibular implants

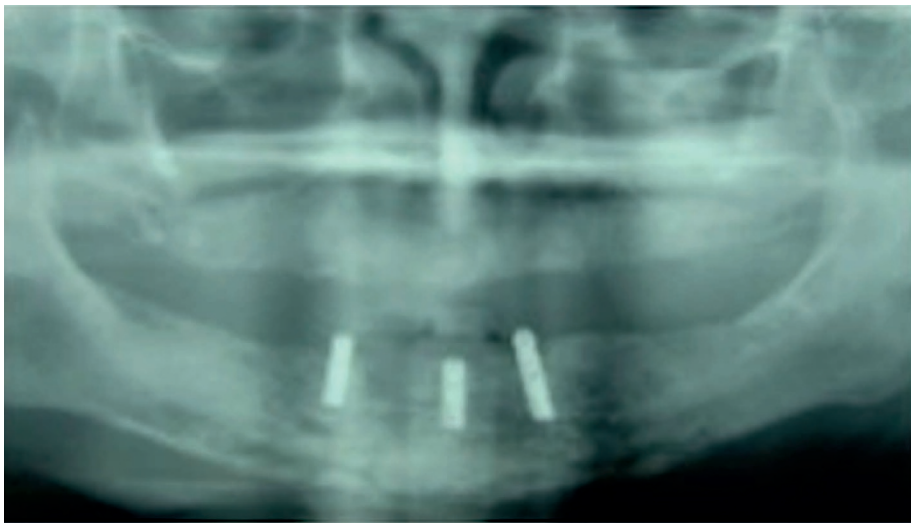

Fig. 11 Radiograph of Figure 10

Official journal of the British Dental Association.

use of composite free flaps (outlined previously), with the fibula being most commonly employed in these situations.[33] The amount of bone and its exact position is of great importance when trying to successfully rehabilitate such cases. The correct contouring of bony flaps before insertion and their bulk in relation to implant positioning can be assessed using CBCT scanning as seen in Figure 13. This allows the ideal 'crown down' approach to implant placement and facilitates dental reconstruction. Figure 14 shows a scapula free flap carrying an implant-supported rehabilitation in an ideal arch shape and occlusion.

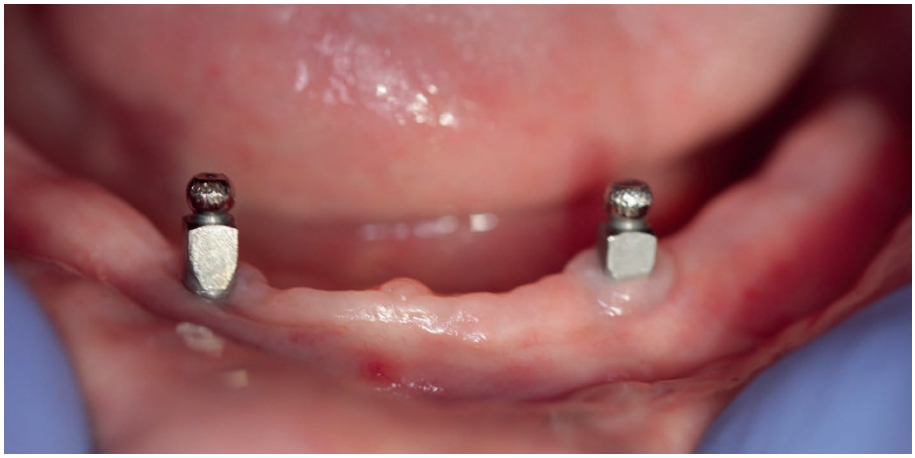

Fig. 12 Mini dental implants into an irradiated mandible (ten years post placement)

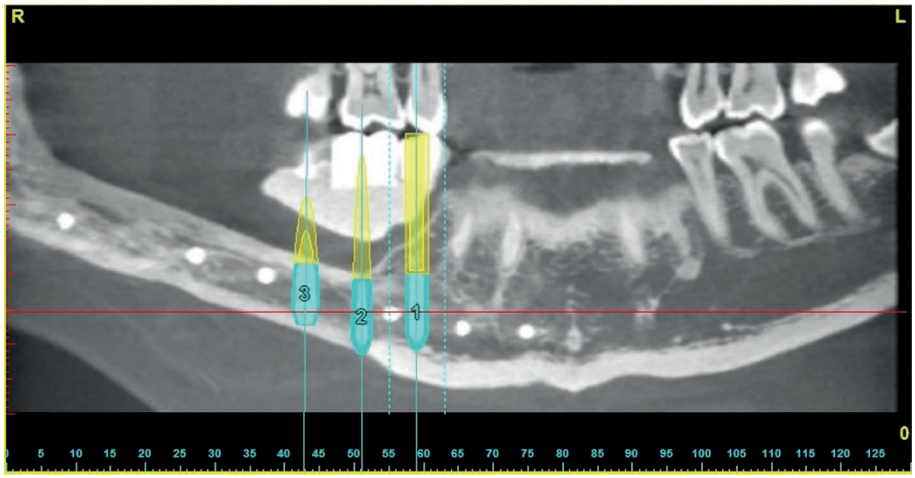

Fig. 13 Dental implant planning into a scapula free flap

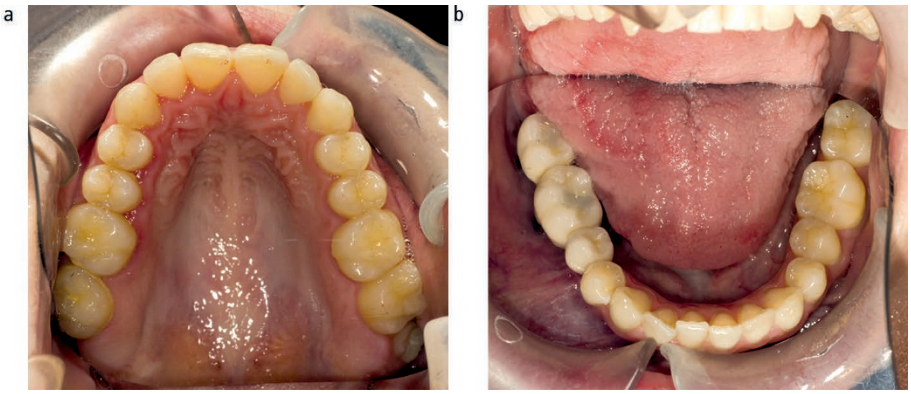

Fig. 14 Final reconstruction of case (Figure 13)

Conclusions

The psychological and physical well-being of oral cancer patients is dependent on integrated planning by the multidisciplinary team at the outset, regarding both management of the primary cancer and the most ideal method of oral rehabilitation for that specific patient (Fig. 15). All the risks and benefits involved in the various rehabilitation options should be fully explained to patients when they commence their cancer journey (Fig. 16). All dental team members should have a basic understanding of oral cancer management, to ensure the most appropriate long-term care and follow up for each patient in the most suitable environment, optimising their oral health and quality of life.

1. National Cancer Intelligence Network. Profile of Head and Neck Cancers in England: Incidence, Mortality and Survival. 2010. Available at http://www.ncin.org.uk/cancer_type_and_topic_specific_work/cancer_type_specific_work/head_and_neck_cancers/head_and_neck_cancer_hub/resources (accessed June 2018).
2. Beumer J, Curtis T A, Marunick M T. *Maxillofacial Rehabilitation: Prosthodontic and Surgical Considerations*. Second edition. University of Michigan: Ishiyaku EuroAmerica, 1996.
3. List M A, Stracks J, Colangelo L *et al*. How do head and neck cancer patients prioritize treatment outcomes before initiating treatment? *J Clin Oncol* 2000; **18:** 877–884.
4. Rogers S N, Hannah L, Lowe D, Magennis P. Quality of life 5–10 years after primary surgery for oral and oro-pharyngeal cancer. *J Craniomaxillofac Surg* 1999; **27:** 187–191.
5. Rogers S N, Lowe D, Brown J S, Vaughan E D. The University of Washington head and neck cancer measure as a predictor of outcome following primary surgery for oral cancer. *Head Neck* 1999; **21:** 394–401.
6. Rogers S N, El-Sheikha J, Lowe D. The development of a Patients Concerns Inventory (PCI) to help reveal patients concerns in the head and neck clinic. *Oral Oncol* 2009; **45:** 555–561.
7. Wells M, Cunningham M, Lang H *et al*. Distress, concerns and unmet needs in survivors of head and neck cancer: a cross-sectional survey. *Eur J Cancer Care* 2015; **24:** 748–760.
8. Allison P J, Locker D, Feine J S. The relationship between dental status and health-related quality of life in upper aerodigestive tract cancer patients. *Oral Oncol* 1999; **35:** 138–143.
9. Rogers S N, McNally D, Mahmoud M, Chan M F, Humphris G M. Psychologic response of the edentulous patient after primary surgery for oral cancer: a cross-sectional study. *J Prosthet Dent* 1999; **82:** 317–321.
10. Brown J S, Magennis P, Rogers S N, Cawood J I, Howell R, Vaughan E D. Trends in head and neck microvascular reconstructive surgery in Liverpool (1992–2001). *Br J Oral Maxillofac Surg* 2006; **44:** 364–370.
11. National Institute for Clinical Excellence (NICE). Improving Outcomes in Head and Neck Cancers: The Manual. London: National Institute for Clinical Excellence, 2004.
12. Butterworth C, McCaul L, Barclay C. Restorative dentistry and oral rehabilitation: United Kingdom National Multidisciplinary Guidelines. *J Laryngol Otol* 2016; **130:** S41–S44.
13. Bruins H H, Jolly D E, Koole R. Preradiation dental extraction decisions in patients with head and neck cancer. *Oral Surg Oral Med Oral Pathol Oral Radiol Endod* 1999; **88:** 406–412.
14. Grobbelaar E J, Owen S, Torrance A D, Wilson J A. Nutritional challenges in head and neck cancer. *Clin Otolaryngol Allied Sci* 2004; **29:** 307–313.

Fig. 15 Treatment options available regarding rehabilitation or no rehabilitation

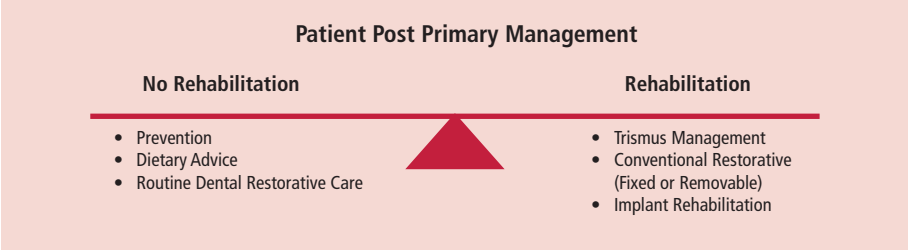

Fig. 16 Risks versus benefits of restorative intervention

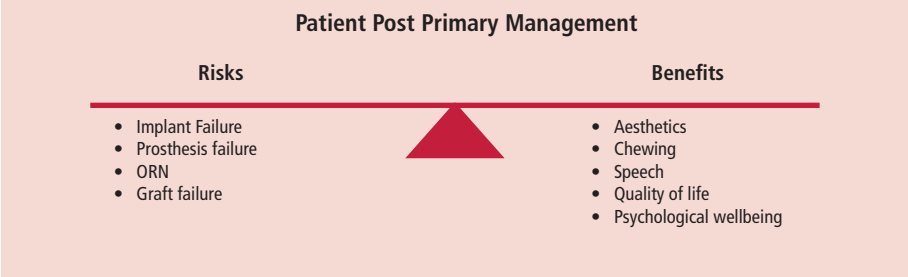

15. Noone J, Barclay C. Head and Neck Cancer Patients – Information for the General Dental Practitioner. *Dent Update* 2017; **44:** 209–210, 213–215.
16. Brown J S, Shaw R J. Reconstruction of the maxilla and midface: introducing a new classification. *Lancet Oncol* 2010; **11:** 1001–1008.
17. Frame R T, King G E. A surgical interim prosthesis. *J Prosthet Dent* 1981; **45:** 108–110.
18. Lapointe H J, Lampe H B, Taylor S M. Comparison of maxillectomy patients with immediate *versus* delayed obturator prosthesis placement. *J Otolaryngol* 1996; **25:** 308–312.
19. Jacobs J R, Marunick M T. Surgical considerations in maxillofacial prosthetic rehabilitation of the maxillectomy patient. *J Surg Oncol* 1988; **37:** 29–32.
20. Aramany M A. Basic principles of obturator design for partially edentulous patients. Part I: classification. *J Prosthet Dent* 1978; **40:** 554–557.
21. Aramany M A. Basic principles of obturator design for partially edentulous patients. Part II: design principles. *J Prosthet Dent* 1978; **40:** 656–662.
22. Brown J S, Jones D C, Summerwill A *et al*. Vascularized iliac crest with internal oblique muscle for immediate reconstruction after maxillectomy. *Br J Oral Maxillofac Surg* 2002; **40:** 183–190.
23. Sharma A B, Beumer J III. Reconstruction of maxillary defects: the case for prosthetic rehabilitation. *J Oral Maxillofac Surg* 2005; **63:** 1770–1773.
24. Urken M L, Buchbinder D, Weinberg H, Vickery C, Sheiner A, Biller H F. Primary placement of osseointegrated implants in microvascular mandibular reconstruction. *Otolaryngol Head Neck Surg* 1989; **101:** 56–73.
25. Butterworth C J, Rogers S N. The zygomatic implant perforated (ZIP) flap: a new technique for combined surgical reconstruction and rapid fixed dental rehabilitation following low-level maxillectomy. *Int J Implant Dent* 2017; **3:** 37.
26. Ali R, Al-Khayatt A, Barclay C. The use of dental implants, cast bars and sleeve overdentures in oral cancer patients. *Br Dent J* 2018; **224:** 605–613.
27. Birkhold A I, Razi H, Duda G, Weinkamer R, Checa S, Willie B M. The influence of age on adaptive bone formation and bone resorption. *Biomaterials* 2014; **35:** 9, 290–299, 301.
28. Marx R E. Osteoradionecrosis: a new concept of its pathophysiology. *J Oral Maxillofac Surg* 1983; **41:** 283–288.
29. Ch'ng S, Skoracki R J, Selber J C *et al*. Osseointegrated implant-based dental rehabilitation in head and neck reconstruction patients. *Head Neck* 2016; **38:** E321–E327.
30. Tsai C J, Hofstede T M, Sturgi s E M *et al*. Osteoradionecrosis and radiation dose to the mandible in patients with oropharyngeal cancer. *Int J Radiat Oncol Biol Phys* 2013; **85:** 415–420.
31. Sammartino G, Marenzi G, Cioffi I, Teté S, Mortellaro C. Implant therapy in irradiated patients. *J Craniofac Surg* 2011; **22:** 443–445.
32. Bras J, de Jonge H K, van Merkesteyn J P. Osteoradionecrosis of the mandible: pathogenesis. *Am J Otolaryngol* 1990; **11:** 244–250.
33. Brown J S, Lowe D, Kanatas A, Schache A. Mandibular reconstruction with vascularised bone flaps: a systematic review over 25 years. *Br J Oral Maxillofac Surg* 2017; **55:** 113–126.