Diagnosis and management of oral candidosis

M. A. O. Lewis*[1] and D. W. Williams[2]

In brief

Discusses the isolation and identification of *Candida* species within the mouth to enable the diagnosis of different forms of oral candidosis.

Highlights the pathogenicity of *Candida* species and the aetiology of oral candidosis.in brief Provides an overview of the clinical management of oral candidosis.

Provides an overview of the clinical management of oral candidosis.

Candida is a fungus (yeast) that is generally regarded as a normal and harmless member of the oral microbiome in humans. Should host defences against these commensals be compromised in any way then *Candida* can cause clinical signs and symptoms, which manifest as distinct forms of oral candidosis (candidiasis). *Candida albicans* is the most frequently isolated candidal species from the oral cavity, although a range of non-*C. albicans Candida* species are being increasingly encountered. The basic principle of the management of candidosis is to identify and eliminate any underlying host predisposing factor. However, in many cases, antifungal therapy will also be required as part of initial management. This article will provide an overview of the isolation, identification and pathogenicity of *Candida* species encountered within the mouth and relate these to clinical management of oral candidosis.

Introduction

Candidosis has been described since the times of Hippocrates (*circa* 460–370 BC), being referred to as '*a disease of the diseased*', which highlights the opportunistic nature of the infection and the primary role of a reduced host defence in its development. *Candida* is a type of fungus (yeast), that is frequently encountered in the mouth of healthy individuals and as such this microorganism is considered to be a member of the normal oral microbiome. The incidence of oral candidal carriage within the general population has traditionally been reported to be between 35%-80%, depending on the specific cohort studied.[1,2] However, these findings have historically been based on cultural studies. More recently, the use of molecular detection methods would suggest that *Candida* species are in fact present in the mouths of all individuals.[3] In addition, other fungal species, including *Saccharomyces*, *Geotrichum* and *Cryptococcus* species have on rare occasions been isolated from the mouth (Table 1), but their numbers are generally limited and they have not been implicated in specific oral infection.[4]

It is important to recognise that oral candidosis is not a single infection entity, and traditionally, four distinct forms of primary oral candidosis are described based on clinical presentation.[5] The reasons why a particular individual patient may present with one form of infection as opposed to another are unclear, especially since all forms are seemingly caused by the same fungal species. It is likely that a combination of host factors and microbial factors will ultimately determine the occurrence of a particular form of oral candidosis. What is also evident is that *Candida albicans*, which is most often the cause of oral candidosis, is an extremely heterogeneous species, whose strains differ markedly, both phenotypically and genotypically. Thus, *Candida* strain variation could also be an influencing factor on whether an individual actually manages to clear the colonising strain or whether it is retained as a commensal. It is conceivable that strain variation could promote pathogenesis through elevated expression of virulence determinants and by affecting the nature of host immune responses. On rare occasions *Candida* can enter the blood stream and be disseminated to many organs with resultant life threatening infection.[5] Such systemic candidal infection is beyond the scope of this article.

While *Candida* species are normally harmless residents of the mouth, when conditions alter to an environment that favours proliferation of *Candida*, a shift to a 'pathogenic' relationship with the host may occur. Infection with *Candida* is described in the literature as a candidosis (candidoses, pl) or candidiasis (candidiases, pl). Both terms are widely used, although candidosis is preferred due to its consistent use of the 'osis' stem with the terminology for other fungal infections. The term *Candida* originates from the Latin word '*candidus*', meaning white.

Identity and pathogenicity

The most prevalent *Candida* species recovered from both healthy and infected human mouths is *C. albicans*, and it is estimated that this species is responsible for over 80% of oral fungal isolates. In terms of prevalence, *C. albicans* is followed in descending order

[1]Professor of Oral Medicine, [2]Professor of Oral Microbiology, School of Dentistry, Cardiff University, Heath Park, Cardiff, CF14 4XY
*Correspondence to: Mike Lewis
Email: lewismao@cardiff.ac.uk

Refereed Paper. Accepted 25 August 2017
DOI: 10.1038/sj.bdj.2017.886

Table 1 Fungal species recovered from the human mouth

Candida species	Non-candida species
Candida albicans	*Paracoccidioides brasiliensis*
Candida glabrata	*Aspergillus species*
Candida tropicalis	*Cryptococcus neoformans*
Candida krusei	*Histoplasma capsulatum*
Candida lusitaniae	*Mucor species*
Candida dubliniensis	*Saccharomyces species*
Candida kefyr	*Geotrichum species*
Candida guilliermondii	*Rhizopus species*
Candida parapsilosis	

Table 2 Sampling methods for recovery of *Candida* from the mouth

Sampling method	Advantage	Disadvantage
Whole saliva	Sensitive; viable organisms isolated	Problems may occur with collection of sample; not site specific
Oral rinse	Quantitative; viable cells obtained	Not site specific
Swab	Simple to use; viable cells isolated; site specific	Not quantitative
Smear	Simple to use; not reliant on culture	Viable cells not obtained; species identity not readily confirmed
Imprint	Quantitative; viable cells obtained; site specific	Some sites difficult to sample
Biopsy	Essential for chronic hyperplastic candidosis	Invasive; not appropriate for other forms of candidosis

by *C. glabrata*, *C. krusei*, *C. tropicalis*, *C. guilliermondii*, *C. kefyr* and *C. parapsilosis*. Even less frequently encountered are *C. inconspicua*, *C. lusitaniae*, *C. norvegensis* and *C. rugosa*. In recent years, the importance of these non-*Candida albicans Candida* species in human disease has increasingly been recognised. While these species typically lack the range of virulence factors encountered with *C. albicans*, they have come to prominence due to their enhanced resistance to antifungal agents. *Candida dubliniensis* was first described in 1995, following its co-isolation with *C. albicans* from cases of oral candidosis in HIV-infected individuals.[7] Since *C. dubliniensis* shares a number of unique phenotypic characteristics with *C. albicans*, its mis-identification as *C. albicans* has probably occurred frequently.

The transition of *Candida* from a harmless commensal to a pathogen is complex and most likely relates to local environmental changes in the host that promote either increased growth of *Candida* or altered expression of its virulence factors. It is becoming increasingly acknowledged that as well as interaction between host factors and *Candida*, the bacterial component of the oral microbiome is also involved in the development of oral candidosis.[8] When considering *Candida* virulence factors, it is important to note that a number of these do not directly induce damage to host tissues, but will influence lifestyle of *Candida*, which indirectly promote pathogenicity.[9]

In order to cause oral candidosis, *Candida* has to be retained within the mouth. Consequently, a key virulence attribute of *Candida* is its ability to adhere to host surfaces. In the mouth, this allows *Candida* to resist removal from the effects of salivary flow and swallowing. Adherence can be to the oral epithelium or surfaces of prosthetic devices including dentures and orthodontic appliances. In the case of oral epithelium, as cells are sloughed off during the constant replacement of the oral mucosa, *Candida* will be removed and swallowed. Therefore, its ability to grow on the surface at a rate that at least is in equilibrium to loss of cells is vital to its persistence. Furthermore, mucosal surfaces can readily be recolonised from chronic reservoirs of *Candida* on intra-oral devices, in particular acrylic dentures, the surfaces of which obviously lack the ability to overcome colonisation by renewal. Once attached to host surfaces, *Candida*, and in particular *C. albicans*, can switch from yeast to filamentous forms, which may facilitate epithelial penetration. This property, coupled with an increased resistance to phagocytosis, will promote persistence of *Candida* in the mouth.

Destruction of host tissues by *Candida* might occur due to the physical effect of filamentous growth into tissues. However, the invading *Candida* release extracellular hydrolytic enzymes into the local environment which also lead to tissue damage.[10] The

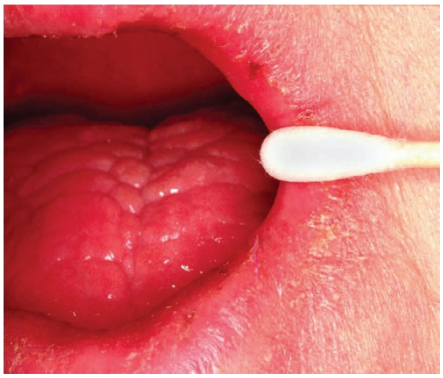

Fig. 1 Plain swab sampling of left angle

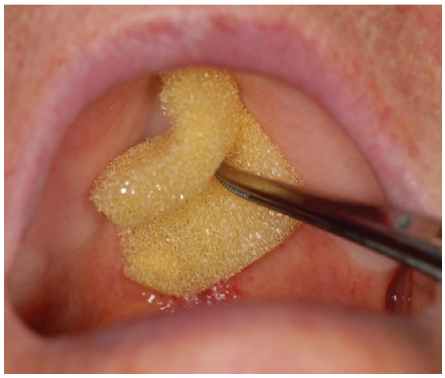

Fig. 2 Imprint sampling of hard palate

Fig. 3 Oral rinse sampling of mouth

Official journal of the British Dental Association.

enzymes most frequently implicated in the virulence of *C. albicans* are secreted aspartyl proteinases (SAPs). In addition to SAPs, enzymes categorised as phospholipases (PLs) are also viewed as virulence factors.

Isolation and identification of *Candida* from the oral cavity

A variety of techniques that enable recovery of *Candida* from the oral tissues,[4] including swab,[11] oral rinse[12] and imprint[13] (Davenport 1970) have been developed (Table 2). Each sampling method for microbial culture has its own particular advantages and disadvantages and as such the most appropriate technique for an individual patient is dependent on the lesion type and suspected clinical form of candidosis.[4]

When there is a defined lesion a direct sampling approach such as use of a swab or imprint is preferred, since both these methods will provide information on the organisms on the surface of the lesion itself. A plain microbial swab can be directly applied to lesion tissue (Fig. 1) and sent for culture. Uptake of the swab is improved if it is dampened first and rotated 360° when on the tissues. The imprint culture technique involves placement of a sterile foam–pad (ca 2.5 cm^2), which has been dipped in sterile saline, onto the lesional tissues or intra-oral appliance for 30 seconds (Fig. 2). The imprint foam pad is then placed directly onto an agar plate in the clinic before being sent to the laboratory.

Where no obvious mucosal lesion is present, then indirect sampling involving collection of whole saliva in a sterile universal container or an oral rinse method is more appropriate. The oral rinse technique involves the patient holding 10 ml of sterile phosphate buffered saline (0.01 M, pH 7.2) in the mouth for 60 seconds. The rinse is then collected in a sterile universal container, which is then labelled and sent for culture (Fig. 3). The sample is concentrated (10-fold) by centrifugation before inoculation onto agar using a spiral plating system. Growth is expressed as candidal colony forming units per ml (cfu/ml) of the rinse. The quantitative nature of the oral rinse also permits differentiation between the level of up to 100 cfu/ml, which is considered to be 'commensal carriage', and higher levels which can be regarded as 'pathogenic'.

Samples for *Candida* detection are traditionally inoculated onto Sabouraud dextrose agar (SDA) and incubated aerobically at 37 °C for 24-48 hours.[13] The vast majority of candidal species cultured on SDA will appear as white/cream colonies and therefore subsequent tests are required to identify isolates to species level (Fig. 4). Chromogenic media (Fig. 5), on which various *Candida* species grow as different colony colours are now available. These differential media provide presumptive identification of certain *Candida* species based on colony appearance and colour following primary culture. The advantage of such media is that the presence of multiple *Candida* species in a single sample can be determined, which may be important in selecting subsequent treatment options, in particular choice of antifungal therapy.

Definitive identification of *Candida* can be made through a variety of supplemental tests usually involving evaluation of morphological and physiological characteristics of an isolate. Biochemical identification of *Candida* is primarily based on carbohydrate assimilation, with a range of commercial systems available to facilitate such tests. Identification is determined by the profile of carbohydrates able to support growth of the test isolate. Increasingly, molecular-based methods are being employed with a number of species-specific polymerase chain reaction (PCR) approaches for *Candida* being used.[4]

The presence of *Candida* on the mucosal surface of the mouth or an intra-oral appliance can easily be confirmed for the vast majority of cases of pseudomembranous candidosis and erythematous candidosis by use of one of microbial culture based techniques. In contrast, a tissue biopsy is required for definitive diagnosis of chronic hyperplastic candidosis, since it is necessary to demonstrate invasion of the epithelium by *Candida* by histological staining using the periodic acid-Schiff (PAS) technique or Gomori's methenamine silver stains. Molecular techniques have also been used to identify candidal species within formalin fixed paraffin embedded tissue.[15]

Antifungal agents

Relatively few antifungal drugs are available compared with the wide range of antibiotics for bacterial infections, which probably reflects the difficulty involved in developing an agent with activity against a eukaryotic cell type without inherent problems of associated host toxicity. Antifungal drugs can be classified into four types according to mode of action and target:

1. Disruption of fungal cell membranes, as in polyene antifungals (nystatin and amphotericin)
2. Inhibition of ergosterol synthesis, in the azole group of antifungals (fluconazole and itraconazole)
3. Inhibition of β-1,3 D-glucan synthetase enzymes in the echinocandin antifungals (caspofungin)
4. Interference with RNA synthesis and DNA replication (flucytosine).

Fig. 4 Incubated Sabouraud dextrose agar plate inoculated with oral rinse using a spiral plating system and yielding a heavy growth of *Candida* species

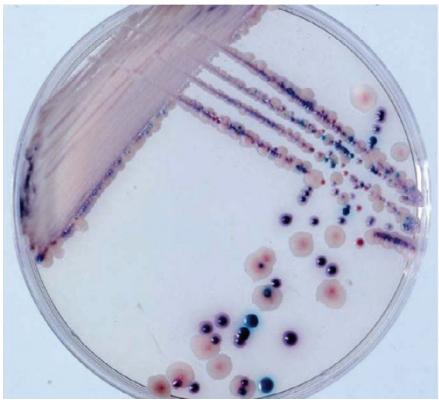

Fig. 5 Incubated CHROMagar Candida plate yielding a mixed growth of *C. albicans* (green), *C. tropicalis* (blue), *C. krusei* (pale) and *C. glabrata* (mauve)

Polyenes were developed in the 1950s and were the first true antifungal agents. These drugs are fungicidal and act by inducing cell membrane porosity following interaction with the ergosterol component of the membrane, and the subsequent effect of loss of cytoplasmic content. Polyenes have a broad spectrum of antifungal activity, but due to their poor absorption through the gut their use in dentistry is limited to topical delivery. Intravenous delivery of amphotericin is an option for serious life threatening forms of systemic candidal infection, but is associated with significant side effects and toxicity. Until

the advent of the azoles, polyenes were the only practical option for treatment of all forms of oral candidosis. The efficacy of topical polyenes in the mouth is limited due to difficulty in maintaining sufficient levels of the antifungal agent in the environment of the candida. This is further complicated by the unpleasant taste of polyenes, which stimulates salivary flow, thereby diluting salivary levels of the drug below therapeutic levels. Pharmaceutical companies have now ceased manufacturing topical forms of amphotericin and all but one format (suspension) of nystatin. Despite widespread use over the past six decades, the incidence of resistance to polyenes by *Candida* is rare, but can sometimes arise through a reduction in the ergosterol content of cell membranes.[16]

Azole antifungals became available for clinical use in the 1980s. These drugs are fungistatic and act through interference with a fungal enzyme, lanosterol demethylase, which is key to the biosynthesis of ergosterol component of the cell membrane. Miconazole is available in cream or ointment format and in combination with a steroid anti-inflammatory. All these formats of miconazole can only be used topically. In contrast, other azoles including ketoconazole, fluconazole and itraconazole, are well absorbed through the gut and were the first antifungals that could be administered systemically through oral administration. However, ketoconazole is associated with significant toxicity, which restricts its clinical use and as such this drug will not be considered any further in this article. Itraconazole and fluconazole are relatively safe and rarely associated with adverse reactions. However, there is an important drug interaction between warfarin and azole antifungal agents, including miconazole even when delivered topically.[17] Warfarin is potentiated and concomitant use can result in serious bleeding and even death. It is possible to use topical nystatin suspension in patients taking warfarin but, as described above, the clinical efficacy of this antifungal preparation is poor. Consideration can be given to approaching the medical staff prescribing the warfarin to see if the patient can be provided with the newer alternative oral anticoagulant drug, dabigatran, since it does not interact with fluconazole. However, the use of dabigatran instead of warfarin may not be appropriate or possible, which does create a dilemma when trying to manage significant oral candidal infection in a patient taking warfarin.

Another commonly encountered potential drug interaction involving azole antifungals is with statins. A patient prescribed fluconazole should be instructed to refrain from taking their statin for the duration of antifungal therapy, usually only seven days. Fluconazole is particularly appropriate for use in the treatment of oral candidosis since it is secreted in saliva at levels equivalent to those achieved in the blood. Fluconazole is routinely prescribed for out-patients in capsule form, but is also available as a suspension if this format of delivery is required. In addition, fluconazole can be administered intravenously.

Unfortunately, acquired resistance to azole antifungals has emerged in recent years and certain *Candida* species are also inherently resistant to these agents. There are several mechanisms of azole resistance reported and include 1) an alteration in the chemical structure of demethylase enzyme, 2) removal of the azole from the cell by multidrug transporter pumps, 3) compensation by other sterol synthesis enzymes in membrane biosynthesis. Even in the absence of a defined resistance mechanism, the *in vitro* susceptibility of a given *Candida* strain often does not often correlate with subsequent clinical outcome for patients with oral candidosis. One possible explanation for this could relate to the phenotypic differences between planktonic and biofilm cultured cells, as it is the former that are most frequently used for *in vitro* antifungal susceptibility testing.

Echinocandin antifungals and flucytosine do not have a role to play in the outpatient treatment of oral candidosis and will not be considered here.

Oral candidoses

The four distinct primary forms of oral candidosis comprise: pseudomembranous candidosis, acute erythematous candidosis, chronic erythematous candidosis (CEC) and chronic hyperplastic candidosis (CHC). Pseudomembranous candidosis (thrush) was previously classified as being either acute or chronic based on duration of signs and symptoms. However, more recently, distinction between the two has been dropped. Any form of oral candidosis can be accompanied by the presence of angular cheilitis. Each of these forms of candidal infection is associated with characteristic clinical signs and symptoms and a range of host predisposing factors (Box 1).

The clinical presentation, diagnosis and management of each type of oral candidosis is described in detail below. However, before describing specific issues related to each individual clinical form of candidosis, some general principles that apply to all need to be considered. Identification and subsequent correction of any underlying predisposing host factor is crucial in the management of oral candidosis.

The medical history will reveal any already recognised predisposing factor. However, assessment of the patient should routinely involve the following haematological tests: full blood count (FBC), serum ferritin, vitamin B_{12}, folate. Any abnormality in the FBC or haematinic deficiency needs to be investigated further and the cause identified. Iron deficiency anaemia or pernicious anaemia are found relatively frequently in patients with candidosis and correction usually leads to resolution of infection. The basis of this association is not clear but may be due in part to the involvement of iron or vitamain B_{12} in epithelial cell formation in the oral mucosa or antimicrobial aspects of the host defence systems. Undiagnosed or poorly controlled diabetes is often an underlying problem in candidal infection and therefore blood glucose and haemoglobin A1c (HbA1c) need to be measured. Establishment of good glycaemic control and maintenance of blood glucose (<10 mmol/L) is key in the management of oral candidosis, but unfortunately many patients have difficulty achieving this. Tobacco smoking is associated with oral candidosis, in particular chronic hyperplastic candidosis. Any patient with a tobacco habit should be advised on smoking cessation.

In some instances, a recognised predisposing factor cannot be eliminated, such as the essential use of immunosuppressive drug

Box 1 Host related predisposing factors associated with oral candidosis

Local host factors

- Intra-oral appliance (in particular, denture)
- Steroid inhaler use
- Reduced salivary flow (including post radiotherapy)
- Carbohydrate rich diet.

Systemic host factors

- New born or elderly
- Endocrine disorders (in particular, diabetes)
- Immuno-suppression or immunodeficiency
- Broad spectrum antibiotic therapy
- Nutritional deficiency

Official journal of the British Dental Association.

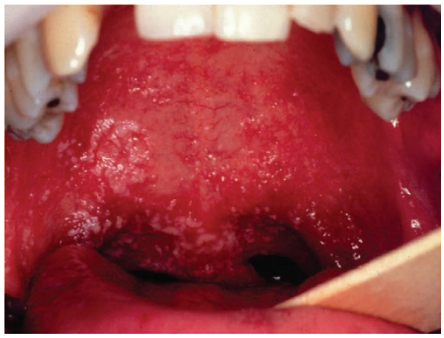

Fig. 6 Pseudomembranous candidosis presenting as removable white plaques in the soft palate

therapy in solid organ transplantation or presence of HIV. In such circumstances the role of antifungal therapy in management of candidosis has special relevance.

Pseudomembranous candidosis

Pseudomembranous candidosis is synonymous with the term 'oral thrush' and is characterised by the presence of superficial white plaques that are easily removed by gentle scraping of the lesion[18] (Fig. 6). The ability to remove these plaques is an accepted diagnostic feature that differentiates pseudomembranous candidosis from the other forms of white patches that develop in the mouth. Microscope examination of a stained smear taken from these plaques reveals fungi in yeast and filamentous forms, together with epithelial cells. Alternatively, a swab from the white patches can be sent for culture and this can be used to identity the *Candida* species present.

The pseudomembranous candidosis form of candidosis is most frequently associated with use of steroid therapy. It is also found relatively frequently in neonates. There is a direct relationship with immunodeficiency, and pseudomembranous candidosis is a recognised presenting feature and ongoing complication of leukaemia and HIV infection. In such instances, long-term use of antifungal agents is often successful.

The vast majority of cases of pseudomembranous candidosis seen in primary dental care will be due to the use of inhaled steroids. Antifungal therapy in the form of fluconazole, 50 mg, once daily for seven days, with appropriate considerations (see above), should be prescribed. This will reduce the candidal load to normal levels. In addition, the patient should be instructed on the need to rinse their mouth with water following inhaler use. This advice is now included on the inhaler product information leaflet.

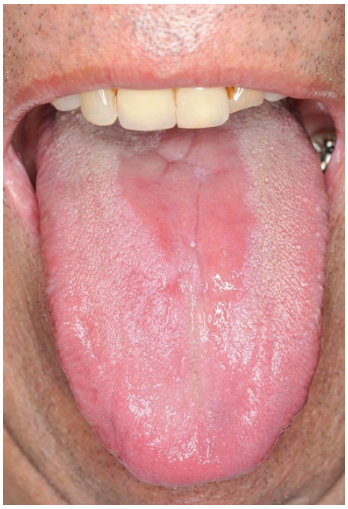

Fig. 7 Acute erythematous candidosis presenting as a red atrophic area on the dorsum of the tongue

Acute erythematous candidosis

Acute erythematous candidosis tends to develop as a consequence of a reduction in the levels of the bacterial component of the oral microflora following the receipt of broad spectrum antibiotics. Unsurprisingly the condition is therefore often referred to as 'antibiotic sore mouth'. Concomitant use of steroid therapy, particularly in inhaler form, may be an additional contributing factor as this can lead to local immunosuppression with a resulting overgrowth of *Candida*.

A reduction of bacterial numbers in the oral cavity results in a lowering of microbial competition with *Candida* in terms of nutrition and adherence sites. The clinical signs and symptoms of acute erythematous candidosis are therefore a direct consequence of an ecological shift from the normal homeostatic balance of the microbial community. Acute erythematous candidosis presents as a painful reddened lesion on the dorsum of the tongue (Fig. 7). Confirmation of the presence of *Candida* and their identity can be made by taking a swab or imprint for culture. Cessation of antibiotic therapy results in a return to normal levels of bacteria, which subsequently resolves the candidosis without intervention. If symptoms are significant then systemic fluconazole, 50 mg once daily for seven days can be prescribed.

Chronic erythematous candidosis

Chronic erythematous candidosis is commonly referred to as *Candida*-associated denture stomatitis and presents as a reddening of the mucosa beneath the fitting surface of a denture

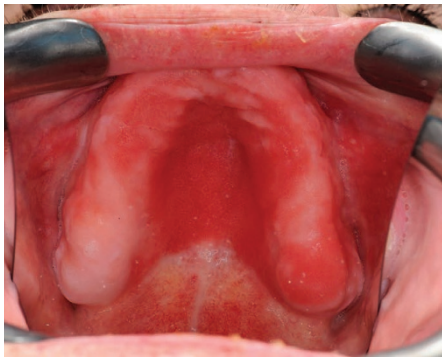

Fig. 8 Chronic erythematous candidosis presenting as red areas of the palatal mucosa

(Fig. 8). The infection may develop under any acrylic denture or indeed intra-oral appliance, but is most often encountered on the palatal rather than the mandibular mucosa. Principal host factors associated with this condition are inadequate oral hygiene, continuous wearing of the denture or the presence of a poor fitting denture.[19] Chronic erythematous candidosis is the most prevalent form of oral candidosis, with up to 75% of denture wearers having clinical signs of this condition, although often the individual is unaware of infection.[20]

Imprints or swabs taken from the fitting surface of the denture and the palatal mucosa can be used to confirm the presence of *Candida* following culture. It is important to appreciate that the *Candida* are colonising the denture and not the mucosa. Therefore, while the sample from the denture should yield candidal growth, sampling of the erythematous mucosa may be negative.

The management of this form of candidosis is primarily focused on eradication of colonisation of denture. As such, miconazole can be applied topically to the fitting surface of the denture and placed in the mouth. The denture, if there are no metal components, should be removed while sleeping and placed in dilute hypochlorite (usually overnight). Dentures with metal components should not be placed in hypochlorite, but soaked in chlorhexidine instead to avoid tarnishing of the metal. While of primary importance in the management of chronic eryhtematous candidosis, the denture hygiene measures described above should be instituted as an aspect of the treatment of all forms of oral candidosis since candidal colonisation of the acrylic componenet of the denture acts as a chronic reservoir of *Candida* species that will lead to recurrence of infection within the mouth.

Official journal of the British Dental Association.

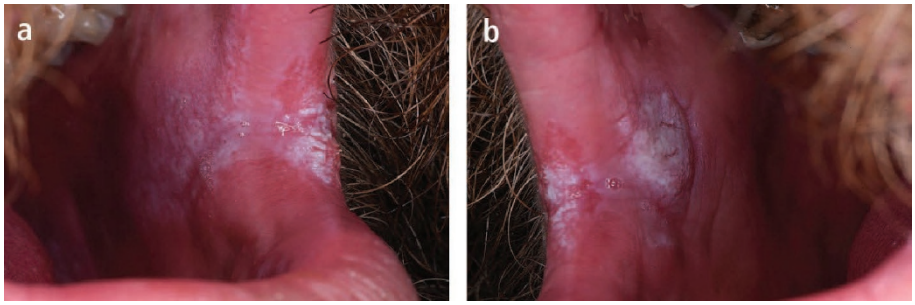

Fig. 9 Chronic hyperplastic candidosis presenting as bilateral adherent white patches in the left (a) and right (b) labial commissure regions

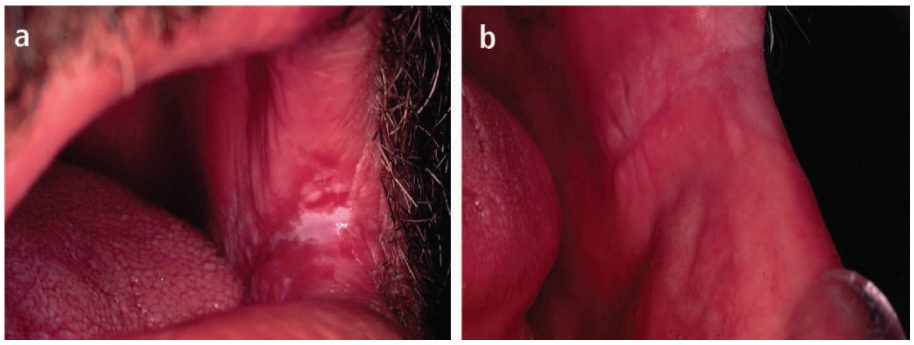

Fig. 10 Appearance of chronic hyperplastic candidosis in the left labial commissure at initial presentation (a) and after 11 days of systemic fluconazole (b)

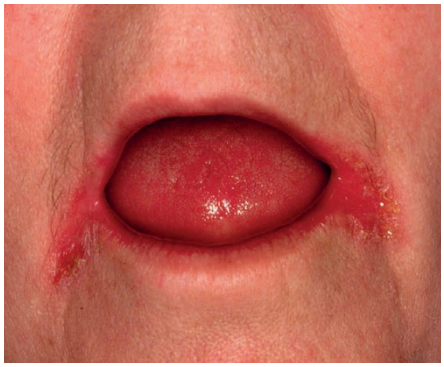

Fig. 11 Angular cheilitis presenting as bilateral painful erythematous areas at the angles of the mouth

Chronic hyperplastic candidosis (CHC)

Characteristically, CHC appears as a thickened white plaque, most frequently at the commissural region of the mouth or on the dorsum of the tongue (Fig. 9). A smoking tobacco habit is almost universally present in patients with CHC. Of concern with this infection is the proposed link with malignant change at lesional sites, although the role of *Candida* in carcinogenesis or the development of epithelial dyspasia remains unclear.[21,22] It has been suggested that it may be helpful to provide a seven day course of systemic antifungal therapy before taking a biopsy of a suspicious lesion since any epithelia dysplasia subsequently observed in the biopsy material can be interpreted as 'true' dysplasia rather than be due to the presence candida.

Two clinical types of CHC have been described based on the lesion encountered. Homogeneous CHC is described as having smooth and white lesions which are notably distinct from those of heterogeneous CHC where areas of erythema occur resulting in a nodular, speckled appearance. It has been suggested that heterogeneous lesions have the greater likelihood of malignant transformation.[23] In contrast with pseudomembranous candidosis, the white patch lesions of CHC do not rub off with gentle scraping. The diagnosis of CHC is dependent on the histological examination of lesional biopsy material which will reveal invading *Candida* hyphae.[24] There will also be a chronic inflammatory response in the underlying connective tissues. Uncertainty remains over whether candidal invasion is the primarily ecological factor of CHC or whether *Candida* infection is secondary to the presence of an altered epithelium.

Management of CHC should involve the prescribing of fluconazole 50 mg daily over a period of 7-14 days depending on the severity of the lesions (Fig. 10). In addition, the patient must stop their tobacco habit. Failure to achieve smoking cessation will inevitably result in recurrence of infection. Patients should be informed of the risk of malignant transformation.

Secondary forms of oral candidosis

Angular cheilitis presents as erythematous lesions at the angles of the mouth (Fig. 11). This form of candidosis may also be accompanied by the presence of *Staphylococcus aureus* or streptococcal species and therefore the exact role that *Candida* itself plays in the infection is difficult to ascertain.[25] Often, angular cheilitis occurs in patients with a pre-existing primary form of oral candidosis. The elevated numbers of *Candida* within the oral cavity results in direct spread and colonisation of the angles of the mouth. Treatment should involve identification and eradication of the cause of the oral candidosis. If this is achieved, then the angular cheilitis should resolve. Symptomatic treatment of the angles should involve the use of topical miconazole alone or in a combination format with hydrocortisone.

Median rhomboid glossitis is a chronic condition with a distinct clinical presentation involving a symmetrically shaped lesion on the midline of the dorsum of the tongue. *Candida* can be recovered from the surface and biopsy material. Tobacco smoking and the use of steroid inhalers seem to be predisposing host factors. The role of *Candida* in this mucosal condition is supported by the observation that provision of systemic fluconazole often results in resolution of the clinical signs and symptoms.

Chronic mucocutaneous candidosis (CMC) is a particular condition where a range of superficial *Candida* infections of mucous membranes skin and nails are encountered. The principle predisposing factor for CMC is congenital impaired cellular immunity against *Candida*.

1. Odds F C. *Candida and candidiasis*. London: Baillière Tindall, 1988.
2. Shimizu C, Kuriyama T, Williams D W *et al.* Association of oral yeast carriage with specific host factors and altered mouth sensation. *Oral Surg Oral Med Oral Pathol Oral Radiol Endod* 2008; **105:** 445–451.
3. Peters B A, Wu J, Hayes R B, Ahn J. The oral fungal mycobiome: characteristics and relation to periodontitis in a pilot study. *BMC Microbiol* 2017; **17:** 157.
4. Williams D W, Lewis M A O. Isolation and identification of *Candida* from the oral cavity. *Oral Dis* 2000; **6:** 3–11.
5. Lewis M A O, Jordan R C K. *A colour handbook of oral medicine,* 2nd ed. London: CRC Press Publishing, 2013.
6. Vazquez J A. Invasive fungal infections in the intensive care unit. *Semin Respir Crit Care Med* 2010; **31:** 79–86.
7. Coleman D C, Sullivan D J Bennett *et al.* Candidiasis: the emergence of a novel species, *Candida dubliniensis*. *AIDS* 1997; **11:** 557–567.
8. Williams D W, Kuriyama T, Silva S *et al. Candida* biofilms and oral candidosis: treatment and prevention. *Periodontol 2000* 2011; **55:** 250–265.

9. Williams D, Lewis M. Pathogenesis and the treatment of oral candidosis. *J Oral Microbiol* 2011; **3:** 1–11.
10. Naglik J, Albrecht A, Bader O *et al.* *Candida albicans* proteinases and host/pathogen interactions. *Cell Microbiol* 2004; **6:** 915–926.
11. Silverman J, Migliorati J, Epstein L *et al.* Laboratory diagnosis of oral candidosis. *In* Samaranayake L P, MacFarlane T W, (eds). Oral candidosis. London: Butterworth, 1990.
12. Samaranayake L P, MacFarlane T W, Lamey P-J *et al.* A comparison of oral rinse and imprint sampling techniques for the detection of yeast, coliform and *Staphylococcus aureus* carriage in the oral cavity. *J Oral Pathol* 1986; **15:** 386–388.
13. Davenport J C. The oral distribution of *Candida* in denture stomatitis. *Br Dent J* 1970; **129:** 151.
14. Odds F C. Sabourand('s) agar. *J Med Vet Mycol* 1991; **29:** 355–359.
15. Williams D W, Wilson M J, Lewis M A O *et al.* Identification of Candida species in formalin fixed, paraffin wax embedded oral mucosa by sequencing of ribosomal DNA. *Clin Mol Pathol* 1996; **49:** M23-M28.
16. Sanglard D, Ischer F, Marchetti O *et al.* Calcineurin A of *Candida albicans*: involvement in antifungal tolerance, cell morphogenesis and virulence. *Mol Microbiol* 2003; **48:** 959–976.
17. Pemberton M N, Oliver R J, Theaker E D. Miconazole oral gel and drug interactions. *Br Dent J* 2004; **196:** 529–531.
18. Samaranayake L P. Superficial oral fungal infections. *Curr Opin Dent* 1991; **1:** 415–422.
19. Figueiral M H, Azul A, Pinto E *et al.* Denture-related stomatitis: identification of aetiological and predisposing factors – a large cohort. *J Oral Rehabil* 2007; **34:** 448–455.
20. Barbeau J, Seguin J, Goulet J P *et al.* Reassessing the presence of *Candida albicans* in denture-related Stomatitis. *Oral Surg Oral Med Oral Pathol Oral Radiol Endod* 2003; **95:** 51–59.
21. Sitheeque M A, Samaranayake L P. Chronic hyperplastic candidosis/candidiasis (candidal leukoplakia). *Crit Rev Oral Biol Med* 2003; **14:** 253–267.
22. Walker D M, Arendorf T. Candidal leukoplakia. Chronic multifocal candidosis and median rhomboid glossitis. *In* Samaranayake L P, MacFarlane TW (eds) *Oral candidosis.* London: Butterworth, 1990.
23. Barrett A W, Kingsmill V J, Speight P M. The frequency of fungal infection in biopsies of oral mucosal lesions. *Oral Dis* 1998; **4:** 26–31.
24. Williams D W, Potts A J, Wilson M J *et al.* Characterisation of the inflammatory cell infiltrate in chronic hyperplastic candidosis of the oral mucosa. *J Oral Pathol Med* 1997; **26:** 83–89.
25. Smith A J, Robertson D, Tang M K *et al.* *Staphylococcus aureus* in the oral cavity: a three-year retrospective analysis of clinical laboratory data. *Br Dent J* 2003; **195:** 701–703.

Official journal of the British Dental Association.