

# Tooth bleaching questions answered

V. B. Haywood\*<sup>1</sup> and R. J. Sword<sup>1</sup>

## In brief

Discusses different bleaching options.

Discusses different bleaching techniques.

Explains the proper examination for bleaching.

Tooth bleaching is an exciting treatment option for patients, which has many treatment options and considerations for the dentist. The purpose of this article is to answer questions in a Q&A fashion about different types of tooth bleaching and their applications to various clinical situations and patients' dental situations.

## Questions

### What are the different bleaching options to consider?

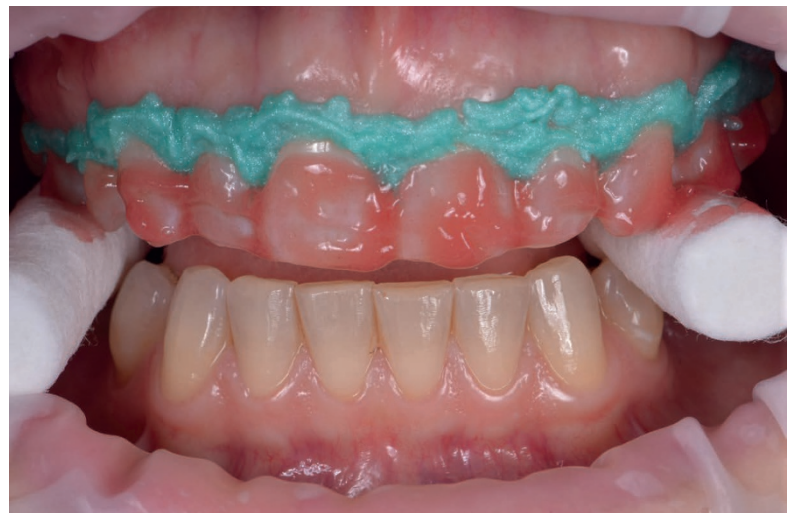There are three basic considerations/methods for bleaching teeth:

#### 1. Dentist-applied materials

In-office bleaching is the oldest form of bleaching, being over 125 years old.<sup>1</sup> The teeth are isolated in the dental operatory (rubber dam or paint-on dam), and then a high concentration of hydrogen peroxide is applied for 20–60 minutes (Fig. 1). Details of the technique vary with the concentration and company products. Some companies recommend the use of light activation, although all research has shown the light does not change the outcome of in-office bleaching.<sup>2</sup>

**Advantages:** the advantage of in-office bleaching is that the dentist is in control of the process, and patient compliance is not required, other than to identify if they feel burning or pain during the procedure.

**Disadvantages:** the problems with in-office techniques are the cost, safety and efficacy.<sup>2</sup>



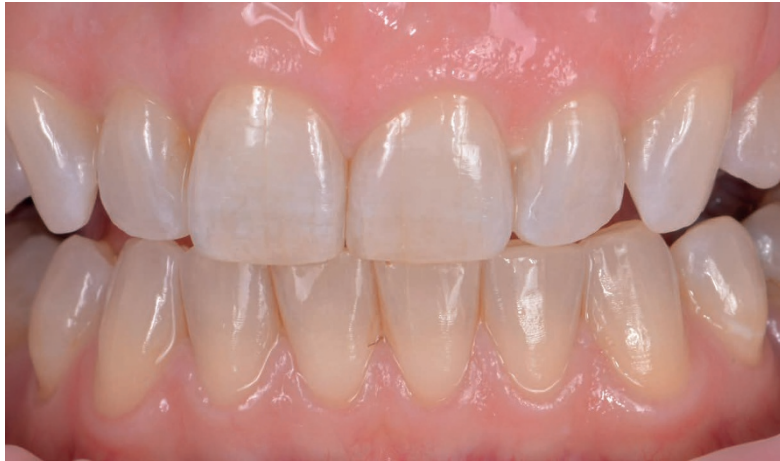**Fig. 1** Current in-office bleaching may involve a paint-on rubber dam, with a thick high-concentration hydrogen peroxide bleaching material

In-office bleaching takes an average of three visits, (1–6 range) to get a satisfactory result unless the teeth are initially lighter than Vita A2 shade.<sup>3</sup> When completing an immediate evaluation after in-office bleaching, the dentist may notice some bleaching effect but the teeth are also whiter due to dehydration from isolation. The dentist and patient will have to wait over two weeks to determine the actual colour change from any bleaching procedure, and possibly as long as six weeks for in-office bleaching. However, the outcome of in-office is not better than the tray, regardless of number

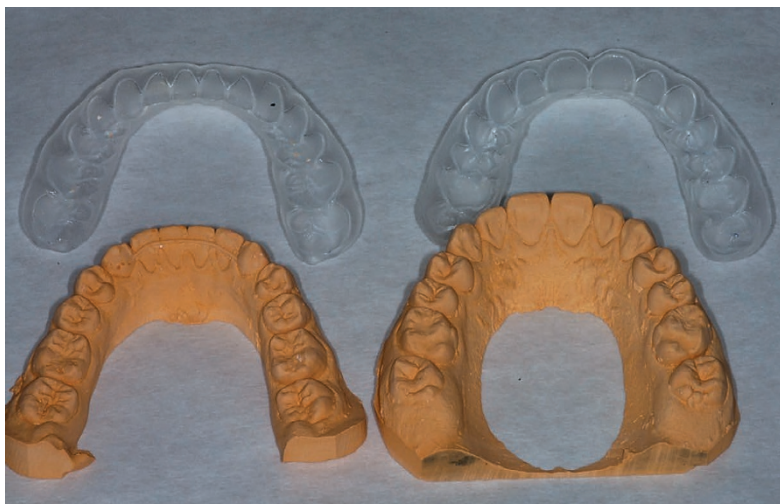of applications.<sup>4</sup> The limiting factor for any bleaching treatment is how the teeth respond, not a higher concentration or a particular product. The cost to the patient and time of use, as well as the unpredictable nature, along with tissue burns (Fig. 2) make it less popular, which is why the tray bleaching has become the standard.<sup>5</sup> In-office bleaching is best used as a single application motivator to be followed by tray application to complete the process.<sup>6</sup> Other indications for in-office bleaching are a patient who is not willing to apply other products or a pregnant female patient.

<sup>1</sup>Augusta University, Restorative Sciences, 1120 15th Street, GC-4322, Augusta, Georgia 30912-1260, USA  
\*Correspondence to: Dr Van Haywood  
Email: vhaywood@augusta.edu

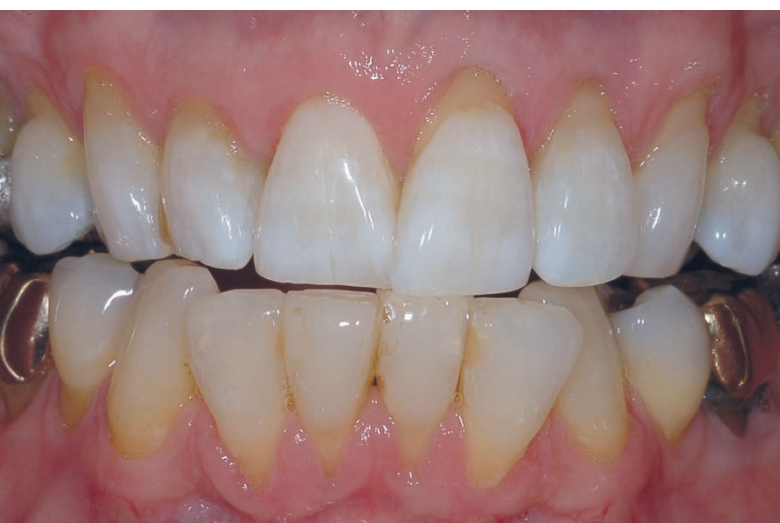Refereed Paper. Accepted 27 July 2017  
DOI: 10.1038/sj.bdj.2017.767



**Fig. 2** After in-office bleaching, there is a burn and loss of papilla between left central and lateral incisor



**Fig. 3** Tray bleaching with a 10% concentration of carbamide peroxide does not require spacers and the tray can extend 1–2 mm onto the tissue without problems



**Fig. 4** Exposed roots and existing restorations will not bleach. Patients may expect all the visible tooth to become white, so a careful explanation is required

### 2. Patient-applied materials, dentist-directed treatment

This bleaching technique consists of tray application of low concentration bleaching products. Tray bleaching was introduced in 1989 and uses the non-scalloped, no reservoir tray with 10% carbamide peroxide overnight (Fig. 3).<sup>7</sup> Later techniques have utilised hydrogen peroxide for daytime wear. The dentist performs the initial examination and constructs the custom-fitted tray. Tray application requires compliance from the patient to wear the tray during the day or night, which can be a treatment challenge. However, no other technique seems to be able to deliver such a favourable outcome due to the slow rate of change in the teeth. Most of this article will focus on the tray delivery, which has many other names such as nightguard vital bleaching, Dentist-prescribed home-applied bleaching, or tray home-bleaching.

### 3. Over-the-counter products, fully consumer-directed treatment

These products are sold directly to the consumer without benefit of a dental examination and diagnosis of the cause of discoloration.<sup>8</sup> Most are hydrogen peroxide products, although some contain carbamide peroxide. They use a variety of delivery methods, from a 'boil and form' tray to strips that are placed on the teeth.

A distinction should be made between 'bleaching' and 'whitening,' since many over-the-counter products make the claim of 'whitening' to rival dentists' 'bleaching' treatments. 'Whitening' is only removing surface stains, but 'bleaching' changes the inherent colour of the tooth.

### What is needed for a proper bleaching examination<sup>9</sup> for any bleaching treatment?

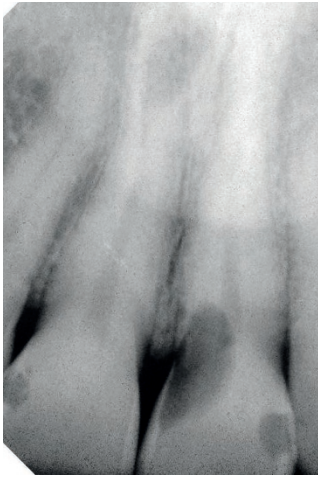
#### Intraoral exam

This standard exam allows the dentist to evaluate the cause of discoloration as well as examine soft tissue health and notice possible pathology issues.<sup>8</sup> Exposed roots and existing restorations must be documented because they will not bleach well if at all (Fig. 4). Evaluation of the existence of caries, the occlusion, the temporomandibular joint, and other aesthetic concerns completes the intraoral examination.

#### Radiographs

Evaluation of the radiographs of the maxillary anterior teeth is important in the diagnosis of the cause of discoloration and they are used to identify any pathology, especially in any single





**Fig. 5** A screening radiograph can show an underlying pathological cause for a single dark tooth, such as external resorption. (courtesy of Dr Tom McDonald)

dark teeth. The teeth could be dark from an abscess, caries, internal resorption, external resorption, a cyst or tumour. The radiographs may reveal dissimilar pulp sizes if one tooth has previously received trauma.<sup>10</sup> The secondary dentin in the smaller pulp chamber may require a longer bleaching time (Figs 5–7).

### Diagnosis

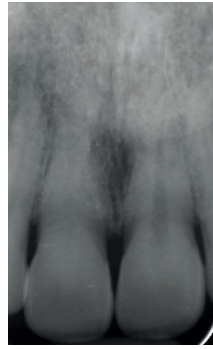
The single most important service of the dentist involves diagnosing the cause of the discoloration. The discoloration could result from aging, extrinsic staining, genetically discoloured teeth (Figs 8 and 9), tetracycline ingestion, trauma, caries, existing mismatched facial restorations, dark lingual restorations, abscessed tooth, internal or external resorption, or even thin transparent enamel from gastroesophageal reflux disease (GERD) or bruxism.

### Identify restorations

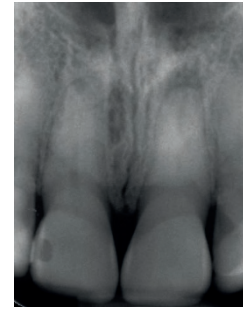
Since a restoration will not change colour from bleaching, the patient needs to be aware of all restorations that are visible in their smile, and should be financially ready to replace those that are markedly different in colour after bleaching. Some composite restorations will be cleaned of stains, and may blend in enough to not require replacement, but reliably predicting the outcome is impossible (Fig. 10).

### Smile analysis

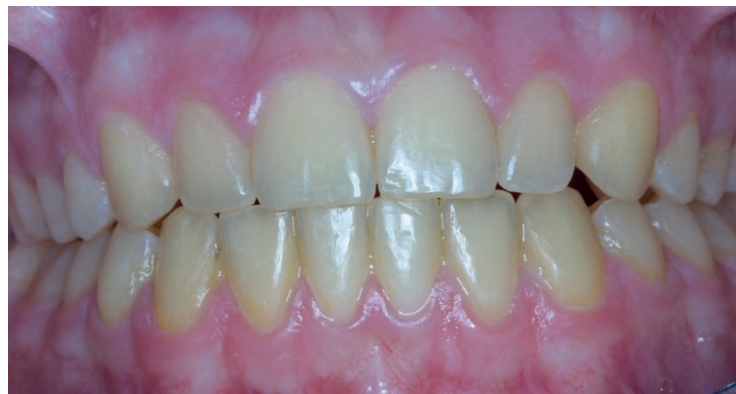Teeth look the best when they match the sclera of the eyes (Fig. 11).<sup>11</sup> Evaluation of the form and shape of the teeth will also indicate other treatments that may be needed to correct a



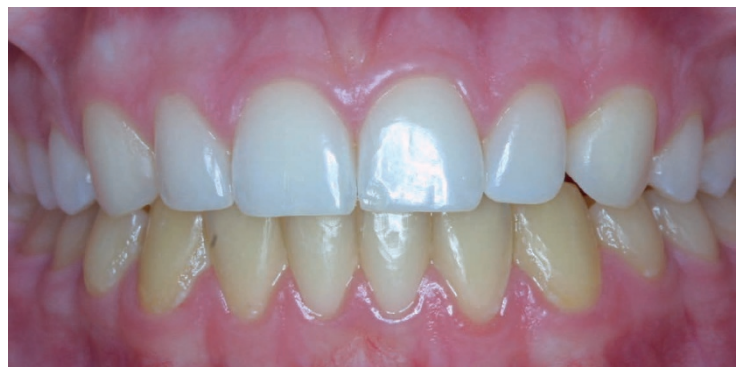**Fig. 6** Dissimilar pulp sizes due to trauma can be a cause for a single dark tooth, and must be addressed with a special tray



**Fig. 7** A screening radiograph may reveal an underlying pathological cause for a single dark tooth such as an abscessed tooth



**Fig. 8** Genetically discoloured yellow teeth, before bleaching



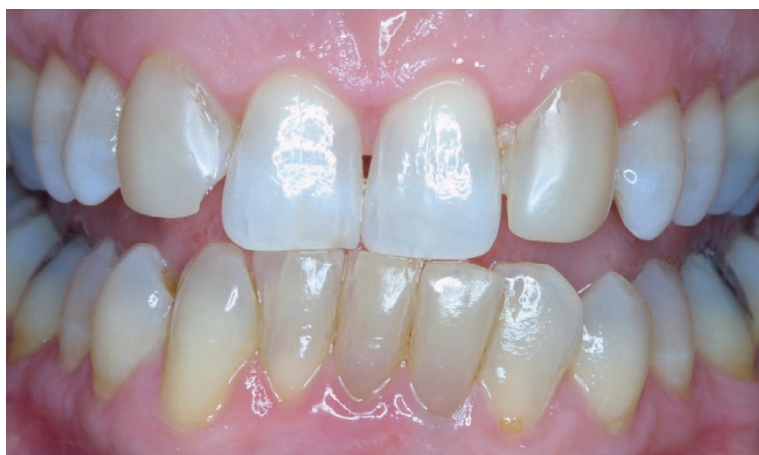**Fig. 9** Genetically discoloured teeth, six weeks of bleaching of the maxillary arch only

patient's smile. If an excessive display of the gingiva exists (gummy smile), then periodontal treatment may be appropriate, because teeth whitened in a gummy smile tend to accentuate the aesthetic problem rather than improve it.

### Sensitivity history

The single biggest detriment to bleaching is tooth sensitivity, closely followed by gingival

sensitivity. This sensitivity is related to the easy passage of peroxide through intact enamel and dentin to the pulp in 5–15 minutes,<sup>12</sup> indicating the sensitivity is a reversible pulpitis. The lower the concentration of material, the less the sensitivity is present. Patients who have the most sensitivity during bleaching usually have either a history of sensitivity or apply the material more than once a day/night.<sup>13</sup>



**Fig. 10** The central incisors bleached nicely as compared to the mandibular teeth, but the composite bonding on the lateral incisors does not change color



**Fig. 12** Potassium nitrate can be placed directly in the tray without the bleaching agent for 10–30 minutes to reduce sensitivity by calming the nerve

### Sensitivity treatment considerations

The best approach to avoid bleaching sensitivity is multi-fold. First, use a low concentration of carbamide peroxide (10% is the lowest available) containing potassium nitrate, which also penetrates the intact tooth and reduces the excitability of the nerve during the pain cycle.<sup>14</sup> Second, the patient should brush with a potassium nitrate containing toothpaste for two weeks before initiating bleaching,<sup>15</sup> as well as apply the potassium nitrate (toothpaste or professional product) in the tray for 10–30 minutes as needed (Fig. 12).<sup>16</sup> Gingival sensitivity can also be avoided by having a well-fitted tray from a proper alginate impression that does not rub the tissue while using a 10% concentration of carbamide peroxide. Mint or other irritating flavours of bleaching material should also be avoided, especially in patients with food allergies.

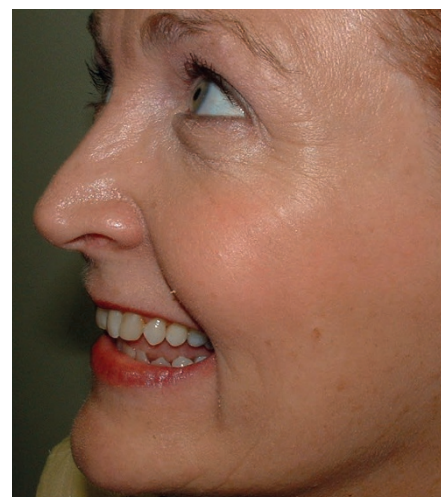### Occlusion and TMD screen

The status of the joint as well as the occlusion is an important consideration since a tray may

be used for bleaching, or the patient may have their mouth open an extended time during in-office bleaching. When fitting a tray, the patient must be able to close into the same occlusion they exhibited without the tray, or they may experience joint or muscle pain.<sup>17</sup> To adjust occlusion on the thin bleaching tray, the most terminal teeth moulds should be removed from the tray, and the occlusion re-evaluated. Anterior contact on the tray is preferred, as is in natural dentition (Figs 13–15). If the patient is a bruxer, plans for multiple trays, or use of harder materials for the tray may be indicated.

### What is the traditional dentist-supervised at-home bleaching technique?

Dentist-supervised at-home bleaching is the most common type of bleaching performed by US dentists, and consists of completing several steps successfully.<sup>5</sup> The dentist must determine that bleaching is the preferred treatment for the patient, complete a medical history and full



**Fig. 11** Teeth look best when they match the sclera of the eyes. This patient is a good candidate for bleaching, since her teeth are darker than her eyes

bleaching exam, fabricate a custom tray, complete the actual bleaching process and follow-up the patient. This bleaching process uses a custom-fitted tray of thermoplastic material and a 10% solution of carbamide peroxide. The at-home process provides longer contact time on the tooth with a lower concentration than the in-office bleaching technique. Tray bleaching has been shown to achieve excellent results and is considered to be safe. The type of bleaching material that has been approved by the American Dental Association is 10% carbamide peroxide and is considered both safe and effective.<sup>8</sup> Initial treatment of only one arch is recommended because of several advantages. These advantages include possible improved patient compliance, because the shade difference between the arches is more apparent to their untrained eyes, reduced impact on occlusion because they are not wearing two trays, and less sensitivity because less teeth are being treated. Because this single tray technique allows patients to begin the bleaching process at a reduced cost, they may be more likely to accept the treatment and have the choice to continue bleaching on the opposing arch at a later time.

### What is the difference between carbamide and hydrogen peroxide?

There are two basic classes of products used in bleaching: hydrogen peroxide and carbamide peroxide. Carbamide peroxide is composed of hydrogen peroxide and urea. Ten percent carbamide peroxide is equivalent to 3.5% hydrogen peroxide and 6.5% urea. There are similarities and differences between the two products (Table 1).

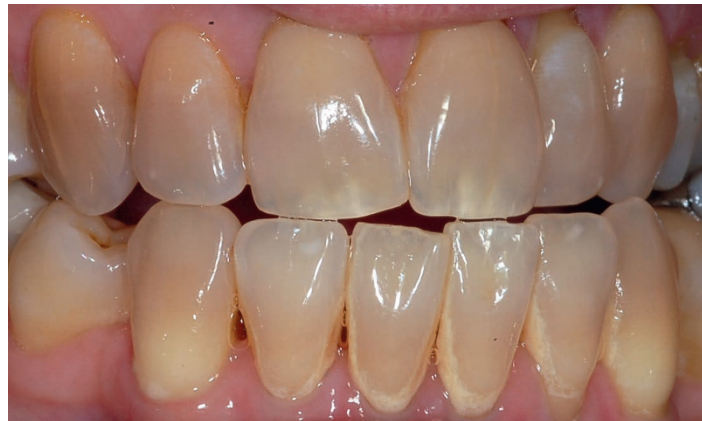

**Similarities**

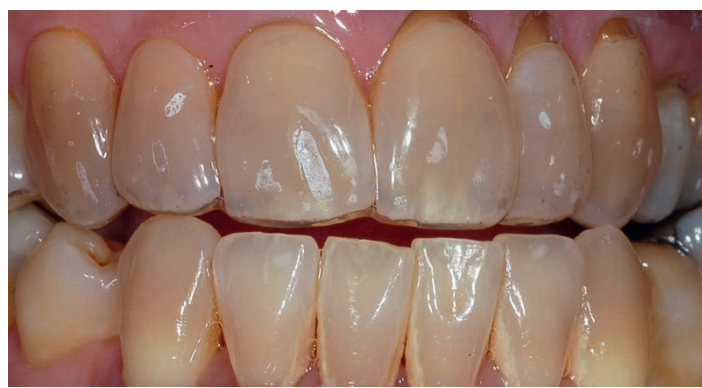They are similar because both bleach teeth supposedly by an oxidation process. Both materials go into the intact enamel and dentin within five minutes of application, and change the colour of the tooth by changing the colour of both the dentin and the enamel.<sup>18</sup> This easy passage of peroxide through intact enamel and dentin is also the cause of tooth sensitivity during bleaching; the higher the concentration of peroxide, the greater the sensitivity.<sup>19</sup> Both peroxides reduce the bond strengths of composite to enamel.<sup>20</sup> This reduction is due to the oxygen in the enamel inhibiting the set of the resin tags, causing a 25–50% reduction in bond strength if applied immediately after bleaching. The oxygen in the tooth also changes the optical qualities of the tooth, making the tooth appear whiter than it actually is, immediately after bleaching. Both materials need a minimum of two weeks delay after bleaching before bonding for both the shade to stabilise and the bond strengths to become normal as the oxygen leaves the tooth.

**Differences**

In other ways, these two products behave very differently, and will influence the patient or dentist’s approach to bleaching. Hydrogen peroxide products are only active for 30–60 minutes, designed for a short application time, usually during the day. Hydrogen peroxide has a pH of 5.0, which is below the 5.5 pH threshold allowing enamel caries to begin. Dentinal caries occurs when the pH is below 6.8, another indication that hydrogen peroxide products are only designed for a short wear time. Carbamide peroxide products are active for up to ten hours, with about 50% of the peroxide release occurring during the first two hours. They are designed for a longer application time, preferably overnight. Since carbamide peroxide contains urea, then the pH is elevated to above eight within minutes after application.<sup>21,22</sup> The elevated pH assures that the patient cannot get tooth decay when bleaching with carbamide peroxide, due to its basic nature. When comparing equivalent concentrations of carbamide peroxide and hydrogen peroxide, carbamide peroxide takes less calendar days with more hours per day; hydrogen peroxide requires more calendar days with fewer hours per day.<sup>23</sup> The dental office should be aware of the type product they are using, giving the appropriate instructions to the patient.



**Fig. 13** When the bleaching tray is not in the mouth, the patient has contact on the anterior teeth



**Fig. 14** With the bleaching tray inserted, the anterior teeth contacts are lost, indicating posterior interferences



**Fig. 15** Because the tray is too thin to adjust, premature occlusal contacts are eliminated by removing the terminal tooth on each side until anterior contact is achieved

**Table 1** Carbamide peroxide and hydrogen peroxide comparison chart

	Carbamide peroxide	Hydrogen peroxide
Time of activity	Up to 6–10 hrs	30 min – 1 hr
Wear time	Overnight (min 2–4 hrs/day)	Daytime (30 min – 1 hr)
Components	Hydrogen peroxide + urea	Hydrogen peroxide
pH	>8 pH	5.0 pH

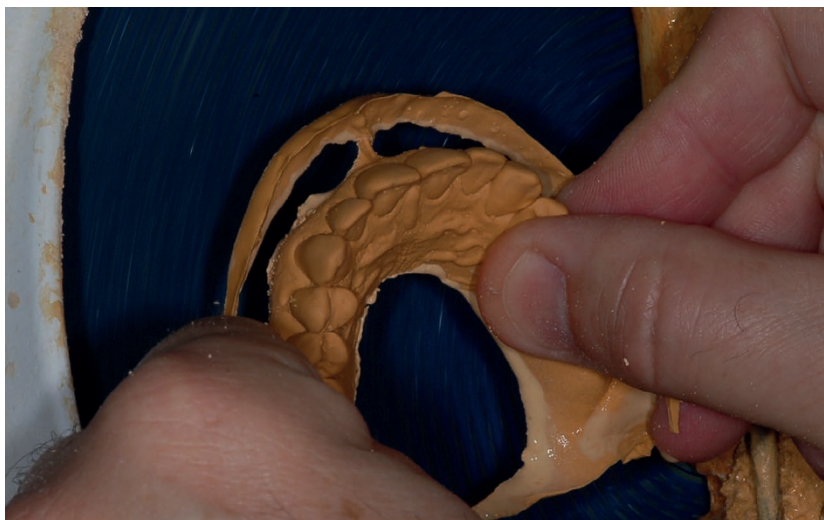### How safe is tray bleaching?

Ten percent carbamide peroxide was the first ingredient used in tray bleaching, and it has the most research in the world on safety and efficacy. Ten percent carbamide peroxide was originally an over-the-counter oral antiseptic called 'Glyoxide', which was used to promote wound healing and periodontal health. It has been classified 'generally recognised as safe' for use for the life of the patient as an oral antiseptic by the Food and Drug Administration of the United States. Many studies pre-dating its use for bleaching show the 10% CP concentration to be safe in infants for ten days of 12 applications per day for candidiasis or thrush,<sup>24</sup> youth in braces for three years as a daily mouthwash to prevent caries,<sup>25</sup> and elderly adults with dry mouth to prevent caries.<sup>26</sup> The human body actually makes peroxide in the liver, the brain, and the eyes. Humans make about 648 mg per day, and the amount of peroxide in two trays is about 3.5 mg, so the body is equipped to handle low doses of peroxide with salivary peroxidases.<sup>27</sup> The human body makes over 20 times the amount of peroxide found in a tray in the eyes, liver and brain, and hence has salivary peroxidases to decompose peroxide. This means that any small amount swallowed from a tray application should not be a problem in children or adults. As the concentrations of CP and HP increase, there are increased tissue burns and increased tooth sensitivity.

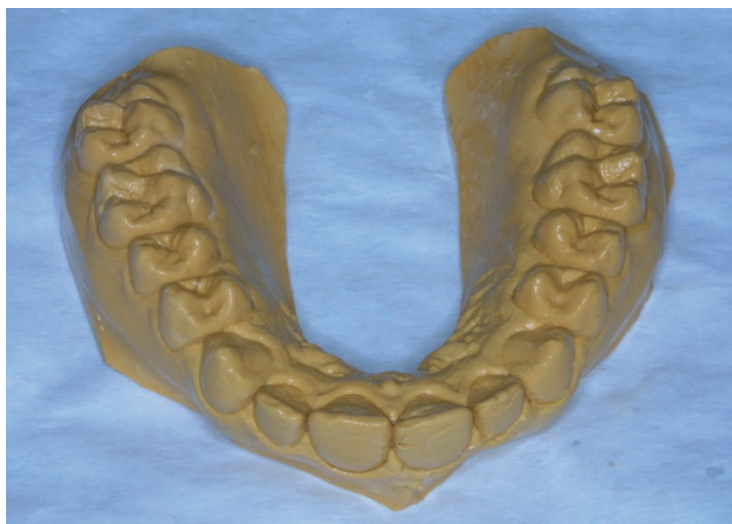### What kind of impression and cast do I need for at-home bleaching?

Once the dentist determines a patient is a good candidate for at-home bleaching, a custom-fitted tray must be fabricated.<sup>28</sup> An alginate or poly-vinyl siloxane impression can be made for the patient, depending on how soon the impression can be poured with dental stone. An impression including the palate is not needed due to the trimming method of the cast.

A bleaching cast must be trimmed aggressively, leaving very little attached gingiva and no vestibule (Figs 16 and 17). Using a traditional model trimmer, the cast should be trimmed from the base, leaving a horse-shoe shape that is as little as 1.25 cm thick, only retaining the teeth and roughly 1–3 mm of attached gingiva, with no palate or tongue space. The cast should be trimmed so that the incisors are perpendicular to the base to help avoid folds or wrinkles in the vacuum-formed thermoplastic material. If the palate or tongue space remains, a 1 cm or larger hole can be drilled in the centre to aid in the vacuum forming process.



**Fig. 16** The cast is trimmed from the bottom only, to avoid tooth damage



**Fig. 17** The cast design that works best in the vacuum-former has the central incisors vertical, no vestibule and no palate

Various types of tray materials have been used for tray fabrication. Though the original bleaching article referenced use of a thick semi-rigid material,<sup>29,30</sup> newer materials are thinner and more flexible reducing the possibilities of occlusal and gingival side effects. For example, Ultradent SofTray material is .035 mm, but that thins to .018mm during fabrication.

### Are reservoirs or spacers in the bleaching tray necessary?

Some companies have advocated creating reservoirs in the tray, which is performed by placing a light-cured flowable resin (or other material such as nail polish or die spacer) on the anterior surfaces of the teeth on the cast. Because the gel is activated by the saliva and affects the tooth at a set rate, there is little evidence that reservoirs

aid in the efficacy of the bleaching process.<sup>31</sup> It is assumed that the material degrades at the same rate in spite of the quantity of material.<sup>32</sup> Most studies show no difference in bleaching outcome,<sup>33,34</sup> so creating reservoirs could waste the bleaching gel material, and was originally designed to reduce sensitivity of the teeth to a rigid tightly fitting tray.<sup>35</sup>

### Do I need to scallop the bleaching tray?

Once the tray is fabricated using the vacuum former, the dentist must decide how to best trim the tray around the teeth. Some recommendations are to scallop the tray to avoid soft tissue contact. However, scalloping is considered unnecessary when using a low concentration of material (10% carbamide peroxide,) and may result in a less comfortable tray for



the patient. Ten percent carbamide peroxide is an oral antiseptic designed to be applied to the gingiva to promote wound healing. Hence, the tissue response generally improves when the 10% carbamide peroxide contacts the gingiva. A smooth border of the tray can be created by trimming the tray straight across, such that it extends onto gingiva about 1–3 mm apical to the tooth's clinical crown. A smooth border of the tray can help reduce fabrication time as well as reduce possible irritation to the patient's tongue and lips from the scalloping. The higher the concentration of bleaching material, the more important scalloping the tray becomes to avoid tissue irritation.

### What do I evaluate during the bleaching tray delivery appointment?

Once the tray is fabricated, the dentist needs to try the tray in the patient's mouth to ensure that the occlusion is similar with and without the thin tray in place. The patient should not develop an open anterior bite with the tray in place. If this condition occurs, the most posterior teeth should be removed from the tray by trimming with scissors until proper occlusion is achieved, including some anterior contact on the tray. This modification is necessary to avoid possible repercussions to the temporomandibular joint or muscles of mastication.

### How many hours a day or night should my patient bleach their teeth?

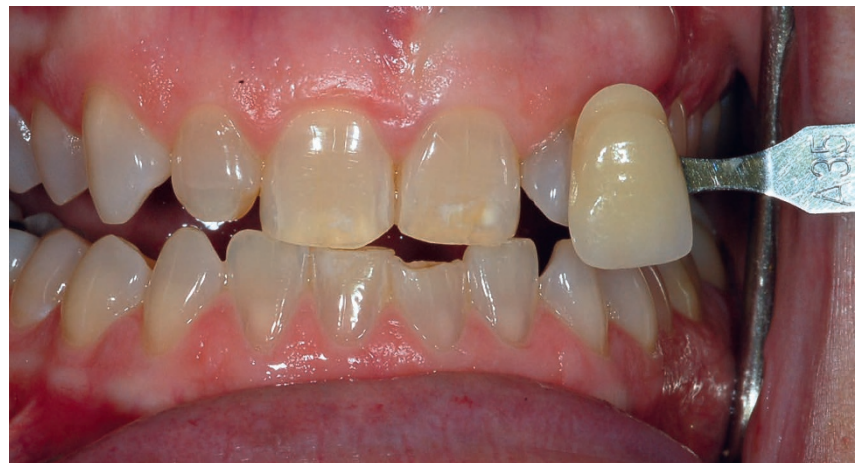With the traditional at-home bleaching technique, the wear time is dependent on the type of bleaching material used. When using 10% carbamide peroxide, overnight wear is suggested for the maximum benefit due to its nature. CP is active for up to ten hours, with approximately 50% of the peroxide release occurring during the first two hours.<sup>19</sup> If overnight wear is not possible or preferred by the patient, daytime wear of 2–4 hours can also be used with 10% carbamide peroxide. If hydrogen peroxide is being used, it is only active for 30 minutes to one hour, making it more suitable for daytime wear.

### How many days should my patient bleach, and how often should I monitor their progress?

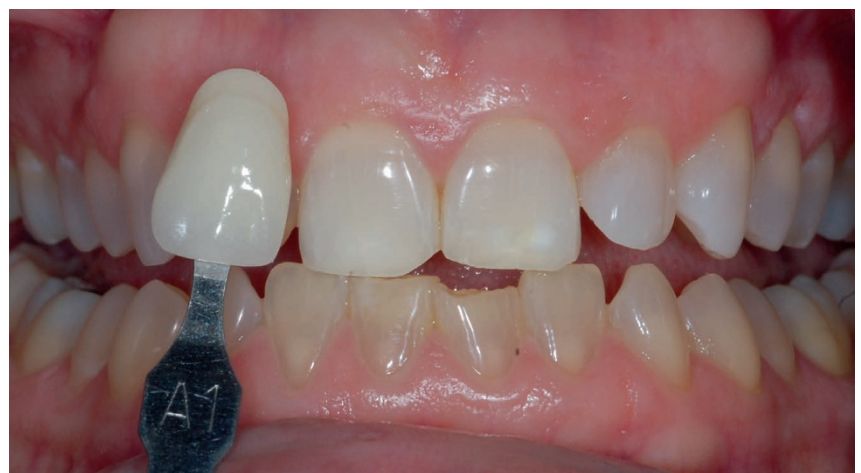The length of treatment will be different for each patient based on the type and location of the discoloration, patient compliance, and the amount of tooth or gingival sensitivity. Some patients with normal darker teeth show bleaching results in as little as three days and

**Table 2** Wear times of 10% CP for different tooth situations

Situation	Wear time	
Normal teeth	3 days to 6 weeks nightly	Non-scalloped, no reservoir tray
Nicotine-stained teeth	1–3 months nightly	NS-NR tray
Tetracycline-stained teeth	2–12 months nightly	NS-NR tray
Single dark tooth	8 weeks or more nightly	Single tooth tray design
Brown fluorosis	6–8 weeks nightly	80% successful
White spots	6 weeks nightly	Only lightens background



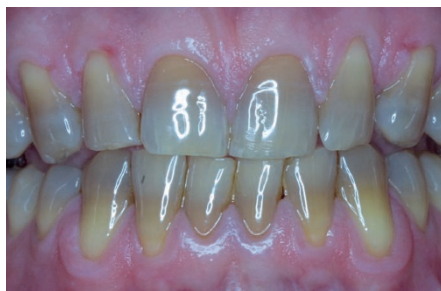**Fig. 18** Baseline shade is documented by photographs with shade tab in the photograph



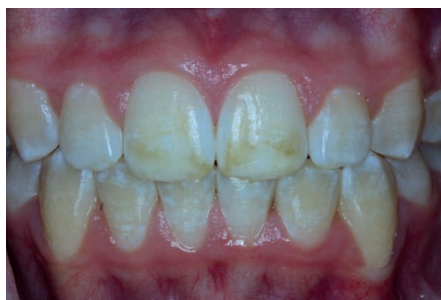**Fig. 19** Final shade change is confirmed with shade tab and by comparing treated maxillary arch with the unbleached mandibular arch

others take as long as six weeks (Table 2). At the tray and bleach delivery appointment, a current shade of the patient's teeth should be taken and recorded in the patient chart (Figs 18 and 19). Extra-oral photographs can be helpful for charting as well as patient education to determine progress. Some dentists prefer to monitor their patients' bleaching progress weekly and some monthly, while others prefer

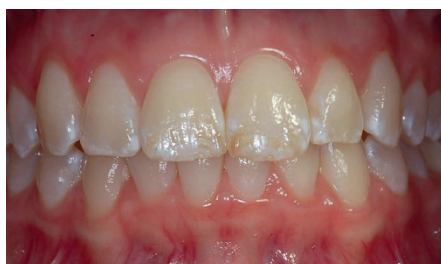to see their patients at the end of treatment.<sup>32</sup> Weekly evaluations may increase compliance, but also increase operating cost. Dentists who monitor the patient monthly could also use that visit to determine the need for a second amount of bleaching material or 'refill kit', depending on the amount and method in which initial bleaching material was dispensed. While common discolorations average a



**Fig. 20** Typical tetracycline stained teeth with multiple discolorations



**Fig. 22** Brown discoloration is most easily removed

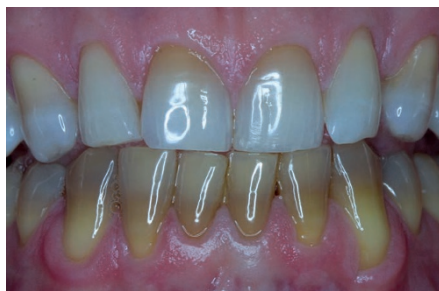

**Fig. 24** White spots are not removed by bleaching, but can be made less noticeable

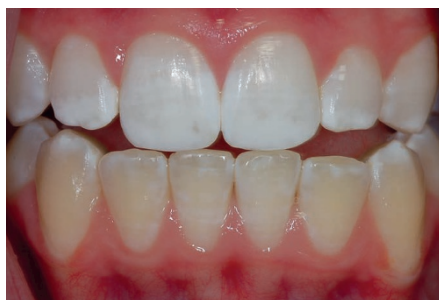treatment time of about two weeks, nicotine stains may average 1–3 months and tetracycline stains 2–12 months with an average of 3–4 months with nightly application.<sup>36</sup>

### What instructions should I give my patient when beginning treatment?

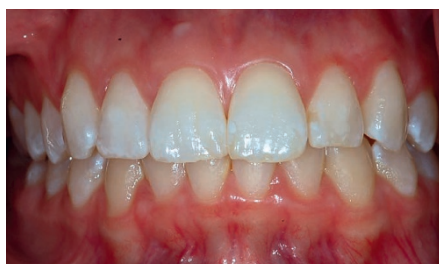The patient should be informed of the general process of bleaching, concerning how to place the bleaching material in the tray, how long to wear the tray, and how many days to bleach. They need to be counselled on possible tooth or gingival sensitivity and when to contact their dentist about complications of bleaching. A bleaching 'log' can be advantageous for a patient to be able to record how many hours and days/nights they have worn the tray. The log may help with compliance because the



**Fig. 21** After bleaching for six months nightly, improvement seen as compared to untreated mandibular arch



**Fig. 23** Brown discoloration gone after 2–6 weeks bleaching nightly



**Fig. 25** White spots are less noticeable from bleaching the background of the tooth

patient is encouraged to keep daily track of their progress. The patient should both be instructed and practise inserting and removing the tray. It is easiest to pinch the tray between the fingers of the dominant hand at a location over the posterior teeth, and peel it out of the mouth. The patient may instinctively attempt to use their fingernails in the anterior to remove the tray, but this method could lead to abrasion of the gingiva and subsequent sensitivity, leading to possible delay of treatment. The patient should be reminded to clean the tray by rinsing in room temperature water, and brushing the tray with a regular toothbrush and water after each application. Waiting two weeks after a prophylaxis appointment before initiating bleaching is recommended to avoid gingival and tooth sensitivity.

### How do I know when my patient is finished bleaching?

Teeth have a limit to how white they can become and vary on how quickly they achieve their maximum whiteness. Patients should continue to bleach until they reach their desired shade or the teeth cease to change shades, whichever comes first. If the patient has not reached their desired shade and the teeth do not continue to become whiter after continuous treatment, they have most likely reached this limit. After active bleaching treatment has been completed, the patient should expect a slight shade reduction.

Bleaching one arch at a time is preferable because the patient will be able to see the amount of colour change of the tooth in comparison to the unbleached arch. This can help the dentist and patient determine when they have reached their desired endpoint for a specific arch. If a patient has an existing crown or restoration that is whiter than the natural dentition, matching the shade of the restoration could be the desired endpoint.

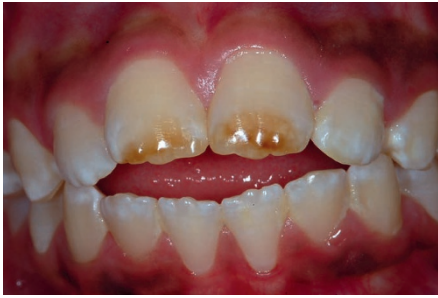### How long will my patients' teeth remain bleached?

Many factors play a role in how long a patient's teeth may remain desirably white. Some of the factors could include how often the patient's teeth are exposed to dark beverages such as coffee, tea, or red wine and may include the type of discoloration of the patient's teeth.<sup>37</sup> Patients do not have to continually bleach. Minimal colour stability is 1–3 years and some patients' teeth have remained a stable shade for over ten years.<sup>38</sup>

### Can I perform bleaching on a patient with tetracycline staining?

Tetracycline stains can occur from antibiotic treatment during tooth formation of childhood, as well as from application during adult years.<sup>39</sup> Minocycline is the most common antibiotic used for treatment of acne in teenagers and adults.<sup>40–47</sup> This antibiotic is secreted in the saliva and soaks into the tooth, as well as is deposited in the secondary dentin. Tetracycline staining is one of the most stubborn stains to address, and has varying degrees of success. Due to the nature of the staining, a longer treatment time is required for treatment. While the typical tetracycline stain looks grey and can have a banded appearance, other presentations may appear brownish, bluish, or even yellow, mimicking traditional intrinsic staining of teeth. These

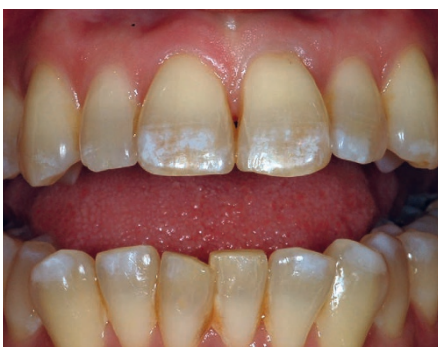



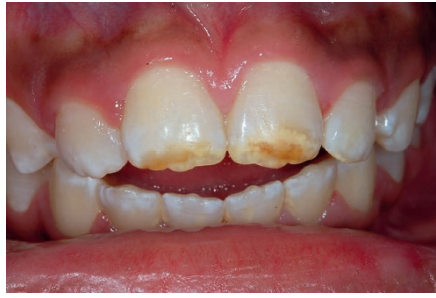**Fig. 26** Brown discolouration in 14-year-old youth with tongue thrust

different discolorations will have different reactions to the bleaching process. Though the teeth may not become a uniform 'pearly' white, some colour lightening will occur. Grey banding and staining at the cervical portions of these teeth are the most challenging part of tetracycline staining to bleach predictably. The tooth may not lose all of its banded appearance. This outcome should be part of the patient counselling before bleaching tetracycline-discoloured teeth. Night-time use of 10% carbamide peroxide<sup>7</sup> can take from 1–12 months treatment time on tetracycline-stained teeth, with the average time being 3–4 months (Figs 20 and 21).<sup>48</sup>

Dental practitioners need a payment model that is appropriate for the extended nature of bleaching a tetracycline patient. Paying a one-time fee for the entire bleaching process is not reasonable due to the unknown length of treatment and amount of material required. A better approach for tetracycline-stained patients is to pay an initial fee as would be charged for bleaching normal teeth, then a monthly fee that would include the cost of the bleaching material refills plus the chair time for the continued examinations. This approach would be considered 'pay as you go' to maintain a reasonable treatment model that is both fair to the patient and fair to the dentist.<sup>49</sup>



**Fig. 29** White discolorations are reported by the patient to stain with wine

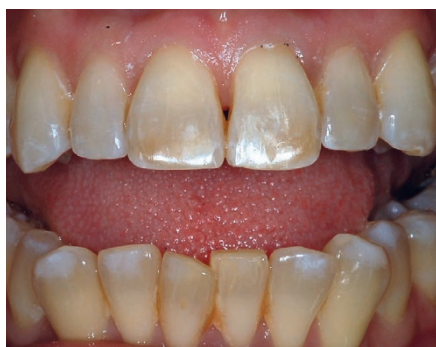

**Fig. 27** Brown discolouration is only partially removed after 6 weeks bleaching

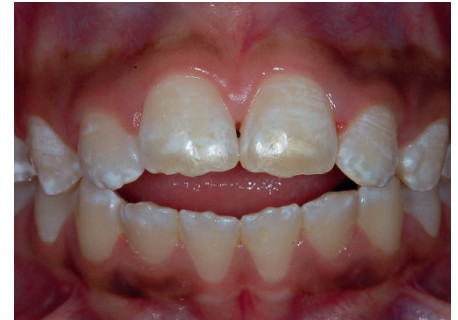### Can bleaching be used to treat brown or white stains?

Brown stains are often caused from high fluoride in the water, or other developmental issues. Bleaching is generally successful at least 80% of the time, with total or partial eradication of the brown stain (Figs 22 and 23).<sup>32</sup> With the night-time wear of 10% carbamide peroxide, the patient applies the material for three days to six weeks on brown stains.<sup>50</sup>

White discolorations cannot be removed by bleaching, but the background of the tooth is lightened by bleaching, so the white area is less noticeable due to less contrast (Figs 24 and 25). Patient should be informed that occasionally in the first 2–5 days of bleaching, the white discoloration may become lighter. This occurrence is called 'the splotchy stage'. This whitening of the problem area can create concern for the patient and the dentist, but they should continue bleaching to lighten the background more. Upon termination of bleaching, the white spot returns to its original colour, and is usually less noticeable. However, if the brown or whitish area is still an aesthetic problem, then abrasion is the next step in the treatment options. This abrasion can be microabrasion (use of pumice with hydrofluoric acid)<sup>51–54</sup> or macroabrasion (use of high speed burs)(Figs 26–28).<sup>55</sup> Sometimes



**Fig. 30** Since white discoloration seemed shallow, patient requested abrasion first

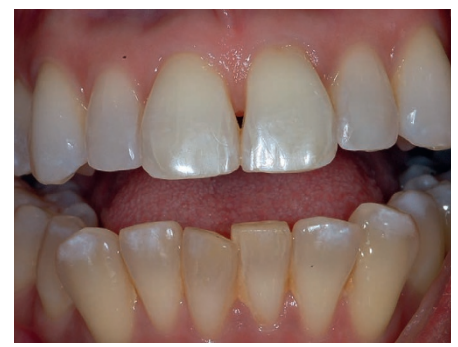

**Fig. 28** Additional abrasion with burs and disks is able to remove the remaining brown discoloration

the white area is a superficial stain and can be removed by sanding (Figs 29–31). Other times, it penetrates deeply into the enamel, and must be removed, then the defective area is restored with composite resin material. The patient should be informed pre-bleaching of the other treatments that may be required, and also the additional fee for those treatments. The only time abrasion is indicated before bleaching is if the tooth is rough and will need polishing anyway, or if it is obvious the white discoloration is a shallow superficial stain.

### Do nicotine stains respond well to bleaching?

Nicotine stains are very stubborn but can be removed. The stains begin as extrinsic and then become intrinsic after they soak into the tooth. With the night-time wear of 10% carbamide peroxide, the patient applies the material for 1–3 months on nicotine stains. Even though a nicotine stain is challenging to clean, bleaching removes virtually all staining when given a long enough application time. This stain removal is a great benefit for patients attempting to quit smoking, as it helps to erase their visual history of smoking very well.<sup>50</sup>



**Fig. 31** Several years later, patient elected to bleach

**What if my patient has just one dark tooth in the aesthetic zone?**

Single dark teeth may be vital or non-vital, with or without having received endodontic treatment. The best approach is to determine the response of the single dark tooth before altering the colour of the other teeth.

*Non-endodontically treated teeth*

Teeth that have not had endodontic therapy, regardless of vitality, are excellent candidates for bleaching externally. If there are no signs (abscess on radiograph, swelling, fistula, etc) or symptoms (pain) of pathology, then elective endodontics is not indicated, even if the tooth

tests non-vital. Due to the easy passage of peroxide through the enamel and dentin, the tooth can be bleached externally as easy as internally. The bleaching process should begin with only the dark tooth. A special tray is fabricated which only applies the bleaching material to the single dark tooth. The tray extends onto the tissue 2–3 mm and has the teeth moulds adjacent to the dark tooth removed (Figs 32–34). The patient applies a small amount to the dark tooth only. Treatment time is usually eight weeks or more. The dentist should only bleach the single dark tooth, and not attempt to bleach all the teeth. Often the other teeth will bleach so white that even if the single dark tooth lightens a good bit, there will still be a shade discrepancy. It is best to determine how successful the single dark tooth will become before considering additional bleaching of the adjacent teeth.<sup>56</sup>

After bleaching the single dark tooth until it reaches the maximum lightest shade, the full arch must be re-examined for aesthetic comparison. If the single dark tooth matches the entire arch, the bleaching treatment is finished, because bleaching the other teeth in the arch could result in their becoming lighter than the previously single dark tooth (it has reached its maximum brightness), and the aesthetic harmony of the teeth would be lost. If, after treatment, the single dark tooth is lighter than the other teeth in the arch, a full-arch bleaching tray can be made to bleach the other teeth only to the point of matching the shade of the previously single dark tooth. Because of the careful nature of the bleaching and matching, less wear time, possibly in the day only, and more frequent examination may be beneficial to titrate the remaining teeth in the arch to match the single, formerly dark tooth.

*Endodontically-treated teeth*

For teeth that have received endodontic treatment, internal bleaching is the first consideration, mainly because often there are remaining materials left inside the tooth that must be removed to be successful. Low concentrations of peroxide are advised to avoid internal resorption, as well as avoid the use of heat. The use of carbamide peroxide internally avoids the risk of peroxide burns, and also raises the pH, which may make the tooth less likely to resorb. Since internal bleaching can take 1-6 applications, the most reasonable approach is to only go inside the tooth once to clean the pulp chamber and lower the gutta percha below the CEJ, then make a single tooth tray to complete the process externally.

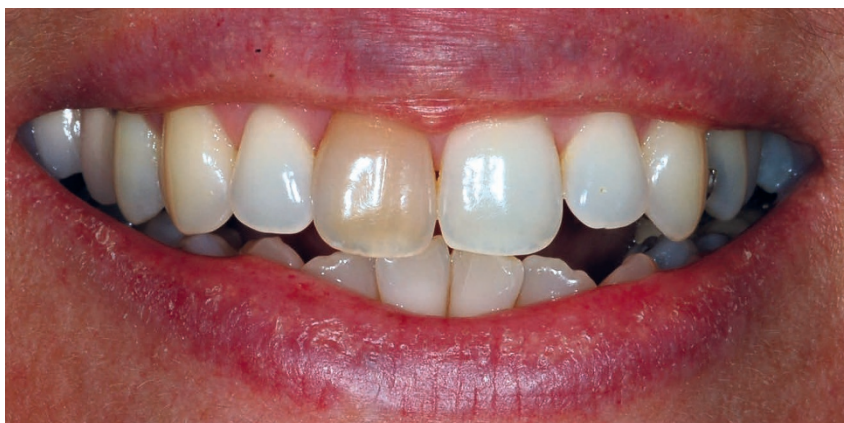

Fig. 32 Single dark central incisor distracting in a normal smile

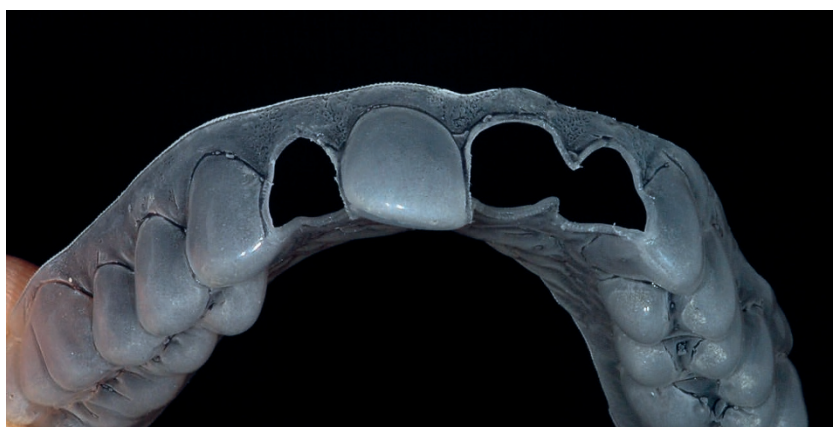


Fig. 33 Single tooth bleaching tray only treats the dark tooth without affecting adjacent teeth

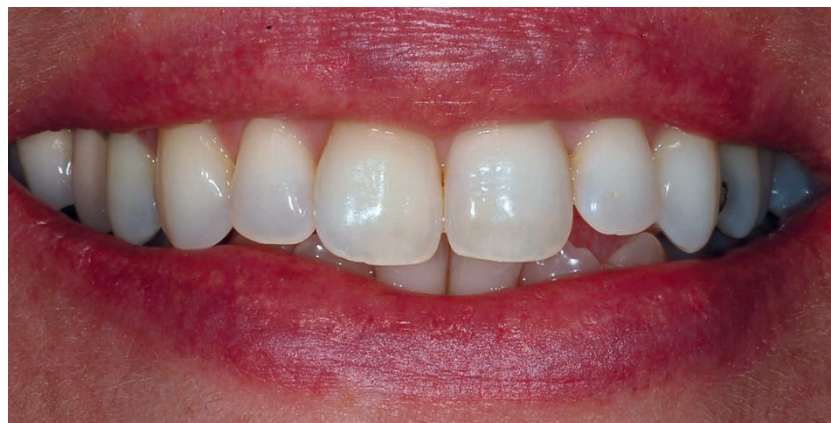

Fig. 34 Single dark tooth bleached for 8 weeks but not lighter than adjacent teeth, so other teeth were not bleached



### Why not crown the single dark tooth?

There will be more single tooth bleaching because research has shown that anterior endodontically-treated teeth have a better prognosis for survival without a post or crown due to the amount of remaining dentin lost during the crown preparation. The anterior tooth should only receive a crown or veneer if the tooth would have needed this treatment when vital, not because the tooth had a root canal. However, posterior endodontically-treated teeth still need a crown due to the multi-rooted anatomy, the increased forces of occlusion and the strong MI contacts along the long axis, which split the tooth.

### Can I perform bleaching on children?<sup>57</sup>

The youngest time to bleach teeth is when the teeth have erupted with some deformity in colour that might be embarrassing to the child and keep them from developing a well-rounded personality. This treatment need usually occurs in the 10–14 age range. Primary teeth are already very white, and the only indication for bleaching primary teeth is when the teeth are darkened by trauma, and do not need any other treatment. In permanent teeth, although the pulp is large, there are also open apices, so sensitivity has never been an issue in youth. Some companies have recommendations of not bleaching below a certain age, but that is based on their decision not to involve children rather than any scientific basis.

The safest most predictable method for bleaching teeth in youth is the use of 10% carbamide peroxide in a custom fitted tray (Figs 35 and 36).<sup>58</sup> With children whose permanent teeth are in various stages of eruption, the use of a 'boil and form' tray made in the office is more cost-effective than a conventional alginate impression. The trays can be worn for several hours during the day, but ideally are worn at night.

### When can composite restorations be placed when bleaching is being considered?<sup>59,60</sup>

Bleaching is an oxidation process that places oxygen into the enamel and dentin. This oxygen inhibits the set of the resin tags that penetrate into the etched enamel, so the bond strengths of composite applied during bleaching are reduced by 25–50%. The dentist should wait at least two weeks after bleaching before bonding.<sup>59</sup> Also, the oxygen in the enamel during bleaching changes the optical

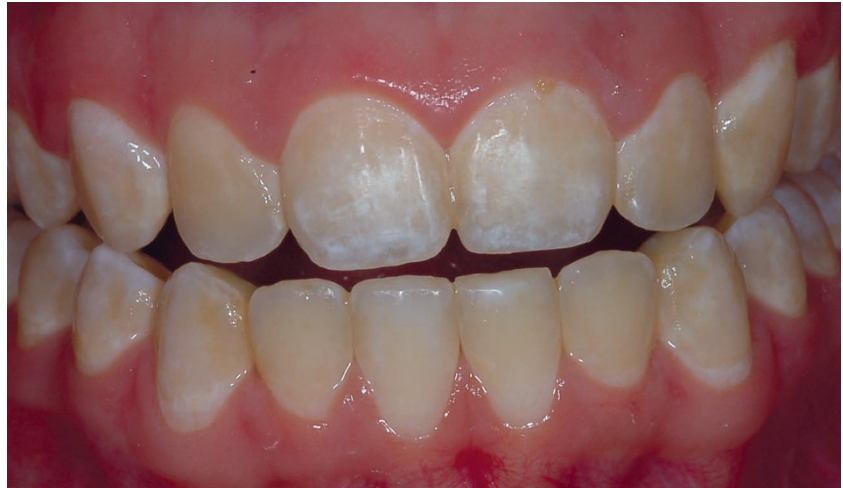

Fig. 35 Eleven-year-old child unhappy with yellow mottled colour of teeth

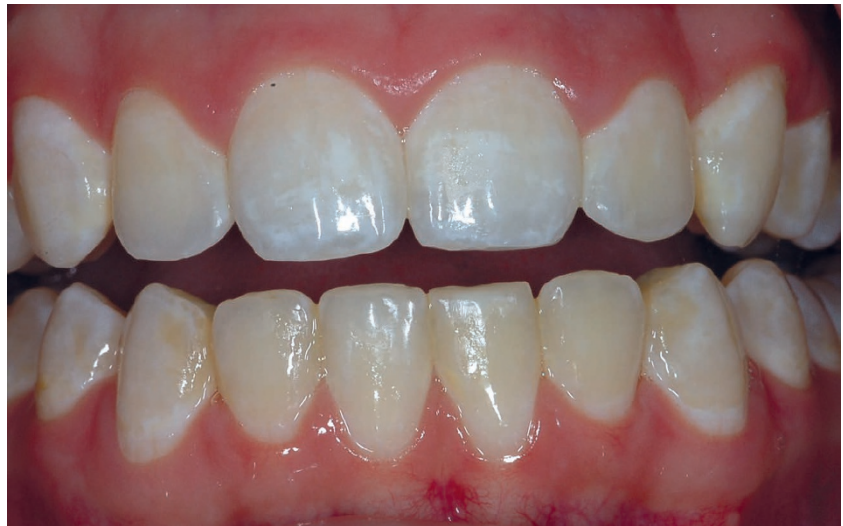

Fig. 36 Bleaching maxillary arch blends most of the discolouration

qualities, making the tooth appear whiter than its actual bleached colour. The two-week wait time also allows the shade of the tooth to return to normal, which is about half a shade darker than what occurs during bleaching. As the oxygen dissipates, the tooth regains its true colour and is able to be restored with maximum bond strengths.

Patients should be informed of the slight shade shift that occurs, and expect a two-week wait before shade selection or bonding. Informing the patient is especially important because often patients want to bleach the night before bonding to get the lightest colour, but after the restoration is placed, the shade will not match two weeks later.

Conversely, if composite is already bonded to the tooth, there is no effect on light-cured composite bond strengths, and chemically-cured composite has an increase in bond

strength due to the oxygen further polymerising the composite.<sup>61</sup>

### What if the patient interested in bleaching has active tooth decay?

If the anterior caries is not deep or causing the tooth to be sensitive, then the first step is to bleach the teeth with carbamide peroxide. Due to the urea in the carbamide peroxide, the pH is elevated above that which the caries can progress. The peroxide also kills the main bacteria causing tooth decay, and cleans the plaque from the teeth. Also, since it is unknown to what shade the tooth will bleach, selection of a shade for a composite is guesswork. Because of the caries control feature of 10% CP, it has also been recommended for caries control alone (without bleaching) in elderly patients having dry mouth, handicapped patients with difficult manual dexterity and young

patients undergoing orthodontic treatment.<sup>26</sup> In the bleaching patient, if the caries is deep or sensitive, then the dentist should restore the tooth with a protective restoration using a resin-modified glass ionomer (RMGI). After bleaching, the top surface of the RMGI can be removed and the proper shade of composite bonded to the RMGI.

## Conclusions

Bleaching teeth has been one of the major aesthetic advances in dentistry in the last 25 years. While there are various techniques for bleaching, the use of 10% carbamide peroxide applied in a custom fitted tray is the most versatile, efficacious, safe and cost-effective method to provide patients with lighter teeth while preserving the enamel of the teeth. Tray bleaching is best performed under dental supervision, which includes a proper initial examination with radiographs, and diagnosis of the cause and appropriate treatment based on the patient's lifestyle, finances and aesthetic desires.

- Haywood V B. History, safety, and effectiveness of current bleaching techniques and applications of the nightguard vital bleaching technique. *Quintessence Int* 1992; **23**: 471–488.
- Haywood V. In-office bleaching: Lights, applications, and outcomes. *Curr Pract* 2009; **16**: 3–6.
- de Silva G M, Brackett M G, Haywood V B. Number of in-office light-activated bleaching treatments needed to achieve patient satisfaction. *Quintessence Int* 2006; **37**: 115–120.
- Auschill T M, Hellwig E, Schmidale S, Sculean A, Arweiler N B. Efficacy, side-effects and patients' acceptance of different bleaching techniques (OTC, in-office, at-home). *Oper Dent* 2005; **30**: 156–163.
- Associates CR. Clinicians' Preferences 2005 – Survey data from 1652 random CRA Newsletter subscribers. CRA Newsletter. 2005; **29**: 4.
- Matis B A, Cochran M A, Wang G, Eckert G J. A clinical evaluation of two in-office bleaching regimens with and without tray bleaching. *Oper Dent* 2009; **34**: 142–149.
- Haywood V B, Heymann H O. Nightguard vital bleaching. *Quintessence Int* 1989; **20**: 173–176.
- Affairs ACoS. Tooth Whitening/Bleaching: Treatment Considerations for Dentists and their Patients. p. 12. Chicago: American Dental Association, 2010.
- Haywood VB. Pre-bleaching exam vital for optimum whitening. *Compend Contin Educ Dent* 2012; **33**: 72–73.
- Haywood V B, Heymann H O. Response of normal and tetracycline-stained teeth with pulp-size variation to nightguard vital bleaching. *J Esthet Dent* 1994; **6**: 109–114.
- Mrazek B. 'Don't bleach until you see the white of their eyes'. *Compend Contin Educ Dent*. 2004; **25**: 472, 474.
- Cooper J S, Bokmeyer T J, Bowles W H. Penetration of the pulp chamber by carbamide peroxide bleaching agents. *J Endod* 1992; **18**: 315–317.
- Leonard R H, Jr., Haywood V B, Phillips C. Risk factors for developing tooth sensitivity and gingival irritation associated with nightguard vital bleaching. *Quintessence Int* 1997; **28**: 527–534.
- Kwon S R, Dawson D V, Wertz P W. Time Course of Potassium Nitrate Penetration into the Pulp Cavity and the Effect of Penetration Levels on Tooth Whitening Efficacy. *J Esthet Restor Dent* 2016; **28 Suppl 1**: S14–S22.
- Haywood V B, Cordero R, Wright K *et al*. Brushing with a potassium nitrate dentifrice to reduce bleaching sensitivity. *J Clin Dent* 2005; **16**: 17–22.
- Haywood V B, Caughman W F, Frazier K B, Myers M L. Tray delivery of potassium nitrate-fluoride to reduce bleaching sensitivity. *Quintessence Int* 2001; **32**: 105–109.
- Williamson E H, Lundquist D O. Anterior guidance: its effect on electromyographic activity of the temporal and masseter muscles. *J Prosthet Dent* 1983; **49**: 816–823.
- McCaslin A J, Haywood V B, Potter B J, Dickinson G L, Russell C M. Assessing dentin colour changes from nightguard vital bleaching. *J Am Dent Assoc* 1999; **130**: 1485–1490.
- Matis B A. Tray whitening: what the evidence shows. *Compend Contin Educ Dent* 2003; **24**: 354–362.
- Scientific Committee on Consumer Products. Guidance document on epidemiological and clinical studies on tooth whitening products. 2006 2. Available at [http://ec.europa.eu/health/ph\\_risk/committees/04\\_sccp/docs/sccp\\_o\\_057.pdf](http://ec.europa.eu/health/ph_risk/committees/04_sccp/docs/sccp_o_057.pdf) (accessed August 2017).
- Leonard R H, Jr., Bentley C D, Haywood V B. Salivary pH changes during 10% carbamide peroxide bleaching. *Quintessence Int* 1994; **25**: 547–550.
- Leonard R H, Jr., Austin S M, Haywood V B, Bentley C D. Change in pH of plaque and 10% carbamide peroxide solution during nightguard vital bleaching treatment. *Quintessence Int* 1994; **25**: 819–823.
- Li Y, Lee S S, Cartwright S L, Wilson A C. Comparison of clinical efficacy and safety of three professional at-home tooth whitening systems. *Compend Contin Educ Dent* 2003; **24**: 357–360, 362, 364.
- Shipman B, Cohen E, Kaslick R S. The effect of a urea peroxide gel on plaque deposits and gingival status. *J Periodontol* 1971; **42**: 283–285.
- Fogel M S, Magill J M. Use of an antiseptic agent in orthodontic hygiene. *Dent Surv* 1971; **47**: 52.
- Lazarchik D A, Haywood V B. Use of tray-applied 10 percent carbamide peroxide gels for improving oral health in patients with special-care needs. *J Am Dent Assoc* 2010; **141**: 639–646.
- Li Y. The safety of peroxide-containing at-home tooth whiteners. *Compend Contin Educ Dent* 2003; **24**: 384–389.
- Haywood V B. Nightguard vital bleaching: Construction of NGBV Prosthetic. *Dent Today* 1997; **16**: 86–91.
- Goldstein F. New 'at home' bleaching technique introduced. *Cosmetic Dent GP* 1989; **6**: 7.
- Haywood V B. Overview and status of mouthguard bleaching. *J Esthet Dent* 1991; **3**: 157–161.
- Matis B A, Hamdan Y S, Cochran M A, Eckert G J. A clinical evaluation of a bleaching agent used with and without reservoirs. *Oper Dent* 2002; **27**: 5–11.
- Haywood VB DJ, Berry T G. Natural Tooth Bleaching. In Hilton T J F J, Summitt J B, Broome J C (editors) *Summitt's Fundamentals of Operative Dentistry: A Contemporary Approach, 4th Edition*. p. 414–447. Hanover Park, IL: Quintessence Publishing Co, 2013.
- Javaheri D S, Janis J N. The efficacy of reservoirs in bleaching trays. *Oper Dent* 2000; **25**: 149–151.
- Miller M, Castellanos I, Rieger M. Efficacy of home bleaching systems with and without tray reservoirs. *Pract Periodont Aesthetic Dent* 2000; **12**: 611.
- Fischer D E. Patent 6,036,943. Methods for treating a person's teeth using sticky dental compositions in combination with passive-type dental trays. 2000. Available at <https://www.google.com/patents/US6036943> (accessed August 2017).
- Haywood V B, Leonard R H, Dickinson G L. Efficacy of six months of nightguard vital bleaching of tetracycline-stained teeth. *J Esthet Dent* 1997; **9**: 13–19.
- Haywood V B C W, Goldstein R E. Stains and Discolorations. In Goldstein RE HV (editor). *Esthetics in Dentistry, 2nd ed*. B C Decker, 2002.
- Haywood V B, Leonard R H, Nelson C F, Brunson W D. Effectiveness, side effects and long-term status of nightguard vital bleaching. *J Am Dent Assoc* 1994; **125**: 1219–1226.
- Moffitt J M, Cooley R O, Olsen N H, Hefferen J J. Prediction of tetracycline-induced tooth discoloration. *J Am Dent Assoc* 1974; **88**: 547–552.
- Mello H S. The mechanism of tetracycline staining in primary and permanent teeth. *J Dent Child* 1967; **34**: 478–487.
- Milch R A, Rall D P, Tobie J E. Bone localization of the tetracyclines. *J Natl Canc Inst* 1957; **19**: 87–93.
- Feinman R A. Reviewing vital bleaching and chemical alterations. *J Am Dent Assoc* 1991; **122**: 55–56.
- Parkins F M, Furnish G, Bernstein M. Minocycline use discolors teeth. *J Am Dent Assoc* 1992; **123**: 87–89.
- Poliak S C, DiGiovanna J J, Gross E G, Gantt G, Peck G L. Minocycline-associated tooth discoloration in young adults. *JAMA* 1985; **254**: 2930–2932.
- Dodson D, Bowles W. Production of minocyclines pigment by tissue extracts. *J Dent Res* 1991; **70**: 424.
- Cheek C C, Heymann H O. Dental and oral discolorations associated with minocycline and other tetracycline analogues. *J Esthet Dent* 1999; **11**: 43–48.
- Chung H Y B W. Oxidative changes in minocycline leading to intrinsic dental staining [abstract A1855]. *J Dent Res* 1989; **68**: 413.
- Leonard R H, Haywood V B, Caplan D J, Tart N D. Nightguard Vital Bleaching of Tetracycline-Stained Teeth: 90 Months Post Treatment. *J Esthetic Rest Dent* 2003; **15**: 142–153.
- Haywood V. Tooth whitening in your practice: treatment time and fee schedules. *Contemp Esthetics Rest Pract* 2000; **4**: 12–15.
- V B H. *Tooth Whitening: Indications and Outcomes of Nightguard Vital Bleaching*. Hanover Park, IL: Quintessence Publishing Co, Inc., 2007.
- Croll T P. Enamel microabrasion: observations after 10 years. *J Am Dent Assoc* 1997; **128 Suppl**: 455S05.
- Croll T P, Bullock G A. Enamel microabrasion for removal of smooth surface decalcification lesions. *J Clin Orthod* 1994; **28**: 365–370.
- Croll T P, Segura A, Donly K J. Enamel microabrasion: new considerations in 1993. *Pract Periodont Aesthetic Dent* 1993; **5**: 19–28.
- Zalkind M, Arwaz J R, Goldman A, Rotstein I. Surface morphology changes in human enamel, dentin and cementum following bleaching: a scanning electron microscopy study. *Endod Dent Traumatol* 1996; **12**: 82–88.
- Heymann H O. Additional Conservative Esthetic Procedures. In Roberson T H, Swift, Jr. E (editor) *Art and Science of Operative Dentistry, 5th ed*. pp. 647–648St. Louis, MO: Mosby, 2006.
- Haywood V B D A. Bleaching the Single Dark Tooth. *Inside Dent* 2010; **6**: 42–52.
- Council on Clinical Affairs of the American Academy of Pediatric Dentistry. Policy on the use of dental bleaching for child and adolescent patients. Reference Manual. Revised 2014. **37**: 76–78. Available at [http://www.aapd.org/media/policies\\_guidelines/p\\_bleaching.pdf](http://www.aapd.org/media/policies_guidelines/p_bleaching.pdf) (accessed August 2017).
- Haywood V B. Bleaching children's teeth: questions and answers. *Georgia Acad Gen Dent* 2006; **4**: 7.
- Cvitko E, Denehy G E, Swift E J, Jr., Pires J A. Bond strength of composite resin to enamel bleached with carbamide peroxide. *J Esthet Dent* 1991; **3**: 100–102.
- Unlu N, Cobankara F K, Ozer F. Effect of elapsed time following bleaching on the shear bond strength of composite resin to enamel. *J Biomed Mater Res B Appl Biomater* 2008; **84**: 363–368.
- Tanner J, Smith B, Rueggerberg F, Haywood V. Effect of dentist-prescribed home bleaching on orthodontic bracket retention. *J Dent Res* 2001; **80**: 205.