

# Is there an association between dental implants and squamous cell carcinoma?

A. O. Salgado-Peralvo,<sup>\*1</sup> L. Arriba-Fuente,<sup>2</sup> M. V. Mateos-Moreno<sup>3</sup> and A. Salgado-García<sup>4</sup>

## In brief

Highlights that oral squamous cell carcinoma (OSCC) is a rare complication of dental implants, but something very important to consider.

Demonstrates that prior to inserting implants, it is necessary to perform a correct examination and know the patient's risk factors in order to try to control them.

Shows that the clinical appearance of OSCC in the peri-implantary mucosa is very similar to peri-implantitis, so in these cases it is necessary to do a differential diagnosis.

**Introduction** The complications associated with dental implants are numerous, most of them of an inflammatory nature; nevertheless, some isolated cases of oral squamous cell carcinoma (OSCC) have been found in the vicinity of the implants. The objective of the present article is to know whether there is an association between dental implants and the development of OSCC.

**Method and materials** A search was carried out in Medline, Tripdatabase and Cochrane with the keywords 'dental implants' AND 'squamous cell carcinoma', and 'dental implant complications' AND 'squamous cell carcinoma.' The criteria for inclusion were articles published in English that dealt with the possible carcinogenic effects of implants and the possible malign transformation of oral lesions after the insertion of the implants. For the analysis, cases were used in which an OSCC had appeared in the peri-implantary mucosa. **Results** After an initial search, 269 articles were selected, of which 197 were excluded as not being directly related to the subject. Finally, 45 articles were selected, with 23 of them being used in the analysis. In these, 46 cases of OSCC in the vicinity of implants were discussed. **Discussion** Chronic inflammation in itself can lead to a malign transformation of the oral tissue, while in other cases it is caused and modulated by carcinogens, genetic factors or inherent factors in the patient, or by the dental implants. **Conclusions** It is not possible to establish a cause-effect relation between the implants and the development of OSCC. Its presence can be confused with peri-implantitis, so that in the cases where it appears suddenly, does not respond to conventional treatment and/or there is anaesthesia or paresthesia, it is advisable to do a biopsy. It is important to make an adequate selection of the patient and reduce or eliminate the risk factors. The findings of the present review are based on case study level of evidence, so meta-analysis is needed to further draw from these results.

## Introduction

Oral cancer is the sixth most frequent cancer in the global population according to the World Health Organisation (WHO). Between 3% and 5% of the malign tumours are located in the area of the head and neck, and approximately half of them are in the oral cavity.<sup>1-4</sup> Oral squamous cell

carcinoma (OSCC) represents 90% of the total and is defined as a malign neoplasm originating in the stratified epithelium.<sup>1-3,5</sup> It is more prevalent in men older than 60 and is associated with certain risk factors. In this sense it has been related to certain habits such as tobacco and/or alcohol and oral hygiene, to certain nutritional deficiencies, exposition to ionising radiation, viral (human papillomavirus) or bacterial infections, immunosuppression, potentially malignant disorders such as leukoplakia or oral lichen planus, and irritants of dental or implantary origin and genetic origin.<sup>1,2,5-8</sup>

Dental implants are not only one of the most advantageous options in the replacement of dental absences, but in certain specific cases they constitute the only alternative. The increment in treatments with implants in recent decades has also caused a series of

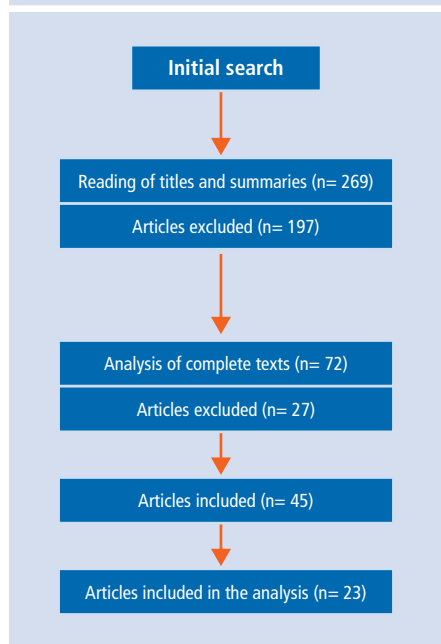
related complications to appear. Most of these complications are of an inflammatory nature, but other more serious but less frequent ones have also been described. Thus, cases have been observed in which the insertion of implants was related to the appearance of an OSCC, but furthermore, in patients who have suffered intraoral carcinomas and who after surgical treatment have needed rehabilitation with endosseous implants in order to restore lost function and esthetics, cases of recurrence and development of new primary tumours have been described.<sup>9-17</sup>

The pathogenesis of the OSCC occurs in two stages: the first consists of the action of a carcinogenic agent on the oral mucosa. After a quiescent period, the initiation would be produced by traumatic or irritating factors. A study has been done of the possibility that the factors acting

<sup>1</sup>Master in Family and Community Dentistry, University of Seville (US); <sup>2</sup>Associate Professor of Stomatology III. School of Dentistry, Universidad Complutense of Madrid (UCM); <sup>3</sup>Associate Professor of Stomatology IV. School of Dentistry, Universidad Complutense of Madrid (UCM); <sup>4</sup>University Specialist in Surgery and Oral Implantology, University of A Coruña. Dentist in the Galician Health Service (SERGAS)  
\*Correspondence to: Ángel-Orión Salgado-Peralvo  
Email: orionsalgado@hotmail.com

Refereed Paper. Accepted 29 September 2016  
DOI: 10.1038/sj.bdj.2016.863  
©British Dental Journal 2016; 221: 645-649

**Fig 1 Flowchart of the articles obtained in performing the bibliographic search**



as irritants can be restorations or materials used in odontology, and in this sense, dental implants could act as irritants.<sup>10,17</sup> It is important to mention that oral cancer in its initial stages is not usually painful, so it is often discovered by chance and, therefore, is diagnosed in very advanced stages of the illness.<sup>2,4</sup> At the present time the survival rate of patients with OSCC is 50% at five years, so that prevention and early detection are very important in diminishing its mortality and morbidity.<sup>5</sup>

The objective of this article is to do a review of the scientific literature available in order to know whether there is an association between dental implants and the development of OSCC.

## Material and methods

A review was performed of all the articles published in the database of MEDLINE (via Pubmed), Tripdatabase and Cochrane, using the search terms 'dental implants' AND 'squamous cell carcinoma', and 'dental implant complications' AND 'squamous cell carcinoma.' Searches were also carried out in the lists of references of the articles reviewed to identify relevant studies that might have been omitted.

The articles included dealt with the possible carcinogenic effects of dental implants and also with the possible malign transformation of oral lesions after the insertion of the implants. For the analysis, cases were used in which an oral squamous cell carcinoma had appeared in the peri-implantary mucosa. The search

was restricted to articles published in English. All articles that did not fulfil the criteria for inclusion were excluded, as were letters to the Editor and books or chapters of books. No date limit was placed on publications, the search being up-dated to March, 2016.

## Results

In an initial search, the reviewers selected 269 articles following the inclusion criteria. Of these, 197 were about other issues related to post oncologic treatment of patients treated for OSCC or other oral cancer, so were excluded. The complete texts of the remaining 72 were analysed, and 27 were excluded as being not directly related to the subject. Finally, 45 articles were included in the study: 23 were used to present the cases in the existing literature that discussed instances of OSCC in the peri-implantary mucosa, and 22 were about the possible causes for malign transformation (Fig. 1). In general, we could say that the pertinent existing bibliography is limited on most occasions to descriptions of clinical cases or series of cases with not many instances (Table 1).

From the 23 works studied, 46 cases of dental implants associated with OSCC are presented. These cases had a similar distribution for sex: 21 men (45.65%) and 25 women (54.35%), and the age of the patients ranged between 42 and 90.

In 45 cases (97.83%) there were predisposing factors that provoke molecular alterations which can go unnoticed and which increase the risk of malign transformation. Really, some of them are considered potentially cancerous lesions or states. Eight cases (16.67%) are described with oral lichen planus lesions,<sup>12,18-22</sup> 15 (31.25%) with leukoplakia<sup>11,12,14,23</sup> and two (4.17%) with erythroplakia;<sup>12</sup> 12 cases (25%) with a history of oral cancer<sup>9,14-16,19,21,23-26</sup> and seven cases (14.58%) with cancer in other places;<sup>3,10,19,20,27,28</sup> in 13 cases (27.08%) association with the consumption of alcohol was observed<sup>10,12,16,19,25,26</sup> and in 11 (22.92%) with a tobacco habit,<sup>10-12,16,19,20</sup> five cases (10.87%) being found in ex-smokers.<sup>10,12,23,26</sup> In three cases (6.25%) it was associated with bad oral hygiene<sup>25,28,29</sup> and in four cases (8.33%) with badly adapted prostheses.<sup>7,10,22,25</sup> Of the medical histories reviewed, three patients (6.25%) had associated cardiac diseases,<sup>7,20,30</sup> one (2.08%) hyperuricemia<sup>30</sup> and one (2.08%) diabetes mellitus.<sup>7</sup> In three cases (6.25%) the presence or absence of risk factors is not specified<sup>3,9,12-15,19,27</sup> and in 32 (66.67%) neither was the association with other illnesses.<sup>3,9,11-16,19-21,26-28</sup>

Clinically considered, 46 cases (100.00%) at the first consultation had an appearance similar to that observed in peri-implantitis, and in the examination there was an increase in the probing depth accompanied by bleeding. Radiographically, images compatible with peri-implantary bone loss were observed. The macroscopic clinical aspect in 18 cases (37.5%) was that of an exophytic lesion,<sup>7,9,12-14,16,18-21,25,26,30</sup> in two (4.17%) a verrucous leukoplakia,<sup>11,13</sup> and in ten cases (21.74%) appeared together with ulcerous lesions.<sup>10,12,19,22</sup>

Also described were two cases (4.17%) in which metastatic lesions were produced around the mandibular implants because of lung cancer<sup>27</sup> and breast cancer.<sup>28</sup>

As for location, in 44 cases (95.65%) the condition was produced in mandibular implants and only in two cases (4.35%) was the location maxillary.<sup>12,19</sup>

Also analysed were the various options with which the implants were repaired, namely 31 cases (64.58%) using overdentures<sup>7,9-12,15,16,20-25,27</sup> and in 12 cases (26.08%) with a fixed prosthesis.<sup>3,10,12-14,18-20,29,30</sup> In three cases (9.34%) it was not specified.<sup>24,26,28</sup>

## Discussion

With the increase that dental treatments have experienced in recent years through dental implants, there are numerous articles that deal with the complications in these treatments. Most of them are of an inflammatory nature; nevertheless, the publication of a number of cases that mention the appearance of OSCC in the peri-implantary tissues is worthy of attention.<sup>1,3,7,9-30</sup> Virchow,<sup>31</sup> in 1863, was the first to describe the relation between chronic inflammation and cancer. It is known that in some cases this inflammation in itself can lead to malignant transformation while in others it is caused and modulated by factors among which are included a certain genetic and carcinogenic predisposition such as tobacco or alcohol.<sup>12,32,33</sup> It has also been associated with certain bacterial or viral infections (human papillomavirus) as well as with other irritating factors, among which can include some that are inherent to implants.<sup>29</sup> Along these lines, in studying the importance that chronic inflammatory response has in the appearance and development of cancer, some studies discuss the association between chronic periodontitis and OSCC.<sup>12</sup>

The modulation of the inflammatory response contributes to the progression of

the tumour by increasing the proliferation and survival of malignant cells, stimulating neoangiogenesis and reducing antitumour immunity.<sup>32,33</sup> Peri-implantary inflammation initially affects the soft tissue around the implant, provoking mucositis, and later, when the inflammation becomes chronic, there is a reabsorption of the surrounding bone, which is known as peri-implantitis.<sup>1,11,16–18</sup> If this inflammation persists, it can have sufficient potential to induce cellular proliferation and prolong cellular survival by activating the oncogenes and inactivating tumour suppressor genes, which would produce genetic instability and a greater risk of having cancer. Furthermore,

certain routes of the inflammation affect the process of carcinogenesis.<sup>1,2,4,10,12,31</sup>

For many years titanium was considered an inert material, but recently cases of allergic reactions of type I or IV have been described that can lead to failure of the implant, as they activate the inflammatory process by functioning as an irritating agent.<sup>6,34,35</sup> Sicilia *et al.*<sup>36</sup> conducted a study to assess the possible allergy to titanium in 1500 patients with implants, and they observed positive reactions in nine of them (0.6%).

In cases where there is mobility of the implants, at microscopic levels particles derived from the implant can be produced that activate an inflammatory response, although

the association with carcinogenesis is not clear. Titanium implants coated with hydroxyapatite aggravate the problem because of a difference between the shearing module of the coating and that of the underlying titanium.<sup>29</sup> Moxley *et al.*<sup>25</sup> presented a case in which two transmandibular posts were inserted; two years after the insertion a clinical inspection revealed metallic filings around both posts which induced peri-implantary mucositis, and one year later an OSCC around one of them.

Some cases of metastasis around implants have been described in the scientific literature.<sup>27,28</sup> Primary cancers that metastasise on the oral level are estimated to be 1%, and in two thirds

**Table 1 Breakdown of case reports (UNS = unspecified by the authors)**

Authors	Article type	Number of cases	Previous history of oral cancer other parts of the body and/or premalignant lesions	Risk factors	Localisation	Prostheses on implants
Clapp <i>et al.</i> 1996	Clinical cases reports	3	Yes (2), No (1)	Yes (2), No (1)	Mandibular (3)	Overdenture (2), UNS (1)
Moxley <i>et al.</i> 1997	Clinical case report	1	Yes	Yes	Mandibular	Overdenture
Block and Scheufler. 2001	Clinical case report	1	Yes	Yes	Mandibular	Overdenture
Shaw <i>et al.</i> 2004	Clinical cases reports	2	Yes (2)	UNS (2)	Mandibular (2)	Fixed prosthesis (2)
Czerninsky <i>et al.</i> 2006	Clinical cases reports	2	Yes (2)	Yes (2)	Mandibular (2)	Fixed prosthesis (2)
Verhoveven <i>et al.</i> 2007	Clinical case report	1	Yes	UNS	Mandibular	Overdenture
Abu El-Naaj <i>et al.</i> 2007	Clinical cases reports	2	Yes (2)	Yes (2)	Mandibular (2)	Overdenture (1), Fixed prosthesis (1)
Dib <i>et al.</i> 2007	Clinical case report	1	Yes	Yes	Mandibular	UNS
Schache <i>et al.</i> 2008	Clinical case report	1	No	UNS	Mandibular	Fixed prosthesis
Chimenos-Küstner <i>et al.</i> 2008	Clinical case report	1	Yes	Yes	Mandibular	UNS
Eguia del Valle <i>et al.</i> 2008	Clinical case report	1	No	No	Mandibular	Fixed prosthesis
Gallego <i>et al.</i> 2008	Clinical case report	1	Yes	No	Mandibular	Overdenture
Kwok <i>et al.</i> 2008	Clinical cases reports	3	Yes (1), No (2)	Yes (3)	Mandibular (3).	Overdenture (2), Fixed prosthesis (1)
Gallego <i>et al.</i> 2009	Clinical case report	1	No	Yes	Mandibular	Overdenture
Gulati <i>et al.</i> 2009	Clinical case report	1	Yes	Yes	Mandibular	Overdenture
De Ceulaer <i>et al.</i> 2010	Clinical cases reports	3	Yes (3)	UNS (3)	Mandibular (3)	Overdenture (3)
Meijer <i>et al.</i> 2010	Clinical case report	1	Yes	UNS	Mandibular	Overdenture
Moshref <i>et al.</i> 2011	Clinical case report	1	No	Yes	Mandibular	Overdenture
Bhatavadekar. 2012	Narrative revision of the literature and clinical cases.	1	No	Yes	Maxillar	Fixed prosthesis
Pfammatter <i>et al.</i> 2012	Clinical case report	1	Yes	UNS	Mandibular	Fixed prosthesis
Marini <i>et al.</i> 2013	Clinical case report	1	Yes	No	Mandibular	Fixed prosthesis
Moergel <i>et al.</i> 2014	Clinical cases reports	15	Yes (14), No (1)	Yes (8), No (4), UNS (3)	Mandibular (14); Maxillar (1)	Overdenture (14), Fixed prosthesis (1)
Nariai <i>et al.</i> 2015	Clinical case report	1	Yes	Yes	Mandibular	Overdenture
23 publications		46 cases	Yes (37), No (9).	Yes (26), No (8), UNS (12)	Mandibular (44), Maxillar (2).	Overdenture (31), Fixed prosthesis (12), UNS (3)

of the cases the primary cancer goes unnoticed until the metastasis is diagnosed.<sup>3,17,28,37</sup> Of the tumours that metastasise on the oral level, the most frequent in women is breast cancer, while in men the most frequent are lung and prostate cancer. The zone most affected in the maxillo-facial area is the posterior mandibular zone.<sup>3,38</sup>

It is thought that in cases of recurrence of the OSCC around the implants after treatment, a proliferation of residual tumour cells is produced. It is estimated that this recurrence at oral level could be 15% to 20%.<sup>13,16</sup> On many occasions, after the removal of an OSCC, the only way to restore the function and aesthetics of the stomatognathic system of the oncological patient will be by means of implantological rehabilitation. Something that has also been considered is the possibility that during radiotherapy a dispersion of the radiation is produced, increasing the dosage in front of the implant and decreasing it in the posterior zone. This relation, however, is difficult to establish as a cause of recurrence of OSCC.<sup>15</sup>

Another factor that can cause inflammation in implants is corrosion. This is considered to be the deterioration of the metal as a result of an electro-chemical attack on the oral environment. Most implants are made of pure titanium or of alloys that are especially resistant to corrosion (with corrosion rates of 0.003  $\mu\text{A}/\text{cm}^2$ ) owing to the stability of the layer of titanium dioxide (TiO<sub>2</sub>) that they have.<sup>6,29,35</sup> When this layer is broken or eliminated, as can happen after the mechanical removal of plaque, from the presence of fluorides, due to friction of the implant with the surrounding bone or because of acidity of the medium (for example, in conditions of inflammation), the titanium can suffer corrosion.<sup>35,39,40</sup> Basically, this occurs between implants made of titanium and other metallic alloys used to rehabilitate implants or in other dental procedures; the alloy of less noble metals acts as the anode and the titanium as the cathode, transferring electrons by metallic contact and liberating into the crevicular space ions that activate the immune system of the host. It has been proved that there is an exchange of ions in the implant-bone interface, as increased levels of calcium and phosphorous have been found on the oxidised surface of the implants.<sup>6,39,40</sup> Localised corrosion can also be produced by the formation of cracks or holes in the surface which would act as an anode and the rest of the implant as a cathode.

Certain authors have associated the liberation of corrosion products with carcinogenic

and mutagenic phenomena in the oral cavity.<sup>39,40</sup> In 2006, titanium dioxide was considered a possible carcinogen for humans by the International Agency for Research on Cancer (IARC), which classified it as belonging to Group 2B.<sup>6,42</sup> In spite of this, the epidemiological cohort studies in humans have not been conclusive, so at the present time there is a great controversy over the matter and studies should be interpreted with caution.<sup>35</sup> In a study by Doran *et al.*,<sup>43</sup> the authors reached the conclusion that at the present time titanium alloys are the safest alloys for dental implants, and that only vanadium, a minor component of this alloy, is toxic. What does seem certain is that a high concentration of metallic ions in the oral cavity can be harmful and act as a local immunodepressant, or they can be metabolised, thereby generating cytotoxic or potentially reactive mutagenic products.<sup>6,35</sup>

Another possibly related factor is the migration of malignant cells through the peri-implantary sulcus to the jaw.<sup>18,29</sup> In the two cases presented by Schache *et al.*<sup>13</sup> and Nariai *et al.*,<sup>16</sup> the authors observed that the osseous extension of the tumour through the medulla originated in the bone crest and extended to the implant in the direction of the root. The cortical vestibular and lingual were intact, so the progression of the tumour was produced in the implant-mucosa interface.

In various cases described, the patients presented lesions in the oral mucosa, some of them benign, but with the passing of time and after insertion of the implants these could become malign. New lesions can also appear, or even in patients with a previous history of cancer or with potentially malignant lesions, there can be a recurrence of them around the implants.<sup>2,6</sup>

The pathogenesis of oral lichen planus (OLP) is not entirely clear, but today it is considered a potentially malignant condition. According to González-Moles *et al.*,<sup>45</sup> the rate of malignant transformation of OLP in different studies carried out between 1924 and 2007 is between 0% and 12.5%; nevertheless, it is necessary to perform a worldwide multicentric survey with a broad study population in order to throw light on the subject. It is a frequently recurrent lesion, and considering lichen planus as an illness that is autoimmune, inflammatory and chronic, and the effect of the implants on the immune system and on the development of chronic inflammation, it is reasonable to think that there can be a relation between the two, and therefore, participation in a possible malignant transformation. More

studies are necessary to confirm this hypothesis.<sup>2,18</sup> In these kind of patients, prolonged treatment with immunosuppressants, both oral and systemic, can facilitate the progression of the illness.<sup>18</sup>

The clinical appearance of OSCC associated with dental implants is difficult to distinguish from peri-implantitis. Considering that peri-implantary inflammation is the most frequent complication, it is not necessary for every patient with peri-implantitis to have a biopsy systematically. However, we should establish a differential diagnosis for OSCC in those cases in which there is a hyperplastic lesion of the oral mucosa with peri-implantary osseous reabsorption in patients at risk, and perform a biopsy in cases where the appearance of the lesion is sudden, shows rapid progression, does not respond to conventional treatment and/or presents anaesthesia or paresthesia.<sup>2,3,12,16,17,30</sup>

## Conclusions

It is not possible to establish a cause-effect relationship between the presence of dental implants and the development of OSCC in the peri-implantary tissue. Dental implants per se are not associated with carcinogenesis; nevertheless, there may be unknown factors or habits that can act synergistically in the development of cancer. Prior to inserting implants, it is necessary to perform a correct examination and know the patient's risk factors in order to try to control them and, in patients at risk, carry out a stricter protocol of visits. In the cases discussed here, the initial presentation of OSCC has been described in relation to dental implants with a clinical appearance very similar to that of peri-implantitis; nonetheless, this alone would not justify the performing of a biopsy in every case of peri-implantitis. It would, however, make it advisable to carry out a differential diagnosis with OSCC in patients at risk who present hyperplasia and peri-implantary osseous reabsorption, and select for a biopsy those cases in which the implantary lesion appears suddenly, does not respond to treatment and/or presents anaesthesia or paresthesia.

1. Jané-Salas E, López-López J, Roselló-Llabrés X, Rodríguez-Argueta O F, Chimenos-Küstner E. Relationship between oral cancer and implants: Clinical cases and systematic literature review. *Med Oral Patol Oral Cir Bucal* 2012; **17**: e23–e28.
2. Agha-Hosseini F, Rohani B. Evaluation of the effects of dental implants on oral lesions. *J Contemp Dent Pract* 2015; **16**: 400–406.
3. Pfammatter C, Lindenmüller I H, Lugli A, Filippi A, Kühl S. Metastases and primary tumours around dental implants: A literature review and case report of peri-implant pulmonary metastasis. *Quintessence Int* 2012; **43**: 563–570.

4. Sarode G S, Sarode S C, Patil A *et al*. Inflammation and Oral Cancer: An update review on targeted therapies. *J Contemp Dent Pract* 2015; **16**: 595–602.
5. Moergel M, Kämmerer P, Kasaj A *et al*. Chronic periodontitis and its possible association with oral squamous cell carcinoma – a retrospective case control study. *Head Face Med* 2013; **9**: 39.
6. Camacho-Alonso F, Sánchez-Siles M, Gilbel-Águila O. No evidence of genotoxic damage in a group of patients with titanium dental implants and different metal restorations in the oral cavity. *Clin Implant Dent Relat Res* 2015; **17**: 811–821.
7. Moshref M, Jamilian A, Lotfi A, Showkatbakhsh R. Oral squamous carcinoma associated with dental implant—a case report and literature review. *J Clin Exp Dent* 2011; **3**: e166–e168.
8. Sappayatosok K, Maneerat Y, Swadison S *et al*. Expression of pro-inflammatory protein, iNOS, VEGF and COX-2 in Oral Squamous Cell Carcinoma (OSCC), relationship with angiogenesis and their clinico-pathological correlation. *Med Oral Patol Oral Cir Bucal*. 2009; **14**: E319–E324.
9. Meijer G J, Dieleman F J, Bergé S J, Mekx M A. Removal of an oral squamous cell carcinoma including parts of osseointegrated implants in the marginal mandibulectomy. A case report. *Oral Maxillofac Surg* 2010; **14**: 253–256.
10. Kwok J, Eyeson J, Thompson I, McGurk M. Dental implants and squamous cell carcinoma in the at risk patient—report of 3 cases. *Br Dent J* 2008; **205**: 543–545.
11. Gulati A, Puthussery F J, Downie I P, Flood T R. Squamous cell carcinoma presenting as peri-implantitis: A case report. *Ann Rev Coll Surg Engl* 2009; **91**: 8–10.
12. Moergel M, Karbach J, Kunkel M, Wagner W. Oral squamous cell carcinoma in the vicinity of dental implants. *Clin Oral Invest* 2014; **18**: 277–284.
13. Schache A, Thavaraj S, Kalavrezos N. Osseointegrated implants: a potential route of entry for squamous cell carcinoma of the mandible. *Br J Oral Maxillofac Surg* 2008; **46**: 397–399.
14. Shaw R, Sutton D, Brown J, Cawood J. Further malignancy in field change adjacent to osseointegrated implants. *Int J Oral Maxillofac Surg* 2004; **33**: 353–355.
15. De Ceulaer J, Magremanne M, Van-Veen A, Scheerlinck J. Squamous cell carcinoma recurrence around dental implants. *J Oral Maxillofac Surg* 2010; **68**: 2507–2512.
16. Nariai Y, Kanno T, Sekine J. Histopathological features of secondary squamous cell carcinoma around a dental implant in the mandible after chemoradiotherapy: A case report with a clinicopathological review. *J Oral Maxillofac Surg* 2015; **1**–9. DOI:10.1016/j.joms.2015.11.04.
17. Javed F, Al-Askar M, Qayyum F, Wang H L, Al-Hezaimi K. Oral Squamous cell carcinoma arising around osseointegrated dental implants. *Implant Dent* 2012; **21**: 280–286.
18. Marini E, Spink M J, Messina A M. Peri-implant primary squamous cell carcinoma: A case report with 5 years follow up. *J Oral Maxillofac Surg* 2013; **71**: 322–326.
19. Czerninsky R, Kaplan I, Almozni G, Maly A, Regev E. Oral squamous cell carcinoma around dental implants. *Quintessence Int* 2006; **37**: 707–711.
20. Abu El-Naaj I, Trost O, Tagger-Green N *et al*. Peri-implantitis or squamous cell carcinoma. *Rev Stomatol Chir Maxillofac* 2007; **108**: 458–460.
21. Gallego L, Junquera L, Baladrón J, Villarreal P. Oral squamous cell carcinoma associated with symphyseal dental implants: An unusual case report. *J Am Dent Assoc* 2008; **139**: 1061–1065.
22. Gallego L, Junquera L, Llorente S. Oral carcinoma association with dental implant overdenture trauma. *Dent Traumatol* 2009; **25**: e3–e5.
23. Block M S, Scheufler E. Squamous cell carcinoma appearing as peri-implant bone loss: A case report. *J Oral Maxillofac Surg* 2001; **59**: 1349–1352.
24. Clapp C, Wheeler J C, Martof A B, Levine P A. Oral squamous cell carcinoma in association with dental osseointegrated implants. An unusual occurrence. *Arch Otolaryngol Head Neck Surg* 1996; **122**: 1402–1403.
25. Moxley J E, Stoelting P J, Blijdorp P A. Squamous cell carcinoma associated with a mandibular stable implant. *J Oral Maxillofac Surg* 1997; **55**: 1020–1022.
26. Chimenos-Küstner E, López-López J, Finestres-Zubeldia F. Squamous carcinoma after dental implants: A clinical Case. *Rev Port Estomatol Cir Maxilofac* 2008; **49**: 97–100.
27. Verhoeven J W, Cune M S, Van-Es R J. An unusual case of implant failure. *Int J Prosthodont* 2007; **20**: 51–54.
28. Dib L L, Soares A L, Sandoval R L, Nannmark U. Breast metastasis around dental implants: a case report. *Clin Implant Dent Relat Res* 2007; **9**: 112–115.
29. Bhatavadekar NB. Squamous cell carcinoma in association with dental implants: An assessment of previously hypothesized carcinogenic mechanisms and a case report. *J Oral Implantol* 2012; **38**: 792–798.
30. Eguia del Valle A, Martínez-Conde Llamas R, López Vicente J, Uribarri Etxebarria A, Aguirre Urizar JM. Primary oral squamous cell carcinoma arising around dental implant osseointegrated implants: mimicking peri-implantitis. *Med Oral Patol Oral Cir Bucal* 2008; **13**: E489–E491.
31. Jeelani S, Rajkumar E, Mary G G, Khan P A, Gopal H, Roy S *et al*. Squamous cell carcinoma and dental implants: A systematic review of case reports. *J Pharm Bioallied Sci* 2015; **7** (Suppl 2): S378–S380.
32. De Souza M B, Curioni O A, Kanda J L, De-Carvalho M B. Serum and salivary macrophage migration inhibitory factor in patients with oral squamous cell carcinoma. *Oncol Lett* 2014; **8**: 2267–2275.
33. Zamarron B F, Chen W. Dual roles of immune cells and their factors in cancer development and progression. *Int J Biol Sci* 2011; **7**: 651–658.
34. Evrard L, Waroquier D, Parent D. Allergies to dental metals. Titanium: A new allergen. *Rev Med Brux* 2010; **31**: 44–49.
35. Özcan M, Hämmerle C. Titanium as a Reconstruction and Implant Material in Dentistry: Advantages and Pitfalls. *Materials* 2012; **5**: 1528–1545.
36. Sicilia A, Cuesta S, Coma G *et al*. Titanium allergy in dental implant patients: A clinical study on 1500 consecutive patient. *Clin Oral Impl Res* 2008; **19**: 823–835.
37. Raubenheimer E J, Noffke C E. Pathogenesis of bone metastasis: A review. *J Oral Pathol Med* 2006; **35**: 129–135.
38. Favia G, Tempesta A, Limongelli L, Crincoli V, Piattelli A, Maiorano E. Metastatic breast cancer in medication-related osteonecrosis around mandibular implants. *Am J Case Rep* 2015; **16**: 621–626.
39. Chaturvedi TP. An overview of the corrosion aspect of dental implants (titanium and its alloys). *Indian J Dent Res* 2009; **20**: 91–98.
40. Bholra R, Bholra S M, Mishra B, Olson D L. Corrosion in titanium dental implants/prostheses- A review. *Trends Biomater Artif Organs* 2011; **25**: 34–46.
41. Goutam M, Giriyaipura C, Mishra S K, Gupta S. Titanium allergy: A literature review. *Indian J Dermatol* 2014; **59**: 630.
42. Baan R, Straif K, Grosse Y, Secretan B, El Guissassi F, Coglianò V. Carcinogenicity of carbon Black, titanium dioxide, and talc. *Lancet Oncol* 2006; **7**: 295–296.
43. Doran A, Law F C, Allen M J, Rushton N. Neoplastic transformation of cells by soluble but not particulate forms of metals used in orthopaedic implants. *Biomaterials* 1998; **19**: 751–759.
44. Lee C H, Chang J S, Syu S H *et al*. IL-1 $\beta$  promotes malignant transformation and tumour aggressiveness in oral cancer. *J Cell Physiol* 2015; **230**: 875–884.
45. González-Moles M A, Scully C, Gil-Montoya J A. Oral lichen planus: controversias surrounding malignant transformation. *Oral Dis* 2008; **14**: 229–243.