Clinical guide to periodontology: Reconstructive periodontal treatment

P. D. Floyd,[1] M. Ide[2] and R. M. Palmer*[3]

IN BRIEF

- Informs surgical techniques for the regeneration of the periodontal ligament include the use of membranes and grafts, and the application of biological agents and growth factors.
- Highlights surgical treatment of gingival recession can be achieved by coverage of exposed root surfaces with soft tissue and by the creation of new keratinised and attached gingiva.

PRACTICE

Regeneration of the lost tissues of the periodontium is an ideal therapeutic goal and has been the subject of much research and ingenious clinical techniques. Reconstructive or regenerative techniques are used either singly or in combination for three main purposes: (1) to regain lost periodontal ligament attachment, (2) to provide a wider zone of attached gingiva, and (3) to cover previously exposed root surfaces.

REGENERATION OF THE PERIODONTAL LIGAMENT

Regeneration involves re-formation of cementum, bone and periodontal ligament, attached to the mineralised tissues by Sharpey's fibres. A simple way to appreciate the events involved would be to consider the healing of an infrabony pocket treated by replaced flap surgery and to consider how this may be modified (Fig. 1). Preservation of soft tissue flaps that are closely approximated to the tooth surfaces should give maximum protection to the underlying clot and connective tissues.

The clot acts as a glue between the flap, tooth surface and underlying tissues and acts as a scaffold for the healing process. The clot is rapidly organised by capillaries and fibroblasts, which proliferate from the adjacent tissues, gingival connective tissue, bone and periodontal ligament. The gingival epithelium rapidly divides and migrates on the connective tissue aspect of the flap to eventually contact the tooth surface and form a junctional epithelium. This rapid epithelial migration has been held responsible for the prevention of a connective tissue attachment following routine surgical procedures. Is it worth recalling here that the post-disease compromised state of the root surface may also have an impact on healing.

Cell division, migration, differentiation, adhesion, matrix deposition, organisation and compartmentalisation in this process are extremely complex. These factors are only simplistically addressed in current therapeutic procedures. Initially, the alveolar bone that has been exposed during surgery undergoes resorption, which is more pronounced following prolonged exposure and surgical recontouring. Traditionally, the types of bone defects that show the best response to conventional treatment are deep and narrow with large areas of surrounding bone and periodontal ligament. These defects have been classified variously as intrabony, infrabony or 'three-wall' and also show the best response to regenerative techniques. Conversely, broad defects with only one remaining bone wall have less favourable regenerative potential. The most challenging area is supracrestal regeneration where the destructive process has resulted in horizontal bone and attachment loss. Because of variable and unpredictable clinical results many attempts have been made to improve this process:

- Grafting with bone or bone substitutes
- Root surface conditioning
- Guided tissue regeneration
- Growth factor application.

Grafting with bone or bone substitutes

Bone loss and repair are normally assessed radiographically although some research studies have employed surgical re-entry procedures. There is no doubt that bone repair can occur following those non-surgical and simple surgical treatments that effectively eliminate inflammation (Fig. 2). Grafting with bone and bone substitutes to enhance this repair process has been a popular procedure and has experienced a revival/reappraisal. An increased radiodensity will result from the placement of a graft material (particularly if mineralised) into a bone defect. This will produce a radiographic improvement if the measuring system is sufficiently sophisticated. Synthetic materials that are non-resorbable, such as dense particulate hydroxyapatite or deproteinised

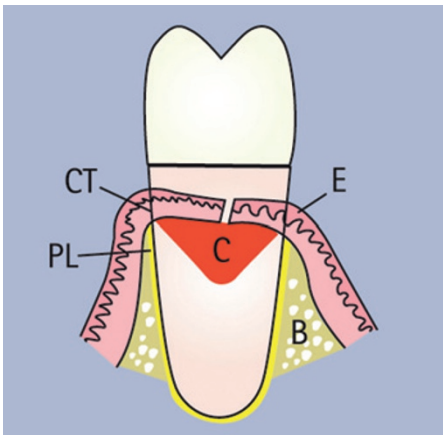

Fig. 1 Diagram of an infrabony defect treated by flap surgery, showing good coverage by the flap and potential tissue contributions to the area from epithelium (E), gingival connective tissue (CT), alveolar bone (B) and periodontal ligament (PL). The defect is initially filled with blood clot (C). Optimum results can only be achieved if the affected root surface has been meticulously instrumented and subsequently kept free of plaque

CLINICAL GUIDE TO PERIODONTOLOGY*

1. Pathology of periodontal disease
2. **Reconstructive periodontal treatment**
3. Multidisciplinary integrated treatment

*This series represents chapters 2, 9 and 10 from the BDJ Book *A clinical guide to periodontology*, 3rd ed, edited by Richard Palmer, Mark Ide and Peter Floyd. All other chapters are published in the complete clinical guide available from the BDJ Books online shop.

[1]Specialist in Periodontics, Principal, Periodontics UK, Wimpole Street, London; [2]Head of Periodontology, [3]Professor of Implant Dentistry and Periodontology, King's College London Dental Institute, London
*Correspondence to Richard Palmer
Email: rich.m.palmer@gmail.com

DOI: 10.1038/sj.bdj.2014.354
©British Dental Journal 2014; 216: 511–518

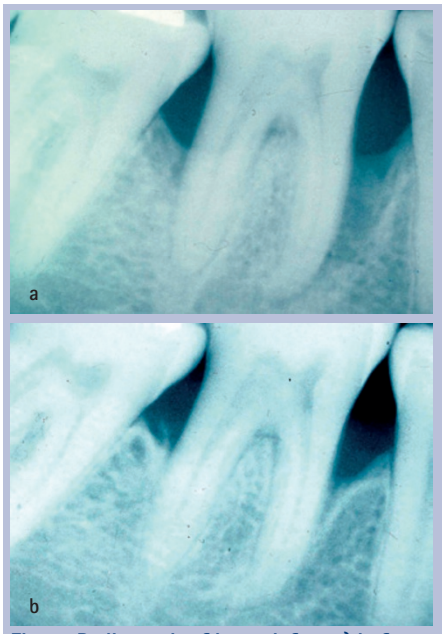

Fig. 2 Radiograph of bone defect a) before treatment and b) bone fill after treatment

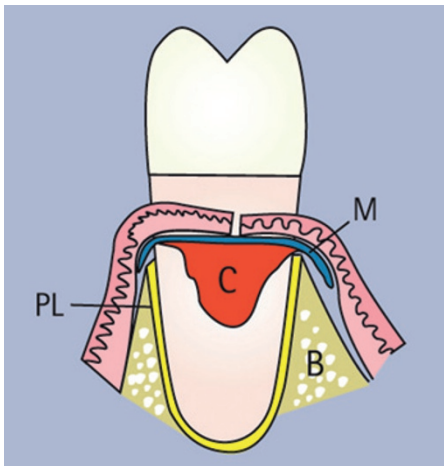

Fig. 3 Diagram of infrabony defect, as shown in Figure 1, showing placement of an exclusionary membrane (M) to prevent contributions by epithelium and gingival connective tissue while allowing periodontal ligament (PL) and bone (B) to grow into the area

bovine bone, are incorporated in the healing tissue and are eventually surrounded by fibrous tissue and variable amounts of bone formation. The material should be viewed as a space filler with variable osteoconductive and no osteoinductive properties.

Bioactive glasses have been shown to bond to bone and soft tissues and provide good space maintenance. Gains in clinical attachment have been shown post-surgically in addition to radiographic bone fill. Other forms of calcium phosphate/hydroxyapatite are more rapidly resorbed, but replacement with bone is highly variable. Bone repair following grafting with both resorbable and non-resorbable synthetic materials is unfortunately no more predictable than an ungrafted defect, although the former often show radiographic advantages.

Guided tissue regeneration

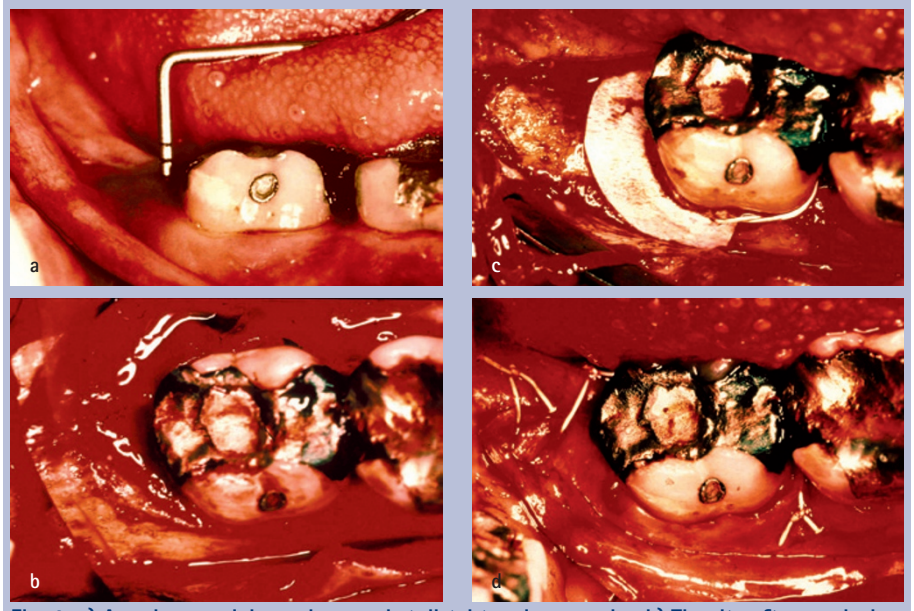

Fig. 4 a) A probe examining a deep pocket distal to a lower molar. b) The site after surgical exposure showing a large bone defect. c) Following extensive root planing and removal of inflammatory tissue the defect is covered with a non-resorbable Gore-Tex membrane which is secured with a suture. d) The membrane is completely covered with the flap and left buried for 4-6 weeks. It is then removed with a secondary surgical procedure

Guided tissue regeneration

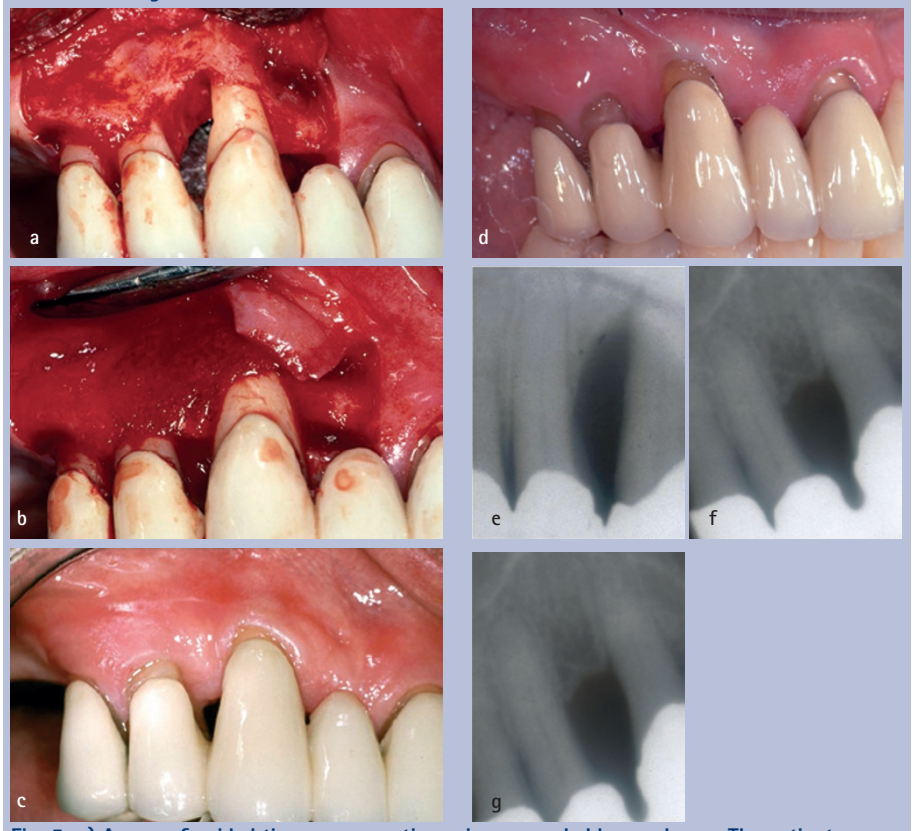

Fig. 5 a) A case of guided tissue regeneration using a resorbable membrane. The patient presented with a deep pocket and substantial bone loss on the distal aspect of 13, which is a key support for a large existing bridge. Buccal and palatal flaps have been raised and the root surfaces cleaned in preparation for regeneration. b) The membrane (Resolut) has been placed and adapted closely around the root of 13. A resorbable suture will now be placed mesial to 13 to prevent the membrane from collapsing into the distal defect. c) One year postoperative. A new restoration has been placed. The soft tissues are healthy and there is no significant probing depth. d) 13 years postoperative. During the 12 years between figures c and d there has been a small amount of gingival recession. The tissues remain healthy with no significant probing depth. e) Preoperative radiograph. f) One year postoperative. g) Ten years postoperative

Grafting with bone or bone substitutes

Fig. 6 a) Presentation showing a probing depth of 9 mm between 31, 32. There is a discharge of pus from the mesial of 32. b) The flaps have been raised and inflammatory tissue removed, revealing an extensive bone defect, 5 mm deep, on the mesial of 32. c) The flaps have been presutured using a non-wicking material (Gore-Tex) and the bone defect filled with a bioactive glass (PerioGlas). d) One month postoperative, showing soft tissue shrinkage. (e) One year postoperative, showing tissue remodelling. f) One year postoperative, with probe in the residual pocket on the mesial of 32. g) Ten years postoperative, showing long-term stability. h) Radiographs pre-grafting (left) post-grafting (centre) and after 10 years (right)

Grafts of autogenous bone can be obtained from intraoral sites (for example, mandibular external oblique ridge/ramus) using small trephines, burs, chisels or purpose-designed bone scrapers, with little additional discomfort to the patient. The amount of bone available can be limited and the desire to avoid major surgery for the procurement of large quantities of autogenous bone graft material has led to the utilisation of human allograft bone bank material or xenograft material (for example, bovine anorganic bone). These graft materials, which are commonly used in periodontal surgery and augmentation for implants, are obtained from human donors screened for blood-borne diseases or from animals that are certified disease free from accredited herds, and must be thoroughly treated to render them safe and non-antigenic. Bone bank material is freeze-dried and available as either mineralised or demineralised forms. Bone morphogenetic proteins within the human bone material may be important for their effectiveness at inducing new bone formation. The deproteinised bovine bone provides a good mineral matrix with optimum pore size for ingrowth of host bone. These particulate grafts are often contained within the defects using xenogeneic collagen membranes.

Repair of bone within a periodontal defect is a good sign, regardless of the procedure used, as it indicates a marked reduction of inflammation. It has been demonstrated in animal models and limited human histological material, however, that despite the appearance of a relatively normal radiographic periodontal ligament space, the attachment to the root surface is a long junctional epithelium with a narrow zone of connective tissue between it and newly formed bone. This is taken as evidence that epithelialisation of the root surface is a major factor preventing formation of a connective tissue attachment. It could also be viewed as a protection against formation of a bony ankylosis/resorption.

Root surface conditioning

All periodontal surgical procedures give access to the root surface to allow thorough debridement. Demineralisation of debrided/planed root surfaces removes the smear layer, exposing collagen fibrils, and may enhance initial adhesion of the blood clot/connective tissue of the flap and subsequently allow formation of a collagen fibre linkage. Early animal experiments using citric acid (pH 1) also demonstrated an accelerated cementogenesis and therefore true connective tissue attachment. Subsequent human clinical trials failed to substantiate these observations and root resorption was reported as a complication. There is still interest in

Table 1 Patients' concerns about gingival recession
Tooth loss
Appearance
Sensitivity to hot and cold
Gingival soreness or bleeding
Will it progress?

Table 2 Examination of gingival recession and associated mucogingival problems
Tooth involved: are there prognostic or aesthetic implications such as furcation exposure on molar teeth or visible recession on anterior teeth?
Measurement of recession: – Distance cement-enamel junction to gingival margin – Width of recession – is there any associated clefting of the gingival tissues? – Height of adjacent papillae – is there interdental recession and loss of attachment?
= Probing depth and presence of pocketing
Width of keratinised gingiva – measure from gingival margin to mucogingival junction, then subtract probing depth to give width of attached gingiva
Functional inadequacy of attached gingiva is present if: – Gingival margin pulls away from tooth surface when tension is applied to mucosa (fraenae may also be involved) – The gingival/mucosal junction is continuously traumatised by patient's oral hygiene efforts – Coexisting pockets extend beyond mucogingival junction – There is measurable progression of recession
Pattern of bone loss – Interproximal bone height – Lateral extension of dehiscence further apically
Do not forget to examine the restorative/endodontic status of the affected tooth for the presence of abrasion cavities (+/– erosion)

Table 3 Indications for treatment of recession/lack of attached gingiva
Aesthetics: improve appearance
Recession and pocketing: simultaneous correction of pocket depth
Progressive recession: root coverage or increase gingival width
Improve local anatomy: – reduce progression – facilitate oral hygiene

Coronally repositioned flaps and pedicle grafts

Fig. 7 a) Patient on presentation with marked recession on the labial aspect of 31. The recession extends well beyond the mucogingival junction. b) Closer view showing obvious inflammation of the soft tissue margins. c) Following initial therapy there has been a marked reduction of the inflammation. d) The initial excision of the detached inflammatory tissues and fraenum is completed. e) The papillae between 31, 32 and 32, 33 have been raised as a split thickness dissection. A piece of palatal connective tissue has been harvested and laid over the exposed roots and soft tissues at the recipient site. f) The pedicle is moved mesially so that the interdental gingiva now overlies the exposed roots and is secured with suspensory sutures. The 'free' connective tissue graft therefore has an adequate nutrient supply for healing to occur over the avascular root surfaces. g) One month postoperative, showing excellent initial healing and good but not complete root surface coverage. h) Ten years postoperative, showing gingival health and stability of the position of the gingival margin

this area; for example, utilising solutions of tetracycline, which have properties of demineralisation and substantivity in addition to their antibacterial activity.

Guided tissue regeneration

In a now classic series of experimental studies in animal models it was shown that the residual periodontal ligament is the most likely tissue to contain cells capable of regenerating a new periodontal ligament attachment. During healing of a periodontal defect, guided tissue regeneration (GTR) aims to provide conditions that facilitate ingrowth of cells from the ligament while excluding those derived from epithelium and gingival connective tissue. The surgical procedure is therefore modified to allow placement of an exclusionary membrane between the meticulously instrumented root surface and the overlying flap (Fig. 3). The procedure is illustrated in Figures 4-5.

Ideally, the membrane should form a small tent over the defect to provide sufficient space to accommodate the missing tissues. Organisation of the clot is therefore limited to contributions from the periodontal ligament and alveolar bone. Whereas it was initially postulated that the appropriate progenitor

Coronally repositioned flaps and pedicle grafts

Fig. 8 a) On presentation there is recession on 41 extending apically to the mucogingival junction. The marginal tissues are very inflamed. b) After initial therapy, showing reduction in inflammation. c) Immediately preoperatively. d) Excision of the fraenum and surrounding marginal tissue in preparation for creation of the pedicle. e) The pedicle has been raised and mobilised to prepare for suturing. f) The pedicle has been transposed and sutured into position. A connective tissue graft extends from the mesial of 41 to the mesial of 43, covering the exposed root surface of 42. g) One month postoperative, showing excellent initial healing. h) Ten years postoperative, showing stability of the position of the gingival margins

cells were present solely in the periodontal ligament, it now seems that cells within the bone may also contribute to the formation of the ligament/cementum. Although ankylosis is theoretically possible, in practice it does not seem to occur and the improvements in attachment levels have been attributed to regeneration, although limited histological proof is available in human specimens.

Most of the early clinical studies used non-resorbable membranes made of e-PTFE (Gore-Tex). This material had to be removed 4-6 weeks after the initial surgical procedure, requiring a second operation and healing period. This led to the development of resorbable membranes made from synthetic materials such as polyglactin/polylactide (the same material as some sutures for example, Vicryl) or from animal collagen. The physical properties of some of these materials make them difficult to handle clinically.

Most published trials with GTR membranes report a small but statistically significant advantage over control surgical sites. The procedure can produce some very good clinical results, especially in deep three-wall defects on single-rooted teeth. Results are poorer in smokers and if the membrane becomes exposed shortly after placement. The initial promise in the treatment of furcation involvements has not been sufficiently realised. More research is required to define which patients and which defects would benefit most from this treatment and how well results are maintained in the long term. The GTR technique is currently most widely used in conjunction with a bone substitute which provides support for the membrane and a matrix for cell ingrowth beneath the membrane. There has also been significant development in microsurgical techniques with minimal access surgery to root surfaces, which appears to produce comparable clinical results without recourse to grafts or membranes.

Growth factor application

This is a rapidly developing field that has had some promising clinical trials. Freeze-dried bone, which has been extensively used, is probably effective because of sufficient levels of residual osteogenic proteins such as the bone morphogenetic proteins. Periodontal ligament fibroblast proliferation may be enhanced by growth factors such as platelet-derived growth factor and insulin-like growth factor. Techniques are available to mass produce growth factors (for example, bone morphogenetic proteins and bone-associated peptide sequences), and technology is being developed to allow slow release over sufficient time periods to promote success. One product that is currently commercially available is enamel matrix derivative, which consists of proteins extracted from porcine enamel (for example, amelogenin, enamelin). Its theoretical action is based upon attempted recapitulation of periodontal ligament development, in which Hertwig's root sheath secretes enamel proteins before its disintegration, thereby inducing differentiation of cementoblasts. It also appears to promote better soft tissue healing. Clinical trials have shown small advantages in clinical attachment gain when this material is applied compared with routine surgery.

Regenerative surgical techniques are technique sensitive and the best results seem to be achieved when defects are treated singly, rather than as part of a larger area, and with minimally invasive techniques, often requiring special instruments and suturing techniques.

Conclusion

The quest for more predictable regeneration has led some clinicians to combine treatment procedures such as acid demineralisation of the root surface, grafting with freeze-dried bone and covering the defect with an

Coronally repositioned flaps and pedicle grafts

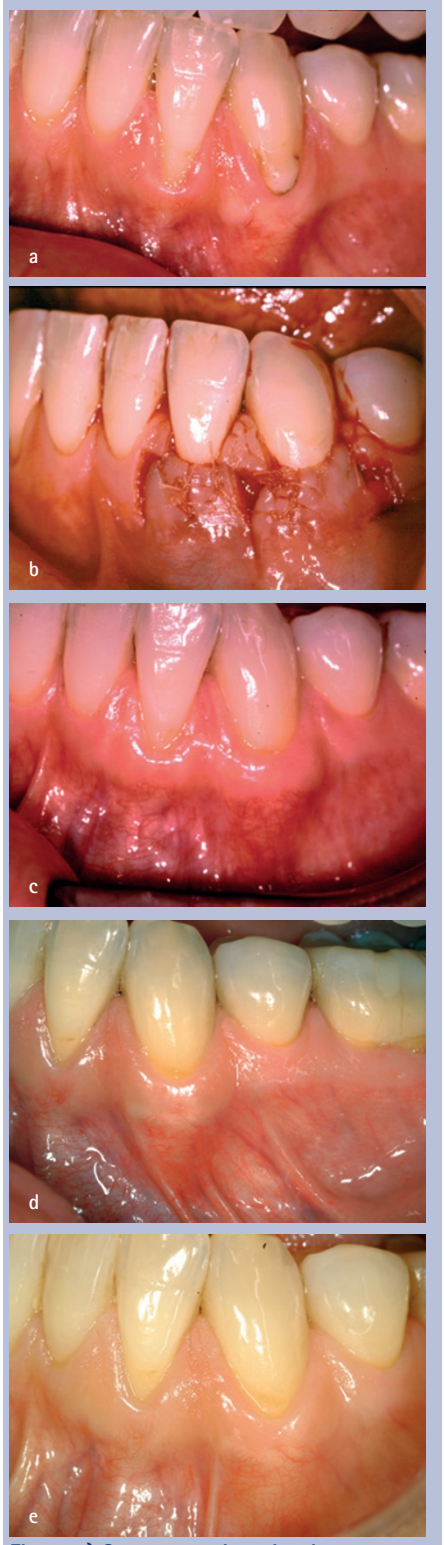

Fig. 9 a) On presentation, showing recession 33, 32. There is a cervical restoration on the labial of 33. b) Four pedicle flaps have been raised as two double papilla flaps and laterally transposed to cover the exposed root surfaces. The restoration in 33 has been removed. The flaps are sutured together and suspended around the teeth. c) Two months postoperative. d) One year postoperative. e) Ten years postoperative. The marginal gingival tissue is healthy and the position is stable over 10 years

Coronally repositioned flaps and pedicle grafts

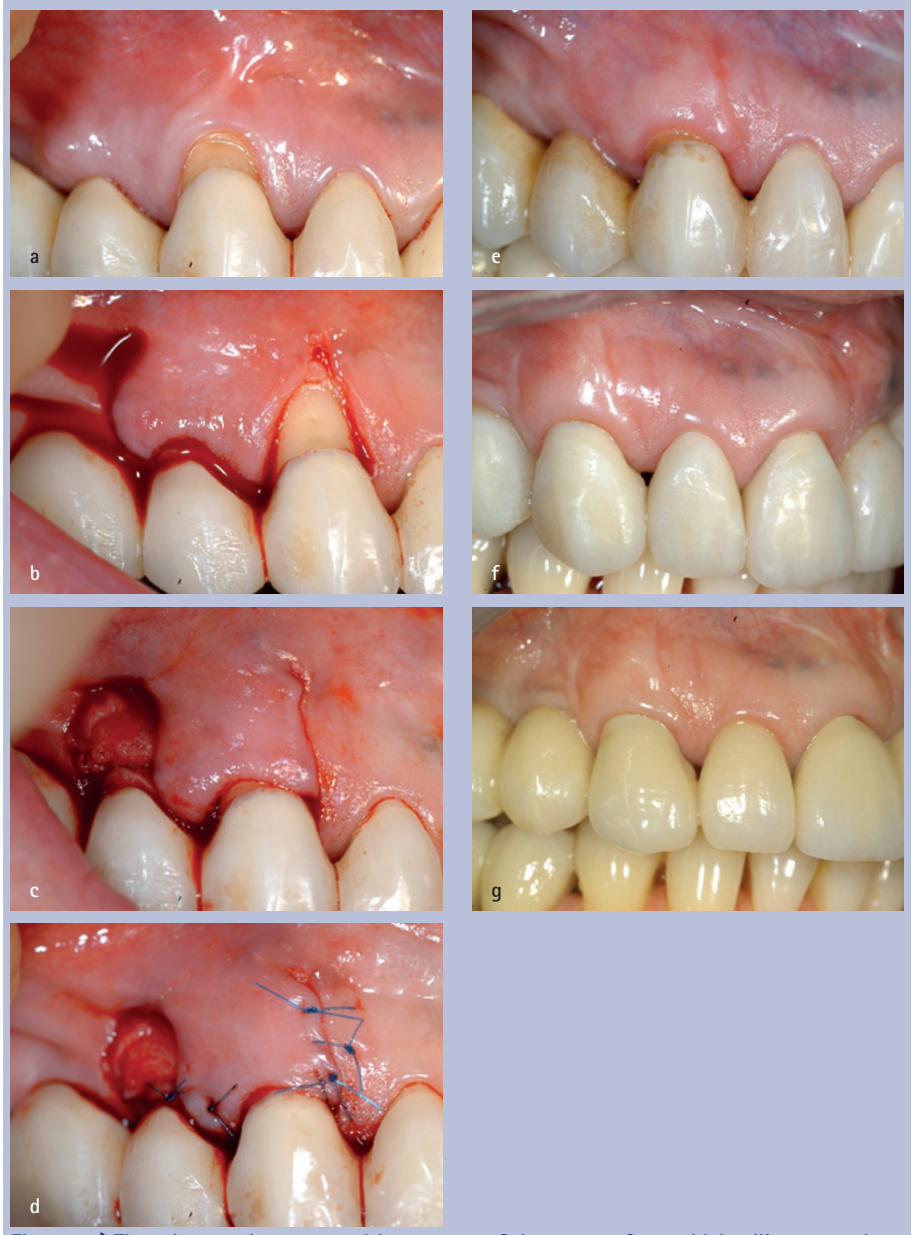

Fig. 10 a) There is recession at 13, with exposure of the root surface, which will compromise the final restorative result. b) The tissues marginal to the recession have been excised and a vertical relieving incision placed distal to 14 in preparation for raising a pedicle flap. c) The pedicle has been raised and transposed mesially to cover the exposed root surface. It remains in place without tension. d) The pedicle has been sutured with interrupted sutures in the mesial vertical with a suspensory suture passing around the palatal of 13 to adapt the pedicle over the root surface. e) One month postoperative, showing initial healing. f) One year postoperative, showing maturation of the soft tissues and good root coverage. g) Ten years postoperative, showing long-term stability of the surgical result

exclusionary membrane. Promising results have been published with these techniques but it is far from clear what the optimum combinations are in any given situation, and in clinical trials such combinations rarely offer much greater benefits than the use of single technologies. Optimum healing still relies on careful flap handling to achieve wound coverage/stability and clot/granulation tissue protection. Prevention of bacterially induced inflammation during the initial healing and subsequent maturation process (adequate root surface cleaning and good plaque control by the patient) is essential to achieve a satisfactory result.

TREATMENT OF GINGIVAL RECESSION

Gingival recession occurs with chronic periodontitis as a result of the disease process and as a consequence of successful treatment. This section, however, will consider localised gingival recession. Thin gingival tissues, under which there may be missing bone

Coronally repositioned flaps and pedicle grafts

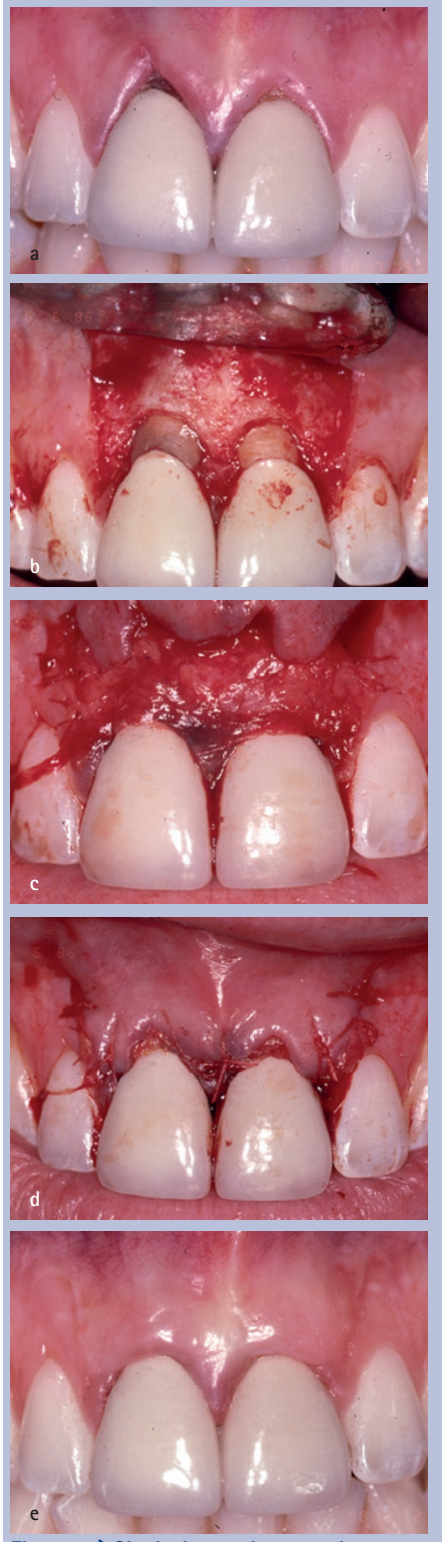

Fig. 11 a) Gingival recession exposing crown margins on central incisors. The gingival margin on the right incisor shows some clefting. b) Flap raised by full and partial thickness dissection and relieving incisions on the mesial line angles of the lateral incisors. c) A connective tissue graft taken from the palate has been placed to cover the prepared root surfaces. d) The flap has been placed to cover the graft and secured with fine Vicryl sutures. e) The healed result with new provisional crowns

Coronally repositioned flaps and pedicle grafts

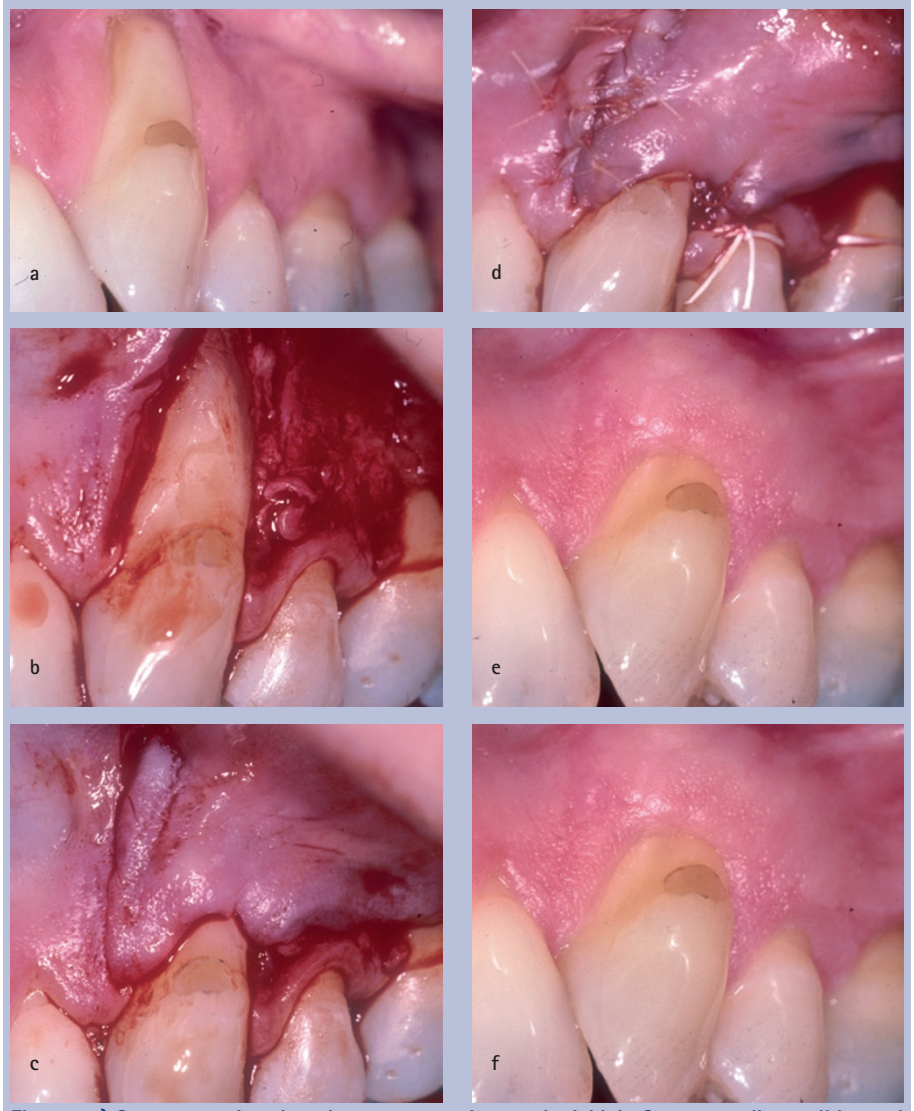

Fig. 12 a) On presentation there is severe recession on the labial of 23, extending well beyond the mucogingival junction. There is labial pocketing and a fleshy fraenum. Interdentally the attachment levels are good. b) An extensive buccal pedicle has been raised from 23 to 27, leaving a collar of gingiva on the buccal of 24. c) The pedicle is transposed mesially to lie, without tension, over the exposed root surface, which has been cleaned and has had some root surface removed to reduce prominence. d) The pedicle is sutured into position, without tension, over a graft of connective tissue. e) Three months postoperative. There has been substantial but not complete coverage of the exposed root and the creation of a wide zone of keratinised gingiva. f) One year postoperative, showing an unchanged and stable result

(dehiscences and fenestrations), is the main predisposing factor. The direct causative factor may be trauma, for example from overaggressive toothbrushing, or plaque-induced inflammatory damage.

Gingival recession results in root exposure, which may produce an aesthetic problem or a reduction in the width of keratinised/attached gingiva. There is considerable debate as to what constitutes an adequate width of attached gingiva from a functional/biological view.

It is obviously important to address the patient's complaint (Table 1) and to determine the importance of the physical features in relationship to it (Table 2). In many patients with localised gingival recession the initial management should be accurate recording of the recession, elimination of traumatic toothbrushing and adoption of effective atraumatic cleaning, and review to determine whether it is stable/progressive or of continuing concern to the patient. The latter circumstances will warrant consideration of surgical procedures to deal with the problem.

Surgical treatment

Surgical procedures can have two objectives:

1. Coverage of exposed root surfaces with soft tissue
2. Creation of new keratinised and attached gingiva.

The indications for treatment are summarised in Table 3. Improvement of appearance by

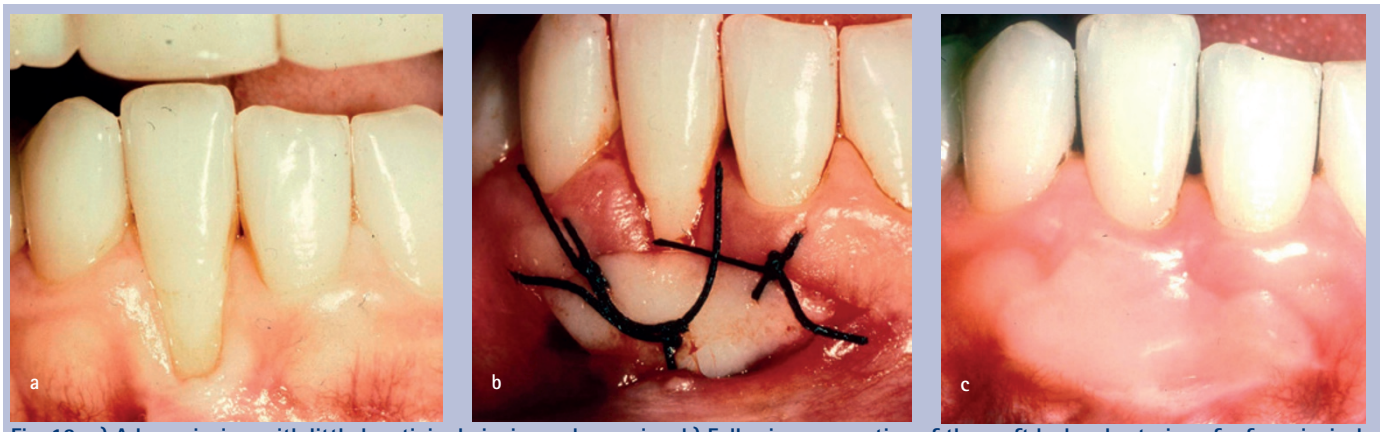

Fig. 13 a) A lower incisor with little keratinised gingiva and recession. b) Following preparation of the graft bed and suturing of a free gingival graft taken from the palate. c) Healed result after one year showing wide zone of attached keratinised gingiva and reduction of recession, which has been helped by further 'creeping reattachment' of the gingival tissues

attempting soft tissue coverage of the exposed root surface is more technically and biologically demanding than increasing the amount of keratinised tissue. The former requires a biological adhesion (epithelial attachment) and possibly new connective tissue attachment to the root surface, as described in the section on regeneration. At the same time the soft tissue has to re-establish a blood supply to adjacent connective tissue because the root surface itself is avascular. This is achieved either by coronal repositioning of a wider flap or by using lateral pedicle grafts. In both cases the flap maintains a blood supply from its base and revascularises to adjacent interdental connective tissues that have had the epithelial surface denuded. In addition, the thickness of the soft tissue can be increased by inserting a sliver of connective tissue (taken from the palate) between the flap and the root surface. The coronal level of the root coverage is limited by the height of the adjacent interdental soft tissues. Increasing the zone of keratinised tissue can be achieved with a free gingival graft (see section entitled 'Free gingival graft'). An epithelial and connective tissue slice taken from the palate is grafted onto a connective tissue bed that is surgically created apical to the area of recession. Survival of this free graft is dependent on an initial supply of nutrient plasma followed by rapid revascularisation from the host bed. This should be readily achieved providing the graft is well stabilised and has been handled as atraumatically as possible. All of these procedures need to be performed with great care and the use of microsurgical techniques is common

Coronally repositioned flaps and pedicle grafts

Procedures that aim to repair areas of recession and thereby cover denuded root surfaces may be made more predictable by using a graft that maintains a blood supply (that is, a pedicle graft). This requires a suitable adjacent donor site that can be compromised by the procedure. Cases are illustrated in Figures 7-12.

Free gingival graft

This procedure is usually employed to produce a wider zone of attached/keratinised gingiva without necessarily altering the position of the gingival margin. It is illustrated in Figure 13. It involves transplantation of a graft of connective tissue covered by epithelium from the palate to a recipient site. The graft initially survives by diffusion of plasma from the recipient bed and the connective tissue dictates the type of epithelium growing on it.

CONCLUSIONS

Regenerative and reconstructive techniques in periodontics are exciting areas of new developments based on good research and sound clinical practice. It is hoped that this paper gives an idea of the range of techniques available and the type of situations where they are applicable.

FURTHER READING

Systematic reviews

Cairo F, Pagliaro U, Nieri M. Treatment of gingival recession with coronally advanced flap procedures: a systematic review. *J Clin Periodontol* 2008; **35:** 136-162.

Chambrone L, Sukekava F, Araújo M G, Pustiglioni F E, Chambrone L A, Lima L A. Root coverage procedures for the treatment of localised recession-type defects. *Cochrane Database Syst Rev* 2009; **Issue 2:** CD007161.

Esposito M, Grusovin M G, Papanikolaou N, Coulthard P, Worthington H V. Enamel matrix derivative (Emdogain®) for periodontal tissue regeneration in intrabony defects. *Cochrane Database Syst Rev* 2009; **Issue 4:** CD003875.

Grusovin M G, Coulthard P, Worthington H V, George P, Esposito M. Interventions for replacing missing teeth: maintaining and recovering soft tissue health around dental implants. *Cochrane Database Syst Rev* 2010; **Issue 8:** CD003069.

Needleman I, Worthington H V, Giedrys-Leeper E, Tucker R. Guided tissue regeneration for periodontal infra-bony defects. *Cochrane Database Syst Rev* 2006; **Issue 2:** CD001724.

Patel R A, Wilson R F, Palmer R M. The effect of smoking on periodontal bone regeneration: a systematic review and metaanalysis. *J Periodontol* 2012; **83:** 143-155.

Trombelli L, Farina R. Clinical outcomes with bioactive agents alone or in combination with grafting or guided tissue regeneration. *J Clin Periodontol* 2008; **35:** 117-135.

Background/historical literature

Bernimoulin J P, Luscher B, Muhlemann H R. Coronally repositioned periodontal flap. *J Clin Periodontol* 1975; **2:** 1-3.

Caton J, Nyman S. Histometric evaluation of periodontal surgery II. Connective tissue attachment levels after four regenerative procedures. *J Clin Periodontol* 1980; **7:** 224-231.

Cortellini P, Pini Prato G, Tonetti M. Periodontal regeneration of human infrabony defects: V Effect of oral hygiene on long term stability. *J Clin Periodontol* 1994; **21:** 606-610.

Gottlow J, Nyman S, Karring T, Lindhe J. New attachment formation as the result of controlled tissue regeneration. *J Clin Periodontol* 1984; **11:** 494-503.

Langer B, Calagna L J. The subepithelial connective tissue graft. A new approach to the enhancement of anterior cosmetics. *Int J Periodontics Restorative Dent* 1982; **2:** 23-33.

Maynard J G. Coronal positioning of a previously placed autogenous gingival graft. *J Periodontol* 1977; **48:** 151-155.

Miller P D. A classification of marginal tissue recession. *Int J Periodontics Restorative Dent* 1985; **5:** 9-13.

Ripamonti U, Reddi A H. Periodontal regeneration: potential role of bone morphogenetic proteins. *J Periodontal Res* 1994; **29:** 225-235.

Sullivan H C, Atkins J H. Free autogenous gingival grafts. I Principles of successful grafting. *Periodontics* 1968; **6:** 130-136.

Sullivan H C, Atkins J H. Free autogenous gingival grafts. II Utilisation of grafts in the treatment of gingival recession. *Periodontics* 1968; **6:** 152-158.

The authors would like to acknowledge Adam Hasan and Tim Newton as specialist contributors to A clinical guide to periodontology, 3rd edition.