Oral surgery: part 4. Minimising and managing nerve injuries and other complications

T. Renton[1]

VERIFIABLE CPD PAPER

IN BRIEF

- Discusses the many complications related to all surgical interventions including haemorrhage, infection, pain and swelling.
- Familiarises the clinician with common complications related to dentoalveolar surgery and, more specifically, third molar surgery.
- Suggests some useful tips on minimising the risks of injuries arising from complications in oral surgery.

PRACTICE

Many post-operative complications can be avoided with good patient selection, training and surgical planning. Obtaining explicit patient consent is also an essential component of treatment. The most significant complications from oral surgical interventions are iatrogenic trigeminal nerve injuries, which can result in permanent altered sensation and pain, causing considerable functional and psychological disability. This paper provides some useful suggestions on minimising the risks of these injuries. By understanding the risk factors and modifying the resulting intervention, more of these injuries may be prevented.

COMPLICATIONS ASSOCIATED WITH ORAL SURGICAL TREATMENT

The removal of M3Ms is a common surgical procedure and – as with all surgical procedures – there is a risk of operative and post-operative complications. The rate of complications overall is reported to be 3.47%[1] and their severity varies. Known risk factors for poor surgical outcomes in relation to M3M surgery are surgical difficulty,[2] older age,[3] poor oral hygiene and smoking.[4]

The management of common and more serious complications is described below.

Nerve damage

Trigeminal nerve injury is the most problematic consequence of dental surgical procedures, with major medicolegal implications.[5] The incidence of lingual nerve injury has remained static in the UK over the last 30 years; however, the incidence of inferior alveolar nerve injury has increased, due to the increases in implant surgery and endodontic therapy (Fig. 1).[5] The risk factors associated with nerve injury in relation to third molar surgery include age and ethnicity of patient, length of surgery (difficulty), operator (inexperience) and, most importantly, lingual access surgery.[6]

Iatrogenic injuries to the third division of the trigeminal nerve remain a common and complex clinical problem. Altered sensation and pain in the orofacial region may interfere with speaking, eating, kissing, shaving, applying make-up, tooth brushing and drinking; in fact just about every social interaction we take for granted (Fig. 2).[7] Usually after oral rehabilitation, the patient expects and experiences significant improvements, not only regarding jaw function, but also in relation to dental, facial, and even overall body image. Thus these injuries have a significant negative effect on the patient's self-image and quality of life and the psychological sequale are worse because the injury is iatrogenic.[7]

ORAL SURGERY*

*This series represents chapters 1, 5, 7 and 8 from the *BDJ* book *A clinical guide to oral diagnosis - book 1*, edited by Tara Renton and C. Michael Hill. All other chapters are published in the complete clinical guide available from the BDJ Books online shop.

[1]Professor Oral Surgery, King's College London Dental Institute, Bessemer Road, London, SE5 9RS
Correspondence to: Tara Renton
Email: tara.renton@kcl.ac.uk; Tel: 0203 299 2313

Accepted 16 July 2013
DOI: 10.1038/sj.bdj.2013.993

FEATURES OF NERVE INJURIES

There are specific features of trigeminal nerve injuries associated with dental procedure:

Closed injuries

Lingual and inferior alveolar nerve injuries are normally closed injuries. Open sensory nerve injuries seen mainly on limbs due to trauma avail themselves to immediate exploration and repair without delay. Conversely our profession has a 'sit and wait' policy for resolution of trigeminal nerve injuries unless known section has taken place.

Resolution

Eighty-eight percent of lingual nerve injuries associated with conventional lingual access third molar surgery resolve[8,9] thus lulling our specialty into a false sense of security believing that all nerve injuries get better. This misconception has also led to the assumption that most inferior alveolar nerve injuries resolve whereas in fact they are predominantly permanent.[10,11]

Complexity of nerve injury

The complexity of nerve injury was previously classified by Seddon and Sunderland in the 1940s,[12] and focused on trying to differentiate nerve injuries anatomically; essentially the sub-types of injury bear no relationship to clinical presentation. It would be difficult to traumatise a nerve with a drill without causing a multitude of events including;

a) Direct mechanical trauma (tear, section, crush, stretch etc)
b) Neural chemical trauma due to

intracellular components released during trauma, haemoglobin irritates neural tissue

c) Ischaemic injury due to entrapment within a bony canal (IAN) with continued bleeding or scar formation.

Thus, it is unlikely that damage to a nerve is due to a simple 'cut'. It is more likely that these nerve injuries incorporate a combination of mechanical injuries (sectioning, stretching, crushing), chemical nerve injuries and ischaemic injuries providing a complex therapeutic challenge.

Type of patient

The type of patient often provides additional difficulty in that they have a complication arising from elective treatment that was supposed to improve their quality of life, not detract from it. These iatrogenic injuries cause understandable distress to both patient and surgeon and the patient's frustration is often compounded by poor management by the surgeon involved (avoidance of contact after the injury has occurred, poor consent procedures, continued reassurance that the injury will resolve over months and years rather than referring the patient to a specialist early on).

Loss of function

Additional distress is caused in that sensory nerve injuries frequently cause pain rather than numbness. As the neuropathic area invariably involves the mouth and face the patients' ability to eat, speak, drink, sleep, kiss, shave or apply makeup is often severely functionally compromised. Due to the chemical and neurophysical changes in the injured sensory nerve, light touch or drafts of air can cause debilitating neuralgic pain (allodynia) and in some instances the patient might experience constant background pain.

Medico-legal considerations

Complaints to the General Dental Council are predominantly related to implants and often involve IAN injury. Neuropathic pain can be very debilitating and when compounded by poor management may result in subsequent litigation. Litigation is often based on inadequate consent procedure, inadequate planning and assessment, causation of avoidable nerve injury and poor management of the patient once the nerve injury has occurred.

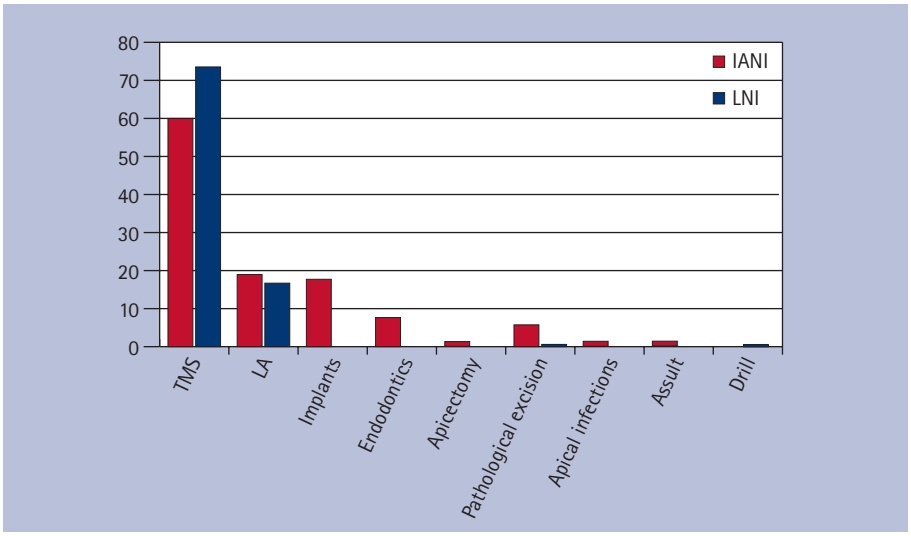

Fig. 1 Frequency of causes of nerve injury

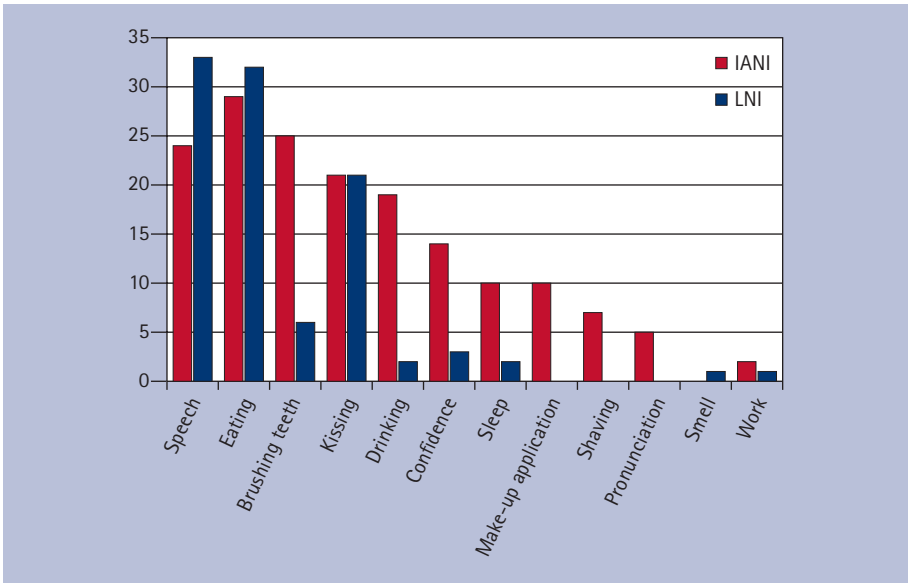

Fig. 2 Relative functional problems related to lingual and ID nerve injuries

Current management of these nerve injuries is often inadequate. Discussion usually centres on surgical correction with little or no attention to medical or counselling intervention. In part the fault rests with how such patients are assessed. There is a deficiency in functional and pain evaluation and a total focus on basic mechano-sensory evaluation which is not necessarily reflective of the patients' difficulties. A recent review of publications pertaining to trigeminal nerve repair highlights that the average time from injury to nerve exploration was 16 months – far too late to prevent central neural changes due to altered peripheral input (neuropathic pain).[13] Most importantly the management of iatrogenic nerve injuries depends upon the mechanism (LA, wisdom teeth, implant, root canal), the duration of the nerve injury and the patient's symptoms.

Lingual nerve

The incidence of lingual nerve injury related to third molar surgery, one day after surgery (excluding the use of lingual flap elevation) varies from 0.4% to 1.5%.[10] The incidence of persistent involvement (still present at six months) varies from 0.5% (with the use of a lingual flap) to a low of 0.0%.[14] The author uses a minimal access buccal approach (see Chapter 4 of the associated BDJ Clinical Guide) for M3Ms as lingual flap access surgery is associated with increased temporary lingual nerve injury (LNI). Causes of lingual nerve injury include dental local anaesthetic injections, intubation, ablative

Fig. 3 High risk M3M based on dental panoramic tomography (DPT)

surgery and submandibular gland surgery. The most common cause of LNIs is third molar surgery, with a reported incidence of 1-20% temporary and 0-2% permanent.[9] Persistence of any peripheral sensory nerve injury depends on the severity of the injury, increased age of the patient, the time elapsed since the injury and the proximity of the injury to the cell body (the more proximal lesions having a poorer prognosis).

Recovery of lingual nerve injury related to lingual access third molar surgery is reported to take place by eight weeks for 85-94% of cases.[15] Thus, lingual nerve injuries injuries may have a better prognosis than inferior alveolar nerve injuries and if the duration of nerve injury is greater than eight weeks then permanency is a risk. However, the true incidence is difficult to gauge without large population surveys. The problem with such injuries is that the nerve will remain intrinsically intact and surgery is therefore not appropriate as one cannot identify the damaged region. The correct treatment of such problems (ie chronic neuropathic pain) is with nonsurgical pain management.[16] Recent settlements of in excess US$1 million in the USA for lingual nerve injury highlights the need for recognition of the associated disability and social repercussions of these injuries.

If complete neural transection or severe nerve injury is suspected, the patient should be informed of the situation and the lingual or inferior alveolar nerves require immediate exploration and or nerve repair by an experienced surgeon. Surgical exploration of damaged nerves usually involves an intraoral approach and decompressions (removal of surrounding scar tissue) with gentle debridement and occasionally excision of a neuroma with good apposition of the nerve endings. Essentially we cannot 'fix' the effects of nerve injury and as with many medical conditions, the apparent normal appearance of a damaged or repaired nerve is not reflected by normal function or indeed a symptom free patient. One recent study has shown that significant improvement in nerve function can be achieved by specialist surgical investigation and repair when undertaken within three months of the injury and therefore recommends early surgical intervention. No improvement of symptoms by three months indicates that a return to normal function is unlikely and that consideration should be given to referral of the patient to a clinician with specialist interest for management of the patient usually using reassurance, education, non-surgical managements (medical pain management, counselling techniques) and rarely surgery.

Inferior alveolar nerve

The incidence of IAN involvement 1-7 days after surgery is around 1-5%. The incidence of persistent IAN involvement (still present after six months) varies from a high of 0.9% to a low of zero.[17] Damage to the inferior alveolar nerve, leading to persistent hypoaesthesia/dysaesthesia in its sensory distribution, is less amenable to surgical repair. The prognosis for spontaneous nerve regeneration after six months is poor.

Causes of inferior alveolar nerve injury include local anaesthetic injections, third molar surgery, implants, endodontics, ablative surgery, trauma and orthognathic surgery.[18] The inferior alveolar nerve (IAN) neuropathy often requires more urgent address compared with lingual nerve injuries. IAN injuries related to implant and root canal work require immediate/ urgent care. If the IAN injury is related to third molar surgery and there are retained tooth roots or local inferior dental canal damage exploration should be undertaken within 2-3 weeks.

Conversely there are rare reports of resolution of implant related IAN neuropathies at over four years[19] but these do not comply with normal reports of peripheral sensory nerve injuries.[14] Some authors recommend referral of injuries after six months[20] but this may be too late for many peripheral sensory nerve injuries to effect a recovery. We now understand that, after three months, permanent central and peripheral changes occur within the nervous system subsequent to injury that are unlikely to respond to surgical intervention.[21]

In a recent study[18] a total of 221 patients with trigeminal nerve injuries collected over three years were consulted at the Dental Institute in King's College Hospital, London. In total, 38 patients with trigeminal neuropathy caused by neurological disease, malignancy, multiple sclerosis, sickle cell disease, known alcoholism, injury caused by non-dental trauma, orthognanthic surgery, diabetes, HIV, post herpetic neuralgia, stroke and patients on chemotherapy were examined. The aetiology and functional status of other 253 injuries to lingual or inferior alveolar nerves were evaluated.

PREVENTION OF NERVE INJURIES

Local anaesthesia related trigeminal nerve injuries

Injuries to inferior alveolar and lingual nerves are caused by local analgesia block injections and have an estimated injury incidence of between 1:26,762 to 1:800,000. Reports of incidences include

1:588,000 for prilocaine and 1:440,000 for articaine IAN blocks, which is 20-21 times greater than for lidocaine injections.[22] Tony Pogrel Professor OMFS UCSF states that *'Perhaps every full-time practitioner will find he or she has one patient during his or her career who has permanent nerve involvement from an inferior alveolar nerve block and there is no means of prevention'.*[8] These injuries are associated with a 34%[23] and 70% incidence of neuropathic pain, which is high when compared with other causes of peripheral nerve injury. More recently we have established that inferior alveolar block local anaesthetic injection related LN or IAN injuries occurs in 1 in 10,000 cases, and is temporary in 60% of cases but persists and become permanent (at three months) in 40% of cases. These injuries can be avoided using infiltration techniques and cannot be 'fixed' with surgery. A 'sit and wait' policy must be undertaken whilst reassuring the patient. Management centres around pain management and reintroducing the patient to dental care.

In the US, liability claims and malpractice suits are inherent risks associated with iatrogenic nerve injury and the reasons for avoiding such injuries are obvious. Iatrogenic nerve lesions may produce symptoms ranging from a minimal irritation to a devastating effect on of quality of life. Few studies, however, describe the range of neurosensory disturbance in terms of signs and symptoms related to impaired nerve conduction and neurogenic affliction and there is a need for better standardisation and documentation of sensory deficits resulting from nerve injuries and their recovery.[24] Due to the incidence of nerve injuries in relation to dental anaesthesia, warning of patients is not considered routine and indeed in the UK these iatrogenic injuries are not considered negligent.

The mechanism of nerve injury due to giving LA is complex. It may be physical (needle, compression due to epineural or perineural haemorrhage) or chemical (haemorrhage or LA contents). Thus the resultant nerve injury may be a combination of peri-, epi- and intra-neural trauma causing subsequent haemorrhage, inflammation and scarring resulting in demyelination (loss of nerve lining).[23] There may be elements of direct mechanical trauma by the needle which has been the focus of most papers (no matter what type of bevel or indeed the method used for LA application!). Some authors infer that the direct technique involving 'hitting' bone before emptying cartridge and withdrawal of needle may cause additional bur deformation at the needle tip thus 'ripping' the nerve tissue.[23] Only 1.3-8.6% of patients get an 'electric shock' type sensation on application of an IAN block and 57% of patients suffer from prolonged neuropathy having not experienced the discomfort on injection, thus this is not a specific sign.

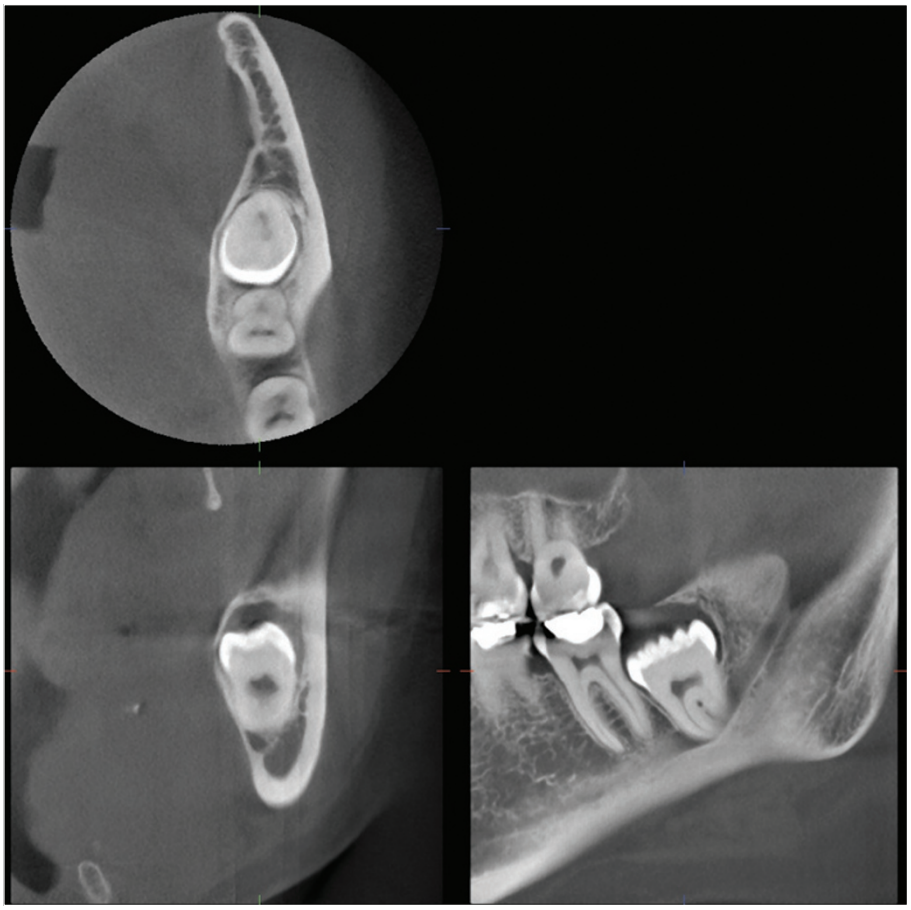

Fig. 4 CBCT illustrating the ID canal corticated and distinct from M3M roots, allowing planning for removal of the tooth

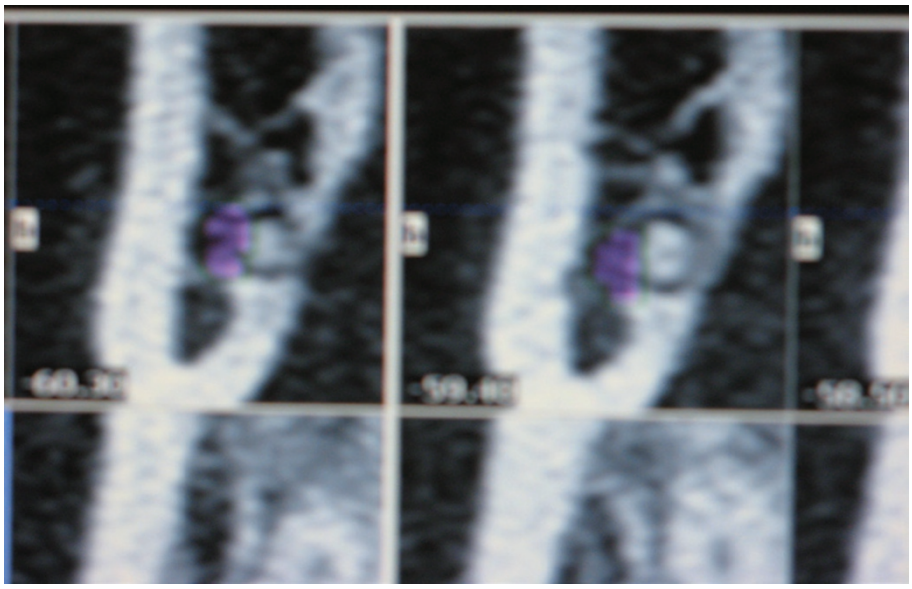

Fig. 5 Cone beam CT scan of M3M root proximal to ID canal with additional loss of lingual plate

Also 81% of IAN block nerve injuries are reported to resolve at two weeks postinjection.[22]

Chemical nerve injury may also be related to specific chemical agents[11] and the LA components (type of agent, agent concentration, buffer, preservative). The variety of local anaesthetics available in the UK include 2% lidocaine, mepivacaine (2% & 3%), prilocaine (3% & 4%) and 4% articaine. It may be the concentration of the local anaesthetic agent that relates to persistent neuropathy where studies have shown that increasing the concentration of local anaesthetic agent significantly affected the survival rate of neurons *in vitro*.[10] Epidemiologically, several reports have highlighted the increased incidence of persistent nerve injury related to IAN blocks with the introduction of high concentration local anaesthetics (prilocaine 4% and articaine 4%).

Articaine is an amide analgesic that was introduced to dentistry in 1998; however, lidocaine (also an amide analgesic) remains the gold standard in the UK. Articaine is the most widely used local anaesthesia in many countries for over 20 years[10] and is said to have a number of advantages. These include low toxicity subsequent to inadvertent intravascular injection which may be due to the rapid breakdown to an inactive metabolite (articainic acid), rapid onset of surgical analgesia (around 2.5 minutes) and, compared with lidocaine, better diffusion through soft and hard tissues.[25]

The conclusion drawn is that articaine is a safe and effective local anaesthetic for use in clinical dentistry but that there are no significant benefits of using articaine 4% compared with lidocaine 2% for IDBs.[24]

There is, however, some concern with regard to using articaine for inferior alveolar and lingual nerve blocks. This persistent altered sensation may be due to the high concentration of the local anaesthetic; however, the technique cannot be excluded as the cause for nerve injury.[24] Another report suggests that it is the type of anaesthetic that dictates the degree of inflammatory reaction to local anaesthetic – lidocaine being the least irritant followed by articaine, mepivicaine and bupivicaine.[26]

The nerve most likely to be damaged during inferior alveolar nerve block injections is the lingual nerve (70%).[22] One suggestion is that this is more likely to be the result of trauma and that over-reporting of such injuries occurs when a new drug formulation, such as 4% articaine, is introduced. There is another explanation why the lingual nerve is more likely to suffer damage. This relates to its structure. At the region of the lingula the lingual nerve is composed of very few fascicles and in some individuals it is uni-fascicular at this point.[22] This is unlike the inferior alveolar nerve, which is multi-fascicular in this region. This structural difference may explain why the lingual nerve is more susceptible than the inferior alveolar nerve to injection damage.

Interestingly, more recently articaine infiltrations are demonstrating similar efficacy to lidocaine IDBs for mandibular dentistry therefore avoiding the necessity of an IDB altogether.[27] It has become routine practice for paedodontic extraction of premolars using articaine infiltrations and many practitioners are routinely undertaking restorative treatment of premolars and molars in adults using LA infiltrations rather than inferior alveolar nerve blocks. This would reduce the incidence of these troublesome untreatable injuries.

Thus prevention of LA nerve injuries is possible and some simple steps may minimise LA related nerve injuries:

- Avoid high concentration LA for ID blocks (use 2% lidocaine as standard)
- Avoid multiple blocks where possible
- Avoid IAN blocks by using high concentration agents (articaine) infiltrations only (see Chapter 2 of the associated BDJ Clinical Guide, Fig. 10).

Intra-operatively all clinicians should document unusual patient reactions occurring during application of local analgesic blocks (such as sharp pain or an electrical shock–like sensation).

Inferior alveolar nerve (IAN) injury related to third molar surgery (TMS)

Prevention of inferior alveolar nerve injuries during third molar surgery[13] may be possible by;

1. Making a clinical decision based on NICE guidelines regarding M3M extractions (ie do not undertake prophylactic surgery unless indicated)
2. Identification of 'high risk teeth' by recognising radiographic risk factors for IAN injury such as:

- Tooth crossing BOTH lamina dura of IAN canal (Fig. 3)
- Juxta-apical area
- Deviation of canal
- Narrowing of roots
- Loss of lamina dura.

If the tooth is in close proximity to the IAN on plain film then cone beam CT scanning may further elucidate the relationship between IAN and tooth roots. If the tooth is vital and patient non-compromised, coronectomy of a tooth which is intimately related to the inferior alveolar canal should be considered (Fig. 4).[27] It should also be considered when the tooth apices are proximal to a missing lingual plate but intimately located on the lingual aspect of the IDC (Fig. 5).

If the tooth is non-vital, or has pathology associated with it, then tooth removal has to take place and, based on the CBCT findings, the roots should be sectioned appropriately to minimise trauma to the adjacent IAN. The patient should be warned of the increased risk of IAN injury (2% permanent and 20% temporary).

DENTAL EXTRACTION OF OTHER TEETH PROXIMAL TO IAN CANAL

It should be noted that any mandibular tooth that is crossing the IAN canal and displays the radiographic signs is associated with increased risk of IAN injury as seen with third molars. This accordingly the patient must be assessed, consented and treated similarly to high risk third molar teeth.

Socket medications

With any mandibular tooth in close proximity to the IAN canal, its extraction can effectively expose the IAN to socket medicaments. If these are irritant to the neural tissue they can lead to chemical neuritis and if the irritant persists there is a risk of development of irreversible neuropathy which is untreatable and often associated with neuropathic pain. There is limited availability of the relative alkalinity or acidity of various dental compounds used for socket medication including; Alvogyl®, Whitehead's Varnish,

chlorhexidine and Surgicel®. However, a previous study highlighted the relative neurotoxicity of Carnoy's Solution, Surgicel, Whitehead's Varnish and bismuth iodoform paraffin paste (BIPP) reporting that Carnoy's is likely to cause permanent nerve damage and that Surgicel, along with Whitehead's varnish, causes temporary sensory disturbances. BIPP was the least neurotoxic.[27] Bone wax has a neutral pH, however, excessive packing or pressure can lead to nerve compression and injury.

Post-operative infection

Inferior alveolar neuritis can present as a symptom of local mandibular infection associated with a periapical abscess on a non-vital tooth close to the IAN canal, or as a sign of osteomyelitis. This may present as persistent or recurrent dry socket that requires repeated socket irrigation and redressing. Suspicions should be aroused after the second or third dressing if accompanied by persistent pain and non-response to antibiotics. More recently, with the advent of bone graft surgery for implants, some patients progress on to osteomyelitis associated with non-vital bone grafts that are not removed quickly enough.

Periapical infection

Once IAN neuropathy develops this may be a sign of spreading bone infection related to a bone sequestrum or tooth fragments remaining *in situ*.

Implant nerve injuries

The quoted incidence of implant-related (IAN) nerve injuries varies from 0–40%.[28] Preoperative planning must include knowledge and assessment of the IAN route through the mandible to prevent nerve damage, with particular reference to the mental nerve region where the nerve often deviates and can be assessed using tomography or CBCT (Fig. 6). IAN injuries often result from direct breaching of the IDC by the preparation drill and implant (Fig. 7). Bone graft harvesting is also associated with IAN injuries. Again, it is crucial that appropriate training, planning and assessment should be undertaken in order to minimise nerve injury. Avoidance of implant nerve injury is sometimes attempted by using

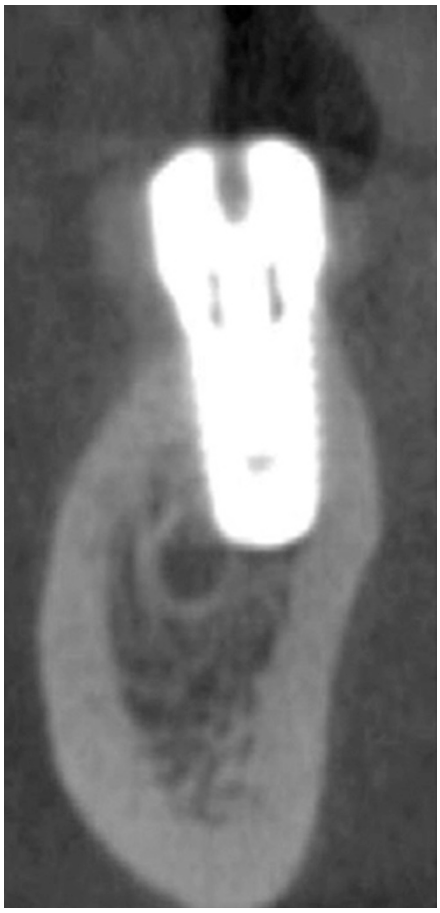

Fig. 6 CBCT illustrating a premolar implant entering mental nerve when apparently above the ID canal on periapical film (courtesy, Andrew Dawood)

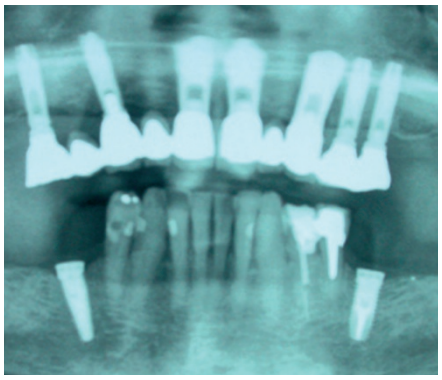

Fig. 7 Implants breaching the mental nerve loop

techniques including IAN lateralisation and posterior alveolar distraction; however, these high risk procedures are more likely to result in IAN defects regardless of the surgeon's experience. Clinicians must remember that 25% of edentulous patients present with a degree of altered IAN function, thus reinforcing the guidelines on the necessity of pre-operative neurosensory evaluation.

Preventing implant related nerve injuries during implant placement includes:

1. Planning

- Be very wary of planning the placement of implants around the mental foramen – ensure you check the nerve position using CBCT yourself.
- Give ample safety zone (minimum 2 mm) above IDC.
- Use CBCT planning and check the position of nerve yourself.

2. Preparation

- Use light buccal LA and stop proceedings if patient gets pain during preparation.
- Never use bur longer than implant, use drill stop system, intra-oral radiographs
- If excessive bleeding occurs during preparation, consider delay of placing implant (2-3 days).
- If there is sudden give – remove implant and check for bleeding, if there is none then ensure the implant is placed at shorter length.

3. Placement

- Delay placement if implant bed is bleeding.
- Don't rely on back up if patient experiences pain on placement – remove it.

4. Post operative

- Always check on your patient post-operatively at four hours.
- If neuropathy occurs – recall patient immediately, confirm whether the neuropathy is in the IAN distribution and, if so, remove implant.
- Place patient on moderately high dose steroids (step down from 20 mg prednisolone over five days).

POSSIBLE MANAGEMENT PROTOCOLS USED BY SPECIALISTS

The management will depend upon the mechanism,the duration of the nerve injury and the patients' symptoms.[28] The patient's ability to cope with the neuropathy and pain, functional problems and their psychological status will drive the need for intervention. Considering that 70% of these patients present with neuropathic pain, most are managed with reassurance and medication. Cognitive behavioural techniques are also being developed for these patients.

Many injuries have limited benefit from surgical intervention and should be managed symptomatically using medication or counselling. Immediate intervention is required for endodontic, implant and third molar related nerve injuries and immediate referral is suggested for all cases.

In summary, this paper highlights several strategies that can be used to assist the practitioner in preventing and managing complications related to oral surgery. Further guidance and information can be found on a website set up by the Trigeminal Foundation. The website www.trigeminalnerve.org.uk provides extensive information and guidance for both patients and clinicians.

1. Contar C M, de Oliveira P, Kanegusuku K, Berticelli R D, Azevedo-Alanis L R, Machado M A. Complications in third molar removal: a retrospective study of 588 patients. *Med Oral Patol Oral Cir Bucal* 2010; **15:** e74–78.
2. Lago-Méndez L, Diniz-Freitas M, Senra- Rivera C, Gude-Sampedro F, Gándara Rey J M, García-García A. Relationships between surgical difficulty and postoperative pain in lower third molar extractions. *J Oral Maxillofac Surg* 2007; **65:** 979–983.
3. Adeyemo W L, Ogunlewe M O, Ladeinde A L, Hassan O O, Taiwo O A. A comparative study of surgical morbidity associated with mandibular third-molar surgery in young and aging populations. *J Contemp Dent Pract* 2010; **11:** E001–E008.
4. Larrazábal C, García B, Peñarrocha M, Peñarrocha M. Influence of oral hygiene and smoking on pain and swelling after surgical extraction of impacted mandibular third molars. *J Oral Maxillofac Surg* 2010; **68:** 43–46.
5. Renton T. Prevention of iatrogenic inferior alveolar nerve injuries in relation to dental procedures. *Dent Update* 2010; **37:** 350–352, 354–356, 358–360, *passim*.
6. Hillerup S. Iatrogenic injury to oral branches of the trigeminal nerve: records of 449 cases. *Clin Oral Investig* 2007; **11:** 133–142. Epub.
7. Blackburn C W. A method of assessment in cases of lingual nerve injury. *Br J Oral and Maxillofac Surg* 1990; **28:** 238–245.
8. Mason D A. Lingual nerve damage following lower third molar surgery. *Int J Oral Maxillofac Surg* 1988; **17:** 290–294.
9. Hillerup S, Stoltze K. Lingual nerve injury in third molar surgery – I. Observations on recovery of sensation with spontaneous healing. *Int J Oral Maxillofac Surg* 2007; **36:** 884–889.
10. Renton T, McGurk M. Valuation of factors predictive of lingual nerve injury in third molar surgery. *Br J Oral Maxillofac Surg* 2001; **39:** 423–428.
11. Flores A J, Lavernia C J, Owens P W. Anatomy and physiology of peripheral nerve injury and repair. *Am J Orthop* 2000; **29:** 167–173.
12. Smith K G, Robinson P P. An experimental study on the recovery of the lingual nerve after injury with or without repair. *Int J Oral Maxillofac Surg* 1995: **24:** 372–379.
13. Zuniga J R, Pate J D, Hegtvedt A K. Regenerative organization of the trigeminal ganglion following mental nerve section and repair in the adult rat. *J Comp Neurol* 1990: **22:** 295: 548–558.
14. Robinson P P, Loescher A R, Smith K G. The effect of surgical technique on lingual nerve damage during lower 3rd molar removal by dental students. *Eur J Dent Educ* 1999; **3:** 52–55.
15. Smith M H, Lung K E. Nerve injuries after dental injection: a review of the literature. *J Can Dent Assoc* 2006; **72:** 559–564.
16. Renton T, Yilmaz Z. Profiling of patients presenting with posttraumatic neuropathy of the trigeminal nerve. *J Orofac Pain*. 2011 Fall; **25:** 333–344.
17. Renton T, Yilmaz Z. Managing iatrogenic trigeminal nerve injury: a case series and review of the literature. *Int J Oral Maxillofac Surg*. 2012 May; **41:** 629–637.
18. Elian N, Mitsias M, Eskow R, Jalbout Z N, Cho S C, Froum S, Tarnow D P. Unexpected return of sensation following 4.5 years of paresthesia: case report. *Implant Dent* 2005; **14:** 364–367.
19. Hegedus F, Diecidue R J. Trigeminal nerve injuries after mandibular implant placement - practical knowledge for clinicians. *Int J Oral Maxillofac Implants* 2006: **21:** 111–116.
20. Ziccardi V B. Trigeminal nerve injuries. *J N J Dent Assoc* 2000: **71:** 41–44.
21. Pogrel M A, Thamby S. Permanent nerve involvement resulting from inferior alveolar nerve blocks. *J Am Dent Assoc* 2000; **131:** 901–907.
22. Haas D A, Lennon D. A 21 year retrospective study of reports of paraesthesia following local anaesthetic administration. *J Can Dent Assoc* 1995; **61:** 319–330.
23. Pogrel M A, Schmidt B L, Sambajon V, Jordan R C. Lingual nerve damage due to inferior alveolar nerve blocks: possible explanation. *J Am Dent Assoc* 2003; **134:** 195–199.
24. Simon M A, Vree T B, Gielen M J, Booij M H. Comparison of the effects and disposition kinetics of Articaine and lidocaine in 20 patients undergoing intravenous regional anaesthesia during day case surgery. *Pharm World Sci* 1998; **20:** 88–92.
25. Hillerup S, Jensen R H, Ersbøll B K. Trigeminal nerve injury associated with injection of local anesthetics: needle lesion or neurotoxicity? *J Am Dent Assoc* 2011; **142:** 531–539.
26. Kanaa M D, Whitworth J M, Corbett I P, Meechan J G. Articaine buccal infiltration enhances the effectiveness of lidocaine inferior alveolar nerve block. *Int Endod J* 2009; **42:** 238–246.
27. Renton T, Hankins M, Sproate C, McGurk M. A randomised controlled clinical trial to compare the incidence of injury to the inferior alveolar nerve as a result of coronectomy and removal of mandibular third molars. *Br J Oral Maxillofac Surg* 2005; **43:** 7–12.
28. Loescher A R, Robinson P P. The effect of surgical medicaments on peripheral nerve function. *Br J Oral Maxillofac Surg* 1998; **36:** 327–332.