

location of the eruption adjacent to the site of exposure imply a causal link, rather than just coincidence.

M. Ziaei, S. A. Aslam, H. Ziaei

London

1. Chapman R S, Cross K W, Fleming D M. The incidence of shingles and its implications for vaccination policy. *Vaccine* 2003; **21**: 2541-2547.
2. Jarade E F, Tabbara K F. Presumed reactivation of herpes zoster ophthalmicus following laser *in situ* keratomileusis. *J Refract Surg* 2002; **18**: 79-80.
3. Fernandes N F, Malliah R, Stitik T P *et al*. Herpes zoster following intra-articular corticosteroid injection. *Acta Dermatovenerol Alp Panonica Adriat* 2009; **18**: 28-30.
4. Clayton T H, Stables G I. Reactivation of ophthalmic herpes zoster following pulsed-dye laser treatment for inflammatory acne vulgaris. *Br J Dermatol* 2005; **152**: 569-570.
5. Wataha J C, Lockwood P E, Lewis J B *et al*. Biological effects of blue light from dental curing units. *Dent Mater* 2004; **20**: 150-157.

DOI: 10.1038/sj.bdj.2011.205

THE SHORT STRAW

Sir, a 3-year-old girl attended our clinic complaining of 'bleeding and painful gums'. The patient's mother reported that the child's gums at the front had looked sore for more than a year, with some kind of build up around a tooth which she was unable to clean by brushing. They had reported the problem a year ago to their previous dentist who suggested that it might be abnormal gum tissue growth that had formed around the tooth. No further advice or intervention occurred.

The mother tried to keep the area as clean as possible but became worried in the last three months when a gap started to appear between the front teeth and the tooth concerned.

Examination revealed adequate oral hygiene apart from moderate gingival inflammation around the LLA. The LLA was grade II mobile, supra-erupted and distobuccally rotated with a yellowish calculus-like covering over the gingival third of the tooth (Fig. 1). The yellow film seemed to be locked in place due to the tight mesial contact with the LRA. There was a build-up of plaque underneath and over the film covering the tooth, suggesting a foreign body.

Radiographically horizontal bone loss was observed around the LLA, but there were no signs of the film covering the tooth on the radiograph (Fig. 2).

A vertical cut was made along the length of the film labially using a scalpel and the object was slid out through the

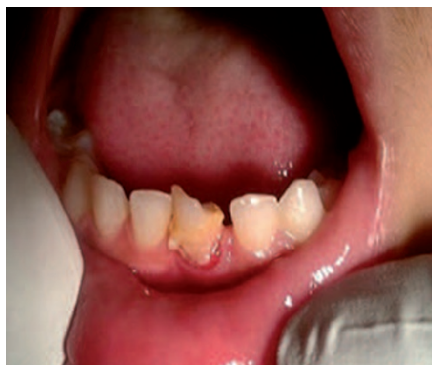

Fig. 1 The affected tooth with its calculus-like covering

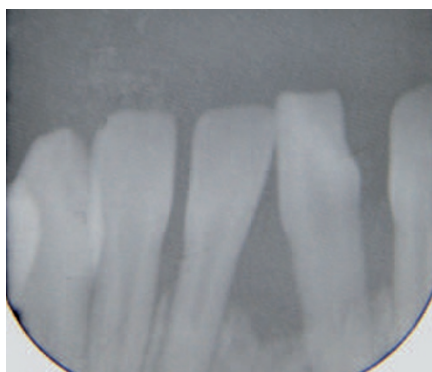


Fig. 2 Radiograph showing horizontal bone loss

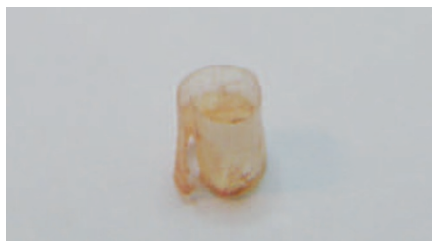

Fig. 3 The foreign body removed from the tooth

contact point. Examination of the object revealed some kind of plastic straw like tubing around 4 mm long and 5 mm in diameter (Fig. 3).

Questioning of the mother and child did not reveal how the foreign object came to be lodged adjacent to the child's tooth.

N. Joshi, I. Al-Hadad, Z. Ullah

By email

DOI: 10.1038/sj.bdj.2011.206

CONSISTENTLY AMAZED

Sir, in the *BDJ* of 8 January a short abstract was provided of a study on the role of anxiety and depression in patients with temporomandibular pains (TMD).¹ It is no surprise that depression plays a role in TMDs as there is also ample evidence in the chronic pain

literature to show that depression is common in these groups of patients and affects outcomes. TMD in many instances is associated with other chronic pain as it appears these patients have an increased vulnerability to pain as shown by case control studies linking TMDs with migraines, fibromyalgia, post traumatic stress and back pain.² Prognostic studies have shown that poor outcomes are to be expected in patients with concomitant psychological factors.² However, in the recent article in the *BDJ* in the series on risk management in clinical practice on TMDs³ there is no mention either of the importance of eliciting co-morbidities and psychological factors in the history, or highlighting the role of psychosocial techniques in management. Gray's and Al-Ani's article³ continues to stress a mechanical approach to a problem which has genetic, environmental, behavioural and psychological risk factors. As Stoher⁴ points out, splints need to be regarded as placebos but patients cling to them as they have few adverse effects and it seems dentists tend to prefer a mechanical rather than a biopsychosocial approach. I am consistently amazed at patients' (who have been wearing splints for months) complete lack of knowledge about the anatomy and functioning of the masticatory apparatus and their relief when this is explained through the use of a model. It is precisely because these broader issues are not taken into account that patients fail to improve and then instigate complaints. Ohrbach has recently extensively reviewed how disability should be assessed in patients with TMDs which is achievable in general practice.⁴

On behalf of facial pain unit

J. M. Zakrzewska

Eastman Dental Hospital

1. Giannakopoulos N N, Keller L, Rammelsberg P, Kronmüller KT, Schmitter M. Anxiety and depression in patients with chronic temporomandibular pain and in controls. *J Dent* 2010; **38**: 369-376.
2. Zakrzewska J M. Facial pain: an update. *Curr Opin Support Palliat Care* 2009; **3**: 125-130.
3. Gray R, Al-Ani Z. Risk management in clinical practice. Part 8. Temporomandibular disorders. *Br Dent J* 2010; **209**: 433-449.
4. Stoher C. Editorial: Temporomandibular joint disorders – the view widens while therapies are constrained. *J Orofac Pain* 2007; **21**: 261.
5. Ohrbach R. Disability assessment in temporomandibular disorders and masticatory system rehabilitation. *J Oral Rehabil* 2010; **37**: 452-480.

DOI: 10.1038/sj.bdj.2011.207