Pulpotomy of human primary molars with MTA and Portland cement: a randomised controlled trial

V. T. Sakai,[1] A. B. S. Moretti,[2] T. M. Oliveira,[3] A. P. C. Fornetti,[4] C. F. Santos,[5] M. A. A. M. Machado[6] and R. C. C. Abdo[7]

VERIFIABLE CPD PAPER

IN BRIEF

- Portland cement (PC) may serve as a substitute for MTA in pulpotomy of primary teeth.
- Besides the similar clinical and radiographic effectiveness of PC and MTA as pulpotomy dressing agents, PC has the advantage of being an inexpensive material.
- Before unlimited clinical use of PC, further studies with large samples and long follow-up assessments are needed.

RESEARCH

Objective This study compared the clinical and radiographic effectiveness of mineral trioxide aggregate (MTA) and Portland cement (PC) as pulp dressing agents in carious primary teeth. **Methodology** Thirty carious primary mandibular molars of children aged 5-9 years old were randomly assigned to MTA or PC groups, and treated by a conventional pulpotomy technique. The teeth were restored with resin modified glass ionomer cement. Clinical and radiographic successes and failures were recorded at 6, 12, 18 and 24-month follow-up. **Results** All pulpotomised teeth were clinically and radiographically successful at all follow-up appointments. Six out of 15 teeth in the PC group and five out of 14 teeth in the MTA group exfoliated throughout the follow-up period. No statistically significant difference regarding dentine bridge formation was found between both groups throughout the follow-up period. As far as pulp canal obliteration is concerned, a statistically significant difference was detected at 6-month follow-up ($p < 0.05$), since the beginning of mineralised material deposition could be radiographically detected in 100% and 57.14% of the teeth treated with PC and MTA, respectively. **Conclusions** PC may serve as an effective and less expensive MTA substitute in primary molar pulpotomies. Further studies and longer follow-up assessments are needed.

INTRODUCTION

Pulpotomy is the most widely accepted clinical procedure for treating primary teeth with inflammation of the coronal pulp caused by caries with no involvement of the radicular pulp.[1–7] Basically, this technique consists of removing the coronal pulp and maintaining the vitality of the radicular pulp. The purpose is to remove the bacterial infection leaving the treated tooth asymptomatic until its exfoliation.[3–7]

Medicaments applied to radicular pulp tissue after pulpotomy have included formocresol,[1,3,4] ferric sulphate,[3,4] calcium hydroxide[4] and mineral trioxide aggregate (MTA).[1,8–14]

[1*,4]Graduate Students, [3]Assistant Professor, [5]Associate Professor, [6,7]Professors, Bauru School of Dentistry, University of São Paulo, Alameda Dr. Octávio Pinheiro Brisolla, 9-75, Bauru, São Paulo 17012-901, Brazil; [2]Adjunct Professor, Federal University of Alfenas, Alfenas 37130-000, Brazil
*Correspondence to: Vivien Thiemy Sakai
Tel: +55 14 32358218; Fax: +55 14 32234679
Email: viviensakai@usp.br

Online article number E5
Refereed Paper – accepted 23 March 2009
DOI: 10.1038/sj.bdj.665

With the development of materials which are not only biocompatible but also bioinductive, the emphasis has shifted from mere preservation to regeneration of the remaining pulp tissue. One such material which has shown immense potential for regeneration is MTA.[15] MTA was developed with the purpose of serving as a root end filling material, but it has also proven to be successful in vital pulp therapy procedures both in animals[16,17] and humans.[2,8,11,12,18] MTA is a biocompatible material and its sealing ability is better than that of amalgam or zinc oxide-eugenol.[2,14,15] Furthermore, its ability to stimulate cytokine release from bone cells has been demonstrated, indicating that it actively promotes hard tissue formation.[2]

Recently, great interest has been focused on the evolution of Portland cement (PC) as an alternative to MTA, and several experimental studies have compared both materials.[16,19–24] PC differs from MTA by the absence of bismuth ions[14,22,23,25,26] and presence of potassium ions.[26] Both materials have comparable antibacterial activity[22] and almost identical properties macroscopically, microscopically and by X-ray diffraction analysis.[23,24,26] It has also been shown that PC and MTA have similar effects on pulp cells when used for direct pulp-capping in rat teeth.[24] Holland *et al.*[16] studied the rat subcutaneous connective tissue response to implanted dentin tubes filled with MTA, PC and calcium hydroxide and found very similar histological results. In addition, both MTA and PC allowed for dentin bridge formation after pulpotomy performed on dogs.[16] Min *et al.*[27] observed that PC allowed the expression of mRNAs of a dentin-specific protein and a noncollagenous protein involved in mineralisation in cultured human pulp cells. De-Deus *et al.*[28] presented a case in which substantial periapical healing occurred with the use of PC to create an apical plug in the root of an immature tooth in human. Finally, Conti *et al.*[29] have recently documented the clinical success of two cases in which PC was applied as a medicament after pulpotomy of mandibular primary molars in children.

Taking into account the low cost and apparently similar properties of PC in comparison with MTA, it is reasonable to consider PC as a possible substitute for MTA in endodontic applications.[17,21,24,27,30,31] Therefore, the purpose of this study was to compare the clinical and

radiographic effectiveness of MTA and PC as pulp dressing agents in human carious primary teeth.

MATERIAL AND METHODS

Participants

The Brazilian Health Ministry and the Ethics Committee of the Bauru School of Dentistry, University of São Paulo approved the protocol of this study (#34/2005 and #134/2004, respectively). During the pretreatment screening period, the parents or guardians of the children received detailed information concerning the nature and the procedures involved in the study and signed informed consent forms.

The criteria for selection of the teeth to be included in the study were: children between the ages of 5 and 9 years old, with one carious mandibular primary molar tooth with vital pulp and absence of history of pain, thus requiring a pulpotomy therapy; no clinical or radiographic evidence of pulp degeneration, such as excessive bleeding from the root canal, internal root resorption and furcal bone destruction; no physiological root resorption of more than one-third, as observed in periapical radiographs; and the possibility of proper restoration of the teeth. Exclusion criteria included the presence of systemic pathology and any history of allergic reaction to latex, local anesthetics or to the constituents of the tested pulp dressing agents.

Technique

The suitability of the teeth for pulpotomy was assessed by two of the authors, who also performed the procedures. The authors were previously involved in several pulpotomy studies and used a standardised technique.

The primary mandibular molars were randomly assigned to MTA or PC groups by the toss of a coin. In both groups, after local anaesthesia with 2% mepivacaine with 1:100,000 adrenaline and rubber dam isolation, caries removal was accomplished using a handpiece with a round bur. The opening of the pulp chambers was conducted with round carbide bur. Full coronal pulp tissues were removed manually with an excavator, followed by irrigation with saline solution in order to clear the debris. The wound surface was continuously irrigated with saline solution until bleeding ceased.

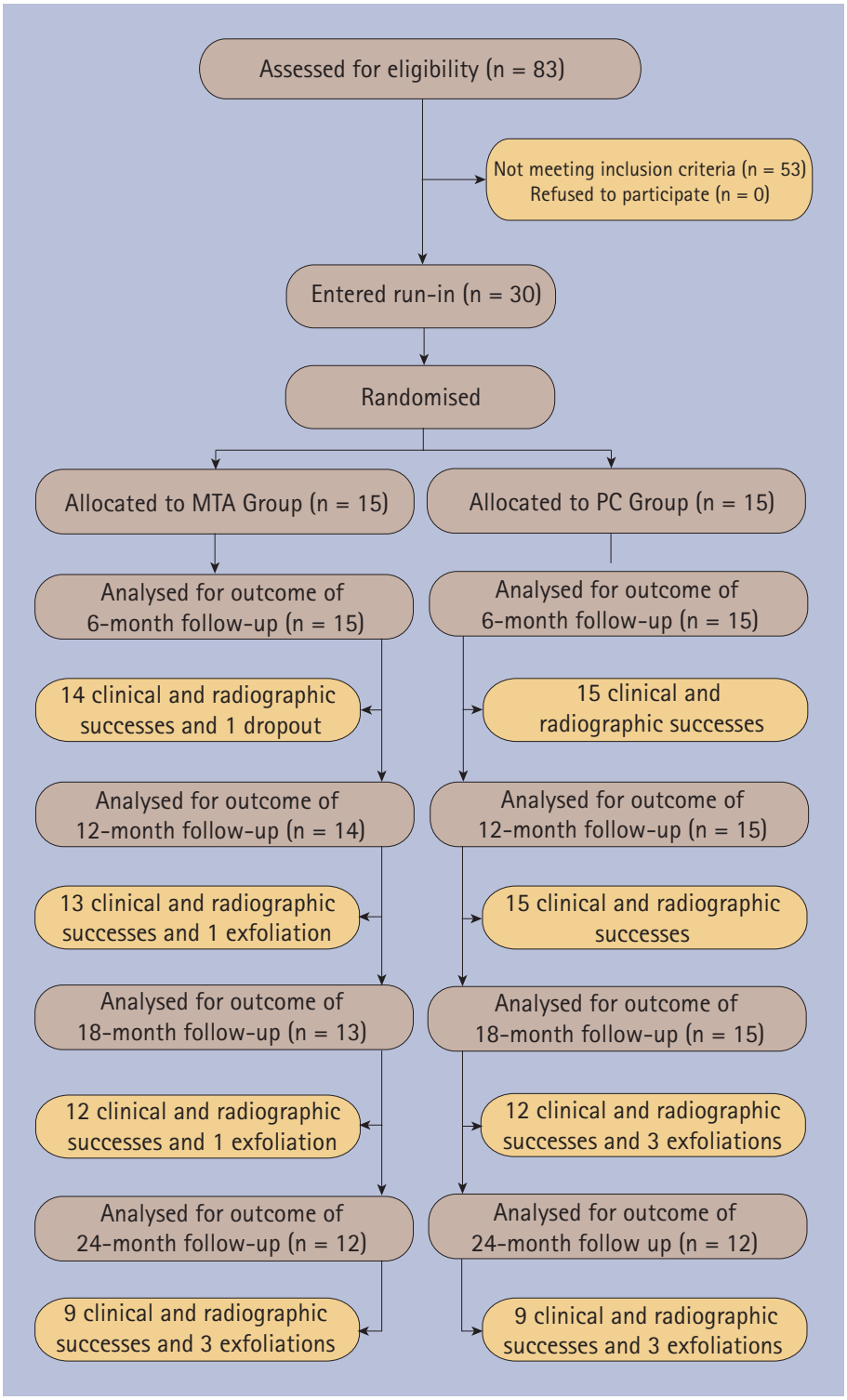

Fig. 1 Flow of patients and pulpotomised teeth up to 24 months

In the MTA group, a paste was obtained by mixing 0.16 g grey MTA powder (Ângelus, Londrina, PR, Brazil) with sterile saline to produce a homogeneous paste. The paste was placed in the pulp chamber. In the other group, 0.16 g of PC (Votorantim-Cimentos, São Paulo, SP, Brazil) was previously sterilised with ethylene oxide and then mixed with sterile water. PC was mixed to a consistency similar to that of MTA, and applied into the pulp chambers with a spatula. In both groups, a layer of reinforced zinc oxide-eugenol (IRM®, Dentsply, Petrópolis, PR, Brazil) was placed before restoration with resin modified glass ionomer cement (Vitremer®, 3M ESPE, São Paulo, SP, Brazil). Immediate postoperative periapical radiographs were taken.

Follow-up

At follow-up appointments, clinical success was confirmed in teeth presenting with no spontaneous pain, mobility, swelling, fistula, or smell. Radiographic success was considered if internal root resorption and furcation radiolucency were absent. Dentine bridge formation was also considered a radiographic success, and intracanal calcifications were not considered as failures.

Periodic follow-up examinations were carried out 6, 12, 18 and 24 months after the end of the treatment. Each check-up involved a clinical and periapical radiographic examination of the pulpotomised teeth, which was performed by two blinded and previously calibrated investigators (kappa values of 0.83 and 0.96 for inter- and intra-examiner reproducibility, respectively). When disagreement arose, a consensus approach was adopted.

Data were submitted to statistical analysis using the Chi-square test followed by Fisher's exact test. Statistical significance was established at 5%.

RESULTS

Thirty primary molars in 30 children (11 girls and 19 boys, with mean age of 6 years and 9 months) were randomly allocated to the PC (15 teeth) or MTA (15 teeth) groups. One tooth in the MTA group was lost to follow-up.

In both groups, 100% of the available teeth were clinically and radiographically successful during all the follow-up appointments. No teeth showed signs of mobility, sinus tract, swelling, or inflammation of the surrounding gingival tissue, and none showed radiographs suggestive of internal root resorption and furcation radiolucency. Six out of 15 teeth in the PC group and five out of 14 teeth in the MTA group exfoliated throughout the follow-up period (Fig. 1).

The formation of dentine bridges could be radiographically observed in two teeth treated with PC during all the follow-up appointments. In the MTA group, a dentine bridge was detected in one tooth during the 6-month follow-up and in four teeth in the subsequent follow-up appointments. However, no statistically significant difference regarding this parameter was found between both groups throughout the follow-up period.

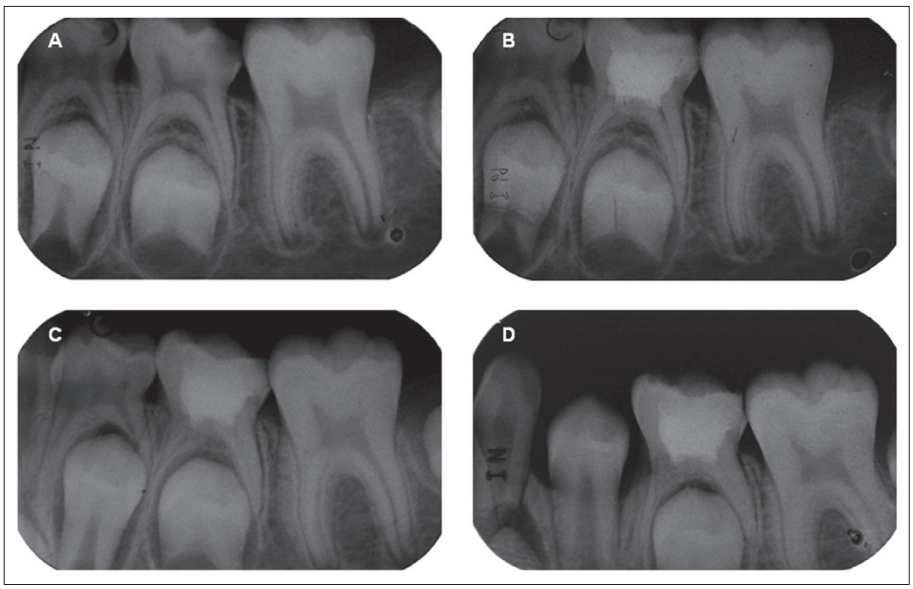

Fig. 2 Pulpotomy treatment performed in a mandibular left primary second molar with the use of MTA in a 9-year-old male patient. (A) Preoperative periapical radiograph of the tooth showing an extensive caries lesion, more than two thirds of root length, and no signs of periapical lesion. (B) Immediate postoperative periapical radiograph of the pulpotomised tooth with MTA. (C) 12-month follow-up periapical radiograph suggesting the initial obliteration of the roots and absence of periapical lesion in the pulpotomised molar. (D) 24-month follow-up periapical radiograph suggesting the obliteration of the roots and their progressive resorption caused by the eruption of the permanent successor

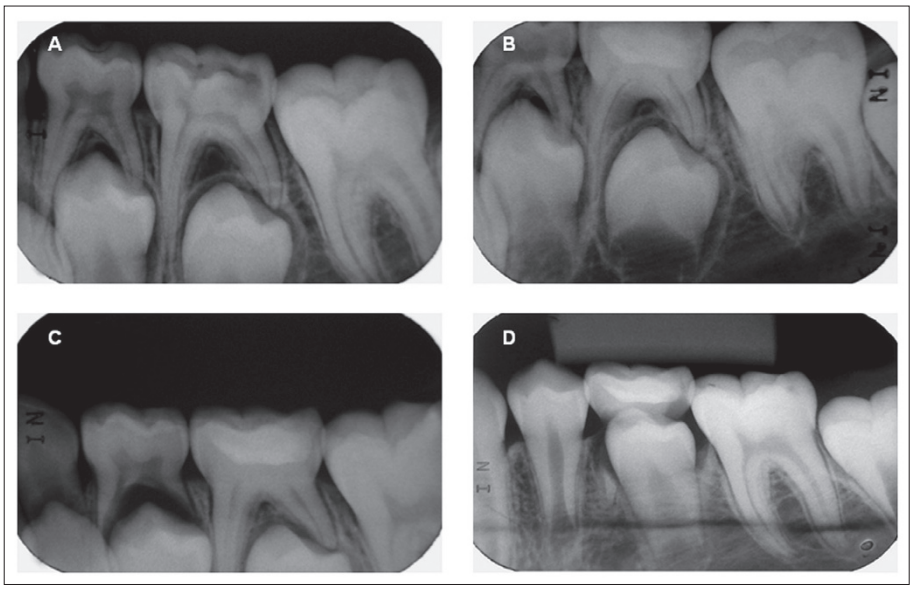

Fig. 3 Pulpotomy treatment performed in a mandibular left primary second molar with the use of PC in an 8-year-old female patient. (A) Preoperative periapical radiograph of the tooth showing an extensive caries lesion, more than two thirds of root length, and no signs of periapical lesion. (B) Immediate postoperative periapical radiograph of the pulpotomised tooth with PC. (C) 12-month follow-up periapical radiograph suggesting the absence of periapical lesion in the pulpotomised molar and the progressive resorption of the roots, mainly the distal one, due to the eruption of the permanent successor. (D) 24-month follow-up periapical radiograph showing the complete resorption of the roots of the pulpotomised tooth caused by eruption of the permanent successor

Regarding pulp canal obliteration, a statistically significant difference was found between both groups at 6-month follow-up ($p < 0.05$). In the PC group, the beginning of mineralised material deposition could be radiographically detected in all of the available teeth 6 months after the placement of the dressing agent over the remaining pulp tissue. In the MTA group, eight teeth (57.14%) presented mineralized material deposition obliterating the root canal at 6-month follow-up and 11 teeth (78.6%) at 12-month follow-up.

Additionally, a greyish colour change of the crowns was observed in all pulpotomised teeth in both groups, although this feature was slighter in the PC group. Radiographs of clinical cases in which MTA and PC were used as pulp capping agents are shown in Figures 2 and 3, respectively.

DISCUSSION

Several studies have reported excellent results when using MTA over pulp.[1,6,8,10–12,17] The factor responsible for the beneficial effects in MTA is also found in PC,[31] although it is important to emphasize that they are not identical materials.[13] This has resulted in a significant body of research showing that PC appears to be a useful substitute for MTA.[17,21,24,27,31,32] However, only four studies reported the use of PC in conservative pulp therapy with considerable success in rats[24] and dogs.[16,17,23] To the best of our knowledge, this is the first randomised controlled clinical trial assessing the effectiveness of PC in human primary teeth and comparing this regenerative dressing agent with MTA.

Danesh *et al.*[20] showed that MTA displayed superior material properties to PC, which was significantly more soluble, reached lower microhardness values and was less radiopaque. The lack of radiopacity in pure PC is due to the absence of bismuth, a chemically inert radiopacifier, in its composition.[25] However, this feature compromises neither the execution of pulpotomy procedures with PC nor their follow-up assessments, which is not the case when this material is used for root-end fillings. In these situations, a radiopacifier is necessary to enable the peri- and postoperative assessment of the cement placement reaching the root apex.

A major concern regarding the use of water-based cements is the amount of leachable arsenic present in the material, which arises from impurities in the limestone used in the manufacture of PC.[23] Duarte *et al.*[30] showed that the concentration of arsenic is low in PC and closely similar to that present in MTA, demonstrating no contraindication due to arsenic for the use of PC in clinical practice. Although one could consider the use of PC in humans a risk, it is noteworthy that its use was assessed by the Brazilian Health Ministry and further approved by the Ethics Committee of the Bauru School of Dentistry, University of São Paulo, thus validating the execution of the present clinical study in human primary teeth.

The concept of dentine bridging is controversial because the presence of a bridge can be viewed as either a healing response or a pulp reaction to irritation.[15,33] Waterhouse *et al.*[34] suggested that reactionary dentine formation is a sign or consequence of attempted repair processes within the pulp tissue. Nevertheless, after an initial attempt by the pulp tissue to 'wall-off' the insult, the protective or reactive process may fail, leading to clinical failure. In the present study, none of the teeth with dentine bridges had other concomitant radiographic or clinical signs of failure, and therefore the presence of dentine bridges was categorised as a radiographic success.

Another radiographic finding in both groups that was not regarded as failure was pulp canal obliteration. The active deposition of tertiary reparative dentine and consequently the narrowing of the canals is the result of extensive activity of odontoblast-like cells, thus indicating the presence of pulp vitality.[6,35] However, it is worth mentioning that histological analysis would be an important approach to assess pulp tissue condition of all pulpotomised teeth as well as to determine the nature and quality of the dentine bridges and the calcified tissues that obliterated the pulp canals. Thus, the histological failure and success rates could also be determined.

Healing of the dental pulp is not exclusively dependent on the supposed stimulatory effect of a particular type of medicament, but is directly related to the capacity of both the dressing and definitive restorative material to provide a biological seal against immediate and long-term microleakage along the entire restoration interface.[5,15] One such material that provides optimal coronal seal is a stainless steel crown.[1,2,5,10–12] However, in this study, all pulpotomised teeth were restored with resin modified glass ionomer cement (RMGIC), which has good sealing properties, is easy to handle[36] and has adhesion properties that impart adequate retention even if mechanical undercuts are absent. Coverage of exposed dentine and sharp margins with RMGIC to provide patient comfort is possible with minimal chair time.[12,36] Therefore, the impaction of the restorative material was not a discriminating factor between the two groups. Additionally, it is important that the absence of evidence for RMGIC should not be misinterpreted as evidence for its lack of efficacy.

Taken together, the present data support the suggestion that PC may serve as an effective and less expensive MTA substitute in primary molar pulpotomies. Although our results are very encouraging, further studies with a larger number of samples and longer follow-up assessments are needed in order to determine the suitability of PC before unlimited clinical use can be recommended.

1. Agamy H A, Bakry N S, Mounir M M, Avery D R. Comparison of mineral trioxide aggregate and formocresol as pulp-capping agents in pulpotomized primary teeth. *Pediatr Dent* 2004; **26:** 302–309.
2. Eidelman E, Holan G, Fuks A B. Mineral trioxide aggregate vs. formocresol in pulpotomized primary molars: a preliminary report. *Pediatr Dent* 2001; **23:** 15–18.
3. Fuks A B. Current concepts in vital primary pulp therapy. *Eur J Paediatr Dent* 2002; **3:** 115–120.
4. Huth K C, Paschos E, Hajek-Al-Khatar N *et al.* Effectiveness of 4 pulpotomy techniques – randomized controlled trial. *J Dent Res* 2005; **84:** 1144–1148.
5. Jabbarifar S E, Khademi A A, Ghasemi D. Success rate of formocresol pulpotomy *versus* mineral trioxide aggregate in human primary molar tooth. *J Res Med Sci* 2004; **6:** 55–58.
6. Maroto M, Barberia E, Planells P, Garcia Godoy F. Dentin bridge formation after mineral trioxide aggregate (MTA) pulpotomies in primary teeth. *Am J Dent* 2005; **18:** 151–154.
7. Ranly D, García-Godoy F. Current and potential pulp therapies for primary and young permanent teeth. *J Dent* 2000; **28:** 153–161.
8. Barrieshi-Nusair K M, Qudeimat M A. A prospective clinical study of mineral trioxide aggregate for partial pulpotomy in cariously exposed permanent teeth. *J Endod* 2006; **32:** 731–735.
9. Camilleri J, Pitt Ford T R. Mineral trioxide aggregate: a review of the constituents and biological properties of the material. *Int Endod J* 2006; **39:** 747–754.
10. Farsi N, Alamoudi N, Balto K, Mushayt A. Success of mineral trioxide aggregate in pulpotomized primary molars. *J Clin Pediatr Dent 2005;* **29:** 307–312.
11. Moretti A B S, Oliveira T M, Sakai V T, Santos C F, Machado M A A M, Abdo R C C. Mineral trioxide aggregate pulpotomy of a primary second molar in a patient with agenesis of the permanent successor. *Int Endod J* 2007; **40:** 738–745.
12. Moretti A B, Sakai V T, Oliveira T M *et al.* Effectiveness of mineral trioxide aggregate, calcium hydroxide and formocresol for pulpotomies in primary teeth. *Int Endod J* 2008; **41:** 547–555.
13. Roberts H W, Toth J M, Berzins C W, Charlton D G. Mineral trioxide aggregate material use in endodontic treatment: a review of literature. *Dent Mater* 2008; **24:** 149–164.
14. Torabinejad M, Chivian N. Clinical applications of mineral trioxide aggregate. *J Endod* 1999; **25:** 197–205.
15. Chacko V, Kukirose S. Human pulpal response to mineral trioxide aggregate (MTA): a histologic study. *J Clin Pediatr Dent* 2006; **30:** 203–210.
16. Holland R, de Souza V, Murata S S *et al.* Healing process of dog dental pulp after pulpotomy and pulp covering with mineral trioxide aggregate or Portland cement. *Braz Dent J* 2001; **12:** 109–113.

17. Menezes R, Bramante C M, Letra A, Carvalho V G G, Garcia R B. Histologic evaluation of pulpotomies in dog using two types of mineral trioxide aggregate and white Portland cements as wound dressings. *Oral Surg Oral Med Oral Pathol Oral Radiol Endod* 2004; **98:** 376–379.
18. Aeinehchi M, Dadvand S, Fayazi S, Bayat-Movahed S. Randomized controlled trial of mineral trioxide aggregate and formocresol for pulpotomy in primary molar teeth. *Int Endod J* 2007; **40:** 261–267.
19. Bortoluzzi E A, Broon N J, Bramante C M, Garcia R B, Moraes I G, Bernardineli N. Sealing ability of MTA and radiopaque Portland cement with or without calcium chloride for root-end filling. *J Endod* 2006; **32:** 897–900.
20. Danesh G, Dammaschke T, Gerth H U V, Zndbiglari T, Schafer E. A comparative study of selected properties of ProRoot mineral trioxide aggregate and two Portland cements. *Int Endod J* 2006; **39:** 213–219.
21. De-Deus G, Petruccelli V, Gurgel-Filho E, Coutinho-Filho T. MTA *versus* Portland cement as repair material for furcal perforations: a laboratory study using polymicrobial leakage model. *Int Endod J* 2006; **39:** 293–298.
22. Estrela C, Bammann L L, Estrela C R A, Silva R S, Pécora J D. Antimicrobial and chemical study of MTA, Portland cement, calcium hydroxide paste, Sealapex and Dycal. *Braz Dent J* 2000; **11:** 19–27.
23. Islam I, Chng H K, Yap A U J. Comparison of the physical and mechanical properties of MTA and Portland cement. *J Endod* 2006; **32:** 193–197.
24. Wucherpfenning A L, Green D B. Mineral trioxide vs Portland cement: two biocompatible filling materials. *J Endod* 1999; **25:** 308.
25. Coomaraswamy K S, Lumley P J, Hofmann M P. Effect of bismuth oxide radioopacifier content on the material properties of an endodontic Portland cement-based (MTA-like) system. *J Endod* 2007; **33:** 295–298.
26. Song J S, Mante F K, Romanow W J, Kim S. Chemical analysis of powder and set forms of Portland cement, gray ProRoot MTA, white ProRoot MTA, and gray MTA-Angelus. *Oral Surg Oral Med Oral Pathol Oral Radiol Endod* 2006; **102:** 809–815.
27. Min K S, Kim H I, Park H J, Pi S H, Hong C U, Kim E C. Human pulp cells response to Portland cement *in vitro*. *J Endod* 2007; **33:** 163–166.
28. De-Deus G, Coutinho Filho T. The use of white Portland cement as an apical plug in a tooth with a necrotic pulp and wide-open apex: a case report. *Int Endod J* 2007; **40:** 653–660.
29. Conti T R, Sakai V T, Fornetti A P *et al.* Pulpotomies with portland cement in human primary molars. *J Appl Oral Sci* 2009; **17:** 66–69.
30. Duarte M A H, Demarchi A C C O, Yamashita J C, Kuga M C, Fraga S C. Arsenic release provided by MTA and Portland cement. *Oral Surg Oral Med Oral Pathol Oral Radiol Endod* 2005; **99:** 648–650.
31. Saidon J, He J, Zhu Q, Safavi K, Spangberg L. Cell and tissue reactions to mineral trioxide aggregate and Portland cement. *Oral Surg Oral Med Oral Pathol Oral Radiol Endod* 2003; **95:** 483–489.
32. Spangberg L S W. Response to letter to the editor by Carolyn M. Prismus, PhD. *Oral Surg Oral Med Oral Pathol Oral Radiol Endod* 2006; **101:** 418.
33. Nair P N, Duncan H F, Pitt Ford T R, Luder H U. Histological, ultrastructural and quantitative investigations on the response of healthy human pulps to experimental capping with mineral trioxide aggregate: a randomized controlled trial. *Int Endod J* 2008; **41:** 128–150.
34. Waterhouse P J, Nunn J H, Whitworth J M, Soames J V. Primary molar pulp therapy – histological evaluation of failure. *Int J Paediatr Dent* 2000; **10:** 313–321.
35. Holan G, Eidelman E, Fuks A B. Long-term evaluation of pulpotomy in primary molars using mineral trioxide aggregate or formocresol. *Pediatr Dent* 2005; **27:** 129–136.
36. Hewlett E R, Mount G J. Glass ionomers in contemporary restorative dentistry – a clinical update. *J Calif Dent Assoc* 2003; **31:** 483–492.