Immediate implant supported bridgework simultaneous with jaw reconstruction for a patient with mandibular osteosarcoma

I. L. Hutchison,[1] A. Dawood[2] and S. Tanner[3]

IN BRIEF

- Describes the benefits of using CT data to generate a Rapid Prototype Anatomical Model of the mandible.
- Shows how the same model can be used to plan simultaneous dental implant placement and the provision of immediately loaded implant supported bridgework.
- Illustrates the physical benefits in terms of immediate restoration of speaking ability and masticatory efficiency and appearance.

PRACTICE

A patient with mandibular osteosarcoma underwent full immediate dental rehabilitation including insertion of dental implants and immediately loaded implant bridgework in the same operation as surgical resection of the tumour and scapular composite free flap reconstruction. Planning and pre-production of the titanium reconstruction plate, drill guides and bridgework using a 3D stereolithographic model of the patient's jaw is described. The advantage of this immediate full rehabilitation of an oncology patient is compared with the potential disadvantages.

INTRODUCTION

Seven percent of osteosarcomata affect the jaws.[1] The treatment of osteosarcoma of the jaws in the UK follows a standard protocol of chemotherapy with Doxorubicin, Cisplatin and Methotrexate followed by surgical resection. Radiotherapy is usually used as an adjunctive treatment following surgery. With this treatment protocol five-year disease-free control rates reach 70%.

Over the past two decades the quality of life for post surgical head and neck tumour patients has improved dramatically with the advent of immediate microvascular free flap reconstruction of the defect left by tumour resection. This is now established practice. Three bones are commonly used for mandibular reconstruction: fibula; iliac crest; or scapula.[2-4] Each of these have diverse attributes relating to bone dimensions, proportion of soft cancellous to hard cortical bone,[5,6] the nature and amount of available soft tissue, and the length of the vascular pedicle and the internal diameter of the vein and artery (Table 1).

Many papers over the past decade have also described taking dental rehabilitation a stage further by the immediate placement of osseointegrated titanium implants into these reconstructed bones at the time of surgical resection of the primary tumour.[7-10]

However, a literature review has not revealed any reports where patients have received immediate full dental arch restoration with bridges in addition to jaw reconstruction and implant placement at the time of tumour resection.

CASE REPORT

We report on a 69-year-old retired businessman who presented to his dentist with a three-month history of pain in the lower left third molar region, followed by swelling of the gingivae in this area. Although the swelling subsided spontaneously, it recurred within a few weeks and grew in size inexorably, causing problems with the patient wearing his lower partial denture.

Radiographs and a reformatted CT scan of the jaw at this stage showed irregular radiolucency on the left side of the mandibular ramus (Figs 1a-1b). The patient was referred for a biopsy, which was initially reported as ossifying fibroma. The

Table 1 Flap properties

Properties of flap	Type of flap		
	Fibula flap	Iliac crest flap	Scapula flap
Bone length	20 cm	14 cm	10 cm
Bone height	17 mm	4 cm	3 cm
Bone thickness	17 mm	18 mm	10 mm
Bone nature	Cortical with small cancellous core	Large amount of cancellous	Mainly cancellous
Pedicle length to bone	Up to 12 cm	6 cm	May be only 5 cm
Skin reliability	Satisfactory	Less reliable	Excellent
Skin thickness	Thin	Thick	Thickest
Skin length	Up to 12 cm	Up to 12 cm	Up to 20 cm
Skin width with primary closure	Narrow – 3 cm	Depends on obesity – can be up to 7 cm	Up to 8 cm

[1*]Professor, Oral and Maxillofacial Surgery, St Bartholomew's Hospital and The Royal London Hospitals; [2]Specialist in Periodontics and Prosthodontics, Dawood & Tanner Dental Practice / Honorary Clinical Fellow, St Bartholomew's & The Royal London Hospitals; [3]Specialist in Prosthodontics, Dawood & Tanner Dental Practice
*Correspondence to: Professor Iain Hutchison, Department of Oral and Maxillofacial Surgery, St Bartholomew's Hospital, London, EC1A 7BE
Email: hutchken@nildram.co.uk

Refereed Paper
Accepted 7 November 2008
DOI: 10.1038/sj.bdj.2009.57

lump continued to grow and the histology was therefore reviewed, leading to a diagnosis of osteosarcoma being made. After a full staging assessment with CT scans of the chest and abdomen he underwent four cycles of chemotherapy with Doxorubicin and Cisplatin over a three-month period.

Pre-surgical planning

The patient, who was extremely concerned by the prospect of losing his teeth and the means to support his existing denture, was referred for a prosthodontic opinion.

Whilst the patient's chemotherapy continued, a three-dimensional, anatomically accurate rapid prototype anatomical model (RPAM) of the patient's jaws and teeth was produced by Cavendish Imaging™, using CT scan data. This 3D model was used by the surgeon to pre-form the titanium reconstruction plate (AO Synthes Unilock™) (Fig. 2) to the absolute form of the untreated mandible. Drill holes were made through the titanium plate holes into the underlying model in the part of the jaw that was to be retained after resection of the osteosarcoma. The prosthodontist then made drill guides to facilitate accurate placement of the plate in the residual native mandible following surgical resection of the osteosarcoma. The prosthodontist then suggested that the same model could be used to pre-plan implant placement in the residual native mandible left after tumour resection, and offered to immediately load these implants with a pre-prepared bridge, which would be cantilevered over the left sided mandibular reconstruction.

Articulated models and a tooth 'try-in' were generated (Fig. 3). A silicon index was formed on the RPAM, and used to 'pick-up' the try-in in the mouth. This enabled the tooth try-in to be located back onto the RPAM with some of the dental units still in place, enabling the RPAM to be articulated against the opposing dentition. Selected teeth were removed from the jaw model, which was sectioned according to the surgeon's planned resection. Implant replicas were 'ideally' located in the jaw model and related to the tooth set-up.

A rigidly constraining drill guide was produced using prefabricated stainless steel sleeves, for use with specialised surgical instrumentation (NobelGuide System™, NobelBiocare, Sweden). This drill guide was supported by dental units that would temporarily have been left in place specifically for the purpose, and the adjacent bony ridge (Figs 4-5). Prosthetic abutments (MultiUnit Abutments™, NobelBiocare) were fitted to the fixture replicas and connected to temporary titanium cylinders, which were related to the set-up. This was then flasked to produce a simple all-acrylic temporary bridge.

Fig. 1a Panoramic radiograph showed irregular radiolucency on the left side of the mandibular ramus

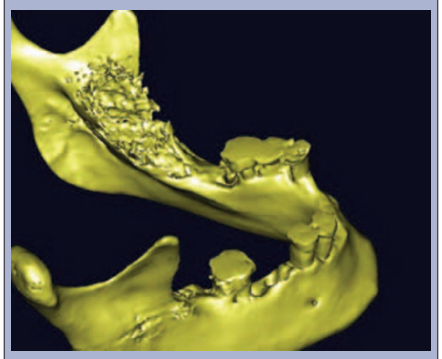

Fig. 1b 3D reconstruction of CT Scan Data showing destructive lesion and ridge morphology

Fig. 2 RPAM with the pre-formed titanium reconstruction plate in place

Fig. 3 An articulated model and denture tooth try-in of the was produced to plan implant position and model the resin temporary bridge

Fig. 4 Implant replicas were ideally located in the RPAM and related to the opposing dentition. 'Guided Cylinders' were used to position stainless steel guiding sleeves

Fig. 5 The sleeves were picked up in a cold-cured resin material to form a rigidly constraining drill guide

Surgery

Following completion of the chemotherapy, the patient underwent a 12-hour operation. This involved left hemi-mandibulectomy with clearance of the left infratemporal fossa, left posterior maxillectomy and removal of the pterygoid plates to the base of the skull. Significant portions of the left masseter and pterygoid muscles were included in the resection specimen (Fig. 6).

The pre-formed titanium bone fixation plate was screwed into its predetermined position on the mandible using the prepared drill guides.

Whilst the reconstructive flap was raised, the implants and bridgework were simultaneously installed: some of the teeth in the residual mandible were removed, leaving others to support the drill guide. A limited gingival flap was raised to allow the drill guide to be positioned on the ridge and teeth.

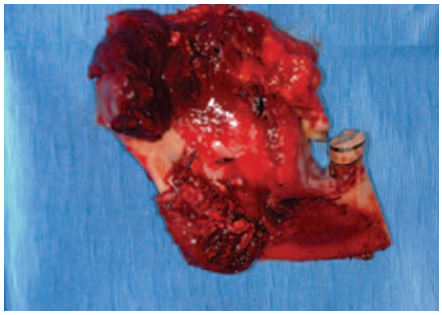

Fig. 6 Resection specimen includes left hemi-mandible, clearance of the left infratemporal fossa, left posterior maxilla and pterygoid plates including significant portions of the left masseter and pterygoid muscles

Fig. 7 The prefabricated resin temporary bridge in place

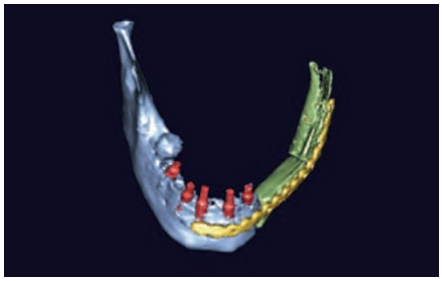

Fig. 8 A postoperative 3D reconstruction of the neo mandible and implants

Fig. 9 The patient 18 days postoperatively

Fig. 10 The intra oral state six months postoperatively

Fig. 11 Six months postoperatively with a resin veneered milled titanium bridge in place

Special surgical drills and drill-guides (NobelGuide instrumentation, Nobel-Biocare AB Sweden), which fitted precisely into the guide, and were rigidly constrained by the titanium sleeves embedded in it were used to prepare the fixture sites. The fixtures themselves were inserted using 'guided' fixture mounts, which constrained the final position of the fixtures in all dimensions. Once the implants were finally seated in place, the guide-supporting teeth were removed. The abutments were connected to the implants and the flap closed. The prefabricated bridge was then screwed into place on the abutments (Fig. 7).

The mandibular defect was reconstructed with a microvascularly reperfused left scapular osteocutaneous flap (9 cm bone length and the skin paddle measuring 7 x 12 cm) (Fig. 8).

The patient made a swift recovery and was immediately able to function well with his temporary bridgework in place (Fig. 9). Six months postoperatively a resin veneered milled titanium bridge was provided (Figs 10-11).

The patient is now 24 months post surgery and 30 months post commencement of treatment. There is no sign of recurrent or metastatic osteosarcoma and none of his implants have failed. He is able to play full regular games of golf and has a healthy social life. He is currently pain free and very satisfied with the look and feel of his teeth and mouth.

DISCUSSION

This report describes collaboration between a prosthodontist with a special interest in imaging and 3D model reconstruction and an oral and maxillofacial surgeon. It has resulted in what we believe, from a literature review, to be the first case where the patient has had full dental and facial rehabilitation at the time of tumour resection and free flap reconstruction. This collaboration illustrates the immense advantages of incorporating advances in computer technology, implant dentistry and prosthodontic techniques into oral and maxillofacial surgical practice.

When the continuity of the mandibular arch is lost in tumour resection, the remaining parts move out of normal alignment in response to unopposed muscle forces. This has previously made anatomically accurate perioperative reconstruction difficult and time-consuming as the surgeon 'eyeballs' the defect and estimates the length and placement of the reconstructed bone. Therefore, the greater predictability of this pre-planning using the 3D model not only improved the accuracy of the reconstruction but also resulted in the saving of at least one hour of operating time.

Previously, oncology patients would have their dental rehabilitation delayed for several months or years. This was to allow completion of post surgical radiotherapy and healing of the oral tissue. Then, the oral cavity lining at the reconstruction site usually needed to be prepared for implant placement. Following this there was also anxiety about the ability of the implants to successfully integrate in the irradiated tissue. This anxiety meant that a significant delay also occurred after implant placement before the superstructure manufacture to ensure that all implants had osseointegrated. Arguments against immediate implant placement have also been advanced in oncology cases where there is a doubt about resection margins and where there is a possibility that drilling bone adjacent to the tumour might produce tumour seeding distant from the original tumour site. Also, if the tumour recurs locally it will be necessary to remove the bridgework

and implants during further surgery. In this situation one could regard the dental rehabilitation effort as wasted time and money.

Although mandibular bony reconstruction reduces disfigurement and restores a confident lower jaw outline, it is the presence of teeth that prevents the sunken appearance of lips and cheeks associated with wrinkling and old age.

Furthermore, the presence of teeth improves speech and masticatory efficiency and allows the patient to resume a normal diet within a few days of surgery. All these factors undoubtedly contribute to improved patient self-esteem and psychological as well as physical well-being.

Immediate loading of implants with bridgework is now commonplace, and generally regarded as a predictable and successful approach to implant treatment.[11,12] Therefore one could argue that full immediate prosthodontic rehabilitation will be of very great value to the patient even if they are unfortunate enough to develop recurrence. They would at least have had a few months of excellent quality of life with a normal diet if they received this level of rehabilitation simultaneous with tumour resection. Although the addition of implant insertion and perioperative bridge placement lengthened the operation by approximately two and a half hours, it saved considerable operative time and costs that would have been incurred later on. The initial bridge that was made and fitted at operation was fashioned out of resin. Six months later the patient was fitted with a permanent bridge on a milled titanium substructure, which provided better aesthetics.

Interestingly, in this case the impetus for the immediate dental rehabilitation came from the patient himself. He expressed puzzlement as to why this had not been done before.

Several pre-requisites are necessary for this operation to be successful. Firstly, it is essential to have anatomically accurate 3D RPAM's from fine cut, high resolution CT or Cone Beam CT data to pre-plan bony reconstruction and implant positioning.

Secondly, it is essential to have a good working relationship between surgeon and prosthodontist, both of whom must be involved early enough for their input to be effective. It is essential to record the preoperative appearance of the patient, with the production of study models, intra and extra-oral photographs, and where necessary tooth set up arrangements and diagnostic try-ins. Thirdly, the prosthodontist has to be prepared to sacrifice one of their evenings to place the implants and fit and adjust bridgework in the operating theatre at the time of surgery.

CONCLUSION

In this case the patient underwent a slightly longer operation than normal, which resulted in immediate full dental rehabilitation as well as satisfactory mandibular reconstruction. This treatment did not prejudice the successful resection of the patient's osteosarcoma and did improve the patient's immediate postoperative appearance and functioning. The accuracy of the bony reconstruction and the achievement of a fully functional dental arch was made possible by marrying high quality CT scan data with modern rapid prototyping techniques to make a three dimensional anatomically accurate model of the patient's jaws. The unique nature of this operation and the resulting improved outcome did not owe anything to new techniques but simply involved the consolidation of all these techniques into a single operation.

1. Warnock G. Malignant neoplasms of the gnathic bones. *In* Thompson L D R. *Head and neck pathology.* pp 493-497. Elsevier, 2006.
2. Flemming A F, Brough M D, Evans N D, Grant H R *et al.* Mandibular reconstruction using vascularised fibula. *Br J Plast Surg* 1990; **43:** 403-409.
3. Bitter K. Bone transplants from the Iliac crest to the maxillofacial region by the microsurgical technique. *J Maxillofac Surg* 1980; **8:** 210-216.
4. Swartz W M, Banis J C, Newton E D, Ramasastry S S *et al.* The osteocutaneous scapular flap for mandibular and maxillary reconstruction. *Plast Reconstr Surg* 1986; **77:** 530-545.
5. Moscoso J F, Keller J, Genden E, Weinberg H *et al.* Vascularized bone flaps in oromandibular reconstruction. A comparative anatomic study of bone stock from various donor sites to assess suitability for enosseous dental implants. Archives of otolaryngology. *Head Neck Surg* 1994; **120:** 36-43.
6. Frodel J L Jr, Funk G F, Capper D T, Fridrich K L *et al.* Osseointegrated implants: a comparative study of bone thickness in four vascularized bone flaps. *Plast Reconstr Surg* 1993; **92:** 449-455, 456-458.
7. Abbott J R, Netherway D J, Wingate P G, Abbott A H *et al.* Computer generated mandibular model: surgical role. *Aust Dent J* 1998; **43:** 373-378.
8. Chan M F, Hayter J P, Cawood J I, Howell R A. Oral rehabilitation with implant-retained prostheses following ablative surgery and reconstruction with free flaps. *Int J Oral Maxillofac Implants* 1997; **12:** 820-827.
9. Zlotolow I M, Huryn J M, Piro J D, Lenchewski E, Hidalgo D A. Osseointegrated implants and functional prosthetic rehabilitation in microvascular fibula free flap reconstructed mandibles. *Am J Surg* 1992; **164:** 677-681.
10. Sekine J, Sano K, Ikeda H, Inokuchi T. Rehabilitation by means of osseointegrated implants in oral cancer patients with about four to six years follow-up. *J Oral Rehabil* 2006; **33:** 170-174.
11. Becker W, Wong J. Early functional loading in the fully edentulous mandible after mandibular resection and reconstruction due to an ameloblastoma: case report. *Clin Implant Dent Relat Res* 2003; **5:** 47-51.
12. Balsh S F, Wolfinger G J, Balshi T J. A prospective study of immediate loading following teeth in a day protocol: a case series of 55 consecutive maxillas. *Clin Implant Dent Relat Res* 2005; **7:** 24-31.