

# Letters to the Editor

Send your letters to the Editor,  
British Dental Journal,  
64 Wimpole Street,  
London  
W1G 8YS  
Email [bdj@bda.org](mailto:bdj@bda.org)

Priority will be given to letters less than 500 words long. Authors must sign the letter, which may be edited for reasons of space.

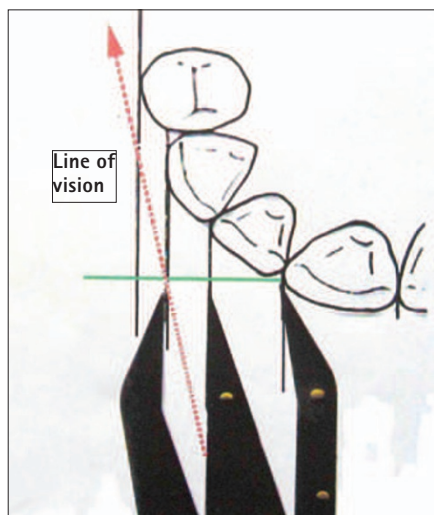
## GOLDEN ADDITIONS

Sir, I thank Dr A. Astakhov for contributing to the discussion on the golden proportion (*BDJ* 2008; 205: 61). It must be agreed that if good reference points like contact points or incisal edges are lost it makes the task a little more difficult and 0.5 mm makes a big difference to the aesthetics of the anterior teeth.

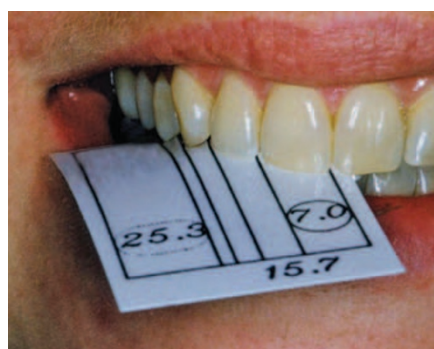
Dr Astakhov emphasises a main point that I cannot repeat often enough, that the golden proportion can only be evaluated when looking at the patient face on. It is erroneous to try to determine this with the gauge on the curve of the arch, as the parallax error can be very large. Figure 1 shows the gauge accurately superimposed on the golden proportion lines between the teeth, but also that the line of vision can give a huge parallax error. I have to disagree, however, about using the golden mean gauge on photographs where the gauge is extremely accurate giving remarkable aesthetic diagnostic information, because here the curve of the arch is reduced to the flat plane on the photograph.

The easiest way to solve the problem clinically and in the laboratory is to use cheap, hygienic, disposable paper grids. Figure 2 shows the grid being used with natural teeth and demonstrates how well they fit the grid spaces irrespective of curvature and irrespective of whether the arch is broad or narrow. These grids in the golden proportion will help to solve most proportional problems. I find the formula suggested by Radlinsky hard to understand and I could not find any written reference to it. However, the formula does suggest that the widths are symmetrical, although perfect symmetry is very rare in nature and indeed

when the teeth are constructed totally symmetrically (which the patient always requests), there is a distinct loss of naturalness and charm.



**Fig. 1** The erroneous use of the golden mean gauge due to parallax. The golden mean gauge is erroneously superimposed on the golden proportion lines between the central and lateral incisor teeth. The gauge shows a grossly distorted enlargement of the bicuspid. The more the arch is tapered the worse the effect



**Fig. 2** The paper grids in the golden proportion showing how perfectly the teeth fit the spaces in a natural dentition

## DAMMED IF YOU DON'T

Sir, as a teacher of undergraduate endodontics and a practitioner of endodontics for nearly 30 years, I find that the basis of Dr Mackay's statements could be equally accused of being illogical and in disregard of a scientific evidence-based approach (*BDJ* 2008; 205: 295-296).

We currently teach chemo-mechanical preparation techniques, where emphasis is based upon the chemical disinfection of the root canal utilising sodium hypochlorite irrigation. Mechanical preparation enlarges and shapes the canal to aid penetration of the irrigant into the depths of the dendritic root canal system, and creates the flared (variable taper) funnel-shaped preparation which maximises the obturation of the 3D intracanal space; primary concepts supported by a wealth of published literature.

If these concepts are valid then rubber dam provides three basic functions: prevention of irrigant leakage from the root canal into the oral cavity; prevention of gross contamination of the root canal by saliva during preparation and before the coronal seal; and the vital medico-legal importance in protection of the patient from inhalation or ingestion of loose instrumentation. I believe that it then becomes a mandatory requirement to use rubber dam where we use the above techniques. There is a wealth of independently published data detailing endodontic success rates that are higher when these protocols are used and lower when they are not. This is not a 'specialist endodontist' conspiracy to charge higher fees but a genuine effort to control all variables and to maximise success for our patients.

Single-visit procedures produce potentially the highest success rates due the

E. Levin  
By email

DOI: 10.1038/sj.bdj.2008.1082

initially lower levels of bacterial contamination of the dentinal and pulpal spaces, and the ability to provide a substantial coronal seal all in one visit. Success rates in endodontics are yet another contentious area, and I am not able to state that my success rate is 'a near perfect success' unlike Dr Mackay. It all depends upon your criteria for success, which may only be a lack of reported clinical signs or symptoms, but I would be very interested in the longer term radiographic evidence of periapical tissue healing and maintenance of tissue health in his patients.

Endodontic research is developing new 'super oxidising' irrigants with greater efficacy but less tissue toxic effects. Photo-activated disinfection with laser activated disinfection solutions for the treatment of root canals, and also periodontal pockets, is well advanced and linked into this concept of disruption or inactivation of the biofilm.

I recognise many of Dr Mackay's statements from when I was newly qualified in 1981 but they do not reflect the concepts of 2008. I would urge all practitioners to carefully examine their own techniques, and standards as legally these will be judged against current teaching.

P. F. Gregory  
By email

DOI: 10.1038/sj.bdj.2008.1083

## A DOUBLE MOLAR

Sir, we would like to share with your readers an unusual case of a patient with a double mandibular molar. A 26-year-old male patient presented to our department complaining of a missing tooth in the lower left posterior region. He gave a history of extraction of the tooth two years previously due to caries. Clinical examination revealed missing teeth 36 and 38 but tooth 37 demonstrated the anomalous morphology of a double tooth (Fig. 1), which radiographically (Fig. 2) revealed a large tooth with multiple roots, none of which were anomalous.

Such teeth are often confused with geminated and fused teeth. Gemination is defined as a single enlarged tooth or joined tooth in which the tooth count is normal when the anomalous tooth is counted as one.<sup>1,2</sup> Fusion is defined as

a single enlarged tooth or joined tooth in which the tooth count reveals a missing tooth when the anomalous tooth is counted as one.<sup>1,2</sup> In order to avoid confusion we termed this a double tooth. Double teeth are uncommon developmental anomalies that can occur in the deciduous and permanent dentition with a prevalence of 0.08% to 0.5%,<sup>3</sup> however, molars are rarely affected.

A. A. Sholapurkar  
Manipal

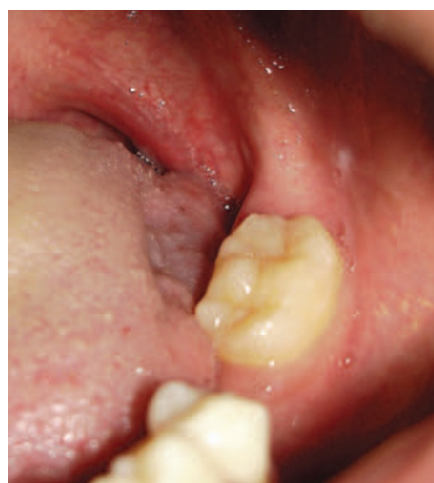

Fig. 1 Tooth 37, demonstrating the anomalous morphology of a double tooth

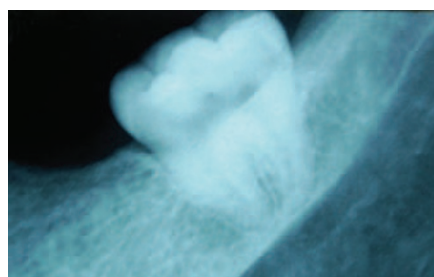


Fig. 2 Radiograph showing a large tooth with multiple roots

1. Neville B N, Damm D D, Allen C M, Bouquot J E. *Oral and maxillofacial pathology*, 2nd ed. pp 74-76. Philadelphia: WB Saunders, 2002.
2. Uys H, Morris D. 'Double' teeth – a diagnostic conundrum. *Dent Update* 2005; **32**: 237-239.
3. Hamasha A A, Al-Khateeb T. Prevalence of fused and geminated teeth in Jordanian adults. *Quintessence Int* 2004; **35**: 556-559.

DOI: 10.1038/sj.bdj.2008.1084

## RELEVANT CRITERIA

Sir, Mr Mackay (*BDJ* 2008; 205: 295-296) is to be congratulated upon his unimpeachable success rate in root canal treatment, far beyond anything I could find in the published literature from so-called specialists. Perhaps this impressive end justifies his questionable means.

I wonder though, given his disregard for the quality guidelines in treatment, as adopted by the British Endodontic Society, whether he has relevant criteria to judge success?

P. Raftery  
London

DOI: 10.1038/sj.bdj.2008.1085

## LOST FILE?

Sir, the letter *Rubber dam purpose* by R. Mackay (*BDJ* 2008; 205: 295-296) gave a good argument for not using a rubber dam. In fact we agree on many of the points made. However, a timely reminder of the perils of working without a dam presented itself to our department a day prior to the publication of this letter.

Although we acknowledge that R. Mackay does stress that 'by taking a number of simple measures' endodontic work poses little risk to the patient, rubber dam is a quick to apply, simple to use, inexpensive yet effective tool. It ensures the safety of the patient and high quality work from the clinician. Its use has few contra-indications.

Loss of an instrument in the oropharynx can lead to many serious sequelae. High up the instrument may become lodged in the larynx leading to a varying degree of inflammation and airway compromise. Recovery of an instrument at this level will be defined as invasive. Further down the respiratory tract the foreign body may cause inflammation, infection and bleeding within the lobes of the lung. Retrieval is technically difficult via a bronchoscope. Procedures may need to be converted to an open procedure and the possible loss of a lobe. Swallowing a sharp, needle-like tool can lead to it perforating at any level in its passage through the gastrointestinal tract. Perforations of the gastrointestinal tract needs to be managed very aggressively as leakage of its contents can result in mediastinitis or peritonitis depending on the level at which the breach occurred.

It is clear that such severe consequences can arise out of something very preventable. We would like to share an interesting case of a patient who presented to us after 'an instrument' was lost following a visit to the dentist. Initially a soft tissue radiograph of the

neck was performed followed by a flexible nasendoscopy. No instrument was located. A chest radiograph was then performed which was normal. Lastly an abdominal film showed the file (Fig. 1). An urgent referral was made to the gastroenterology team who kindly arranged removal endoscopically. The patient was observed for 24 hours and discharged without incident.

Dental defence organisations make guidelines whilst performing root canal treatment abundantly clear. Unless rotary instruments are used (held securely within a handpiece), the use of handheld files should be supported by at least a parachute chain. Their view is so strong that any injury inflicted whilst not using a rubber dam during root treatment is deemed 'indefensible'. The choice ultimately though is that of the practitioner!

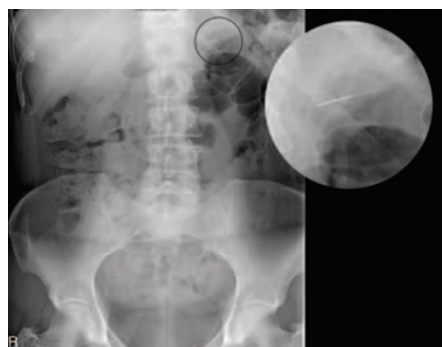

Fig. 1 Abdominal film showing the lost file

M. Singh, T. Pepper, H. Kiani, R. Paul

By email

DOI: 10.1038/sj.bdj.2008.1086

### SWABBING FOR ACCURACY

Sir, further to the letter on denture ulcerations (*BDJ* 2008; 205: 297) it comes to mind how simple measures can control multifarious causes of oral ulcers, especially the more common ones such as denture sore mouth. Betamethasone mouthwash is one of the widely prescribed mouthwashes in such cases. As the authors correctly point out, monomer leaching is not a very common cause of symptoms in such a patient and we would like to add the importance of taking an oral swab for culture of any possible fungal organisms in such cases as these micro-organisms are of prime importance in sore denture mouths. Subsequent to this, it might be appropriate

to prescribe miconazole gel or nystatin pastilles to such patients for symptomatic relief.

R. Paul, M. Singh, K. Shekar

By email

DOI: 10.1038/sj.bdj.2008.1087

### BIDI TOBACCO

Sir, 'bidis', 'beedis' or 'beeris' are slim, hand-rolled, unfiltered cigarettes. A bidi consists of about 0.2 g of sun-dried and processed tobacco flakes, rolled in a tendu leaf (*Diospyros elanoxylon*) or temburni leaf and held together by a cotton thread. The tobacco rolled in bidis is different from that used in cigarettes and is referred to as 'bidi tobacco'.

The relatively low combustibility and non-porous nature of the tendu leaves requires more frequent and deeper puffs by the smoker to keep bidis lit, and is therefore harder on the smoker's lungs than cigarettes rolled in paper. Tar levels delivered by bidis are high, at 45–50 mg/bidi. One study found that bidis produced approximately three times the amount of carbon monoxide and nicotine and approximately five times the amount of tar as cigarettes. Bidis are known as the 'poor man's cigarettes', as they are smaller and cheaper than cigarettes. About 19% of tobacco consumption in India is in the form of cigarettes, while 53% is smoked as bidis. The rest occurs mainly in smokeless form.

Flavoured and herbal bidis have a very small market in India but they are marketed aggressively in the West. Herbal bidis claim to contain mixtures of herbs rolled in tendu leaves and are marketed as safer, healthier alternatives to cigarettes.

One factor that may contribute to the popularity of bidi smoking among young adults is the perception that bidis are natural or herbal. Researchers have also suggested that young people may mistakenly think that bidis are tobacco-free herbal cigarettes. Bidi smoking among college students is rare, and those who do smoke bidis often do not do so in public because of the lower social class status associated with bidi smoking. However, attitudes and perceptions might be changing among these young people.

In areas where women and children roll bidis in the absence of other income

generation, strategies for research are needed on developing a diverse array of alternative income-generating opportunities. Policies aimed at holding the industry accountable for ensuring an education for all children in any way associated with bidi work, even within the home, is central to addressing the child labour issue. Finally, there is a need to reconsider regulating the bidi industry in light of the regulation of other tobacco products and to question its favoured status from the vantage point of public health.

M. Kamboj

Lucknow

DOI: 10.1038/sj.bdj.2008.1088

### LET'S FACE IT

Sir, on 25 October 2008 I attended a seminar organised by the charity 'Let's Face It' at the Royal College of Surgeons. It was an excellent day intended to raise awareness of the charity and the needs of patients who have undergone radical surgery which has changed their face, to the professionals who treat them.

Towards the end of the day two patients gave an account of their experiences and how the charity had helped them to regain their life after surgery. I found it interesting that both had been initially referred to hospital by their general dental practitioner (GDP). I am aware that GDPs are willing to treat their patients after radical surgery, but wondered how many have heard of 'Let's Face It'.

The charity was founded in 1984 by Christine Piff seven years after undergoing surgery herself, and gives patients the choice to seek help from others who have experienced similar problems. The aim of the charity is to give one to one support and counselling, as well as group meetings with people who have had similar experiences.

The charity is happy to supply leaflets to any members of the dental profession outlining the aims of the charity to patients who have a facial disfigurement, regardless of how it was caused.

'Let's Face It' can be contacted by telephoning Christine on 01843 833724.

B. Jones

By email

DOI: 10.1038/sj.bdj.2008.1089