Paraplegia (1995) 33, 560–564

Experience with augmentation cystoplasty. A review

P Mast[1], P Hoebeke[1], JJ Wyndaele[2], W Oosterlinck[1] and K Everaert[1]

[1]*Department of Urology, University Hospital, De Pintelaan 185 B-9000 Ghent;* [2]*Department of Urology, University of Antwerp, Wilrijkstraat 10 B-2520 Edegem, Belgium*

Good experience with clam cystoplasty is reported for 28 patients (14 female), 89% of whom had a neuropathic bladder. Prolonged conservative treatment had failed in all cases. The efficacy of the operation in terms of continence, increased bladder compliance, and bladder capacity was confirmed. Complications were common and included inability to void (70%) requiring clean intermittent catheterisation (CIC), recurrent urinary tract infection (59%) and stone formation (22%). Due to these complications, further surgery was required for 44% of the patients. Although clam enterocystoplasty is an efficient way to reconstruct a functionally disturbed urinary tract, careful patient selection is essential. Lifetime follow-up and recognition of the most frequent complications is mandatory.

Keywords: neuropathic bladder; urinary incontinence; urinary reservoir; vesicoureteral reflux; artificial urinary sphincter; augmentation cystoplasty

Introduction

The use of gastrointestinal segments for bladder augmentation has increased over the last decade. The purpose of bladder augmentation is to create a reservoir that can store adequate amounts of urine at low pressure, thus preserving the upper urinary tract from damage and facilitating continence. These goals can be achieved by conservative therapy: anticholinergic drugs with or without clean intermittent catheterisation (CIC). If these measures fail, more invasive techniques can be helpful. Bladder distention, bladder transection, transvesical phenolisation of the pelvic plexus, autoaugmentation, augmentation, and rhizotomy with sacral root-stimulator implantation have been reported to have varying degrees of success.

Patients and methods

Patients

The files of the patients who underwent a bladder augmentation were analysed retrospectively. Between July 1987 and July 1993, 28 patients underwent augmentation (14 women, 14 men). The ages varied from 5 to 54 years (mean 26 years), and the follow-up periods varied from 3 to 72 months (mean 31 months). No patient was lost to follow-up.

Table 1 shows the underlying disease. Half of the patients had a meningomyelocoele, while the second largest group consisted of spinal trauma patients (20%).

All patients had been evaluated with video-urodynamics. The majority (89%) showed urodynamically a hyperreflex or low compliant bladder. Nine patients had reflux and all but one were incontinent (96%). A patient was considered incontinent if pads were needed and if urge or stress incontinence was proven by urodynamics.

Table 2 shows the prior therapies. Eighty nine per cent of the patients received anticholinergic drugs for 14 to 192 months (mean 69 months) preoperatively; five patients (18%) had undergone surgical correction

Table 1 Underlying disease

Meningomyelocoele	14 (50%)
Tetraplegia	3 (10%)
Paraplegia	3 (10%)
Neuropathic bladder after hysterectomy	2 (7%)
Extrophia + epispadias	1
Multiple sclerosis	1
Post radiotherapy (small bladder)	1
Sacrococcygeal teratoma	1
Tethered cord	1
Bladder pain (hysteria?)	1
Total	28

Table 2 Previous treatment

Anticholinergics	25 (89%)
No operations	10 (36%)
Phenolisation	3 (10%)
Antireflux	7 (25%)
Nephrectomy	3 (10%)
Sphincterotomy	2 (7%)
Artificial sphincter	2 (7%)
Burch	2 (7%)
Sling	1 (3.5%)
Extrophia	1 (3.5%)
Autoaugmentation	1 (3.5%)

of incontinence; three nephrectomies had been performed, two of which were due to reflux nephropathy; nine refluxing ureters had been reimplanted prior to bladder augmentation in seven patients.

The preoperative urodynamic findings (Table 3) showed a mean low bladder compliance ($\triangle V/\triangle P$) of 7.4 and a mean low bladder capacity of 235 ml. Leak pressure was reached in 26 patients during urodynamic investigation, the mean leak pressure being 72 cm H_2O. Twenty two patients (79%) showed a compliance less than 10. Three patients had a neuropathic bladder with neuropathic sphincter deficiency; two patients had a low bladder capacity; and one patient presented with intense bladder pain during filling.

At the time of augmentation, reflux was present in 17 ureters in 14 patients (50%) of which four patients were treated before for reflux (two nephrectomies, two recurrences) (Table 4).

Surgical technique

The technique used in this series was first described by Bramble (1982) for refractory urge incontinence.[1] It was popularised by Mundy and Stephenson. The bladder is opened like a clam, bivalving it almost completely in the coronal plane. The incision is carried on 1.5 cm proximal to the internal urethral meatus, anterior to the ureteric orifices.[1-2] In 26 patients, a preterminal ileum segment of 15 to 60 cm (mean 21 cm) was then isolated with its own blood supply and detubularised by incising the anti-mesenteric border. The ileal patch was sewn into the bladder defect with a single layer of running 2.0 polygluconate suture (Vicryl[R]). Bowel continuity was restored using staples. In one patient, the ascending colon was used. In one patient with borderline renal function, the stomach was used. In all of the patients, the augmented bladder was diverted for 12 days with a suprapubic catheter. After 12 days cystography was done to check the watertightness of the suture. If no leakage was observed, the catheter was removed and a temporary transurethral catheter was left for a few days. After removal of the latter, the patient could start emptying the bladder, either by straining, or by clean intermittent catheterisation.

Table 3 Preoperative urodynamics

Compliance ($\triangle V/\triangle P$)	1–33 (7.4)
Capacity (ml)	50–550 (235)
Leak-pressure (cm H_2O)	16–120 (72)
Reflux (ureters)	17

Table 4 Patients with preoperative reflux

Bilateral	3
Unilateral	9
Post nephrectomy (in ureteral remnant)	2
Total	14 (50%)

In 13 patients, 19 other surgical procedures were performed during the augmentation; these are described in Table 5. In seven patients, nine refluxing ureters were treated (two ureterectomies, seven antireflux). In three patients, definitive bladder neck closure was performed with bladder diversion. In four patients, a surgical urethral continence procedure was performed.

Results

The hospital stay varied from 16 to 180 days (mean 31 days).

The postoperative urodynamic findings after a mean follow-up of 31 months (3–72 months) are listed in Table 6. The mean compliance was 27.1, and the mean bladder capacity 511 ml. Only 10 patients reached leak pressure (mean 46 cm H_2O). Grade I reflux persisted in two ureters in two patients.

The postoperative bladder emptying situation is set out in Table 7.

Incontinence persisted in 30% of the patients and was caused by low urethral resistance in four patients and by persistent hyperreflex bladder contractions in four patients. In the former four patients, an artificial sphincter was later successfully implanted, giving overall postoperative incontinence of 15%.

Table 5 Additional procedures

Antireflux	7
Ureterectomy	2
Bladder neck closure	3
Mitrofanoff	2
Cystostomy	1
Sling	1
Burch	1
Artificial sphincter	1

Table 6 Postoperative urodynamics

Compliance ($\triangle V/\triangle P$)	6–78 (27.1)
Capacity (ml)	170–1000 (511)
Leak-pressure (cm H_2O)	32–100 (46)
Reflux (ureters)	2

Table 7 Bladder emptying after augmentation

	Continent	*Incontinent*
CIC[a]	17	3 (70%)
Straining	1	3 (15%)
CIC + straining	0	3 (11%)
Spontaneous voiding	1	0 (4%)
Total	19 (70%)	8[b] (30%) (100%)

[a]CIC: clean intermittent catheterisation
[b]Four patients with low urethral pressure

The short-term complications are indicated in Table 8. One patient died 4 weeks after augmentation because of a massive pulmonary embolism. The longest hospital stay of 180 days followed an illness from general peritonitis in the patient with the sphincter implantation. Urosepsis occurred in three patients, and three patients required a surgical intervention for short-term complications. These interventions consisted of removal of a broken catheter, removal of the artificial sphincter, and drainage of a perivesical abscess.

The long term complications are listed in Table 9. Adhesions of the ileum patch necessitated remodelling 9 months postoperatively in one case, resulting in an acceptable urodynamic situation. One patient developed a urethral fistula by traumatic CIC, and five patients developed bladder or kidney stones. Chronic infections of the augmented bladder occurred in 59% of the cases. Furthermore, as a result of these complications, one or more reinterventions were necessary in nine patients. These are listed in Table 10. The total number of patients requiring reintervention following complications, therefore, was 12 (44%). If we include the four patients who were later given an artificial sphincter, 59% of the patients needed a reintervention after augmentation.

Discussion

Although bladder augmentation was already being performed in 1958 for interstitial cystitis and tuberculous cystitis,[3] only at the end of the seventies did it become popular for the treatment of bladder dysfunction. Surgical bladder augmentation is used to reconstruct the impaired lower urinary tract. The purpose of this intervention is to preserve the upper urinary tract from function loss and possibly to achieve continence.

Table 8 Short term complications

Major		*Minor*	
Urosepsis	3	Kidney stone	1
Peritonitis	1*	Diarrhoea	1
Perivesical abscess	1*	Unconsciousness	1
Pulmonary embolism	1	Erysipelas	1
		Broken drain	1[a]

[a]Reinterventions = 3

Table 9 Long term complications

Major		*Minor*	
Clam adhesions	1[a]	Chronic infection	16 (59%)
Renal function	1[a]	Bladder calculi	3[a] (11%)
Urethra fistula	1[a]	Kidney stone	2[a] (7%)
		Incisional hernia	1[a]
		Bladder tamponade with mucus	1

[a]Reinterventions = 9

Table 10 Reinterventions

	n
Bladder stone lithotrypsy	3
Percutaneous litholapaxy	2
Laparotomy (drain)	1
Revision of ileum bladder	1
Closure of hernia	1
Drainage of abscess	1
Pyelostomy + dilatation ureterovesical junction	1
Cystostomy (urethral fistula)	1
Exploratory laparotomy + removal artificial sphincter	1
Total	12 (44%)
Later addition of artificial sphincter	4
Total	16 (59%)

Low compliance and high-pressure hyperreflexic detrusor contractions threatening the upper urinary tract despite conservative therapy are the indications for this intervention. Because bladder augmentation means urinary retention, the technique only became popular after the widespread acceptance of CIC.[4]

Careful patient selection is mandatory: the patients must have or be at risk of having upper urinary tract damage due to bladder dysfunction which cannot be influenced adequately by conservative means of treatment. In this series the largest group consisted of patients with a neuropathic bladder disease (89%). The use of the technique in the epispadias-extrophy complex, urethral valves, and radiocystitis is described, but this group is small in the present series (only two patients).

The preoperative video-urodynamic results (low compliance, low capacity, incontinence, and reflux despite conservative treatment) indicate the severity of bladder dysfunction in this series.

One of the difficulties in the preoperative decision-making is the need for concomitant ureter reimplantation. The degree of reflux on cystography and impaired function on radionuclide scanning can provide helpful information. In those with low-grade refluxing ureters and non-impaired kidney function, the augmentation alone will be sufficient: in six out of eight with refluxing ureters, the reflux disappeared due to the augmentation alone. Ureter reimplantation is by far the most frequently associated procedure in this series (seven reimplantations).

The second difficulty in the preoperative decision-making concerns urethral resistance. Is simultaneous correction of a low urethral pressure (sling-colposuspension-artificial sphincter) indicated? The preoperative urodynamic results can be helpful. Stress incontinence will be important even after augmentation in patients with sphincter deficiency. The judgement of sphincter activity and the measurement of leak pressure during urodynamic investigations are of particular importance in this respect. An artificial sphincter implant is a challenge: in this series only one simultaneous implant was performed, with poor results. Thus,

delayed implantation was chosen and was performed successfully in four patients. Other groups report good results with simultaneous implantation.[5]

The third important preoperative decision concerns bladder emptying. One should always assume that augmentation will result in retention, especially if simultaneous correction of low urethral pressure is performed. The possibility of CIC has to be discussed with the patient who should be trained before the augmentation. In this series 70% performed CIC. Continence was achieved in 95% of these patients. All the patients using straining were incontinent. In one patient, the CIC ability was overestimated, resulting in urethral perforation and a vesicovaginal fistula. After closing the bladder neck, a Mitrofanoff diversion was performed.[6] This diversion was chosen in two additional patients. The first had an epispadias-extrophy complex, making catheterisation of the urethra impossible; the second was a wheelchair-bound girl with a myelomeningocoele. These patients are the ideal candidates for the Mitrofanoff procedure.

Patients with a ventriculoperitoneal shunt constitute an important subgroup. There is a risk of infection and dysfunction of the shunt,[7–8] thus antibiotic prophylaxis is mandatory. One patient developed headache and lost consciousness after augmentation. A shunt complication was feared but the symptoms resolved spontaneously.

The results in this series match the expectations. The mean compliance ($\triangle V/\triangle P$) increased from 7.4 to 27.1 and the mean bladder capacity from 235 ml to 511 ml. Seventy per cent of the patients became continent, in contrast to 4% continent patients preoperatively. After implantation of an artificial sphincter at a second operation, the rate increased to 85%. Postoperatively, anticholinergic drugs are still needed, due to persisting low bladder compliance and intermittent high intravesical pressures.[9] After 9 months, the maximal effect of the intervention is reached.[10]

Nevertheless, it is important to note that good results are achieved only at the expense of complications and that good final results depend on early diagnosis and treatment of these complications. In addition to the complications inherent in major surgery, there are some specific ones.

Chronic infections are frequent. In this series, 59% of patients were infected,[11] the cause being multifactorial. The intestinal mucosa probably plays a major role in the persistence of infection, for the mucus layer makes it difficult for antibiotics and antiseptics to reach the mucosa. Introduction of bacteria during CIC is frequent and favours infections. These infections probably play a major role in the increased risk of malignancy in the intestinal mucosa of neobladders. Bacteria form n-nitrosamines from urinary urea, which are carcinogenic. The literature describes nine cases of malignancy in an ileum bladder (seven adenocarcinomas, two transitional carcinomas).[12,13] If the colon is used for augmentation, this risk is even higher.

In this series, metabolic acidosis was found in about 20% of the patients. When necessary, it was treated with bicarbonate. The ileal mucosa contains separate cation and anion exchangers. Sodium and chloride are absorbed against a concentration gradient (active process). When chloride absorption exceeds sodium absorption, there is a net loss of bicarbonate into the lumen, resulting in acidosis. The acidosis in ileocystoplasties tends to decrease with time probably subsequent to villous atrophy of the mucosa.[14–16]

The presence of natural intestinal secretions (mucus) can also be troublesome as the intestine continues to secrete.[17] These secretions can obstruct the catheter for CIC. Furthermore, the mucus can cause stone formation[18] and favours chronic infection. Regular bladder irrigation with saline can help to evacuate these mucus plugs. Mucolysis can be achieved with acetylcystein instillation, which facilitates evacuation.[17] Recently, the efficacy of H_2-blockers in diminishing the mucus production has been demonstrated.[19] It is also important to note that iodium-contrast products can stimulate mucus secretion.[20] Preventative intake of H_2-blockers before carrying out radiological investigations (cystography, IVU) can be useful. In this series one instance of mucus bladder tamponade was observed.

As mentioned above, stone formation is another major complication. It was found in 22% of the patients in this series. The cause is multifactorial (Figure 1). In patients who are already immobilised, calcium carbonate is mobilised from bone to buffer metabolic acidosis. The carbonate combines with hydrogen ions and calcium is excreted in the urine.[16] Moreover, chronic infection in combination with mucus forms an ideal environment for stone formation.[18]

Bile salts diarrhoea in augmented patients was a rare complication in this series. Preserving the terminal ileum tends to avoid this problem.[21] Cholestyramin gives good results if diarrhoea occurs despite this measure. Bladder rupture has been assessed regularly in the literature,[22–25] but this complication did not occur in our series. Bladder overdistention causing vascular insufficiency probably causes this life-threatening event. Brisk movements can also cause rupture because of the inertia of large urine masses. Therefore patients are advised not to allow their bladder content to become too great and to catheterise their bladder before physical exercise.

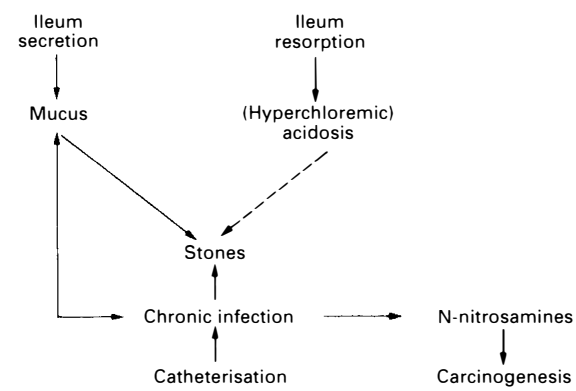

Figure 1

Every option is possible in choosing the segment of the gastrointestinal tract for augmentation. The ileum provides a good compliance; the stomach also has a good compliance and will also prevent chronic infection because of the acid environment it creates. Furthermore, resorption through the stomach mucosa does not occur, which makes this segment ideal for patients with border-line kidney function. Mucus production also does not occur, thus the risk for malignancy is probably less than with both of the other segments. In spite of these positive features, H+ secretion can cause metabolic alkalosis. Furthermore, stomach ulcers were observed. Patients with a low diuresis are not good candidates for this operation, nor are patients with normal urethral sensitivity; acid urine causes extreme dysuria in patients with normal sensitivity.

Finally, the mortality of augmentation in our series was 4%. Indeed, one patient died 4 weeks postoperatively following a massive pulmonary embolism.

Conclusion

Clam enterocystoplasty is an excellent form of treatment for those with therapy-resistent low compliance, and low-capacity bladders. Augmentation is not without complications; however, careful patient selection is vital and the evaluation of simultaneous additional urinary tract operations is essential. Augmentation causes major physiological disturbances, thus lifetime follow-up is mandatory. Good long term results can only be achieved with early recognition of any complication.

References

1 Bramble FJ. The clam cystoplasty. *Br J Urol* 1990; **66**: 337–341.
2 George VK *et al*. Clam ileocystoplasty. *Br J Urol* 1991; **68**: 487–489.
3 Kockelbergh RV *et al*. Clam enterocystoplasty in general urological practice. *Br J Urol* 1991; **68**: 38–41.
4 Lapides J, Diokno AC, Silber SJ, Lowe BS. Clean intermittent selfcatheterisation in the treatment of urinary tract disease. *J Urol* 1972; **107**: 458.
5 Goodwin WE, Turner RD, Winter CC. Results of ileocystoplasty. *J Urol* 1958; **80**: 461.
6 Strawbridge LA, Kramer SA, Castillo OA, Barrett DM. Augmentation cystoplasty and the artificial genito-urinary sphincter. *J Urol* 1989; **142**: 297–301.
7 Khoury JM, Timmons SL, Corbel L, Webster GD. Complications of enterocystoplasty. *Urology* 1992; **40**: 9–14.
8 Kreder KJ, Webster GD, Oakes WJ. Augmentation cystoplasty complicated by postoperative ventriculoperitoneal shunt infection. *J Urol* 1990; **144**: 955–956.
9 Andersson KE, Hedlund H, Mansson W. Pharmacologic treatment of bladder hyperactivity after augmentation and substitution enterocystoplasty. *Scand J Urol Nephrol* 1992; Suppl **142**: 42–46.
10 Fenn N, Conn IG, German KA, Stephenson TP. Complications of clam enterocystoplasty with particular reference to urinary tract infection. *Br J Urol* 1992; **69**: 366–369.
11 Nurse DE, Mundy AR. Assessment of the malignant potential of cystoplasty. *Br J Urol* 1989; **64**: 489–492.
12 Golomb J *et al*. Bladder neoplasms associated with augmentation cystoplasty: report of 2 cases and literature review. *J Urol* 1989; **142**: 377–380.
13 Wagstaff KE, Woodhouse CRJ, Duffy PG, Ransley PG. Delayed linear growth in children with enterocystoplasties. *Br J Urol* 1992; **69**: 314–317.
14 Nurse DE, Mundy AR. Metabolic complications of cystoplasty. *Br J Urol* 1989; **63**: 165–170.
15 Gillon G, Mundy AR. The dissolution of urinary mucus after cystoplasty. *Br J Urol* 1989; **63**: 372–374.
16 Nurse DE, Mundy AR. Calcium balance, growth and skeletal mineralisation in patients with cystoplasties. *Br J Urol* 1992; **69**: 257–259.
17 Blyth B, Ewalt DH, Duckett JW, Snyder HM. Lithogenic properties of enterocystoplasty. *J Urol* 1992; **148**: 575–577.
18 George VK *et al*. The effect of ranitidine on urine mucus concentration in patients with enterocystoplasty. *Br J Urol* 1992; **70**: 30–32.
19 Leibovitch IJ, Ramon J, Ben Chaim J, Goldwasser B. Increased urinary mucus production: a sequela of cystography following enterocystoplasty. *J Urol* 1990; **145**: 736–737.
20 Canning DA, Perman JA, Jeffs RD, Gearhart JP. Nutritional consequences of bowel segments in the lower urinary tract. *J Urol* 1989; **142**: 509–511.
21 Crane JM, Scherz HS, Billman GF, Kaplan GW. Ischemic necrosis: a hypothesis to explain the pathogenesis of spontaneously ruptured enterocystoplasty. *J Urol* 1991; **146**: 141–144.
22 Rosen MA, Light JK. Spontaneous bladder rupture following augmentation enterocystoplasty. *J Urol* 1991; **146**: 1232–1234.
23 Anderson PAM, Rickwood AMK. Detrusor hyperreflexia as a factor in spontaneous perforation of augmentation cystoplasty for neuropathic bladder. *Br J Urol* 1991; **67**: 210–212.
24 Bauer SB *et al*. Perforation of the augmented bladder. *J Urol* 1992; **148**: 699–702.
25 St Clair SR, Ritchey ML, Hansberry H, Hixson CJ. Viability and functional characteristics of enterocystoplasty after ligation of the vascular pedicle. *J Urol* 1991; **146**: 554–557.