Paraplegia (1995) 33, 536–537

Gastric volvulus—a complication of spinal cord omental transposition. Case report

A Ray[1], G Savich[2] and B Gardner[3]

[1]Senior House Officer, [2]Research Associate, [3]Consultant Surgeon in Spinal Injuries, The National Spinal Injuries Centre, Stoke Mandeville Hospital, Aylesbury, Bucks, HP21 8AL, UK

Keywords: spinal cord; omental transposition; complications; stomach volvulus

Introduction

It is claimed by some that omental graft transfer is beneficial to spinal cord injured patients.[1–6] The procedure has several complications.[7–9] This case report describes gastric volvulus causing obstruction and requiring gastrojejunostomy as another complication of spinal cord omental transposition.

Case report

A 51-year-old Nigerian man sustained C5 complete tetraplegia in a road traffic accident in 1987. Two years following injury an omental graft transposition was performed in London. Through a midline abdominal incision the omentum was mobilised on the right gastroepiploic artery. It was tunnelled subcutaneously up the right chest wall. Through a separate incision on the back of his neck his cervical spinal cord was exposed. The omentum was placed on the dorsal aspect of the cervical cord. Following transposition he regained patchy sensation but no motor function below the level of his injury.

Five years later he developed recurring upper intestinal obstruction. Gastroscopy was unhelpful because of the distorted anatomy. The barium meal showed a gastric volvulus (Figure 1).

After the fourth episode of intestinal obstruction his abdomen was explored. The omental graft was found to have caused complete rotation of the stomach by pulling on the right gastroepiploic artery resulting in gastric outlet obstruction (Figure 2). There were no adhesions. No attempt was made to correct the gastric volvulus for fear of compromising the vascularity of the graft. The obstruction was bypassed by means of a retrocolic isoperistaltic gastrojejunostomy.

He had a satisfactory postoperative recovery and has had no further intestinal obstruction in the 5 months since surgery.

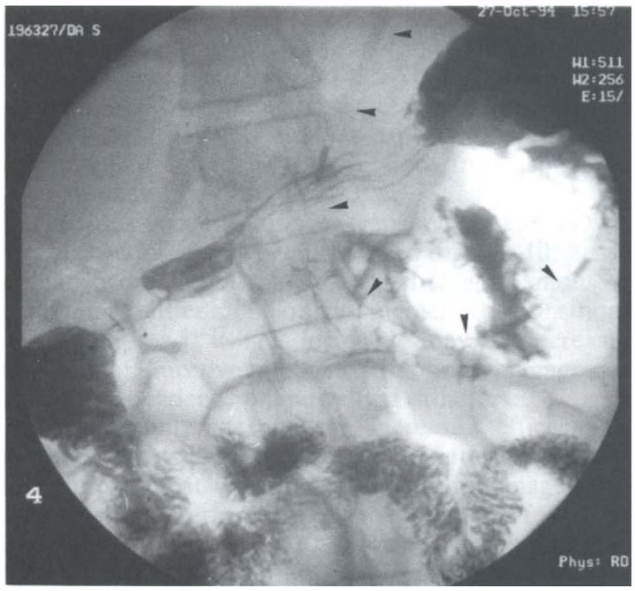

Figure 1 Barium meal—the stomach volvulus is indicated by the direction of the nasogastric tube, which is marked by arrows

Discussion

The use of the omentum in surgery was reported by Jobert de Lambelle in 1826. The extraordinary capacity of the omentum to form blood vessels was recognised by the British surgeon Rutherford Morison at the end of the 19th century. Many different clinical applications for the omentum have been described.[10,11]

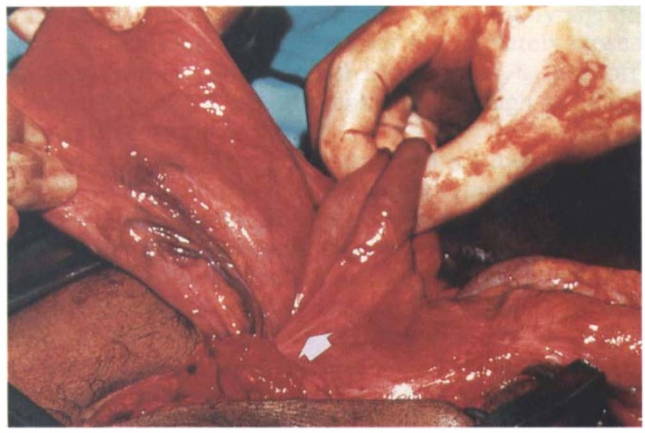

Figure 2 Operative photograph—the tight constricting band around the stomach is indicated by the arrow

Correspondence: B Gardner

Spinal cord omental graft transposition has been performed with the aim of improving neurological function. Although some success has been claimed this is not supported by any well conducted clinical trial.

Van Gardersen *et al* reported a series of 74 patients in whom pedicled omentoplasty was performed to reconstruct large soft-tissue defects, to treat radiation necrosis and to prevent radiation enteritis. There were 47 complications. These included intestinal obstruction due to adhesions, stomach herniation, total necrosis of the omental flap, infection, incisional herniation and one case of fatal pulmonary embolism. Other complications of the procedure reported include middle colic artery damage[8] and gastric perforation.[9] The case reported here describes another serious complication of omental transposition. Whilst some complications settle with conservative treatment others require major surgery to correct them.

The value of spinal cord omental transposition remains unproven. Its place should be demonstrated by means of a carefully planned and executed clinical study. Until that time it should not be performed in clinical practice especially bearing in mind the potential complications. There is little place at present for the occasional operator who is much more likely to meet complications than the surgeon who has already gone through the learning curve for the procedure.

References

1 Goldsmith HS, Neil-Dwyer G, Barsoum L. Omental transposition to the chronically injured human spinal cord. *Paraplegia* 1986; **24**: 173–174.
2 Zhan Ming-shu *et al*. The effect of transposition of pedicled omentum to spinal cord ischemia segments. *Ch Med J* 1989; **102**: 214–218.
3 Goldsmith HS, Steward E, Duckett S. Early application of pedicled omentum to the acutely traumatised spinal cord. *Paraplegia* 1985; **23**: 100–112.
4 Rafael H, Malpica A. Espinoza M, Moromizato P. Omental transplantation in the management of chronic traumatic paraplegia. Case report. *Acta Neurochir (Wien)* 1992; **114**: 145–146.
5 Abraham J *et al*. Omento-myelo-synangiosis in the management of chronic traumatic paraplegia: Case report. *Paraplegia* 1987; **25**: 44–49.
6 Song MF. Indications and complications of omental transplantation to the spinal cord. *Chung-Hua-Wai-Ko-Tsa-Chih Jun* 1990; **28**: 342–345, 381.
7 Van Garderen JA, Wiggers TH, van Geel AN. Complications of the pedicled omentoplasty. *Neth J Surg* 1991; **43**: 171–174.
8 Abbott WC, White H. Omental transposition for recurrent breast carcinoma following limited surgical excision and radiation therapy. *Eur J Surg Oncol* 1986; **12**: 59–66.
9 Kiricuta I. L'emploi du grand epiploon dans la chirurgie du sein cancereux. *Presse Med* 1963; **71**: 15–17.
10 Ruffini E. Surgical applications of the greater omentum. A critical review of the literature. *Panminerva Med* 1992; **34**: 135–140.
11 Liebermann DM, Kaufmann M. Utilization of the greater omentum in surgery: a historical review. *Neth J Surg* 1991; **43**: 136–144.