

**Proceedings of the Annual Scientific Meeting of the
International Medical Society of Paraplegia
held at Stoke Mandeville Hospital on 28th to 30th July 1971**

**EXTERNAL SPHINCTEROTOMY FOR THE RELIEF OF OUTLET
OBSTRUCTION IN NEUROGENIC BLADDER**

By J. DERMOT O'FLYNN, M.CH., F.R.C.S.(Ed.), F.R.C.S.I.

*National Medical Rehabilitation Centre; Urological Department, Meath Hospital and
Department of Surgery, Trinity College, Dublin*

It is widely accepted that failure of relaxation of the external sphincter is an important factor in the production of outlet obstruction in neurogenic bladder. The external sphincter is composed of striated muscle fibres and it is assumed that it participates in the spasticity associated with neurological disease, and its failure to relax during the act of micturition can constitute a major cause of obstruction to bladder emptying. The earlier work of Emmett and Dunn (1946), Emmett and Beare (1948), Emmett *et al.* (1951), indicated that the main obstruction at the vesical outlet was due to functional and hypertrophic changes at the internal urinary sphincter, and these changes reflect the changes in the bladder detrusor. Emmett showed that transurethral resection of the vesical neck and prostate relieved outlet obstruction in a large number of neurogenic bladders, but not all cases are relieved by this operation even when the procedure is repeated, and this situation led Ross *et al.* (1958, 1963) to exploit division of the external sphincter to relieve what appeared to be a secondary, and possibly less important, cause of bladder outlet obstruction. They showed that when transurethral resection of the vesical neck and prostate failed to permit complete emptying of the bladder, transurethral excision of part of the external sphincter did so.

Emmett and Dunn (1946) had reasoned that the 'external sphincter is the most important single factor in the control of micturition', but did not explain how resection of the internal sphincter relieved retention of urine in neurological cases. Damanski and Kerr (1957) have shown that obstruction can be demonstrated very frequently at the level of the external sphincter. Recently, Angoli (1967), on the basis of a radiological study, suggested that the primary cause of bladder outlet obstruction is the external sphincter. He suggested that transurethral resection of the bladder neck was not indicated if the posterior urethra showed dilatation, and he questioned the value of transurethral resection of the vesical neck and prostate to relieve outlet obstruction. The fact remains, however, that transurethral resection is well known to relieve outlet obstruction in many cases, and this becomes understandable only if it is accepted that the initial obstruction caused by the external sphincter is overcome by the bladder increasing its expulsive force by hypertrophy of the detrusor muscle and thereby overcoming the now relatively weak external sphincter, and that *this hypertrophy extending to the vesical neck becomes in itself a secondary obstruction to micturition*. Removal of this bar to micturition restores fairly normal voiding: the now hypertrophied bladder empties at a high pressure and thereby overcomes the obstruction presented by the external

sphincter. This conclusion therefore indicates that such a bladder must always empty at a higher than normal pressure, and that trabeculation, diverticulum formation and reflux may occur more often in a bladder treated by vesical neck resection alone. These changes do not always occur in practice, but it is of considerable significance that external sphincterotomy is far more frequently necessary in tetraplegic spinal lesions as distinct from lower and cauda equina lesions, and it can be argued that spasticity of the external sphincter is a very marked feature in tetraplegics, whereas a more flaccid, but still unrelaxed external sphincter is present in the lower spinal lesions and in cauda equina lesions.

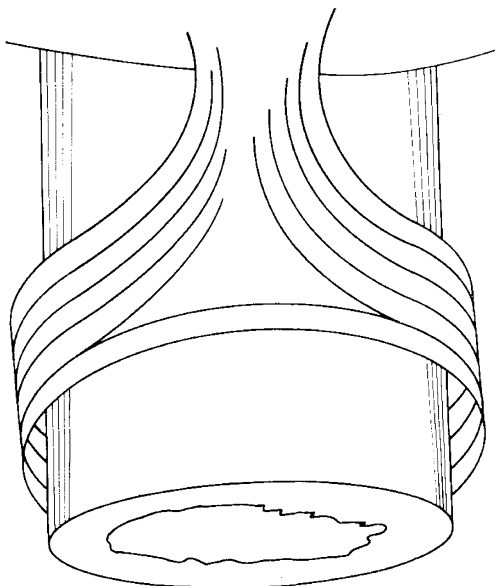


FIG 1.

Distribution of external sphincter muscle fibres.

The anatomy of the external sphincter in its relationship to the urethra has not been extensively studied. To the cystoscopist its exact site and extent is fairly easily definable, but the anatomical distribution of the striated fibres is not so simple. Manley (1966), on the basis of an anatomical dissection, indicated that the external sphincter 'was much thicker anteriorly, gradually thinning laterally, and becoming quite sparse posteriorly'. Anteriorly the striated fibres spread upwards to become attached to the prostate or prostatic capsule (Manley, 1966; Kinder, 1969). It also appears that the striated fibres are developed from the striated muscle of the perineal musculature. Recently, Sant (1971) found that the striated fibres lying on the superior surface of the urethra were distributed mostly longitudinally, and that distally they sweep laterally to enclose the urethra, thinning out somewhat as they do so, and are sometimes deficient posteriorly (fig. 1). On the basis of his studies, it appears that possibly the best site for incision to render this mechanism incompetent is superiorly or laterally.

The main function of the external sphincter would appear to be to help to maintain continence. Its relaxation may be also an essential factor in the act of

micturition after the detrusor has contracted (Lapides *et al.*, 1957), and its closure essential to decisive termination of micturition. Tanagho and Miller (1970) have shown that the striated external sphincter accounts for about 50 per cent. of the urethral closure pressure. They also concluded that the entire pelvic floor is part of the sphincter mechanism. It is also quite well known, to resectionists especially, that a single incision in the external sphincter is sufficient to cause incontinence, but incision of the sphincter does not cause incontinence in all cases.

The external sphincter can be rendered incompetent by either pudendal neurectomy or external sphincterotomy. Pudendal neurectomy has been shown by Ross (1968) and Murnaghan and Farnsworth (1969) to be a successful procedure. Personal experience has indicated that it is not invariably successful, that the results of the operation are unpredictable, and that external sphincterotomy is possibly a preferable method. Ross (1968) stated that external sphincterotomy is a better procedure and the transurethral approach for doing this would appear to be the most satisfactory. Ross *et al.* (1958, 1963) used a punch resectoscope to excise part of the external sphincter, taking tissue in the postero-lateral area of the urethra distal to the verumontanum, and they later modified their technique and used diathermy incision instead at these sites. It is now apparent that simple incision of the external sphincter, using a knife electrode through a resectoscope at one or more sites, is as effective. Currie *et al.* (1970) have divided the external sphincter at 3 and 9 o'clock and have achieved excellent results. Many of the cases reported here had division of the external sphincter at 2, 4, 8 and 10 o'clock, and it is likely that incision almost anywhere except infrolaterally and inferiorly might be satisfactory.

It must, however, be conceded that if only a single incision is made, the possibility of it healing, with some restoration of function, is possible theoretically and it is now apparent that any incision that destroys the integrity of the external sphincter muscle ring is probably an effective procedure, temporarily at least.

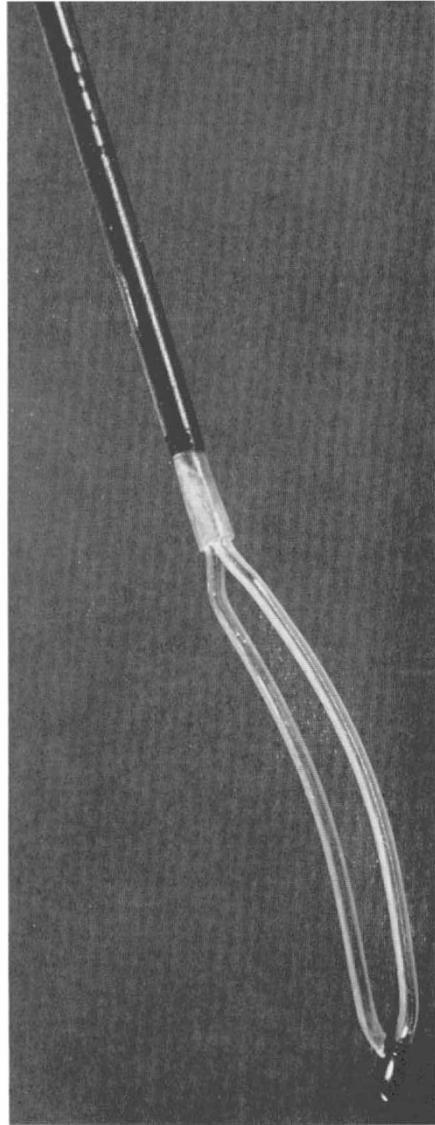


FIG. 2

Knife Electrode. Manufactured by American Cystoscope Makers Incorporated, New York.

The object of this paper is to evaluate the status of external sphincterotomy in relation to the known anatomy of the external sphincter, to examine the effectiveness of the operation in relation to the site of incision of the external sphincter and its value as a primary procedure for the relief of vesical outlet obstruction and as a secondary procedure after transurethral resection of the vesical neck has been carried out.

MATERIALS AND METHODS

All the cases presented here were males who had established neurological disease with vesical outlet obstruction causing retention of urine (Table I).

TABLE I
External Sphincterotomy (Neurological Lesions in 42 Cases)

1. Traumatic = 28		
	Complete	Incomplete
Cervical	11	6
Thoracic	8	1
Lumbar	2	—
2. Disc lesions, Neoplasms, Arterial lesions = 6		
	Complete	Incomplete
Cervical	—	1
Thoracic	2	2
Lumbar	1	—
3. Multiple sclerosis, Arachnoiditis, T.B. Meningitis = 8.		

Because it had been the policy at the National Medical Rehabilitation Centre to treat outlet obstruction primarily by transurethral resection many of them had transurethral resection done prior to external sphincterotomy. In a smaller group external sphincterotomy was tried out as a primary procedure.

External sphincterotomy in all cases was done with an A.C.M.I. knife electrode used through a MacCarthy resectoscope sheath (fig. 2). One, two, three or four longitudinal cuts were made in the external sphincter, dividing the striated muscle fibres transurethrally. Results were later assessed by the patient's ability to void and empty the bladder satisfactorily, as judged by the post-micturition film or residual urine estimation.

RESULTS

The total number of cases treated by external sphincterotomy was 42 (Tables II and III). Of these, 28 had previously had one or more vesical neck resections

TABLE II		
External Sphincterotomy		
Total cases		42
Post-vesical neck resection		28
Successful	26	
Failed	2	
'Primary'		14
Successful	12	
Failed	2	

TABLE III
Age-groups

10-19	20-29	30-39	40-49	50-59	60-69	70-79
5	8	4	9	6	8	2

for the relief of outlet obstruction, and in the remaining 14 cases external sphincterotomy had been done as the primary operation. In 8 cases the operation had been repeated because the patient failed to pass urine satisfactorily after the first procedure, and in the whole series there were 4 failures.

FAILED CASES

Case 1. A male, aged 69, with an incomplete C5 lesion due to spinal artery thrombosis. Three transurethral resections followed by external sphincterotomy failed to relieve the vesical outlet obstruction and diversion by suprapubic cystotomy was eventually necessary. The case was otherwise very complicated and no cause for the failure can be advanced.

Case 2. A male, aged 19, with a complete C5 traumatic lesion, developed outlet obstruction four years after injury. An external sphincterotomy failed, but satisfactory emptying was established after transurethral resection of the bladder neck. It seems likely that, as this was a long-standing case, secondary obstruction was the main cause of the voiding difficulty, and that transurethral resection of the vesical neck would be necessary to relieve obstruction.

Case 3. A male, aged 73, with a complete C5 traumatic lesion, had an external sphincterotomy done six months after injury and passed urine satisfactorily for nine months after this. He then developed outlet obstruction again and was treated with a good result by transurethral resection of the vesical neck and prostate. Prostatic obstruction alone cannot be excluded as a factor in this case.

Case 4. A male, aged 61, with a complete C5 lesion due to spinal artery thrombosis, had a transurethral resection of vesical neck done five months after injury. An external sphincterotomy three months later produced no improvement, but a further transurethral resection one month later produced a satisfactory result. This case indicates that, unless the external sphincterotomy is done early, secondary vesical neck obstruction is likely to dominate the picture.

A study of Table IV gives some indication of the likelihood of outlet obstruction developing in traumatic cases. Of 287 spinal cord injuries admitted during

TABLE IV
Outlet Obstruction in Traumatic Cases

Total cases		287
Vesical neck resection (TUR)		58
Vesical neck resection (TUR) followed by external sphincterotomy		16
Satisfactory	15	
Failed	1	
'Primary' external sphincterotomy		12
Satisfactory	10	
Failed	2	

the years 1961-70 inclusive, transurethral resection was the initial operation in 58 cases, and in 16 of these the operation failed and external sphincterotomy was done. In this group, which consisted of 11 tetraplegics (6 complete, 5 incomplete) and 5 paraplegics (all complete), the results of operation were satisfactory in 15 cases, unsatisfactory in 1 case.

When the policy was changed and external sphincterotomy was done as a primary procedure, of 12 cases so treated the results were satisfactory in 10.

This group of cases is unique in the fact that they were all treated from the time of their injury at the National Medical Rehabilitation Centre, and an endeavour was made in these cases to treat the vesical outlet obstruction at the earliest possible time. The results clearly indicate that about 25 per cent. of cases are not relieved by transurethral resection, but that external sphincterotomy is a very successful procedure when used to relieve outlet obstruction when a transurethral resection of the vesical neck has failed to do so, or when it is used as a primary treatment.

OPERATIVE TECHNIQUE—DIFFICULTIES AND COMPLICATIONS

Using a MacCarthy resectoscope sheath the site of the external sphincter is particularly easily visualised after transurethral resection of the vesical neck, and is seen as a ring contraction just beyond the level of the verumontanum. Its length would appear to be little more than a centimetre. Its location is not quite as easily defined if transurethral resection has not been done, but when the resectoscope sheath is withdrawn beyond the verumontanum its site can usually be determined, and it is quite easily incised using a knife electrode and a cutting current. The muscle is incised through the mucosa and this should be done rather tentatively as it is very easy to cut deeply through the muscle and injure the periurethral venous sinuses and cause severe haemorrhage. Usually some fibres can be seen during incision, and, in fact, in some cases the ring of muscle seems to spring open after the first incision is made. As the incision is deepened the fibres become more sparse and a more smooth appearance is seen—this is a warning that the venous sinus is adjacent. The implication of the work of Manley (1966) and of Sant (1971) indicates that posterior or lateral incisions in the external sphincter may not be as effective as incisions at the roof or on either side of the midline at the roof of the urethra. As the greatest concentration of fibres appears to be at these sites, an attempt was made to investigate this by varying the number of incisions made in different cases.

It seems likely that any incision that interfered with the integrity of the sphincter might give a satisfactory result, provided, of course, that vesical neck hypertrophy or prostatic obstruction was not present. The number of incisions in the external sphincter per case was as follows:

30 cases had 4 incisions,
1 case had 3 incisions,
9 cases had 2 incisions,
2 cases had 1 incision.

Eight cases failed to pass urine satisfactorily after the first external sphincterotomy, and of these, 2 cases had 4 incisions, 1 had 3 incisions, 4 had 2 incisions, and 1 had 1 incision. From these figures it would appear that four incisions are probably

indicated in most cases, but it is of some significance that one case, in whom only one cut was made in the antero-superior part of the sphincter, passed urine satisfactorily and continued to do so. The length of the incision made is largely determined by the endoscopic appearance, but it is probably better to err on the side of making the incision too long rather than too short. A length of about 2 cm. at least should be aimed at. One of the difficulties that arise is that after the first incision is made in the external sphincter its exact location is often difficult to define, and frequently it is better to mark the sites of the incisions by light diathermy before any cut is made. Occasional operative difficulty may occur due to the fact that as the operative incision is being done at the level of the perineal membrane, the resectoscope may 'jump' distally in the urethra and a much longer and deeper incision than intended may be made accidentally. If venous sinuses are entered, severe urethral bleeding may follow. In two cases in this series this happened—both needed transfusion, and one had to be returned to the operating theatre for evacuation of a clot retention. If venous sinus bleeding is caused it is usually controlled satisfactorily by perineal pressure, and if there is any doubt about bleeding a perineal pressure bandage should be applied after the operation is completed. A 22 Foley catheter should always be left in the bladder post-operatively—the bag should usually prevent any urethral haemorrhage from getting into the bladder, but the nursing instructions must include examination for urethral bleeding for some hours post-operatively.

DISCUSSION

The evidence from this study strongly suggests that the primary and most important cause of vesical outlet obstruction is the external sphincter, but the degree to which it causes obstruction may be variable. In lower thoracic and lumbar region lesions it would appear that the external sphincter obstruction can be fairly easily overcome by the expulsive force of the detrusor, but in higher up lesions of the cord the external sphincter obstruction may be greater and the increased expulsive force developed by a hypertrophied detrusor may not be sufficient to overcome the tightly closed external sphincter. External sphincterotomy is therefore the logical first operation indicated for vesical outlet obstruction, but it should be done *before detrusor hypertrophy occurs*. It is particularly indicated in the high, complete, tetraplegic case, and in those cases it should be done as soon as it is established that the lesion is complete and will not recover. It is well known that even with a catheter *in situ* the neurogenic bladder hypertrophies and occasionally vesico-ureteric reflux may occur, and, if external sphincterotomy is not done at an early stage, hypertrophy and vesical neck obstruction will develop and cause a *secondary* obstruction. External sphincterotomy almost always causes incontinence, which usually amounts to some dribbling in between acts of micturition, and this makes very little difference to the tetraplegic or the high-level paraplegic who has no sensation or control, and is certain to have to wear an incontinence device.

The situation is not the same for the paraplegic. Experience here shows that many paraplegic cases, especially those with lower spinal lesions, may pass urine satisfactorily after transurethral resection of the vesical neck, with total continence between acts of micturition. Therefore, in these cases, transurethral resection of the vesical neck seems to be the treatment of choice, and external sphincterotomy

only indicated when micturition is unsatisfactory after adequate transurethral resection. These conclusions are substantiated by the findings of this study. With the exception of one case, all the complete lesions who had external sphincterotomy done had a satisfactory result, and where transurethral resection was unsatisfactory, good results were obtained by secondary external sphincterotomy.

SUMMARY

Forty-two cases of external sphincterotomy are presented, and the indications, operative technique, complications and results are described. Early external sphincterotomy for tetraplegic cases is suggested.

REFERENCES

- ANGOLI, R. R. (1967). *Paraplegia*, **4**, 235.
CURRIE, R. J., BILBISI, A. A., SCHIEDLER, J. C. & BUNTS, R. C. (1970). *J. Urol.* **103**, 64.
DAMANSKI, M. & KERR, A. (1957). *Brit. J. Urol.* **44**, 398.
EMMETT, J. L., ALBERS, D. D. & ANDERSON, R. E. (1951). *J. Urol.* **65**, 36.
EMMETT, J. L. & BEARE, J. B. (1948). *Amer. Med. Ass.* **136**, 1093.
EMMETT, J. L. & DUNN, J. H. (1946). *Surg. Gyn. Obst.* **83**, 597.
KINDER, H. (1969). Personal communication.
LAPIDES, J., SWEET, R. B. & LEWIS, L. W. (1957). *J. Urol.* **77**, 247.
MANLEY, C. B. (1966). *J. Urol.* **95**, 234.
MURNAGHAN, G. F. & FARNSWORTH, R. H. (1969). *Med. J. Austral.* **1**, 623.
ROSS, J. C. (1968). *Paraplegia*, **6**, 176.
ROSS, J. C., GIBBON, N. & DAMANSKI, M. (1958). *Brit. J. Urol.* **30**, 204.
ROSS, J. C., GIBBON, N. & DAMANSKI, M. (1963). *J. Urol.* **89**, 692.
SANT, G. (1971). *Paraplegia* (this issue).
TANAGHO, E. & MILLER, E. R. (1970). *Brit. J. Urol.* **42**, 175.