Papers Read at the Scientific Meeting of the International Medical Society of Paraplegia, Stoke Mandeville Hospital, Aylesbury, England, on 24th and 25th July 1964

THE ARTERIAL BLOOD SUPPLY OF THE HUMAN SPINAL CORD

By Professor G. J. ROMANES, F.R.C.S.
Department of Anatomy, University of Edinburgh

THE arteries of the spinal cord are three major longitudinal vessels: a single, median anterior spinal artery lying at the mouth of the anterior median fissure, and two posterior spinal arteries, one lying at the entry of each row of dorsal rootlets of the spinal nerves. Each of these vessels gives rise to transverse pial branches which may form communications between the main longitudinal vessels and from which perforating branches enter the spinal cord. In addition the anterior spinal artery sends perforating branches into the anterior median fissure and these supply the central regions of the spinal cord.

Each main longitudinal vessel is supplied with blood by a number of feeding vessels arising from the segmental arteries, and it is on these and the anastomoses which the longitudinal vessels form between them that the integrity of the spinal blood supply depends. It is obvious from the short period of absolute anoxaemia which the spinal cord can survive without permanent damage, that there is little possibility for the effective enlargement of a collateral circulation and that survival or death of spinal tissue following injury to the vascular supply must depend on the adequacy of the channels remaining intact. It is of some importance therefore, to determine which of the features of this blood supply are standard and which are liable to marked variation before attempting to predict the results of injury to different parts of this system.

Table I gives only a general indication of the most usual pattern, but in some cases, especially where the number of feeders to the anterior spinal artery is small,

TABLE I
Size of the Longitudinal Vessels
The diameters given are for fixed vessels

	Maximum	Minimum
Anterior spinal . .	Lumbosacral part Up to 1·2 mm.	T6-T8 or 10 Down to 0·2 mm. or less
Posterior spinal . .	Lumbosacral part Up to 0·8 mm.	T2-T6 or lower Down to 0·1 mm.

this vessel may be large throughout its length. The posterior spinal arteries, however, are always small in the region inferior to the cervical enlargement and may be quite asymmetrical in size.

The anterior and posterior spinal arteries are continuous vessels extending throughout the length of the spinal cord, except in one case where the anterior

spinal artery is missing for a few millimetres between the 6th and 7th cervical segments. In this case there is a very adequate supply to this region by four medium-sized (0·4-0·7 mm.) tributaries between the 5th and 7th cervical segments. In this region the anterior spinal artery is commonly double for a short distance (fig. 4).

Excluding the tributaries from the vertebral arteries, the number of feeding vessels to the anterior spinal artery varies from 2 to 10 and the frequency of each number in the 22 spinal cords studied is shown in Table II.

TABLE II

Number of feeders	2	3	4	5	6	7	8	9	10
Number of spinal cords with each number of feeders .	3	5	3	2	2	3	1	2	1

Thus in 22 spinal cords, 11 had four or fewer feeding vessels. Of these the majority divide into ascending and descending branches which are approximately equal in size, but in the caudal part of the spinal cord their branches are unequal, the caudal branch being the largest (fig. 2).

The distribution of the feeding vessels to the anterior spinal arteries of 22 spinal cords is shown in Figure 1. This shows that the chance of a feeding vessel

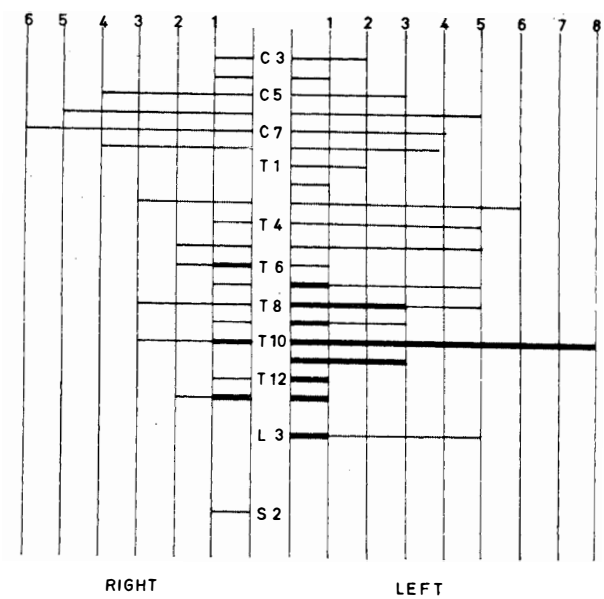

FIG. 1

A diagram to show the position of the feeding vessels to the anterior spinal artery in 22 spinal cords. This gives the frequency of such vessels on each ventral root; the great spinal arteries being indicated by the thick line.

entering on the right or left sides is about equal in the cervical and lumbar regions but there is a marked preponderance on the left in the thoracic region where the majority of these vessels enter. The feeding vessels vary in size from 0·2 to 1·2 mm.

but there is always one particularly large vessel, the great spinal artery, which enters the caudal half of the anterior spinal artery and sends the greater part of its supply caudally (fig. 2). Figure 1 also shows the sites of entry of the great spinal artery the great majority of which are on the ventral roots of T8-T11 on the left side, and all the feeding vessels entering on the left 10th thoracic to 1st lumbar ventral roots are great spinal arteries. In cases where the great spinal artery enters superior to this, there is usually a large feeding vessel to one posterior spinal artery in the region of the 10th thoracic dorsal root.

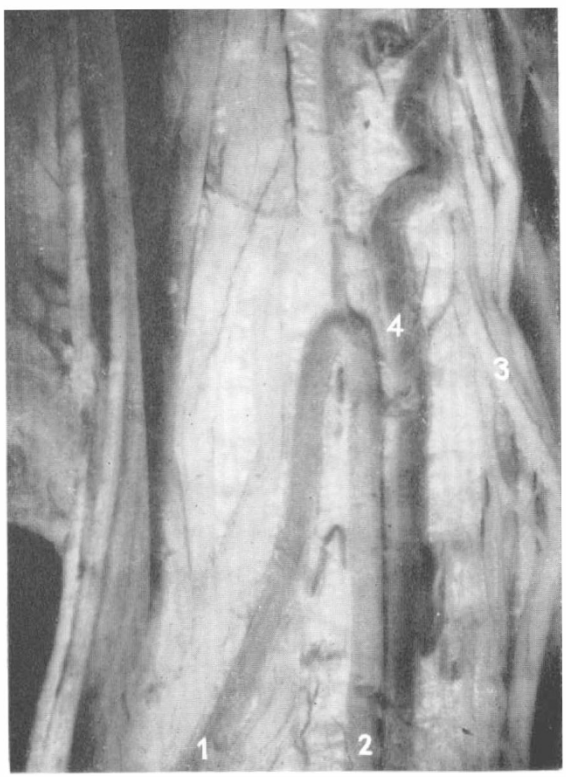

FIG. 2

Photograph of the ventral surface of the spinal cord in the lower thoracic region. (1) Great spinal artery. (2) Anterior spinal artery. (3) Ventral rootlets of spinal nerve. (4) Anterior spinal veins.

Branches of the Anterior Spinal Artery. The branches to the pial surface of the spinal cord are symmetrical and several arise in each segment. All are transverse and some are short, terminating on the anterior column of white matter or reaching the ventral rootlets of the spinal nerves. In each segment there is a larger branch on both sides which passes through or around the corresponding ventral rootlets (figs. 3 and 4), sends small branches on to them and continues over the lateral column of white matter to anastomose with the corresponding posterior spinal artery. These larger vessels, which are scarcely more than 0·1 mm. in

diameter, give rise to longitudinal branches which may anastomose with adjacent arteries among the ventral rootlets (fig. 4) or lie in the region of the ligamentum denticulatum (fig. 5). Such anastomoses do not usually extend for more than a segment or two and are composed of tiny vessels which allow of communications with the posterior spinal artery at various levels.

In the coccygeal part of the spinal cord there is a large communication between the anterior and posterior spinal arteries (fig. 6), and at this level the anterior spinal artery is suddenly reduced to a small vessel on the conus and filum terminale. The

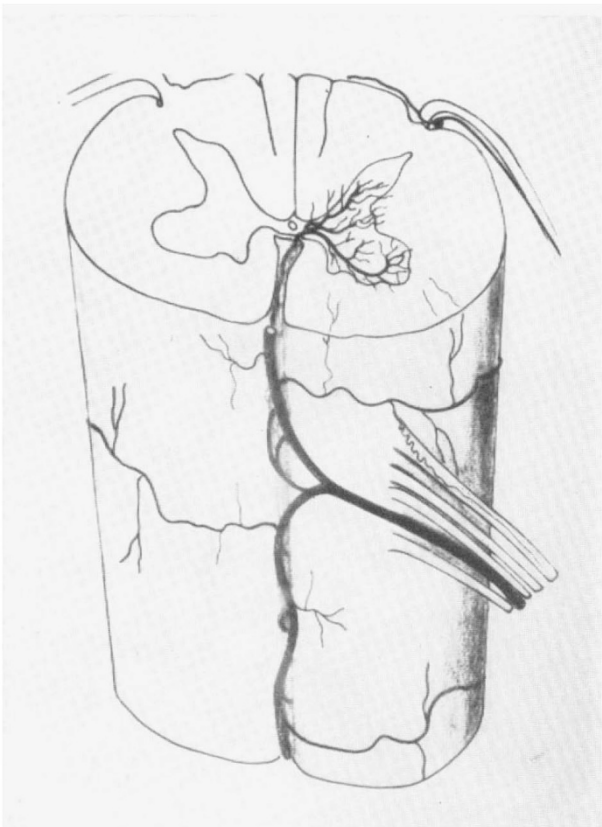

FIG. 3
Diagram to show the arrangement of the anterior spinal artery and its main branches, based on the cervical region.

above communications, which are usually symmetrical but may be present on one side only, form the largest communication between the three longitudinal arteries at any level of the spinal cord. Between the entry of the great spinal artery and the origin of these communicating branches, the anterior spinal artery remains of relatively uniform calibre despite the number of branches arising from it, and this suggests the possibility that the communicating branches transmit blood to the anterior from the posterior spinal arteries, a possibility supported by the fact that large feeding vessels on the dorsal roots in the lumbar region send their major branches caudally.

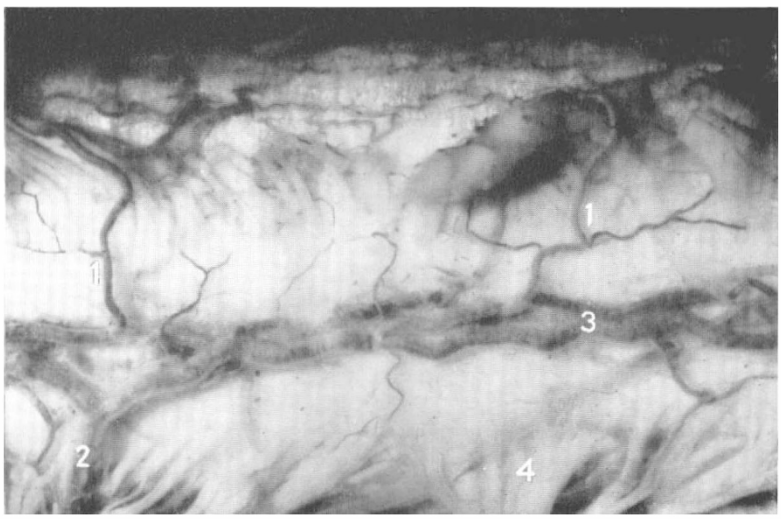

FIG. 4

Ventral view of the cervical region of the spinal cord to show the branches of the anterior spinal artery. (1) Larger pial branches passing through the cut ventral rootlets of two spinal nerves. (2) Feeding vessel to the anterior spinal artery. (3) Anterior spinal artery showing duplication. (4) Ventral rootlets of spinal nerve.

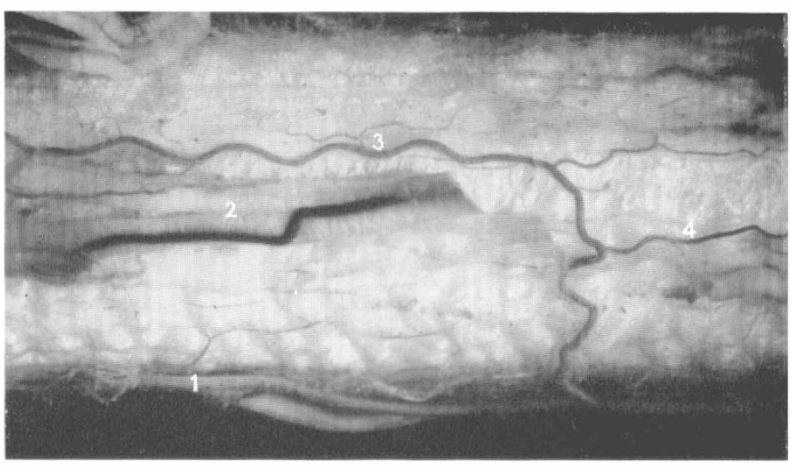

FIG. 5

Photograph of a lateral view of the spinal cord in the cervical region. The ventral and dorsal rootlets of the spinal nerves have been cut and the ligamentum denticulatum removed. (1) Anterior spinal artery. (2) Cut ventral rootlets. (3) Longitudinal anastomotic vessel in the region of the ligamentum deuticulatum. (4) Longitudinal anastomotic branch among the ventral rootlets. Junction with the branches of the posterior spinal artery occurs above and below this level.

The perforating branches of the anterior spinal artery arise at regular intervals and are closely spaced in the lumbo-sacral region and widest apart between the enlargements. These branches are larger than most of those to the pial surface and pass either to the right or the left, branching into the grey matter and reaching the deeper parts of the white matter of the lateral column. In one case a communication was followed through the lateral column of white matter to anastomose with the pial arteries. Several such perforating vessels may arise from a common stem, but corrosion specimens have not shown any evidence of anastomoses between the perforating vessels in the substance of the cord. The longitudinal vessel running parallel to the central canal which is frequently seen in transverse sections of the spinal cord is thought to be formed by branches of the perforating vessels which spread longitudinally but do not anastomose with branches of adjacent perforating vessels.

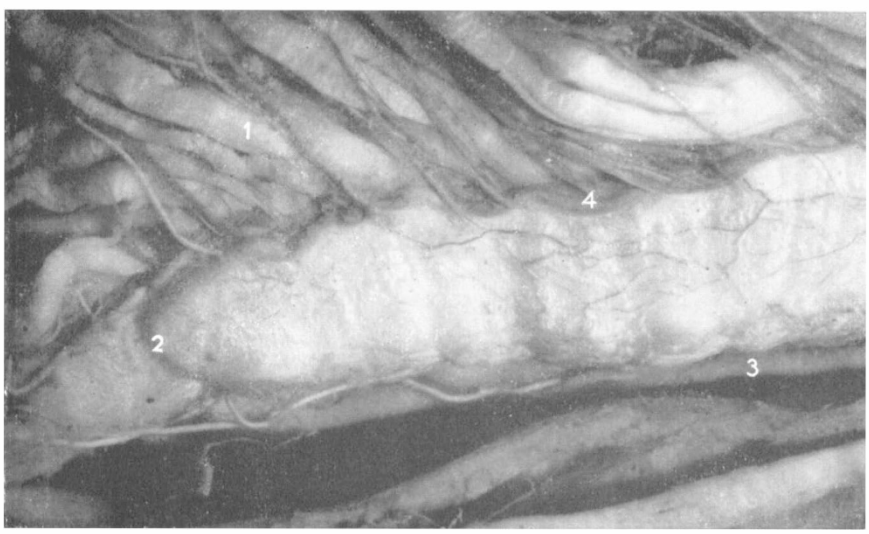

FIG. 6

Lateral view of the sacrococcygeal region of the spinal cord. (1) Dorsal rootlet. Note the number of small feeding vessels to the posterior spinal artery on the dorsal rootlets. (2) Large communication between anterior (3) and posterior (4) spinal arteries.

The posterior spinal arteries receive many more feeding vessels than the anterior spinal (fig. 6). The majority of these are small, 0·1-0·2 mm. in diameter, the number of large tributaries (0·4-0·7 mm.) falling within the range given for the anterior spinal artery with the largest being in the lower part of the spinal cord and not infrequently in the region of the 10th thoracic dorsal root, corresponding with the great spinal artery on the ventral root. There is no preponderance of these feeders on the left though the majority enter in the lower half of the thoracic region and send their major branches caudally.

The branches of the posterior spinal arteries pass anteriorly over the lateral surface of the spinal cord and medially over the posterior columns. The former anastomose with the branches of the anterior spinal artery and the latter form communications with the opposite posterior spinal artery. In the lumbo-sacral and

cervical regions these posterior communications are large and in the former are of sufficient calibre to compensate for any disparity in size of the posterior spinal arteries (fig. 7). In these two regions the main part of the posterior spinal arteries pass on to the dorsal aspect of the spinal cord though elsewhere they lie ventral to the dorsal rootlets.

In an anatomical study of this kind it is not possible to give any clear indication of the pattern of blood flow through the arteries of the spinal cord and it is impossible to give a confident prediction of the position of the feeding vessels or an indication of their numbers in any individual case. It is, however, possible to indicate the dangers inherent in injuries in the region of the 8th to 12th thoracic roots because of the presence of the great spinal and large dorsal root arteries feeding the lumbo-sacral part of the spinal cord in this region. Also it seems obvious that the sequelae of injury to the great spinal artery must depend to some extent on the size of the anterior spinal artery immediately above its point of entry and on the amount of blood entering the posterior spinal arteries through the large number of dorsal root arteries of small calibre throughout this region.

FIG. 7

Dorsal view of the sacral region of the spinal cord. (1) Dorsal rootlet. (2) Posterior spinal vein. (3) Posterior spinal artery; particularly large on this side because of a large feeding vessel entering cranial to this photograph. Note large communications (4) with smaller left posterior spinal artery. (5) Cut dorsal rootlet. (6) Two small feeding vessels to the posterior spinal artery dissected off the cut dorsal rootlets.

SUMMARY

The arrangement of the arteries in 22 spinal cords is described with special reference to the site, distribution and size of the vessels supplying the anterior and posterior spinal arteries, and the branches and communications of the latter arteries. The range of variation is considerable, making it impossible to predict the pattern in any individual, though the majority of feeding vessels to the anterior

spinal artery entering in the thoracic region do so on the left, and one of these, the great spinal artery, supplying a large part of the lumbo-sacral enlargement, most frequently enters on a left thoracic ventral root between the 8th and 11th. The posterior spinal arteries receive a greater number of smaller feeding vessels and may supply blood to the anterior spinal artery through large communications in the region of the conus medullaris. One of them commonly receives a large tributary on the dorsal root of the spinal nerve whose ventral root carries the great spinal artery, but there is no left-sided preponderance of feeding vessels equivalent to that in the anterior spinal artery. Large communications between the posterior spinal arteries are present in both enlargements, particularly the lumbo-sacral.

Résumé

La distribution artèrielle de 22 moëlles épinières est décrite, spécialement en ce qui concerne la topographie, la distribution et le callibre des artères radiculo-médullaires qui suppléent les artères spinales antérieures et postérieures ainsi les branches et communicantes de ces dernières.

Les variations sont considérables, rendant impossible la prédiction de leur topographie dans les cas individuels, cependant la majorité des artères nourricières de la spinale antérieure penètrent la region thoracique du côté gauche et une de celles-ci l'artère radiculaire lombaire, qui irrigue le territoire du renflement lombo-sacré accompagne une racine anterieure, entre la huitième et la onzième dorsales.

Les artères spinales postérieures recoivent un plus grand nombre d'artères nourricières et peuvent irriguer la spinal antérieure grâce au large reseau vasculaire de la règion du cône médullaire. Une de celles-ci reçoit, en general, une large branche nourricière qui accompagne la racine postérieure au même niveau que l'artère radiculaire lombaire, mais il n'y a pas de préponderance à gauche telle qu'on la retrouvé pour la spinale antérieure. D'importantes communications entre les artères postérieures sont presentes au niveau des deux renflements, surtout au niveau du renflement lombo-sacré.

Zusammenfassung

Die Anordnung der Arterien von 22 Präparaten des Rückenmarks wird beschrieben mit besonderer Berücksichtigung der Lokalisation, Verteilung und Grösse der Gefässe, welche die vorderen und hinteren Spinalarterien versorgen, sowie deren Verzweigungen und Verbindungen.

Es bestehen beträchtliche individuelle Verschiedenheiten, die es unmöglich machen, die Anordnung individuell vorauszusagen. Die Mehrzahl der Zubringer-Arterien für die vordere Spinalarterie im Bereich der thorakalen Segmente liegt links. Eine von ihnen, die grosse Spinalarterie, versorgt einen grossen Teil der lumbosakralen Segmente und verläuft auf einer der linken vorderen Thorakalwurzeln zwischen Th. 8 und 11.

Die hinteren Spinalarterien werden von einer grossen Anzahl kleinerer Zubringer-Arterien versorgt und sind manchmal mit der vorderen Spinal-Arterie durch weite Verbindungsgefässe in der Gegend des Conus medullaris verbunden. Eine von ihnen erhält oft einen grösseren Ast an der hinteren Wurzel des Spinalnerven, dessen vordere Wurzel die grosse Spinalarterie begleitet, doch es besteht nicht dasselbe Überwiegen zur linken Seite wie bei der vorderen Spinalarterie.

Weite Verbindungen bestehen zwischen den beiden hinteren Spinalarterien an beiden Anschwellungen des Marks, besonders an der lumbosakralen.

Discussion

WOLMAN, L. (*England*) asked Professor Romanes a question about the vascular supply. He had shown them beautiful pictures of the arteries and veins but had not gone into any details of capillary distribution. It was usually said that the grey matter was very much more vascular in the capillary distribution than the white. He wondered if Professor Romanes would like to enlarge on that aspect of the vascular supply.

ROMANES, G. J. (*Scotland*) thought the answer to that was Yes. The grey matter was much more vascular in capillary veins than the white matter.

WOLMAN, L. (*England*) said he was particularly interested in the difference between anterior and posterior horns, where they had the concentration of nerve cells. Did the capillary network correlate with the increased number of nerve cells? Was there any difference?

ROMANES, G. J. (*Scotland*) replied that if one took the actual density of nerve cells the density would be in the anterior horn, in areas where there were big motor cells taking up a great deal of room. In the posterior horn the density of nerve cells was quite high. If one counted these they were higher in the posterior horn in the intermediate region than they were in the lateral part of the anterior horn in the lumbar enlargement. What was interesting was the fact that the tip of the posterior horn was supplied from the posterior spinal vessels, while one had the remainder of the grey matter supplied from the perforating branches of the anterior spinal artery but, where they joined, there was no evidence of junction; there must be anastomosis of capillary fields, because there was no break that one could see, and yet on injecting one vessel one filled one territory and on injecting the other one filled another territory.

WOLMAN, L. (*England*). It looked the same in both anterior and posterior horn?

ROMANES, G. J. (*Scotland*). Agreed. He had not done actual measurements of density. Horn Cragie had done quite a lot of this at one time, measuring the lengths of capillaries in a given volume of grey and white matter, but as far as he could recall the figures did not seem to show any difference.

THE PATHOLOGY OF VASCULAR DISORDERS OF THE SPINAL CORD

By J. TREVOR HUGHES, M.D.
The Radcliffe Infirmary, Oxford

THE spinal cord has one of the most complex blood supplies of any part of the body and it is necessary to understand some of its complexity before turning to the problem of its vascular disorders. At this meeting we have been fortunate in hearing Professor Romanes' excellent account of the anatomy of the spinal cord vascular supply. Reflecting on the complicated pattern of blood supply I should like to pick out the features that have a special importance in the pathology of vascular disorders of the spinal cord:

1. The multiplicity of feeding sources into the spinal arterial system. This forms a powerful reserve of arterial supply immune except to interruption at specially vulnerable places.
2. The dependence on a moderate number of tributary arteries of inconstant position and which are relatively so large that the other tributaries may be interrupted with impunity.
3. The strict division into anterior and posterior spinal artery territories which supply two-thirds and one-third of the cross-sectional area respectively.
4. The absence of significant anastomosis between anterior and posterior spinal artery circumferentially around the cord. (But the anterior spinal