



OPEN Predictive factors for dissection-free sentinel node micrometastases in early oral squamous cell carcinoma

Takashi Matsuzuka¹✉, Kiyooki Tsukahara², Seiichi Yoshimoto³, Kazuaki Chikamatsu⁴, Akihiro Shiotani⁵, Isao Oze⁶, Yoshiko Murakami⁷, Takeshi Shinozaki⁸, Yuichiro Enoki⁹, Shinichi Ohba¹⁰, Daisuke Kawakita¹¹, Nobuhiro Hanai¹², Yusuke Koide¹³, Michi Sawabe¹², Yusuke Nakata¹⁴, Yujiro Fukuda¹⁵, Daisuke Nishikawa¹⁶, Gaku Takano¹⁷, Takahiro Kimura¹⁸, Keisuke Oguri¹⁹, Hitoshi Hirakawa²⁰ & Yasuhisa Hasegawa¹

This sentinel node (SN) biopsy trial aimed to assess its effectiveness in identifying predictive factors of micrometastases and to determine whether elective neck dissection is necessary in oral squamous cell carcinoma. This retrospective study included 55 patients from three previous trials, with positive SNs. The relationship between the sizes of the metastatic focus and metastasis in non-sentinel node (NSN) was investigated. Four of the 55 largest metastatic focus were isolated tumor cells, and the remaining 51 were ranged from 0.2 to 15 mm, with a median of 2.6 mm. The difference of prevalence between 46 negative- and 9 positive-NSN was statistically significant with regard to age, long diameter of primary site and number of cases with regional recurrence. In comparing the size of largest metastatic focus dividing the number of positive SN, with metastatic focus range of < 3.0 mm in one-positive SN group, there were 18 (33%) negative-NSN and no positive-NSN. Regarding prognosis, 3-year overall survival rate of this group (n = 18) and other (n = 37) were 94% and 73% ($p = 0.04$), and 3-year recurrence free survival rate of this group and other were 94% and 51% ($p = 0.03$), respectively. Absolutely a further prospective clinical trial would be needed, micrometastases may be defined as solitary SN metastasis with < 3.0 mm of metastatic focus, and approximately 33% of neck dissections could be avoided using these criteria.

¹Department of Head and Neck Surgery - Otorhinolaryngology, Asahi University Hospital, 3-23 Hashimoto-cho, Gifu 500-8523, Japan. ²Department of Otorhinolaryngology Head and Neck Surgery, Tokyo Medical University, Tokyo, Japan. ³Department of Head and Neck Surgery, National Cancer Center Hospital, Tokyo, Japan. ⁴Department of Otolaryngology Head and Neck Surgery, Gunma University School of Medicine, Maebashi, Japan. ⁵Department of Otolaryngology Head and Neck Surgery, National Defense Medical College, Tokorozawa, Japan. ⁶Division of Cancer Epidemiology and Prevention, Aichi Cancer Center Research Institute, Nagoya, Japan. ⁷Department of Diagnostic Pathology, Nagoya Medical Center, Nagoya, Japan. ⁸Department of Head and Neck Surgery, National Cancer Center Hospital East, Kashiwa, Japan. ⁹Department of Head and Neck Oncology / Ear, Nose and Throat, Saitama Medical University International Medical Center, Saitama, Japan. ¹⁰Department of Otorhinolaryngology, Juntendo University Graduate School of Medicine, Tokyo, Japan. ¹¹Department of Otorhinolaryngology, Head and Neck Surgery, Nagoya City University Graduate School of Medical Sciences, Nagoya, Japan. ¹²Department of Head and Neck Surgery, Aichi Cancer Center Hospital, Nagoya, Japan. ¹³Department of Otolaryngology Head and Neck Surgery, Japan Community Health Care Organization Chukyo Hospital, Nagoya, Japan. ¹⁴Department of Otorhinolaryngology, Shiga University of Medical Science, Otsu, Japan. ¹⁵Department of Otolaryngology Head and Neck Surgery, Kawasaki Medical School, Kurashiki, Japan. ¹⁶Department of Otorhinolaryngology, Kindai University Nara Hospital, Nara, Japan. ¹⁷Department of Otorhinolaryngology, Nagoya City University West Medical Center, Nagoya, Japan. ¹⁸Department of Otolaryngology - Head and Neck Surgery, Nara Medical University, Kashihara, Japan. ¹⁹Department of Otorhinolaryngology, Konan Kosei Hospital, Konan, Japan. ²⁰Department of Otorhinolaryngology, Head and Neck Surgery, University of the Ryukyus Faculty of Medicine, Okinawa, Japan. ✉email: tmtzk@hosp.asahi-u.ac.jp

Elective neck dissection (END) is recommended as a treatment strategy for early oral squamous cell carcinoma (OSCC). It aims to prevent metastasis to the cervical lymph nodes, thus improving the chance of survival. Although END has low morbidity and mortality, the former is inevitable owing to the nature of the procedure; moreover, a large number of such unnecessary procedures are performed¹. Sentinel node (SN) biopsy has been explored in clinical trials as a tool for the management of early OSCC, which may help avoid unnecessary ENDs². In Japan, a national multi-facilities group was organized in 2009 to acquire insights on SN navigation surgery and its viability for OSCC. Briefly, radioisotope scanning, by itself or in combination with indocyanine, was used to detect SNs. These were examined with multi-slice frozen section analysis intraoperatively; patients with positive SNs underwent one-stage or backup neck dissection procedures.

In the clinical pathology of breast cancer, the volume of metastasis in the lymph node can be fit into one of three categories: isolated tumor cells (ITC), micrometastasis, and macrometastasis. Treatment guidelines depend on how each case is classified. In contrast, there is no pathological classification for head and neck cancer, and clinical treatment is based solely on the presence or absence of lymph node metastases. SN biopsy allows assessment of lymph nodes beyond this level, which may, in turn, allow for early detection of micrometastases.

Because the properties of the cancerous cells from specific tissues are different, the diagnostic criteria used for breast cancer cannot be applied to oral cancer. We hypothesize that if the status of SN metastases is known early enough, non-sentinel node (NSN) metastases can be avoided. Thus, the present study aimed to investigate the relationship between the status of SN and NSN to assess the effectiveness of SN biopsy for patients with OSCC. The biopsy should be adequate for identifying micrometastasis, thus helping determine non-invasive treatment for micrometastasis when END is unnecessary.

Methods

This retrospective study builds on data from previous phase II (A, B) and phase III (C) trials^{3–5}. Details of the SN detection by radioisotope scanning and SN biopsy are described in the respective reports. A total of 162 cases of SN biopsy were registered (trial A: 42 cases, B: 18 and C: 104). After the biopsy, all 60 of the phase II cases underwent backup neck dissection, and 102 of the phase III cases underwent SN navigation surgery. Of the 162 cases, 62 had pathologically positive SN biopsy results. The size of the primary region and the size of metastatic focus in the positive SNs were additionally registered after reexamination by the Ethical Review Board of the Cancer Center (Feb. 14, 2017/ No. 2017-293). This research has been performed following the relevant guidelines and regulations, including the Declaration of Helsinki. We were unable to re-examine or obtain consent from seven patients. There were four patients in facilities which did not participate in this supplementary study, and three patients whose measurement of metastatic focus were inability. Finally, 55 patients (study A; 15 cases, B; 6 and C; 34, mean age: 58.5 ± 16.3 years old) were registered were considered as participants in this study.

Size of metastatic focus was measured microscopically as the maximum longitudinal diameters of positive lesions, based on AE1/3 cytokeratin staining. In cases with more than one-positive SNs, size of largest metastatic focus was taken from the biggest positive lesion. Cases in which metastatic focus were single cells or clusters of cells of < 0.2 mm in diameter, were registered non-numerically as ITC. The metastatic status of NSN in each case was classified as negative or positive NSN, and compared between both groups while considering the number of positive SN. Positive-NSN was defined, during surgery, as the presence of cancer cells within NSN at the level of therapeutic neck dissection. Cases except positive-NSN were considered to have negative-NSN.

The relationship between size of largest metastatic focus and NSN metastasis was investigated. For continuous data, we used the Student's t-test to compare the two groups. We used the Pearson's chi-square test and Fisher's exact test for comparisons of discrete variables. Additionally, the clinical findings and tumor characteristics predicted to have an impact on NSN metastasis were analyzed using logistic analysis. StatView® version 5.0 (SAS Institute Inc., USA) and Microsoft Excel® 2019 (Microsoft Corporation, USA) were used for statistical analyses. A p-value less than 0.05 was considered statistically significant.

Results

Patient's characteristics are listed in Table 1. Four of the 55 largest metastatic focus were ITC, while the size of remaining 51 largest metastatic focus ranged from 0.2 to 15 mm; the median size of largest metastatic focus was 2.6 mm. Of these 55 patients, 9 (16%, mean age: 68.8 ± 7.69 years old) had pathological metastasis in NSNs. Thus, the number of negative-NSN and positive-NSN were considered to be 46 (84%) and 9 (16%), respectively. The difference of prevalence between negative- and positive-NSN was statistically significant with regard to age, long diameter of primary site and number of cases with regional recurrence (Table 1). Extranodal extension was observed in four cases of positive SN, two cases showed negative-NSN whereas the others showed positive-NSN, and size of largest metastatic focus in each case was 4.0, 4.7, 3.0 and 12 mm, respectively. All four had underwent adjuvant radiotherapy.

Comparing the size of largest metastatic focus between negative- and positive-NSN, the median size of largest metastatic focus in the 46 negative-NSN and the 9 positive-NSN was 2.4 mm (ITC: 4 cases, numeric range: 0.2–15 mm) and 3.5 mm (ITC: 1 case, numeric range: 0.9–10 mm), respectively.

If positive SN cases are grouped according to the number of affected nodes, that is, one, two, and three and more, the rates of positive-NSN were 7% (2/27), 25% (5/20) and 25% (2/8), respectively. Figure 1 shows a comparison of size of largest metastatic focus between negative and positive-NSN with respect to the number of positive SN. In one-positive group, there were 25 negative-NSN and two positive-NSN, the median size of largest metastatic focus of negative-NSN was 1.2 mm (ITC: 3 cases, numeric range: 0.2 to 10 mm) and the size of positive NSN were 3.5 and 10 mm. With a size of largest metastatic focus range of 3.0 mm or less in one-positive SN group, there were 18 (33%) negative-NSN and no positive-NSN. Regarding prognosis of this group, one patient died with primary recurrence and the others alive without relapse during the follow-up period. 3-year overall

	Total (n = 55)	Negative-NSN (n = 46)	Positive-NSN (n = 9)	p
Age	58.5 ± 16.3	56.5 ± 16.8	68.8 ± 7.7	0.04
Male/female	40/15	34/12	6/3	NS
Tongue/oral floor/Gingiva	48/6/1	40/6/0	8/0/1	NS
8th pT1/pT2/pT3/pT4	10/22/20/3	9/19/17/1	1/3/3/2	NS
Depth of invasion of primary site	8.91 ± 4.29	8.86 ± 4.15	9.21 ± 5.23	NS
Long diameter of primary site	24.1 ± 9.81	22.3 ± 8.34	33.6 ± 11.7	0.03
Number of SN	3.51 ± 1.47	3.56 ± 1.34	3.22 ± 2.11	NS
Number of positive SN	1.69 ± 0.81	1.63 ± 0.83	2.00 ± 0.71	NS
Size of largest metastatic focus	3.75 ± 3.87	3.72 ± 4.02	3.91 ± 3.16	NS
Number of cases underwent adjuvant radiation	4	3	1	NS
3-year overall survival rate	79.6%	77.8%	88.9%	NS
3-year recurrence free survival rate	64.9%	69.1%	44.4%	NS
3-year regional recurrence free survival rate	81.0%	84.0%	66.7%	NS
Number of cases with regional recurrence	10	6	4	0.05

Table 1. Characteristics of 55 cases with sentinel node metastasis and comparison with and without non-sentinel node metastasis. NSN Non-sentinel node, 8th TNM classification according to 8th edition of the Union for International Cancer Control, SN Sentinel node, NS Not significant.

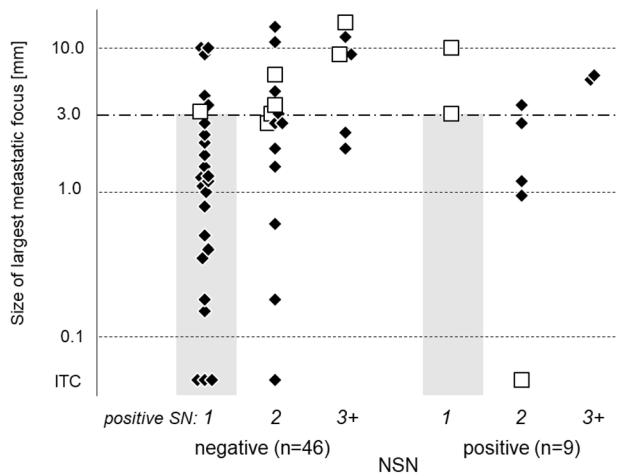


Figure 1. Comparison of size of largest metastatic focus between negative-NSN and positive-NSN dividing the number of positive SN. White square in the figure shows regional recurrence. With a size of largest metastatic focus range of 3.0 mm or less in one-positive SN group (gray area), there were 18 (33%) negative-NSN and no positive-NSN. 3-year overall survival rate of this group and other were 94.1% and 73.0% ($p = 0.04$), and 3-year recurrence free survival rate of this group and other were 94.1% and 51.2% ($p = 0.03$), respectively. NSN Non-sentinel node, SN Sentinel node, ITC Isolated tumor cells, white square Regional recurrence.

survival rate of this group and other were 94.1% and 73.0% ($p = 0.04$), and 3-year recurrence free survival rate of this group and other were 94.1% and 51.2% ($p = 0.03$), respectively.

Discussion

Lymph node metastasis is an important factor in the prognosis of OSCC. In the management of the neck for early OSCC, despite the morbidity associated with END, it is strongly suggested that it be routinely performed to increase both the local control of metastasis and the chances of survival^{6–8}. The purpose of SN biopsy in OSCC is to distinguish cases without metastasis in the SN, in which END is avoidable⁹. SN biopsy is also associated with better postoperative mobility and shoulder function when compared to END¹⁰. According to the European multicentre study, the presence of positive NSN was a factor for poor prognosis¹¹. In western countries, it is recommended that OSCC patients be offered cervical node testing by neither END or SN biopsy. Japan's Pharmaceutical Affairs Law does not allow the use of tracers, such as indocyanine, tilmanocept, and phytate, to detect SN in OSCC patient. We have promoted their acceptance for clinical use in early OSCC and laryngo-pharyngeal squamous cell carcinoma based on domestic multi-institutional joint research¹². Trial A was a phase II trial with 57 OSCC cases, performed to examine the feasibility of SN biopsy with back up END³. Trial B was a phase II trial with 20 OSCC cases, aimed to examine the diagnostic accuracy of indocyanine green (ICG) fluorescence

navigated SNBs in comparison to the radioisotope method⁴. Trial C, a phase III randomized trial including 271 OSCC cases, aimed to compare SN navigation surgery with END, found that the 3-year overall and disease-free survival rates did not differ between the SN navigation surgery (87.9%, 78.7%) and END groups (86.6%, 75.0%). The scores of neck functionality in the SN navigation surgery group were significantly better than those in the END group. SN navigation surgery may replace END without a survival disadvantage and reduce postoperative neck disability in patients with early-stage OSCC⁵.

In the treatment of early breast cancer, SN biopsy has been used routinely for several decades; management strategies based on its results have changed. Formerly, in cases with positive SN, axillary node dissection (AD) used to be a common treatment to reduce the risk of recurrence. Later studies concluded that AD was not recommended routinely because the disease-free survival of patients with positive SNs treated with SN biopsy alone was almost identical to that of patients with negative SN¹³. SN dissection alone and AD also offered similar survival rates¹⁴, whereas lymph node radiation and AD offered similar recurrence and survival rates, with a higher incidence of lymphedema after AD¹⁵. While pathological classification of SN is mentioned as an independent predictor of the involvement of NSN, this depends significantly and exclusively on macro-metastatic SN¹⁶. Some studies suggest that micrometastases and ITC found in the SN are a sign of another, presumably systemic disease, which may not justify an aggressive treatment approach^{17–21}. Micrometastases is considered an important factor for predicting the prognosis and selecting a surgical strategy^{22,23}.

Although the pathological status was defined for breast cancer, it has been reported that the SN status has a significant impact on survival, depending on whether it is negative, ITC, micrometastases or macrometastasis²⁴. The spread of SN biopsy for OSCC was expected to result in an increase in the reports of micrometastases as an artifact of increased testing. Therefore, it is important to prepare for a concept of the micrometastases in the treatment of OSCC. It is assumed that micrometastases for OSCC is the condition when cancer cell infiltration in the SN is too small to extend to the other regional nodes; in these cases, SN lymphadenectomy may be considered as an adequate treatment. To define the tissue characteristics of micrometastases in OSCC could help in the development of minimally invasive treatments²⁵. In the present study, if metastatic focus was small enough and positive SN was not accompanied by positive NSN, hidden NSN metastases tended not to occur. Multiple positive SN was reported as one of the predictive factors for NSN metastasis²⁶. Generally, metastasis in multiple lymph nodes is a factor for poor prognosis. The plural positive SN should also be excluded from a definition of the micrometastases. Our suggestion is for micrometastases to be defined as the condition where SN metastasis is solitary and metastatic focus is less than 3.0 mm, with a margin of error yet to be defined. Using these criteria, approximately 33% of neck dissections in OSCC patients with positive SN could be avoided. To verify this hypothesis, a further prospective clinical trial would be needed. In melanoma primary tumor burden and the distribution in the positive SN whether metastasis foci were subcapsular or parenchymal are also predictive of non-SLN metastases²⁷. In planning and executing further trial, various related to lymph node metastasis, such as the number of lymph nodes examined, should be included.

Data availability

Since patient data cannot be made available, no access details can be provided. Any other requests for information should be made to the corresponding author.

Received: 13 July 2022; Accepted: 10 April 2023

Published online: 15 April 2023

References

1. Harish, K. Neck dissections: Radical to conservative. *World J. Surg. Oncol.* **3**, 21 (2005).
2. Calabrese, L. *et al.* Role of sentinel lymph node biopsy in oral cancer. *Acta Otorhinolaryngol. Ital.* **26**, 345–349 (2006).
3. Miura, K. *et al.* Sentinel node biopsy for oral cancer: A prospective multicenter phase II trial. *Auris Nasus Larynx* **44**, 319–326 (2017).
4. Yokoyama, J. *et al.* Long term-follow-up multicenter feasibility study of ICG fluorescence-navigated sentinel node biopsy in oral cancer. *Mol. Clin. Oncol.* **13**, 41 (2020).
5. Hasegawa, Y. *et al.* Neck dissections based on sentinel lymph node navigation versus elective neck dissections in early oral cancers: A randomized, multicenter, and noninferiority trial. *J. Clin. Oncol.* **39**, 2025–2036 (2021).
6. Capote, A. *et al.* Elective neck dissection in early-stage oral squamous cell carcinoma—Does it influence recurrence and survival?. *Head Neck* **29**, 3–11 (2007).
7. Nieuwenhuis, E. J. *et al.* Lymphoscintigraphy and ultrasound-guided fine needle aspiration cytology of sentinel lymph nodes in head and neck cancer patients. *Recent Results Cancer Res.* **157**, 206–217 (2000).
8. D’Cruz, A. K. *et al.* Elective versus therapeutic neck dissection in node-negative oral cancer. *N. Engl. J. Med.* **373**, 521–529 (2015).
9. Matsuzuka, T. *et al.* Usefulness of sentinel node navigation surgery in the management of early tongue cancer. *Auris Nasus Larynx* **41**, 475–478 (2014).
10. Murer, K., Huber, G. F., Haile, S. R. & Stoeckli, S. J. Comparison of morbidity between sentinel node biopsy and elective neck dissection for treatment of the n0 neck in patients with oral squamous cell carcinoma. *Head Neck* **33**, 1260–1264 (2011).
11. Gurney, B. A. *et al.* Implications of a positive sentinel node in oral squamous cell carcinoma. *Head Neck* **34**, 1580–1585 (2012).
12. Yoshimoto, S. *et al.* Sentinel node biopsy for oral and laryngopharyngeal squamous cell carcinoma: A retrospective study of 177 patients in Japan. *Auris Nasus Larynx* **39**, 65–70 (2012).
13. Takei, H. *et al.* Current trends of sentinel lymph node biopsy for breast cancer—A surgeon’s perspective. *Breast Cancer* **14**, 362–370 (2007).
14. Giuliano, A. E. *et al.* Effect of axillary dissection vs no axillary dissection on 10-year overall survival among women with invasive breast cancer and sentinel node metastasis: The ACOSOG Z0011 (Alliance) randomized clinical trial. *JAMA* **318**, 918–926 (2017).
15. Donker, M. *et al.* Radiotherapy or surgery of the axilla after a positive sentinel node in breast cancer (EORTC 10981–22023 AMAROS): A randomised, multicentre, open-label, phase 3 non-inferiority trial. *Lancet Oncol.* **15**, 1303–1310 (2014).
16. Fournier, K., Schiller, A., Perry, R. R. & Laronga, C. Micrometastasis in the sentinel lymph node of breast cancer does not mandate completion axillary dissection. *Ann. Surg.* **239**, 859–863 (2004) (**discussion 863**).

17. Youssef, M. M. G., Cameron, D., Pucher, P. H., Olsen, S. & Ferguson, D. The significance of sentinel lymph node micrometastasis in breast cancer: Comparing outcomes with and without axillary clearance. *Breast* **30**, 101–104 (2016).
18. Apple, S. K. Sentinel lymph node in breast cancer: Review article from a pathologist's point of view. *J. Pathol. Transl. Med.* **50**, 83–95 (2016).
19. Nasser, I. A. *et al.* Occult axillary lymph node metastases in “node-negative” breast carcinoma. *Hum. Pathol.* **24**, 950–957 (1993).
20. Solà, M. *et al.* Complete axillary lymph node dissection versus clinical follow-up in breast cancer patients with sentinel node micrometastasis: Final results from the multicenter clinical trial AATRM: 048/13/2000. *Ann. Surg. Oncol.* **20**, 120–127 (2013).
21. Houvenaeghel, G. *et al.* Impact of completion axillary lymph node dissection in patients with breast cancer and isolated tumour cells or micrometastases in sentinel nodes. *Eur. J. Cancer* **67**, 106–118 (2016).
22. Märkl, B. *et al.* Prognostic significance of histologically detected lymph node micrometastases of sizes between 0.2 and 2 mm in colorectal cancer. *Int. J. Colorectal Dis.* **28**, 977–983 (2013).
23. Loong Chong, C. Y., Mirbagheri, N., Harris, M. & Fox, J. Sentinel node micrometastases in breast cancer: A survey of Australian and New Zealand breast surgeons. *ANZ J. Surg.* **82**, 766–767 (2012).
24. Broglie, M. A., Haerle, S. K., Huber, G. F., Haile, S. R. & Stoeckli, S. J. Occult metastases detected by sentinel node biopsy in patients with early oral and oropharyngeal squamous cell carcinomas: Impact on survival. *Head Neck* **35**, 660–666 (2013).
25. Matsuzuka, T. *et al.* Attempting to define sentinel node micrometastasis in oral squamous cell carcinoma. *Fukushima J. Med. Sci.* **66**, 143–147 (2020).
26. Den Toom, I. J. *et al.* Additional non-sentinel lymph node metastases in early oral cancer patients with positive sentinel lymph nodes. *Eur. Arch. Otorhinolaryngol.* **274**, 961–968 (2017).
27. Palve, J. *et al.* Sentinel node tumor burden in prediction of prognosis in melanoma patients. *Clin. Exp. Metastasis.* **37**, 365–376 (2020).

Acknowledgements

This study was performed in line with the principles of the Declaration of Helsinki. Approval was granted by the Ethical Review Board of the Aichi Cancer Center (Feb. 14, 2017/ No. 2017-293).

Author contributions

Study concept and design: T.M. and Y.H.; acquisition of data: T.M., K.T., S.Y., K.C., A.S., I.O., T.S., Y.E., S.O., N.H., T.K., and Y.M.; analysis and interpretation of data: T.M., I.O. and Y.H.; statistical analysis: T.M. and Y.H.; drafting of the manuscript: T.M., and Y.H.; manuscript review: all authors.

Funding

This study was supported by a Health and Labor Sciences Research Grant for Clinical Cancer Research (H21-Gannrinshou-Ippan-016 and H24-Gannrinshou-Ippan-006), and by JSPS KAKENHI Grant Number JP21K09620. This study was supported by physicians, nurses, medical technicians, and research staff at the participating institutions. We thank the patients and their families for their participation in the trial. We would like to thank Editage (www.editage.com) for English language editing.

Competing interests

The authors declare no competing interests.

Additional information

Correspondence and requests for materials should be addressed to T.M.

Reprints and permissions information is available at www.nature.com/reprints.

Publisher's note Springer Nature remains neutral with regard to jurisdictional claims in published maps and institutional affiliations.



Open Access This article is licensed under a Creative Commons Attribution 4.0 International License, which permits use, sharing, adaptation, distribution and reproduction in any medium or format, as long as you give appropriate credit to the original author(s) and the source, provide a link to the Creative Commons licence, and indicate if changes were made. The images or other third party material in this article are included in the article's Creative Commons licence, unless indicated otherwise in a credit line to the material. If material is not included in the article's Creative Commons licence and your intended use is not permitted by statutory regulation or exceeds the permitted use, you will need to obtain permission directly from the copyright holder. To view a copy of this licence, visit <http://creativecommons.org/licenses/by/4.0/>.

© The Author(s) 2023