nature reviews endocrinology

https://doi.org/10.1038/s41574-023-00926-0

Consensus statement

Check for updates

Management of phaeochromocytoma and paraganglioma in patients with germline *SDHB* pathogenic variants: an international expert Consensus statement

David Taïeb[1], Svenja Nölting[2,3], Nancy D. Perrier[4], Martin Fassnacht[5], Jorge A. Carrasquillo[6], Ashley B. Grossman[7,8], Roderick Clifton-Bligh[9], George B. Wanna[10], Zachary G. Schwam[10], Laurence Amar[11,12], Isabelle Bourdeau[13], Ruth T. Casey[14], Joakim Crona[15], Cheri L. Deal[16], Jaydira Del Rivero[17], Quan-Yang Duh[18], Graeme Eisenhofer[19], Tito Fojo[20,21], Hans K. Ghayee[22,23], Anne-Paule Gimenez-Roqueplo[11,24], Antony J. Gill[25,26], Rodney Hicks[27], Alessio Imperiale[28], Abhishek Jha[29], Michiel N. Kerstens[30], Ronald R. de Krijger[31,32], André Lacroix[33], Ivica Lazurova[34], Frank I. Lin[35], Charlotte Lussey-Lepoutre[11,36], Eamonn R. Maher[14], Ozgur Mete[37], Mitsuhide Naruse[38,39], Naris Nilubol[40], Mercedes Robledo[41,42], Frédéric Sebag[43], Nalini S. Shah[44], Akiyo Tanabe[45], Geoffrey B. Thompson[46], Henri J. L. M. Timmers[47], Jiri Widimsky[48], William J. Young Jr[49], Leah Meuter[50], Jacques W. M. Lenders[47] & Karel Pacak[29]

Abstract

Adult and paediatric patients with pathogenic variants in the gene encoding succinate dehydrogenase (SDH) subunit B (*SDHB*) often have locally aggressive, recurrent or metastatic phaeochromocytomas and paragangliomas (PPGLs). Furthermore, *SDHB* PPGLs have the highest rates of disease-specific morbidity and mortality compared with other hereditary PPGLs. PPGLs with *SDHB* pathogenic variants are often less differentiated and do not produce substantial amounts of catecholamines (in some patients, they produce only dopamine) compared with other hereditary subtypes, which enables these tumours to grow subclinically for a long time. In addition, *SDHB* pathogenic variants support tumour growth through high levels of the oncometabolite succinate and other mechanisms related to cancer initiation and progression. As a result, pseudohypoxia and upregulation of genes related to the hypoxia signalling pathway occur, promoting the growth, migration, invasiveness and metastasis of cancer cells. These factors, along with a high rate of metastasis, support early surgical intervention and total resection of PPGLs, regardless of the tumour size. The treatment of metastases is challenging and relies on either local or systemic therapies, or sometimes both. This Consensus statement should help guide clinicians in the diagnosis and management of patients with *SDHB* PPGLs.

A full list of affiliations appears at the end of the paper. e-mail: karel@mail.nih.gov

Sections

Introduction

Methods

Health-care environment

Initial and preoperative work-up for patients and affected first-degree relatives

Evaluation for surgery and treatment interventions of patients with *SDHB* PPGL

SDHB PPGLs, regardless of the location

Surveillance of *SDHB* PPGL

Locoregional treatment for recurrent *SDHB* PPGL

Systemic treatment for advanced and/or metastatic *SDHB* PPGL

Conclusion

Introduction

The adrenal medulla is the main hormonal unit of the autonomic nervous system and it arises from neural crest-derived Schwann cell precursors. The Schwann cell precursors migrate along the preganglionic autonomic fibres until they reach their final destination[1,2].

Although most phaeochromocytomas occur sporadically, most sympathetic paragangliomas are driven by germline pathogenic variants. In 2000, Baysal et al. described the first paraganglioma syndrome related to a deficiency in succinate dehydrogenase (SDH, which is part of the mitochondrial tricarboxylic acid cycle) activity due to germline *SDHD* (encoding SDH complex subunit D) pathogenic variants[3]. This major discovery represented the first unequivocal genetic link between a mitochondrial defect and phaeochromocytomas and paragangliomas (PPGLs). Subsequent associations between the tricarboxylic acid cycle, mitochondria and PPGLs were confirmed by identifying other pathogenic variants encoding the B[4], C[5] and A[6] SDH subunits. Collectively, these tumours belong to the cluster 1 subgroup of PPGLs and are mainly characterized by a pseudohypoxic phenotype (that is, hypoxia-inducible factor stabilization despite a normal oxygen supply).

The *SDHB* pathogenic variants have an estimated disease penetrance of 20–30% by the age of 65 years[7]. For the purposes of clarity and brevity, in this Consensus statement, we use the term 'pathogenic' to refer both to variants that are known to be pathogenic and those that are likely to be pathogenic[8]. Among patients with *SDHB* pathogenic variants who develop PPGL (syndrome type 4), 70–80% of tumours are sympathetic (mainly extra-adrenal) paragangliomas[9]. Head and neck paragangliomas (HNPGLs) and anterior mediastinum paragangliomas, almost all derived from the parasympathetic nervous system, are often solitary tumours that occur in only 20–30% of patients with *SDHB* pathogenic variants[10]. The coexistence of sympathetic and parasympathetic paragangliomas within one patient is rare (<3%) and multifocal disease is observed in only 20% of patients with *SDHB* mutations[11].

However, the recurrence rate of *SDHB* PPGLs is high[12]. These tumours are also at high risk of aggressive behaviour, with at least 30% of patients developing metastatic disease[13–20] and a predisposition to developing other tumours, such as gastrointestinal stromal tumours, renal cell carcinoma and pituitary tumours[7,21–23] (Table 1).

Patients with *SDHB* PPGLs present with increases in plasma and/or urine levels of noradrenaline, predominantly of its metabolite normetanephrine. Importantly, an elevation of dopamine levels, and particularly of its metabolite 3-methoxytyramine, is often also observed[24].

Considering the complex landscape of management options for PPGL arising within the context of *SDHB* pathogenic variants, the current Consensus statement seeks to assist physicians in navigating the clinical decision-making process for the treatment of patients with an existing PPGL. The initial screening and follow-up of patients with asymptomatic *SDHB* pathogenic variants have been addressed in another international Consensus statement[25].

Methods

The Consensus statement project included three chairpersons (D.T., J.W.M.L. and K.P.) and one project manager (L.M.). The project was initiated in June 2021, with the establishment of the steering and rating groups. The steering group comprised eight members (R.C.-B., N.D.P., G.B.W., Z.G.S., A.B.G., M.F., J.A.C. and S.N.), and the rating group members included the remaining co-authors of the Consensus statement, except for the chairpersons. All the steering and rating group members participating in the development of the Consensus statement are experts in PPGL and represent a variety of countries, practice settings and disciplines (endocrinology, internal medicine, oncology, surgery, radiotherapy, radiology, nuclear medicine, clinical and molecular genetics, otolaryngology, clinical chemistry, and pathology). The participants were chosen because of their long-term expertise and recognition in the field of PPGL or their subspecialty.

The first meeting with the steering group was held in August 2021. During the meeting, the steering group members were asked to conduct their own literature searches in PubMed (US National Library of Medicine) using the proposed search strategies with controlled vocabulary MeSH terms and keywords for the condition of interest and section topic (Supplementary Table 1). The search was limited to articles published after 2000, with the possibility of adding specific landmark publications published before 2000. During the screening of results, articles were excluded if they were animal studies, case reports, case series or were not published in English. The steering group members were requested to perform a review and critical analysis of the available literature to draft relevant graded recommendations using the Grading of Recommendations Assessment, Development, and Evaluation (GRADE) framework for each thematic area, which was supported by a concise paragraph detailing the most relevant supporting evidence (including references, figures and tables).

In August 2022, the rating group members received proposed recommendations with evidence and supplementary tables but without ratings of the strength of grading and quality of evidence. Each member of the rating group voted on whether they agreed or disagreed with the narrative forms of the recommendations (strongly agree, agree, neither agree nor disagree, disagree, strongly disagree, and do not know), and then rated the strength of the proposed grading (grade 1 represents strong and grade 2 represents weak) and the quality of the evidence using GRADE. For each recommendation, the quality of evidence was rated as very low, low, moderate or high[26]. They could also leave further comments or suggestions about why they agreed or disagreed or why they did not make any ratings (for example, lack of expertise in a specific topic) with the proposal (optional, not required).

The results of the responses from the members of the rating group were presented to the members of the steering and rating groups during two meetings (26 September 2022 and 6 October 2022). During these meetings, any discordance between the rating and steering groups was discussed to reach a consensus on the phrasing of the recommendations and grades regarding the strength of the proposal and quality of the evidence. After this initial period, two additional rounds of voting were conducted with the rating group using Google Forms. Three additional virtual meetings (2 December 2022, 14 December 2022 and 30 January 2023) were conducted with members of the rating and steering groups to reach a consensus. After the last meeting, the chairpersons and project manager drafted a final version of the guidelines and sent the manuscript with supplementary files to all members of the steering and rating groups for final review and approval.

Health-care environment

- **R1. We recommend that all major treatment and management decisions of patients with *SDHB* PPGLs should be carried out in an expert, interdisciplinary team conference to optimize care** (Grade 1, very low).

The management and treatment of patients with *SDHB* PPGLs pose a challenge to clinicians in many disciplines. These tumours are heterogeneous and can manifest in many organs with high rates of recurrence, local aggressive growth and metastasis over time.

Table 1 | Characteristics of paraganglioma syndrome type 4 (*SDHB*)[7,28,47,120,138,182–190]

Category	Characteristic	Data
Genetics and disease penetrance	Types of germline *SDHB* pathogenic variants	Nucleotide substitutions (73%, for example, missense 44%); other variants (for example, 27%, frameshift indels 17%, large deletions or duplications 6%)
	Frequency of germline *SDHB* pathogenic variants in patients with PPGLs	5–10%
	Disease penetrance at age 65 years	20–30% (more common in male than female individuals)
Clinical and biochemical presentation	Age at first diagnosis of PPGL (carriers and index)	30–35 years
	Proportion of patients with PPGL who are symptomatic at presentation	84%
	Proportion of patients with non-functional sympathetic PPGLs	5–10%
	PPGL locations	Extra-adrenal sympathetic paragangliomas (thoracic, abdominal and pelvic): ~60%; phaeochromocytoma: ~20%; HNPGLs: ~20–30%
	Associated tumours	RCC, <5%; pituitary adenoma, <1%; GIST, <1%
	PPGL multifocality	20%
	Biochemical phenotype	Noradrenergic or dopaminergic
Tumour behaviour	Local invasion at first surgery	5–10%
	Synchronous metastases at first PPGL surgery	20–25%
	Lifetime risk of metastases	35–40%
Imaging	Morphological and functional imaging modalities	CT, MRI and [^{68}Ga]DOTA-SSA PET–CT

CT, computed tomography; GIST, gastrointestinal stromal tumour; HNPGL, head and neck paraganglioma; PET, positron emission tomography; PPGL, phaeochromocytoma and paraganglioma; RCC, renal cell carcinoma; SSA, somatostatin analogues.

Most specialists across various disciplines have limited experience in this area of *SDHB* PPGLs and, therefore, international experts in this committee are convinced that an interdisciplinary discussion of management decisions in patients with *SDHB* PPGLs is an optimal approach. This approach also facilitates personalized tailoring of management in specific clinical situations, including plans for individualized surveillance and follow-up[9,27]. However, this recommendation cannot be supported by evidence from well-designed clinical studies because such studies do not exist. Therefore, management decisions based on discussions in an interdisciplinary team with expertise in *SDHB* PPGLs are required to potentially achieve the most favourable outcomes for patients.

Initial and preoperative work-up for patients and affected first-degree relatives

- **R2. We recommend that patients with *SDHB* PPGLs should, in the first instance, undergo clinical assessment and measurement of plasma levels of metanephrines and 3-methoxytyramine (if available) or urinary levels of metanephrines as well as anatomical and functional whole-body imaging; the same assessment should be undertaken if an operation is planned** (Grade 1, moderate).
- **R3. We recommend that adult patients with *SDHB* PPGLs should, on diagnosis, receive whole-body imaging with either magnetic resonance imaging (MRI) or computed tomography (CT) (head, neck, thorax, abdomen and pelvis) and somatostatin receptor positron emission tomography–CT (SSTR PET–CT) imaging** (Grade 1, moderate).
- **R4. We recommend that paediatric patients with *SDHB* PPGLs should, on diagnosis, undergo whole-body MRI (head, neck, thorax, abdomen and pelvis) and SSTR PET–CT, with sedation when necessary. A regular CT scan can be added on an individual basis** (Grade 1, low).

Identifying germline *SDHB* pathogenic variants[8,28] in approximately 10% of all patients with PPGLs[29] has important management implications. At presentation, up to 25% of patients with these variants have synchronous primary tumours and the lifetime risk of developing metastases is 35–40% in any patient with these tumours[11,30–39] (Table 1). Therefore, a comprehensive diagnostic evaluation is essential to plan appropriate treatments (Supplementary Table 2a and Supplementary Table 2b).

Preoperative diagnosis of germline *SDHB* pathogenic variants is ideal but is generally limited to those with a positive family history or a high index of suspicion (that is, young age (<40 years old) of onset, locally invasive sympathetic PPGL often marked by [^{18}F]-fluorodeoxyglucose uptake, tumour multifocality mainly arising from sympathetic paraganglia, presence of metastasis, and an absence of syndromic features to otherwise suggest von Hippel–Lindau syndrome, multiple endocrine neoplasia type 2 or neurofibromatosis type 1). Even for patients whose *SDHB* pathogenic variant is discovered at the initial screening or following initial surgery, it is still valuable to follow the same screening advice for preoperative or postoperative staging (or re-staging) as well as to detect any future new tumours or metastases.

The majority of *SDHB* phaeochromocytomas and sympathetic paragangliomas are associated with increased levels of normetanephrine or 3-methoxytyramine as measured by liquid chromatography with tandem mass spectrometry, with plasma analyses being more accurate than urine-based measurements[40,41]. Plasma concentrations of normetanephrine should be considered positive at any level above the

normal range[40,42]. Although high plasma levels of normetanephrine are uncommon in *SDHB* HNPGLs, at least one-third of patients with these tumours have elevated plasma levels of 3-methoxytyramine[43].

Imaging should extend from the skull base to the pelvis and include MRI or CT in adults and MRI in children. Several MRI protocols have been described[30,33], and diffusion-weighted imaging, in particular, has high sensitivity even for small *SDHB* thoraco-abdominal and pelvic paragangliomas[44]. Magnetic resonance angiography has excellent sensitivity for HNPGLs and can differentiate small tumours from small vascular branches, particularly by reformatting along the axis of the carotid bifurcation to detect small carotid or vagal paragangliomas[45]. In general, CT is performed with contrast enhancement but potential allergy to the contrast medium should be considered as should substantial renal dysfunction. For MRI, the toxicity of contrast media is low but there might be situations in which it can be omitted. For example, for the follow-up of a single lesion in terms of size parameters, rapid-sequence non-contrast-enhanced MRI has been recommended[30].

CT is less costly than MRI and is particularly useful for perioperative planning due to its very high resolution. CT is also preferred by most surgeons who are trained in cross-sectional interpretation. To limit cumulative ionizing radiation exposure in children, as already described, MRI is preferred over CT; however, CT might still be very valuable for perioperative planning or detailed staging before deciding on any systemic therapy. Thus, avoidance of radiation should not lead to inappropriate management or sub-optimal precise localization of some specific lesions (for example, in the lungs). Paediatric MRI generally requires specific radiological expertise.

The advent of SSTR-targeted PET (performed either as PET–CT or PET–MRI) has superseded other PET radiopharmaceuticals or SSTR scintigraphy for the detection of PPGLs in patients with *SDHB* pathogenic variants. However, in some patients, [^{18}F]-fluorodeoxyglucose PET–CT might be more sensitive than other functional imaging modalities[46–48]. Several studies have shown superior diagnostic accuracy for SSTR PET–CT compared with MRI or CT, with false negative findings being very rare[46,49]. Except for abdominal *SDHB* paragangliomas (data are still limited), SSTR PET–CT also has a high sensitivity in imaging of paediatric PPGLs and should be added on an individual basis[50].

- **R5. We recommend that all first-degree relatives of patients with germline *SDHB* pathogenic variants should be offered a referral for genetic counselling** (Grade 1, moderate).

It is necessary for physicians caring for patients with germline *SDHB* pathogenic variants to ensure that all family members at risk are appropriately identified and counselled about the risks of inheriting these variants[51,52]. There are several potential barriers, including the cost of genetic testing, potential genetic discrimination in health insurance or workplaces, reluctance to commit to a lifetime surveillance programme, parental concern about testing children, and negative psychological outcomes[53]. The fairly low-to-moderate penetrance of *SDHB* pathogenic variants means that family history might be sparse for PPGLs, thereby creating a false sense of security. A consensus has been published to guide physicians regarding appropriate surveillance for relatives of patients who are found to be positive for a pathogenic variant on screening[25]. It is important to remember that there are drawbacks to any surveillance programme, including the use of ionizing radiation and the psychological consequences of 'medicalizing' the lives of individuals and subjecting them to long-term anxiety and uncertainty. By contrast, reassuring people that any abnormality will be rapidly diagnosed and treated is paramount and helps with self-assurance and confidence.

There is some evidence that counselling is best provided by genetic counsellors and cancer genetics specialists[53,54]. Their skillset is not only limited to counselling individuals but also involves systematically contacting family members who are at risk, retaining their engagement with surveillance and reproductive counselling that can also be further guided by specialists.

Evaluation for surgery and treatment interventions of patients with *SDHB* PPGL

- **R6. We recommend that all patients with *SDHB* PPGLs should be offered surgical consultation with an experienced surgeon to discuss resection with regards to risk–benefit balance** (Grade 1, low).

Currently, surgery is the only curative treatment for *SDHB* PPGL. If there are no contraindications and the patient is otherwise a good surgical candidate, patients with an *SDHB* PPGL should undergo surgical consultation with a surgeon knowledgeable about the particular tumour type. Both the Endocrine Society Clinical Practice guidelines and the American Association of Endocrine Surgeons guidelines on adrenalectomy fully concur[9,55].

- **R7. We recommend that in patients with large or potentially invasive thoraco-abdominal and pelvic *SDHB* PPGLs, surgical resection via an open approach is preferred for complete vascular and lymphatic dissection and management due to the risk of future local recurrence and metastasis** (Grade 1, very low).

In patients with *SDHB* PPGLs, the goals of surgery are complete tumour resection and avoidance of capsular disruption to minimize the risk of local recurrence and dissemination of tumour cells. Several conditions should be considered when choosing an open rather than laparoscopic operation (Box 1). Usually, large size or worrisome features of invasion prompt the surgeon to consider performing the operation with a manual technique to enable maximal discernment of tension and retraction, which are more difficult to assess with instrumentation. These are a few of the important factors that need to be combined with excellent clinical judgement when deciding on the operative approach[55]. The laparoscopic approach has an obviously easier recovery than open surgery and is superior for cases when the tumour is not large or bulky. Open resection enables broad exposure and, importantly, digital palpation of a tumour, manual retraction, tangible assessment of the surrounding structures and digital assessment of thrombus in outflow vessels or vascular invasion, if necessary. Some manoeuvres, such as precise side clamping of the vena cava, can be more easily performed when multiple or large broad-based veins are present. If the blood supply is copious from a longstanding tumour, the open approach eliminates the scurry that can occur with rapid equipment conversion from a minimally invasive to an open technique and possible repositioning.

These benefits of open procedures can also be important when a re-operation is needed as tissue planes can be considerably distorted in these patients (Box 1). For example, in the case of large or potentially locally invasive thoracic, para-aortic and pelvic paragangliomas, open surgical procedures provide the advantage of tactile feedback from hands-on evaluation of two crucial elements: the assessment of the extent of vascular wall invasion and the identification of an abnormal

Box 1

Considerations for planning of open or laparoscopic operation of *SDHB* PPGL

Criteria for selecting the most appropriate approach

Open operation
- Large size (6 cm or larger)
- Suspected lymph node involvement
- Involvement of large blood vessels
- High risk of bleeding
- Re-operative surgery

Laparoscopic operation
- Small size (4 cm or smaller)
- Clear delineation of surrounding structures
- No obvious blood vessel involvement

PPGL, phaeochromocytoma and paraganglioma.

lymph node (or nodes). Interpreting imaging results and foreseeing potential vessel invasion or adherence is of utmost importance for effective perioperative planning. In selected patients with small tumours (that is, tumours with the largest diameter of <4 cm) and unclear vascular involvement, a minimally invasive approach might be considered. Locally invasive thoracic paragangliomas with vascular involvement might require additional support from a specialized cardiac surgical team.

Compared with open resection, laparoscopic or minimally invasive adrenalectomy has the benefits of faster recovery time, shorter hospitalization and less morbidity[56]. Case reports have demonstrated the effectiveness and safety of such a surgical approach for tumours without vascular invasion and that are small, especially those with the largest diameter <4 cm (ref. 57). Laparoscopy is not recommended for tumours measuring >6 cm because of the high risk of local invasion, recurrence and metastatic spread[12,17,58]. For tumours measuring 4–6 cm, an individualized approach is recommended. If a laparoscopic approach is chosen and adherence to surrounding structures or lymph node involvement is detected intraoperatively, conversion to an open procedure to facilitate en bloc removal is recommended. With regard to the access and approach with a laparoscopic procedure, both the intra-abdominal and retroperitoneal techniques are considered to be equally effective[59].

Because paragangliomas are located close to major vessels, they can present with vascular invasion resulting in metastatic disease. A retrospective study that included 29 patients with retroperitoneal paragangliomas and major blood vessel involvement found a higher overall survival in patients who underwent complete tumour resection than in those who underwent only medical management[60]. This observation is further supported by findings of a high rate of lymph node involvement in a final pathological review in *SDHB* paragangliomas compared with non-*SDHB* paragangliomas[61]. This finding also argues in strong favour of concomitant lymph node dissection for paraganglioma at the initial operation. Therefore, lymphadenectomy might have important prognostic implications. However, there is still no good evidence that lymphadenectomy improves overall survival.

- **R8. We recommend that cortex-sparing resection should not be offered for *SDHB* phaeochromocytomas due to an increased risk of local recurrence and/or metastasis** (Grade 1, low).

Patients with *SDHB* phaeochromocytomas should undergo total adrenalectomy rather than a cortical-sparing procedure, regardless of tumour size. This recommendation is mainly based on the exceedingly low probability of encountering bilateral adrenal phaeochromocytomas in this context, whether synchronously or metachronously[11], such that adrenal insufficiency due to the need to perform surgery on the contralateral adrenal gland is highly unlikely. Total adrenalectomy for *SDHB* phaeochromocytoma is also supported by data showing a higher risk of locoregional recurrence and metastasis than with other phaeochromocytoma subtypes[13–20,62]. Furthermore, technical and anatomic considerations are important because partial adrenalectomy frequently requires direct tumour manipulation and positive margins are not uncommon, which can lead to tumour spillage and intraperitoneal and adrenal bed tumour recurrence[63]. Such local seeding due to fracturing of the adrenal tissue at operation is much less likely with attempts at total resection as is recommended for other potentially metastatic tumours. The 2017 World Health Organization classification described all PPGL as potentially metastatic, noting that the *SDHB* subtype is at an even higher risk than other hereditary forms. Therefore, the risk of leaving potentially malignant cells in situ is high if a cortical-sparing technique is performed. Furthermore, there is no reliable method to predict the metastatic risk of *SDHB* phaeochromocytomas[14,34,64]. However, some characteristics, such as tumour size >4–5 cm (ref. 12,17,19,65) and high plasma levels of 3-methoxytyramine[41], indicate a high risk of aggressive or metastatic behaviour, supporting a more aggressive surgical approach for *SDHB* phaeochromocytoma[9].

- **R9. We recommend that patients with *SDHB* primary PPGL with local invasion, debilitating catecholamine excess or mass effects on adjacent organs or structures should be evaluated for tumour resection with multidisciplinary planning, especially if the tumour is affecting quality of life** (Grade 1, very low).

SDHB PPGL can be large or locally invasive as defined by adherence to the surrounding structures. In this situation, decisions regarding the goals for margin-free resection of the primary tumour or a reasonable chance of complete resection should be carefully evaluated by a multidisciplinary care team to determine whether the benefits of total resection of the primary tumour outweigh the risks. In addition to available technical skills and judgement, the patient's functional status and ability to tolerate surgical intervention, the feasibility of margin-negative resection, and associated morbidity are some of the variables that need to be individualized.

Resection can mitigate or provide complete symptomatic relief from the effect of the mass on the surrounding structures. When margin-negative resection is not possible, the question becomes whether incomplete tumour removal will improve overall survival or whether the risk of complications from the procedure will delay or modify other treatments. This consideration is even more important in the presence of a high primary tumour burden or metastatic disease. A retrospective study of patients with synchronous metastatic disease showed a survival benefit among those who underwent surgery

for a primary tumour compared with those who did not undergo resection[66].

Regarding the excessive production of catecholamines and their related symptom and sign control, some patients might benefit from upfront partial tumour (or tumours) resection to decrease the need for antihypertensive medications. Nevertheless, without leaving the patient free of disease, long-term pharmacological independence is rarely possible. Furthermore, debulking surgery might not have a role in the long-term reduction of tumour burden, except in facilitating systemic or radionuclide therapy treatment shortly after debulking surgery[67].

- **R10. We recommend that a personalized and interdisciplinary cardiovascular management plan should be in place to prevent complications before, during and after surgical resection** (Grade 1, low).

Most patients with *SDHB* PPGLs should be prepared before surgical intervention. No medical treatment is required prior to interventions for patients who are fully asymptomatic (including normal blood pressure) and who have normal plasma or urinary levels of metanephrines as these tumours do not produce catecholamines regardless of their location. Patients with an exclusively dopamine-producing PPGL (as indicated by isolated elevation of plasma levels of 3-methoxytyramine and a lack of hyperadrenergic signs and symptoms) also do not need particular preparations before surgery.

Perioperative cardiovascular management comprises pharmacological treatment of blood pressure and heart rate whilst ensuring adequate hydration and intravascular volume expansion. A well-coordinated management plan should be implemented by clinicians who monitor continuity of care throughout the perioperative period. This approach requires knowledge of the availability of medications and awareness of cardiovascular drug pharmacokinetics and pharmacodynamics in both inpatient and outpatient aspects of care. The use of preoperative antihypertensive medication has been cited as a key factor in decreasing morbidity and mortality to current rates of <3% globally[68].

Although the requirement for preoperative α-adrenoceptor blockade would benefit from more substantial evidence[69], its use before surgery for PPGLs that are producing noradrenaline or adrenaline is recommended by this Consensus statement, and is supported by five international guidelines or consensus documents[9,27,55,67,70]; four of these were conducted under the umbrella of the Endocrine Society, the American Association of Endocrine Surgeons, the European Society of Hypertension and the North American Neuroendocrine Tumour Society.

Several studies have challenged the advice to initiate preoperative α-adrenoceptor blockade in all patients[71,72]. These studies are limited by a retrospective design, allocation bias, lack of stratification and lack of information on medication titration. A meta-analysis of four studies of preoperative α-adrenoceptor blockade versus no blockade[73–76] showed a very low quality of evidence for beneficial effects of α-adrenoceptor blockade. However, there was also no convincing evidence to support abandoning the longstanding practice of preoperative α-adrenoceptor blockade[77]. Therefore, we believe that, at least on medicolegal grounds, the recommendation for preoperative α-adrenoceptor blockade should stand.

The choice of α-adrenoceptor blockade might depend on several factors such as drug availability, cost, team experience and the patient's drug tolerability. In a randomized trial of patients with non-metastatic PPGLs receiving preoperative phenoxybenzamine or doxazosin, phenoxybenzamine was more effective in preventing intraoperative haemodynamic instability, but there were no differences in clinical outcome[78]. Both the Endocrine Society and European Society of Medical Oncology guidelines recommend 7–14 days of α-adrenoceptor blockade before any procedure is performed in patients with PPGL[9,79]. For use of other or additional antihypertensive agents, readers are referred to existing international guidelines[9,27,55,67,70,79].

Coordinating perioperative management requires good communication among multiple specialties, including anaesthesiologists experienced in PPGL resection. Excellent perioperative communication between the surgical and anaesthetic teams and knowledge and understanding of the half-life and effects of pharmacological agents are important factors in the management of intravascular volume, heart rate and blood pressure. Medical preparation should also be performed in patients who undergo any interventional procedure such as radiofrequency ablation, cryoablation or chemoembolization, external beam radiation of the tumour, or any other surgical or non-surgical procedure not directly related to the tumour (such as cholecystectomy or colonoscopy).

- **R11. We recommend that for patients with *SDHB* HNPGL in whom surgical resection is indicated, a decision regarding gross total resection or subtotal resection should be made on an individual basis to avoid profound disability, particularly due to damage to cranial nerves and other structures, with the option of irradiation of the residual tumour. Therapeutic radiation should be considered as an effective treatment option for patients with unresectable disease or unacceptable surgical risk** (Grade 1. low).
- **R12. We suggest considering excision of peri-tumoural lymph nodes in patients with *SDHB* non-tympanic HNPGL already undergoing resection, as it might provide valuable staging information and optimize locoregional control** (Grade 2, very low).
- **R13. We recommend that for patients with *SDHB* jugular, vagal and large carotid paraganglioma undergoing surgery, preoperative angiography with embolization should be considered. Balloon occlusion testing should be considered if internal carotid artery sacrifice with reconstruction is contemplated** (Grade 1, low).

Globally, ~30% of patients with *SDHB* pathogenic variants have HNPGL[80]. Although the overall risk of metastasis is increased in patients with *SDHB* PPGLs (30%, range 20–70%) compared with sporadic cases[10,35–38,81,82], there are data suggesting that *SDHx* HNPGL do not have an increased metastatic risk[83]; thus, metastatic HNPGLs are accordingly rare[18,84,85].

Primary, non-metastatic *SDHB* HNPGLs should be managed conservatively[81] with shared decision-making between the patient and the treatment team. Although gross total resection (macroscopically complete surgery) of *SDHB* HNPGL is considered optimal for locoregional control, in the absence of high-quality survival data, it should not come at the cost of unnecessary major neurological morbidity. Thus, in a patient without preoperative cranial deficits, subtotal resection might be an option, with a plan to irradiate any residual tumour on an individual basis. This decision should also be weighed against an upfront decision to pursue therapeutic radiation as the primary therapy[81,86,87]. The treatment team should always consider active observation, particularly in asymptomatic patients with *SDHB* HNPGL

who have stable or slow-growing tumours in whom intervention might cause unnecessary morbidity. An initial trial of observation also enables appropriate characterization of tumour behaviour.

In patients with preoperative cranial neuropathies ipsilateral to the lesion, a more aggressive approach with a sacrifice of the already defunct nerves might be performed to achieve gross total resection, with an expectant decline in functional status. Cranial nerve status on the contralateral side should also guide decision-making; if the patient has a left recurrent laryngeal nerve or Bell palsy with incomplete recovery, surgical intervention on a right-sided skull base lesion is particularly challenging[81].

In patients with non-tympanic HNPGLs and proven nodal metastases who are undergoing surgical resection, the affected nodal basins should be resected. In the absence of nodal disease on anatomical or functional imaging, one might consider sending off peri-tumoural nodes that are encountered as part of the standard cervical exposure; however, this approach is not supported by solid evidence[10,88,89]. In patients with distant metastatic disease, surgery should be performed only with palliative intent and specific goals in mind.

Preoperative tumour embolization is helpful for all jugular and large or locally invasive carotid body and vagal paragangliomas to minimize blood loss, maintain a clean operative field and visualize critical structures, which augment the probability of gross total resection[90,91]. However, this approach is not without risk as embolization might sometimes cause temporary or permanent cranial neuropathies or multifocal infarcts even with superselective embolization[92]. Migration of particles to the vasa nervorum of the cranial nerves can be limited by using particulate embolic agents, which also dissolve in time and therefore might only lead to temporary weakness[92]. Any patient in whom internal carotid artery sacrifice is considered should undergo preoperative balloon occlusion testing during the same angiographic session; the relevant vascular teams should risk-stratify and be prepared to intervene as necessary[81]. Although balloon test occlusion is widely performed, there is a risk of thrombosis, dissection and infarction[93–95] in addition to an up to 10% false negative rate[86].

Staging resection of lesions at the base of the skull that have considerable intracranial and extracranial components should be considered to minimize the risk of intracranial bleeding and cerebrospinal fluid leakage into the neck.

For patients with unresectable HNPGL or those who are poor surgical candidates, therapeutic radiation (fractionated external beam or stereotactic radiosurgery) should be considered to arrest tumour growth[96,97].

We refer the reader to the supplementary information section for a discussion on individual anatomic subsites and nuances of radiotherapy (Supplementary Box 1).

SDHB PPGLs, regardless of the location

- **R14. We suggest not using any neoadjuvant therapy in *SDHB* PPGL** (Grade 2, very low).

Currently, there are only a few case reports[98–101] describing the potential survival benefit of neoadjuvant treatment with chemotherapy or targeted radionuclide therapy. However, these reports are limited and include very few patients and there are no prospective or retrospective studies on neoadjuvant therapy. Therefore, we do not generally recommend the use of neoadjuvant therapy, possibly except in rare situations. These rare situations include patients who would benefit from resection and/or debulking surgery and patients for whom neoadjuvant treatment could lower the risk of surgery-related comorbidities and complications, including those related to excess levels of catecholamine following surgery. Reducing the risk of recurrent and/or metastatic disease might have other benefits; however, well-designed prospective cohort studies are required.

- **R15. We recommend not using any adjuvant therapy if there is complete resection of all detected PPGL lesions (R0 resection)** (Grade 1, very low).

Patients with *SDHB* PPGLs have a higher risk of locoregional recurrence or metastasis than most patients with PPGLs associated with other pathogenic variants or apparently sporadic PPGLs[12,62,102,103]. However, there is currently no convincing evidence that any therapeutic intervention (for example, radiotherapy or systemic therapy) can considerably reduce the risk of tumour recurrence or metastases after successful removal of a primary or recurrent tumour. Nevertheless, adjuvant radiotherapy can be considered in patients with repeated locoregional recurrences. Furthermore, in patients with incomplete resection of a primary or recurrent tumour or metastatic lesion (or lesions), additive local radiotherapy or targeted radionuclide therapy could be discussed on an individual basis; however, this approach is beyond the scope of this guideline.

Surveillance of *SDHB* PPGL

- **R16. We recommend that for biochemically positive *SDHB* PPGL, a patient's plasma or urinary levels of metanephrines (and, if available, also plasma levels of 3-methoxytyramine) should be measured by 8 weeks postoperatively, and thereafter at least once a year** (Grade 1, very low).
- **R17. We recommend that for all patients after surgery, re-evaluation with the preferred CT or MRI should be performed within 6 months. SSTR PET–CT should also be performed within 6 months after surgery, especially if not performed preoperatively** (Grade 1, low). **If there is no evidence of disease within 6 months, including repeated negative biochemistry, we suggest performing MRI from skull base-to-pelvis at least every 1–2 years to detect new PPGLs, recurrences or metastases. If there is evidence of disease persistence either at the first postoperative scan or positive postoperative biochemistry, more frequent imaging (CT or MRI, with or without SSTR PET–CT) and possible therapeutic interventions might need to be considered. We suggest lifelong follow-up with increasing intervals after long-term tumour stability** (Grade 2, low).
- **R18. We recommend that surveillance of patients with metastases should rely on clinical assessment, biochemical measurement of plasma or urinary levels of metanephrines (and plasma levels of 3-methoxytyramine if available), CT or MRI at 3 months following diagnosis and every 6–12 months in the absence of clear progression. SSTR PET–CT should be performed on an individual basis** (Grade 1, very low).

The frequency of follow-up and serial imaging is guided by the size of the primary tumour (or tumours), tumour location, and the success of the initial surgery or other types of non-surgical interventions. Additional factors to consider include the rate of residual disease progression and the recurrence or occurrence of a new primary or metastatic tumour (or tumours).

In *SDHB* PPGLs, the rate of progression (whether local or represented by metastasis) is often dependent on the initial tumour size

(the rate is higher in tumours >5 cm), location (higher in extra-adrenal tumours), plasma levels of 3-methoxytyramine (higher at elevated 3-methoxtytyramine levels)[41] and high proliferation indices, including Ki-67 and mitotic count. Nevertheless, there is evidence that the Ki-67 index is less useful for predicting PPGL progression on an individual basis than for other types of neuroendocrine tumours[12,104].

In patients who have elevated levels of metanephrines before surgery, repeated testing should be performed by 8 weeks postoperatively, assuming that a patient has fully recovered (that is, they have no pain or surgical complications), to verify whether there is any residual tumour left. If available, measurement of plasma levels of 3-methoxytyramine should also be included. In patients with *SDHB* PPGLs with only a dopaminergic biochemical phenotype, plasma levels of dopamine can be used to monitor successful surgical removal when the measurement of plasma levels of 3-methoxytyramine is not possible[105]. Annual follow-up of biochemical measurements in these patients includes plasma or urine levels of metanephrines and plasma levels of 3-methoxytyramine to detect recurrence or metastatic disease[106]. Regular imaging is most helpful in gauging disease recurrence or progression. Imaging is expected to be frequent in many patients with *SDHB* pathogenic variants, especially those presenting with tumours at an early age (<20 years old) or those with a large primary tumour, so MRI might be the preferred option to minimize radiation exposure (Supplementary Box 2, Supplementary Box 3 and Supplementary Box 4).

The periodicity, intensity and duration of follow-up are contingent on whether any residual tumour is present after resection, with a more relaxed protocol following gross total resection. However, as noted already, the risk factors for recurrence, progression and metastasis are multifactorial, and tumours might appear several years after surgery; therefore, the follow-up parameters will depend as much on the tumour characteristics as on the completeness of resection. Each follow-up appointment for patients with residual disease should include a clinical history, assessment of blood pressure and heart rate, and measurement of plasma or urinary levels of metanephrines. The value of the routine assessment of plasma levels of 3-methoxytyramine has not yet been established; however, many health-care professionals would include this metabolite (Supplementary Box 5).

We recommend routine functional (radionuclide) imaging in the long term. If the residual tumour shows progression on CT or MRI and levels of metanephrines or 3-methoxytyramine begin to rise, these findings might have a role in determining the next therapeutic manoeuvre. Similarly, in patients with no residual tumours but who demonstrate evidence of new tumours, recurrence or metastases on routine CT or MRI, functional imaging might help define the extent of the disease and suggest the possibility of targeted radionuclide therapy. One particular advantage of radionuclide imaging is that it encompasses the entire body, including the head and extremities. Therefore, lesions can be detected at unexpected sites.

For patients with metastatic disease that is not surgically resectable, we recommend an initial 3-month follow-up contrast-enhanced MRI or CT. The scan should be repeated every 6–12 months in the absence of clear progression.

Locoregional treatment for recurrent *SDHB* PPGL

- **R19. We recommend that surgery for locoregional recurrence should be considered in all patients with *SDHB* PPGL who fulfil the following conditions: the time between recurrence and previous surgery is not <6 months, gross total resection seems feasible and there is an acceptable level of surgical risk for the patient. Debulking surgery might be considered on an individual basis in patients with clinically relevant symptoms and signs related to catecholamine excess or mass effects** (Grade 1, very low).

In the absence of randomized trials or large cohort studies analysing different approaches in the surgical management of locoregional recurrence, different treatment options should be discussed on a case-by-case basis. Analogous to the treatment paradigm for primary tumours, it can be assumed that complete resection of any PPGL reduces the risk of recurrent or metastatic disease and catecholamine-related complications. However, if gross total resection is impossible or fails, the benefits and risks of debulking surgery and other local and systemic therapies must be weighed against those of active surveillance. Tumours that rapidly recur or metastasize after radical resection (<6 months interval) are usually very aggressive and require systemic therapy together with local radiation. However, we have to acknowledge that there are no specific studies on this topic in PPGL, so these comments are based on the experience of the authors and from looking at parallels with other malignancies.

- **R20. We recommend local or systemic therapy for patients with symptoms for whom surgery is not possible** (Grade 1, low).
- **R21. We suggest selecting, on an individual and personalized basis, the currently most appropriate local therapy based on tumour localization and behaviour, institutional expertise, the patient's general condition and the patient's preference** (Grade 2, very low).
- **R22. We suggest active surveillance for patients without symptoms who have a low tumour burden or otherwise indolent tumour behaviour, in whom treatment is not currently deemed beneficial** (Grade 2, very low).

Most published evidence on local therapies (for example, radiotherapy, radiofrequency ablation, cryoablation, microwave ablation and chemoembolization) for *SDHB* PPGL is limited. Although radiotherapy is well established for HNPGL, its role in thoracic or abdominal paragangliomas has not been extensively examined. Owing to the slow proliferation rate of many of these tumours, local radiotherapy has been considered ineffective for many years. However, several case reports and small series provide evidence for the efficacy of external beam radiotherapy for aggressively growing primary PPGLs after they have been incompletely resected or for some aggressively growing recurrent tumours[107,108]. Although the administered dose is quite variable, the in-field control growth rate is approximately 75% in most cases. However, unlike typical carcinomas and lymphomas, notable tumour volume reduction following local radiotherapy is uncommon, and most local control is attributed to disease stabilization. As bones are one of the most common sites of metastases in patients with metastatic PPGLs, causing severe pain, spinal cord compression, pathological fractures and/or hypercalcaemia[109], they require special attention. Thus, similar to the situation for many other malignancies, local radiotherapy is the palliative treatment of choice for symptomatic bone metastases. Combination with systemic radionuclide therapy might also be an option, especially in patients with bulky and multiple tumours[107]. However, certain centres advocate pre-emptive treatment of skeletal lesions with interventional radiological techniques (such as cementoplasty, osteosynthesis and/or thermal ablation) to prevent skeletal-related events[110].

Regarding other local therapies, published evidence is even more limited, and most series include <10 patients[111–113]. One of the largest series included local treatment of 31 patients with 123 metastatic PPGLs and reported 42 radiofrequency ablations, 23 cryoablations and four percutaneous ethanol injections[114]. Radiographic local control was achieved in 86% of lesions, and improvement in pain or symptoms and signs of catecholamine excess was found in 92% of patients. Notably, these treatments might have adverse effects, including haemodynamic instability[115]. Furthermore, for liver metastases, especially if numerous and not amenable to the other local therapies described already, embolization or chemoembolization should be considered[116]. If local therapies are not possible (for example, if disease is widespread), systemic therapy should be strongly considered in patients who have symptoms. By contrast, locoregional therapies are usually only indicated in patients without symptoms if they are at high risk of local complications within a short space of time; otherwise, adverse effects might outweigh the benefits.

Active surveillance should be performed for all patients who are asymptomatic. Active surveillance comprises close monitoring using certain examinations and tests in a regular schedule without active antitumour treatment unless there are changes in test results that show a worsening condition. Patients with low tumour burden (for example, involvement of only one or two organs with a limited number of lesions that are usually approximately 1 cm and not found in some critical anatomical areas that might be addressed quickly) or indolent tumour behaviour as shown by stable disease or very slow progression (a few millimetres as the largest diameter for over 6–12 months) are particularly good candidates for active surveillance. Initially, 3–6 months is a suitable interval for active surveillance and, for most patients, this interval could be adapted (6–12 months) over time[12,17,52,117–120].

Systemic treatment for advanced and/or metastatic *SDHB* PPGL

- **R23. We recommend adrenoceptor blockers for the treatment of catecholamine-associated manifestations associated with *SDHB* PPGLs** (Grade 1, low).
- **R24. We recommend that medications that might elicit a catecholamine crisis in catecholamine-secreting *SDHB* PPGLs should be avoided** (Grade 1, very low).

To control the symptoms and signs of catecholamine excess, α-adrenoceptor blockers are widely used as the primary treatment in patients with *SDHB* PPGLs. Furthermore, α-adrenoceptor blockade is recommended in palliative care settings or for chronic treatment in patients with metastatic PPGL who either have hypertension or are otherwise symptomatic from secretory tumours. This approach reduces the frequency of complications from catecholamine excess such as hypertensive emergency, myocardial infarction, arrhythmia, and ischaemic or haemorrhagic stroke[67,121]. The long-term effect of secretory metastatic PPGL on cardiovascular outcomes is not yet known and is currently being investigated in an international multicentre prospective register for PPGL. However, in patients with PPGL, it is also recommended to use α-adrenoceptor blockade with local therapies, such as radiotherapy and microwave ablation, or systemic therapies such as radionuclide therapy, chemotherapy or tyrosine kinase inhibitors[67,121,122]. The aim is to counteract the effects of released catecholamines during tumour destruction due to systemic therapy and to reduce the frequency of catecholamine-induced cardiovascular complications[123–126] (Supplementary Table 3).

- **R25. We recommend active surveillance in patients with very slowly progressing and/or stable *SDHB* PPGLs (usually for over 6–12 months) without relevant symptoms or signs** (Grade 1, low).
- **R26. We recommend chemotherapy with cyclophosphamide, vincristine and dacarbazine as the first-line therapy for rapidly progressive *SDHB* PPGLs or for patients with high visceral tumour burden, or potentially as a second-line therapy if there is rapid progression following other systemic therapies** (Grade 1, low). **In patients in whom cyclophosphamide, vincristine and dacarbazine chemotherapy is not tolerated, not wanted by the patient or if there are contraindications to cyclophosphamide, vincristine and dacarbazine, tyrosine kinase inhibitors (such as sunitinib) or temozolomide can be used as alternative agents with careful evaluation of their adverse effects** (Grade 1, low).
- **R27. We recommend that targeted radionuclide therapy with iodine-131 meta-iodobenzylguanidine ([^{131}I]MIBG) or peptide receptor radionuclide therapy (PRRT) should be considered as a first-line treatment in patients with inoperable *SDHB* PPGL if there is slow-to-moderate progression with moderate-to-high tumour burden. [^{131}I]MIBG or PRRT might be considered for patients with metastatic disease as a first-line treatment if there are signs and symptoms owing to uncontrolled catecholamine excess (such as hypertension, tachyarrhythmias and other cardiovascular events) or if there are mass-related effects** (Grade 1, low).

For patients with rapidly progressing tumours or for patients with a high visceral tumour burden, chemotherapy with cyclophosphamide, vincristine and dacarbazine is the recommended first-line therapy[27,127–136]. Additionally, cyclophosphamide, vincristine and dacarbazine should be the second-line chemotherapy after targeted radionuclide therapy in patients with rapid progression or high visceral tumour burden. Nevertheless, considering radiotherapy-induced immunosuppression, it is currently unknown whether cyclophosphamide, vincristine and dacarbazine chemotherapy or any other therapy that causes bone marrow suppression should be administered shortly after targeted radionuclide therapy. Additional treatment options are discussed in recommendations 26 and 29.

For slow-to-moderate growing tumours with moderate-to-high tumour burden, targeted radionuclide therapy ([^{131}I]MIBG or PRRT) might be considered as a first-line treatment (Table 2). However, when rapid cytoreduction is desirable, cyclophosphamide, vincristine and dacarbazine chemotherapy should be considered initially.

Targeted radionuclide therapy for metastatic and/or inoperable *SDHB* PPGLs is, however, a palliative treatment (Supplementary Table 4). The goals of therapy include mainly stabilization or partial regression of locally aggressive, metastatic, or inoperable tumours and amelioration of symptoms and signs related to catecholamine excess. The natural histories of metastatic, inoperable and locally aggressive PPGLs vary. Although the National Comprehensive Cancer Network guidelines[137] consider [^{177}Lu]DOTATATE as an option for PPGL treatment, it is not an FDA-approved indication. By contrast, high-specific activity [^{131}I]MIBG is approved in the USA by the FDA but does not have approval in other countries. In the USA, health insurance companies typically require peer-to-peer interactions to consider [^{177}Lu]DOTATATE treatment approval on an individual basis and do not guarantee reimbursement. In Europe, the treatment might be eligible for compassionate use under specific circumstances.

Table 2 | Targeted internal radiotherapy: schedules and adverse effects

Radiopharmaceutical	Schedule	Adverse effects
Low specific activity [^{131}I]MIBG	High dose (>444 MBq/kg), meta-analysis[144,147,191]	87% grade 3–4 neutropenia (required growth factor), 83% grade 3–4 thrombocytopenia (required platelet transfusion), myelodysplastic syndrome (4%) (especially together with chemotherapy), hypothyroidism (11–20%), acute respiratory distress syndrome, bronchiolitis obliterans, hypertension, hypogonadism (6.8%); rarely: renal failure, hypertensive crisis (despite α-adrenoceptor blockade), hepatotoxicity; constitutional symptoms, that is, nausea and vomiting
Low specific activity [^{131}I]MIBG	Low–intermediate dose (<9.25 GBq total dose, often repeated)[147,191]	Myelodysplasia (7%), hypothyroidism (11–20%), hypogonadism, myelotoxicity (<19%) grade 3–4; constitutional symptoms are common
High specific activity [^{131}I]MIBG (Azedra)	High dose (~18.5 GBq, usually ×2)[141,147]	Severe and long-term myelosuppression as indicated by haematological adverse effects in 90% of patients, with grade 3–4 adverse effects in 72% of patients, 25% required haematological supportive care, 19% serious adverse effects related to haematological toxicity, 3% lung embolism, 4% myelodysplastic syndrome, 1.5% AML, 1.5% ALL, 3.4% hypothyroidism, 11% worsening hypertension within 24 h, 7% kidney failure or acute renal injury; constitutional symptoms, that is, nausea 76%, all grades
[^{177}Lu]DOTATATE	Typically, 7.4 GBq four times[147]	Adverse events in one meta-analysis (n=234)[191]: 1.4–2.2% myelodysplastic syndrome, 0–1.5% nephrotoxicity, 9.5–11.3% haematological toxicity, all grade 3–4; in another meta-analysis (n=201)[145]: 4% nephrotoxicity, 3% neutropenia, 9% thrombocytopenia, 11% lymphopenia, all grade 3–4; constitutional symptoms, that is, 65% nausea and 53% vomiting, of all grades, commonly related to amino acid pretreatment, 3% renal failure, grade 3–4; incidence for PRRT-related myelodysplastic syndrome 2.5–8.3%

Although toxicity data specifically related to *SDHB* phaeochromocytoma and paraganglioma are limited, it is thought that, with exceptions related to hypertensive issues, other organ toxicities seen in other neuroendocrine neoplasms or in non-*SDHB* PPGL are applicable to *SDHB* PPGL. AML, acute myeloid leukaemia; ALL, acute lymphocytic leukaemia; PRRT, peptide receptor radiotherapy; [^{131}I]MIBG, iodine-131meta-iodobenzylguanidine.

Patients with *SDHB* PPGLs are at increased risk of symptomatic metastases or inoperable (for example, locally aggressive or large) tumours, often with refractory hypertension, tachyarrhythmias or other health-related issues[138,139]. Patients with a history of hypertension and catecholamine production are at increased risk of acute hypertension during or in the first 24 h after infusion of either low specific activity [^{131}I]MIBG or PRRT[140–143]; thus, these patients should be premedicated and monitored during this period. Several studies using targeted radionuclide therapy in PPGLs have reported a high disease control rate (DCR), which is mainly dominated by stable disease or partial response[144,145] (Supplementary Table 4). Many of these studies did not explicitly address the response and outcomes of *SDHB* PPGLs, although some specifically included small numbers of *SDHB* PPGLs and can therefore shed light on this subgroup. Almost no data exist to determine whether there are differences in response rates between *SDHB* PPGLs and non-*SDHB* PPGLs[136,140,146].

Supplementary Table 4 delineates reports of patients treated with [^{131}I]MIBG, [^{90}Y]DOTATATE or [^{177}Lu]DOTATATE, including approximately 56 patients with *SDHB* PPGL, with one additional study containing 20 patients with *SDHB* or *SDHD* PPGL.

- **R28. We recommend that [^{131}I]MIBG or PRRT should be considered based on the radionuclide uptake for each tracer ([^{131}I]MIBG and SSTR PET–CT, respectively), favouring the one that is clearly superior in targeting most or all of the tumour burden. When uptake is similar, medical issues, including bone marrow reserve, highly elevated levels of normetanephrine and other factors, such as availability, should be considered** (Grade 1, low).

As mentioned above, the results of [^{123}I]MIBG and SSTR PET–CT scans determine whether a patient is more likely to benefit from [^{131}I]MIBG or PRRT using somatostatin analogues. Tracer selection is also influenced by whether the visualized lesions are in visceral organs versus bone or lymph nodes, with visceral organs presenting a higher risk of worse outcomes in patients.

[^{131}I]MIBG therapy studies

It is critical to determine the [^{123}I]MIBG uptake pattern before considering its administration as it has low sensitivity for metastatic paragangliomas, particularly those with *SDHB* pathogenic variants[147–151].

Although this modality was introduced in 1984 (ref. 152), most studies had small cohorts and were retrospective[147]. A meta-analysis including participants from all relevant studies irrespective of pathogenic variants showed complete response, partial response and stable disease rates of 3%, 27% and 52%, respectively[144]. Thus, it is critical to determine the MIBG uptake pattern prior to considering [^{131}I]MIBG as it has a rather low sensitivity for paragangliomas, in particular *SDHB*-related PPGLs[147–151]. While there are several case reports using [^{131}I]MIBG therapy in patients with *SDHB*-associated PPGLs, some of which show partial response or stability[98,153], only three therapy trials using [^{131}I]MIBG have explicitly reported on *SDHB* PPGL responses, with a total of 19 patients[107,136,140] (Supplementary Table 4).

In the past, [^{131}I]MIBG with an activity of 0.555–1.850 GBq/mg was used, which is now considered to have a low specific activity[154]. In 2018, high specific activity [^{131}I]MIBG containing 92.5 GBq/mg was approved by the FDA and is the standard commercially available product in the USA. This approach translates to a much lower amount of [^{131}I] being administered than previously, thereby improving the adverse effect profile. A study used high-dose low specific activity [^{131}I]-MIBG in 49 patients with PPGLs, with 12 of 24 patients who underwent genetic testing showing *SDHB* pathogenic variants[140]. A median dose of 444 MBq/kg (range, 222–703 MBq/kg) with a cumulative activity of 18.20–147.67 GBq was administered in one to three cycles. The *SDHB* PPGL group had an improved complete response or partial response of 41.7% compared with 0% in those without the *SDHB* PPGL. However, this improvement did not translate into better progression-free survival (PFS) or overall survival, which might be due to the increased mortality associated with *SDHB* pathogenic variants[14,155,156]. Another study examining patients with metastatic *SDHB* PPGLs indicated that 6 of 15 patients had received [^{131}I]MIBG, but it provided no information

on the administered dose, response to treatment or effect on survival parameters[36].

Phase I and II trials of high specific activity [^{131}I]MIBG (iobenguane I-131, sold under the name Azedra) have been conducted in patients with PPGLs[141,157]. In the phase II study, 68 patients (19 of whom had paraganglioma) were treated with approximately 18.5 GBq per cycle over two cycles. The single administration of ~18.5 GBq, with the exception of a few studies[140,158,159], was much higher than the typical <9.25 GBq used with low specific activity [^{131}I]MIBG[147]. Using at least one single treatment, partial response and stable disease rates of 23% and 69%, respectively, were documented for a total DCR of 92% (Supplementary Table 4). Unfortunately, it is unknown whether any of the patients had *SDHB* pathogenic variants, as is the case in most reports. Furthermore, when comparing the low administered activity in the 9.25 GBq range to the higher activity of ~18.5 GBq typically used for the high specific activity [^{131}I]MIBG, more toxicity is noted with the latter[140,141].

It should be noted that the Azedra regimen requires a dosimetric step that uses a lower administered activity of [^{131}I]MIBG or of [^{177}Lu]DOTATATE; by contrast, no dosimetry is typically performed or required with other approaches. Furthermore, there are no studies that directly compare the efficacy or outcomes of treatment with the approved high specific activity regimen compared with the lower administered activities with repeated cycles.

In 2023, Lantheus Holdings, Inc. announced its intention to discontinue the production of the Azedra. The company stated that manufacturing of Azedra will continue until the first quarter of 2024 to ensure the availability of doses for existing patients.

Peptide receptor radionuclide therapy

Because 89–100% of *SDHB* PPGLs have moderate-to-high expression of SSTR type 2, radiolabelled somatostatin analogues have been used in PRRT for PPGLs[160–162]. A meta-analysis of PRRT in advanced PPGLs, regardless of pathogenic variants (that is, including *SDHB* PPGL and non-*SDHB* PPGL), concluded that there was a beneficial effect using either [^{90}Y]DOTATATE or [^{177}Lu]DOTATATE, with an objective response rate of 25%[145].

PRRT in *SDHB* PPGLs can also have a positive response in terms of improvements in tumour size, biochemistry or hypertension[136,163,164]. In Supplementary Table 4, we included some of the PRRT outcomes in *SDHB* PPGLs using [^{90}Y]DOTATATE or [^{177}Lu]DOTATATE. Typically, a high DCR, comprising patients with a tumour response plus a stable disease rate of 80–100% has been demonstrated in those with subdiaphragmatic lesions[136,143,165–167]. However, it should be noted that these series did not report complete objective tumour responses.

Although some studies have used [^{90}Y]DOTATATE, it is neither approved by the FDA nor readily available, and it has a greater potential for renal toxicity than [^{177}Lu]DOTATATE. Most studies in the USA will continue to use [^{177}Lu]DOTATATE as it is an FDA-approved therapy for gastroenteropancreatic neuroendocrine tumours and is considered for use in PPGLs by the National Comprehensive Cancer Network guidelines[137].

Additional data on the use of [^{131}I]MIBG or PRRT with radiolabelled somatostatin analogues can be found in Supplementary Box 6.

Other systemic therapies

- **R29. We recommend either tyrosine kinase inhibitors (such as sunitinib)** (Grade 1, moderate) **or temozolomide** (Grade 1, low) **as treatment options for slowly or moderately progressing *SDHB* PPGLs that are not eligible for PRRT or [^{131}I]MIBG, or following progression to radionuclide therapy or cyclophosphamide, vincristine and dacarbazine chemotherapy.**

The Working Group on Endocrine Hypertension of the European Society of Hypertension recommended radionuclide therapy for moderately progressive PPGLs as a first-line therapy, either with [^{177}Lu]DOTATATE or [^{131}I]MIBG (either high-specific-activity or conventional low-specific-activity [^{131}I]MIBG)[27]. For a more detailed rationale for the use of these therapeutic modalities, see the targeted radionuclide section.

One retrospective study investigating chemotherapy with temozolomide in PPGLs (n = 14, 10 of whom were patients with *SDHB* PPGL) provided evidence for good response rates and PFS specifically for patients with *SDHB* PPGLs[168]. The reported overall DCR was 80%, and the partial response rate was 33% (according to RECIST (Response Evaluation Criteria In Solid Tumours) 1.1 criteria[169] and PERCIST (Positron Emission tomography Response Criteria In Solid Tumours) 1.0 criteria[170] in non-RECIST-evaluable patients) with all responders being patients with *SDHB* pathogenic variants (overall PFS was 13.3 months, with a significantly longer PFS of 19.7 versus 2.9 months in patients with *SDHB* PPGL versus those with non-*SDHB* PPGLs)[168]. Therefore, temozolomide is one of the recommended first-line or second-line therapies for slowly or moderately progressing *SDHB* PPGLs not eligible for radionuclide therapy or in instances of progression to radionuclide therapy (Fig. 1).

Additionally, hypermethylation and downregulation of the DNA repair enzyme O-6-methylguanine-DNA methyltransferase in *SDHB* PPGLs might increase the susceptibility of *SDHB* PPGLs to temozolomide[171]. Thus, assessment of O-6-methylguanine-DNA methyltransferase hypermethylation might help guide treatment decisions for temozolomide in patients with *SDHB* PPGLs.

Evidence on the efficacy of the tyrosine kinase inhibitor sunitinib in PPGLs[172], including in patients with *SDHB* PPGL, is available from several studies. These include one prospective study (n = 23, five of whom had *SDHB* PPGL)[173] and two retrospective studies (n = 14, eight of whom had *SDHB* PPGL; n = 7, three of whom had *SDHB* PPGL)[174] as well as preliminary data from the first randomized double-blind placebo-controlled phase II (FIRST-MAPPP) trial investigating sunitinib in 78 patients with metastatic PPGLs (32% *SDHB* pathogenic variants: 33% in the sunitinib group and 23% in the placebo group) presented at the European Society of Medical Oncology conference in 2021 (ref. 175). The prospective study showed a DCR of 83% over 3 months (DCR 61% over 6 months) with a response rate of 13% in all patients (overall PFS, 13.4 months)[173]. Ayala-Ramirez et al. described, in their prospective study, a DCR of 57% with a response rate of 21% over 4 months and stable disease of 36% over 6 months (overall PFS 4.1 months)[136,174]. Fisher et al., in their retrospective study, reported a DCR of 100% over 3 months for sunitinib as first-line therapy (median survival until detected progression was 18 months)[136]. The FIRST-MAPPP trial reported a DCR of 35.9% over 12 months and a significantly longer PFS of 8.9 months in the sunitinib group than in the placebo group (3.6 months)[175]. The results of the FIRST-MAPPP trial are unfortunately not yet published in a peer-reviewed journal. So far, sunitinib is the tyrosine kinase inhibitor with the best evidence in patients with PPGLs and is recommended as the second-line or third-line treatment or as first-line if the patient is not eligible for targeted radionuclide therapy (Fig. 1). Axitinib might provide a feasible option for the treatment of progressive advanced PPGLs; some initial results of this approach were presented at the ASCO Annual Meeting in 2015 but have not yet been published.

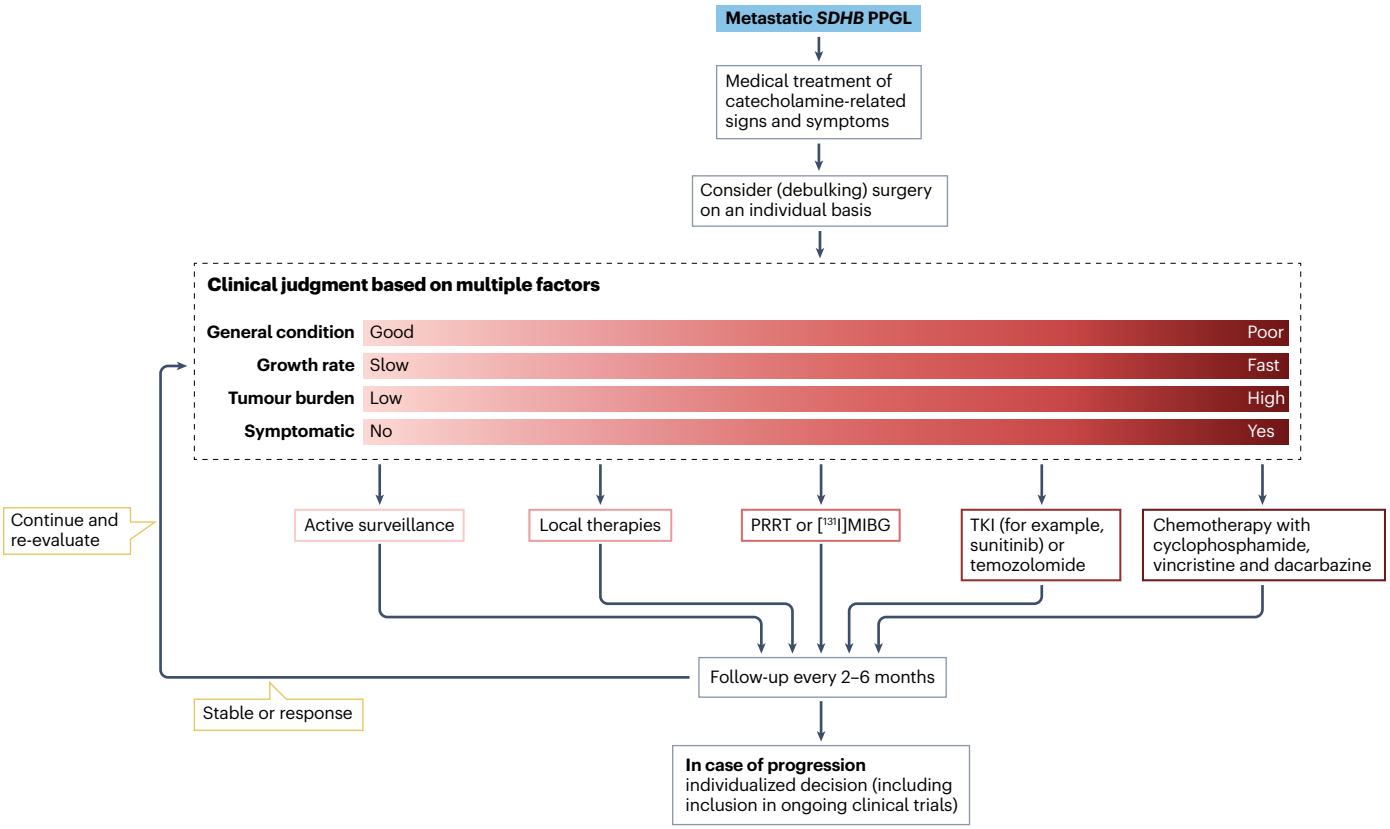

Fig. 1 | Management of metastatic *SDHB* PPGL. This figure shows an algorithm for the treatment of metastatic *SDHB* phaeochromocytoma and paragangliomas (PPGLs). After medical treatment of catecholamine-related signs and symptoms, surgery is considered on an individual basis, depending on several clinical factors that can vary from mild to severe. When considering debulking surgery, note that surgery should be performed if all tumoural lesions can be removed. However, debulking surgery could be considered only in patients with symptoms and signs related to notable catecholamine excess or mass effect. Treatment options depend on the condition of the patient, severity of progression, tumour load and presence of catecholamine-related signs and symptoms. Treatment must be followed up and the patient should be re-evaluated depending on treatment results. Local therapies include radiotherapy, radiofrequency ablation, cryoablation, microwave ablation, embolization, chemoembolization and palliative surgery. [^{131}I]-MIBG, iodine-131 meta-iodobenzylguanidine; PRRT, peptide receptor radionuclide therapy; TKI, tyrosine kinase inhibitor.

At the fifth International Symposium on Pheochromocytoma and Paraganglioma in 2017, promising preliminary data from a prospective study (NCT02302833) investigating the tyrosine kinase inhibitor cabozantinib in patients with PPGLs ($n = 10$, five of whom had *SDHB* PPGL) were presented[176]. The DCR was 90% (all minor or partial responses) over 3 months, 70% over 6 months and 30% over 12 months (PFS 11.1 months), with all five patients with *SDHB* PPGLs showing a partial or minor response.

Two prospective phase II clinical studies investigating an immune checkpoint inhibitor, pembrolizumab, in PPGLs ($n = 9$ and $n = 11$, including one patient with *SDHD* PPGL and two patients with *SDHB* PPGL, respectively) reported DCRs of 75%[177] and 73% (response rate, 9%; 1 *SDHB* PPGL with shrinkage >30%; and overall PFS, 5.7 months)[178]. Further evidence is necessary to confirm the potential efficacy of pembrolizumab in *SDHB* PPGLs. Importantly, we recommend considering inclusion in clinical trials following progression to third-line therapy.

In cases of SSTR positivity on [^{68}Ga]DOTA-SSTR PET–CT and contraindications for other recommended therapies, SSTR treatment (intramuscular long-acting release octreotide 30 mg or subcutaneous lanreotide autogel 120 mg every 2–4 weeks) can be considered on an individual basis given their use in gastroenteropancreatic neuroendocrine tumours. The options include first-line, second-line or third-line therapy in PPGLs with slow progression or, on a case-by-case basis, as maintenance therapy following a good response to SSTR-based radionuclide therapy or chemotherapy[179–181]. However, there are currently no published studies investigating non-radioactive, termed 'cold', SSTR analogues in *SDHB* PPGLs that would enable the provision of any recommendation. One small retrospective study included four patients with PPGL treated with first-line 'cold' SSTR analogues (all progressive at baseline) and showed a very good DCR at 3 months (100%) (median survival until detected progression not reached)[136]. Moreover, SSTR type 2 expression in PPGL is associated with *SDHB* pathogenic variants (as described previously) and is independently related to metastatic disease[162]. This finding further supports the idea of SSTR-guided systemic treatments in *SDHB* PPGLs.

Conclusion

All patients with *SDHB* pathogenic variants should be managed by an expert interdisciplinary team and require excellent clinical and biochemical care as well as modern imaging work-up to screen for

multifocality, recurrence, locoregional spread and metastases. Following initial management, lifelong surveillance is mandatory. Management of metastatic PPGL is complex and therapeutic options might vary across patients depending on several factors (such as general condition, growth rate of the tumours, tumour burden, certain histopathological criteria, and symptoms or signs related to the presence of the tumour itself or catecholamine excess). This Consensus statement should help standardize high-quality care for patients with PPGL who have *SDHB* pathogenic variants.

Published online: 14 December 2023

References

1. Kastriti, M. E. et al. Schwann cell precursors generate the majority of chromaffin cells in zuckerkandl organ and some sympathetic neurons in paraganglia. *Front. Mol. Neurosci.* **12**, 6 (2019).
2. Furlan, A. et al. Multipotent peripheral glial cells generate neuroendocrine cells of the adrenal medulla. *Science* **357**, eaal3753 (2017).
3. Baysal, B. E. et al. Mutations in SDHD, a mitochondrial complex II gene, in hereditary paraganglioma. *Science* **287**, 848–851 (2000).
4. Astuti, D. et al. Gene mutations in the succinate dehydrogenase subunit SDHB cause susceptibility to familial pheochromocytoma and to familial paraganglioma. *Am. J. Hum. Genet.* **69**, 49–54 (2001).
5. Niemann, S. & Muller, U. Mutations in SDHC cause autosomal dominant paraganglioma, type 3. *Nat. Genet.* **26**, 268–270 (2000).
6. Burnichon, N. et al. SDHA is a tumor suppressor gene causing paraganglioma. *Hum. Mol. Genet.* **19**, 3011–3020 (2010).
7. Andrews, K. A. et al. Tumour risks and genotype-phenotype correlations associated with germline variants in succinate dehydrogenase subunit genes SDHB, SDHC and SDHD. *J. Med. Genet.* **55**, 384–394 (2018).
8. Richards, S. et al. Standards and guidelines for the interpretation of sequence variants: a joint consensus recommendation of the American College of Medical Genetics and Genomics and the Association for Molecular Pathology. *Genet. Med.* **17**, 405–424 (2015).
9. Lenders, J. W. et al. Pheochromocytoma and paraganglioma: an Endocrine Society clinical practice guideline. *J. Clin. Endocrinol. Metab.* **99**, 1915–1942 (2014).
10. Taieb, D. et al. Current approaches and recent developments in the management of head and neck paragangliomas. *Endocr. Rev.* **35**, 795–819 (2014).
11. Gimenez-Roqueplo, A. P. et al. Imaging work-up for screening of paraganglioma and pheochromocytoma in SDHx mutation carriers: a multicenter prospective study from the PGL.EVA Investigators. *J. Clin. Endocrinol. Metab.* **98**, E162–E173 (2013).
12. Assadipour, Y. et al. SDHB mutation status and tumor size but not tumor grade are important predictors of clinical outcome in pheochromocytoma and abdominal paraganglioma. *Surgery* **161**, 230–239 (2017).
13. Timmers, H. J. et al. Staging and functional characterization of pheochromocytoma and paraganglioma by ^{18}F-fluorodeoxyglucose (^{18}F-FDG) positron emission tomography. *J. Natl Cancer Inst.* **104**, 700–708 (2012).
14. Turkova, H. et al. Characteristics and outcomes of metastatic SDHB and sporadic pheochromocytoma/paraganglioma: an National Institutes of Health Study. *Endocr. Pract.* **22**, 302–314 (2016).
15. Gimenez-Roqueplo, A. P. et al. Functional consequences of a SDHB gene mutation in an apparently sporadic pheochromocytoma. *J. Clin. Endocrinol. Metab.* **87**, 4771–4774 (2002).
16. Gimenez-Roqueplo, A. P. et al. Mutations in the SDHB gene are associated with extra-adrenal and/or malignant phaeochromocytomas. *Cancer Res.* **63**, 5615–5621 (2003).
17. Schovanek, J. et al. The size of the primary tumor and age at initial diagnosis are independent predictors of the metastatic behavior and survival of patients with SDHB-related pheochromocytoma and paraganglioma: a retrospective cohort study. *BMC Cancer* **14**, 523 (2014).
18. Brouwers, F. M. et al. High frequency of SDHB germline mutations in patients with malignant catecholamine-producing paragangliomas: implications for genetic testing. *J. Clin. Endocrinol. Metab.* **91**, 4505–4509 (2006).
19. Pamporaki, C. et al. Prediction of metastatic pheochromocytoma and paraganglioma: a machine learning modelling study using data from a cross-sectional cohort. *Lancet Digit. Health* **5**, e551–e559 (2023).
20. Rijken, J. A. et al. Increased mortality in SDHB but not in SDHD pathogenic variant carriers. *Cancers* **11**, 103 (2019).
21. Papathomas, T. G. et al. Non-pheochromocytoma (PCC)/paraganglioma (PGL) tumors in patients with succinate dehydrogenase-related PCC-PGL syndromes: a clinicopathological and molecular analysis. *Eur. J. Endocrinol.* **170**, 1–12 (2013).
22. Pasini, B. et al. Clinical and molecular genetics of patients with the Carney-Stratakis syndrome and germline mutations of the genes coding for the succinate dehydrogenase subunits SDHB, SDHC, and SDHD. *Eur. J. Hum. Genet.* **16**, 79–88 (2008).
23. Denes, J. et al. Heterogeneous genetic background of the association of pheochromocytoma/paraganglioma and pituitary adenoma: results from a large patient cohort. *J. Clin. Endocrinol. Metab.* **100**, E531–E541 (2015).
24. Eisenhofer, G. et al. Catecholamine metabolomic and secretory phenotypes in phaeochromocytoma. *Endocr. Relat. Cancer* **18**, 97–111 (2011).
25. Amar, L. et al. International consensus on initial screening and follow-up of asymptomatic SDHx mutation carriers. *Nat. Rev. Endocrinol.* **17**, 435–444 (2021).
26. Atkins, D. et al. Grading quality of evidence and strength of recommendations. *BMJ* **328**, 1490 (2004).
27. Lenders, J. W. M. et al. Genetics, diagnosis, management and future directions of research of phaeochromocytoma and paraganglioma: a position statement and consensus of the Working Group on Endocrine Hypertension of the European Society of Hypertension. *J. Hypertens.* **38**, 1443–1456 (2020).
28. Ben Aim, L. et al. International initiative for a curated SDHB variant database improving the diagnosis of hereditary paraganglioma and pheochromocytoma. *J. Med. Genet.* **59**, 785–792 (2022).
29. Benn, D. E. et al. Bayesian approach to determining penetrance of pathogenic SDH variants. *J. Med. Genet.* **55**, 729–734 (2018).
30. Daniel, E., Jones, R., Bull, M. & Newell-Price, J. Rapid-sequence MRI for long-term surveillance for paraganglioma and phaeochromocytoma in patients with succinate dehydrogenase mutations. *Eur. J. Endocrinol.* **175**, 561–570 (2016).
31. Eijkelenkamp, K. et al. Calculating the optimal surveillance for head and neck paraganglioma in SDHB-mutation carriers. *Fam. Cancer* **16**, 123–130 (2017).
32. Jafri, M. et al. Evaluation of SDHB, SDHD and VHL gene susceptibility testing in the assessment of individuals with non-syndromic phaeochromocytoma, paraganglioma and head and neck paraganglioma. *Clin. Endocrinol.* **78**, 898–906 (2013).
33. Jasperson, K. W. et al. Role of rapid sequence whole-body MRI screening in SDH-associated hereditary paraganglioma families. *Fam. Cancer* **13**, 257–265 (2014).
34. Jochmanova, I. et al. SDHB-related pheochromocytoma and paraganglioma penetrance and genotype-phenotype correlations. *J. Cancer Res. Clin. Oncol.* **143**, 1421–1435 (2017).
35. Martins, R. G. et al. Surveillance of succinate dehydrogenase gene mutation carriers: insights from a nationwide cohort. *Clin. Endocrinol.* **92**, 545–553 (2020).
36. Niemeijer, N. D. et al. The phenotype of SDHB germline mutation carriers: a nationwide study. *Eur. J. Endocrinol.* **177**, 115–125 (2017).
37. Tufton, N., Sahdev, A. & Akker, S. A. Radiological surveillance screening in asymptomatic succinate dehydrogenase mutation carriers. *J. Endocr. Soc.* **1**, 897–907 (2017).
38. Tufton, N., Sahdev, A., Drake, W. M. & Akker, S. A. Can subunit-specific phenotypes guide surveillance imaging decisions in asymptomatic SDH mutation carriers? *Clin. Endocrinol.* **90**, 31–46 (2019).
39. Benn, D. E., Richardson, A. L., Marsh, D. J. & Robinson, B. G. Genetic testing in pheochromocytoma- and paraganglioma-associated syndromes. *Ann. N. Y. Acad. Sci.* **1073**, 104–111 (2006).
40. Eisenhofer, G. et al. Biochemical diagnosis of chromaffin cell tumors in patients at high and low risk of disease: plasma versus urinary free or deconjugated o-methylated catecholamine metabolites. *Clin. Chem.* **64**, 1646–1656 (2018).
41. Eisenhofer, G. et al. Plasma methoxytyramine: a novel biomarker of metastatic pheochromocytoma and paraganglioma in relation to established risk factors of tumour size, location and SDHB mutation status. *Eur. J. Cancer* **48**, 1739–1749 (2012).
42. Saie, C. et al. Screening of a large cohort of asymptomatic SDHx mutation carriers in routine practice. *J. Clin. Endocrinol. Metab.* **106**, e1301–e1315 (2021).
43. Rao, D. et al. Plasma methoxytyramine: clinical utility with metanephrines for diagnosis of pheochromocytoma and paraganglioma. *Eur. J. Endocrinol.* **177**, 103–113 (2017).
44. Tufton, N., White, G., Drake, W. M., Sahdev, A. & Akker, S. A. Diffusion-weighted imaging (DWI) highlights SDHB-related tumours: a pilot study. *Clin. Endocrinol.* **91**, 104–109 (2019).
45. Gravel, G. et al. The value of a rapid contrast-enhanced angio-MRI protocol in the detection of head and neck paragangliomas in SDHx mutations carriers: a retrospective study on behalf of the PGL.EVA investigators. *Eur. Radiol.* **26**, 1696–1704 (2016).
46. Janssen, I. et al. Superiority of [^{68}Ga]-DOTATATE PET/CT to other functional imaging modalities in the localization of SDHB-associated metastatic pheochromocytoma and paraganglioma. *Clin. Cancer Res.* **21**, 3888–3895 (2015).
47. Taieb, D. et al. European Association of Nuclear Medicine practice guideline/Society of Nuclear Medicine and Molecular Imaging procedure standard 2019 for radionuclide imaging of phaeochromocytoma and paraganglioma. *Eur. J. Nucl. Med. Mol. Imaging* **46**, 2112–2137 (2019).
48. Carrasquillo, J. A. et al. Imaging of pheochromocytoma and paraganglioma. *J. Nucl. Med.* **62**, 1033–1042 (2021).
49. Kong, G. et al. The role of ^{68}Ga-DOTA-Octreotate PET/CT in follow-up of SDH-associated pheochromocytoma and paraganglioma. *J. Clin. Endocrinol. Metab.* **104**, 5091–5099 (2019).
50. Jha, A. et al. Superiority of ^{68}Ga-DOTATATE over ^{18}F-FDG and anatomic imaging in the detection of succinate dehydrogenase mutation (SDHx)-related pheochromocytoma and paraganglioma in the pediatric population. *Eur. J. Nucl. Med. Mol. Imaging* **45**, 787–797 (2018).
51. Buffet, A. et al. Positive impact of genetic test on the management and outcome of patients with paraganglioma and/or pheochromocytoma. *J. Clin. Endocrinol. Metab.* **104**, 1109–1118 (2019).
52. Davidoff, D. F. et al. Surveillance improves outcomes for carriers of SDHB pathogenic variants: a multicenter study. *J. Clin. Endocrinol. Metab.* **107**, e1907–e1916 (2022).
53. Raygada, M., King, K. S., Adams, K. T., Stratakis, C. A. & Pacak, K. Counseling patients with succinate dehydrogenase subunit defects: genetics, preventive guidelines, and dealing with uncertainty. *J. Pediatr. Endocrinol. Metab.* **27**, 837–844 (2014).
54. Athens, B. A. et al. A systematic review of randomized controlled trials to assess outcomes of genetic counseling. *J. Genet. Couns.* **26**, 902–933 (2017).

55. Yip, L. et al. American Association of Endocrine Surgeons guidelines for adrenalectomy: executive summary. *JAMA Surg.* **157**, 870–877 (2022).
56. Lee, J. et al. Open and laparoscopic adrenalectomy: analysis of the National Surgical Quality Improvement Program. *J. Am. Coll. Surg.* **206**, 953–959 (2008).
57. Li, J., Wang, Y., Chang, X. & Han, Z. Laparoscopic adrenalectomy (LA) vs open adrenalectomy (OA) for pheochromocytoma (PHEO): a systematic review and meta-analysis. *Eur. J. Surg. Oncol.* **46**, 991–998 (2020).
58. Zelinka, T. et al. Metastatic pheochromocytoma: does the size and age matter? *Eur. J. Clin. Invest.* **41**, 1121–1128 (2011).
59. Dickson, P. V. et al. Posterior retroperitoneoscopic adrenalectomy is a safe and effective alternative to transabdominal laparoscopic adrenalectomy for pheochromocytoma. *Surgery* **150**, 452–458 (2011).
60. Hu, H. et al. En bloc resection with major blood vessel reconstruction for locally invasive retroperitoneal paragangliomas: a 15-year experience with literature review. *World J. Surg.* **41**, 997–1004 (2017).
61. Abadin, S. S. et al. Impact of surgical resection for subdiaphragmatic paragangliomas. *World J. Surg.* **38**, 733–741 (2014).
62. Cui, Y. et al. Local-regional recurrence of pheochromocytoma/paraganglioma: characteristics, risk factors and outcomes. *Front. Endocrinol.* **12**, 762548 (2021).
63. Li, M. L., Fitzgerald, P. A., Price, D. C. & Norton, J. A. Iatrogenic pheochromocytomatosis: a previously unreported result of laparoscopic adrenalectomy. *Surgery* **130**, 1072–1077 (2001).
64. Ricketts, C. J. et al. Tumor risks and genotype-phenotype-proteotype analysis in 358 patients with germline mutations in SDHB and SDHD. *Hum. Mutat.* **31**, 41–51 (2010).
65. Hamidi, O. et al. Malignant pheochromocytoma and paraganglioma: 272 patients over 55 years. *J. Clin. Endocrinol. Metab.* **102**, 3296–3305 (2017).
66. Roman-Gonzalez, A. et al. Impact of surgical resection of the primary tumor on overall survival in patients with metastatic pheochromocytoma or sympathetic paraganglioma. *Ann. Surg.* **268**, 172–178 (2018).
67. Fishbein, L. et al. The North American Neuroendocrine Tumor Society consensus guidelines for surveillance and management of metastatic and/or unresectable pheochromocytoma and paraganglioma. *Pancreas* **50**, 469–493 (2021).
68. Livingstone, M. et al. Hemodynamic stability during pheochromocytoma resection: lessons learned over the last two decades. *Ann. Surg. Oncol.* **22**, 4175–4180 (2015).
69. Berends, A. M. A., Kerstens, M. N., Lenders, J. W. M. & Timmers, H. Approach to the patient: perioperative management of the patient with pheochromocytoma or sympathetic paraganglioma. *J. Clin. Endocrinol. Metab.* **105**, dgaa441 (2020).
70. Taieb, D. et al. Clinical consensus guideline on the management of phaeochromocytoma and paraganglioma in patients harbouring germline SDHD pathogenic variants. *Lancet Diabetes Endocrinol.* **11**, 345–361 (2023).
71. Groeben, H. et al. International multicentre review of perioperative management and outcome for catecholamine-producing tumours. *Br. J. Surg.* **107**, e170–e178 (2020).
72. Buisset, C. et al. Pheochromocytoma surgery without systematic preoperative pharmacological preparation: insights from a referral tertiary center experience. *Surg. Endosc.* **35**, 728–735 (2021).
73. Shao, Y. et al. Preoperative alpha blockade for normotensive pheochromocytoma: is it necessary? *J. Hypertens.* **29**, 2429–2432 (2011).
74. Brunaud, L. et al. Both preoperative alpha and calcium channel blockade impact intraoperative hemodynamic stability similarly in the management of pheochromocytoma. *Surgery* **156**, 1410–1417 (2014).
75. Ulchaker, J. C., Goldfarb, D. A., Bravo, E. L. & Novick, A. C. Successful outcomes in pheochromocytoma surgery in the modern era. *J. Urol.* **161**, 764–767 (1999).
76. Groeben, H. et al. Perioperative Perioperative alpha-receptor blockade in phaeochromocytoma surgery: an observational case series. *Br. J. Anaesth.* **118**, 182–189 (2017).-receptor blockade in phaeochromocytoma surgery: an observational case series. *Br. J. Anaesth.* **118**, 182–189 (2017).
77. Schimmack, S. et al. Meta-analysis of α-blockade versus no blockade before adrenalectomy for phaeochromocytoma. *Br. J. Surg.* **107**, e102–e108 (2020).
78. Buitenwerf, E. et al. Efficacy of α-blockers on hemodynamic control during pheochromocytoma resection: a randomized controlled trial. *J. Clin. Endocrinol. Metab.* **105**, 2381–2391 (2020).
79. Fassnacht, M. et al. Adrenocortical carcinomas and malignant phaeochromocytomas: ESMO-EURACAN Clinical Practice Guidelines for diagnosis, treatment and follow-up. *Ann. Oncol.* **31**, 1476–1490 (2020).
80. Neumann, H. P. et al. Distinct clinical features of paraganglioma syndromes associated with SDHB and SDHD gene mutations. *JAMA* **292**, 943–951 (2004).
81. Lloyd, S., Obholzer, R. & Tysome, J.; BSBS Consensus Group. British Skull Base Society clinical consensus document on management of head and neck paragangliomas. *Otolaryngol. Head Neck Surg.* **163**, 400–409 (2020).
82. McCrary, H. C. et al. Characterization of malignant head and neck paragangliomas at a single institution across multiple decades. *JAMA Otolaryngol. Head Neck Surg.* **145**, 641–646 (2019).
83. Richter, S. et al. Head/neck paragangliomas: focus on tumor location, mutational status and plasma methoxytyramine. *Endocr. Relat. Cancer* **29**, 213–224 (2022).
84. Timmers, H. J., Gimenez-Roqueplo, A. P., Mannelli, M. & Pacak, K. Clinical aspects of SDHx-related pheochromocytoma and paraganglioma. *Endocr. Relat. Cancer* **16**, 391–400 (2009).
85. Rijken, J. A. et al. Nationwide study of patients with head and neck paragangliomas carrying SDHB germline mutations. *BJS Open* **2**, 62–69 (2018).
86. Wanna, G. B. et al. Subtotal resection for management of large jugular paragangliomas with functional lower cranial nerves. *Otolaryngol. Head Neck Surg.* **151**, 991–995 (2014).
87. Manzoor, N. F. et al. Contemporary management of jugular paragangliomas with neural preservation. *Otolaryngol. Head Neck Surg.* **164**, 391–398 (2021).
88. Sethi, R. V., Sethi, R. K., Herr, M. W. & Deschler, D. G. Malignant head and neck paragangliomas: treatment efficacy and prognostic indicators. *Am. J. Otolaryngol.* **34**, 431–438 (2013).
89. Moskovic, D. J. et al. Malignant head and neck paragangliomas: is there an optimal treatment strategy? *Head Neck Oncol.* **2**, 23 (2010).
90. Moore, M. G., Netterville, J. L., Mendenhall, W. M., Isaacson, B. & Nussenbaum, B. Head and neck paragangliomas: an update on evaluation and management. *Otolaryngol. Head Neck Surg.* **154**, 597–605 (2016).
91. Ivan, M. E. et al. A meta-analysis of tumor control rates and treatment-related morbidity for patients with glomus jugulare tumors. *J. Neurosurg.* **114**, 1299–1305 (2011).
92. Gaynor, B. G., Elhammady, M. S., Jethanamest, D., Angeli, S. I. & Aziz-Sultan, M. A. Incidence of cranial nerve palsy after preoperative embolization of glomus jugulare tumors using Onyx. *J. Neurosurg.* **120**, 377–381 (2014).
93. Linskey, M. E. et al. Stroke risk after abrupt internal carotid artery sacrifice: accuracy of preoperative assessment with balloon test occlusion and stable xenon-enhanced CT. *AJNR Am. J. Neuroradiol.* **15**, 829–843 (1994).
94. Tarr, R. W. et al. Complications of preoperative balloon test occlusion of the internal carotid arteries: experience in 300 cases. *Skull Base Surg.* **1**, 240–244 (1991).
95. Mathis, J. M. et al. Temporary balloon test occlusion of the internal carotid artery: experience in 500 cases. *AJNR Am. J. Neuroradiol.* **16**, 749–754 (1995).
96. Suarez, C. et al. Carotid body paragangliomas: a systematic study on management with surgery and radiotherapy. *Eur. Arch. Otorhinolaryngol.* **271**, 23–34 (2014).
97. Suarez, C. et al. Jugular and vagal paragangliomas: systematic study of management with surgery and radiotherapy. *Head Neck* **35**, 1195–1204 (2013).
98. Makis, W., McCann, K., McEwan, A. J. & Sawyer, M. B. Combined treatment with 131I-MIBG and sunitinib induces remission in a patient with metastatic paraganglioma due to hereditary paraganglioma-pheochromocytoma syndrome from an SDHB mutation. *Clin. Nucl. Med.* **41**, 204–206 (2016).
99. Ibuki, N. et al. A pheochromocytoma of urinary bladder treated with neoadjuvant chemotherapy [Japanese]. *Hinyokika Kiyo* **55**, 765–768 (2009).
100. Visani, J. et al. Surgical treatment of metastatic pheochromocytomas of the spine: a systematic review. *J. Integr. Neurosci.* **20**, 499–507 (2021).
101. Bizzarri, N. et al. Peritoneal carcinomatosis from ovarian paraganglioma: report of a rare case and systematic review of the literature. *J. Obstet. Gynaecol. Res.* **44**, 1682–1692 (2018).
102. Amar, L. et al. MANAGEMENT OF ENDOCRINE DISEASE: recurrence or new tumors after complete resection of pheochromocytomas and paragangliomas: a systematic review and meta-analysis. *Eur. J. Endocrinol.* **175**, R135–R145 (2016).
103. Holscher, I., van den Berg, T. J., Dreijerink, K. M. A., Engelsman, A. F. & Nieveen van Dijkum, E. J. M. Recurrence rate of sporadic pheochromocytomas after curative adrenalectomy: a systematic review and meta-analysis. *J. Clin. Endocrinol. Metab.* **106**, 588–597 (2021).
104. Wachtel, H. et al. Predicting metastatic potential in pheochromocytoma and paraganglioma: a comparison of PASS and GAPP scoring systems. *J. Clin. Endocrinol. Metab.* **105**, 4661–4670 (2020).
105. Eisenhofer, G. et al. Biochemical and clinical manifestations of dopamine-producing paragangliomas: utility of plasma methoxytyramine. *J. Clin. Endocrinol. Metab.* **90**, 2068–2075 (2005).
106. Pamporaki, C. et al. Determinants of disease-specific survival in patients with and without metastatic pheochromocytoma and paraganglioma. *Eur. J. Cancer* **169**, 32–41 (2022).
107. Fishbein, L. et al. External beam radiation therapy (EBRT) for patients with malignant pheochromocytoma and non-head and -neck paraganglioma: combination with ^{131}I-MIBG. *Horm. Metab. Res.* **44**, 405–410 (2012).
108. Mesko, S. et al. Spine stereotactic radiosurgery for metastatic pheochromocytoma. *Cureus* **11**, e4742 (2019).
109. Ayala-Ramirez, M. et al. Bone metastases and skeletal-related events in patients with malignant pheochromocytoma and sympathetic paraganglioma. *J. Clin. Endocrinol. Metab.* **98**, 1492–1497 (2013).
110. Gravel, G. et al. Prevention of serious skeletal-related events by interventional radiology techniques in patients with malignant paraganglioma and pheochromocytoma. *Endocrine* **59**, 547–554 (2018).
111. Pacak, K. et al. Radiofrequency ablation: a novel approach for treatment of metastatic pheochromocytoma. *J. Natl Cancer Inst.* **93**, 648–649 (2001).
112. Venkatesan, A. M. et al. Radiofrequency ablation of metastatic pheochromocytoma. *J. Vasc. Interv. Radiol.* **20**, 1483–1490 (2009).
113. Zhang, W. et al. Computed tomography-guided cryoablation for adrenal pheochromocytoma: safety and clinical effectiveness. *Surg. Laparosc. Endosc. Percutan. Tech.* **29**, 409–412 (2019).
114. Kohlenberg, J. et al. Efficacy and safety of ablative therapy in the treatment of patients with metastatic pheochromocytoma and paraganglioma. *Cancers* **11**, 195 (2019).
115. Deljou, A. et al. Hemodynamic instability during percutaneous ablation of extra-adrenal metastases of pheochromocytoma and paragangliomas: a case series. *BMC Anesthesiol.* **18**, 158 (2018).
116. Hidaka, S. et al. Malignant pheochromocytoma with liver metastasis treated by transcatheter arterial chemo-embolization (TACE). *Intern. Med.* **49**, 645–651 (2010).

117. Hescot, S. et al. One-year progression-free survival of therapy-naive patients with malignant pheochromocytoma and paraganglioma. *J. Clin. Endocrinol. Metab.* **98**, 4006–4012 (2013).
118. Hescot, S. et al. Prognosis of malignant pheochromocytoma and paraganglioma (MAPP-Prono study): an ENS@T retrospective study. *J. Clin. Endocrinol. Metab.* **104**, 2367–2374 (2019).
119. Dhir, M. et al. Clinical predictors of malignancy in patients with pheochromocytoma and paraganglioma. *Ann. Surg. Oncol.* **24**, 3624–3630 (2017).
120. Jochmanova, I. et al. Clinical characteristics and outcomes of SDHB-related pheochromocytoma and paraganglioma in children and adolescents. *J. Cancer Res. Clin. Oncol.* **146**, 1051–1063 (2020).
121. Nolting, S. et al. Current management of pheochromocytoma/paraganglioma: a guide for the practicing clinician in the era of precision medicine. *Cancers* **11**, 1505 (2019).
122. Zheng, L. et al. Hypertensive crisis during microwave ablation of adrenal neoplasms: a retrospective analysis of predictive factors. *J. Vasc. Interv. Radiol.* **30**, 1343–1350 (2019).
123. Eisenhofer, G. et al. Adverse drug reactions in patients with phaeochromocytoma: incidence, prevention and management. *Drug Saf.* **30**, 1031–1062 (2007).
124. Pacak, K. Preoperative management of the pheochromocytoma patient. *J. Clin. Endocrinol. Metab.* **92**, 4069–4079 (2007).
125. Nazari, M. A., Rosenblum, J. S., Haigney, M. C., Rosing, D. R. & Pacak, K. Pathophysiology and acute management of tachyarrhythmias in pheochromocytoma: JACC review topic of the week. *J. Am. Coll. Cardiol.* **76**, 451–464 (2020).
126. Talvacchio, S., Nazari, M. A. & Pacak, K. Supportive management of patients with pheochromocytoma/paraganglioma undergoing noninvasive treatment. *Curr. Opin. Endocrinol. Diabetes Obes.* **29**, 294–301 (2022).
127. Huang, H. et al. Treatment of malignant pheochromocytoma/paraganglioma with cyclophosphamide, vincristine, and dacarbazine: recommendation from a 22-year follow-up of 18 patients. *Cancer* **113**, 2020–2028 (2008).
128. Averbuch, S. D. et al. Malignant pheochromocytoma: effective treatment with a combination of cyclophosphamide, vincristine, and dacarbazine. *Ann. Intern. Med.* **109**, 267–273 (1988).
129. Niemeijer, N. D., Alblas, G., van Hulsteijn, L. T., Dekkers, O. M. & Corssmit, E. P. Chemotherapy with cyclophosphamide, vincristine and dacarbazine for malignant paraganglioma and pheochromocytoma: systematic review and meta-analysis. *Clin. Endocrinol.* **81**, 642–651 (2014).
130. Asai, S., Katabami, T., Tsuiki, M., Tanaka, Y. & Naruse, M. Controlling tumor progression with cyclophosphamide, vincristine, and dacarbazine treatment improves survival in patients with metastatic and unresectable malignant pheochromocytomas/paragangliomas. *Horm. Cancer* **8**, 108–118 (2017).
131. Deutschbein, T. et al. Treatment of malignant phaeochromocytoma with a combination of cyclophosphamide, vincristine and dacarbazine: own experience and overview of the contemporary literature. *Clin. Endocrinol.* **82**, 84–90 (2015).
132. Tanabe, A. et al. Combination chemotherapy with cyclophosphamide, vincristine, and dacarbazine in patients with malignant pheochromocytoma and paraganglioma. *Horm. Cancer* **4**, 103–110 (2013).
133. Jawed, I. et al. Continued tumor reduction of metastatic pheochromocytoma/paraganglioma harboring succinate dehydrogenase subunit b mutations with cyclical chemotherapy. *Cell Mol. Neurobiol.* **38**, 1099–1106 (2018).
134. Fishbein, L. et al. SDHB mutation carriers with malignant pheochromocytoma respond better to CVD. *Endocr. Relat. Cancer* **24**, L51–L55 (2017).
135. Pacheco, S. T. et al. Metastatic pheochromocytoma and paraganglioma: a retrospective multicentre analysis on prognostic and predictive factors to chemotherapy. *Ecancermedicalscience* **17**, 1523 (2023).
136. Fischer, A. et al. Responses to systemic therapy in metastatic pheochromocytoma/paraganglioma - a retrospective multi-center cohort study. *Eur. J. Endocrinol.* https://doi.org/10.1093/ejendo/lvad146 (2023).
137. Shah, M. H. et al. Neuroendocrine and adrenal tumors, version 2.2021, NCCN clinical practice guidelines in oncology. *J. Natl Compr. Canc. Netw.* **19**, 839–868 (2021).
138. Benn, D. E. et al. Clinical presentation and penetrance of pheochromocytoma/paraganglioma syndromes. *J. Clin. Endocrinol. Metab.* **91**, 827–836 (2006).
139. Petrak, O. et al. Blood pressure profile, catecholamine phenotype, and target organ damage in pheochromocytoma/paraganglioma. *J. Clin. Endocrinol. Metab.* **104**, 5170–5180 (2019).
140. Gonias, S. et al. Phase II study of high-dose [^{131}I]metaiodobenzylguanidine therapy for patients with metastatic pheochromocytoma and paraganglioma. *J. Clin. Oncol.* **27**, 4162–4168 (2009).
141. Pryma, D. A. et al. Efficacy and safety of high-specific-activity ^{131}I-MIBG therapy in patients with advanced pheochromocytoma or paraganglioma. *J. Nucl. Med.* **60**, 623–630 (2019).
142. Makis, W., McCann, K. & McEwan, A. J. The challenges of treating paraganglioma patients with ^{177}Lu-DOTATATE PRRT: catecholamine crises, tumor lysis syndrome and the need for modification of treatment protocols. *Nucl. Med. Mol. Imaging* **49**, 223–230 (2015).
143. Zandee, W. T. et al. Treatment of inoperable or metastatic paragangliomas and pheochromocytomas with peptide receptor radionuclide therapy using ^{177}Lu-DOTATATE. *Eur. J. Endocrinol.* **181**, 45–53 (2019).
144. van Hulsteijn, L. T., Niemeijer, N. D., Dekkers, O. M. & Corssmit, E. P. ^{131}I-MIBG therapy for malignant paraganglioma and phaeochromocytoma: systematic review and meta-analysis. *Clin. Endocrinol.* **80**, 487–501 (2014).
145. Satapathy, S., Mittal, B. R. & Bhansali, A. Peptide receptor radionuclide therapy in the management of advanced pheochromocytoma and paraganglioma: a systematic review and meta-analysis. *Clin. Endocrinol.* **91**, 718–727 (2019).
146. Nastos, K. et al. Peptide receptor radionuclide treatment and ^{131}I-MIBG in the management of patients with metastatic/progressive phaeochromocytomas and paragangliomas. *J. Surg. Oncol.* **115**, 425–434 (2017).
147. Carrasquillo, J. A. et al. Systemic radiopharmaceutical therapy of pheochromocytoma and paraganglioma. *J. Nucl. Med.* **62**, 1192–1199 (2021).
148. Fonte, J. S. et al. False-negative ^{123}I-MIBG SPECT is most commonly found in SDHB-related pheochromocytoma or paraganglioma with high frequency to develop metastatic disease. *Endocr. Relat. Cancer* **19**, 83–93 (2012).
149. Timmers, H. J. et al. Superiority of fluorodeoxyglucose positron emission tomography to other functional imaging techniques in the evaluation of metastatic SDHB-associated pheochromocytoma and paraganglioma. *J. Clin. Oncol.* **25**, 2262–2269 (2007).
150. Timmers, H. J. et al. Comparison of ^{18}F-fluoro-L-DOPA, ^{18}F-fluoro-deoxyglucose, and ^{18}F-fluorodopamine PET and ^{123}I-MIBG scintigraphy in the localization of pheochromocytoma and paraganglioma. *J. Clin. Endocrinol. Metab.* **94**, 4757–4767 (2009).
151. Petenuci, J. et al. SDHB large deletions are associated with absence of MIBG uptake in metastatic lesions of malignant paragangliomas. *Endocrine* **72**, 586–590 (2021).
152. Lynn, M. D. et al. Portrayal of pheochromocytoma and normal human adrenal medulla by *m*-[^{123}I]iodobenzylguanidine: concise communication. *J. Nucl. Med.* **25**, 436–440 (1984).
153. Donato, S., Simoes, H., Pinto, A. T., B, M. C. & Leite, V. SDHx-related pheochromocytoma/paraganglioma — genetic, clinical, and treatment outcomes in a series of 30 patients from a single center. *Endocrine* **65**, 408–415 (2019).
154. Carrasquillo, J. A., Pandit-Taskar, N. & Chen, C. C. I-131 metaiodobenzylguanidine therapy of pheochromocytoma and paraganglioma. *Semin. Nucl. Med.* **46**, 203–214 (2016).
155. Amar, L. et al. Succinate dehydrogenase B gene mutations predict survival in patients with malignant pheochromocytomas or paragangliomas. *J. Clin. Endocrinol. Metab.* **92**, 3822–3828 (2007).
156. Ayala-Ramirez, M. et al. Clinical risk factors for malignancy and overall survival in patients with pheochromocytomas and sympathetic paragangliomas: primary tumor size and primary tumor location as prognostic indicators. *J. Clin. Endocrinol. Metab.* **96**, 717–725 (2011).
157. Noto, R. B. et al. Phase 1 study of high-specific-activity I-131 MIBG for metastatic and/or recurrent pheochromocytoma or paraganglioma. *J. Clin. Endocrinol. Metab.* **103**, 213–220 (2018).
158. Safford, S. D. et al. Iodine -131 metaiodobenzylguanidine is an effective treatment for malignant pheochromocytoma and paraganglioma. *Surgery* **134**, 956–962 (2003).
159. Thorpe, M. P. et al. Long-term outcomes of 125 patients with metastatic pheochromocytoma or paraganglioma treated with 131-I MIBG. *J. Clin. Endocrinol. Metab.* **105**, e494–e501 (2020).
160. Elston, M. S. et al. Increased SSTR2A and SSTR3 expression in succinate dehydrogenase-deficient pheochromocytomas and paragangliomas. *Hum. Pathol.* **46**, 390–396 (2015).
161. Kaemmerer, D. et al. Evaluation of somatostatin, CXCR4 chemokine and endothelin A receptor expression in a large set of paragangliomas. *Oncotarget* **8**, 89958–89969 (2017).
162. Fischer, A. et al. Metastatic pheochromocytoma and paraganglioma: somatostatin receptor 2 expression, genetics and therapeutic responses. *J. Clin. Endocrinol. Metab.* **108**, 2676–2685 (2023).
163. Roll, W. et al. Somatostatin receptor-targeted radioligand therapy in head and neck paraganglioma. *World Neurosurg.* **143**, e391–e399 (2020).
164. Tsang, E. S., Funk, G., Leung, J., Kalish, G. & Kennecke, H. F. Supportive management of patients with advanced pheochromocytomas and paragangliomas receiving PRRT. *Curr. Oncol.* **28**, 2823–2829 (2021).
165. Pinato, D. J. et al. Peptide receptor radionuclide therapy for metastatic paragangliomas. *Med. Oncol.* **33**, 47 (2016).
166. Kolasinska-Cwikla, A. et al. A clinical efficacy of PRRT in patients with advanced, nonresectable, paraganglioma-pheochromocytoma, related to SDHx gene mutation. *J. Clin. Med.* **8**, 952 (2019).
167. Vyakaranam, A. R. et al. Favorable outcome in patients with pheochromocytoma and paraganglioma treated with ^{177}Lu-DOTATATE. *Cancers* **11**, 909 (2019).
168. Hadoux, J. et al. SDHB mutations are associated with response to temozolomide in patients with metastatic pheochromocytoma or paraganglioma. *Int. J. Cancer* **135**, 2711–2720 (2014).
169. Eisenhauer, E. A. et al. New response evaluation criteria in solid tumours: revised RECIST guideline (version 1.1). *Eur. J. Cancer* **45**, 228–247 (2009).
170. O, J. H., Lodge, M. A. & Wahl, R. L. Practical PERCIST: a simplified guide to PET response criteria in solid tumors 1.0. *Radiology* **280**, 576–584 (2016).
171. Hegi, M. E. et al. Correlation of O6-methylguanine methyltransferase (MGMT) promoter methylation with clinical outcomes in glioblastoma and clinical strategies to modulate MGMT activity. *J. Clin. Oncol.* **26**, 4189–4199 (2008).
172. Zhou, Y., Cui, Y., Zhang, D. & Tong, A. Efficacy and safety of tyrosine kinase inhibitors in patients with metastatic pheochromocytomas/paragangliomas. *J. Clin. Endocrinol. Metab.* **108**, 755–766 (2023).
173. O'Kane, G. M. et al. A phase 2 trial of sunitinib in patients with progressive paraganglioma or pheochromocytoma: the SNIPP trial. *Br. J. Cancer* **120**, 1113–1119 (2019).

174. Ayala-Ramirez, M. et al. Treatment with sunitinib for patients with progressive metastatic pheochromocytomas and sympathetic paragangliomas. *J. Clin. Endocrinol. Metab.* **97**, 4040–4050 (2012).
175. Baudin, E. et al. 567O_PR — First international randomized study in malignant progressive pheochromocytoma and paragangliomas (FIRSTMAPPP): an academic double-blind trial investigating sunitinib. *Ann. Oncol.* **32**, S621–S625 (2021).
176. Jimenez C, P. M., Busaidy N, Habra MA, Waguespack S, Jessop A. A phase 2 study to evaluate the effects of cabozantinib in patients with unresectable metastatic pheochromocytomas and paragangliomas. *International Symposium on Pheochromocytoma and Paraganglioma* (Sydney, Australia, 2017).
177. Naing, A. et al. Phase 2 study of pembrolizumab in patients with advanced rare cancers. *J. Immunother. Cancer* **8**, e000347 (2020).
178. Jimenez, C. et al. Phase II clinical trial of pembrolizumab in patients with progressive metastatic pheochromocytomas and paragangliomas. *Cancers* **12**, 2307 (2020).
179. Caplin, M. E. et al. Lanreotide in metastatic enteropancreatic neuroendocrine tumors. *N. Engl. J. Med.* **371**, 224–233 (2014).
180. Pavel, M. et al. Gastroenteropancreatic neuroendocrine neoplasms: ESMO Clinical Practice Guidelines for diagnosis, treatment and follow-up. *Ann. Oncol.* **31**, 844–860 (2020).
181. Rinke, A. et al. Placebo-controlled, double-blind, prospective, randomized study on the effect of octreotide LAR in the control of tumor growth in patients with metastatic neuroendocrine midgut tumors: a report from the PROMID Study Group. *J. Clin. Oncol.* **27**, 4656–4663 (2009).
182. Greenberg, S. E. et al. Tumor detection rates in screening of individuals with SDHx-related hereditary paraganglioma-pheochromocytoma syndrome. *Genet. Med.* **22**, 2101–2107 (2020).
183. Hes, F. J. et al. Low penetrance of a SDHB mutation in a large Dutch paraganglioma family. *BMC Med. Genet.* **11**, 92 (2010).
184. Papathomas, T. G. et al. SDHB/SDHA immunohistochemistry in pheochromocytomas and paragangliomas: a multicenter interobserver variation analysis using virtual microscopy: a Multinational Study of the European Network for the Study of Adrenal Tumors (ENS@T). *Mod. Pathol.* **28**, 807–821 (2015).
185. Pasini, B. & Stratakis, C. A. SDH mutations in tumorigenesis and inherited endocrine tumours: lesson from the phaeochromocytoma-paraganglioma syndromes. *J. Intern. Med.* **266**, 19–42 (2009).
186. Rijken, J. A. et al. Low penetrance of paraganglioma and pheochromocytoma in an extended kindred with a germline SDHB exon 3 deletion. *Clin. Genet.* **89**, 128–132 (2016).
187. Schiavi, F. et al. Are we overestimating the penetrance of mutations in SDHB? *Hum. Mutat.* **31**, 761–762 (2010).
188. Solis, D. C. et al. Penetrance and clinical consequences of a gross SDHB deletion in a large family. *Clin. Genet.* **75**, 354–363 (2009).
189. Timmers, H. J. et al. Clinical presentations, biochemical phenotypes, and genotype-phenotype correlations in patients with succinate dehydrogenase subunit B-associated pheochromocytomas and paragangliomas. *J. Clin. Endocrinol. Metab.* **92**, 779–786 (2007).
190. van Hulsteijn, L. T., Dekkers, O. M., Hes, F. J., Smit, J. W. & Corssmit, E. P. Risk of malignant paraganglioma in SDHB-mutation and SDHD-mutation carriers: a systematic review and meta-analysis. *J. Med. Genet.* **49**, 768–776 (2012).
191. Taieb, D., Jha, A., Treglia, G. & Pacak, K. Molecular imaging and radionuclide therapy of pheochromocytoma and paraganglioma in the era of genomic characterization of disease subgroups. *Endocr. Relat. Cancer* **26**, R627–R652 (2019).

Acknowledgements

This Consensus statement was supported by a National Institutes of Health grant (grant number Z1AHD008735), awarded to K.P. This Consensus statement was supported by the Intramural Research Program of the National Institutes of Health and Eunice Kennedy Shriver National Institute of Child Health and Human Development. S.N. has received a research grant from German Research Foundation (Deutsche Forschungsgemeinschaft (DFG)) within the CRC/Transregio 205/2, Project number: 314061271 – TRR 205 'The Adrenal: Central Relay in Health and Disease'. E.R.M. has received funding from the NIHR Cambridge Biomedical Research Centre (BRC-1215-20014 and NIHR203312) and the University of Cambridge has received salary support (E.R.M.) from the NHS in the East of England through the Clinical Academic Reserve. The views expressed are those of the authors and not necessarily those of the NHS or Department of Health. J.A.C. was funded in part by the NIH/NCI Cancer Center Support Grant to MSK, P30 CA008748. We acknowledge Michael Lui and Uriel Clemente-Gutierrea (surgical endocrine research fellows in the Department of Surgical Oncology, University of Texas MD Anderson Cancer Center) for their contributions to the Surgery section and Katharina Wang (MD in the Department of Medicine IV, University Hospital, Ludwig-Maximilians-University Munich, Munich, Germany) and Alessa Fischer (MD in the Department of Endocrinology, Diabetology and Clinical Nutrition, University Hospital Zurich and University of Zurich, Zurich, Switzerland) for their contribution to the therapy section. We acknowledge Alicia A. Livinski, National Institutes of Health Library, Bethesda, MD, USA, for assistance with this project and manuscript. We acknowledge Editage for professional editing prior to submission.

Author contributions

D.T., S.N., N.D.P., M.F., J.A.C., A.B.G., R.C.-B., G.B.W., Z.G.S., C.L.-L., J.W.M.L. and K.P. researched data for the article, contributed to discussion of the content, wrote the article, and reviewed and/or edited the manuscript before submission. L.A., I.B., R.T.C., J.C., J.D.R., A.-P.G.-R., M.N.K., A.L., O.M., N.N. G.E. and H.J.L.M.T. researched data for the article, contributed to discussion of the content, and reviewed and/or edited the manuscript before submission. C.L.D., Q.-Y.D., T.F., H.K.G., A.J.G., R.H., A.I., M.R. and F.S. contributed to discussion of the content and reviewed and/or edited the manuscript before submission. A.J. and L.M. researched data for the article, wrote the article, and reviewed and/or edited the manuscript before submission. R.R.d.K., I.L., E.R.M., M.N., N.S.S., A.T., G.B.T., J.W. and W.J.Y.Jr. reviewed and/or edited the manuscript before submission. F.I.L. researched data for the article and reviewed and/or edited the manuscript before submission.

Competing interests

D.T. has received personal honoraria for lectures and consulting from AAA/Novartis and support for meeting attendance from AAA/Novartis. S.N. has received research contracts from Novartis, lecture fees from Ipsen, and support for meeting attendance from Novartis and Ipsen. A.B.G. has received lecture fees from AAA/Novartis and Advisory Board fees from Ipsen. Z.G.S. is a paid consultant for Acclarent. L.A. has received personal honoraria for lectures from Servier and Ipsen. R.T.C. has received personal honoraria for lectures from Novartis, support for meeting attendance from Ipsen, and serves as a board member on the clinical committees for the Society for Endocrinology and UK and Ireland Neuroendocrine Tumour Society. R.H. is a shareholder in Telix Pharmaceuticals and PreMIT Pty Ltd. C.L.-L. has received personal honoraria for lectures from Ipsen and support for meeting attendance from Ipsen. E.R.M. has received fees for consulting from MSD and personal honoraria for lectures from MSD. M.N. has received personal honoraria for lectures from PDRadiopharma Inc. N.N. has received an intramural research grant from the NIH. The other authors declare no competing interests.

Additional information

Supplementary information The online version contains supplementary material available at https://doi.org/10.1038/s41574-023-00926-0.

Peer review information *Nature Reviews Endocrinology* thanks Giuseppe Opocher and the other, anonymous, reviewer(s) for their contribution to the peer review of this work.

Publisher's note Springer Nature remains neutral with regard to jurisdictional claims in published maps and institutional affiliations.

This is a U.S. Government work and not under copyright protection in the US; foreign copyright protection may apply 2023

[1]Department of Nuclear Medicine, Aix-Marseille University, La Timone University Hospital, Marseille, France. [2]Department of Endocrinology, Diabetology and Clinical Nutrition, University Hospital Zurich and University of Zurich, Zurich, Switzerland. [3]Department of Medicine IV, University Hospital, Ludwig-Maximilians-University Munich, Munich, Germany. [4]Department of Surgical Oncology, MD Anderson Cancer Center, Houston, TX, USA. [5]Department of Medicine, Division of Endocrinology and Diabetes, University Hospital, University of Würzburg, Würzburg, Germany. [6]Molecular Imaging and Therapy Service, Radiology Department, Memorial Sloan Kettering Cancer Center, New York, NY, USA. [7]Green Templeton College, University of Oxford, Oxford, UK. [8]NET Unit, Royal Free Hospital, London, UK. [9]Department of Endocrinology, Royal North Shore Hospital and Cancer Genetics Laboratory, Kolling Institute, University of Sydney, Sydney, New South Wales, Australia. [10]Department of Otolaryngology-Head and Neck Surgery, Icahn School of Medicine at Mount Sinai, New York, NY, USA. [11]Université Paris Cité, Inserm, PARCC, Equipe Labellisée par la Ligue contre le Cancer, Paris, France. [12]Hypertension Unit, Hôpital Européen Georges Pompidou, Assistance Publique — Hôpitaux de Paris, Paris, France. [13]Division of Endocrinology, Department of Medicine and Research Center, Centre hospitalier de l'Université de Montréal (CHUM), Montréal, Québec, Canada. [14]Department of Medical Genetics, University of Cambridge, Cambridge Biomedical Campus, Cambridge, UK. [15]Department of Medical Sciences, Uppsala University, Uppsala, Sweden. [16]Research Center, CHU Sainte-Justine and Dept. of Paediatrics, University of Montreal, Montreal, Québec, Canada. [17]Developmental Therapeutics Branch, Center for Cancer Research, National Cancer Institute, National Institutes of Health, Bethesda, MD, USA. [18]Department of Surgery, UCSF-Mount Zion, San Francisco, CA, USA. [19]Institute of Clinical Chemistry and Laboratory Medicine, University Hospital Carl Gustav Carus at the TU Dresden, Dresden, Germany. [20]Columbia University Irving Medical Center, New York City, NY, USA. [21]James J. Peters VA Medical Center, New York City, NY, USA.

[22]Division of Endocrinology & Metabolism, Department of Medicine, University of Florida, Gainesville, FL, USA. [23]Malcom Randall VA Medical Center, Gainesville, FL, USA. [24]Department of Oncogenetics and Cancer Genomic Medicine, AP-HP, Hôpital européen Georges Pompidou, Paris, France. [25]University of Sydney, Sydney NSW Australia, Cancer Diagnosis and Pathology Group Kolling Institute of Medical Research, Royal North Shore Hospital, St Leonards, New South Wales, Australia. [26]NSW Health Pathology Department of Anatomical Pathology, Royal North Shore Hospital, St Leonards, New South Wales, Australia. [27]Department of Medicine, St Vincent's Hospital Medical School, Melbourne, Victoria, Australia. [28]Department of Nuclear Medicine and Molecular Imaging – Institut de Cancérologie de Strasbourg Europe (ICANS), IPHC, UMR 7178, CNRS, University of Strasbourg, Strasbourg, France. [29]Section on Medical Neuroendocrinology, Eunice Kennedy Shriver National Institute of Child Health and Human Development, National Institutes of Health, Bethesda, MD, USA. [30]Department of Endocrinology, University Medical Center Groningen, Groningen, Netherlands. [31]Department of Pathology, University Medical Center Utrecht, Utrecht, Netherlands. [32]Princess Máxima Center for paediatric oncology, Utrecht, Netherlands. [33]Division of Endocrinology, Department of Medicine, Centre de recherche du Centre hospitalier de l'Université de Montréal, Université de Montréal, Montréal, Canada. [34]Department of Internal Medicine 1, University Hospital, P.J. Šafárik University, Košice, Slovakia. [35]Molecular Imaging Program, National Cancer Institute, National Institutes of Health, Bethesda, MD, USA. [36]Sorbonne University, Department of Nuclear Medicine, Pitié-Salpêtrière, Paris, France. [37]Department of Laboratory Medicine and Pathobiology, University of Toronto, Toronto, Ontario, Canada. [38]Clinical Research Institute of Endocrinology and Metabolism, National Hospital Organization Kyoto Medical Center and Endocrine Center, Kyoto, Japan. [39]Clinical Research Center, Ijinkai Takeda General Hospital, Kyoto, Japan. [40]Surgical Oncology Program, National Cancer Institute, National Institutes of Health, Bethesda, MD, USA. [41]Hereditary Endocrine Cancer Group, Spanish National Cancer Research Center (CNIO), Madrid, Spain. [42]Centro de Investigación Biomédica en Red de Enfermedades Raras (CIBERER), Institute of Health Carlos III (ISCIII), Madrid, Spain. [43]Department of Endocrine Surgery, Aix-Marseille University, Conception Hospital, Marseille, France. [44]Department of Endocrinology, Seth GS Medical College and KEM Hospital, Mumbai, Maharashtra, India. [45]Department of Diabetes, Endocrinology and Metabolism, National Center for Global Health and Medicine, Tokyo, Japan. [46]Division of Endocrine Surgery, Department of Surgery, Mayo Clinic, Rochester, MN, USA. [47]Department of Internal Medicine, Radboud University Medical Center, Nijmegen, Netherlands. [48]Third Department of Medicine, Department of Endocrinology and Metabolism of the First Faculty of Medicine, Charles University and General University Hospital, Prague, Czech Republic. [49]Division of Endocrinology, Diabetes, Metabolism, and Nutrition, Mayo Clinic, Rochester, MN, USA. [50]Stanford University School of Medicine, Department of Physician Assistant Studies, Stanford, CA, USA.