Hypertension Research (2019) 42:1092–1094
https://doi.org/10.1038/s41440-019-0232-8

CORRESPONDENCE

Observation of renal sympathetic nerves by intravascular ultrasound

Shunsuke Satou[1,2] · Keisuke Okamura[1] · Ryohei Konishi[2] · Kazuyuki Shirai[1] · Hidenori Urata[1]

Received: 28 December 2018 / Revised: 15 January 2019 / Accepted: 16 January 2019 / Published online: 15 February 2019

Renal denervation (RDN) has been found to be effective for reducing the blood pressure in recent clinical trials, including the SPYRAL HTN—ON MED trial [1], the SPYRAL HTN—MED trial [2], and the RADIANCE-HTN SOLO trial [3]. By overcoming the disappointing results of the SYMPLICITY HTN-3 trial [4], treatment of hypertension with RDN entered a new era with these three clinical trials [5]. In the two SPYRAL trials, a helical multi-electrode catheter was used for RDN [1, 2]. The four electrodes on a Spyral catheter distribute radiofrequency energy to the four quadrants of the target renal artery, allowing ablation of sympathetic nerves through the vessel wall. However, the Paradise system used in the RADIANCE trial provides circumferential ultrasonic cauterization of the renal artery to a depth of 1–6 mm with a cooling balloon [3]. With both systems, there is no way to assess whether or not renal sympathetic nerves have been cauterized by the procedure, making it difficult to judge the success or failure of RDN. One reported method of selecting the target sites for ablation and the endpoint of RDN is electrical autonomic nervous stimulation conducted from inside the renal artery [6]. Although this method is presently considered to be the most useful method, it has not reached the stage of clinical application.

Observation of nerves by ultrasound has already been done clinically during lumbar nerve block or diagnosis of carpal tunnel syndrome. Intravascular ultrasound (IVUS) is widely used for percutaneous coronary intervention, but neither the observation of nerves around the coronary arteries nor the observation of renal sympathetic nerves around the renal artery have been attempted. However, it might be possible to identify the renal sympathetic nerves as structures running parallel to the renal artery by careful observation with IVUS. Therefore, we reviewed IVUS images obtained during percutaneous transluminal renal angioplasty (PTRA) and searched for evidence of renal sympathetic nerves. During PTRA for treatment of renal artery stenosis, we used a VISICUBE® and Navifocus® (TERUMO Corporation) to observe the vessel diameter and the features of the culprit lesion. During PTRA, IVUS is usually done with the settings shown in Table 1 (Configuration A). By reviewing IVUS images from PTRA, we found multiple hypoechoic structures running along the renal artery at approximately 1–4 mm outside the vessel (Fig. 1). Observation of IVUS images revealed low echoic structures running along the renal artery approximately 68

Table 1 Configuration of intravascular ultrasound (IVUS)

Configuration	A	B
Frequency drive	H	C
Pullback speed (mm/s)	0.5	0.5
FPS (frame/s)	30	30
Acquisition depth (mm)	6	32
Display depth (mm)	5	8
STC1	–2	–2
STC2	0	0
STC3	1	2
STC4	2	0
STC5	3	4
STC6	4	4
Gain	13	13
Contrast	4	1
Gamma	5	6
Sharpness filter	1	1
Time average	3	2

Configuration A: for percutaneous transluminal renal angioplasty (PTRA)

Configuration B: for observing renal sympathetic nerves

FPS frames per second, *STC* sensitivity time control

✉ Keisuke Okamura
okamurakmd@cis.fukuoka-u.ac.jp

[1] Department of Cardiovascular Diseases, Fukuoka University Chikushi Hospital, Chikushino, Japan

[2] Clinical Engineering Center, Fukuoka University Chikushi Hospital, Chikushino, Japan

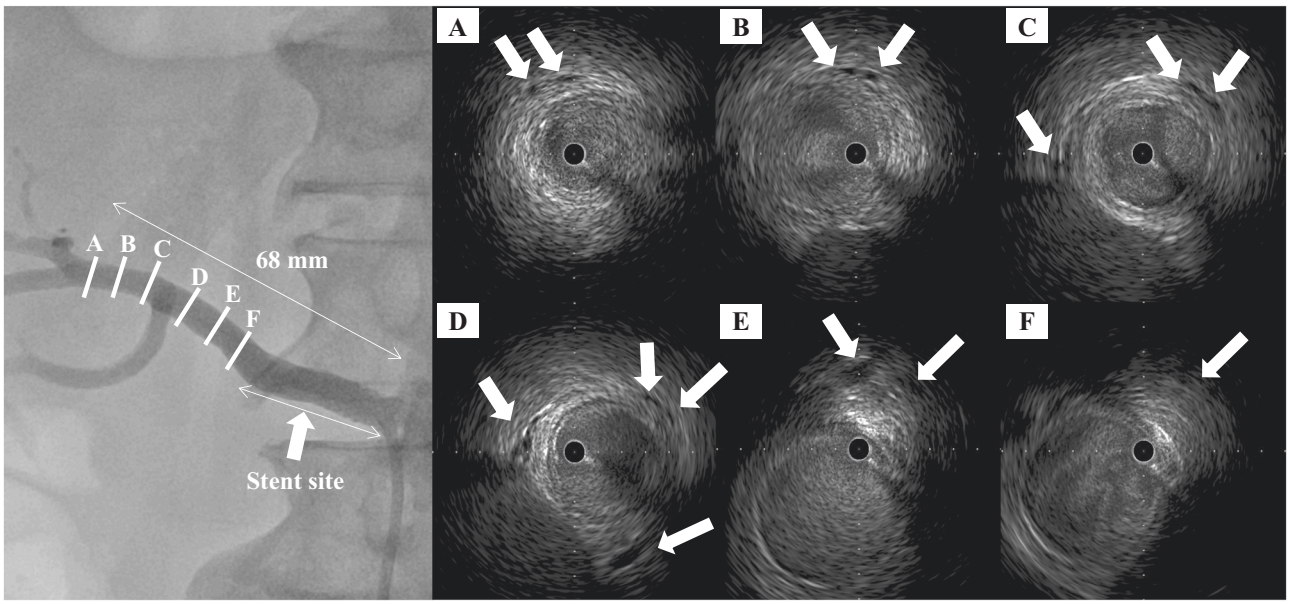

Fig. 1 Observation of renal sympathetic nerves by intravascular ultrasound (IVUS). Renal sympathetic nerves could be observed by IVUS after percutaneous transluminal renal angioplasty (PTRA). Low echoic structures, which were considered to be renal sympathetic nerves, were observed near the vascular wall at sites **a**, **b**, **c**, and **d**. Compared with the distal part of the renal artery, the low echoic structures run further from the proximal part of the artery (sites **e** and **f**)

mm from its ostium where pullback was initiated (Figs. 1a–d). These structures become more distant from the renal artery near its proximal end (Figs. 1e, f). The structures had no lumen and blood flow could not be detected by Doppler echo. Generally, ultrasound shows nerve fibers as hypoechoic and vessels as hyperechoic.

Moreover, the structures closely resembled nerves in arrangement and thickness when compared with the data on renal artery sections reported by Sakakura et al. [7]; thus, we concluded that these structures were renal nerves.

When tissue is cauterized, protein undergoes denaturation. Radiofrequency ablation is performed for treatment of liver cancer, with heating to approximately 50–70 °C to cauterize liver tissue and cancer cells. When cauterization is done under ultrasound guidance, the brightness of the ultrasound image increases due to protein denaturation because of reduced moisture inside the liver tissue. During RDN, the tissue temperature was increased to approximately 70 °C by the PARADISE system [3], which used in RADIANCE-HTN. In addition, it was reported that the tissue temperature is raised to approximately 68.8 °C by a radiofrequency catheter [8]. Thus, there is a possibility that cauterized tissue, including nerves, will show increased brightness on IVUS. However, it is difficult for the guidewire to run concentric with the center of the renal artery lumen since the renal artery is larger than the coronary arteries, which means that IVUS provides eccentric images in most cases. Therefore, observing the entire circumference outside the renal artery with IVUS requires a different IVUS configuration from that for coronary artery observation. In other words, to observe the extravascular renal sympathetic nerves around the full circumference of the renal artery, it is necessary to increase the depth of imaging.

Some IVUS devices can be used to observe both the vessel diameter and nerves at various depths using only one pullback. Because the sympathetic nerves run closer to the distal part of the renal artery than the proximal part, performing cauterization at the distal part has been recommended to achieve an antihypertensive effect [7]. While it is important to observe the distal part of the renal artery, advancing the IVUS system deep into the artery might lead to kidney injury by the guidewire or probe. Therefore, an IVUS probe with a short distance from its tip to the ultrasound element should be selected. For example, a Navi-Forcus® not only has a short tip but can also obtain deep images because the frequency can be lowered to 32 MHz by using C mode. We recommend the IVUS configuration shown in Table 1 (Configuration B) to obtain good images of the renal sympathetic nerves. It was reported that the renal sympathetic nerve plexus is mainly located more than 0.5–1.0 mm from the renal artery lumen, while another report indicated that the sympathetic nerve plexus is located 2.0–8.0 mm from the lumen [9]. Using a radiofrequency catheter, the renal artery can be cauterized at a depth of 1–6 mm, achieving denervation of approximately 80% of efferent and afferent renal sympathetic nerves in the adventitia of the main renal arteries [7]. Since the sympathetic nerve runs relatively near the vessel wall in the distal

part of the renal artery, we found that it was possible to observe these nerves easily with IVUS. In addition, we could easily observe extravascular tissue around the entire circumference in the distal part of the artery because the guidewire runs concentric with the center of the lumen. Conversely, we confirmed that the guidewire tended to run eccentrically in the proximal part of the artery and it was difficult to observe the entire circumference. Thus, it is difficult to observe the renal nerves in the proximal part of the renal artery with current IVUS systems. However, there is a possibility that observation could be improved by employing an IVUS catheter equipped with a balloon. Since the guidewire should run through the center of the renal artery lumen with such a device, we would be able to observe renal nerves around the entire circumference of the vessel. Some IVUS systems can obtain images up to a radius of 32 mm, and it is possible that such systems could be used to assess the effect of RDN during the procedure.

Similarly, optical coherence tomography (OCT) is a modality that allows for intravascular observation of a blood vessel wall. It was reported that the observation of the inner wall after RDN was performed using OCT in the swine model [10]. However, observable depth is low due to the characteristics of OCT in addition to the large amount of contrast medium necessary for filling the renal artery. The clinical application of OCT to the renal artery for observation of extravascular sympathetic nerves will need reconsideration.

In conclusion, there is currently no method for evaluating the efficacy of cauterization during RDN. While extravascular nerves have not yet been observed by IVUS in the clinical setting, IVUS observation of the tissues around the distal renal artery has the potential to become a useful modality for determining whether RDN has been performed correctly.

Compliance with ethical standards

Conflict of interest The authors have received honoraria and grant support for a clinical trial from Otsuka Holdings and Terumo Corporation.

References

1. Kandzari DE, Bohm M, Mahfoud F, Townsend RR, Weber MA, Pocock S, et al. Investigators SH-OMT. Effect of renal denervation on blood pressure in the presence of antihypertensive drugs: 6-month efficacy and safety results from the SPYRAL HTN-ON MED proof-of-concept randomised trial. Lancet. 2018;391:2346–55.
2. Townsend RR, Mahfoud F, Kandzari DE, Kario K, Pocock S, Weber MA, et al. investigators* SH-OMt. Catheter-based renal denervation in patients with uncontrolled hypertension in the absence of antihypertensive medications (SPYRAL HTN-OFF MED): a randomised, sham-controlled, proof-of-concept trial. Lancet. 2017;390:2160–70.
3. Azizi M, Schmieder RE, Mahfoud F, Weber MA, Daemen J, Davies J, et al. Endovascular ultrasound renal denervation to treat hypertension (RADIANCE-HTN SOLO): a multicentre, international, single-blind, randomised, sham-controlled trial. Lancet. 2018;391:2335–45.
4. Bhatt DL, Kandzari DE, O'Neill WW, D'Agostino R, Flack JM, Katzen BT, et al. A controlled trial of renal denervation for resistant hypertension. New Engl J Med. 2014;370:1393–401.
5. Okamura K, Urata H. Anticipated expansion of a new approach to treating hypertension without medication by catheter-based renal denervation. J Thorac Dis. 2018;10:S3266–70.
6. Chinushi M, Izumi D, Iijima K, Suzuki K, Furushima H, Saitoh O, et al. Blood pressure and autonomic responses to electrical stimulation of the renal arterial nerves before and after ablation of the renal artery. Hypertension. 2013;61:450–6.
7. Sakakura K, Ladich E, Cheng Q, Otsuka F, Yahagi K, Fowler DR, et al. Anatomic assessment of sympathetic peri-arterial renal nerves in man. J Am Coll Cardiol. 2014;64:635–43.
8. Sakaoka A, Terao H, Nakamura S, Hagiwara H, Furukawa T, Matsumura K, et al. Accurate depth of radiofrequency-induced lesions in renal sympathetic denervation based on a fine histological sectioning approach in a porcine model. Circ Cardiovasc Interv. 2018;11:e005779.
9. Atherton DS, Deep NL, Mendelsohn FO. Micro-anatomy of the renal sympathetic nervous system: a human postmortem histologic study. Clin Anat. 2012;25:628–33.
10. Delgado-Silva J, Fernandes R, Pita IR, Pereira FC, Jaguszewski M, Gutiérrez-Chico JL, et al. Intravascular imaging, histopathological analysis, and catecholamine quantification following catheter-based renal denervation in a swine model: the impact of prebifurcation energy delivery. Hypertens Res. 2018;41:708–17.