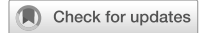

IMAGE OPEN

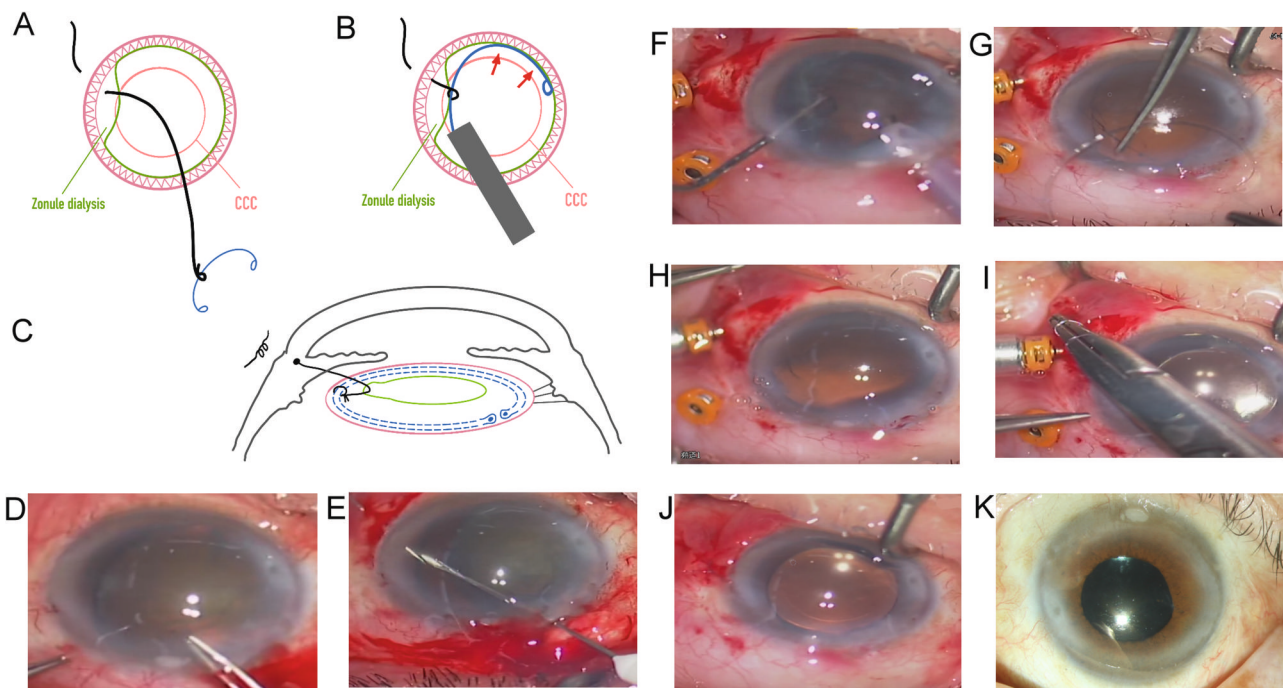


# Lord of the Ring technique for capsular tension ring in subluxated cataract surgery

Pei-Chang Wu<sup>1</sup>

© The Author(s) 2024

Eye; <https://doi.org/10.1038/s41433-024-02988-4>



**Fig. 1 Lord of Ring technique for capsular tension ring (CTR).** **A** A movable knot is tied by 10-0 prolene string in the CTR shift. **B** The CTR is slowly released into bag. **C** The other end of string is fixed to the sclera. The movable knot is moved to a good location. Moderate tension is maintained to hold the CTR. Lateral view of the string holding the ring in the zonule dialysis area. **D** A case of traumatic cataract with temporal 180° zonular dialysis (video). Circular capsulorhexis was performed gently. **E** A 10-0 string needle was inserted from the temporal sclera away limbus 2 mm into anterior chamber, and pulled out by a 27-gauge needle. **F** Phacoemulsification and gentle cortical removal can be performed, or after CTR insertion. **G** = **A**. **H** = **B**. **I** IOL was implanted and procedure in (**C**) is carried out. **J** A well-centered IOL. **K** After 3 months, vision improved to 20/40.

**VIDEO DESCRIPTION**

A case of traumatic cataract with temporal 180° zonular dialysis received surgery with the Lord of the Ring technique.

**ACKNOWLEDGEMENTS**

The author thanks Jasmine Si-Yi Wu for drawing the line-art figures.

**DATA AVAILABILITY**

The data are available from the corresponding author on reasonable request.

**COMPETING INTERESTS**

The author declares no competing interests.

<sup>1</sup>Department of Ophthalmology, Kaohsiung Chang Gung Memorial Hospital and Chang Gung University College of Medicine, Kaohsiung, Taiwan. A supplemental video is available at Eye's website. email: wpc@adm.cgmh.org.tw

Received: 20 September 2023 Revised: 26 January 2024 Accepted: 8 February 2024

Published online: 07 March 2024

## ADDITIONAL INFORMATION

**Supplementary information** The online version contains supplementary material available at <https://doi.org/10.1038/s41433-024-02988-4>.

**Correspondence** and requests for materials should be addressed to Pei-Chang Wu.

**Reprints and permission information** is available at <http://www.nature.com/reprints>

**Publisher's note** Springer Nature remains neutral with regard to jurisdictional claims in published maps and institutional affiliations.



**Open Access** This article is licensed under a Creative Commons Attribution 4.0 International License, which permits use, sharing, adaptation, distribution and reproduction in any medium or format, as long as you give appropriate credit to the original author(s) and the source, provide a link to the Creative Commons licence, and indicate if changes were made. The images or other third party material in this article are included in the article's Creative Commons licence, unless indicated otherwise in a credit line to the material. If material is not included in the article's Creative Commons licence and your intended use is not permitted by statutory regulation or exceeds the permitted use, you will need to obtain permission directly from the copyright holder. To view a copy of this licence, visit <http://creativecommons.org/licenses/by/4.0/>.

© The Author(s) 2024