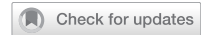

IMAGE



Infographic: Intravitreal aflibercept injection in patients with myopic choroidal neovascularization: the MYRROR study

Imran H. Yusuf^{1,2✉}, Christin Henein^{3,4} and Sobha Sivaprasad^{1,4}

© The Author(s), under exclusive licence to The Royal College of Ophthalmologists 2023

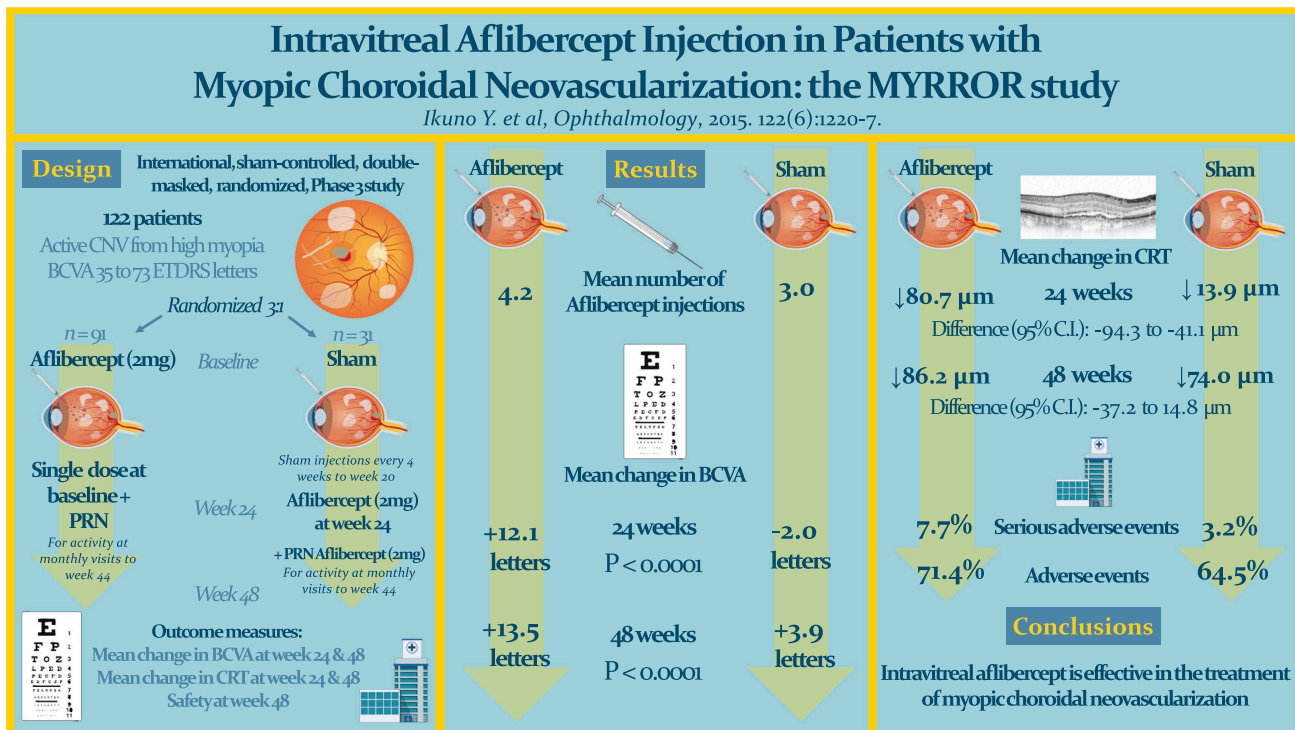
Eye; <https://doi.org/10.1038/s41433-023-02393-3>

This study, conducted in East Asia, included patients aged 18 and over with visual impairment due to active choroidal neovascularization secondary to pathological myopia with spherical equivalence of $\geq -6D$, or an axial length ≥ 26.5 mm. Activity of CNV lesions was confirmed on fluorescein angiography. Exclusion criteria included: one functional eye, recurrent myopic CNV, ocular inflammation, iris neovascularization, uncontrolled glaucoma or previous trabeculectomy. Predefined retreatment criteria for the aflibercept group (to a maximum frequency of 4-weekly) were: (1) loss of ≥ 5 ETDRS letters from previous visit (2) Increase in central retinal thickness ≥ 50 μm , or other OCT changes consistent with activity (3) investigator discretion. These criteria were applied to

the control group from week 24 to 44. Note that the control group did not receive any intervention except for sham injections until week 24. The paper does not present statistical comparisons in adverse events between treatment groups.

CNV – choroidal neovascularisation; BCVA – best corrected visual acuity; ETDRS – early treatment diabetic retinopathy study; PRN – pro re nata (i.e. as needed); CRT – central retinal thickness (on optical coherence tomography imaging); μm – micrometres.

Reference: Ikuno et al. Intravitreal Aflibercept Injection in Patients with Myopic Choroidal Neovascularization: The MYRROR Study". *Ophthalmology*, 2015. 122(6):1220–7.



¹Nuffield Laboratory of Ophthalmology, Department of Clinical Neurosciences, Oxford University, West Wing, John Radcliffe Hospital, Oxford OX3 9DU, UK. ²Oxford Eye Hospital, John Radcliffe Hospital, Oxford University Hospitals NHS Foundation Trust, Headley Way, Oxford OX3 9DU, UK. ³UCL Institute of Ophthalmology, 11-43 Bath Street, London EC1V 9EL, UK. ⁴NIHR Moorfields Biomedical Research Centre, Moorfields Eye Hospital, London, UK. ✉email: Imran.yusuf@eye.ox.ac.uk

Received: 29 November 2022 Revised: 10 December 2022 Accepted: 13 January 2023

Published online: 04 February 2023

FUNDING

Medical Research Council UK (MR/R000735/1).

COMPETING INTERESTS

The authors declare no competing interests.

ADDITIONAL INFORMATION

Correspondence and requests for materials should be addressed to Imran H. Yusuf.

Reprints and permission information is available at <http://www.nature.com/reprints>

Publisher's note Springer Nature remains neutral with regard to jurisdictional claims in published maps and institutional affiliations.