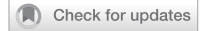



**CORRECTION**



# Correction: Anterior segment optical coherence tomography in ocular surface tumours and simulating lesions

Ahmet Kaan Gündüz , Ibadulla Mirzayev , Aylin Okcu Heper, Işinsu Kuzu, Zarifakhanım Gahramanli, Cevriye Cansız Ersöz, Ömür Özlenen Gündüz and Ömür Ataoğlu

© The Author(s), under exclusive licence to The Royal College of Ophthalmologists 2022

*Eye* (2023) 37:1045; <https://doi.org/10.1038/s41433-022-02378-8>

Correction to: *Eye* <https://doi.org/10.1038/s41433-022-02339-1>, published online 13 December 2022

The original online version of this article was revised: In the legend to Fig 2 the term (B-F) should have read (D-F).

The legend to Figure 2 should be read: Conjunctival melanocytic tumours including conjunctival nevus (A–C), primary acquired melanosis (PAM) (D–F), and conjunctival melanoma (G–I).

The original article has been corrected.