The ROYAL COLLEGE of OPHTHALMOLOGISTS

www.nature.com/eye

ARTICLE

Familial Mediterranean fever associated frosted branch angiitis, retinal vasculitis and vascular occlusion

Hana A. Mansour[1], Pinar Ç Ozdal[2], Sibel Kadayifcilar[3], Ilknur Tugal-Tutkun[4], Hilal Eser-Ozturk[5], F. Nilüfer Yalçındağ[6], Harry Petrushkin[7,8], Errol W. Chan[9,10], Soukaina Belfaiza[11], Remzi Karadag[12,13], Sirel Gür Güngör[14], Maurizio Battaglia Parodi[15] and Ahmad M. Mansour[1,16]✉

OBJECTIVES: To analyse the entity of retinal vasculitis, including frosted branch angiitis (FBA), or retina vascular occlusion in patients with familial Mediterranean fever (FMF).

METHODS: Retrospective collaborative case series using invitation by email to uveitis specialists around the Mediterranean basin. This series was combined with a literature review. Exclusion criteria included infectious diseases, Behçet's disease or other autoimmune diseases.

RESULTS: A total of 16 patients (21 eyes) had FMF and retinal vasculitis (FBA 11 patients, mild retinal vasculitis 5 patients). The mean age at onset of vasculitis was 29.5 ± 13.4 (range 9–62) with a female to male ratio of 9 to 7. In 19 eyes treated with various forms of corticosteroid and/or immunosuppression, the mean initial spectacle-corrected visual acuity improved from 6/194 to 6/10.5 at the last mean follow-up of 29.0 ± 34.9 months ($p < 0.001$). The most common FEVR mutations were M680I and M694V. In addition, retinal vascular occlusions included one case of central retinal artery occlusion and one case of branch retinal artery occlusion.

CONCLUSION: FBA and milder forms of retinal vasculitis are associated with FMF. Therapy involves an increase in colchicine dosage in early cases, a long period of oral corticosteroid, intravitreal dexamethasone implant or periocular corticosteroid in select cases, and combination therapy with systemic immunosuppression in severe cases. FMF needs to be included in the differential diagnosis of retinal vasculitis.

Eye (2022) 36:2157–2162; https://doi.org/10.1038/s41433-021-01822-5

INTRODUCTION

Familial Mediterranean fever (FMF) is one of the most prevalent periodic monogenic autoinflammatory diseases affecting select ethnic groups (Jewish, Armenian, Turkish and Arabic) living around the Mediterranean basin. The prevalence is around 1/500 in Armenians and 1/1000 in Turks. The clinical manifestations in decreasing order include peritonitis, fever, arthritis, pleuritis, myalgia, erysipelas-like rash, and amyloidosis. This genetic disorder results from pathogenic mutations located on the short arm of chromosome 16p13.3 [1–14].

Ocular involvement in FMF is quite uncommon [1–9]. Retinal vasculitis has been reported in a few cases with FMF mostly as pictures and perspectives [10, 11] or letter [12] or briefcase reports [13, 14]. We analyzed the clinical presentation of retinal vasculitis or retinal vascular occlusion in the context of FMF in a retrospective multicenter collaborative study.

MATERIALS AND METHODS

Uveitis specialists practising around the Mediterranean basin and senior authors (cited on Google Scholar) that published on ocular findings in FMF were invited to collaborate. Excel sheet was filled by the collaborators in an anonymous fashion. The study received institutional review board approval (AMM) and followed the tenets of the declaration of Helsinki. Patients were diagnosed clinically according to the Tel Hashomer criteria. Variables included inflammatory blood markers, initial vision, final vision, follow-up time, therapy type dosage and duration. Exclusion criteria included infectious causes like tuberculosis and autoimmune disorders such as Behçet's disease, periarteritis nodosa, IgA vasculitis, lupus, and rheumatoid arthritis. Snellen spectacle-corrected visual acuity was converted to logMAR for statistical analyses. Paired student t-test was calculated to measure the change in visual acuity at the last follow-up. This case series was combined with previously reported cases (PubMed Central and Google Scholar using the search terms retinal vasculitis or retinal vascular occlusion AND FMF before June 2021).

[1]Department of Ophthalmology, American University of Beirut, Beirut, Lebanon. [2]Uveitis and Behçet Disease Service, University of Health Sciences, Department of Ophthalmology, Ulucanlar Eye Training and Research Hospital, Ankara, Turkey. [3]Department of Ophthalmology, Hacettepe University, Ankara, Turkey. [4]Department of Ophthalmology, Istanbul University, Istanbul, Turkey. [5]Department of Ophthalmology, Ondokuz Mayıs University, Samsun, Turkey. [6]Department of Ophthalmology, University of Ankara, Ankara, Turkey. [7]Uveitis and Scleritis Service, Moorfields Eye Hospital, London, UK. [8]Pediatric Uveitis Service, Great Ormond St Hospital, London, UK. [9]Department of Ophthalmology and Visual Sciences, McGill University, Montreal, Canada. [10]Department of Ophthalmology, National University Health System, Singapore, Thailand. [11]Department of Ophthalmology, Mohammed V Military Hospital, Rabat, Morocco. [12]RK Eye, Aesthetic and Health Services, Kadikoy, Istanbul, Turkey. [13]Veni Vidi Eye Center, Caddebostan, Kadikoy, Istanbul, Turkey. [14]Department of Ophthalmology, Başkent University, Ankara, Turkey. [15]Department of Ophthalmology, University Vita-Salute, IRCCS Ospedale San Raffaele, Milan, Italy. [16]Department of Ophthalmology, Rafic Hariri University Hospital, Beirut, Lebanon. ✉email: ammansourmd@gmail.com

Received: 17 May 2021 Revised: 27 September 2021 Accepted: 14 October 2021
Published online: 1 November 2021

Table 1. Clinical parameters of subjects with retinal vasculitis and FMF (*NLP* No light perception; *LP* Light perception; *HM* Hand motion; *NA* Not available; *R* Right; *L* Left; *RL* right and left eye; *CF* Counting finger; *FMF* Familial Mediterranean fever; *MEFV gene* Gene responsible for FMF).

Author [reference]	Case 1	Case 2	Case 3	Case 4	Case 5	Case 6	Case 7	Case 8	Case 9	Case 10	Case 11	Case 12	Case 13	Petrushkin [12]	Özlem [13]	Satoh [14]
Age at time of vasculitis	32	23	32	9	25	18	25	47	13	36	33	62	14	27	37	39
Age at onset of FMF	31	20	24	1	2	2	14	45	5	13	10	56	NA	13	27	childhood
Gender	Female	Female	Male	Female	Female	Female	Female	Male	Male	Male	Female	Female	Male	Female	Male	Male
Race	Caucasian	Caucasian	Caucasian	Caucasian	Caucasian	Caucasian	Caucasian	Caucasian	Caucasian	Caucasian	Caucasian	Caucasian	Caucasian	Caucasian	Caucasian	Asian
Country of origin	Turkey	Turkey	Turkey	Turkey	Lebanon	Lebanon	Morrocco	Middle East	Turkey	Turkey	Turkey	Turkey	Turkey	Spain (Sephardic Jew)	Armenia	Japan
Family history of FMF	Yes	No	Yes	No	Yes	Yes	No	No	Yes	Yes	Yes	No	Yes	No	NA	No
MEFV gene mutations	Homozygote M694V	Heterozygote M680I	NA	Positive	Homozygote M694V	Homozygote M694V	Positive	V726A	NA	NA	M694V R761H R761H	M694Vheterozygote	heterozygous V726A	NA	NA	M694I
Right R/left L eye	L	RL	R	RL	L	L	RL	L	RL	L	R	R	RL	R	L	L
Snellen Initial Vision	HM	20/20	CF30cm	20/50-R 20/25-L	20/200	20/200	LP-R LP-L	20/70	NLP-R CF50cm-L	LP	20/1600	20/70	CF20cm-R CF1.5m-L	20/20	20/200	20/200
Snellen Final Vision	20/20	20/20	20/30	20/20RL	20/25	20/20	20/200-RL	20/30	20/30-R 20/20-L	20/400	20/50	20/20	R CF20cm L CF1.5 m	20/20	20/25	20/20
Visual recovery	Full	Full	Partial	Full	Full	Full	Partial	Full	Full	Partial	Partial	Full	No	Full	Full	Full
Follow up (month)	50	24	30	24	9	120	9	1	8	22	36	102	2	12	2.5	12
Oral corticosteroid	Yes	Yes	Yes	No	Yes	Yes	Yes	Yes	Yes	Yes	No	No	No	No	Yes	Yes
Duration of oral corticosteroid (month)	24	2	3	No	9	6	9	1	>2	6	No	No	No	No	No	5
Systemic Immunosuppression	azathioprine	azathioprine	No	methotrexate/ adalimumab then cyclosporine	No	No	No	No	cyclophosphamide	no	No	No	No	No	No	No
Retinal hemorrhages	Yes	No	Yes	No	Yes	Yes	Yes	Yes	Yes	Yes	Yes	No	Yes	No	Yes	Yes
Cystoid macular edema	No	No	Yes	No	Yes	Yes	Yes	No	No	Yes	Yes	Yes	No	No	yes	Yes
Vitreous hemorrhage	Yes	No	Yes	No	No	No	Yes	Yes	No	Yes	Yes	No	No	No	No	Yes
Disc edema	Yes	No	No	No	Yes	Yes	Yes	No	Yes	No	Yes	No	Yes	No	Yes	Yes
Frosted branch angiitis	Yes	No	Yes	No	Yes	Yes	Yes	Yes	No	Yes	Yes	No	Yes	No	Yes	Yes

RESULTS

This is a retrospective review of 16 cases of FMF associated with retinal vasculitis (Table 1) (including 3 published cases) [12–14] from Belgium (1 case), Canada (1 case), Japan (1 case), Morocco (1 case), UK (1 case), Lebanon (2 sisters), Turkey (9 cases) involving 13 centres with one case of central retinal artery occlusion (Turkey, 1 case). The mean age at onset of the retinal vasculitis was 29.5 ± 13.4 (range 9–62), and the mean age at onset of FMF was 18.4 ± 16.0 (range 1–56). There was a total of 9 women and 7 men, 15 Caucasian and 1 Asian. Family history of FMF was present in 8 patients, absent in 7 patients, and not mentioned in 1 patient. FEVR mutations were not registered in 5 cases but were positive in 11 cases: M680I (3 cases), M694V (3 cases), V726A (2 cases), M694I (1 case), and R761H (1 case having also M694V mutation), and not specified (2 cases). There was a negative workup for antinuclear antibody, antineutrophil cytoplasmic antibody, anti-cyclic citrullinated peptide, rheumatoid arthritis latex, purified protein derivative skin test, chest radiograph and brain magnetic resonance imaging (except one patient had occipital lesion from vasculitis). Erythrocyte sedimentation rate was elevated in 8 patients, while C-reactive protein was elevated in a single patient. Behcet's disease was excluded by the rheumatology consultant and by the absence of recurrent oral and genital ulcers.

In 19 eyes (omitting Case 13 that received laser pan-retinal photocoagulation only) of 15 patients with FMF and retinal vasculitis treated with oral or local corticosteroid, logMAR initial spectacle-corrected visual acuity improved from 1.51 ± 1.30 (Snellen equivalent 6/194 or 20/647) to 0.23 ± 0.40 (Snellen equivalent 6/10.5 or 20/34) (paired t-test $p < 0.001$) after a mean follow-up of 29.0 ± 34.9 months (range 1–120). Nine eyes had initial corrected visual acuity below 6/60 or 20/200: No light perception (1 eye), light perception (2 eyes), hand motion (1 eye), counting finger near the face (3 eyes), and counting finger at 1.5 m (2 eyes). Visual recovery was absent in 2 eyes that underwent solely laser pan-retinal photocoagulation (PRP) and was either partial in 5 eyes or full in 14 eyes that received systemic or local therapies. The left eye was involved in 7 patients, the right eye in 4 patients, and both eyes in 5 patients. Eleven patients (14 eyes) received oral corticosteroid (initial prednisone 1 mg/kg/day) tapered slowly over a mean of 6.9 ± 6.6 months (range 1–24). Fast tapering of oral corticosteroid as sole therapy resulted in recurrence of the retinal vasculitis in 2 cases. Concomitant immunosuppression was given in 7 eyes (4 patients) (azathioprine 1 mg/kg/d alone in 3 eyes, methotrexate with adalimumab followed by cyclosporine in 2 eyes and cyclophosphamide 500 mg/d in 2 eyes). Five patients (7 eyes) did not receive oral corticosteroid: one patient received methotrexate 15 mg/m^2/d with adalimumab 40 mg biweekly then maintained on cyclosporine A 3 mg/kg/d, one patient had an increase in the colchicine dosage, one patient received intravitreal bevacizumab with an increase in the colchicine dosage, one patient underwent pan-retinal photocoagulation, and two patients received intraocular dexamethasone implant. All patients were maintained on oral colchicine (0.5mg–2.5 mg/d) with one subject developing retinal vasculitis 7 months after discontinuing the drug.

Frosted branch angiitis (FBA) occurred in 11 patients (13 eyes) including 2 sisters (Figs. 1–3) (grandparents and parents are first cousins) while a milder form of retinal vasculitis occurred in 5 patients (8 eyes). In a few cases, the initial presentation mimicked other entities delaying proper diagnosis and prompt treatment. In one case (Case 13), the initial diagnosis was central retinal vein occlusion hence pan-retinal photocoagulation was offered initially. Also in Case 10, the initial diagnosis was demyelinating disease (optic neuritis and central nervous system vasculitis) with a very prompt response to systemic corticosteroid while the correct diagnosis was retinal and central nervous system vasculitis from FMF.

Besides retinal vasculitis, two eyes developed central retinal artery occlusion or branch retinal artery occlusion [15] both well-controlled by a short course of oral corticosteroid.

DISCUSSION

Table 1 collected a total of 16 cases having FMF who developed retinal vasculitis (21 eyes) and besides an additional case of central retinal artery occlusion (1 case) and branch retinal artery occlusion (1 case). It seems that FMF is primarily involved in the pathogenesis of retinal vasculitis and needs to be included in the differential of retinal vasculitis and especially with FBA. Similarly, vasculitis can involve other sites such as the central nervous system [16], the heart [17], the skin and the kidneys [18]. The pathogenesis of FMF-associated vasculitis remains still unknown but includes increased serum proinflammatory cytokines (IL-6, IL-18, and INF-γ) and exuberant IL-1β production [19].

FBA consists of a florid translucent retinal perivascular sheathing with variable uveitis, macular oedema and visual loss, Fluorescein angiography shows normal arterial and venous flow and profuse dye leakage from sheathed vessels. FBA may be idiopathic or associated with Behçet's disease, Crohn's disease, lupus or infectious aetiology (cytomegalovirus, herpes simplex type 2, toxoplasmosis, tuberculosis) and blood dyscrasias. Additional retinal findings may include intraretinal haemorrhages, hard exudates, and serous exudative detachments of the macula and periphery. A proposed mechanism of retinopathy involves immune complex deposition in retinal vessels [10–13]. Other theories pointed toward an autoimmune response often triggered by exposure to an infectious agent. Patients complain of sudden onset of blurred vision, central scotomas, floaters, and photopsia,

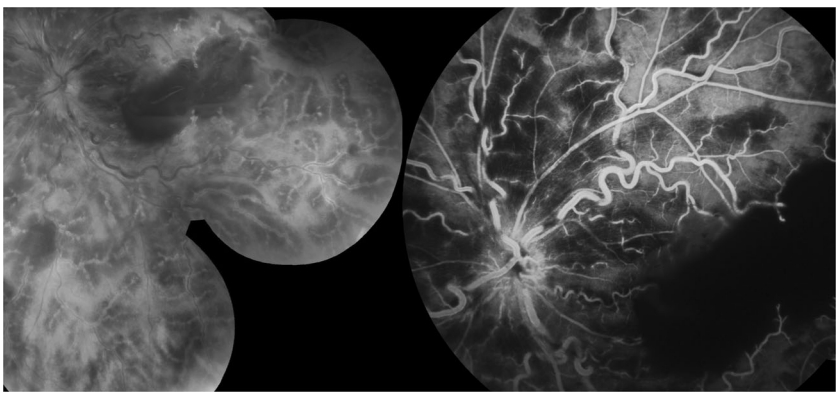

Fig. 1 Comparison between a color fundus montage and a fluorescein angiographic image of the posterior pole. Frosted branch angiitis of the left eye in a 31-year-old Caucasian woman with FMF (case 1) of one-year duration and visual recovery from hand motion to 6/7.5 (20/25) after 2 years of oral corticosteroid with azathioprine.

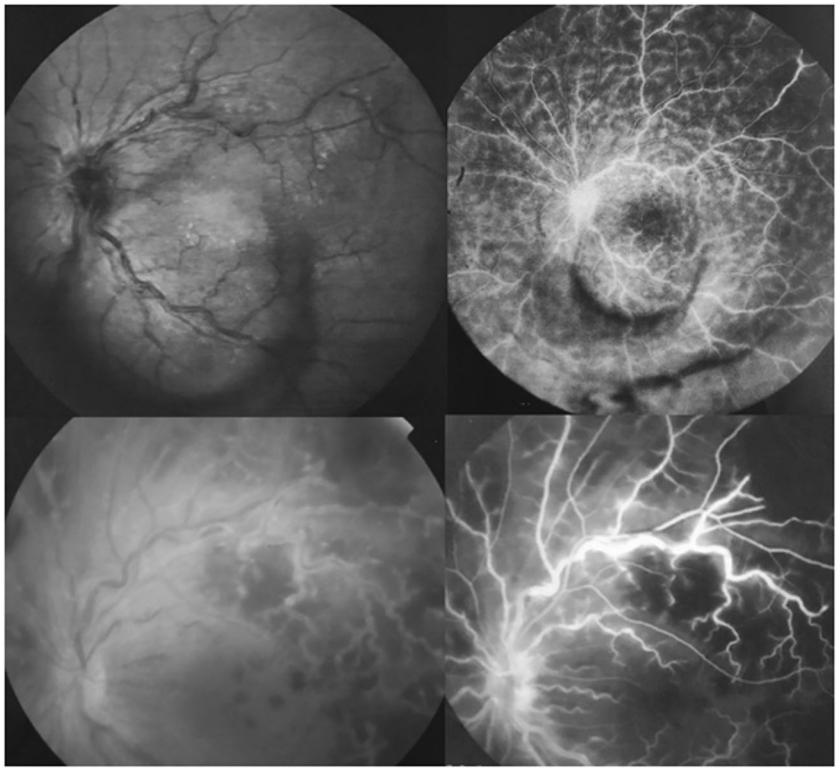

Fig. 2 Comparison between a color fundus image and a fluorescein angiographic image of the posterior pole. Frosted branch angiitis of the left eye in two Caucasian sisters with FMF (Case 5 top, Case 6 bottom). FMF was diagnosed at age 2 years in both sisters. The parents and grandparents are first cousins. FBA responded to oral corticosteroids tapered over 6–8 months with the recovery of vision.

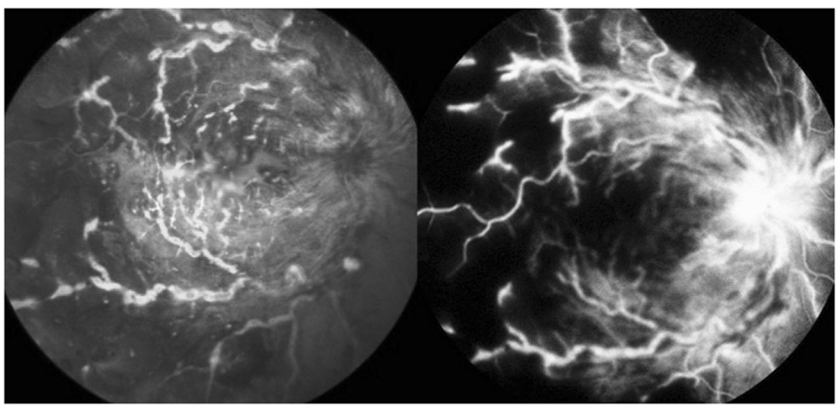

Fig. 3 Comparison between a color fundus image and a fluorescein angiographic image of the posterior pole. Frosted branch angiitis in the right eye of a 33-year-old Caucasian woman with FMF (Case 11) initial vision of 6/480 (20/1600) improving to 6/15 (20/50) up to the last follow-up 36 months after a single intravitreal dexamethasone implant.

and most patients respond to systemic corticosteroid therapy with good recovery of visual acuity. Vitreous haemorrhage is an additional cause of visual loss in FBA being noted in 10 eyes in the current series. The temporal association between the fever, abdominal pain and the visual loss in immunocompetent young subjects coupled with the prompt response to systemic corticosteroid and absence of retinitis rule out CMV as the cause of FBA.

Kölber et al. [15] described a 14-year-old boy with FMF of 12 years duration and controlled on oral colchicine who developed quadrantic visual field loss. Branch retinal occlusion was documented on intravenous fluorescein angiography. Complete workup (coagulation screen, protein electrophoresis, HLA for Behçet's disease) was negative. There was a rapid decrease of the scotoma on initiation of corticosteroid. In the current case series, one patient had FMF-related central retinal artery occlusion responding to corticosteroid therapy. These 2 cases of retinal artery occlusion in young subjects insinuate the idea that some FMF patients exhibit increased vascular morbidity from the prothrombotic condition of massive or covert inflammation that can manifest in an increased intima-media thickness of the carotid artery, enhanced atherosclerosis, hyperfibrinogenemia, and risk of stroke in very young subjects [20].

On chromosome 16.p13.3, the FMF gene, also known as MEFV, encodes the protein pyrin that modulates the activity of target proteins directly involved in inflammation. Cekin et al. [21] did not find any mutations in 55% of 514 Turkish patients with FMF. Five of the most commonly found mutations were M694V (48%), E148Q (18%), M680I (15%), V726A (12.5%) and P369S (3.3%)in the Turkish study (514 patients). Five of the most commonly found mutations were M694V (41.3%), V726A (27.6%), M680I (18.2%),

E148Q (5.3%), R761H (3.4%) in the Armenian study (10,370 patients) [22]. The frequency of symptoms in that Turkish series [21] was as follows: abdominal pain (76%), fever (58%), arthritis (28%) and chest pain (19%). M694V or M680I mutant alleles had the highest frequency of FMF symptoms. In contrast, patients carrying the E148Q or V726A mutant allele showed few clinical FMF symptoms. In other studies, FMF-associated vasculitis was associated with the M694V allele [21]. M694V mutations appear to be of high penetrance, with earlier onset and more severe phenotypes in general FMF symptoms, and probably as well in retinal vasculitis as shown here.

Colchicine is a tricyclic alkaloid administered in Behçet's disease, pericarditis and atrial fibrillation. On July 29, 2009, colchicine won Food Drug Administration approval as a stand-alone drug for the treatment of familial Mediterranean fever. Colchicine impairs neutrophil recruitment migration and function, prevent activation of macrophage (TNF-α receptor expression) and interrupt granule release in mast cells with the end result being decreased levels of the proinflammatory cytokines IL-1β, IL-6, IL-18, and IFNγ [23].

The standard therapy of retinal vasculitis remains the maintenance of an adequate dosage of oral colchicine (1 mg daily). While on maintenance therapy, colchicine lowered CRP to within normal levels in the current study (except in one patient who discontinued the drug). Colchicine is well-known to normalize the CRP level in many inflammatory disorders [24]. A decrease in the dose [1, 12] or discontinuation of the medication results in a flare-up of ocular inflammation. When retinal vasculitis is mild and is caught early, an increase in colchicine dosage may adequately and solely control the inflammation [1, 12]. When the vasculitis is severe with visual decline, systemic corticosteroid for several months can control the vasculitis and prevent recurrences, albeit with a slow taper. When the retinal vasculitis is severe, systemic immunosuppression can supplement the oral corticosteroid (Cases 1, 2, 4 and 9). The indications for longer-term steroid use in FMF are protracted febrile myalgia (a sort of vasculitis), protracted arthritis (belongs to the spectrum of spondyloarthropathy of FMF), and ocular inflammation (scleritis, retinal vasculitis). Panretinal photocoagulation alone did not alter the downhill natural course, while intraocular dexamethasone did control retinal vasculitis in 2 patients. Of note is that severe forms of FBA can be accompanied by an irreversible visual loss in case of delayed control of inflammation.

The current study suffers from a retrospective nature, short follow-up in many cases, absence of virological studies (human immunodeficiency virus, cytomegalovirus, herpes virus), serology for toxoplasma, or work up for either Crohn's disease or blood dyscrasias. Also, there is a lack of a uniform therapeutic strategy because of changing vasculitis regimens over the past decade. Moreover, retina specialists may be geared for laser pan-retinal photocoagulation or intravitreal injections of vascular endothelial growth factor antagonists if FBA is mistaken for retinal venous occlusion (Case 13) [8]. Conservatively, uveitis specialists most often would initiate therapy with oral corticosteroids. However more recently there is a trend for use of intraocular dexamethasone implants or newly approved immunomodulators. Of note is that FMF can rarely present with serositis without fever [25] and that it can involve patients not originating around the Mediterranean basis such as Japan [25] or China [26]. Despite the early presentation of FMF, occasionally late presentations can occur [25] as in the current series and especially so in countries such as Japan or China [24].

In conclusion, FBA with severe visual loss as well as milder forms of retinal vasculitis is associated with FMF. Prompt systemic or local therapy with corticosteroid or dexamethasone implant alone or with concomitant systemic immunosuppression can restore vision. Colchicine therapy remains the best prophylactic tool to prevent retinal vasculitis. The current case series highlights the importance of the recognition of the association of FBA with FMF even outside the endemic areas of FMF.

Summary

What is known about this topic

- Frosted branch angiitis is caused by infections (cytomegalovirus, *Toxoplasma gondii*).
- Frosted branch angiitis is associated with Behcet disease, lupus and Crohn's disease.

What this study adds

- Frosted branch angiitis can be associated with familial Mediterranean fever in the absence of concomitant infection or autoimmune disease.
- Frosted branch angiitis can present with severe visual loss in the context of familial Mediterranean fever either from retinal vasculitis and/or the presence of vitreous haemorrhage.
- Prompt and prolonged therapy for several months with systemic corticosteroids is sight-saving.
- Life-long colchicine therapy is essential in the control and prevention of retinal (or systemic) vasculitis in familial Mediterranean fever.

REFERENCES

1. Petrushkin H, Stanford M, Fortune F, Jawad AS. Clinical review: Familial Mediterranean fever-An overview of pathogenesis, symptoms, ocular manifestations, and treatment. Ocul Immunol Inflamm. 2016;24:422–30.
2. Erdurmuş M, Bekdaş M, Demircioğlu F, Soydan A, Göksügür SB, Kısmet E. Retinal and choroidal thickness in children with familial Mediterranean fever. Ocul Immunol Inflamm. 2014;22:444–8.
3. Gundogan FC, Akay F, Uzun S, Ozge G, Toyran S, Genç H. Choroidal thickness changes in the acute attack period in patients with familial Mediterranean fever. Ophthalmologica 2016;235:72–7.
4. Alim S, Özer S, Demir S, Ortak H, Sönmezgöz E, Er E, et al. Peripapillary retinal nerve fiber layer and ganglion cell-inner plexiform layer thickness in children with familial Mediterranean fever. Ocul Immunol Inflamm. 2016;24:372–6.
5. Karaca EE, Ozek D, Omma A, Evren Kemer O. Comparison of optical coherence tomography angiography results of adult patients with familial Mediterranean fever and healthy individuals. Ther Adv Ophthalmol. 2019;11:2515841419892056.
6. Alim S, Esen M, Demir AK, Demir S, Ortak H, Güneş A, et al. Peripapillary retinal nerve fiber layer and ganglion cell-inner plexiform layer thickness in adult-onset familial Mediterranean fever. Int Ophthalmol. 2018;38:183–90.
7. Bicer T, Celikay O, Kosker M, Alp MY, Ozisler C, Yesilyurt A, et al. Retinal and choroidal thickness in adult patients with familial Mediterranean fever. Ophthalmic Epidemiol. 2017;24:346–51.
8. Ozates S, Ozdal PÇ, Teke MY. Frosted branch angiitis secondary to familial Mediterranean fever resembling central retinal vein occlusion. Case Rep Ophthalmol Med. 2016;2016:2916027. https://doi.org/10.1155/2016/2916027.
9. Mansour AM, Khatib L, Mansour HA. Posterior scleritis in familial Mediterranean fever. Case Rep Ophthalmol. 2019;10:134–9.
10. Chan EW, Sun V, Chen JC. Frosted branch angiitis associated with familial Mediterranean fever. Ophthalmol Retin. 2018;2:1249.
11. Belfaiza S, Zerrouk R, Brarou H, Jeddou I, Abdellaoui T, Mouzari Y, et al. Angéite givrée: Une manifestation rare de la fièvre méditerranéenne familiale. J Fr Ophtalmol. 2021;S0181-5512:30630–6. https://doi.org/10.1016/j.jfo.2020.06.036.
12. Petrushkin HJ, Karagiannis DA, Bird A, Jawad ASM. Intermediate uveitis associated with familial Mediterranean fever. Clin Exp Rheumatol. 2015;33:S170.
13. Özlem K, Willermain F, Caspers L, Postelmans L, El Ouardighi H, Guillaume M-P, et al. Acute frosted retinal periphlebitis in a patient with Mediterranean fever. Retinal Cases Brief Rep. 2020;14:228–231.
14. Satoh S, Itoh C, Nakamura N. A case of frosted branch angiitis associated with retinal vein occlusion as a complication of familial Mediterranean fever. Nippon Ganka Gakkai Zasshi. 2010;114:621–8.
15. Körber N, Jung F, Kiesewetter H, Wolf S, Prünte C, Stolze H, et al. [Television fluorescence angiography and image analysis: clinical use with a case example]. Klin Monbl Augenheilkd. 1985;186:117–20.

16. Luger S, Harter PN, Mittelbronn M, Wagner M, Foerch C. Brain stem infarction associated with familial Mediterranean fever and central nervous system vasculitis. Clin Exp Rheumatol. 2013;31:93–5.
17. Serrano R, Martínez MA, Andrés A, Morales JM, Samartin R. Familial Mediterranean fever and acute myocardial infarction secondary to coronary vasculitis. Histopathology. 1998;33:163–7.
18. Aksu K, Keser G. Coexistence of vasculitides with familial Mediterranean fever. Rheumatol Int. 2011;31:1263–74.
19. Abbara S, Grateau G, Ducharme-Bénard S, Saadoun D, Georgin-Lavialle S. Association of vasculitis and familial Mediterranean fever. Front Immunol. 2019;10:763. https://doi.org/10.3389/fimmu.2019.00763.
20. Aghdashi M, Seidmardani SM, Vossoughian S, Seyed Mokhtari SA. Very rare presentation of cerebrovascular accident in 20-year-old man with familial Mediterranean fever-Case report. Clin Med Insights Case Rep. 2018;11: 1179547617749208. https://doi.org/10.1177/1179547617749208.
21. Cekin N, Akyurek ME, Pinarbasi E, Ozen F. MEFV mutations and their relation to major clinical symptoms of familial Mediterranean fever. Gene 2017;626:9–13.
22. Kriegshäuser G, Enko D, Hayrapetyan H, Atoyan S, Oberkanins C, Sarkisian T. Clinical and genetic heterogeneity in a large cohort of Armenian patients with late-onset familial Mediterranean fever. Genet Med. 2018;20:1583–8.
23. Dasgeb B, Kornreich D, McGuinn K, Okon L, Brownell I, Sackett DL. Colchicine: An ancient drug with novel applications. Br J Dermatol. 2018;178:350–6.
24. Nidorf M, Thompson PL. Effect of colchicine (0.5 mg twice daily) on high-sensitivity C-reactive protein independent of aspirin and atorvastatin in patients with stable coronary artery disease. Am J Cardiol. 2007;99:805–7.
25. Hotta Y, Kawasaki T, Kotani T, Okada H, Ikeda K, Yamane S, et al. Familial Mediterranean fever without fever. Intern Med. 2020;59:1267–70.
26. Wu D, Shen M, Zeng X. Familial Mediterranean fever in Chinese adult patients. Rheumatology. 2018;57:2140–4.

AUTHOR CONTRIBUTIONS

Drafting of the paper: All authors. Critical revision of the paper for important intellectual content: All authors. Data input: All authors. Supervision: All authors. A Mansour confirms final responsibility for the decision to submit for publication.

COMPETING INTERESTS

The authors declare no competing interests.

ADDITIONAL INFORMATION

Correspondence and requests for materials should be addressed to Ahmad M. Mansour.