Eye (2021) 35:2155–2163
https://doi.org/10.1038/s41433-020-01316-w

The ROYAL COLLEGE of OPHTHALMOLOGISTS

ARTICLE

The epidemiology and outcomes of combat ocular trauma among local nationals managed at a deployed military hospital in Afghanistan

William G. Gensheimer[1,2] · Michael T. Kerber[3] · Richard J. Blanch[4,5,6,7]

Received: 20 June 2020 / Revised: 24 September 2020 / Accepted: 11 November 2020 / Published online: 12 February 2021

Abstract

Background/objectives There is limited published data on combat ocular trauma (COT) among local nationals managed at deployed United States (US) and United Kingdom (UK) military hospitals in recent conflicts. We report the epidemiology and outcomes of COT from a deployed military hospital in Afghanistan.

Subjects/methods In this retrospective case series, consecutive injuries requiring ophthalmic surgery at a military hospital in Afghanistan where the sole US and UK ophthalmologist(s) were deployed between January 2017 and September 2019 were reviewed. The main outcomes were mean post-operative visual acuity (VA) in open and closed globe injury and the incidence of retinal detachment after open globe repair.

Results There were 102 eyes of 84 patients who had ocular injuries and underwent ophthalmic surgery at the military hospital. Most patients were male (81 [96%]) and were local nationals (71 [85%]). Blast exposure (82 [80%]) was the most common mechanism of injury. Mean post-operative VA was 1.24 ± 2.29 logMAR (20/348 Snellen equivalent) in open globe injury and 1.59 ± 1.17 logMAR (20/778 Snellen equivalent) in closed globe injury. After open globe repair, retinal detachment developed in 8 of 18 (44%) eyes.

Conclusions COT injuries often resulted in poor post-operative VA and retinal detachment after open globe repair was common. The high incidence and severity of COT sustained by local civilians and combatants in this study may support programs to increase the availability and wear of combat eye protection among local nationals partnered with US and coalition troops.

Introduction

In modern armed conflicts, most combat related injuries and deaths are sustained by local civilians and combatants [1–3]. However, there is limited published data on the epidemiology and outcomes of combat ocular trauma (COT) among local populations from the recent conflicts in Iraq and Afghanistan. Reports on COT have predominately described United States (US) and United Kingdom (UK) service members who underwent primary repair for ocular trauma at a deployed military hospital in the geographic area where they were injured and then were evacuated to hospitals with vitreoretinal surgical support [4–12].

Supplementary information The online version of this article (https://doi.org/10.1038/s41433-020-01316-w) contains supplementary material, which is available to authorized users.

✉ William G. Gensheimer
williamgensheimer@gmail.com

1 Warfighter Eye Center, Malcolm Grow Medical Clinics and Surgery Center, Joint Base Andrews, MD, USA

2 Department of Surgery, Division of Ophthalmology, Uniformed Services University, Bethesda, MD, USA

3 Department of Ophthalmology, United States Air Force Academy, Colorado Springs, CO, USA

4 Academic Department of Military Surgery and Trauma, Royal Centre for Defence Medicine, Birmingham, UK

5 Neuroscience and Ophthalmology, Institute of Inflammation and Ageing, University of Birmingham, Birmingham, UK

6 Department of Ophthalmology, University Hospitals Birmingham NHS Foundation Trust, Birmingham, UK

7 NIHR Surgical Reconstruction and Microbiology Centre, University Hospitals Birmingham NHS Foundation Trust, Birmingham, UK

The US Department of Defense Trauma Registry (DoDTR) and UK Joint Theatre Trauma Registry include data on the incidence of ocular injury and treatment procedures performed on local civilians and combatants. A retrospective review of this data using Abbreviated Injury Scale codes and International Classification of Diseases codes showed that host nation civilians and military accounted for 3876 of 6241 (62%) of open globe injuries treated at coalition military treatment facilities during the Iraq and Afghanistan conflicts [11]. However, the limitation of these registries is that they do not record data for analysing COT outcomes including visual acuity (VA) and other elements of the Ocular Trauma Score. The registries also do not record post-operative follow-up including VA or complications such as retinal detachment and endophthalmitis. We could find no reference in a PubMed search that reported follow-up data on local nationals treated for COT at US, UK, or coalition military treatment facilities from the conflicts in Iraq and Afghanistan.

The US military deploys and organizes health care support services with progressive capabilities referred to as the four roles of care (Roles 1–4) [13]. Combat casualty care begins with aid administered by medics, corpsmen, other members of the unit on the battlefield. Role 1 provides immediate lifesaving measures and initial resuscitation for trauma. Role 2 is a higher echelon of care that continues resuscitation for trauma and provides more advanced management including some surgical capability. Role 3 is a military treatment facility in the theater of operations that provides comprehensive trauma care including specialized surgical capability such as ophthalmology and is often the location for definitive care for local civilians and combatants. Role 4 is a robust military treatment facility in the US or overseas that is the location for definitive care for US military personnel.

The initial management of COT in the military is guided by the Joint Trauma System (JTS) Clinical Practice Guidelines (CPGs) Eye Trauma: Initial Care, which are evidence-based guidelines developed by subject matter experts [14]. For open globe injury, the JTS CPGs recommend administration of systemic fluoroquinolone antibiotics (moxifloxacin or levofloxacin) and vancomycin if available. Terminology to describe ocular trauma injuries have been established by the Ocular Trauma Classification Group and Birmingham Eye Trauma Terminology System (BETTS) [15, 16]. Mechanical eye injuries are classified as open globe or closed globe. Open globe injuries are further categorized as rupture, penetrating, perforating, intraocular foreign body, or mixed mechanism. The zone of injury is categorized as zone I isolated to the cornea, zone II involving the sclera no more than 5 mm posterior to the limbus, or zone III involving the sclera more than 5 mm posterior to the limbus.

The North Atlantic Treaty Organization (NATO) and the US missions in Afghanistan transitioned to train, advise, and assist roles on January 1, 2015 that were officially named Operation Resolute Support (ORS) and Operation Freedom's Sentinel (OFS) respectively. The combat missions in Iraq and Afghanistan that preceded these operations were officially named Operation Iraqi Freedom (OIF) and Operation Enduring Freedom (OEF). The purpose of this study was to report the epidemiology and outcomes of COT among local nationals managed at a deployed military hospital in Afghanistan with limited access to vitreoretinal surgical support during ORS and OFS.

Materials/subjects and methods

Study design

We conducted a retrospective review of all COT surgical cases performed from January 1, 2017 to September 30, 2019 at a Role 3 military hospital in Afghanistan where the sole US and UK ophthalmologist(s) have been deployed during ORS and OFS.

Approval

This review was approved as a Performance Improvement initiative by the United States Central Command Command Surgeon. It was reviewed by the US Army Medical Research and Development Command's Office of Research Protections, Institutional Review Board Office, and given a Not Research Determination (IRB Office Log Number M-10807). This review adhered to the Declaration of Helsinki and all federal and Department of Defense laws and regulations.

Inclusion/exclusion criteria

All patients that were admitted to the deployed Role 3 military hospital and underwent an ophthalmic surgical procedure in the hospital operating room were included in this study. Patients were excluded if they sustained injuries that did not require an ophthalmic surgical procedure.

Records review

The admission, inpatient, and operative reports were reviewed using the hospital Theater Medical Information Program Composite Health Care System Cache (TC2) and DoDTR. For Afghan nationals, outpatient follow-up records were reviewed using the Armed Forced Health Longitudinal Technology Application - Theater (ALTA-T). For US service members, outpatient follow-up records were reviewed

using the Theater Medical Data Store which contains records from military treatment facilities and the Veterans Health Administration. The total number of trauma patients presenting to the deployed emergency department (ED) was determined by reviewing the ED trauma log. Perioperative antibiotics administered within 24 h of the primary surgical procedure were determined by a review of records by the hospital pharmacist. There was a US Air Force ophthalmologist deployed at the hospital from January 2017 to October 2018 and April 2019 to September 30, 2019. There was an UK ophthalmologist deployed at the hospital from November 2018 to September 2019.

Outcomes

Primary outcomes were post-operative VA in open and closed globe injury and the incidence of post-operative retinal detachment after open globe repair. Secondary outcomes were percentage of trauma patients presenting to the ED that underwent an ophthalmic surgical procedure, mechanism of injury, primary ophthalmic surgical procedures, open globe injury classification, and secondary surgical procedures.

Statistical analysis

Data analysis was performed using R as the statistical software. When regressions were performed Shapiro–Wilk tests for normality and Levene's tests of constant variance revealed no definitive evidence that violations of standard simple linear regression assumptions were present with p values > 0.05. For each analysis missing observations were dropped, and no imputation methods were employed in this analysis.

Results

Patient demographics and mechanism of injury

From January 1, 2017 to September 30, 2019, there were 102 eyes (54 right eye, 48 left eye) of 84 patients that had COT injuries and underwent ophthalmic surgery at the hospital (Table 1). There were 18 patients with bilateral COT injuries, 17 were local Afghanistan nationals and one was US active duty military. Most patients were male (81 [96%]). Blast exposures (82 [80%]) from mechanisms including improvised explosive devices (IEDs), vehicle-borne improvised explosive devices (VBEIDs), rocket propelled grenade (RPDs), and grenades were the most common injuries.

There were 71 (85%) Afghan military or civilians that underwent an ophthalmic procedure, 10 (12%) were US active duty military, and 3 (4%) were coalition military (Table 2). There were 1164 trauma patients who presented to the deployed ED including 658 (57%) Afghanistan military or civilian, 305 (27%) US active duty military, and 115 (9%) coalition military. There were 635 trauma patients that underwent surgery including 509 (80%) Afghanistan military or civilian, 66 (10%) US active duty military, and 38 (6%) coalition military. Seven (7%) of trauma patients presenting to the ED underwent an ophthalmic surgical procedure. Thirteen (13%) of trauma patients that underwent surgery had an ophthalmic surgical procedure.

Table 1 Patient demographics and mechanism of injury for 102 eyes of 84 patients with combat ocular trauma injuries.

Patient demographics and mechanism of injury	*n* (%)
Sex	
Male	81 (96)
Female	3 (4)
Eye injured	
Right	54 (53)
Left	48 (47)
Mechanism of injury	
Blast exposure	82 (80)
Gunshot wound	6 (6)
Thermal burn	2 (2)
Motor vehicle accident	2 (2)
Helicopter accident	2 (2)
Blunt	1 (1)
Unknown or not documented	7 (6)

Blast exposures included improvised explosive devices, vehicle-borne improvised explosive devices, rocket propelled grenades, and grenades.

Primary ophthalmic surgical procedures

There were 169 primary ophthalmic surgical procedures performed (Table 3). There were 54 open globes resulting in 35 open globe repairs and 19 enucleations or eviscerations. Among the 54 open globe injuries, 39 (72%) received systemic antibiotics that followed JTS CPGs guidelines, 9 (17%) received systemic antibiotics that did not follow JTS CPGs guidelines, and 6 (11%) did not receive systemic antibiotics or had no documentation of antibiotics being administered. There were 53 eyelid procedures, 76 procedures involving the cornea, conjunctiva, or sclera, including open globe repairs, 1 posterior segment procedure, and 20 orbital procedures including 15 orbital wall fracture repairs.

Open globe injury classification

The injury types for the 54 open globes were 17 (31%) rupture, 2 (4%) penetrating, 10 (19%) intraocular foreign

Table 2 Country of origin for trauma patients who presented to the deployed emergency department, underwent a surgical procedure, and underwent an ophthalmic surgical procedure.

Country of origin	Trauma patients presented to emergency department, *n* (%)	Trauma patients underwent surgical procedure, *n* (%)	Trauma patients underwent ophthalmic surgical procedure, *n* (%)
US active duty military	305 (27)	66 (10)	10 (12)
US non-military	79 (7)	21 (3)	0 (0)
Coalition military	115 (9)	38 (6)	3 (4)
Afghanistan military or civilian	658 (57)	509 (80)	71 (85)
Other or unknown	7 (1)	1 (0)	0 (0)
Total	1164	635	84

body, 3 (6%) perforating, 20 (37%) mixed, and 2 (4%) not documented. All of the 20 mixed mechanism were rupture with intraocular foreign body. Therefore, the type of injury included a rupture mechanism in 68% of open globes. The zones of injury were 8 (15%) zone I, 13 (24%) zone II, 31 (57%) zone III, and 2 (4%) not recorded. Pre-operative VA was not recorded or unable to be assessed because the patient was unresponsive or intubated and sedated in 43 (80%) of eyes.

Post-operative VA and injury type

Post-operative VA was able to be assessed and recorded in 54 of 85 (64%) cases with open or closed globe injury (Fig. 1). Mean post-operative VA was 1.24 ± 2.29 logMAR (20/348 Snellen equivalent) in open globe injury and 1.59 ± 1.17 logMAR (20/778 Snellen equivalent) in closed globe injury. Mean logMAR post-operative VA was 2.84 ± 1.26 in open globe rupture, 2.42 ± 0.88 in open globe mixed mechanism, and 1.87 ± 1.27 in open globe intraocular foreign body. There was no statistically significant difference in post-operative VA when comparing open globe rupture with open globe intraocular foreign body ($p = 0.12$) or open globe mixed with open globe intraocular foreign body ($p = 0.38$).

Post-operative VA and zone of injury

Post-operative VA and pre-operative zone of injury was able to be assessed and recorded in 22 of 54 (41%) open globe injuries. Mean post-operative logMAR VA was 2.31 ± 1.31 in zone I injury, 1.32 ± 1.32 in zone II injury, and 2.81 ± 1.24 in zone III injury. There was no statistically significant difference in post-operative VA between the zone I and II ($p = 0.408$) or zone II and III ($p = 0.103$).

Post-operative outcomes and complications

Follow-up of equal to or greater than 30 days was possible and recorded for 21 of 35 (60%) primary open globe repairs (Table 4). There were 11 local nationals lost to follow-up and 3 coalition military members aeromedically evacuated to their home country with no follow-up records available to review. Final VA at last follow-up for open globe repair was

Table 3 Primary ophthalmic surgical procedures, total of 169 procedures.

Primary ophthalmic surgical procedures	Procedures, *n* (%)
Eyelids	
Eyelid laceration repair, non-marginal	12 (7)
Eyelid laceration repair, marginal, non-canalicular	23 (14)
Eyelid laceration repair, marginal, canalicular	3 (2)
Canthoplasty	4 (2)
Lateral canthotomy with inferior cantholysis	6 (4)
Eyelid abscess drainage	1 (1)
Skin flap	3 (2)
Dacryocystorhinostomy	1 (1)
Cornea, Conjunctiva, and Sclera	
Conjunctival foreign body removal, superficial	13 (8)
Conjunctival foreign body removal, embedded	7 (4)
Corneal foreign body removal	10 (6)
Exploration	8 (5)
Amniotic membrane sutured to ocular surface	1 (1)
Corneal laceration repair, non-perforating	2 (1)
Open globe repair, not involving uveal tissue	5 (3)
Open globe repair, with reposition or resection of uveal tissue	30 (18)
Enucleations and Eviscerations	
Enucleation with implant	9 (5)
Enucleation without implant	0 (0)
Evisceration with implant	3 (2)
Evisceration without implant	7 (4)
Posterior segment	
Intravitreal injection of air	1 (1)
Orbit	
Orbital foreign body removal	5 (3)
Orbital wall fracture repair	15 (9)

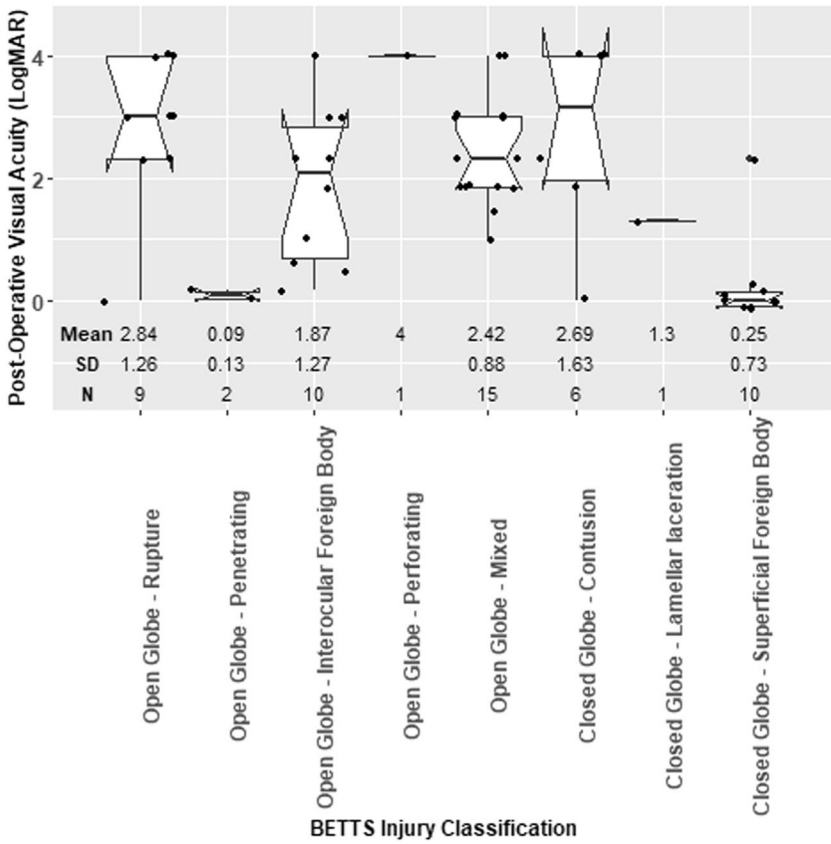

Fig. 1 Post-operative LogMAR visual acuity in 54 of 85 cases with open or closed globe injury where post-operative visual acuity was able to be assessed and recorded. Injuries are classified according to the Birmingham Eye Trauma Terminology System (BETTS) [16]. Mean, standard deviation (SD), and number (N) displayed.

no light perception in 2 (10%) eyes and light perception or hand motion in 10 (48%) eyes. At follow-up, there was a retinal detachment in 11 (52%) eyes and no retinal detachment in 10 (48%) eyes. On pre-operative examination, retinal detachment was noted in 3 of the 11 eyes that had a post-operative retinal detachment. Therefore, retinal detachment developed after open globe repair in 8 of 18 (44%) eyes. There were no cases of post-operative endophthalmitis. Follow-up of equal to or greater than 30 days was possible and recorded for 12 of 19 (63%) primary enucleation or evisceration procedures. Extrusion occurred in 1 eye (8%) that underwent primary enucleation without placement of an implant and then underwent secondary placement of an implant. There were no other cases of exposure, extrusion, or migration of the implant. There were no cases of infection or sympathetic ophthalmia of the contralateral eye.

Secondary surgical procedures

There were a total of 44 secondary ophthalmic surgical procedures performed in theatre (Supplemental Table 1). There were 16 eyelid procedures, 15 procedures involving the cornea, conjunctiva, or sclera including 8 wound revisions for open globes after primary repair, 5 anterior segment procedures, 7 secondary implants for enucleations or eviscerations, and 1 secondary evisceration with implant.

Discussion

We report consecutive epidemiology, management, visual outcomes, and post-operative complications of COT surgical cases from a Role 3 military treatment facility in Afghanistan. In common with previous reports, blast exposure was the most common injury mechanism [5–7, 9, 10]. In contrast to previous reports detailing the management and outcomes of COT in US, UK, and coalition service members who were evacuated to military treatment facilities outside the theatre of operation with vitreoretinal surgical capability, 85% of cases in this series were local nationals who were managed in country at the Role 3 military hospital [4, 6–9, 11]. Deployed ophthalmic care has some limitations and differences to that provided after evacuation. At the military hospital in this review, there was no vitreoretinal surgical capability and referral within country or out of the country to hospitals with that capability was usually not possible. These COT injuries often resulted in poor post-operative VA and post-operative retinal detachment after open globe repair was common.

Table 4 Post-operative outcomes and complications.

Outcomes and complications after open globe repair[a]	Eyes, *n* (%)
Final visual acuity	
No light perception	2 (10)
Light perception or hand motion	10 (48)
1/200–19/200	5 (24)
20/200–20/50	1 (5)
≥20/40	3 (14)
Retinal detachment	
Yes[b]	11 (52)
No	10 (48)
Endophthalmitis	0 (0)
Yes	0 (0)
No	21 (100)
Complications after enucleation or evisceration[c]	Eyes, *n* (%)
Exposure, extrusion, or migration of implant	
Yes[d]	1 (8)
No	11 (92)
Infection	
Yes	0 (0)
No	12 (100)
Sympathetic ophthalmia of contralateral eye	
Yes	0 (0)
No	12 (100)

[a]Open globe repair with or without uvea. Follow-up of ≥30 days for 21 of 35 (60%) procedures.

[b]On pre-operative examination, retinal detachment was noted in 3 of the 11 eyes that had a postoperativeretinal detachment. Therefore, retinal detachment developed after open globe repair in 8 of 18 (44%) eyes.

[c]Enucleation or evisceration with primary or secondary implant. Follow-up of ≥30 days for 12 of 19 (63%) procedures.

[d]Extrusion occurred in one eye that underwent primary enucleation without placement of an implant and then underwent secondary placement of an implant.

The high incidence and severity of COT sustained by local civilians and combatants in this study may support programs to increase the availability and wear of combat eye protection among local nationals partnered with US and coalition troops in the future. There are several possible explanations why local nationals comprised 57% of the trauma patients presenting to the ED but 85% of trauma patients that underwent an ophthalmic surgical procedure. During ORS and OFS, the sole coalition ophthalmologist(s) in Afghanistan were deployed to the Role 3 military hospital in this study. Therefore, local nationals with COT who were eligible for care at coalition military treatment facilities were often transferred to this hospital. In addition, US and coalition casualties have decreased during ORS and OFS, which may have resulted in a decrease in the incidence of COT among US and coalition service members [17, 18]. Although we could not find data on the wear of eye protection among local nationals based upon a records review and PubMed search, the lack of availability and lower rates of combat eye protection wear among local nationals is perceived by the authors to be an important factor for the higher incidence of COT among local nationals. Adoption of military combat eye protection wear among US service members has increased and has been shown to decrease the incidence and severity of ocular injury [10, 19]. Eyewear products that meet the Army standards for tactical eye protection are included on the Authorized Protective Eyewear List (APEL) [20]. A retrospective review of data from the US DoDTR found a statistically significant difference in the incidence of eye injury among US casualties who reported wearing eye protection (17%) compared with those do who did not report wearing eye protection (26%) [21]. There are several reasons why military members and civilians do not wear eye protection including the additional cost, limited availability, added weight or bulk of protective equipment, fogging, and cultural norms [10].

Similar to the OEF and OIF conflicts, most injuries were due to blast mechanisms [5, 9]. Blast injuries often result in polytrauma with multiple injuries that include ocular trauma [10]. In this case series, 7% of trauma patients presenting to the ED underwent an ophthalmic surgical procedure and 13% of trauma patients that underwent surgery had an ophthalmic surgical procedure. This is similar to the reported incidence of COT during OIF and OEF of 10–15% of combat trauma injuries [5, 9]. The type of injury included a rupture mechanism in 68% of injuries, which is higher than the rates of 10% and 43% previously reported for COT in OEF and OIF. [5, 9] This may indicate a higher injury severity in this cohort than reported in previous case series that did not include local national military or civilians. Full thickness wounds in zone III occurred in 57% of injuries in this review, which is similar to the rates of 58% and 66% previously reported for COT in recent conflicts [8, 9].

With modern techniques of primary open globe repair and anterior segment surgery, this review demonstrated the natural history of post-operative complications after open globe repair of COT at a deployed military hospital without access to vitreoretinal surgery in most cases. In this series, retinal detachment developed in 44% eyes after open globe repair. In high risk open globe injuries, as defined by initial VA, zone of injury, and presence of a vitreous haemorrhage, rates of 73–86% retinal detachment after open globe injury have been reported [22, 23]. The rate of retinal detachment in this series should be considered in the context of the high severity of injuries from blast mechanisms, barriers to follow-up for local national patients, and the lack of access to vitreoretinal surgery in Afghanistan. The

absence of vitreoretinal capabilities in theatre and difficulty in referring Afghans in country or outside the country due to security and logistics barriers resulted in poor visual outcomes for some patients despite successful primary open globe repair.

There were no cases of post-operative endophthalmitis after open globe repair in our series. Most patients received prophylactic systemic antibiotics including 72% that received systemic antibiotics that followed JTS CPGs guidelines and 17% that received systemic antibiotics that did not follow JTS CPGs guidelines. This is similar to prior US military reports that have showed low rates of endophthalmitis after open globe repair and delayed intraocular foreign body removal [7, 9]. This is in contrast to other published reports that have shown higher rates of endophthalmitis after open globe repair and identified risk factors such as time to repair, ruptured lens capsule, dirty wound, and age as being associated with the development of post-traumatic endophthalmitis [24–26].

In this case series, we were not able to obtain accurate time of injury data despite a review of all available records and databases. Most patients were aeromedically evacuated to the hospital by helicopter. The JTS CPGs recommend "evacuation of all vision-threatening injuries so they are able to receive treatment by an eye surgeon within 24 h if possible." The "if possible" clause is added to account for aeromedical evacuation delays due to factors such as military operations, polytrauma injuries, aeromedical transport availability, weather, night-time missions, and proximity to medical care. Those same factors also affected the assessment of COT and documentation of information including time of injury at lower echelons of care. Most patients underwent primary repair within hours of arrival at the hospital unless other medical interventions were required to preserve the life of the patient.

There are limitations and potential biases in this retrospective review. The loss to follow-up for Afghanistan military members and civilians can introduce selection bias and limits the validity of follow-up outcomes. Follow-up for local nationals is often limited because of ongoing combat operations, security risks, lack of transportation, the remote geography of the country, or because arrangements were made for disposition closer to their family or military unit. Another limitation is that the Role 3 military hospital in this review had advanced sub-specialty services and accepted the transfer of some of the most severely wounded trauma patients that could not be managed at lower echelons of care. In addition, not all military or civilian patients were eligible to receive care at the hospital. Therefore, the types of injuries seen at this hospital may not be reflective of ocular trauma injuries in Afghanistan during ORS and OFS.

Another limitation of this study was the difficulty in assessing and documenting pre-operative VA in 80% cases. Vision could not be assessed in some cases because the patient was unresponsive or intubated and sedated. The acuity of other injuries and need to perform life-saving measures sometimes limited the safety and timing of performing an eye exam and testing VA in other cases. The lack of pre-operative VA data limited the sample sizes needed to perform some statistical analysis such as correlating pre-operative VA or pre-operative ocular trauma scores with post-operative VA and outcomes. The age of patients in this series was not reported because the age of Afghans was often either unknown or not recorded. The outcomes of orbital wall fracture repairs were not reported in this study because they were described in a separate study on combat facial trauma [27].

One of the expeditionary ophthalmologist's primary roles during deployment is the surgical management of eye trauma. This case series provides the most recent snapshot of the knowledge, skills, and abilities required of the expeditionary ophthalmologist in the current conflicts. The core competencies of the expeditionary ophthalmologist are eyelid laceration repair, open globe repair, and enucleation or evisceration. However, a wide range of primary and secondary procedures were performed in theatre including complex oculoplastic, corneal, anterior segment, and orbital procedures. In cases where the expeditionary ophthalmologist may not have the necessary equipment or lacks the knowledge, skills, and abilities to manage complex cases, teleophthalmology may improve and extend care by providing consultation with sub-speciality experts [28].

The expeditionary ophthalmologist functions as an important part of the deployed surgical team at military hospitals. In this case series, 13% of the surgical cases underwent an ophthalmic procedure. Most ophthalmic trauma management in our current conflicts is in local nationals, where the expeditionary ophthalmologist functions as an isolated practitioner without the ability to refer to tertiary care subspecialties. The outcomes here underscore the importance of prompt access to vitreoretinal surgery to facilitate improved long-term outcomes in the patients who develop retinal detachment after open globe repair.

Summary

What was known before

- In modern armed conflicts, most COT injuries are sustained by local civilians and combatants.
- The US DoDTR does not have follow-up data on COT injuries including post-operative VA after open globe repair.

What this study adds

- Local nationals accounted for 85% of COT injuries that underwent ophthalmic surgery at a Role 3 military hospital in Afghanistan between January 2017 and September 2019.
- COT injuries among local nationals often resulted in poor VA outcomes and post-operative retinal detachment was common after open globe repair.

Disclaimer statement

The views, opinions and findings contained in this paper are those of the authors and do not necessarily reflect the views of the Department of Defense (DoD) or Air Force and should not be construed as an official DoD or Air Force position, policy, or decision unless so designated by other documentation. No official endorsement should be made. Reference herein to any specific commercial products, process, or service by trade name, trademark, manufacturer, or otherwise, does not necessarily constitute or imply its endorsement, recommendation, or favouring by the U.S. Government. This work has not been previously presented at a conference/published as a conference abstract.

Acknowledgements The authors would like to thank Dr Ramesh Natarajan and Dr David King of the Henry M. Jackson Foundation for the Advancement of Military Medicine (HJF) for technical editing of this paper and statistical analysis.

Funding This research did not receive any specific grant from funding agencies in the public, commercial, or not-for-profit sectors.

Compliance with ethical standards

Conflict of interest The authors declare that they have no conflict of interest.

Publisher's note Springer Nature remains neutral with regard to jurisdictional claims in published maps and institutional affiliations.

References

1. Wild H, Stewart BT, LeBoa C, Stave CD, Wren SM. Epidemiology of injuries sustained by civilians and local combatants in contemporary armed conflict: an appeal for a shared trauma registry among humanitarian actors. World J Surg. 2020; 44:1863–73.
2. Tapp C, Burkle FM, Wilson K, et al. Iraq War mortality estimates: a systematic review. Confl Health. 2008;2:1.
3. Iraq Family Health Survey Study Group, Alkhuzai AH, Ahmad IJ, et al. Violence-related mortality in Iraq from 2002 to 2006. N Engl J Med. 2008;358:484–93. https://doi.org/10.1056/NEJMsa0707782.
4. Colyer MH, Chun DW, Bower KS, Dick JSB, Weichel ED. Perforating globe injuries during operation Iraqi Freedom. Ophthalmology. 2008;115:2087–93.
5. Blanch RJ, Bindra MS, Jacks AS, Scott RAH. Ophthalmic injuries in British Armed Forces in Iraq and Afghanistan. Eye (Lond). 2011;25:218–23.
6. Justin GA, Baker KM, Brooks DI, Ryan DS, Weichel ED, Colyer MH. Intraocular Foreign Body Trauma in Operation Iraqi Freedom and Operation Enduring Freedom: 2001 to 2011. Ophthalmology. 2018;125:1675–82.
7. Colyer MH, Weber ED, Weichel ED, et al. Delayed intraocular foreign body removal without endophthalmitis during Operations Iraqi Freedom and Enduring Freedom. Ophthalmology. 2007;114: 1439–47.
8. Vlasov A, Ryan DS, Ludlow S, et al. Corneal and Corneoscleral Injury in Combat Ocular Trauma from Operations Iraqi Freedom and Enduring Freedom. Mil Med. 2017;182:114–9.
9. Weichel ED, Colyer MH, Ludlow SE, Bower KS, Eiseman AS. Combat ocular trauma visual outcomes during operations iraqi and enduring freedom. Ophthalmology. 2008;115:2235–45.
10. Weichel ED, Colyer MH. Combat ocular trauma and systemic injury. Curr Opin Ophthalmol. 2008;19:519–25.
11. Breeze J, Blanch RJ, Mazzoli R, DuBose J, Bowley DM, Powers DB. Comparing the Management of Eye Injuries by Coalition Military Surgeons during the Iraq and Afghanistan Conflicts. Ophthalmology. 2020;127:458–66.
12. Blanch R, Scott RaH. Military ocular injury: presentation, assessment and management. BMJ Mil Health. 2009;155:279–84.
13. Roles of Medical Care (United States). In: Emergency War Surgery. https://www.cs.amedd.army.mil/FileDownloadpublic.aspx?docid=6f9e0685-1290-4e92-8277-c1e7b0f2fef0. Accessed Nov, 2019.
14. Gensheimer WG, Mazzoli R, Reynolds M, et al. Eye Trauma: Initial Care (CPG ID:03). Joint Trauma System Clinical Practice Guideline (JTS CPG). August 2019. https://jts.amedd.army.mil/assets/docs/cpgs/JTS_Clinical_Practice_Guidelines_(CPGs)/Eye_Trauma_Initial_Care_28_Aug_2019_ID03.pdf. Accessed 30 Aug, 2020.
15. Pieramici DJ, Sternberg P, Aaberg TM, et al. A system for classifying mechanical injuries of the eye (globe). The Ocular Trauma Classification Group. Am J Ophthalmol. 1997;123:820–31.
16. Kuhn F, Morris R, Witherspoon CD. Birmingham Eye Trauma Terminology (BETT): terminology and classification of mechanical eye injuries. Ophthalmol Clin North Am. 2002;15:139–43.
17. U.S. Department of Defense Casualty Status. Published August 24, 2020. Accessed Aug, 2020. https://www.defense.gov/casualty.pdf.
18. Blanch RJ, Kerber MT, Gensheimer WG. Deployed ophthalmic workload in support of US and NATO operations in Afghanistan. BMJ Mil Health. March 2020. https://doi.org/10.1136/bmjmilitary-2019-001379.
19. Auvil JR. Evolution of Military Combat Eye Protection. US Army Med Dep J. 2016;135–9.
20. PEO Soldier | Approved Eyewear. Authorized Protective Eyewear List (APEL®). Accessed 27 Aug, 2020. https://www.peosoldier.army.mil/equipment/eyewear/.
21. Thomas R, McManus JG, Johnson A, Mayer P, Wade C, Holcomb JB. Ocular injury reduction from ocular protection use in current combat operations. J Trauma. 2009;66:S99–103.
22. Brodowska K, Stryjewski TP, Papavasileiou E, Chee YE, Eliott D. Validation of the Retinal Detachment after Open Globe Injury (RD-OGI) Score as an Effective Tool for Predicting Retinal Detachment. Ophthalmology. 2017;124:674–8.
23. Stryjewski TP, Andreoli CM, Eliott D. Retinal detachment after open globe injury. Ophthalmology. 2014;121:327–33.
24. Thompson JT, Parver LM, Enger CL, Mieler WF, Liggett PE. Infectious endophthalmitis after penetrating injuries with retained intraocular foreign bodies. National Eye Trauma System. Ophthalmology. 1993;100:1468–74.

25. Thompson WS, Rubsamen PE, Flynn HW, Schiffman J, Cousins SW. Endophthalmitis after penetrating trauma. Risk factors Vis Acuity Outcomes Ophthalmol. 1995;102:1696–701.
26. Essex RW, Yi Q, Charles PGP, Allen PJ. Post-traumatic endophthalmitis. Ophthalmology. 2004;111:2015–22.
27. Breeze J, Gensheimer W, DuBose JJ. Combat Facial Fractures Sustained During Operation Resolute Support and Operation Freedom's Sentinel in Afghanistan. Mil Med. https://doi.org/10.1093/milmed/usaa159.
28. Gensheimer WG, Miller KE, Stowe J, Little J, Legault GL. Military Teleophthalmology in Afghanistan Using Mobile Phone Application. JAMA Ophthalmol. Published online August, 2020. https://doi.org/10.1001/jamaophthalmol.2020.3090.