Eye (2021) 35:1050–1053
https://doi.org/10.1038/s41433-020-01134-0

The ROYAL COLLEGE of OPHTHALMOLOGISTS

COMMENT

Contamination of reusable Honan balloons during routine sub-Tenon blocks: a cause for concern

Shashi B. Vohra[1]

Received: 20 July 2020 / Revised: 29 July 2020 / Accepted: 5 August 2020 / Published online: 17 August 2020

Introduction

Honan balloon is a reusable oculo-compressive device. It is routinely used to help dissipate local anaesthetic, reduce intraocular pressure and improve quality of ocular blocks (http://www.honanballoon.com/). Sub-Tenon local anaesthetic block (STB) is a routine procedure used for providing surgical anaesthesia for ophthalmic procedures. A back seepage of local anaesthetic during oculo-compression following STB poses a risk of contamination of the balloon as it overlies eye pad. Currently, there are no studies addressing the incidence of contamination of reusable Honan balloons. This prospective study examined the presence of blood on the Honan balloon as an indicator of contamination, a potential risk of transmission of pathogens.

Materials and methods

Siemens Multisticks® 8 SG were used to reveal blood on the surfaces studied. These multi-sticks have eight reactive pads. The fifth pad from the tip is designed to detect blood. The pseudoperoxidase in haemoglobin catalyses the reaction between the haem and the chromogen tetramethylbenzidine, which when oxidized attains a green-blue colour. This pad has ability to detect 5 erythrocytes/µl and haemoglobin 0.03 mg/µl. The negative yellow pad turns dark green on contact with red blood cells whilst microscopic blood shows up as just a tinge or speckles of green.

These multi-sticks were first evaluated for their suitability for this study.

Set 1

A drop of blood was placed on a clean plastic film, which was then wiped clean to remove all visual trace of blood. A few drops of sterile water were then placed on the film and multi-sticks were used to see if they could detect any microscopic blood residue.

Set 2

(a) Sterile water, (b) clean work surfaces, (c) clean plastic films and (d) the universal germicidal wipes used to disinfect the Honan balloons were tested individually to see if any of them independently changed the colour of the test pad.

Set 3: clinical setting

A total of 30 routine, elective, inferomedial sub-Tenon blocks were performed by an experienced anaesthetist using a standard technique described by Stevens [1]. There were no haemorrhagic or any other complications. After completion of injection of LA, the eye was wiped dry, and an eye pad was placed on the closed lids. A Honan balloon was secured on the eye pad and inflated to 32 mmHg for 5 min, after which the eye pad and the balloon were removed and inspected for visual evidence of blood.

A multi-stick was pressed on the top surface of the used eye pad and change in the colour of the test-pad on the stick noted. Same procedure was repeated for the ocular surface of the used Honan balloon. If the surface appeared to be dry, a few drops of sterile water were used to haemolyse any potential erythrocytes and change in colour of the test-pad noted.

A total of 30 paired samples of the eye pads and the Honan balloons were thus tested.

Set 4

This arm of the investigation included random spot tests of ten conventionally cleaned and ‘disinfected’ Honan balloons for presence of blood residue as described above.

✉ Shashi B. Vohra
shashi@vohra.org.uk

[1] Birmingham and Midland Eye Centre, City Hospital, SWBH NHS Trust, Birmingham, UK

Results

Set 1

The fifth pad of multi-stick turned green indicating that it was sensitive enough to detect microscopic blood on plastic sheet on which a drop of blood had been placed and wiped clean.

Set 2: clean controls

There was no change in the colour of the test-pads (fifth from the tip) when tested with sterile water on its own, or with universal germicidal wipes. (Fig. 1a). Direct contacts with clean work surfaces and clean plastic sheets were also negative.

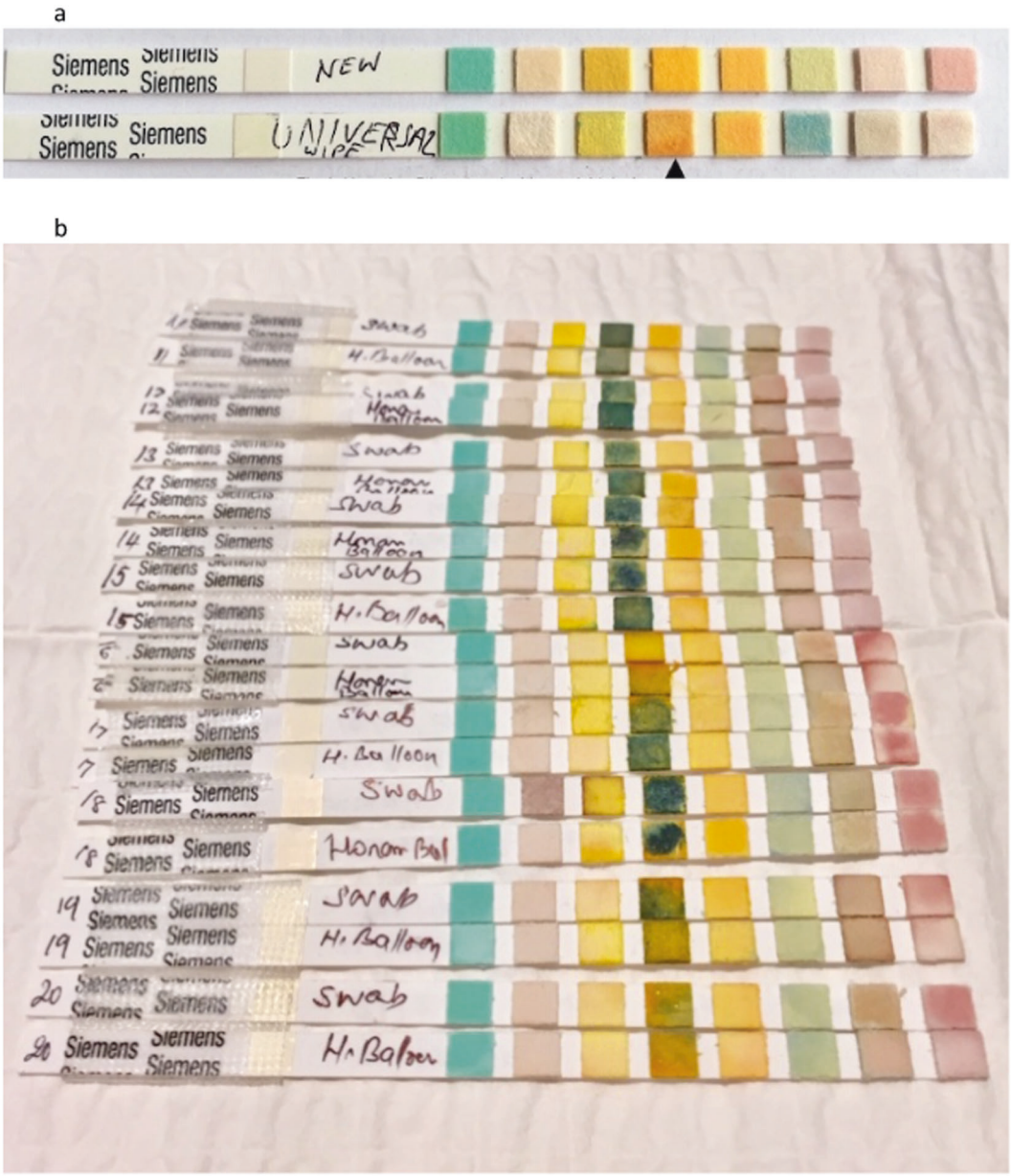

Fig. 1 Siemens multi-sticks® 8 SG showing colour of the test-pads (fifth from the tips). a Examples of clean controls: on the top is a new unused multi-stick. The one below shows unchanged colour of the test-pad (fifth from the tip) when tested with universal germicidal wipe. **b** A selection of multi-sticks showing green discolouration of the test-pads (fifth from the tips) indicating presence of blood on the used eye pads and their corresponding Honan balloons.

Set 3: clinical setting

Eye pads

Of the 30 eye pads, the upper surfaces of 16 (53.3%) were visibly wet with blood tinged fluid, 14 (46.7%) were just damp. The test pads of the multi-sticks turned intensely green in 21 (70.3%) cases and 9 (29.7%) developed mild green hue, indicating presence of blood (Fig. 1b).

Honan balloons

Some balloons had wet surfaces due to ocular fluids having seeped back, others were dry. It was difficult to see blood with the naked eye due to black colour of the device. When tested with the multi-sticks, 16/30 (53.3%) were positive for overt blood and 14/30 (46.7%) revealed traces (Fig. 1b).

Set 4: random spot tests

Traces of residual blood were found within creases of the balloons in three out of ten instances. It was difficult to know if the balloons had previously been used for STB, or peribulbar blocks, or how long they had been sitting around on the trolleys after cleaning and disinfection. This arm of investigation was not pursued any further as it was difficult to standardise all variables.

Discussion

Back seepage of fluid from closed lids following STB is not unusual. The eye pads protect the eye and soak up the fluid. An overlying Honan balloon being in direct contact with the eye pads is consequently at a risk of getting contaminated with the fluid.

Manufacturers recommend that balloons be cleaned with recognised germicidal wipes. Wet wash, autoclaving or gas sterilisation is prohibited. The wipes contain cationic biocides, which are effective against MRSA, *Staphylococcus aureus*, Listeria, Salmonella, Hepatitis B and C, HIV, H5N1 and Norovirus. 99.9% of pathogens are killed after 10 s of contact with the wipes. Norovirus can take 1 min, Influenza H1N1 and H3N2 need 2 min, *Enterococcus hirae* and Pseudomonas require up to 5 min. Some spores are resistant and escape altogether.

In practice, the contact with the germicidal wipes happens to be variable, often less than 1 or 2 min. The shape of the concertina balloon means that some sections might not get sufficient contact with the germicidal and pathogens may escape altogether posing a risk of cross infection.

This study shows that all Honan balloons get contaminated with blood after STB. Some have frank soiling, in others the contamination is microscopic. Owing to the black rubber construction of the balloon the blood staining is not visible. This presents a biohazard and needs to be addressed as conventional surface cleaning may not always guarantee adequate disinfection.

One solution is to use disposable oculo-compressive devices. Unfortunately, these devices unlike standard Honan balloons may not apply consistent, or, measurable pressure. They also pose a significant economic and environmental burden for routine use.

Manual ocular massage as a substitute is dangerous as it varies with technique, build and strength of the clinician. It is inconsistent, unmeasurable, uncontrollable and potentially sight threatening to vulnerable eyes with borderline vascularity particularly in an orbit full of local anaesthetic [2, 3].

Not applying any oculo-compression is not an option as chemosis, higher intraocular pressure, poor akinesia and sub-optimal surgical conditions ensue due to uneven dispersion of LA [4].

A suggested way forward

Since safe oculo-compression is an integral part of local anaesthetic eye blocks, the way forward is to continue the use of reusable Honan balloons but interpose an additional barrier in between the eye pad and overlying balloon in the form of a disposable, impermeable, purpose made, thin sleeve/pouch that can be slipped over the entire balloon to avoid its soiling. The author suggests until such a purpose made sleeve/pouch is manufactured, a glove could be used to cover the business end of the balloon and the distal segment of its tubing.

Conclusion

This study showed that reusable Honan balloons get soiled with blood/ocular fluids after sub-Tenon blocks. Conventional cleaning cannot guarantee complete elimination of contaminants.

In the interest of patient safety, and prevention of cross infection, a disposable impermeable barrier should be interposed between the balloon and the patient's eye.

Compliance with ethical standards

Conflict of interest The author declares no conflict of interest.

References

1. Stevens JD. A new local anaesthesia technique for cataract extraction by one quadrant sub-Tenon's infiltration. Br J Ophthalmol. 1992;76:670–74.
2. Ernest JT, Goldstick TK, Stein MA, et al. Ocular massage before cataract surgery. Trans Am Ophthalmol Soc. 1985;83:205–17.
3. Bullock JD, Warwar RE, Green WR. Ocular explosion during cataract surgery: a clinical, histopathological, experimental, and biophysical study. Trans Am Ophthalmol Soc. 1998;96: 243–81.
4. Kumar CM, Eid H, Dodds C. Sub-Tenon's anaesthesia: complications and their prevention. Eye. 2011;25:694–703.