

ARTICLE OPEN



The phenotype of MEGF8-related Carpenter syndrome (CRPT2) is refined through the identification of eight new patients

Laura M. Watts¹, Marta Bertoli², Tania Attie-Bitach^{3,4}, Natalie Roux³, Antonio Rausell^{3,4}, Cate R. Paschal⁵, Jessica L. Zamboni⁶, Cynthia J. Curry^{7,8}, Blanche Martin^{9,10}, Rebecca S. Tooze⁹, Lara Hawkes¹, Usha Kini¹, Stephen R. F. Twigg⁹ and Andrew O. M. Wilkie^{1,9}✉

© The Author(s) 2024

Carpenter syndrome (CRPTS) is a rare autosomal recessive condition caused by biallelic variants in genes that encode negative regulators of hedgehog signalling (*RAB23* [CRPT1] or, more rarely, *MEGF8* [CRPT2]), and is characterised by craniosynostosis, polysyndactyly, and other congenital abnormalities. We describe a further six families comprising eight individuals with *MEGF8*-associated CRPT2, increasing the total number of reported cases to fifteen, and refine the phenotype of CRPT2 compared to CRPT1. The core features of craniosynostosis, polysyndactyly and (in males) cryptorchidism are almost universal in both CRPT1 and CRPT2. However, laterality defects are present in nearly half of those with *MEGF8*-associated CRPT2, but are rare in *RAB23*-associated CRPT1. Craniosynostosis in CRPT2 commonly involves a single midline suture in comparison to the multi-suture craniosynostosis characteristic of CRPT1. No patient to date has carried two *MEGF8* gene alterations that are both predicted to lead to complete loss-of-function, suggesting that a variable degree of residual *MEGF8* activity may be essential for viability and potentially contributing to variable phenotypic severity. These data refine the phenotypic spectrum of CRPT2 in comparison to CRPT1 and more than double the number of likely pathogenic *MEGF8* variants in this rare disorder.

European Journal of Human Genetics; <https://doi.org/10.1038/s41431-024-01624-9>

INTRODUCTION

Carpenter syndrome (CRPTS) is an autosomal recessive disorder characterised by the core features of craniosynostosis and polysyndactyly of the hands and feet, with other reported features including obesity, congenital heart disease and cryptorchidism [1]. Originally described in 1901 in a family with craniosynostosis and polysyndactyly [2], the most common form of CRPTS (CRPT1; OMIM 201000) was shown in 2007 to be caused by biallelic pathogenic variants in *RAB23* [3, 4]. *RAB23* encodes a small GTPase that is a negative regulator of hedgehog signalling and loss of *RAB23* function causes excessive hedgehog signalling resulting in craniosynostosis and polydactyly. Although the precise mechanism by which *RAB23* represses hedgehog signalling remains unclear, there is evidence for differential regulation by *RAB23* of downstream *GLI* transcription factors (repression of *GLI2*, activation of *GLI3* repressor) [3, 5–8]. Since the original description of *RAB23*-associated CRPTS in 17 affected individuals [3], a further 22 cases have been described with common additional features including facial dysmorphism, short stature with obesity, cryptorchidism, congenital heart disease and variable developmental delay [4, 9–15]. Rarely, patients heterozygous for megabase-sized deletions of chromosome 7p14.1, including *GLI3* and multiple contiguous genes, may present with a phenotype that overlaps with CRPTS [16, 17].

In 2012 a second genetic type of CRPTS (CRPT2; OMIM 614976) was delineated, caused by biallelic alterations in the gene encoding multiple epidermal-growth-factor-like-domains 8 (*MEGF8*). The initial report featured five affected individuals from four families, who harboured biallelic variants (missense, nonsense or splicing) in *MEGF8*. Analysis of the missense variants in a zebrafish embryo assay supported that these were deleterious for protein function. Although substantial clinical overlap was observed with *RAB23*-associated CRPTS, abnormal left-right patterning was more frequent (3/5 cases) [18] and mirrored observations in mice. Mice with alterations in *Megf8* have polydactyly and altered left-right patterning, similar to those found in humans [19–21], whilst morpholino knockdown of *megf8* in zebrafish also results in alterations in left-right patterning [19]. Mechanisms underlying the phenotype are unclear, although similar to *RAB23*, evidence supports *MEGF8* as a negative regulator of hedgehog signalling [22]. In contrast to *RAB23*, *MEGF8* appears to act by promoting degradation of the hedgehog pathway signal transduction factor *Smoothed* [6, 22].

Since the original description of *MEGF8*-associated CRPTS in 2012, we are only aware of one other family, comprising two affected siblings, formally reported in the literature [23]. Owing to the paucity of reported cases, evidence for CRPT2 was classified as

¹Oxford Centre for Genomic Medicine, Oxford University Hospitals NHS Foundation Trust, Oxford, UK. ²Northern Genetics Service, Newcastle upon Tyne Hospitals NHS Foundation Trust, Newcastle upon Tyne, UK. ³Service de Médecine Génomique des Maladies Rares, Hôpital Necker-Enfants Malades, Paris, France. ⁴Laboratoire de biologie médicale multisites SeqOIA, Paris, France. ⁵Seattle Children's Hospital, Seattle, WA, USA. ⁶Provincial Medical Genetics Program, BC Women's Hospital and Health Centre, Vancouver, BC, Canada. ⁷University of California San Francisco/Fresno, Fresno, CA, USA. ⁸Genetic Medicine, Community Regional Medical Center, Fresno, CA, USA. ⁹MRC Weatherall Institute of Molecular Medicine, University of Oxford, John Radcliffe Hospital, Oxford, UK. ¹⁰Present address: Institut de Pathologie et de Génétique, Gosselies, Belgium. ✉email: andrew.wilkie@imm.ox.ac.uk

Received: 18 January 2024 Revised: 31 March 2024 Accepted: 25 April 2024

Published online: 17 May 2024

being Moderate using the ClinGen Craniofacial Malformations gene-disease curation process [24, 25]. Here we describe a further eight affected individuals (thus more than doubling the number of documented cases of this rare pathological entity) and compare these to previously reported cases of *MEGF8*- and *RAB23*-associated CRPTS, emphasising that the core clinical features are similar between *RAB23* and *MEGF8* patients, but demonstrating that laterality defects are more common, and craniosynostosis appears less severe, in the *MEGF8*-associated form of the condition.

PATIENTS AND METHODS

A single family (Family 6) was formally enrolled into a research study (Genetic Basis of Craniofacial Malformation; London Riverside NHS Research Ethics Committee ref 09/H0706/20). For the remaining families, clinicians who had either previously contacted the Clinical Genetics Group at the MRC Weatherall Institute of Molecular Medicine Oxford, regarding patients with *MEGF8* alterations, or presented unpublished data at specialist meetings, were re-contacted to ascertain whether the patient or parents would be willing to participate in the study. Following agreement, the clinician was sent a proforma to complete providing clinical details including *MEGF8* alteration, details of craniosynostosis, hand and foot abnormalities, and cardiac, gastrointestinal and developmental findings. All participants or their legal guardians consented to inclusion in this study.

MEGF8 has two major splice forms, which differ depending upon the inclusion or exclusion of exon 12A, without altering the reading frame [18]. For comparison with the previous publication all variant details are numbered with respect to the shorter 2778 amino acid reference transcript (RefSeq accession NM_001410.3, Ensembl ENST00000334370.8); note that the MANE select transcript is the longer isoform encoding 2845 amino acids, which, however, shows low expression in most or all tissues (Genotype-tissue expression project analysis release V8 [26]).

RESULTS

We describe eight individuals from six unrelated families with clinical features compatible with CRPTS. Each family presented to a different clinical centre, and following diagnostic exome or genome sequencing, was found to harbour two variants in *MEGF8* consistent with a causal role. The major molecular and clinical features in these individuals are summarised in Table 1 and their clinical presentations are outlined below. A more detailed clinical description of each patient is provided in the Supplementary Case Descriptions and Supplementary Table 1. To provide a comparison with previously reported cases of *MEGF8*- and *RAB23*-associated CRPTS, a summary of all cases is presented in Supplementary Table 2.

The first patient (Subject 1) was referred to a clinical genetics department for reproductive counselling at the age of 37 years (Fig. 1A–D). He had presented during infancy with polysyndactyly and craniosynostosis, both treated surgically, and had a clinical diagnosis of CRPTS. Following negative clinical genetic testing, he was recruited to the 100,000 Genomes whole genome sequencing research project (100kGP). Initial analysis of the whole genome sequencing data did not reveal a diagnosis because the allele bearing the 3 nucleotide deletion was filtered out based on the quality threshold in operation [27], but further research investigation confirmed that he had two likely pathogenic alterations in *MEGF8*, which were shown to have been inherited biallelically. Brief details of this case were previously included in an analysis of patients with craniosynostosis in the 100kGP [27].

Family 2 comprises a foetus (Subject 2.i) terminated at 25 weeks' gestation owing to multiple anomalies detected on ultrasound scanning, and a liveborn sibling (Subject 2.ii) (Fig. 1E–I). Post-mortem examination of the foetus documented dysmorphic facies, talipes equinovarus, hand syndactyly and abnormalities of left-right patterning. Her brother (Subject 2.ii) had antenatally-detected craniosynostosis. Post-natal findings

included syndactyly, bowel malrotation with polysplenia, sagittal craniosynostosis, facial dysmorphism, and complex congenital heart disease; he required ventilation via a tracheostomy for pharyngomalacia and vocal cord paralysis. Aged two years old he has global developmental delay but is acquiring new skills. He is non-verbal but has good understanding and can communicate non-verbally, can sit and stand with support, but is not yet walking independently. Biallelically inherited *MEGF8* variants were identified in a postnatal trio exome analysis of Subject 2.ii, and the same variants were subsequently identified in a stored sample from 2.i.

Subject 3 presented antenatally with increased nuchal translucency and oedema at 20 + 3 weeks' gestation. Post-natal findings included metopic craniosynostosis, dysmorphic facies, polysyndactyly and talipes equinovarus (Fig. 1J–M). Reinterpretation of a trio foetal exome taking account of the post-natal findings revealed two *MEGF8* variants, one maternally inherited and the other arising as a de novo variant. At the age of 20 months, he has evidence of mild speech delay and cannot walk independently, although he can walk with support and fine motor skills are unaffected.

Subject 4 presented with metopic craniosynostosis, cutaneous syndactyly of her hands and pre-axial polydactyly of her feet, together with a patent ductus arteriosus (PDA) and atrial septal defect (ASD). Aged 24 months she has delayed speech and gross motor skills. Targeted next generation sequencing with 300 gene capture and analysis of 50 genes associated with craniosynostosis identified two variants in *MEGF8*, consistent with the characteristic phenotype of Carpenter syndrome. One variant was maternally inherited, but no paternal sample was available.

Subject 5 is the 13th pregnancy of an unrelated couple with four living children, six early spontaneous miscarriages and two pregnancy losses at 20 and 23 weeks' gestation owing to umbilical cord abnormalities. Antenatal ultrasound at 17 weeks of pregnancy demonstrated suspected craniosynostosis, short long bones, renal asymmetry and a horizontalized heart with four chambers. The couple requested a termination of pregnancy, which was performed at 20 weeks' gestation. Post-mortem examination demonstrated dysmorphic facies, craniosynostosis of all sutures, polysyndactyly, left atrial isomerism and abdominal situs inversus, absent uterus and streak ovaries. Trio genome sequencing demonstrated biallelic alterations in *MEGF8*.

Family 6 comprises two male siblings now aged 16 (subject 6.i) and 10 (subject 6.ii) years (Fig. 1J–U). Both shared features including facial dysmorphism, cutaneous syndactyly, bilateral cryptorchidism, mild pectus deformity and developmental delay or learning difficulties. Subject 6.i additionally had metopic and sagittal synostosis and bilateral preaxial polydactyly of the feet, whilst subject 6.ii had a ventricular septal defect. Exome sequencing demonstrated biallelic variants in *MEGF8*.

Genetic variants

All individuals harboured two different heterozygous variants in *MEGF8* (Table 1, Fig. 2). In four families, inheritance was demonstrated to be biallelic based upon analysis of both parents; this inheritance pattern is likely, but not formally proven in Subject 4, for whom only the maternal sample was available. Unusually for a recessive disorder, in Subject 3 one of the variants arose de novo, so the allelic relationship could not be deduced based on parental inheritance.

The twelve variants described here (Table 1, Fig. 2) comprise four missense, three in-frame deletions and five likely truncating variants (two affecting canonical splice donor sequences, one at position +5 of a splice donor sequence, and two frameshifts). Only one of these variants, (p.(Arg1499His)), has previously been reported in the literature independently of the patients in this study, being present in a homozygous state in a patient with *MEGF8*-associated CRPT2 [18]. All of the variants are either absent, or present at an extremely low frequency in the heterozygous

Table 1. Summary of clinical and molecular features of the newly reported MEGF8 Carpenter syndrome cases.

Family	Sex	Age at examination	Variants (NM_001410.3)	Inheritance	CADD score	gnomAD frequency	Craniosynostosis	Facial dysmorphism	Brachydactyly	Syndactyly	Polydactyly	Talipes equinovarus	Laterality defect	Cardiac findings	Genital abnormalities	Developmental delay
1	M	37 years	c.4496G>A p.(Arg1499His) c.7766_7768del p.(Phe2589del)	Paternal Maternal	27 -	8.26×10^{-6} 0	Y (sutures unknown)	+	+	H (1-5 BL) & Fo (1-5 BL)	Fo	-	-	-	Cryptorchidism (L)	-
2.i	F	25 weeks' gestation	c.878T>C p.(Leu293Pro) c.2298+1G>A p.?	Paternal Maternal	28 34	1.45×10^{-6} 6.86×10^{-6}	-	+	-	H	-	+	+	Left atrial isomerism, AVSD, bilateral SVCs	-	NA
2.ii	M	7 days (initial); 17 months	c.878T>C p.(Leu293Pro) c.2298+1G>A p.?	Paternal Maternal	28 34	1.45×10^{-6} 6.86×10^{-6}	S	+	+	H (1-5 BL) & Fo (1-5 BL)	-	-	+	DORV, ASD,VSD, PDA	Cryptorchidism	+
3	M	6 weeks	c.5643+1G>A c.8137G>A p.(Val2713Met)	De novo ^a Maternal	34 25.9	1.38×10^{-6} 2.14×10^{-6}	Me	+	+	H (1-5 BL) & Fo (1-5 BL)	Fo	+	-	PDA	Cryptorchidism	+
4	F	2 years	c.4872delG p.(Phe1625Serfs*38) c.7769_7771delCCT p.(Ser2590del)	Paternal or De novo ^b Maternal	34 -	1.38×10^{-6} 0	Me	+	+	H (1-5 BL)	Fo	-	-	ASD, PDA	-	+
5	F	20 weeks' gestation	c.7759_7770del p.(Val2587_Ser2590del) c.7791_7794del p.(Leu2596Valfs*24)	Paternal Maternal	- 33	0 6.88×10^{-7}	All	+	Thumb brachymetacarpary	H & Fo	H & Fo	-	+	Left atrial isomerism	Uterine agenesis, streak ovaries	NA
6.i	M	16 years	c.7126C>T p.(Arg2376Cys) c.7068+5G>A	Paternal Maternal	28 22.7	2.51×10^{-6} 3.1×10^{-6}	Me, S	+	Spatulate thumbs with split distal phalanx	H & Fo	Fo	+	-	-	Cryptorchidism (BL)	+
6.ii	M	10 years	c.7126C>T p.(Arg2376Cys) c.7068+5G>A	Paternal Maternal	28 22.7	2.51×10^{-6} 3.1×10^{-6}	-	+	-	H(2-5) & Fo	-	-	-	VSD	Cryptorchidism (BL)	+

gnomAD genome allele frequency was obtained from v4.0.0.

F female, M male, Me metopic synostosis, S sagittal synostosis, BL bilateral, Fo foot, H hand, with involved digit numbers in brackets, ASD atrial septal defect, AVSD atrioventricular septal defect, DORV double outlet right ventricle, PDA patent ductus arteriosus, SVC superior vena cava, VSD ventricular septal defect, NA not applicable.

^aWork undergoing to confirm that in *trans*.

^bNo paternal sample available.

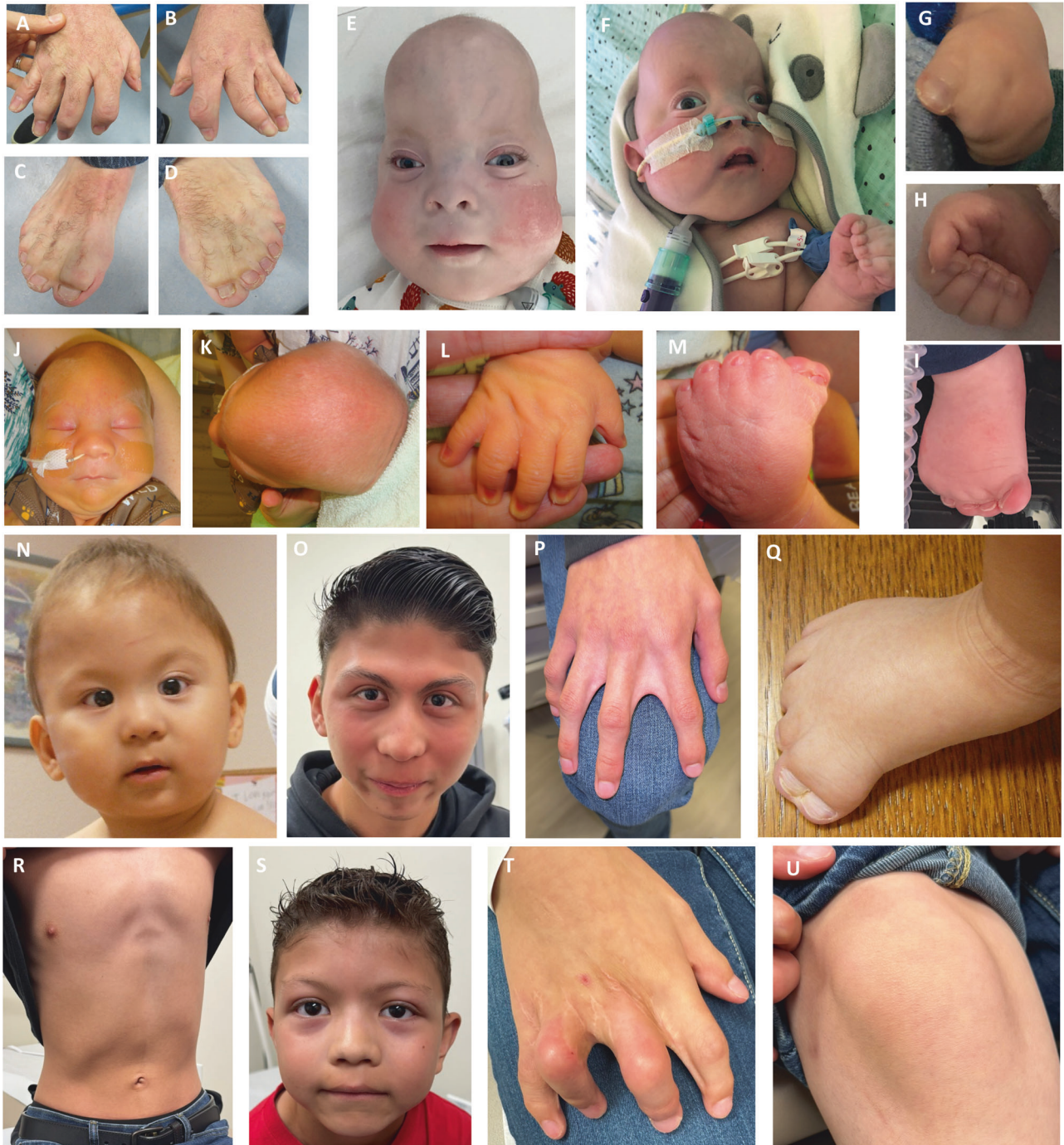

Fig. 1 Clinical features of individuals with *MEGF8* variants. Hands (A, B; post-operative following multiple syndactyly releases) and feet (C, D) of subject 1 at the age of 37 years; facial features (E, F), hands (G, H) and feet (I) of subject 2.ii; facial features (J, K), hand (L) and foot (M) of subject 3; facial features (N, O), hands (P), feet (Q) and chest (R) of subject 6.1 at 11 months (N, Q) and 16 years (O, P, R); facial features (S), hands (T) and knee demonstrating broad patellae (U) of subject 6.ii at 10 years old.

state in the gnomAD v4.0.0 database [28]. Whilst we did not perform functional assays on any variants, the pattern of variants observed, in combination with the very distinct clinical features of CRPTS and failure to identify other plausible pathogenic variants, suggest that the phenotypes described are likely to be caused by the associated combinations of *MEGF8* variants. Regarding the three novel missense variants ((p.(Leu293Pro), p.(Arg2376Cys) and p.(Val2713Met)), all are located at extremely conserved amino acids (Supplementary Fig. 1), including invertebrates, have CADD scores >25 and are considered likely pathogenic by

AlphaMissense (all three scoring 0.96 out of a maximum of 1) [29]. At position 293, vertebrate and invertebrate organisms all have a leucine or the chemically similar isoleucine. By alignment with human KEAP1, this variant locates within a β -strand of the second of six blades of a predicted Kelch domain [30] where substitution to proline is expected to be highly disruptive. The arginine at position 2376 is predicted to lie in a laminin EGF-like domain and is highly conserved across evolutionary time. Similarly, the valine at position 2713 lies within a predicted intracellular region that is very highly conserved (Supplementary

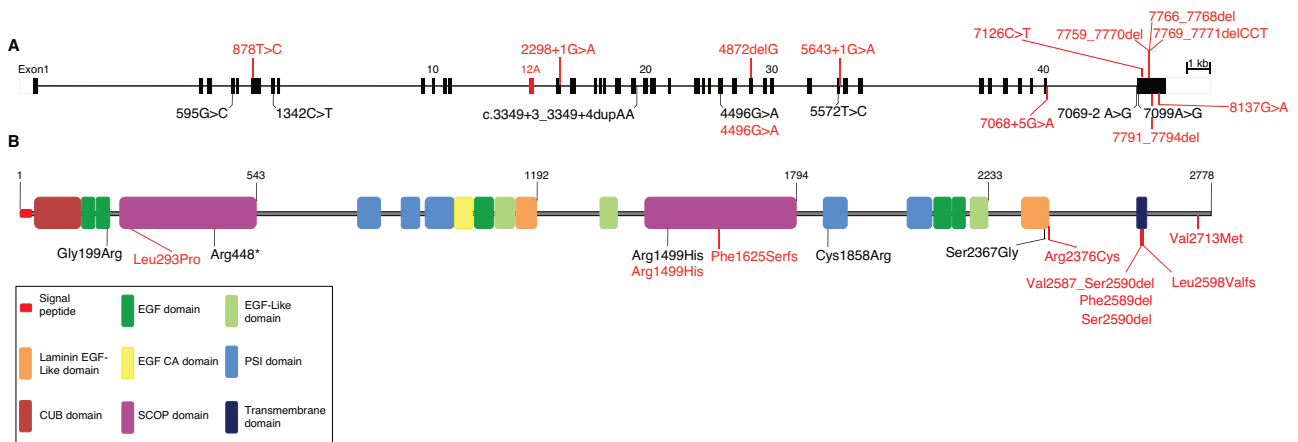


Fig. 2 Structure of *MEGF8* and *CRPT2*-associated gene alterations reported in this study (red) and previously published (black). **A** Diagram of the 41 exons of *MEGF8*. The 2778 amino acid reference sequence (RefSeq accession NM_001410.3, Ensembl ENST00000334370.8) omits exon 12A, shown in red. Genetic variants are shown, previously described are shown in black, those identified in this work are shown in red. **B** Domain organisation of *MEGF8* protein with previously described variants shown in black and those identified in this work shown in red.

Fig. 1), but does not correspond to an identified domain. It is predicted with moderate confidence by AlphaFold [31] to reside in a region of β -strand (Uniprot accession Q05BT0), but the consequence of substitution to methionine is unclear. Interestingly the three in-frame deletions, although each is distinct, all affect the same stretch of four conserved amino acids located in the single predicted helical transmembrane region (Fig. 2). No genotype-phenotype correlations are apparent. No individual harboured two loss-of-function alleles.

Craniofacial features

Six of eight individuals had craniosynostosis, the remaining two individuals without craniosynostosis comprising a foetus terminated at 25 weeks' gestation and a ten year old. These six cases demonstrated a spectrum of phenotypic severity, from Subject 5 who had craniosynostosis affecting all sutures detected prenatally at 17 weeks' gestation, to Subjects 2.ii, 3 and 4 who had single suture fusion, of either the metopic or sagittal suture (Table 1). Considering all patients with *MEGF8*-associated CRPT2 to date, six out of fifteen cases have had involvement of a single midline suture, comprising five with metopic and one with sagittal craniosynostosis, and only four individuals had multiple suture craniosynostosis. In contrast, 32 out of 39 reported cases of *RAB23* CRPTS had synostosis of more than one suture and involvement of both coronal or all sutures is common [3, 4, 9–15] (Supplementary Table 2). A relatively consistent pattern of dysmorphic facial features was apparent in the series, including micrognathia, hypertelorism (including in the presence of metopic synostosis), a broad depressed nasal bridge and small low-set posteriorly rotated ears (Fig. 1).

Limb abnormalities

All eight individuals had cutaneous syndactyly involving multiple digits of the hands, and in six individuals (Subjects 1, 2.ii, 3, 5, 6.i, 6.ii) the feet were also affected. Five individuals had polydactyly of the hands or feet and three had talipes equinovarus (Table 1, Fig. 2). Brachydactyly with missing or uncalcified middle phalanges was also present (Table 1, Supplementary Table 1). Cutaneous syndactyly is a universal feature in all cases of *MEGF8*-associated CRPT2 to date (15/15 individuals, Supplementary Table 2) and is also near-universal in *RAB23*-associated CRPT1 (38/39 individuals), with polydactyly, abnormalities of the middle phalanges and talipes also being common in both forms (Supplementary Table 2).

Left-right patterning abnormalities

Three of eight individuals demonstrated a laterality defect, comprising both siblings from family 2, and Subject 5. In Family 2, foetus 2.i demonstrated left atrial isomerism, abdominal situs inversus, bi-lobed lungs bilaterally, midline liver and polysplenia and her surviving brother (2.ii) demonstrated complex congenital heart disease, polysplenia and bowel malrotation; whilst Subject 5 demonstrated heterotaxy with polysplenia. None of the eight individuals had dextrocardia and five did not have a left-right patterning abnormality. Considering all reported cases of *MEGF8*- and *RAB23*-associated CRPTS, laterality defects were significantly more common in CRPT2 (7/15 cases) than in CRPT1 (4/39 reported cases, Fisher's exact test, $P = 0.006$, Supplementary Table 2).

Prenatal features

Six of eight individuals in this series (Subjects 2.i, 2.ii, 3, 5, 6.i, and 6.ii) presented prenatally, with features of abnormal tissue fluid accumulation combined with other congenital abnormalities. These included increased nuchal translucency, polyhydramnios and congenital heart disease (Family 2); prenatal non-immune hydrops (Subject 3), increased nuchal translucency/cystic hygroma with craniosynostosis and renal asymmetry (Subject 5) and in family 6, ventriculomegaly (subject 6.i) or enlarged cisterna magna with congenital heart disease (subject 6.ii). Two pregnancies (Subjects 2.i and 5) were terminated owing to the severity of the foetal anomalies. Subject 3 had amniocentesis and prenatal exome testing, but the diagnosis was not made until the genetic data were re-examined in light of the post-natal findings. The parents of Subject 5 had six early spontaneous miscarriages and two pregnancy losses at 20 and 23 weeks' gestation possibly owing to umbilical cord abnormalities. It is uncertain whether these foetal losses were similarly affected by CRPTS, but there was additionally a maternal history of a pituitary adenoma about which no further information is available.

Additional clinical features

All five males in this series had cryptorchidism (Subjects 1 (unilateral), 2.ii, 3, 6.i and 6.ii, Table 1). Combined with previously reported males with *MEGF8*-associated CRPT2, all males with *MEGF8*-associated CRPTS have demonstrated cryptorchidism, which is also common but not universally reported in *RAB23*-associated CRPT1 (*MEGF8*: 9/9 males; *RAB23* 14/23 males; Fisher's exact $P = 0.035$). Developmental delay is common, but of variable severity, ranging in this series from Subjects 2, 3 and 4 who have

speech and gross motor delay, to Subject 1 who attended mainstream school with some childhood speech and language therapy and is university educated. This spectrum of severity is also reflected in the previously reported cases of both CRPT1 and CRPT2, with no clear differences depending upon causal gene (Supplementary Table 2). Congenital heart disease is present in 6/8 cases reported here, 4/7 previously reported cases of *MEGF8*-associated CRPTS and 10/39 previously reported cases of *RAB23*-associated CRPTS (Supplementary Table 2). Subject 2.ii has required long-term ventilation via a tracheostomy for respiratory difficulties, pharyngomalacia and vocal cord paralysis. Some individuals demonstrated additional skeletal features including two individuals with short long bones and three with pectus deformities or chest asymmetry. In family 6 broad patellae, camptodactyly and delayed dentition were additionally noted features and subject 6.i had a stable s-shaped scoliosis of the thoracic spine (Supplementary Table 1).

DISCUSSION

We describe eight individuals from six different families, each of whom harbours two different variants in the *MEGF8* gene, more than doubling the number of reported families from 5 to 11 and increasing the total number of affected individuals reported with *MEGF8*-associated CRPT2 to fifteen.

As noted above, no patient reported to date with CRPT2 has been biallelic for two loss-of function *MEGF8* alleles. Mice completely lacking *Megf8* are embryonic lethal and null mutations of the *Drosophila* homologue of *MEGF8* die as larvae [20, 21, 32], suggesting some *MEGF8* function is needed for viability. Most likely, the missense and in-frame deletion alleles allow some residual function, providing rescue from early lethality. A notable feature of *MEGF8*-associated CRPT2 is the wide range of clinical severity, from prenatal presentation with multiple foetal anomalies (Subjects 2i and 5) to graduate level education (Subject 1, who is the only individual compound heterozygous for missense and in-frame deletion variants). Variable residual function associated with diverse alleles and allele combinations identified in *MEGF8*-associated CRPT2 may explain the spectrum of phenotypes seen. Also of note is that in 7 of the 11 independent families documented to date, one of the two *MEGF8* alleles has been predicted to cause complete loss of function (3 canonical splice site, 2 nonsense, and 2 frameshift substitutions). Given the rarity of *MEGF8*-related CRPT2 in the context of a very large protein target (2778 amino acids), we speculate that there may be a relatively narrow window of residual *MEGF8* activity that is embryopathic, so that many homozygous or compound heterozygous combinations of missense alleles exceed a threshold of activity and are without pathogenic effect. Of interest, the gnomADv4.0.0 database lists 68 different amino acid substitutions, occurring at widely scattered locations throughout the protein, for which at least one homozygote exists. Hence we urge that great caution should be exerted in the pathogenic interpretation of biallelic *MEGF8* variants, in the absence of the characteristic clinical features described here and in previous publications [18, 23].

The CRPT2 patients reported here and previously emphasise that the core features of CRPTS are similar whether caused by *RAB23* or *MEGF8* alterations [3, 4, 9–15, 18, 23]. In particular craniosynostosis with complete cutaneous syndactyly of multiple digits is a near universal presentation, with polydactyly, cryptorchidism, talipes equinovarus, congenital heart defects and variable developmental delay being common features in both CRPT1 and CRPT2. However, left-right patterning abnormalities are a more common finding in CRPT2 [18], being present in just under half of cases to date, but only around one tenth of *RAB23*-associated CRPT1 [3, 4, 9–15]. Where laterality defects have been demonstrated in CRPT1, these are generally milder than in CRPT2 comprising only one reported individual with true abdominal situs

inversus, two individuals with accessory spleens but no other evidence of heterotaxy and one individual with a double outlet right ventricle [4, 10, 12]. The clinical findings in CRPT2 mirror the heterotaxy seen in mice with *Megf8* alterations, and *megf8* knockdown in zebrafish, which was attributed to abnormal propagation of asymmetric *Nodal* expression in the lateral plate mesoderm [19]. However, 8/15 individuals with *MEGF8*-associated CRPTS do not have any evidence of a laterality defect, indicating reduced penetrance of this phenotypic feature. Even considering mouse models lacking *Megf8*, left-right patterning abnormalities were variable, with only around a half having dextrocardia or transposition of the great arteries [21], suggesting that additional unidentified factors interact with the *MEGF8* genotype to determine final left-right patterning in *MEGF8*-associated CRPTS.

Craniosynostosis is a nearly universal feature in cases of both *RAB23*- and *MEGF8*-associated CRPTS. However, the review presented here suggests that craniosynostosis in CRPT2 is often less severe. Whereas multi-suture synostosis is common in the reported *RAB23* cases, six out of the fifteen *MEGF8* cases have had documented fusion of only a single midline suture (metopic or sagittal) [18, 23], most commonly isolated metopic craniosynostosis. Nevertheless, there is clearly a spectrum of severity as one individual with CRPT2 had synostosis of all sutures and presented prenatally (case 5).

Dysmorphic facial features (hypertelorism, epicanthic folds, wide flat nasal bridge, high palate, low set posteriorly rotated ears) are shared by both types of CRPTS. These dysmorphic features appear a characteristic part of the syndrome, rather simply than a secondary effect of craniosynostosis, illustrated by the paradoxical finding of metopic synostosis with hypertelorism rather than the expected hypotelorism in cases of *MEGF8* CRPTS reported here and elsewhere [1, 18].

In conclusion, we report a further eight cases of CRPTS caused by biallelic variants in *MEGF8*, strongly supporting that CRPT2 is a distinct clinical entity. These cases confirm that *MEGF8*-associated CRPT2 shares many core features of *RAB23*-associated CRPT1, but differences include a significantly higher frequency of left-right patterning abnormalities, and lower frequency of multi-suture craniosynostosis in the *MEGF8*-associated condition, refining the phenotypic spectrum of this rare condition.

DATA AVAILABILITY

All data are available in the manuscript and Supplementary Material.

REFERENCES

- Cohen DM, Green JG, Miller J, Gorlin RJ, Reed JA. Acrocephalopolysyndactyly type II-Carpenter syndrome: clinical spectrum and an attempt at unification with Goodman and Summit syndromes. *Am J Med Genet.* 1987;28:311–24.
- Carpenter G. Two sisters showing malformations of the skull and other congenital abnormalities. *Rep. Soc Study Dis Child Lond.* 1901;1:110–8.
- Jenkins D, Seelow D, Jehee FS, Peryn CA, Alonso LG, Bueno DF, et al. *RAB23* mutations in Carpenter syndrome imply an unexpected role for hedgehog signaling in cranial-suture development and obesity. *Am J Hum Genet.* 2007;80:1162–70.
- Jenkins D, Baynam G, De Cattede L, Elcioglu N, Gabbett MT, Hudgins L, et al. Carpenter syndrome: extended *RAB23* mutation spectrum and analysis of nonsense-mediated mRNA decay. *Hum Mutat.* 2011;32:E2069–78.
- Eggenschwiler JT, Espinoza E, Anderson KV. *Rab23* is an essential negative regulator of the mouse Sonic hedgehog signalling pathway. *Nature.* 2001;412:194–8.
- Eggenschwiler JT, Bulgakov OV, Qin J, Li T, Anderson KV. Mouse *Rab23* regulates hedgehog signaling from smoothened to Gli proteins. *Dev Biol.* 2006;290:1–12.
- Hor CH, Goh EL. Small GTPases in hedgehog signalling: emerging insights into the disease mechanisms of *Rab23*-mediated and *Arl13b*-mediated ciliopathies. *Curr Opin Genet Dev.* 2019;56:61–8.
- Hasan MR, Takatalo M, Ma H, Rice R, Mustonen T, Rice DP. *RAB23* coordinates early osteogenesis by repressing FGF10-pERK1/2 and GLI1. *Elife.* 2020;9:e55829.
- Khairat R, Elhossini R, Sobreira N, Wohler E, Otaifi G, Mohamed AM, et al. Expansion of the phenotypic and mutational spectrum of Carpenter syndrome. *Eur J Med Genet.* 2022;65:104377.

10. Alessandri J-L, Dagonneau N, Laville J-M, Baruteau J, Hébert J-C, Cormier-Daire V. RAB23 mutation in a large family from Comoros Islands with Carpenter syndrome. *Am J Med Genet A*. 2010;152A:982–6.
11. Haye D, Collet C, Sembely-Taveau C, Haddad G, Denis C, Soulé N, et al. Prenatal findings in carpenter syndrome and a novel mutation in RAB23. *Am J Med Genet A*. 2014;164A:2926–30.
12. Victorine AS, Weida J, Hines KA, Robinson B, Torres-Martinez W, Weaver DD. Prenatal diagnosis of Carpenter syndrome: looking beyond craniosynostosis and polysyndactyly. *Am J Med Genet A*. 2014;164A:820–3.
13. Ben-Salem S, Begum MA, Ali BR, Al-Gazali L. A Novel Aberrant Splice Site Mutation in RAB23 Leads to an Eight Nucleotide Deletion in the mRNA and Is Responsible for Carpenter Syndrome in a Consanguineous Emirati Family. *Mol Syndromol*. 2013;3:255–61.
14. Lodhia J, Rego-Garcia I, Koipapi S, Sadiq A, Msuya D, Spaendonk R, et al. Carpenter syndrome in a patient from Tanzania. *Am J Med Genet A*. 2021;185:986–9.
15. Mowva S, Kotecha UH, Sharma D, Puri RD, Verma IC. Prenatal Diagnosis and Elucidation of a Novel Molecular Mechanism in Carpenter Syndrome. *J Fetal Med*. 2014;1:89–93.
16. McDonald-McGinn DM, Feret H, Nah H-D, Bartlett SP, Whitaker LA, Zackai EH. Metopic craniosynostosis due to mutations in GLI3: A novel association. *Am J Med Genet A*. 2010;152A:1654–60.
17. Hurst JA, Jenkins D, Vasudevan PC, Kirchhoff M, Skovby F, Rieubland C, et al. Mutations in multidomain protein MEGF8 identify a Carpenter syndrome subtype associated with defective lateralization. *Am J Hum Genet*. 2012;91:897–905.
19. Zhang Z, Alpert D, Francis R, Chatterjee B, Yu Q, Tansey T, et al. Massively parallel sequencing identifies the gene *Megf8* with ENU-induced mutation causing heterotaxy. *Proc Natl Acad Sci USA*. 2009;106:3219–24.
20. Engelhard C, Sarsfield S, Merte J, Wang Q, Li P, Beppu H, et al. MEGF8 is a modifier of BMP signaling in trigeminal sensory neurons. *Elife*. 2013;2:e01160.
21. Wang W, Zheng X, Song H, Yang J, Liu X, Wang Y, et al. Spatial and temporal deletion reveals a latent effect of *Megf8* on the left-right patterning and heart development. *Differentiation*. 2020;113:19–25.
22. Kong JH, Young CB, Pusapati GV, Patel CB, Ho S, Krishnan A, et al. A Membrane-Tethered Ubiquitination Pathway Regulates Hedgehog Signaling and Heart Development. *Dev Cell*. 2020;55:432–49.
23. Bilal M, Haack TB, Buchert R, Peralta S, Uddin N, Ali RH, et al. Sequence Variants in *MEGF8* and *GJA1* Underlying Syndactyly. *Mol Syndromol*. 2023;14:201–7.
24. Rehml HL, Berg JS, Brooks LD, Bustamante CD, Evans JP, Landrum MJ, et al. ClinGen-the Clinical Genome Resource. *N Engl J Med*. 2015;372:2235–42.
25. Clinical Genome Resource: MEGF8 [curated 23/12/21]. <https://search.clinicalgenome.org/kb/genes/HGNC:3233>. Accessed 18/1/24.
26. Aguet F, Brown AA, Castel SE, Davis JR, He Y, Jo B, et al. Genetic effects on gene expression across human tissues. *Nature*. 2017;550:204–13.
27. Hyder Z, Calpena E, Pei Y, Toozee RS, Brittain H, Twigg SRF, et al. Evaluating the performance of a clinical genome sequencing program for diagnosis of rare genetic disease, seen through the lens of craniosynostosis. *Genet Med*. 2021;23:2360–8.
28. Karczewski KJ, Francioli LC, Tiao G, Cummings BB, Alfoldi J, Wang Q, et al. The mutational constraint spectrum quantified from variation in 141,456 humans. *Nature*. 2020;581:434–43.
29. Cheng J, Novati G, Pan J, Bycroft C, Žemgulytė A, Applebaum T, et al. Accurate proteome-wide missense variant effect prediction with AlphaMissense. *Science*. 2023;381:eadg7492.
30. Li X, Zhang D, Hannink M, Beamer LJ. Crystal structure of the Kelch domain of human Keap1. *J Biol Chem*. 2004;279:54750–8.
31. Jumper J, Evans R, Pritzel A, Green T, Figurnov M, Ronneberger O, et al. Highly accurate protein structure prediction with AlphaFold. *Nature*. 2021;596:583–9.
32. Lloyd DL, Toegel M, Fulga TA, Wilkie AOM. The *Drosophila* homologue of MEGF8 is essential for early development. *Sci Rep*. 2018;8:8790.

ACKNOWLEDGEMENTS

We thank all the family members for their participation and the associated clinicians for their help in data collection.

AUTHOR CONTRIBUTIONS

Study conception: AOMW; data acquisition: all authors; manuscript drafting: LMW, AOMW; manuscript revision, editing and approval: all authors.

FUNDING

This work was supported by an NIHR Academic Clinical Fellowship (LMW), a Doctoral Training Programme studentship funded jointly by the Radcliffe Department of Medicine, Exeter College (Oxford) Usher Cunningham Scholarship and the MRC (RST), and the NIHR Oxford Biomedical Research Centre Programme (SRFT, AOMW).

COMPETING INTERESTS

The authors declare no competing interests.

ETHICAL APPROVAL

Ethical approval for research investigation of Family 6 was provided by London Riverside NHS Research Ethics Committee ref 09/H0706/20). Other families were recruited as a result of clinical investigations. All patients or their legal guardians gave informed consent for inclusion in this study, and separate written informed consent was obtained for the publication of all clinical images.

ADDITIONAL INFORMATION

Supplementary information The online version contains supplementary material available at <https://doi.org/10.1038/s41431-024-01624-9>.

Correspondence and requests for materials should be addressed to Andrew O. M. Wilkie.

Reprints and permission information is available at <http://www.nature.com/reprints>

Publisher's note Springer Nature remains neutral with regard to jurisdictional claims in published maps and institutional affiliations.



Open Access This article is licensed under a Creative Commons Attribution 4.0 International License, which permits use, sharing, adaptation, distribution and reproduction in any medium or format, as long as you give appropriate credit to the original author(s) and the source, provide a link to the Creative Commons licence, and indicate if changes were made. The images or other third party material in this article are included in the article's Creative Commons licence, unless indicated otherwise in a credit line to the material. If material is not included in the article's Creative Commons licence and your intended use is not permitted by statutory regulation or exceeds the permitted use, you will need to obtain permission directly from the copyright holder. To view a copy of this licence, visit <http://creativecommons.org/licenses/by/4.0/>.

© The Author(s) 2024