European Journal of Human Genetics (2021) 29:1158–1163
https://doi.org/10.1038/s41431-021-00847-4

BRIEF COMMUNICATION

Evidence of mosaicism in *SPAST* variant carriers in four French families

Chloé Angelini[1,2] · Cyril Goizet[1,2,3] · Samia Ait Said[4] · William Camu[5] · Christel Depienne[4,6,7] · Bénédicte Heron[8] · Bophara Kol[4] · Marine Guillaud-Bataille[4] · Perrine Pennamen[1,3] · Caroline Rooryck[1,3] · Clarisse Scherer-Gagou[9] · Laurène Tissier[4] · Giovanni Stevanin[4,6,10] · Eric Leguern[4,6] · Guillaume Banneau[4,11]

Received: 13 July 2020 / Revised: 14 February 2021 / Accepted: 24 February 2021 / Published online: 6 May 2021

Abstract

Hereditary spastic paraplegias (HSP) are heterogeneous disorders, with more than 70 causative genes. Variants in *SPAST* are the most frequent genetic etiology and are responsible for spastic paraplegia type 4 (SPG4). Age at onset can vary, even between patients from the same family, and incomplete penetrance is described. Somatic mosaicism is extremely rare with only three patients reported in the literature. We report here *SPAST* mosaic variants in four unrelated patients. We confirm that mosaicism in *SPAST* is a very rare event with only four identified cases on more than 300 patients with a *SPAST* variant previously described by our clinical diagnostic laboratory.

Introduction

Hereditary spastic paraplegias (HSP) are a heterogeneous group of neurodegenerative disorders, characterized by a large phenotypic and genetic heterogeneity [1]. Clinically, two forms are distinguished: uncomplicated and complicated forms. The uncomplicated forms include progressive spasticity and lower limbs (LL) weakness; whereas the complicated forms associate additional neurological signs such as cerebellar ataxia, intellectual disability, peripheral neuropathy, optic atrophy, or brain anomalies on MRI [1]. Moreover, an inter- and intra-familial variability of the phenotype has been reported, regarding age at onset, the presence of associated neurological signs or severity of handicap. To date, more than 70 spastic paraplegia genes (SPG) have been identified [2]. Variants in *SPAST* (SPG4) are observed in ~40% of HSP with autosomal dominant inheritance. SPG4 is typically uncomplicated, although complicated forms also exist [3]. Incomplete, age-dependent penetrance is observed in families [4]. *SPAST* variants are frequent in sporadic HSP but the proportion of cases linked to de novo variants is low [5, 6]. Similarly, somatic mosaicism is rare with only three reported cases in three independent series of patients [7–9]. We report here

Supplementary information The online version contains supplementary material available at https://doi.org/10.1038/s41431-021-00847-4.

✉ Eric Leguern
eric.leguern@aphp.fr

1 Service de Génétique Médicale, CHU Bordeaux, Bordeaux, Bordeaux, France

2 Centre de Référence Maladies Rares Neurogénétique, Service de Génétique Médicale, Bordeaux, France

3 INSERM U1211, laboratoire MRGM, Univ. Bordeaux, Bordeaux, France

4 Sorbonne Université, AP-HP, GH Pitié-Salpêtrière, Département de génétique, Paris, France

5 Centre de référence SLA, explorations neurologiques, CHU et Univ Montpellier, Montpellier, France

6 Sorbonne université, Institut du Cerveau, INSERM U 1127, Paris, France

7 Institute of Human Genetics, University Hospital Essen, University of Duisburg-Essen, Essen, Germany

8 Service de Neurologie Pédiatrique, Hôpital Armand Trousseau-La Roche Guyon, GHUEP, APHP, Paris, France

9 Centre National de Référence pour les Maladies Neurogénétiques de l'Adulte, Département de Neurologie, Centre Hospitalier Universitaire d'Angers, Angers, France

10 Equipe de neurogénétique, Ecole Pratique des Hautes Etudes (EPHE), PSL Research University, Paris, France

11 Département de Génétique Médicale, Institut Fédératif de Biologie, Hôpital Purpan, Toulouse, France

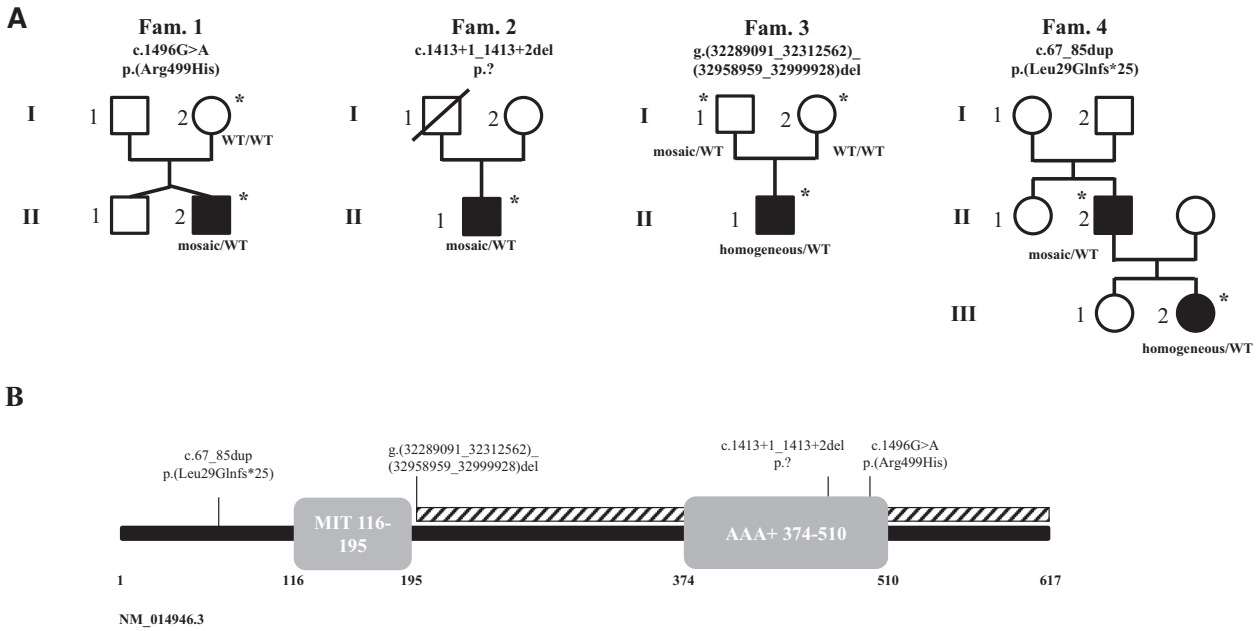

Fig. 1 Family pedigrees and schematic representation of identified variants in SPAST. A Pedigrees of the four families. Mosaic mosaic variant, homogeneous homogeneous variant, WT wild type; *sampled individual. Black: patients presenting spasticity. **B** schematic view of *SPAST* with its main domains and the variants found in the series.

the first series of *SPAST* mosaic variants in four unrelated patients.

Material and methods

Patient's collection and variants detection and analyses are detailed in Supplementary data.

Clinical and genetic findings

We report in this study four patients with mosaic *SPAST* variants from four unrelated families (Fig. 1), identified as part of routine diagnosis in the two genetics departments, at Pitié-Salpêtrière and Bordeaux University Hospitals. Three patients have HSP symptoms and one patient is asymptomatic (Table 1).

In Family 1, the proband (1.II.2) is a 9-year-old boy presenting a moderate spasticity since the age of 1 year, associated with moderate motor deficit and mild amyotrophy of the LL. Next generation sequencing identified in patient 1.II.2 the previously reported NM_014946.3: c.1496G>A p.(Arg499His) recurrent variant in exon 13 [4, 5, 10, 11]. Allelic frequency (AF) was 26% (143/543 reads) on first NGS identification and 32% on an independent sequencing (194/604 reads). Estimation of mosaicism rate was hence around 58% of patient's lymphocytes and statistically significant (chi-squared test, p value < 0.00001). This variant is located on the AAA domain of the spastin protein, where missense variants have previously been associated with an earlier age at onset [2]. Segregation studies could only be performed in the mother (1.I.2) who did not carry the variant. This variant was previously reported in at least 4 symptomatic individuals. Two of them presented an early pure and isolated form of SPG4 as observed in our patient [5, 11]. The third patient presented a pure familial form and the last one had an early complex form with dysarthria leading to anarthria at age 12 years old [4, 10].

In Family 2, the proband (2.II.1) presented a mild spasticity with late onset (at 60 years) associated with moderate motor deficit and mild amyotrophy at LL. Brain MRI revealed slight periventrical white matter hyperintensities. NGS identified a novel variant, NG_008730.1 (NM_014946.3):c.1413 + 1_1413 + 2del, which was predicted to affect splice donor site of intron 11 (predicting scores: SpliceSiteFinder = 75.37, MaxEntScan = 8.07 and NNSPLICE = 0.97). Observed read fraction was 19% (164/847 reads) on first NGS identification and 17% (229/1329 reads) on an independent sequencing. Mosaicism was evaluated at 36% of patient's lymphocytes (p value < 0.00001). Parental DNAs were unavailable for genetic testing.

The index case of Family 3 (3.II.1) presented since childhood a complex phenotype associating moderate spasticity, weakness of the LL, mild LL amyotrophy, mild ataxic gait, and infantile hypertrophic pyloric stenosis. An array-CGH was performed to investigate the uncommon association between HSP and hypertrophic pyloric stenosis. Two microdeletions were identified at the heterozygous

Table 1 Clinical and paraclinical examinations and genetic findings in the different patients.

Family	Patient	Mutation	Status	Age at onset, y	Age at examination, y	Spasticity	Deficit motor	Amyotrophy	MRI	Additional signs
Fam. 1	II.2	c.1496G>A[a] p.(Arg499His)	Mosaic ≈ 58% (AF ≈ 29%) p value < 0.00001*	1	9	Moderate	Moderate (LL)	Mild (LL)	Normal	–
Fam. 2	II.1	c.1413 + 1_1413 + 2del p.?	Mosaic ≈ 36% (AF ≈ 18%) p value < 0.00001±	60	63	Mild	Moderate (LL)	Mild (LL)	Slight periventricular white matter hyperintensities	–
Fam. 3	I.1	g.(32289091_32312562)_(32958959_32999928)del	Mosaic ≈ 45% (AF ≈ 23%) p value < 0.00001¥	NA	68	None	None	None	Not done	Normal electromyogram
	II.2		Heterozygous (AF ≈ 50%)	Childhood	38	Moderate	None	Mild (LL)	Not done	Mild ataxic gait, hypertrophic pyloric stenosis
Fam. 4	II.2	c.67_85dup[b] p.(Leu29Glnfs*25)	Mosaic ≈ 58% (AF ≈ 29%) p value < 0.01*	70	74	Severe	None	Moderate (LL)	Normal	–
	III.2		Heterozygous (AF ≈ 50%)	47	48	Mild	None	Mild (LL)	Normal	–

Status: for each mosaic variant, percentage of mosaicism was evaluated by average of mosaicism observed on first and second independent technical identification, excepted patient 3.I.1 where percentage was estimated on intensity of unique CGH-array experiment.

NA not adapted.

[a]Variant previously described [4, 5, 12, 13].

[b]Variant previously described [16, 17].

*p value was calculated by comparing numbers of reads with variant or wild type for each run between patient and positive control.

±p value was calculated by comparing numbers of reads with variant or wild type for each run between patient and simulated positive control (with an allelic frequency at 50 and 100% of lymphocytes).

¥p value was calculated by comparing estimated allelic frequency on CGH-array intensity of deletion and wild-type position between patient and positive control.

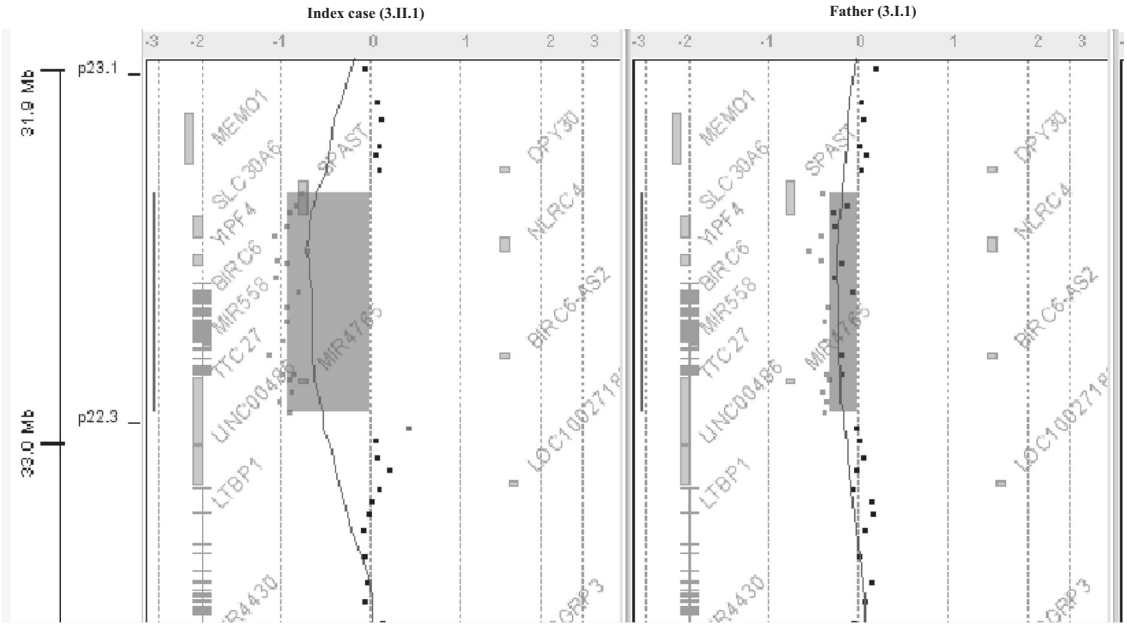

Fig. 2 Array-CGH profiles of patient 3.II.1, and his father 3.I.1. Probes are plotted as dots corresponding to the log2 ratio of fluorescence intensities Cy5/Cy3. Observe the deletion in the proband 3.II.1, partially including *SPAST* ($\log_2$ ratio is equal to −0.948). In the father's proband (3.I.1), $\log_2$ ratio is around −0.31, indicating a deletion with a mosaic pattern (mosaic rate estimated around 45% and allelic frequency around 23%).

state: a 2p22.3 613 kb microdeletion NC_000002.11:g.(32289091_32312562)_ (32958959_32999928)del, disrupted *SPAST* from exons 2–17, and a 512 kb 3q25.2q25.31 microdeletion including *MME*. *MME* (OMIM*120520) had been implicated in autosomal-recessive Charcot–Marie–Tooth disease [12]. This gene has also been associated with the autosomal dominant spinocerebellar ataxia 43, but in a single large Belgian family [13]. Analyses were performed in the two parents and showed that the deletions were both inherited from the father. Notably, *SPAST* deletion was observed in the healthy father with a mosaic pattern on array-CGH ($\log_2$ratio = −0.31, Fig. 2) whereas the 3q25.2q25.31 deletion was observed with homogeneous heterozygous pattern ($\log_2$ratio = −1). A karyotype excluded a balanced translocation. Mosaicism of the *SPAST* deletion was confirmed by interphase and metaphase FISH analysis and evaluated to 45% of father's lymphocytes and AF estimated to 23% (p value < 0.00001). At the age of 68 years, the father was not complaining of any symptoms and had a normal electromyogram.

The index patient (4.II.2) of Family 4 presented with a severe spasticity of very late onset (at 70 years) associated with moderate LL amyotrophy. His daughter (4.III.2) had a milder phenotype with an earlier onset at 47 years old. NGS analyses were performed in two individuals and identified the previously reported variant, NM_014946.3: c.67_85dup p.(Leu29Glnfs*25) in exon 1 [14, 15]. Index case (4.II.2) carried the variant with a mosaic pattern. Mosaicism was evaluated at 58% of all father's lymphocytes, with an AF of 30% (29/98 reads, p value < 0.01) in first NGS identification and 28% in an independent sequencing (103/371 reads). As expected, the variant was observed at homogeneous heterozygous state in the daughter. This variant was previously reported in 2 patients, one with a pure familial form, and one with a pure sporadic form [14, 15].

Discussion

We report four unrelated patients with a *SPAST* variant at the mosaic state. Mosaic *SPAST* variants have been rarely reported in the literature, with only three patients described so far [7–9]. Our study confirms this low frequency, with four patients identified in more than 300 patients with a *SPAST* variant previously reported by our diagnostic laboratories [2]. However, a large segregation study in each family was not achievable (most often due to the absence of parental samples, sometimes deceased, or not wishing to have samples taken) and we cannot exclude the existence of other mosaic carriers among the patients' relatives in our cohorts.

SPAST variants are the most common cause of autosomal dominant pure HSP, and only 5% of *SPAST* mutated cases are sporadic [2]. In these sporadic cases, confirmation of the de novo status of the variant is rarely established. In a large review of the literature in 2019, Schieving et al. found only 14 patients with de novo variants [6]. This frequency appears low compared to the large number of publications

describing individuals, symptomatic or not, carrying *SPAST* variants. We hypothesized that the very low frequency of *SPAST* mosaic cases could be explained by a non-systematic exploration of parents, especially for patients with late onset.

Based on data from the literature and our series, we note that there are more men with mosaicism than women, with only one women described with a *SPAST* mosaicism, who was asymptomatic [8]. It is established that SPG4 has a lower penetrance in women, the hypothesis being that in women low allelic fractions may not reach the threshold for phenotypic expression as easily as males can do [2].

Three patients with *SPAST* mosaic variants were affected whereas one patient was asymptomatic. All symptomatic mosaic carriers had an uncomplicated HSP form. This observation conforms with previously reported data where complicated HSPs are rare in *SPAST* variants carriers [2, 16]. Several studies have reported asymptomatic *SPAST* variant carriers, representing ~6% of all molecularly confirmed patients [2, 4, 5, 17]. Asymptomatic mosaic carriers have been previously reported but with a very low rate of somatic mosaicism in lymphocytes [8]. In our study, all patients with mosaic variant presented a high rate of mosaicism, from 36 to 58% of lymphocytes. Moreover, asymptomatic patient 3.I.1 did not present the lowest rate of mosaicism. We could not determine a minimum rate of mosaicism of *SPAST* variant triggering the disease. However, blood mosaicism may not reflect mosaicism rate in other tissues, especially in the nervous system [18]. Since this patient was 68 years old at examination, a later onset of HSP for this patient cannot be excluded, as previously reported for this type of truncating variants [2]. Finally, the boundary between a mosaicism and a germ-line heterozygosity can be tenuous, with very close allelic frequencies. This notion must be taken into account in the interpretation of allelic frequencies close to 50%.

The nature of the variant does not seem to be associated with mosaicism since three out of four mosaic pathogenic variants reported here are variants leading to premature stop codons including three frameshift variants and one large deletion, and previously reported mosaic patients included missense and nonsense variants, showing that all variant types that affect function can be found at mosaic state [7–9].

In conclusion, patients with mosaic *SPAST* variants appear to be rare. Nevertheless, systematic screening of both parents of apparently sporadic patients and assessment of the allelic imbalance could increase detection of mosaicism and clarify the number of individuals carrying mosaic variants, which is of great importance for genetic counseling. Future research may also be focused on understanding the role of sex in modulating the mosaicism expressivity [19].

Compliance with ethical standards

Conflict of interest The authors declare no competing interests.

Publisher's note Springer Nature remains neutral with regard to jurisdictional claims in published maps and institutional affiliations.

References

1. Harding AE. Classification of the hereditary ataxias and paraplegias. Lancet. 1983;321:1151–5. 21
2. Parodi L, Fenu S, Barbier M, Banneau G, Duyckaerts C, Tezenas du Montcel S, et al. Spastic paraplegia due to SPAST mutations is modified by the underlying mutation and sex. Brain. 2018;141: 3331–42. 01
3. Lo Giudice T, Lombardi F, Santorelli FM, Kawarai T, Orlacchio A. Hereditary spastic paraplegia: clinical-genetic characteristics and evolving molecular mechanisms. Exp Neurol. 2014;261:518–39. 1
4. Fonknechten N, Mavel D, Byrne P, Davoine C-S, Cruaud C, Boentsch D, et al. Spectrum of SPG4 mutations in autosomal dominant spastic paraplegia. Hum Mol Genet. 2000;9:637–44. 1
5. Depienne C, Tallaksen C, Lephay JY, Bricka B, Poea-Guyon S, Fontaine B, et al. Spastin mutations are frequent in sporadic spastic paraparesis and their spectrum is different from that observed in familial cases. J Med Genet. 2006;43:259–65.
6. Schieving JH, de Bot ST, van de Pol LA, Wolf NI, Brilstra EH, Frints SG, et al. De novo SPAST mutations may cause a complex SPG4 phenotype. Brain 2019;142:e31–e31.
7. Depienne C, Fedirko E, Faucheux J-M, Forlani S, Bricka B, Goizet C, et al. A de novo SPAST mutation leading to somatic mosaicism is associated with a later age at onset in HSP. Neurogenetics. 2007;8:231–3.
8. Aulitzky A, Friedrich K, Gläser D, Gastl R, Kubisch C, Ludolph AC, et al. A complex form of hereditary spastic paraplegia in three siblings due to somatic mosaicism for a novel SPAST mutation in the mother. J Neurological Sci. 2014;347:352–5.
9. Matthews AM, Tarailo-Graovac M, Price EM, Blydt-Hansen I, Ghani A, Drögemöller BI, et al. A de novo mosaic mutation in SPAST with two novel alternative alleles and chromosomal copy number variant in a boy with spastic paraplegia and autism spectrum disorder. Eur J Med Genet. 2017;60(Oct):548–52. 1
10. Ogasawara M, Saito T, Koshimizu E, Akasaka N, Sasaki M. A p. Arg499His mutation in SPAST is associated with infantile onset ascending spastic paralysis complicated with dysarthria and anarthria. Neuropediatrics. 2019;50:391–4.
11. Polymeris AA, Tessa A, Anagnostopoulou K, Rubegni A, Galatolo D, Dinopoulos A, et al. A series of Greek children with pure hereditary spastic paraplegia: clinical features and genetic findings. J Neurol. 2016;263:1604–11. 1
12. Higuchi Y, Hashiguchi A, Yuan J, Yoshimura A, Mitsui J, Ishiura H, et al. Mutations in MME cause an autosomal-recessive Charcot–Marie–Tooth disease type 2. Ann Neurol. 2016;79:659–72.
13. Depondt C, Donatello S, Rai M, Wang FC, Manto M, Simonis N, et al. MME mutation in dominant spinocerebellar ataxia with neuropathy (SCA43). Neurol Genet. 2016;2. https://www.ncbi.nlm.nih.gov/pmc/articles/PMC4991603/
14. Screening of patients with hereditary spastic paraplegia reveals seven novel mutations in the SPG4 (Spastin) gene - Proukakis - 2003 - Human Mutation - Wiley Online Library. https://onlinelibrary.wiley.com/doi/abs/10.1002/humu.9108
15. Park H, Kang S-H, Park S, Kim SY, Seo SH, Lee SJ, et al. Mutational spectrum of the SPAST and ATL1 genes in Korean patients with hereditary spastic paraplegia. J Neurol Sci. 2015; 357:167–72.

16. Solowska JM, Baas PW. Hereditary spastic paraplegia SPG4: what is known and not known about the disease. Brain 2015;138: 2471–84.
17. Parodi L, Rydning SL, Tallaksen C, Durr A. Spastic paraplegia 4. In: Adam MP, Ardinger HH, Pagon RA, Wallace SE, Bean LJ, Stephens K, et al., editors. GeneReviews® [Internet]. Seattle (WA): University of Washington, Seattle; 1993. http://www.ncbi.nlm.nih.gov/books/NBK1160/
18. Mosaicism and clinical genetics - Spinner - 2014 - American Journal of Medical Genetics Part C: Seminars in Medical Genetics - Wiley Online Library. 2020 https://onlinelibrary-wiley-com.docelec.u-bordeaux.fr/doi/full/10.1002/ajmg.c.31421
19. Morais S, Raymond L, Mairey M, Coutinho P, Brandão E, Ribeiro P, et al. Massive sequencing of 70 genes reveals a myriad of missing genes or mechanisms to be uncovered in hereditary spastic paraplegias. Eur J Hum Genet. 2017;25:1217–28.