

3. Potter R W K, Szomszor M, Adams J. Comparing standard, collaboration and fractional CNCI at the institutional level: Consequences for performance evaluation. *Scientometrics* 2022; **127**: 7435–7448.  
<https://doi.org/10.1038/s41415-023-5632-0>

## Oral medicine

### MRI and trigeminal neuralgia

Sir, in view of the recent published guidelines regarding the management of trigeminal neuralgia by the Royal College of Surgeons of England,<sup>1</sup> we wanted to bring a recent case to your attention.

An adult male attended an oral medicine department with complaints of an intermittent, shooting, unilateral pain radiating along the left maxilla towards the left nose and upper lip. Episodes could last up to five minutes, and he reported many sleepless nights resulting in fatigue throughout the day. Liaison with his GP had resulted in carbamazepine being prescribed which provided some symptom resolution.

After a sustained period of delay, he eventually attended his oral medicine consultation, describing his pain as having now settled. He reported side effects relating to the carbamazepine. No imaging was arranged. Following a further review, pain severity had now intensified. Oxcarbazepine and then gabapentin were both trialled, neither successful with unpleasant side effects reported.

Given the reoccurrence, an MRI brain scan was requested in line with trigeminal protocol.<sup>1</sup> A report revealed a left petrous apex meningioma with mass effect of the left trigeminal nerve cisternal course. His trigeminal neuralgia was diagnosed as being secondary to an intracranial meningioma.<sup>2</sup> Surgical resection of this tumour was recommended by his neurologist, which could result in resolution of his facial symptoms.<sup>3</sup>

Guidelines released by the Royal College of Surgeons of England supports MRI as the imaging modality of choice for screening of trigeminal neuralgia aetiology.<sup>1</sup> Up to 10% of patients presenting with trigeminal neuralgia have a secondary causal pathology such as a brain tumour, multiple sclerosis, or vascular malformations.<sup>1</sup> These can be identified through neuroimaging.<sup>1</sup> The following symptoms, as identified in this case, may indicate intracranial pathology: lack of response to pharmacological treatments, increase in

pain severity over time and continuous interrupted sleep patterns.

Trigeminal neuralgia is often misdiagnosed as migraines, post-herpetic neuralgia, TMD and dental aetiology.<sup>1</sup> This case highlights that even in sustained pain-free episodes, if the patient's history is consistent with trigeminal neuralgia, then there should be a low threshold for requesting imaging. Dental practitioners reviewing patients with confirmed trigeminal neuralgia may wish to confirm whether an MRI of the brain has been performed previously.

L. Roorcroft, Z. Khan, Manchester, UK

### References

1. Faculty of Dental Surgery of the Royal College of Surgeons of England. Guidelines for the management of trigeminal neuralgia. 2021. Available at: [https://www.rcseng.ac.uk/-/media/files/rcs/fds/guidelines/trigemina-neuralgia-guidelines\\_2021\\_v4.pdf](https://www.rcseng.ac.uk/-/media/files/rcs/fds/guidelines/trigemina-neuralgia-guidelines_2021_v4.pdf) (accessed February 2023).
2. Niwant P, Motwani M, Naik S. Atypical trigeminal neuralgia secondary to meningioma. *Case Rep Dent* 2015; doi: 10.1155/2015/462569.
3. Castro M R H, Magill S T, Morshed R A *et al*. Facial pain and sensory outcomes following resection of tumors compressing the trigeminal nerve. *J Neurosurg* 2021; **136**: 1119–1127.

<https://doi.org/10.1038/s41415-023-5633-z>

## Dental trauma

### Kite string-induced facial trauma

Sir, we read the article 'Facial trauma due to e-scooters' by I. Turner and M. Shah.<sup>1</sup> We wanted to address another grievous facial injury caused by kite strings. In northern India, kite flying is common during the winter festival of Lohri. During these festivals, 'kite fighting' is played mainly from rooftops of residential buildings, where people attempt to cut the opponent's kite string with theirs. People have recently employed techniques to strengthen their kite strings (*plastic dor*) by covering them with glass and glue, making the thread extremely sharp to cut other kite strings.<sup>2</sup> The leftover kite strings are seldom removed and become tangled over power lines and buildings,

frequently causing severe facial injuries and even fatalities to humans and birds.

Head and neck injuries account for 59%, whereas upper limb injuries account for 29% of all kite string injuries.<sup>3</sup> There have been reports of injuries ranging from laceration injuries to lethal throat lacerations, secondary impact injuries where strings get wrapped around a person's feet, leading to falling, causing fracture of extremities or head injuries, and ocular injuries. The high rate of injuries in the head and neck region is attributed to the region's exposure while riding a two-wheeler, the most common mode of transport in thickly populated residential areas, often without helmets. Injuries sustained by two-wheeler riders are more severe than those sustained by pedestrians, as the injury's severity is determined by the vehicle's speed onto tightly entangled kite strings.

During the Lohri celebration (14 January 2023), our oral and maxillofacial surgery team at Christian Dental College Ludhiana, India, treated ten cases of injuries caused by kite strings. Figure 1 shows kite string-induced facial trauma cases reported at the trauma unit. Although the local government has banned glass-coated kite strings, there needs to be a more effective public awareness campaign about the risks of trauma caused by kite strings to sensitise the general public.<sup>4</sup>

A. T. Alexander, I. Singh, A. M. Sabu, N. Kurian, Y. Vohra, Ludhiana, India

### References

1. Turner I, Shah M. Facial trauma due to e-scooters. *Br Dent J* 2023; **234**: 74.
2. Muvalia G, Jamshed N, Sinha T P, Bhoi S. Kite-string injuries: A case series. *Int J Crit Illn Inj Sci* 2019; **9**: 147–150.
3. Swain S K. Kite string injury to the head-and-neck region: A review. *Int J Otorhinolaryngol Head Neck Surg* 2022; **6**: 1–5.
4. Singh H. Open use of banned 'Chinese' string in Ludhiana for flying kite poses threat. *The Tribune* 2 January 2023. Available at: <https://www.tribuneindia.com/news/ludhiana/open-use-of-banned-chinese-string-in-ludhiana-for-flying-kite-poses-threat-466860> (accessed February 2023).

<https://doi.org/10.1038/s41415-023-5631-1>

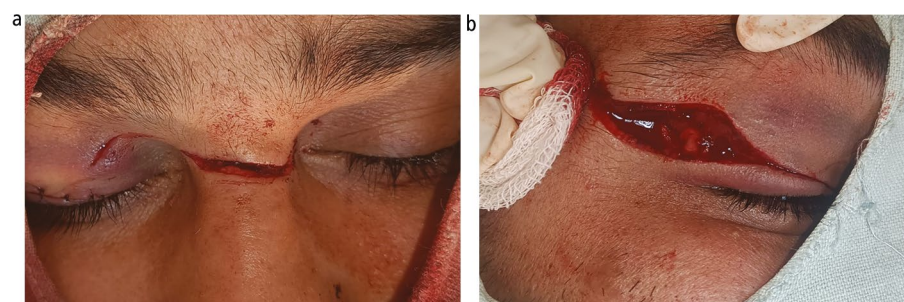


Fig. 1 a, b) Kite string-induced facial lacerations