

dental student. He had been struggling to extract a particularly stubborn lower molar and I intervened. After application of judicious force and technique, the tooth finally yielded. My husband later reported that his patient, a mature gentleman of large stature, had commented, about me, 'She was bl**dy good but I wouldn't want to be married to her'. My husband had wisely decided that any response would be inappropriate.

E. A. Field, Wirral, UK

References

1. Dewshi C. Why do we accept sexism in dentistry? *Br Dent J* 2022; **232**: 675.
2. Sellers J. Not an excuse. *Br Dent J* 2022; **232**: 842.

<https://doi.org/10.1038/s41415-022-4567-1>

Oral health

Menopause and oral health

Sir, the oral health effects of changes in certain hormone levels during pregnancy, namely in the form of pregnancy gingivitis, are well recognised with a large body of research and guidance for both patients and clinicians.¹ What is less clear, however, are the impacts of a reduction in certain hormone levels on oral health in post-menopausal patients.

The menopause is the period in a woman's life where the menstrual cycle stops, usually occurring between the ages of 45–55. This is due to a decline in hormone levels, particularly oestrogens and progesterone. The oral mucosa and salivary glands are known to contain oestrogen receptors, leading to suggestions that variations in oestrogen levels may directly affect the oral cavity.² Oral discomfort is often found in post-menopausal women with possible increased risks of periodontal disease, xerostomia and burning mouth syndrome.³

In addition to physiological symptoms, the menopause can have detrimental psychological effects on mood, confidence and anxiety which may alter dietary habits and dental attendance patterns with subsequent detrimental effects on oral health. Hormone replacement therapy (HRT) is a common treatment intended to relieve the symptoms of menopause but there is insufficient research on its benefits to oral health.³

We thank the authors of the *BDJ* article drawing attention to the issue of menopause in the dental workplace; however, guidance, research and discussion on patients transitioning through this phase in their

life is unfortunately absent.⁴ We ask dental professionals to be conscious of the menopause when managing this cohort of patients, whose oral health may be at risk akin to women in pregnancy. We hope with a larger research base and guidance, we can inform, advise and treat this large cohort of patients more appropriately in years to come.

M. Adam, Preston; J. Wooton, Sheffield, UK

References

1. European Federation of Periodontology. Oral health & pregnancy. 2022. Available at: <https://www.efp.org/gum-disease-general-health/oral-health-pregnancy> (accessed July 2022)
2. Leimola-Virtanen R, Salo T, Toikkanen S, Pulkkinen J, Syrjänen S. Expression of estrogen receptor (ER) in oral mucosa and salivary glands. *Maturitas* 2000; **31**: 131–137.
3. Suri V, Suri V. Menopause and oral health. *J Midlife Health* 2014; **5**: 115–120.
4. Bell J A, Garlick D, Stevens C. It's time to talk about the M word. *Br Dent J* 2022; **232**: 15–17.

<https://doi.org/10.1038/s41415-022-4568-0>

Dental trauma

Dental trauma aids and resources

Sir, I read with interest the recent publication in the *BDJ* entitled 'Top tips for the immediate management of dental trauma' by C. Seeballuck *et al.*¹ in which the authors mention resources such as the Dental Trauma Guide and Dental Trauma UK websites as well as the ToothSOS mobile app in the management of dental trauma.

It would be of interest to note that clinical decision support tools (CDSTs) in the print or web/mobile app-based form have been demonstrated as effective tools in the management and diagnosis of traumatic injuries to the dentition.^{2,3} There is evidence in the literature to support the absence of a pathway for decision-making for dental trauma in emergency departments dealing with paediatric dental injuries. This makes the incorporation of CDSTs more valuable. Dental injuries may not necessarily present to the dentist but may also have to be managed initially by medical professionals, which further underscores the importance of incorporating CDSTs. One such study has highlighted the improvement in performance exhibited by medical students when aided with CDSTs in the context of diagnosing and managing paediatric dental trauma.³

Web/mobile-app based resources, however, need to have a sound basis in literature. Of these, the app *Dental Trauma* has the

endorsement of the IADT and *AcciDent* is one app which is tailored for usage by dental professionals.²

V. Sahni, Chandigarh, India

References

1. Seeballuck C, Dolan S, Kilgariff J. Top tips for the immediate management of dental trauma. *Br Dent J* 2022; **233**: 8–12.
2. Machado J P, Lam X T, Chen J W. Use of a clinical decision support tool for the management of traumatic dental injuries in the primary dentition by novice and expert clinicians. *Dent Traumatol* 2018; **34**: 120–128.
3. Huh A J H, Chen J W, Bakland L, Goodacre C. Comparison of different clinical decision support tools in aiding dental and medical professionals in managing primary dentition traumatic injuries. *Pediatr Emerg Care* 2022; doi: 10.1097/PEC.0000000000002409.

<https://doi.org/10.1038/s41415-022-4569-z>

Air gun injury

Sir, it is with great interest that I read a recent article detailing a management approach for injuries caused by air guns.¹ It reminded me of a patient I saw during my third dental core training year, who presented with a diabolo-shaped pellet in the superficial fascia below the lower border of their mandible (Fig. 1), with no concomitant symptoms other than tenderness over the point of entry.

Fortunately, my supervising OMFS registrar was able to assist me in managing this patient.

I would like to thank the authors as, although this type of injury may be uncommon, I am sure their flowchart will assist clinicians with decision-making.

K. Matharu, Birmingham, UK

Reference

1. Owen-Johnstone M, Broderick D, Graham R. Air guns and their wider relevance to the dental profession. *Br Dent J* 2022; **232**: 861–863.

<https://doi.org/10.1038/s41415-022-4570-6>

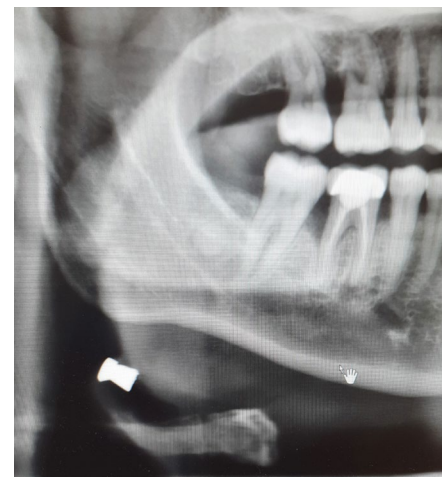


Fig. 1 Radiograph showing a pellet in a patient's mandible