been cross-referenced to the clinical picture. Where anomalies are identified, a radiograph report can contribute invaluable information to rule out errors and artefacts.

H. Sapa, L. Johnston, A. Casaus, Birmingham, UK

Reference

1. Rondon R H, Pereira Y C, do Nascimento G C. Common positioning errors in panoramic radiography: A review. *Imaging Sci Dent* 2014; **44:** 1-6.

https://doi.org/10.1038/s41415-021-3101-1

OMFS

Stabilisation

Sir, surgical management of patients can often be complicated by advancing age and multiple co-morbidities.[1] This requires increasingly considered, flexible and conservative approaches to surgical decision-making.

A 77-year-old patient presented with a fractured atrophic edentulous mandible, already challenging to manage because of poor bone quality with reduced vascularity and fracture end contacts which risk significant complications. Poor fracture healing may also follow periosteal stripping associated with traditional open reduction/internal fixation (ORIF) techniques.[2] The medical history revealed advanced osteoporosis managed with previous IV bisphosphonates and concurrent Denosumab with steroids.[3] This patient was therefore at high risk of medication-related osteonecrosis of the jaw (MRONJ). To reduce this risk, the pre-existing lower denture was used to reduce and stabilise the fractured mandible,[4] which we believe is an under-utilised minimally invasive/closed strategy.

The denture was stabilised with supra-periosteal circum-mandibular wires, thereby splinting the fractures. Wires were positioned vertically close to the fracture sites, which led to improved apposition, reduced wire migration and no occlusal interference (Fig. 1). Denture stability was increased utilising the patient's pre-existing anterior mandibular dental implants with precision attachments and ensuring correct occlusion. Acceptable fracture reduction and stabilisation was achieved with eventual healing (Fig. 2). This was done knowing that the risks of open surgery in older patients with systemic health problems may outweigh the risks of sub-optimal fracture alignment.

This minimally invasive strategy avoided ORIF, therefore reducing patient exposure to the risks associated with this and thereby lowering their potential risk of MRONJ. This case demonstrates a minimally invasive decision-making approach based on clinicians' experience that was also influenced by significant patient risk factors.

J. E. Tebbutt, Bournemouth; A. H. Bhanji, R. M. Graham, H. Nasry, North Manchester, UK

References

1. Brucoli M, Boffano P, Romeo I *et al*. The epidemiology of edentulous atrophic mandibular fractures in Europe. *J Craniomaxillofacial Surg* 2019; **47:** 1929-1934.
2. Barber H D. Part I: conservative management of the fractured atrophic edentulous mandible. *J Oral Maxillofacial Surg* 2001; **59:** 789-791.
3. Ruggiero S L, Dodson T B, Fantasia J *et al.* American Association of Oral and Maxillofacial Surgeons position paper on medication-related osteonecrosis of the jaw - 2014 update. *J Oral Maxillofacial Surg* 2014; **72:** 1938-1956.
4. Gerhards F, Kuffner HD, Wagner W. Pathological fractures of the mandible: a review of the etiology and treatment. *Int J Oral Maxillofacial Surg* 1998; **27:** 186-190.

https://doi.org/10.1038/s41415-021-3102-0

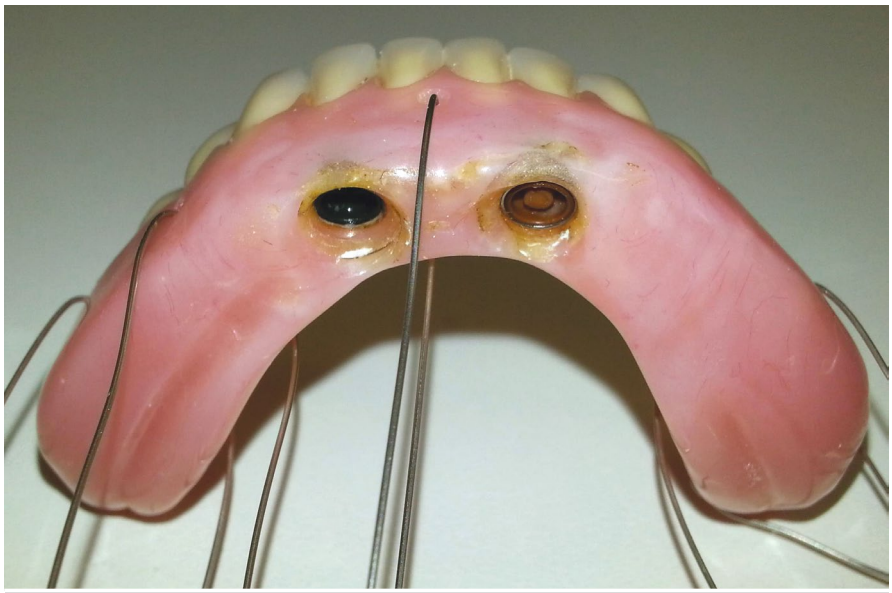

Fig. 1 The denture was stabilised with supra-periosteal circum-mandibular wires, thereby splinting the fractures

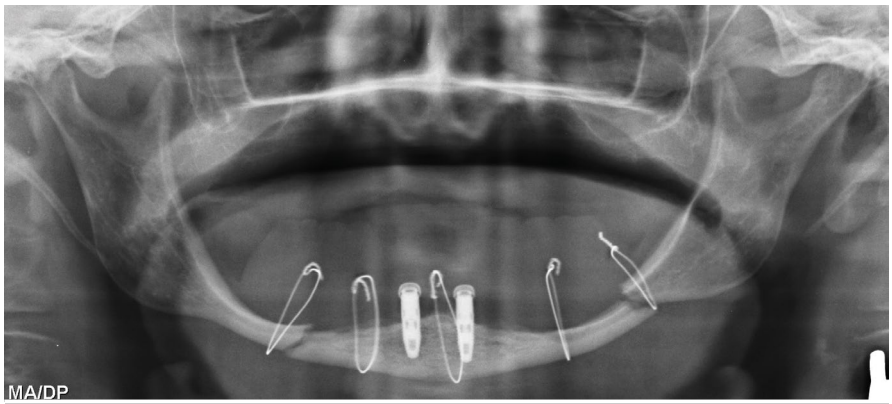

Fig. 2 Acceptable fracture reduction and stabilisation was achieved with eventual healing