

Dental radiography

Another conundrum

Sir, following on from M. Watts' letter, I report a similar experience.¹ A 26-year-old female was referred to our specialist oral surgery practice for removal of a grossly carious 17. A half-orthopantomogram (OPT) of the right side showed gross caries of 17, 18 and 47 and five regular radiopacities within the right eye socket (Fig. 1). The patient had no history of facial, eye or brain surgery nor injury and was not wearing hair clips or clip-in hair extensions. Provisional diagnosis was artefact or previous forgotten surgery.

A full OPT was taken post-operatively and bilateral radiopacities were identified within the right and left eye sockets, also revealing caries in 37 and 38 (Fig. 2). The patient was wearing short, false eyelashes which, upon

requested removal, revealed five metal pieces in each lash. These magnetic eyelashes work by painting an iron oxide liner on the upper eyelid lash line, to which small magnets at the base of false eyelashes adhere. They have been on the market since 2018 and some manufacturers warn not to wear them when having an MRI. The patient had attached her lashes with regular eyelash glue, she was unaware they were magnetic, which added to the dilemma.

This is an interesting case which practitioners may come across on radiographs, especially as beauty products become ever more advanced.

K. O'Brien, Belfast, UK

Reference

1. Watts M. A radiological conundrum. *Br Dent J* 2020; **229**: 636.

<https://doi.org/10.1038/s41415-021-2757-x>

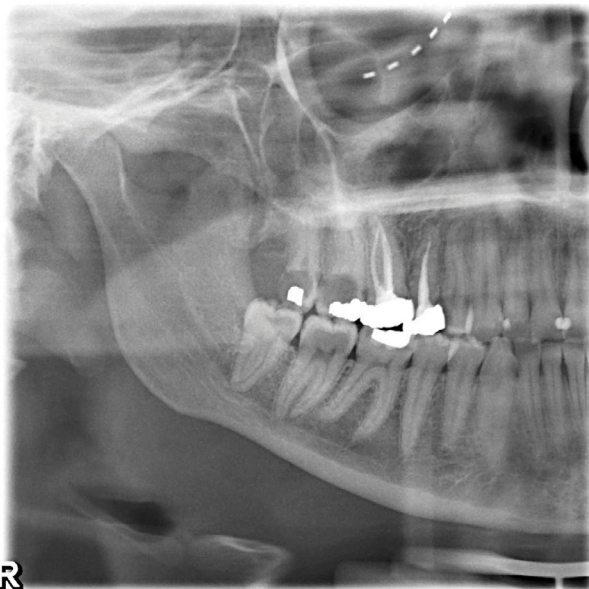


Fig. 1 An OPT of the right side showed gross caries of 17, 18 and 47, and five regular radiopacities within the right eye socket

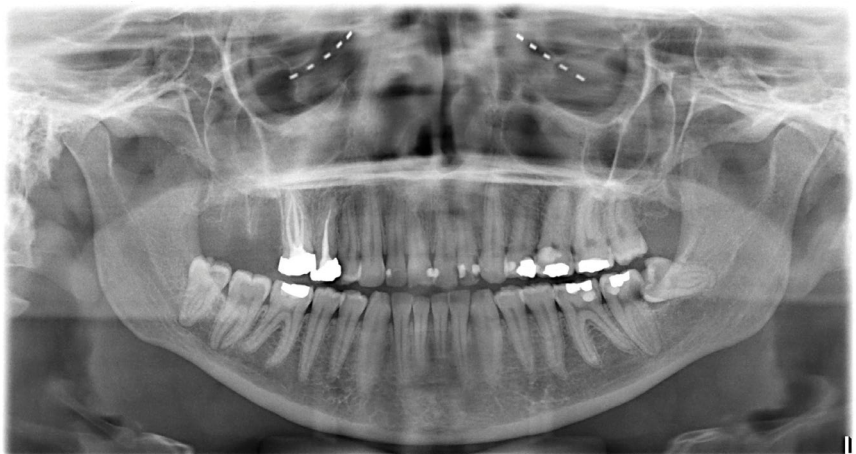

Fig. 2 Full OPT taken post-operatively

The history of dentistry

Historic value

Sir, all those BDA members who are interested in the history and heritage of our profession will wish to mark 2021 as the 150th anniversary of the birth of Dr Lilian Lindsay CBE, FSA. The Robert and Lilian Lindsay Library and the BDA Museum are entities of which the UK dental profession can be justly proud. Since 1964 both have been supported by the BDA Charitable Trust and are now internationally renowned. How sad to contrast this progress with the recent action of my own specialty society. Last year the Board of the British Orthodontic Society (BOS) decided, without consultation, to reduce the annual budget of its Archive and Museum Committee by two-thirds to just £5,000, and this in the year in which the Society's total funds showed an increase of £163,570 to almost £3.5 million.¹

Were she alive today Dr Lindsay, who was both a President and Senior Vice President of the British Society for the Study of Orthodontics (BSSO), the BOS's predecessor, would surely be dismayed. Such concerns would also be shared by the late George Northcroft OBE, a founder of the BSSO and a highly cultured man, who was also the first curator of the BDA Museum which he supported from his own pocket.²

In 1933, Dr Lindsay published her notable work *A short history of dentistry*.³ The following year the Cambridge historian George Macaulay Trevelyan OM started compiling his masterwork *English social history*. In this he states 'There is nothing that more divides the civilised from the semi-savage man than to be conscious of our forefathers as they really were, and bit by bit to reconstruct the mosaic of the long-forgotten past'.⁴

Long may the BDA and its Lindsay Society continue to embrace the civilised traditions and responsibilities of a learned society without which we are all the poorer.

*C. Stephens, President of the BOS 2001–2002,
Bristol, UK*

References

1. British Orthodontic Society. Summarised Balance Sheet, as at 31/12/2019.
2. Handley N. Museum man - The overlooked influence of Joseph Lewin Payne. *Dent Hist* 2016; **63**: 56-61.
3. Lindsay L. *A short history of dentistry*. London: John Bale & Sons, 1933.
4. Trevelyan G M. *English social history*. London: Longman Green and Co. Ltd., 1942.

<https://doi.org/10.1038/s41415-021-2758-9>