CPD: ONE HOUR

CPD questions

This article has four CPD questions attached to it which will earn you one hour of verifiable CPD. To access the free BDA CPD hub, go to https://cpd.bda.org/login/index.php

Challenges in plain film radiographic diagnosis for the dental team

As more cross-sectional imaging is undertaken in primary and secondary care, **Manas Dave**,[1] **Amanda Loughlin**,[2] **Edward Walker**[3] and **Jonathan Davies**[4] examine the common pathological conditions of the maxillary sinus that can be visualised on dental imaging.

Abstract

The maxillary sinus is the largest of the paranasal sinuses, with its structure and contents commonly visualised on dental radiographs. Dental practitioners are required to evaluate the entire radiograph, and it is likely there is limited exposure to maxillary sinus pathoses and radiological interpretation in the undergraduate curriculum and routine continuing professional development courses. This review covers radiological features of common benign and malignant sinus disease. Identification of normal anatomical features, common variations and pathoses can facilitate holistic patient management and potentially early detection of neoplastic disease.

Introduction

There are paired air-filled cavities in the skull: frontal, ethmoidal, maxillary and sphenoidal sinuses, collectively termed the paranasal sinuses. These are collectively termed the paranasal sinuses. The largest are the maxillary sinuses which are pyramidal in shape and arguably the most important sinuses for dental professionals.

The maxillary sinus (synonymous with the terms maxillary antrum and antrum of Highmore)[1] is lined with respiratory epithelium – pseudostratified ciliated columnar epithelium with mucus-secreting goblet cells which forms the Schneiderian membrane (it is of note that the Schneiderian membrane covers the nasal mucosa and paranasal sinuses, but will be referred to as the maxillary sinus membrane hereafter to specifically refer to its anatomical site). Mucus is transported through the contractile motion of ciliated cells towards the opening of the sinus, termed the ostium. The ostium of the maxillary sinus drains into the middle meatus of the nasal cavity. The anatomical composition of this drainage pathway is complex and the components are collectively termed the ostiomeatal unit (Fig. 1).[2]

While the maxillary sinus appears pyramidal in shape, its anatomy is best visualised as a three-dimensional rhomboid – the base as the maxillary palate and alveolar process, roof as the floor of the orbit, medial surface as the lateral wall of the nasal cavity, and lateral/anterior surface as the wall between the cheek forming the

Author information

[1]Academic Clinical Fellow Oral Maxillofacial Pathology, Division of Dentistry, School of Medical Sciences, Faculty of Biology, Medicine and Health, University of Manchester, Manchester Academic Health Science Centre, Oxford Road, Manchester, M13 9PL, UK; [2]Speciality Trainee in Dental Maxillofacial Radiology, Guy's Hospital, Floor 23, Tower Wing, Great Maze Pond, London, SE1 9RT, UK; [3]Speciality Trainee in Dental Maxillofacial Radiology, Leeds Dental Institute, The Worsley Building, Clarendon Way, Leeds, LS2 9LU, UK; [4]Consultant in Dental Maxillofacial Radiology, Guy's Hospital, Floor 23, Tower Wing, Great Maze Pond, London, SE1 9RT, UK.

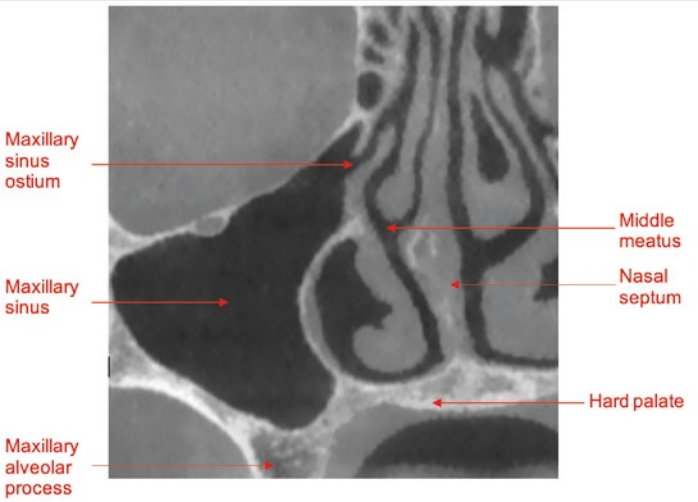

Fig. 1 Labelled cone beam computed tomography (CBCT) coronal slice demonstrating the relationship of the maxillary sinus to the nasal cavity and other surrounding structures

Fig. 2 a) Left sectional DPT appears to show the roots of 26 extending into the left maxillary antrum. b) Coronal slice of the subsequent CBCT examination demonstrates that the appearance on the DPT is due to superimposition, as opposed to direct extension of the roots into the antrum

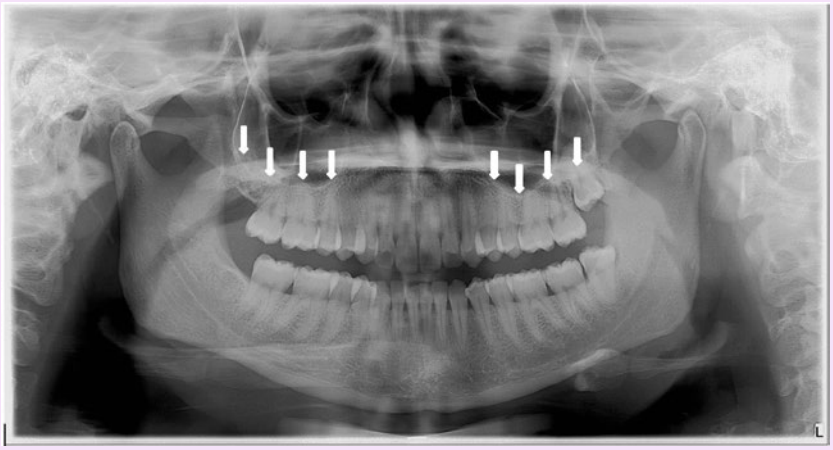

Fig. 3 The intact maxillary sinus floor appears as a well-defined, uninterrupted radiopaque line (identified bilaterally by white arrows) on the panoramic radiograph. The adjacent healthy maxillary sinuses are radiolucent due to their air content

facial surface of the maxilla. The posterior wall of the sinus creates a barrier with the infratemporal and pterygopalatine fossae.

The Ionising Radiation (Medical Exposure) Regulations (2017) state that employers must have procedures for 'carrying out and recording an evaluation for each exposure', with evaluation defined as interpretation of the information resulting from an exposure.[3] For the majority of dentists in general practice, this is likely to be the same individual who prescribes, undertakes and then reports on the radiograph. The maxillary sinus can often be visualised on dental radiographs and it is common to see radiological signs of antral pathoses. Normal anatomical variations and pathoses of the maxillary sinuses were one of the most common diagnoses made by dental maxillofacial radiologists as a result of referrals primarily from general dental practitioners (GDPs).[4]

The anatomy, its variations and common pathoses are unlikely to be covered in detail in the undergraduate curriculum or in continuing professional development courses. Therefore, the aim of this paper is to review radiological features of common variations and pathoses of the maxillary sinus.

Normal anatomy

Intra-oral radiographs can visualise the inferior aspect of the maxillary sinus, while dental panoramic tomography (DPT – synonymous with orthopantomogram [OPG or OPT]) can show a large proportion of the sinus. The roots of maxillary posterior teeth may appear to be extending into the sinus (Fig. 2a); however, it is important to remember that plain film dental radiography is two-dimensional and the roots may simply be superimposed over the sinus (as demonstrated in a cross-sectional image in Fig. 2b). The floor/inferior border of the maxillary sinus can be traced as a thin corticated outline (Fig. 3), which should appear well-defined and intact. As the healthy sinus contains air, its appearance should be radiolucent compared to surrounding trabecular bone.

Anatomical variations relevant to dentistry

The maxillary sinus can be partially or completely divided into recesses by barriers of cortical bone emerging from the lateral walls known as septa (synonymous with Underwood's septa).[5] These are common anatomical variations with studies showing 22–31% of the population having one or multiple septa within one or both maxillary sinuses.[6,7] The maxillary sinus membrane is a mucoperiosteal membrane that adheres not only to the walls of the sinus but also to the septae. These bony barriers can be

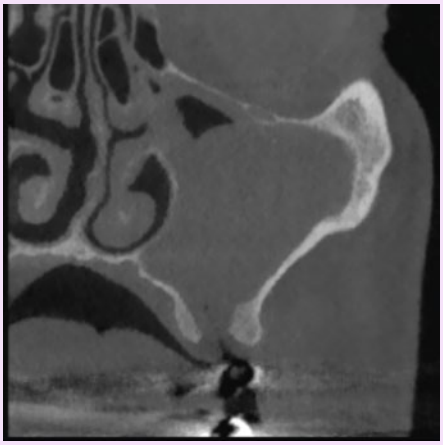

Fig. 4 Coronal CBCT slice demonstrating the presence of an oro-antral communication following extraction of 26. The left maxillary sinus is opacified due to inflammatory mucosal thickening, secretions, passage of fluid from the oral cavity, or a combination of these

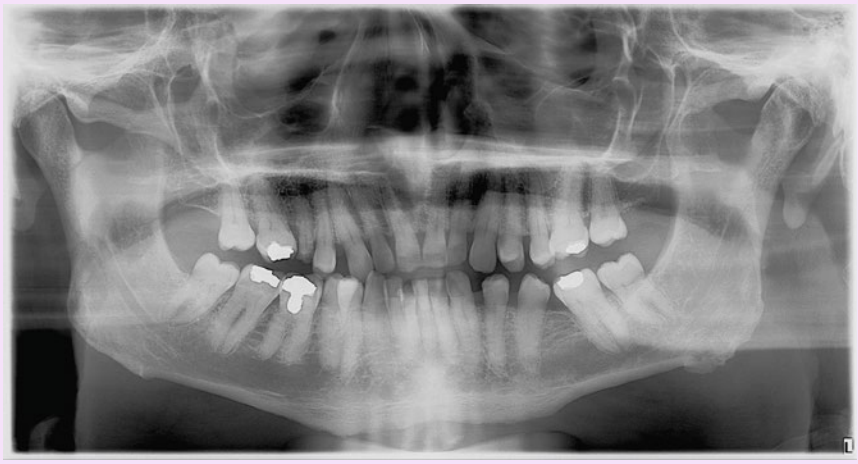

Fig. 5 Partial opacification of the left maxillary sinus. The normal radiolucent appearance is lost due to reduction in the volume of air within the sinus

'It is important to ensure the entirety of the lesion is visualised to allow for distinction between anatomical variations and true pathosis'

visualised on DPTs; however, their orientation is poorly identified, hence clinicians performing sinus surgery or access through the lateral sinus wall should consider three-dimensional imaging of septa in the region of the surgical site.[6,8] Clinical implications of septa include visual obstruction during surgery, increased difficulty of luxating the maxillary sinus membrane during sinus floor elevation, and subsequent risk of perforation.[9,10,11] There is also the possibility for misinterpretation of septa as the wall of a cyst. If clinicians suspect a pathological change, it is important to ensure the entirety of the lesion is visualised to allow for distinction between anatomical variations and true pathosis.

Hypoplasia of the paranasal sinuses is an uncommon finding with a reported incidence of 1.73–10.4% in patients with sinus symptoms. It can be mistaken for other pathoses so its recognition as a variant of normal anatomy is important.[12] The maxillary sinus develops embryologically and continues to grow until around eight years of age. Developmental conditions (such as Down syndrome and craniosynostosis), infections, irradiation or trauma can arrest sinus development to varying degrees.[13]

An infectious process can initiate metaplasia of the maxillary sinus membrane from a respiratory epithelium towards a squamous epithelium and lead to maxillary sinus hyperplasia.[14] Other causes of maxillary sinus lining hyperplasia include trauma, neoplastic disease, dental disease and allergic rhinitis.[15] Both hypoplasia and hyperplasia of the maxillary sinus are commonly asymptomatic incidental findings and themselves usually require no treatment.

Pneumatisation is a physiological process that affects all paranasal sinuses. It refers to the increase in size and volume of the air space and is commonly observed following extraction of a tooth in the posterior maxilla.[16] The exact mechanism is contested; however, it is likely a combination of maxillary sinus expansion and loss of vertical dimension of the edentulous ridge.[17] Pneumatisation between adjacent teeth is often seen and can increase the risk of oral antral communication (OAC). An OAC is a direct channel between the oral cavity and maxillary sinus (Fig. 4), with food, fluid and air being transferred between both cavities. An oral antral fistula (OAF) develops when this channel becomes lined by epithelium. At this stage, the channel cannot undergo repair with granulation

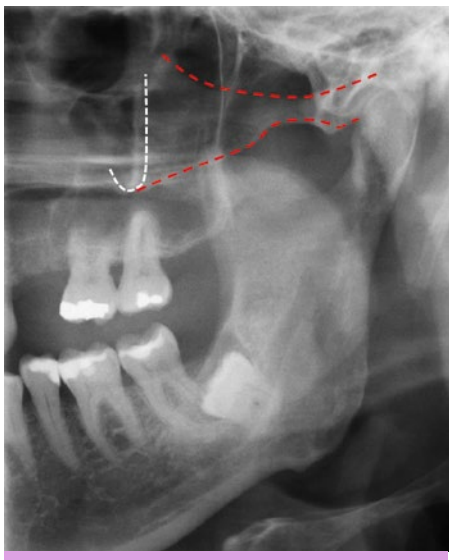

Fig. 6 The relative radiopacity of the maxillary sinus is artefactual due to superimposition of the left zygomatic process of the maxilla and zygoma (traced by the red interrupted lines and the zygomatic buttress is outlined by the white interrupted lines)

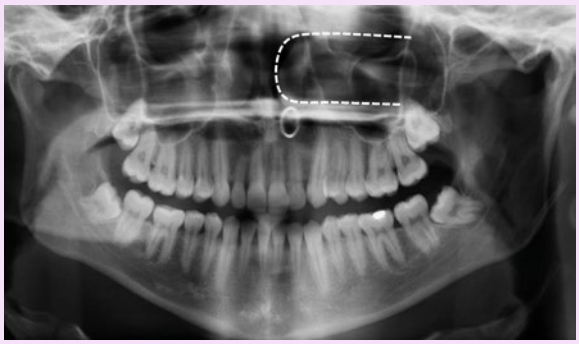

Fig. 7 The superimposition of the inferior nasal concha on this dental panoramic radiograph has resulted in an artefactual radiopaque appearance of the maxillary sinus. The left nasal piercing is projected superior to the upper left incisors

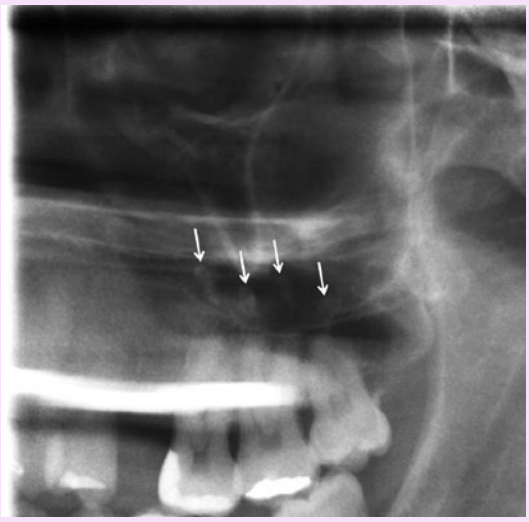

Fig. 8 The left maxillary sinus contains small radiodense material consistent with the appearance of an antrolith (white arrows). Image courtesy of Dr Jackie Brown

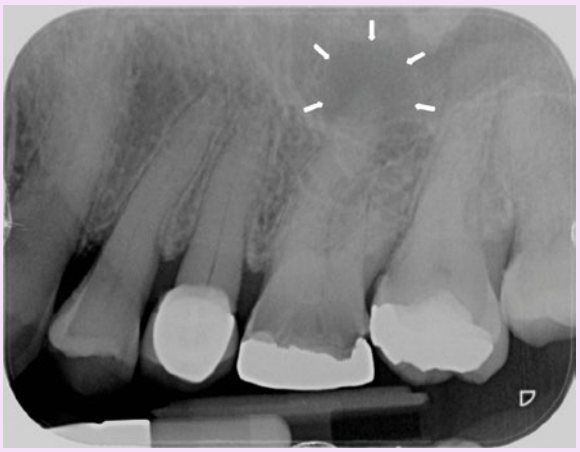

Fig. 9 Intra-oral periapical radiograph demonstrating periapical pathosis associated with the palatal root of 26 (white arrows). When compared to air within the oral cavity, this has a radiopaque appearance. It is relatively isodense to the contents of the maxillary sinus, suggesting mucosal thickening of the adjacent maxillary sinus lining

tissue so there is no maturation of tissue to form bone. The epithelial tract in the OAF needs to be excised to allow healing to occur. Aside from discomfort, the channel also results in microbial contamination and can lead to inflammation of the maxillary sinus, plus symptoms of pain, maxillary toothache, congestion and postnasal drip.[18]

Exostoses are outgrowths of cortical and cancellous bone, similar to those present intra-orally as maxillary and mandibular tori. They characteristically attach to the maxillary sinus wall with free margins in all other dimensions; nevertheless, are uncommon with a reported prevalence of 0.9–4.8% and do not require treatment.[19,20]

Opacification

Sinus opacification is a term used to describe complete opacification of the maxillary sinus either unilaterally or bilaterally (Fig. 5). The complete radiodense appearance of the sinuses can be caused by a number of conditions displacing air out of the sinus, including inflammatory disease, fungal sinusitis, mucoceles, mucous retention cysts and benign neoplastic disease such as an inverted papilloma (the most common benign neoplasm of the paranasal sinuses).[21] Superimposition of anatomical structures on rotated panoramic radiographs can lead to the artefactual appearance of maxillary sinus opacification (Figures 6 and 7). Clinicians need to carefully examine the radiograph and ensure the appearance is due to disease rather than positioning errors.

It is of note that malignant neoplastic disease, while uncommon, can also manifest as maxillary sinus opacification; features of which are discussed later in this article.[22] As not all DPT radiographs will visualise the roof of the maxillary sinus, total opacification (once dental causes have been ruled out) does require referral for appropriate management that may include further cross-sectional imaging to visualise the entire lesion and referral to an ENT (otorhinolaryngology) specialist.

Antroliths

Calcification of mineral salts around a nidus within the maxillary sinus can lead to the formation of an antrolith. The nidus can be exogenous (foreign body) or endogenous (mucus, clot, fungal mass) in origin. The continual action of the cilia in the sinus epithelium prevents stagnation of salts; however, this mechanism can be disrupted by an inflammatory process.[23] Radiographically, the appearance of an antrolith is that of a concentrated area of radiodensity (Fig. 8), with

Fig. 10 Localised elevation of the maxillary sinus floor (white arrows) in response to apical pathosis associated with the root-filled 26. Image courtesy of Dr Mohamed El-Belihy

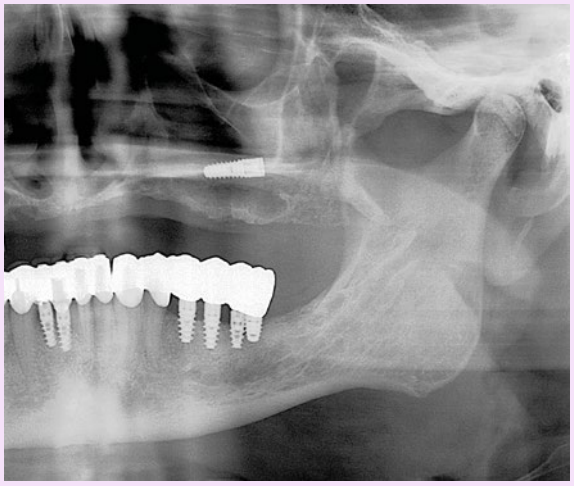

Fig. 11 An example of maxillary sinus mucosal thickening of iatrogenic origin. The left maxillary sinus has lost its normal radiolucent appearance inferiorly, suggesting a degree of mucosal thickening around the displaced implant

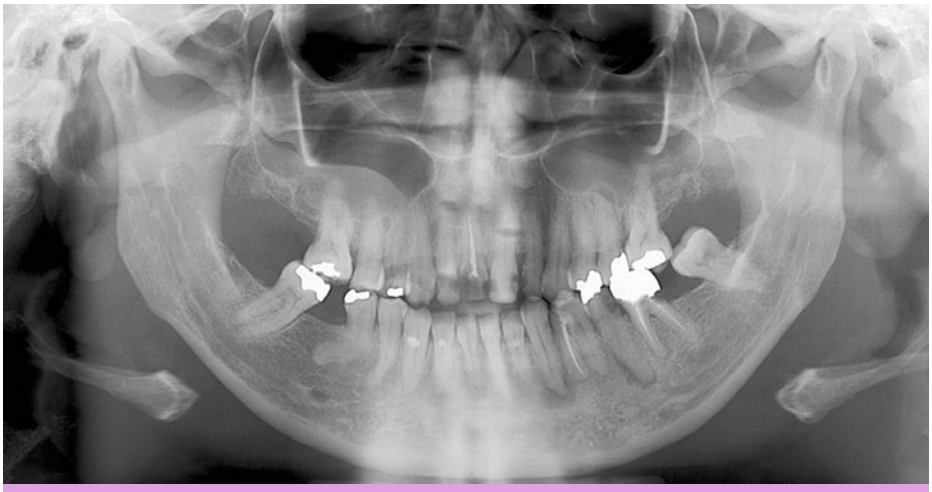

Fig. 12 Partial opacification of the maxillary sinuses bilaterally. On the left, the appearance is suggestive of mucosal thickening, possibly in response to the apical pathosis associated with upper left second premolar. On the right, the absence of adjacent dental pathosis and the smooth, dome-shaped superior border of the area of radiodensity is more suggestive of a benign mucous retention cyst

symptoms variable depending on size. Small antroliths are seldom likely to cause symptoms; however, as further calcification takes places, it can manifest symptoms of sinusitis, epistaxis and congestion.[16] They are uncommonly seen on two-dimensional imaging and most commonly occur unilaterally.[24] It is important to differentiate them from neoplastic disease, which may grow to a substantial size before symptoms arise.[25] It is of note that calcified masses developing in the nose are distinct and termed rhinoliths.

Foreign bodies

Foreign bodies in the sinus can often be detected on DPT or lateral cephalometric radiographs where the majority of the sinus can be visualised. Plastics and metals can often be clearly visualised due to their relative radiodensity; however, if they have been present for a considerable length of time, a local inflammatory (foreign body) reaction can result in granulation tissue deposition. This causes thickening of the sinus lining around the object, making detection and retrieval more challenging. Root apices displaced into the sinus can be difficult to clearly visualise, especially within the mucosal lining. These foreign bodies left in the sinus can lead to chronic inflammation, symptoms of sinusitis, and act as a nidus for calcium salts. It is important to refer the patient to ENT or oral surgery for localisation with further cross-sectional imaging and root retrieval with appropriate surgical intervention.

Odontogenic disease and the maxillary sinus

Dental pathoses such as periapical infections normally result in a radiolucency near the apices; however, when the roots of such affected teeth are superimposed over the air space of the maxillary sinus, the appearance is relatively radiopaque (Fig. 9). This is the result of inflammatory tissue and fluid being more radiodense than surrounding air in the sinus, projecting such a relative radiopacity.

Trabecular bone is porous and the cortex of the maxillary sinus is thin. Inflammatory exudate related to an odontogenic lesion within the alveolar bone can result in local inflammatory mucosal thickening of the maxillary sinus membrane. Progression of apical pathosis and development of expansile cystic lesions can result in bony remodelling and localised elevation of the cortical floor of the maxillary sinus (Fig. 10). Periodontal disease, trauma, pathological lesions of the maxilla and surgical complications such as implant surgery (Fig. 11) or overextended root canal obturations have also been shown

to cause inflammation of the membrane.[26,27]

Chronic infection can result in mucosal thickening of the floor of the sinus, which is observed as a pronounced uniform radiopacity, and can result in classic sinusitis symptoms or remain asymptomatic. Odontogenic factors have been reported to contribute to 12–40% of all cases of maxillary sinusitis.[28,29] Other dental causes of maxillary sinusitis may include extruded root filling material, displaced roots of extracted teeth, implants which encroach on the maxillary sinus, displaced bone graft material, and other dental pathoses.

The floor of the maxillary sinus lies in close proximity to the apices of the maxillary premolars and molars. Benign lesions of odontogenic origin tend to displace the floor of the maxillary sinus in a superior direction, whereas benign lesions arising within the maxillary sinus have little effect on the floor of the maxillary sinus. If the lesion has an overlying cortical outline, this is likely an odontogenic lesion. The overlying cortical outline is the displaced floor of the maxillary sinus and this appearance is referred to as an 'antral halo'. This can be a useful diagnostic tool when examining a lesion in the region of the maxillary sinus.

Inflammatory mucosal thickening

It is important to differentiate the terms sinusitis from inflammatory mucosal thickening of the maxillary sinus. Sinusitis is a clinical diagnosis based on investigations and clinical history; the clinician should be confident to exclude other pathoses. Inflammatory mucosal thickening refers to the increased radiopacity overlying the sinus floor; it is a sign that could indicate sinusitis but is not exclusive to this condition – for example, inflammation of the sinus membrane can result in reactive hyperplasia.[28,30] The common cold, allergies, pollution, dust, asthma, neoplastic disease, disease of odontogenic origin (Fig. 12) and otolaryngeal infections are among the many conditions that can cause inflammatory mucosal thickening.[15,31] Unilateral or bilateral thickening of the mucosal lining have been reported as the most frequent incidental findings on computed tomography (CT) scans that include the maxillary sinus.[28]

Polyps

Polyps within the maxillary sinuses are known as antrochoanal polyps or Killian's polyps and are the result of benign respiratory epithelial hypertrophy, which has a tendency to grow and track out of the ostium towards the nasopharynx. They are distinct from nasal polyps which emerge from ethmoidal cells.[32] Blockage of the ostium can produce classic

Fig. 13 Left sectional panoramic radiograph demonstrating a benign mucous retention cyst within the left maxillary sinus. This homogenous radiodensity has a well-defined, smooth, dome-shaped superior surface (white arrows) and sessile relationship to the adjacent maxillary sinus wall. The lesion arises from within the maxillary sinus and, as such, is non-corticated

Fig. 14 An example of a squamous cell carcinoma causing bony destruction of the right maxillary sinus. Radiographically, there is loss of continuity of the floor of the maxillary sinus

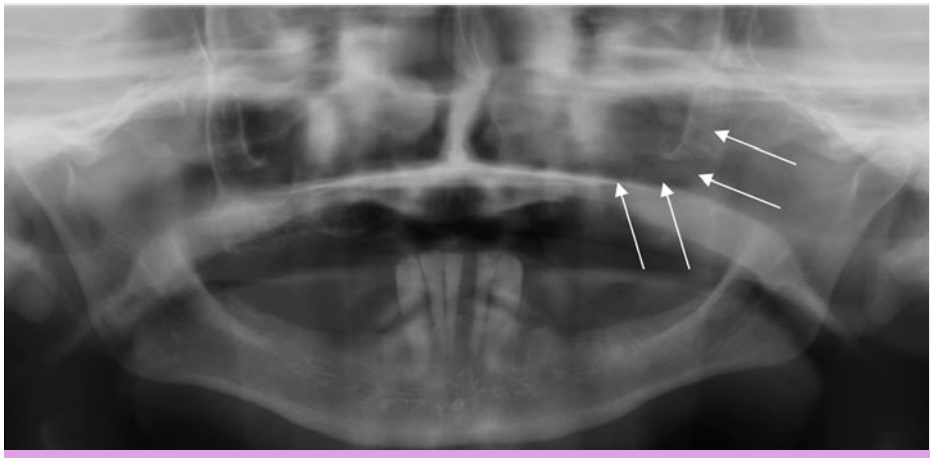

Fig. 15 An example of a lymphoma causing destruction of the floor and part of the posterior wall of the left maxillary sinus

sinus obstruction symptoms, but some have been known to produce epistaxis, dysphagia and dyspnea.[33] Antrochoanal polyps are usually unilateral and can be detected as a dome-shaped radiopaque mass with curved edges, sometimes with a stalk; however, this may not be clearly visualised in two-dimensional radiographs. Suspected cases are often evaluated with nasoendoscopy and cross-sectional imaging. Management depends on a number of factors, including the severity of symptoms. It may involve either medical treatment with topical steroids, surgical excision, or both.

Cysts of the sinus

Odontogenic cysts within the maxillary sinuses appear as rounded, soft-tissue masses in the region of the floor of the maxillary sinus with an overlying antral halo. The most common cyst in the tooth-bearing areas of the jaws is the radicular cyst.[16] This cyst is associated with the apex of a non-vital tooth, and treatment may include endodontic treatment and apicectomy or extraction and enucleation of the cyst. Failure to adequately remove a radicular cyst at the time of exodontia may result in a residual cyst persisting.

A dentigerous cyst is associated with the crown of an unerupted tooth. It may show a greater degree of expansion than a radicular cyst and may cause significant displacement of the associated tooth. An ectopic maxillary third molar in an unusual position (for example, near the orbital floor) should raise suspicion of the presence of a dentigerous cyst.

Obstruction of ducts within the mucous-secreting goblet cells that form the epithelium of the maxillary sinus cause dilatation of the gland and mucous accumulation. They are referred to as mucous retention cysts, a relatively frequent incidental finding which are often asymptomatic but may produce symptoms of nasal obstruction, headache, facial pain, postnasal drip and discharge. They are often self-limiting with spontaneous regression reported between 16–41% of all cases, with treatment not often required.[34,35] It is of note that their appearance can resemble those of a maxillary polyp. Radiologically, benign mucous retention cysts appear as a homogenous radiodensity with a smooth, dome-shaped superior surface. The adjacent maxillary sinus wall is always intact (Fig. 13).

Malignant neoplastic sinus disease

While maxillary sinus malignancies are uncommon, accounting for 3% of all head and neck malignancies, the maxillary sinus is the most likely paranasal sinus for neoplastic disease, with squamous cell carcinoma having the highest prevalence at 65–70%.[36,37,38,39] Lesions tend to be asymptomatic in the early stages, hence late detection results in reduced survival rates and complex management of a progressed lesion.[40] As the tumour expands and infiltrates surrounding bone, the patient may start to experience symptoms of neuropathy, nasal obstruction, loosening of teeth and ophthalmic symptoms when there is invasion through the orbital floor.[41]

Bone changes in conjunction with the radiographic appearance of a tumour can give an indication regarding the lesion's aggressiveness. Malignant lesions infiltrate and destroy bony walls, which can be detected radiographically (examples are provided in Figures 14 and 15). In contrast, slow-growing benign lesions such as Schneiderian papillomas exert pressure on surrounding bone and can cause bony expansion and osseous remodelling.[42,43]

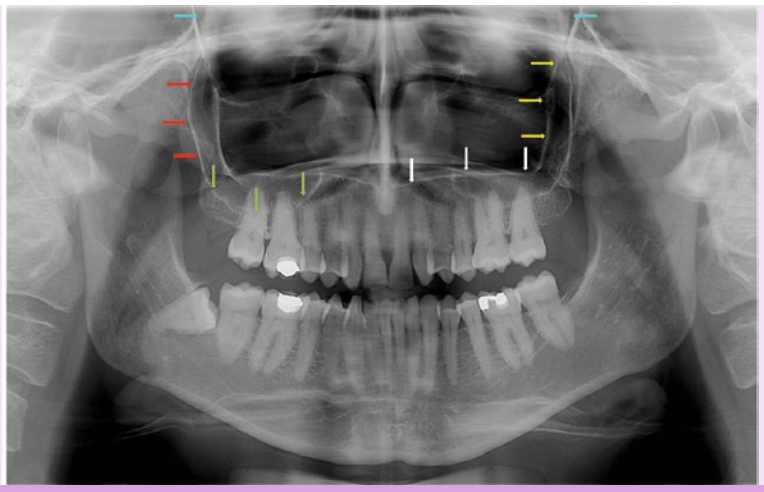

Fig. 16 Dental panoramic radiograph demonstrating aerated maxillary sinuses with intact cortical borders; antral floor (green arrows), posterior wall (red arrows), zygomatic buttress (yellow arrows), hard palate (white arrows) and pterygomaxillary fissure (blue arrows). The integrity of these cortical boundaries should be assessed as part of the methodical evaluation of all panoramic radiographs

Radiological reporting of the maxillary sinus

When examining the maxillary sinus, the clinician should first check the natural boundaries of the sinus to ensure all bony walls are intact. The contents of the sinus should be examined to ensure it is radiolucent, and any lesion(s) should be described based on its size, site and shape and a comment made on its relative radiodensity. Figure 16 demonstrates the important anatomical landmarks which represent the borders of the maxillary sinus on plain film imaging. It is crucial that their integrity is reviewed in all radiographs where the antra are visible.

Identification of a lesion should prompt the clinician to examine surrounding tissues to check for local signs (expansion, ulceration, communication etc) and enquire of any symptoms. This should be documented and a decision made regarding any referral that needs to be conducted, its recipient (for example, general medical practitioner, ENT surgeons, dental maxillofacial radiologist etc) and urgency.

Declarations of interests
The authors have no conflicts of interest to declare for this article.

This article was originally published in the BDJ *as* Challenges in plain film radiographic diagnosis for the dental team: a review of the maxillary sinus *on 24 April 2020 (Volume 228 pages 587-594).*

References

1. Sargi Z B, Casiano R R. Surgical anatomy of the paranasal sinuses. *In* Kountakis S E, Önerci M (eds) *Rhinologic and Sleep Apnea Surgical Techniques*. pp 17–26. Berlin: Springer Berlin Heidelberg, 2007.
2. Bell G W, Joshi B B, Macleod R I. Maxillary sinus disease: diagnosis and treatment. *Br Dent J* 2011; **210:** 113–118.
3. UK Government. The Ionising Radiation (Medical Exposure) Regulations 2017. 2017. Available at http://www.legislation.gov.uk/uksi/2017/1322/made (accessed August 2018).
4. Dave M, Horner K. Challenges in X-ray diagnosis: a review of referrals for specialist opinion. *Br Dent J* 2017; **222:** 431–437.
5. Underwood A S. An Inquiry into the Anatomy and Pathology of the Maxillary Sinus. *J Anat Physiol* 1910; **44(Pt 4):** 354–369.
6. Pommer B, Ulm C, Lorenzoni M, Palmer R, Watzek G, Zechner W. Prevalence, location

and morphology of maxillary sinus septa: systematic review and meta-analysis. *J Clin Periodontol* 2012; **39:** 769–773.
7. Kim M J, Jung U W, Kim C S *et al.* Maxillary Sinus Septa: Prevalence, Height, Location, and Morphology. A Reformatted Computed Tomography Scan Analysis. *J Periodontol* 2006; **77:** 903–908.
8. Ata-Ali J, Diago-Vilalta J V, Melo M *et al.* What is the frequency of anatomical variations and pathological findings in maxillary sinuses among patients subjected to maxillofacial cone beam computed tomography? A systematic review. *Med Oral Patol Oral Cir Bucal* 2017; DOI: 10.4317/medoral.21456.
9. van den Bergh J P, ten Bruggenkate C M, Disch F J, Tuinzing D B. Anatomical aspects of sinus floor elevations. *Clin Oral Implants Res* 2000; **11:** 256–265.
10. G andhi K R, Wabale R N, Siddiqui A U, Farooqui M S. The incidence and morphology of maxillary sinus septa in dentate and edentulous maxillae: a cadaveric study with a brief review of the literature. *J Korean Assoc Oral Maxillofac Surg* 2015; **41:** 30–36.
11. Lana J P, Carneiro P M, Machado Vde C, de Souza P E, Manzi F R, Horta M C. Anatomic variations and lesions of the maxillary sinus detected in cone beam computed tomography for dental implants. *Clin Oral Implants Res* 2012; **23:** 1398–1403.
12. Erdem T, Aktas D, Erdem G, Miman M C, Ozturan O. Maxillary sinus hypoplasia. *Rhinology* 2002; **40:** 150–153.
13. Jafari-Pozve N, Sheikhi M, Ataie-Khorasgani M, Jafari-Pozve S. Aplasia and hypoplasia of the maxillary sinus: A case series. *Den Res J* 2014; **11:** 615–617.
14. Christensen O, Gilhuus-Moe O. Surgical treatment of chronic hyperplastic sinusitis and maxillary sinus empyema of oral/dental origin. *Int J Oral Surg* 1979; **8:** 276–282.
15. Drumond J P N, Allegro B B, Novo N F, de Miranda S L, Sendyk W R. Evaluation of the Prevalence of Maxillary Sinuses Abnormalities through Spiral Computed Tomography (CT). *Int Arch Otorhinolaryngol* 2017; **21:** 126–133.
16. Mallya S M, Lam E W N. *White and Pharoah's Oral Radiology Principles and Interpretation*. 8th ed. St Louis: Mosby, 2018.
17. Levi I, Halperin-Sternfeld M, Horwitz J, Zigdon-Giladi H, Machtei E E. Dimensional changes of the maxillary sinus following tooth extraction in the posterior maxilla with and without socket preservation. *Clin Implant Dent Relat Res* 2017; **19:** 952–958.
18. Hamdy R M, Abdel-Wahed N. Three-dimensional linear and volumetric analysis of maxillary sinus pneumatization. *J Adv Res* 2014; **5:** 387–395.
19. Alkurt M T, Peker I, Demirel O, Akay G, Gungor K, Ucok O. The prevalence of antral exostoses in the maxillary sinuses, evaluated by cone-beam computed tomography. *J Dent Sci* 2016; **11:** 225–230.
20. Ohba T, Langlais R P, Langland O E. Antral exostosis in panoramic radiographs. *Oral Surg Oral Med Oral Pathol* 1993; **76:** 530–533.
21. Kaplan B A, Kountakis S E. Diagnosis and pathology of unilateral maxillary sinus opacification with or without evidence of contralateral disease. *Laryngoscope* 2004; **114:** 981–985.
22. Chen H J, Chen H S, Chang Y L, Huang Y C. Complete Unilateral Maxillary Sinus Opacity in Computed Tomography. *J Formos Med Assoc* 2010; **109:** 709–715.
23. Ogata Y, Okinaka Y, Takahashi M. Antrolith associated with aspergillosis of the maxillary sinus: Report of a case. *J Oral Maxillofac Surg* 1997; **55:** 1339–1341.
24. Shenoy V, Maller V, Maller V. Maxillary Antrolith: A Rare Cause of the Recurrent Sinusitis. *Case Rep Otolaryngol* 2013; DOI: 10.1155/2013/527152.
25. Cohen M A, Packota G V, Hall M J, Steinberg J. Large asymptomatic antrolith of the maxillary sinus: Report of a case. *Oral Surg Oral Med Oral Pathol* 1991; **71:** 155–157.
26. Simuntis R, Kubilius R, Vaitkus S. Odontogenic maxillary sinusitis: a review. *Stomatologija* 2014; **16:** 39–43.
27. Abrahams J J, Glassberg R M. Dental disease: a frequently unrecognised cause of maxillary sinus abnormalities? *AJR Am J Roentgenol* 1996; **166:** 1219–1223.
28. Lim C G, Spanger M. Incidental maxillary sinus findings in patients referred for head and neck CT angiography. *Singapore Dent J* 2012; **33:** 1–4.
29. Patel N A, Ferguson B J. Odontogenic sinusitis: an ancient but under-appreciated cause of maxillary sinusitis. *Curr Opin Otolaryngol Head Neck Surg* 2012; **20:** 24–28.
30. Hansen A G, Helvik A S, Nordgård S *et al.* Incidental findings in MRI of the paranasal sinuses in adults: a population-based study (HUNT MRI). *BMC Ear Nose Throat Disord* 2014; **14:** 13.
31. Karikal A, Sharma S M, Gopinath A, Karikal A. Osteolytic nasal polyp of the maxillary sinus mimicking malignancy. *Contemp Clin Dent* 2014; **5:** 397–401.
32. Mandour Z M. Antrochoanal polyp in paediatric age group. *Egypt J ENT Allied Sci* 2017; **18:** 17–21.
33. Frosini P, Picarella G, De Campora E. Antrochoanal polyp: analysis of 200 cases. *Acta Otorhinolaryngol Ital* 2009; **29:** 21–26.
34. Donizeth-Rodrigues C, Fonseca-Da Silveira M, Gonçalves-De Alencar A H, GarciaSantosSilva M A, FranciscoDeMendonça E, Estrela C. Three-dimensional images contribute to the diagnosis of mucous retention cyst in maxillary sinus. *Med Oral Patol Oral Cir Bucal* 2013; DOI: 10.4317/medoral.18141.
35. Wang J H, Jang Y J, Lee B J. Natural Course of Retention Cysts of the Maxillary Sinus: Long-Term Follow-Up Results. *Laryngoscope* 2007; **117:** 341–344.
36. Lund V J, Clarke P M, Swift A C, McGarry G W, Kerawala C, Carnell D. Nose and paranasal sinus tumours: United Kingdom National Multidisciplinary Guidelines. *J Laryngol Otol* 2016; DOI: 10.1017/S0022215116000530.
37. Dooley L, Shah J. Management of the neck in maxillary sinus carcinomas. *Curr Opin Otolaryngol Head Neck Surg* 2015; **23:** 107–114.
38. Stelow E B, Bishop J A. Update from the 4th Edition of the World Health Organisation Classification of Head and Neck Tumours: Tumours of the Nasal Cavity, Paranasal Sinuses and Skull Base. *Head Neck Pathol* 2017; **11:** 3–15.
39. Dulguerov P, Jacobsen M S, Allal A S, Lehmann W, Calcaterra T. Nasal and paranasal sinus carcinoma: are we making progress? A series of 220 patients and a systematic review. *Cancer* 2001; **92:** 3012–3029.
40. Santos M R M, Servato J P S, Cardoso S V *et al.* Squamous cell carcinoma at maxillary sinus: clinicopathologic data in a single Brazilian institution with review of literature. *Int J Clin Exp Pathol* 2014; **7:** 8823–8832.
41. Mehanna P, Smith G. Maxillary carcinoma: A wolf in sheep's clothing. *Can Fam Physician* 2009; **55:** 262–264.
42. Wieneke J A, Koeller K K. Head Neck Pathol Radiology Pathology Classics. *Head Neck Pathol* 2007; **1:** 99–101.
43. Kawaguchi M, Kato H, Tomita H *et al.* Imaging Characteristics of Malignant Sinonasal Tumours. *J Clin Med* 2017; DOI: 10.3390/jcm6120116.

CPD questions

This article has four CPD questions attached to it which will earn you one hour of verifiable CPD. To access the **free** BDA CPD hub, go to https://cpd.bda.org/login/index.php.

https://doi.org/10.1038/s41407-020-0341-x