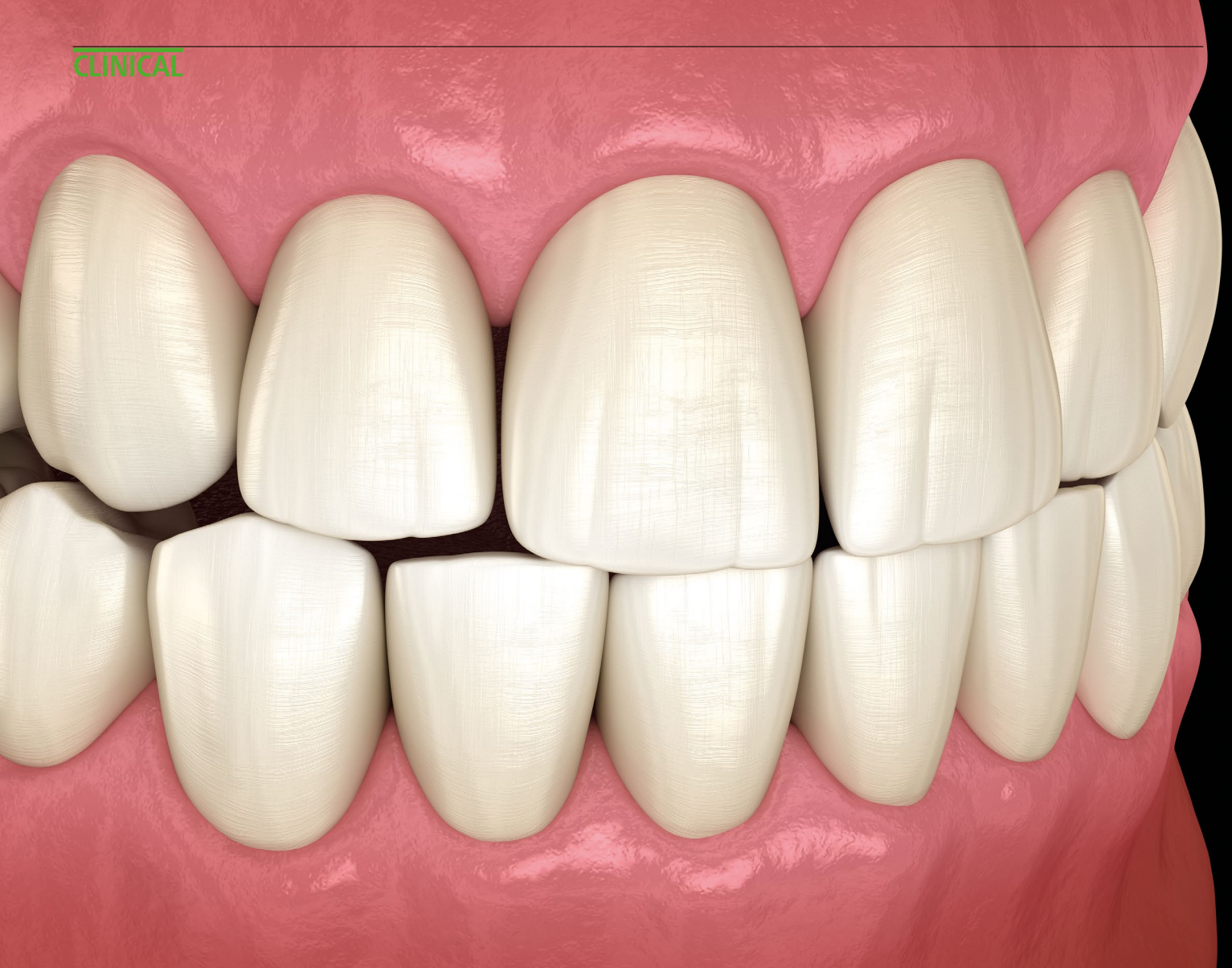



## By Tara Bharadia, DCT in Special Care and Restorative Dentistry

Occlusion can be tricky to get your head around. Here are some tips, terms and definitions<sup>1</sup> to help you get to grips with it.

### Definitions

**Occlusion** – contacts between teeth

**Terminal Hinge Axis** – imaginary line between the two TMJs, around which the mandible rotates (not describing translational movement)

**Centric Occlusion** – also called ICP or habitual bite, occlusion when patients fit their teeth together in maximum intercuspation

**Centric Relation** – a reproducible position, not a tooth relationship, but a jaw relationship, where the head of the condyle is in the most upper and foremost position, in its terminal hinge axis and the related muscles are in their most relaxed and least strained position

**Retruded Contact Position** – the first tooth contact when closing from Centric Relation

**Freedom in Centric Occlusion** – mandible can move slightly anterior in the same plane and maintain tooth contact – for example, bite your teeth together, can you move your jaw slightly forward while keeping all your teeth in contact still, this won't be present if a patient's front teeth hit harder or sooner than back teeth, in the case of Class 2 Division 2 or thick palatal surfaces on anterior crowns<sup>2</sup>

**Static Occlusion** – the contacts between teeth when the mandible is closed and still

**Dynamic Occlusion** – the contacts between teeth when the mandible is moving relative to the maxilla

### Determinants of occlusion

Occlusion is determined by a patient's articular system. Like traditional systems, it relies on motors, hinges and contacts – or

muscles, the TMJ and tooth-to-tooth contact.<sup>2</sup>

**1. Tooth contacts – the mandible movement is neuromuscular but controlled by the CNS in 2 guidance systems – these create the contacts:**

- Anterior guidance – the teeth
- Posterior guidance – the TMJs.

These create static and dynamic occlusion. Static occlusion can be described with the terms CR, CO, RCP and Freedom in CO. However dynamic occlusion is a little more complicated and can be described using these terms:<sup>1</sup>

- **Working Side** – the side which the mandible moves towards during lateral excursions (WS)
- **Non-working Side** – side of the mandible that moves towards the midline during lateral excursion (NWS)
- **Interferences** – tooth contact that hinders

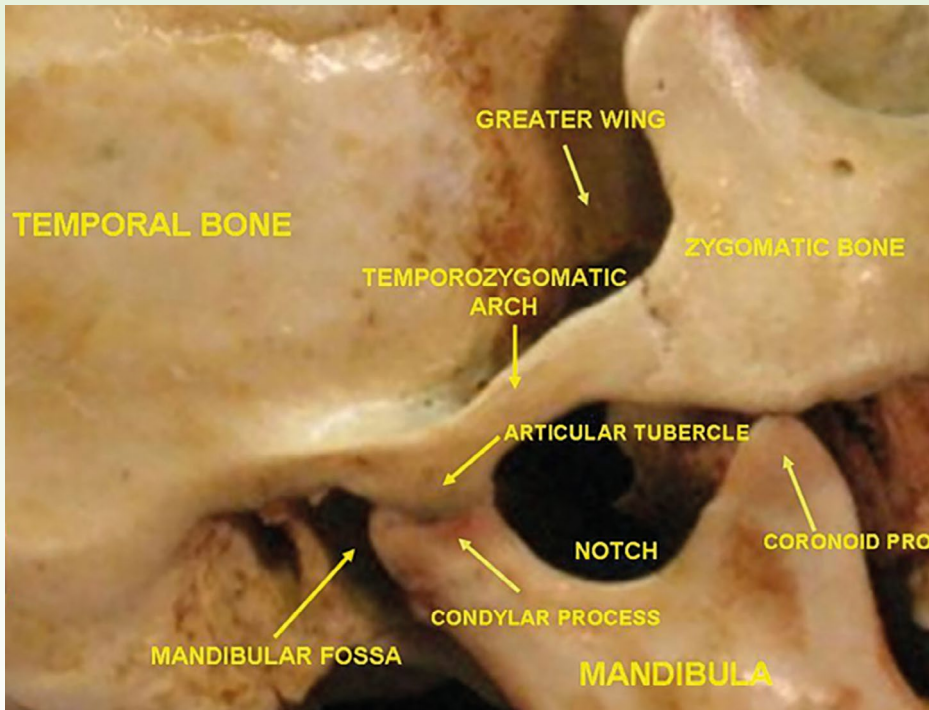


Fig. 1 A photo showing the hard anatomy of the TMJ and associated structures

mandibular movement, can be on the WS or NWS

- **Canine Guidance** – canine contact in lateral excursion (canine protective is when canines are the only teeth in contact during lateral excursions)
- **Group Function** – contacts between several teeth on the working side during lateral excursions.

## 2. TMJ – this is the hinge that allows contacts between the teeth, to happen

- The joint is located between the mandibular fossa and articular tubercle of the temporal bone superiorly and the head of the mandible inferiorly
- A modified hinge type of synovial joint (two bones with a fluid-filled capsule in-between)
- Allows free movement between the bones – rotates then translates
- Has an articular disc which normally stays above the condyle as the joint moves
- The disc is attached to the fibrous joint capsule
- The joint capsule is loose, fibrous and attached to the margins of the articular

cartilage on the temporal bone and around the neck of the mandible

- The disc is stabilised and reinforced by accessory ligaments both intrinsic (lateral which strengthens the joint and postglenoid which prevents posterior dislocation)<sup>3</sup> and extrinsic (stylomandibular and sphenomandibular, which connect the mandible to the cranium) as shown in Figure 1.

## 3. Muscles – the hinge (TMJ) is controlled by the motors or muscles including:

- **Masseter** – the main elevator of the mandible, assists with protrusion, most commonly affected muscle in parafunction
- **Temporalis** – the only retractor of the mandible, assists with elevation, can become tender in the bruxing patient
- **Lateral pterygoid** – superior head allows for clenching and stabilisation of the disc, the inferior head draws the condyle forward, medially and down the articular eminence during opening, parafunction in this muscle can manifest as pre-auricular pain, disc displacement and clicks or locks<sup>2</sup>

- **Medial pterygoid** – elevates, protrudes and assists with lateral movements, cannot palpate so unsure of its involvement in parafunction
- **Digastric** – assists the lateral pterygoid in depressing the mandible, lifts the hyoid bone during swallowing, there can be pain under the body of the mandible in patients who clench their front teeth
- **Mylohyoid** – raises the hyoid and tongue during swallowing
- **Suprahyoid, infrahyoid, cervical muscles** – these muscles are responsible for head posture, which can affect the position and health of other muscles<sup>2</sup>

## Ideal Occlusion

The definition of an ideal occlusion is important when discussing cases and prescribing stabilisation splints. The textbook definition of an ideal occlusion states that three things must be present:<sup>4</sup>

- CO occurs in CR
- There is freedom in Centric Occlusion
- Interior guidance is on the front teeth (when the mandible slides forward or laterally, only the anterior teeth are touching and posterior teeth are disoccluded such in the case of canine guidance or group function).

However, it is important to remember that while these may be the features of an ‘ideal occlusion’, this does not mean that any variation in these features mean that the patient has a bad occlusion.<sup>2</sup> If a patient can eat, speak and smile how they are, you don’t need to start editing how their teeth fit together, in order to achieve an ‘ideal occlusion’.

Like my mentor always says, occlusion is easy!

## References

1. Ferro K J, Morgano S M, Driscoll C F *et al.* The glossary of prosthodontic terms. *J Prosthet Dent* 2017; 117.
2. Davies S. A guide to good occlusal practice. Cham: Springer International Publishing AG; 2023.
3. Moore K L, R. A A M, Dalley A F. Clinically oriented anatomy. Wolters Kluwer Health; 2019.
4. Davies S, Gray R, Smith P. Good occlusal practice in simple restorative dentistry. *Br Dent J* 2001; 191: 365-381.

<https://doi.org/10.1038/s41406-023-0948-4>