ISCoS The International Spinal Cord Society

www.nature.com/scsandc

CASE REPORT

An infected Andersson lesion presented with incomplete paraplegia in a patient with ankylosing spondylitis. A unique case report with literature review

Ioannis Papaioannou[1✉], Georgia Pantazidou[2], Thomas Repantis[1], Andreas Baikousis[1] and Panagiotis Korovessis[1]

INTRODUCTION: A relatively rare and unknown entity in patients with ankylosing spondylitis is the Andersson lesion (AL). It was first described by Andersson in 1937 as destructive vertebral or disco-vertebral lesion of the spine without history of trauma. AL may result from inflammation or stress fracture of the rigid spine, while there is no evidence for an infectious origin. To our knowledge, only one case with an infected AL has been published many years ago; we hereby present the second case, but the first one with severe neurologic deterioration.

CASE PRESENTATION: A 79-year-old male patient was presented to our emergency department and his neurological examination on admission revealed incomplete paraplegia below the Th10 level. Plain radiograms at the level of 10th thoracic vertebra revealed a lesion mimicking a severe vertebral fracture. The computed tomography confirmed the diagnosis of the AL and due to the significant local instability and the neurologic deficit, the patient underwent posterior decompression and stabilization. During decompression, we noticed purulence and extensive debridement was performed. The cultures of the Th10 pus revealed Enterococus sp, while the same pathogen was developed to urine cultures. The patient received intravenous antibiotics for 4 weeks, followed by per os antibiotic therapy. At the 18-month follow-up our patient had significant improvement of this functional status.

DISCUSSION: Most studies support that inflammatory or traumatic/mechanical (pseudarthrosis) etiology are the most possible causes of Anderson lesions. Possible neurological deterioration should be investigated and demonstrates significant spinal instability. The integrity of the posterior column should be investigated, and exclusion of other concomitant lesions should be done. In cases with instability due to the fractured posterior elements, surgical intervention is mandatory. Spine surgeons should be competent to differentiate fracture from the Andersson lesion. In this rare case we highlight also that spine surgeons should obtain intraoperative cultures in cases with Andersson lesions, to exclude the minor possibility of the infectious origin of the entity and/or the possible secondary contamination of the affected area.

Spinal Cord Series and Cases (2022)8:73 ; https://doi.org/10.1038/s41394-022-00541-7

INTRODUCTION

In ankylosing spondylitis (AS) the spine becomes rigid, without segmental movement, and finally ends up with osteopenia and vulnerability to trauma. Decrease in bone mineral density associated with aging and degenerative changes in bone and ligaments contribute also to this vulnerability [1]. Thus, minimal severity trauma can cause serious injury, which can easily be overlooked or misdiagnosed. In 1988 Trent et al. described the so-called "shearing" fracture pattern in patients with AS. These injuries are highly unstable with failure of all three columns and can be either flexion or extension type injuries [2]. Flexion-type injury is comparable to the notorious chance fracture, while most of the unstable fractures in AS patients concern the extension-type fracture. Nowadays, we classify these fractures according to Arbeitsgemeinschaft für Osteosynthesefragen/ Orthopaedic Trauma Association (AO/OTA) classification system, as B-type injuries (B1–B3). If these injuries are not properly treated a neglected fracture of the rigid spine can easily occur, accompanied with evidence-based complications such as bed sores, persistent back pain, constipation, residual kyphotic deformity, urinary tract infection, depression, deep vein thrombosis, joint contractures, paralytic ileus, and respiratory tract infection [3]. Another relatively rare and unknown entity in AS patients is the Andersson lesion. Andersson lesion (AL) was first described by Andersson in 1937 as destructive vertebral or disco-vertebral lesions of the spine [4]. The pathophysiology of this lesion is still a controversy, although AL may result from inflammation or stress fracture of the rigid spine, while there is no evidence for an infectious origin [5]. On the other hand, infection cannot be excluded in advance, especially in cases with persistent back pain, excruciating and unrelieved with rest accompanied with remarkable indicators of inflammation such as leukocytosis, elevated ESR and CRP or imaging indicative for infection (abscess formation) [6]. Hereby we report a unique case of a 79-year-old male patient

[1]Orthopedic Department of General Hospital of Patras Spine and Trauma Unit, Patras, Greece. [2]Public Health, Postgraduate MSc Program, University of Patras, Patras, Greece. ✉email: john-pane1984@hotmail.com

Received: 29 December 2021 Revised: 28 July 2022 Accepted: 29 July 2022
Published online: 09 August 2022

diagnosed with a neglected AL with fractured posterior elements of the 10th thoracic vertebra accompanied with incomplete paraplegia and intraoperative findings of spinal infection by Enterococcus. Extensive and neglected AL can result in fracture of the posterior column and this entity can be easily misdiagnosed as a type B fracture as in our case. Although, we found only one case report in the literature with septic Andersson lesions [6], while the combination of lesions we report (AL with fractured posterior elements accompanied with paraplegia and infectious origin of the instability) has never been reported again. The presence of Andersson lesion doesn't exclude the co-existence of local spine instability, the presence of infection, and neurological deterioration, especially in neglected cases with immunocompromised patients. The possible infectious cause of the AL should be ruled out based on the intraoperative cultures.

CASE PRESENTATION

A 79-year-old male patient was presented to our emergency department due to inability to bear weight and even stand, without any trauma. The patient's medical history included prostate hyperplasia, obesity (BMI: 49.3) and arthritis of hip and knee joints. One week before admission he complained about severe pain in his right knee with inability to actively move his knee joint. The patient was counseled from a private orthopedic surgeon, and was treated for knee osteoarthritis with intra-articular injection of hyaluronic acid plus per os corticosteroids (methylprednisolone 16 mg once a day) and paracetamol, without any improvement of knee pain or movement. His neurological examination on admission revealed sensory deficit below 10th thoracic vertebra (Th10) level (both sides pin prick and light touch were 1/2) and absent motor function of both lower extremities. Anal sphincter was spoiled, while urinary retention was confirmed via bladder ultrasound. The laboratory blood tests on admission were the following: white blood cells (WBCs): 11.500 K/μl and 82.9% of them were neutrophils, hematocrit (Hct): 37.5% with hemoglobin 13.2 g/dL, erythrocyte sedimentation rate (ESR): 75 mm/1sth, C-reactive protein (CRP): 15.5 mg/dl, glucose (GLU): 223 mg/dl, potassium: 5.6 mg/dl, sodium 142 mg/dl, urea 79 mg/dl, creatinine 0.9 mg/dl, albumin 1.6 gr/dl, while liver function blood tests were all within normal limits. Due to the increased glucose levels, we performed hemoglobin A1c (HbA1c) blood test to evaluate our patient's glycemic status. The HbA1c was excessive high (8.3%) and according to the World Health Organization (WHO) recommendations the diagnosis of diabetes mellitus type 2 was settled. The profile radiograph of the thoracic spine showed fusion of the thoracic and a part of the lumbar spine with the classical vertical syndesmophytes and the appearance of bamboo spine. At the level of 10th thoracic vertebra, we also noticed a lesion mimicking a type B vertebral fracture according to AO/OTA classification (Fig. 1). Based on this finding, the pathologists refer the patient to our clinic. A computed tomography of the spine was performed to further evaluate this lesion. We recognized chronic structural changes such as joint erosions and subchondral sclerosis of the Th10 vertebra and severe stenosis of the spinal canal at the same level due to the posterior tension band disruption (Figs. 2 and 3). Unfortunately, spine magnetic resonance imaging (MRI) was not performed due to the limitations of our machine due to the excessive obesity of our patient. Based on the findings of imaging (c/t, radiograms), medical history, and clinical examination, we performed HLA-B27 blood test to confirm the diagnosis of ankylosing spondylitis. According to the New York and Rome Criteria for Diagnosis of ankylosing spondylitis (AS) our patient scored 9 out of 16 and the diagnosis of ankylosing spondylitis was settled. In addition, we settled the diagnosis of this lesion as an extensive neglected AL lesion with fractured posterior elements and confirmed the misdiagnosis of the B-type fracture. At this point the patient was suffered from mechanical instability of the thoracic spine accompanied with neurologic deterioration, so we combined decompression, stabilization, and sampling for cultures and biopsy. The patient underwent posterior decompression of Th10 vertebrae and stabilization via pedicle screws from Th7 to L1. During the decompression we noticed purulence (Fig. 4) and extensive debridement was performed (Fig. 5). Body temperature was within normal limits, while the blood cultures and Mantoux reaction were negative. The cultures of the Th10 pus revealed Enterococus sp, while the same pathogen was developed to urine cultures. The biopsy was indicative for infection with acute inflammatory cells infiltration, soft tissue edema, vascular congestion, and small-vessel thrombosis. The patient received intravenous antibiotics (ampicillin plus vancomycin) for 4 weeks,

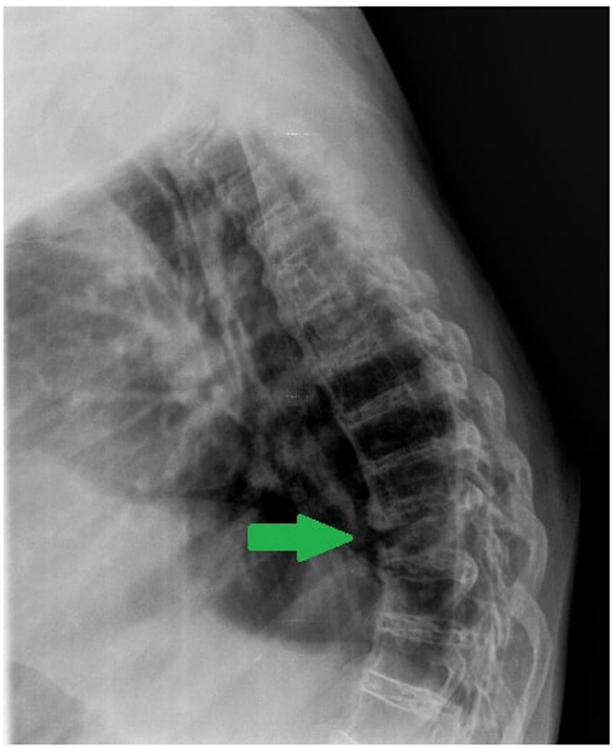

Fig. 1 Profile radiogram of the thoracic spine. The green arrow indicates the lesion mimicking a B-type fracture.

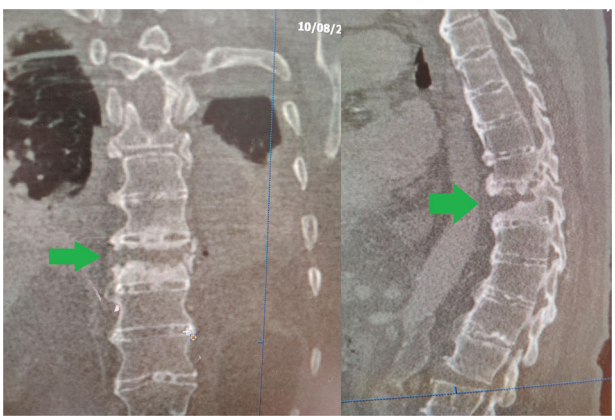

Fig. 2 Coronal (left side) and sagittal (right side) computed tomography image of the thoracic spine. The green arrows indicate the lesion on coronal and sagittal plane. The chronic structural changes of the lesion are obvious on the computed tomography images.

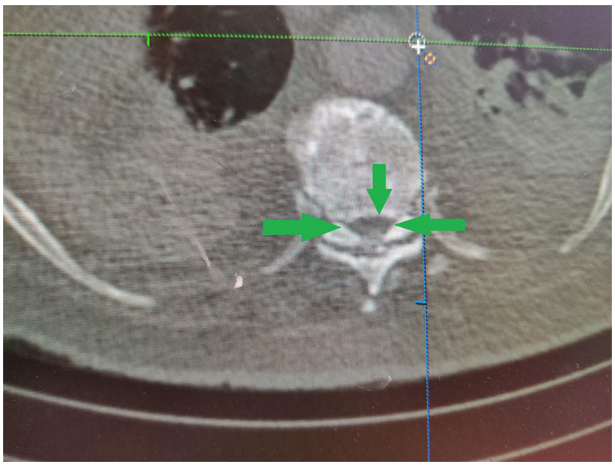

Fig. 3 Axial computed tomography image of the lesion. The three green arrows show the spinal stenosis of the level of the 10th thoracic vertebra.

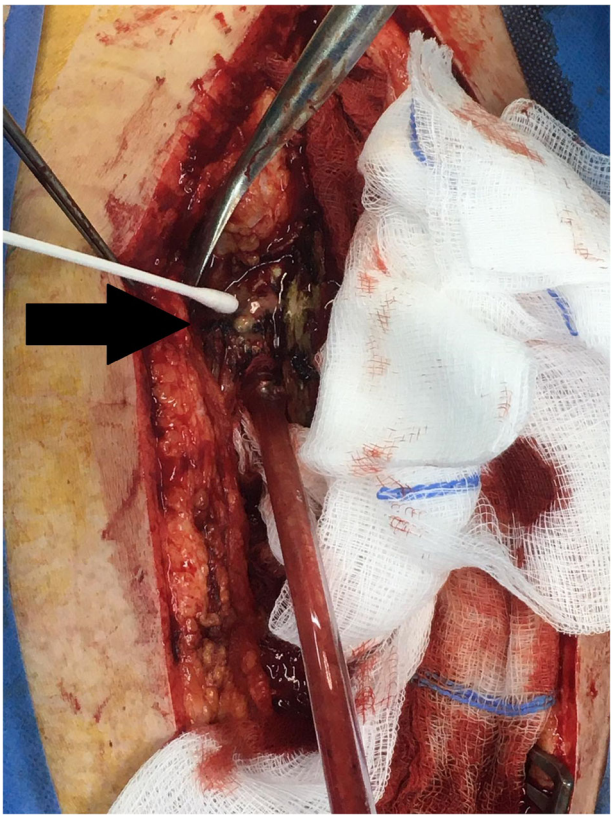

Fig. 4 Intraoperative image during the decompression. The black arrow indicates the purulence of the affected vertebra and the sample collection.

until CRP and ESR return to normal values (taken into consideration that ankylosing spondylitis is characterized by CRP and ESR elevation), followed by per os antibiotic therapy (linezolid plus nitrofurantoin) for three months based on the instructions of the infectious disease's specialist and the consensus of the patient. Assessment of procalcitonin levels would be more appropriate and sensitive for this patient to assess infection, but unfortunately this marker can't be estimated in our hospital's lab, so we followed the CRP and ESR levels for twelve months. Radiographic evaluation of the posterior instrumentation and the sagittal

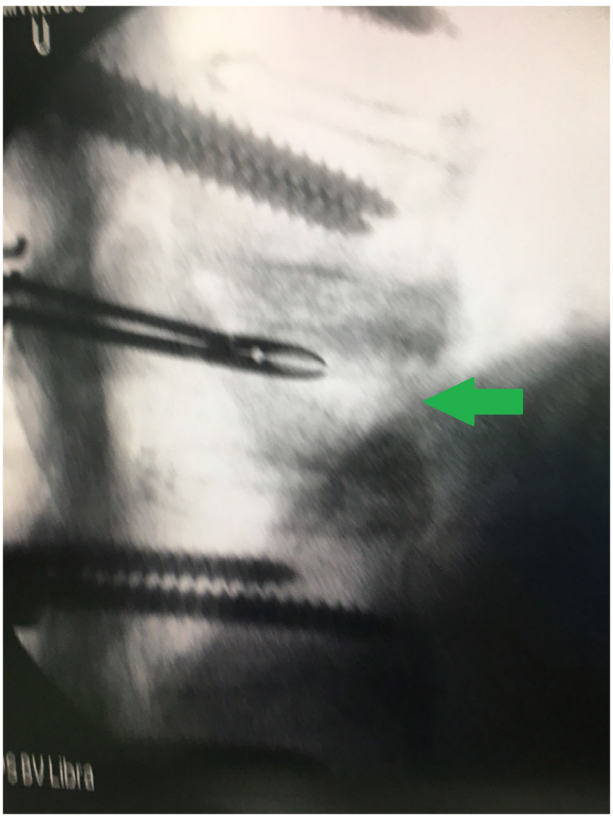

Fig. 5 Profile intraoperative photo from the image intensifier. The green arrow demonstrates the technique for the intrabody debridement through the pedicles via a pituitary forceps.

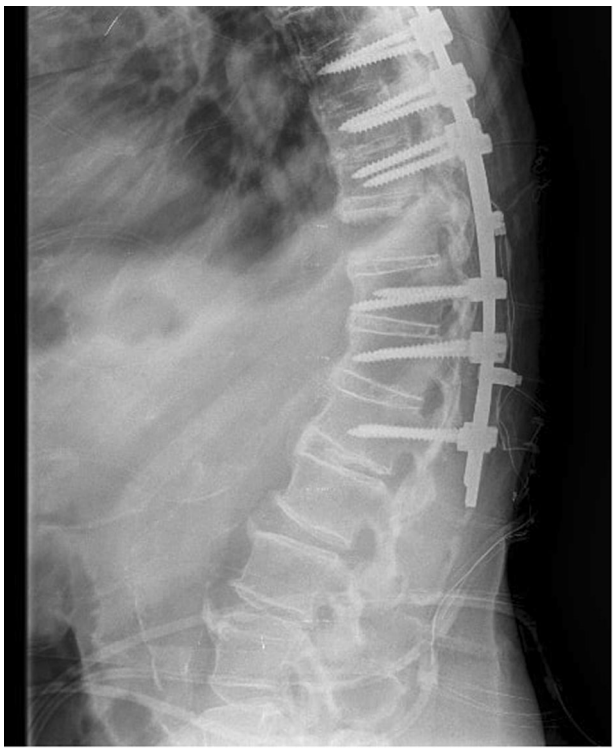

Fig. 6 Postoperative profile radiogram of the thoracolumbar junction. This image demonstrates the posterior stabilization via pedicle screws and rods from Th7 to L1 and bypass of the affected Th10 vertebra.

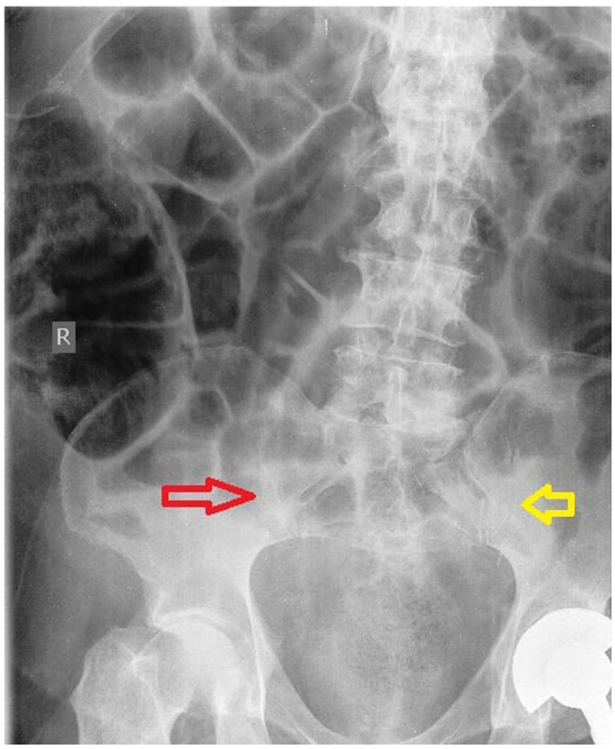

Fig. 7 Anteroposterior radiogram of the sacroiliac joints. This image demonstrates end stage sacroiliitis on the right side as the joint is nearly visible (red arrow), while the contralateral side is characterized by subchondral erosions, sclerosis, and proliferation on the iliac side (yellow arrow).

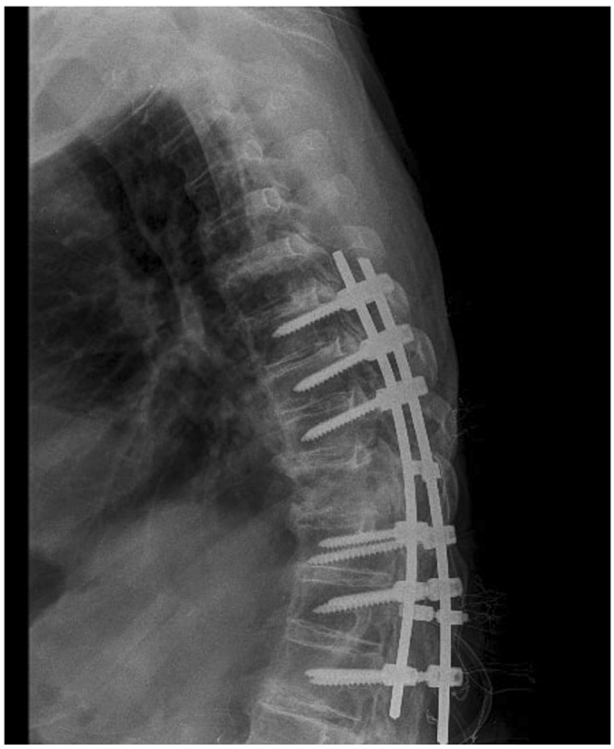

Fig. 8 Profile radiogram of the spine at the 18 months follow-up. This image shows adequate fusion and remodeling of the affected Th10 vertebra.

alignment were satisfactory (Fig. 6). Neurologic evaluation just before transferring him to the rehabilitation center, revealed improvement of the motor function (bilateral 3/5 MRC L5, S1). As the diagnosis of AS was settled by us, we refer the patient to our rheumatologists for further evaluation. The Bath Ankylosing Spondylitis Disease Activity Index (BASDAI) was defined to 6.1, while the Bath Ankylosing Spondylitis Functional Index (BASFI) before the neurologic deterioration of the patient was 6.7. The anteroposterior radiogram of the sacroiliac joints (Fig. 7) revealed end-stage sacroiliitis on the right side as the joint is nearly visible (red arrow), while the contralateral side is characterized by subchondral erosions, sclerosis, and proliferation on the iliac side (yellow arrow). In this patient there are radiographic findings from both spine and sacroiliac joints, so the diagnosis of radiographic axial spondylarthritis was established. Sacroiliac joint magnetic resonance imaging couldn't be performed due to the excessive weight of the patient. In addition, the patient has also peripheral joint arthropathy as he underwent total hip replacement on the left side 5 years ago, while he recently suffered from knee pain. Although, for all these years he was undiagnosed, and he was wrongfully treated for hip and knee osteoarthritis with inappropriate algorithm (oral corticosteroids), without ever receiving a rheumatologic consultation.

At the eighteen-months follow-up and just three months after the discharge from the rehabilitation unit, our patient had significant improvement of this functional status. He could stand and walk some steps with two walking sticks, he had minor sensory deficits, he performed intermittent catheterization for his bladder, he mentioned some annoying numbness in his feet and most of the muscles of the lower extremities had according to Medical Research Council (MRC) Scale 3–4 out of 5 grading. The radiographic evaluation showed adequate fusion (Fig. 8) without signs of infection (normal CRP, ESR).

DISCUSSION

Andersson's lesion is a rare complication of ankylosing spondylitis (AS). The exact prevalence of this entity is currently unknown and ranges from 1.5% to over 28% [5]. This remarkable variation reflects the difficulty in diagnosis of this lesion due to the lack of diagnostic criteria, non-specific clinical manifestations, possible pre-existing spinal changes, the unawareness of this entity for most of the clinicians and spine surgeons and the lack of proper follow-up of patients with AS. It is important to stress out that history of trauma should always be ruled out [5].

The etiology of the AL is still unknown, and controversy exists concerning the main cause of this entity. Inflammation and the repetitive mechanical forces to the non-ossified segments are the two more popular causes. An infectious origin has also been suggested, although this has never gained much popularity in the literature [7]. The literature review revealed only one case published many years ago [6], which supports the infectious origin of AL, while most of the studies support that inflammatory [8] or traumatic/mechanical (pseudarthrosis) etiology are the most possible causes of AL [5, 7].

Bron et al. have categorized AL lesions into three groups according to the etiology: (1) minor lesions with inflammatory origin, (2) extensive lesions with combination of mechanical and inflammatory origin accompanied with intact posterior elements and (3) more extensive lesions with always fractured posterior elements resulting from mechanical trans-discal or trans-vertebral stresses with significant instability [5].

In our patient there was no history of trauma, while intraoperative cultures revealed Enterococcus sp. The same pathogen was found to the urine cultures, even though blood cultures at the time of admission to our clinic were negative. Since enterococcus was developed to urine cultures reactive arthritis or Reiter's syndrome should be included to the differential diagnosis of the initial manifestation of the patient, the knee pain. Although,

on admission our patient had no eye or genital tract symptoms, and the right knee joint had no tenderness or swelling and probably the pain was due to the gradual neurological deterioration of the patient due to the instability of the thoracic spine.

We cannot be sure if infection was the cause of the AL, or the pathogen was spread from the urinary tract to the spine through the Batson plexus [9] in this neglected lesion. We believe that obesity, the undiagnosed diabetes mellitus, and the cortisone administration contributed to the development of this spinal infection.

The differential diagnosis of the Anderson lesion includes mainly the bacterial discitis, metastasis, and fracture of the spine [7]. The diagnostic algorithm includes radiograms and computed tomography (CT) to evaluate the bony structures and specially to identify the fracture of the posterior elements, while magnetic resonance images (MRI) are mandatory to assess the spinal cord and possible formation of abscess or adhesions of the dura. Multilevel spondylodiscitis should also be excluded, while AL is not restricted to AS, but also in patients with rheumatoid arthritis, psoriatic arthritis, and SAPHO-syndrome (synovitis, acne, pustulosis, hyperostosis, osteitis) [7, 8]. Although CT and MRI can aid to the diagnosis, imaging can be often misdiagnosed as infection (bacterial or tuberculosis) or metastasis [10] and in these cases high level of suspicion is needed.

Conservative treatment with brace, rest and physiotherapy can only be effective in asymptomatic localized lesions without fractured posterior elements in neurologically intact patients [11]. Additionally, spinal segments with increased mobility such as cervical and thoracolumbar junction require more aggressive treatment and consist of a significant indication for surgical intervention [5]. Certain indications for surgical treatment of these lesions are the unbearable pain with progression of the symptoms, the progressive kyphotic deformity, and the presence of neurological deficits [5], as in our case.

In our country the prevalence of ankylosing spondylitis remains low [12] probably due to the lack of awareness of the patients, who rarely seek medical consultation for mild clinical manifestations, which characterize the disease in our country [13]. This results in the chronicity of the disease and in increased complications such as Andersson lesion. In many cases the diagnosis of AS is settled after trauma to the spine or persistent back pain.

The basic limitation of our study is our inability to define if infection was the cause of the AL, or the pathogen was spread from the urinary tract to the spine through the Batson plexus in this neglected lesion. On the other hand, the strength of our case consists of our suggestion that Andersson lesions should be evaluated for possible infectious origin of the entity either by percutaneous sampling or during surgical stabilization of the lesion. Although, more studies with larger number of patients are mandatory to confirm or reject our proposal. The infectious origin of the Anderson lesion remains controversial and further investigation of this essential issue is paramount of importance with significant clinical impact.

Spine surgeons should be able to recognize AS and the Andersson lesion and properly consult patients to receive rheumatologic consultation. They also should be competent to differentiate the B-type fracture from the Andersson lesion. After recognition of the Andersson lesion, the integrity of the posterior column should be investigated, and exclusion of other concomitant lesions should be done. In cases with neurologic impairment the posterior column is always fractured, and stabilization is mandatory. We suggest spine surgeons to obtain intraoperative cultures in cases with Andersson lesions, to exclude the minor possibility of the infectious origin of the entity and/or the possible secondary contamination of the affected area.

DATA AVAILABILITY

All data supporting the findings of this study are available within the article.

REFERENCES

1. Lee CK, Yoon DH, Kim KN, Yi S, Shin DA, Kim B, et al. Characteristics of cervical spine trauma in patients with ankylosing spondylitis and ossification of the posterior longitudinal ligament. World Neurosurg. 2016;96:202–8.
2. Trent G, Armstrong GW, O'Neil J. Thoracolumbar fractures in ankylosing spondylitis: high-risk injuries. Clin Orthop Relat Res. 1988;227:61–6.
3. Khatri K, Farooque K, Sharma V, Gupta B, Gamanagatti S. Neglected thoraco lumbar traumatic spine injuries. Asian Spine J. 2016;10:678.
4. Andersson O. Röntgenbilden vid spondylarthritis ankylopoetica. Nord Med Tidskr. 1937;14:2000–2.
5. Bron JL, de Vries MK, Snieders MN, van der Horst-Bruinsma IE, van Royen BJ. Discovertebral (Andersson) lesions of the spine in ankylosing spondylitis revisited. Clin Rheumatol. 2009;28:883–92.
6. Lohr KM, Barthelemy CR, Schwab JP, Haasler GB. Septic spondylodiscitis in ankylosing spondylitis. J Rheumatol. 1987;14:616–20.
7. Dave BR, Ram H, Krishnan A. Andersson lesion: are we misdiagnosing it? A retrospective study of clinico-radiological features and outcome of short segment fixation. Eur Spine J. 2011;20:1503–9.
8. Nikolaisen C, Nossent H. Early histology in ankylosing spondylitis related spondylodiscitis supports its inflammatory origin. Scand J Rheumatol. 2005;34:396–8.
9. Leigh TF, Kelly RP, Weens HS. Spinal osteomyelitis associated with urinary tract infections. Radiology. 1955;65:334–42.
10. Shaik I, Bhojraj SY, Prasad G, Nagad PB, Patel PM, Kashikar AD, et al. Management of Andersson lesion in ankylosing spondylitis using the posterior-only approach: a case series of 18 patients. Asian Spine J. 2018;12:1017–27.
11. Rasker JJ, Prevo RL, Lanting PJH. Spondylodiscitis in ankylosing spondylitis, inflammation or trauma? Scand J Rheumatol. 1996;25:52–7.
12. Alamanos Y, Papadopoulos NG, Voulgari PV, Karakatsanis A, Siozos C, Drosos AA. Epidemiology of ankylosing spondylitis in Northwest Greece, 1983-2002. Rheumatology. 2004;43:615–8.
13. Kassimos DG, Vassilakos J, Magiorkinis G, Garyfallos A. Prevalence and clinical manifestations of ankylosing spondylitis in young Greek males. Clin Rheumatol. 2014;33:1303–6.

COMPETING INTERESTS

The authors declare that there is no potential conflict of interest relevant to this article and they also obtain a written consent from the patient.

ADDITIONAL INFORMATION

Supplementary information The online version contains supplementary material available at https://doi.org/10.1038/s41394-022-00541-7.

Correspondence and requests for materials should be addressed to Ioannis Papaioannou.