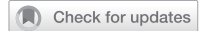

## ARTICLE



# Alterations in key signaling pathways in sinonasal tract melanoma. A molecular genetics and immunohistochemical study of 90 cases and comprehensive review of the literature

Małgorzata Chłopek<sup>1,2,16</sup>, Jerzy Lasota<sup>1,16</sup>✉, Lester D. R. Thompson<sup>3</sup>, Magdalena Szczepaniak<sup>2</sup>, Alina Kuźniacka<sup>4</sup>, Kinga Hińcza<sup>2</sup>, Kamila Kubicka<sup>2</sup>, Maciej Kaczorowski<sup>1,5</sup>, Michael Newford<sup>1</sup>, Yalan Liu<sup>1</sup>, Abbas Agaimy<sup>6</sup>, Wojciech Biernat<sup>7</sup>, Monika Durzyńska<sup>8</sup>, Ireneusz Dziuba<sup>9</sup>, Arndt Hartmann<sup>6</sup>, Shingo Inaguma<sup>10</sup>, Ewa Izycka-Świeszewska<sup>11</sup>, Hiroyuki Kato<sup>10</sup>, Janusz Kopczyński<sup>12</sup>, Michal Michal<sup>13</sup>, Michael Michal<sup>13</sup>, Rafał Pęksa<sup>7</sup>, Monika Prochorec-Sobieszek<sup>8</sup>, Anna Starzyńska<sup>14</sup>, Satoru Takahashi<sup>10</sup>, Bartosz Wasąg<sup>4</sup>, Artur Kowalik<sup>2,15</sup> and Markku Miettinen<sup>1</sup>

This is a U.S. Government work and not under copyright protection in the US; foreign copyright protection may apply 2022

Sinonasal mucosal melanoma is a rare tumor arising within the nasal cavity, paranasal sinuses, or nasopharynx (sinonasal tract). This study evaluated 90 cases diagnosed in 29 males and 61 females with median age 68 years. Most tumors involved the nasal cavity and had an epithelioid morphology. Spectrum of research techniques used in this analysis includes targeted-DNA and -RNA next-generation sequencing, Sanger sequencing, fluorescence in situ hybridization and immunohistochemistry. Sinonasal melanomas were commonly driven by *RAS* (38/90, 42%), especially *NRAS* ( $n = 36$ ) mutations and rarely (4/90, 4%) displayed *BRAF* pathogenic variants. *BRAF/RAS* mutants were more frequent among paranasal sinuses (10/14, 71%) than nasal (26/64, 41%) tumors. *BRAF/RAS*-wild type tumors occasionally harbored alterations of the key components and regulators of Ras-MAPK signaling pathway: *NF1* mutations (1/17, 6%) or *NF1* locus deletions (1/25, 4%), *SPRED1* (3/25, 12%), *PIK3CA* (3/50, 6%), *PTEN* (4/50, 8%) and *mTOR* (1/50, 2%) mutations. These mutations often occurred in a mutually exclusive manner. In several tumors some of which were *NRAS* mutants, *TP53* was deleted (6/48, 13%) and/or mutated (5/90, 6%). Variable nuclear accumulation of TP53, mirrored by elevated nuclear MDM2 expression was seen in >50% of cases. Furthermore, sinonasal melanomas ( $n = 7$ ) including *RAS/BRAF*-wild type tumors ( $n = 5$ ) harbored alterations of the key components and regulators of canonical WNT-pathway: *APC* (4/90, 4%), *CTNBN1* (3/90, 3%) and *AMER1* (1/90, 1%). Both, *TERT* promoter mutations (5/53, 9%) and fusions (2/40, 5%) were identified. The latter occurred in *BRAF/RAS*-wild type tumors. No oncogenic fusion gene transcripts previously reported in cutaneous melanomas were detected. Eight tumors including 7 *BRAF/RAS*-wild type cases expressed *ADCK4::NUMBL* cis-fusion transcripts. In summary, this study documented mutational activation of *NRAS* and other key components and regulators of Ras-MAPK signaling pathway such as *SPRED1* in a majority of sinonasal melanomas.

*Modern Pathology* (2022) 35:1609–1617; <https://doi.org/10.1038/s41379-022-01122-7>

## INTRODUCTION

Sinonasal tract mucosal melanoma (SNTMM), first reported in 1869, consist of tumors developing in the nasal cavity, paranasal sinuses, and nasopharynx<sup>1,2</sup>. SNTMM is an aggressive tumor mostly diagnosed in sixth and seventh decades of life. In the United States, it accounts for <1% of all melanomas, with a steady increased incidence in white females<sup>3</sup>.

Histologically, SNTMM has an epithelioid, spindle cell, or round cell/undifferentiated morphology. A lack of melanin pigmentation is

common. Therefore, immunohistochemical demonstration of melanocytic markers is essential for the diagnosis. However, the immunohistochemical profile of SNTMMs and cutaneous tumors is similar and cannot distinguish primary lesion from metastatic ones<sup>2</sup>.

SNTMM is often diagnosed at an advanced stage, with surgery as the first-line treatment, but only 25–30% of patients survive more than five-years. As a result, adjuvant therapy, including postoperative radiation, chemotherapy and targeted therapy are often considered<sup>4</sup>. As more options become available for the

<sup>1</sup>Laboratory of Pathology, National Cancer Institute, Bethesda, MD, USA. <sup>2</sup>Molecular Diagnostics, Holycross Cancer Center, Kielce, Poland. <sup>3</sup>Head and Neck Pathology Consultations, Woodland Hills, CA, USA. <sup>4</sup>Department of Biology and Genetics, Medical University of Gdańsk, Gdańsk, Poland. <sup>5</sup>Department of Clinical and Experimental Pathology, Wrocław Medical University, Wrocław, Poland. <sup>6</sup>Institute of Pathology, University Hospital of Erlangen, Erlangen, Germany. <sup>7</sup>Department of Pathomorphology, Medical University of Gdańsk, Gdańsk, Poland. <sup>8</sup>Department of Pathology, The Maria Skłodowska-Curie National Research Institute of Oncology, Warsaw, Poland. <sup>9</sup>Faculty of Medicine, University of Technology, Katowice, Poland. <sup>10</sup>Department of Experimental Pathology and Tumor Biology, Nagoya City University Graduate School of Medical Sciences, Mizuho-cho, Mizuho-ku, Nagoya, Japan. <sup>11</sup>Department of Pathology and Neuropathology, Medical University of Gdańsk, Gdańsk, Poland. <sup>12</sup>Department of Surgical Pathology, Holycross Cancer Center, Kielce, Poland. <sup>13</sup>Sikl's Department of Pathology, University Hospital, Charles University in Prague, Medical Faculty in Plzeň, Plzeň, Czech Republic. <sup>14</sup>Department of Oral Surgery, Medical University of Gdańsk, Gdańsk, Poland. <sup>15</sup>Division of Medical Biology, Institute of Biology Jan Kochanowski University, Kielce, Poland. <sup>16</sup>These authors contributed equally: Małgorzata Chłopek, Jerzy Lasota. ✉email: jurek.p.lasota@gmail.com

Received: 15 May 2021 Revised: 1 June 2022 Accepted: 1 June 2022  
Published online: 17 August 2022

latter, the need to identify genetic markers has become increasingly important.

The mutation profile of SNTMM remains incompletely characterized. Most Sanger sequencing studies have been limited to *BRAF*, *KIT*, and *NRAS* mutation status<sup>5–11</sup>. Recent investigations utilizing targeted-, whole exome-, and whole genome-next generation sequencing (NGS) provided more comprehensive mutation profiles but with only a limited number of cases analyzed<sup>12–17</sup>.

The aim of this study was to elucidate the molecular characteristics of SNTMM. A large series of well-characterized tumors was evaluated using targeted NGS, Sanger sequencing, fluorescence in-situ hybridization (FISH), and immunohistochemistry (IHC), identifying genetic alterations affecting dominant oncogenes and tumor suppressor genes and their respective pathways in SNTMM.

## MATERIAL AND METHODS

Following review of clinical data, evaluation of histopathology and immunohistochemistry, and assessment of the quality of nucleic acids, 90 cases (80 primary tumors and 10 local recurrences) were included in the study. A process of tumor selection is described in detail in Supplementary Data.

### Immunohistochemical studies

Immunohistochemistry (IHC) was performed using either BenchMark Ultra (Ventana Medical Systems-Roche Group, Tucson, AZ) or Leica Bond-Max automated immunostainer (Leica, Bannockburn, IL). A threshold of  $\leq 10\%$  was used for focal positivity, while  $>10\%$  but  $\leq 80\%$  and  $>80\%$  for mosaic and diffuse positivity, respectively. The panel included antibodies against human melanoma markers, PReferentially expressed Antigen in MELanoma (PRAME), keratin proteins, histone H3 trimethylated at lysine 27 (H3K27me3), transcription factor E3 (TFE3), synaptophysin (SYP), DNA-mismatch repair (MMR) proteins,  $\beta$ -catenin (CTNNB1), C-myc (CMYC), KIT (CD117), mouse double minute 2 (MDM2), tumor protein 53 (TP53), neurotrophic tyrosine receptor kinase (NTRK) and ROS proto-oncogene 1 (ROS-1). Detailed description of antibodies and protocols is provided in Supplemental Material and Methods and Supplementary Table 1.

### Genetic studies

Nucleic acids were extracted from formalin fixed paraffin embedded (FFPE) tumor tissues using Maxwell<sup>®</sup> RSC system (Promega, Madison, WI). Targeted-DNA NGS was done employing Ion Torrent<sup>™</sup> (Life Technologies/Thermo Fisher Scientific, Waltham, MA) platform and either cancer hotspot (CH) or comprehensive cancer (CC) gene panels. Sprouty Related EVH1 Domain Containing 1 (*SPRED1*) was evaluated using custom made Ion AmpliSeq<sup>™</sup> libraries. Targeted-RNA NGS for the detection of fusion gene transcripts were done using Archer<sup>®</sup> FusionPlex Solid Tumor panel (ArcherDx, Boulder, CO) and MiSeqDx sequencing instrument (Illumina, San Diego, CA). Genes targeted by NGS are listed in Supplementary Table 2. Telomerase reverse transcriptase gene promoter (*TERTp*) region frequently harboring mutations (228 C > T and 250 C > T) was screened by conventional PCR amplification and Sanger sequencing. Integrity of *NF1* and *TP53* loci were evaluated by interphase FISH using *TP53/NF1* deletion probe (MetaSystems Probes GmbH, Altlußheim, Germany). Detailed NGS, Sanger sequencing, and FISH protocols are available in Supplemental Material and Methods.

## RESULTS

### Demographic and clinicopathologic data

SNTMMs analyzed in this study were diagnosed in Europe ( $n = 67$ ), USA ( $n = 18$ ) and Japan ( $n = 5$ ). There were 29 males and 61 females (ratio 1:2.1). The median age at the diagnosis was 68 years (67 years for females and 70 years for males). Nine of 73 tumors localized within the nasal cavity also expanded into the maxillary ( $n = 6$ ) or ethmoid sinus. Three melanomas involved the nasopharynx. In 13 cases, tumors affected a single paranasal sinus: maxillary ( $n = 9$ ), ethmoid ( $n = 3$ ), and frontal sinus; one tumor affected both maxillary and ethmoid sinuses. None of the

patients had a history of primary melanoma elsewhere in the body. Demographic and clinicopathologic data for each patient are listed in Supplementary Table 3.

### Histological features and immunohistochemical profile

Exclusively epithelioid morphology ( $n = 57$ ) or predominantly epithelioid morphology with focal spindle ( $n = 12$ ) or round cell ( $n = 9$ ) pattern was seen in 87% of SNTMMs. One tumor had all three patterns. Remaining 11 cases displayed spindle cell or mostly spindle cell features. Nuclear pleomorphism was present in 59% (53/90) and necrosis in 48% (43/90) of cases. Mitoses (evaluated in 87 cases with sufficient tumor volume) varied from 2 to 132 (median 20) per 2 mm<sup>2</sup>. Melanin pigmentation was seen in 58% (52/90) of tumors, focally in 10 cases. Histopathologic features analyzed for each case are listed in Supplementary Table 3. Representative histopathological images are shown in Fig. 1A–C.

Expression of antigens was assessed using IHC. All SNTMMs were positive for at least one melanocytic marker (HMB-45, MELAN A, S100 protein, SOX10, Tyrosinase). A representative immunohistochemical image is shown in Fig. 1D. Synaptophysin was detected in 26% (20/78) of SNTMMs with 12 showing immunoreactivity in more than 10% of cells. Three cases (4%) revealed focal keratin expression. At least partial nuclear retention of H3K27me3 was seen in all analyzed ( $n = 82$ ) cases, with a significant fraction (33/82, 40%) demonstrating mosaic staining. Almost all (78/79, 99%) SNTMMs showed PRAME-immunopositivity with diffuse expression pattern seen in 89% (69/79) of cases. None of analyzed ( $n = 79$ ) tumors expressed TFE3. Detailed results of immunohistochemical studies are listed in Supplementary Table 4.

### Overview of targeted-DNA NGS

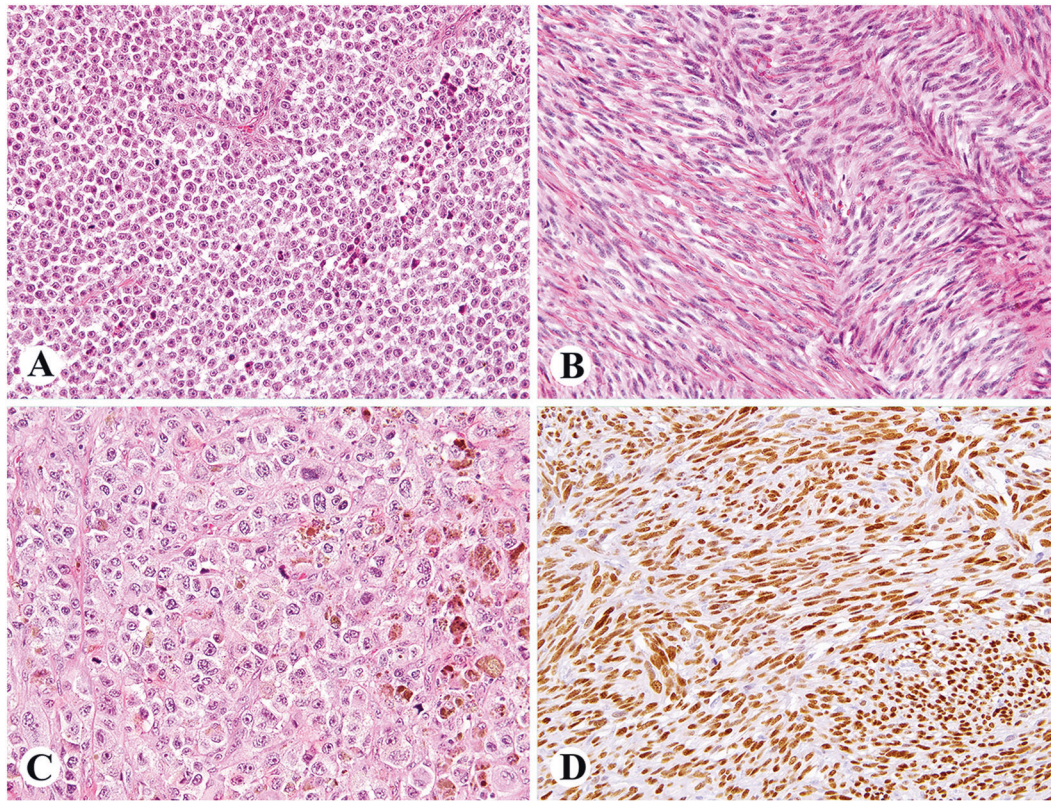
Molecular status of 50 oncogenes and tumor suppressor genes was assessed in all SNTMMs. Additional sequencing data of 359 genes were available for 21 cases. *SPRED1* was sequenced separately in 50 SNTMMs including 25 *BRAF/RAS*-WT tumors. Of 156 detected sequence variations, 124 represented unique molecular events including single nucleotide substitutions ( $n = 102$ ), deletions or deletion-insertions ( $n = 17$ ), two duplications ( $n = 2$ ), and insertions ( $n = 3$ ). Some of these alterations triggered frameshift ( $n = 9$ ) or STOP-codon ( $n = 12$ ) mutations.

Almost half ( $n = 60$ ) of sequence variations were previously identified to occur in somatic manner in cancer. Of remaining alterations 30% (19/64) had a variant allelic frequency (VAF) 40–60% that might indicate germline nature<sup>18</sup>. Nevertheless, normal tissue matching tumor samples were not available and a direct assessment of somatic versus germline status was not possible.

Most important molecular findings including gene mutations/sequence variations detected by NGS are summarized in Fig. 2. Supplemental Database shows all mutations/sequence variations (sheet A) and their pathogenic effects (sheet B) calculated/predicted by FATHMM, PolyPhen, SIFT and Human Genomic Variant Search Engine (<https://varsome.com>).

***BRAF*, *RAS*, *NF1* and *SPRED1*.** *BRAF* variants were found in 4% (4/90) of SNTMMs. They included class 2 (p.K601N, p.G469A) and class 3 (p.S467L) mutations, and p.V471I substitution of unknown significance. The last two coincided with *NRAS* p.G12A driver mutations and showed low ( $\leq 10\%$ ) allele frequency. No p.V600E class 1 mutation (typical of cutaneous melanoma) was detected. However, transcripts of *BRAF* isoform containing exon 10 to 18 duplication were identified in the tumor harboring *GNA11* p.Q209L mutation.

*RAS* driver mutations were identified in 42% (38/90) of SNTMMs. *NRAS* ( $n = 36$ ) mutations involved codon 61 ( $n = 16$ ), 12 ( $n = 14$ ) and 13 ( $n = 6$ ) with p.Q61K substitution being the most common ( $n = 8$ ). *NRAS* mutants carried additional mutations/sequence



**Fig. 1** Examples of histologic spectrum and immunophenotype of SNTMM. **A** Tumor composed of uniform rounded cells with prominent nucleoli. **B** A spindle cell variant with scant collagenous matrix. **C** An epithelioid tumor with pigmentation. **D** Prominent nuclear expression of SOX10 seen in 99% (88/89) of cases.

variations in 39% (14/36). Affected genes encoded receptor tyrosine kinases (RTKs) other than *KIT*, G-protein  $\alpha$  subunits, components of the PI3K-, *RB1*-, *TP53*-, *WNT*- pathways, chromatin regulatory factors and proteins participating in DNA repair processes. Two SNTMMs harbored *KRAS* hot-spot mutations, p.G12D and p.G13D. The former coincided with *JAK2* p.G614E substitution. *BRAF/RAS* mutations were identified in 71% (10/14) of primary paranasal sinuses melanomas but only in 41% (26/64) of nasal cavity tumors. Also, no such mutations were seen in three lesions involving nasopharynx.

*NF1* mutations ( $n = 3$ ) were detected in 10% (2/21) of SNTMMs. A *NRAS* mutant revealed two *NF1* truncating (p.Q1070\*, p.S2188fs) mutations, while a *BRAF/RAS*-WT tumor harbored *NF1* p.G1219R substitution coinciding with mutations/sequence variations in *CDKN2A*, *EGFR*, *MTOR*, *TERTp*, and *TP53*.

*SPRED1* frameshift mutations (p.E51\*, p.Q158Sfs\*15, p.V309Wfs\*9) were identified in 12% (3/25) of *BRAF/RAS*-WT SNTMMs including *KIT* mutant. In contrast, 1 of 25 *BRAF/RAS*-mutants harbored low allele frequency *SPRED1* variant (p.R207K).

*BRAF/RAS/NF1*-WT. Mutations/sequence variations in genes encoding RTKs, G-protein  $\alpha$  subunits, components of the PI3K-, *RB1*-, *TP53*-, *WNT*- pathway (*PIK3CA* p. E542K, *RB1* p.V754L, *TP53* p.G244D, *CTNNB1* p.S45del), chromatin regulatory factors (*EZH2* p.Y646C) and proteins participating in DNA repair processes (*ERCC4* p.R799W) were found in 36% (12/33) of *BRAF/RAS*-WT (evaluated with Ion Torrent™ CH-panel) and 88% (14 of 16) of *BRAF/RAS/NF1*-WT tumors (Ion Torrent™ CC-panel). A complete list of identified genetic changes is available in Supplemental Database.

*GNAS*, *GNAQ* and *GNA11*. Mutations in *GNAS*, *GNAQ* and *GNA11*, genes encoding G-protein  $\alpha$  subunits, were identified in 6% (5/90)

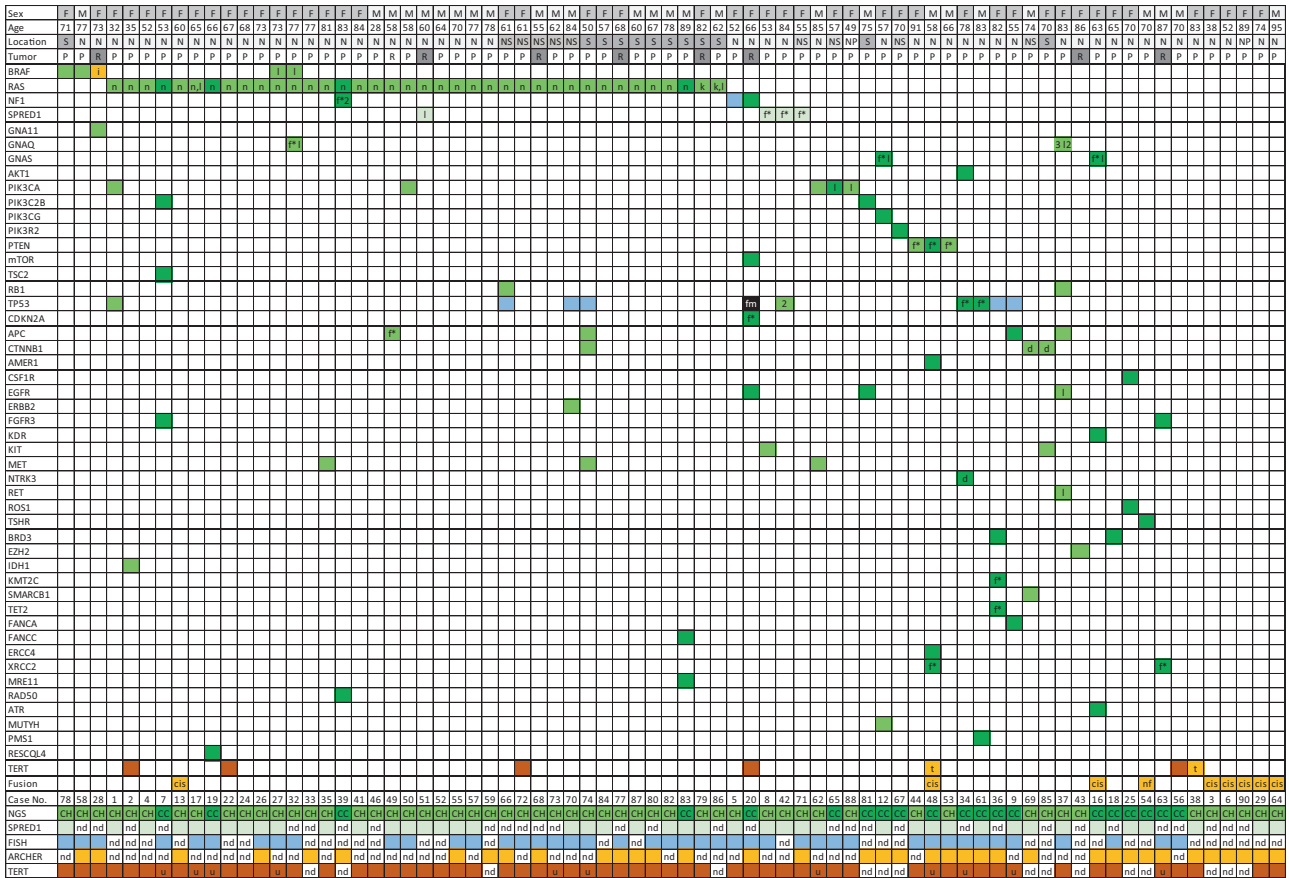
of SNTMMs. However, only *GNA11* p.Q209L demonstrated high allele frequency (58%). *GNAQ* ( $n = 4$ ) and *GNAS* ( $n = 2$ ) mutations identified in 4 melanomas showed low allele frequency and co-occurred with mutations affecting PI3K pathway.

*PI3K-AKT-MTOR*. Mutations/sequence variations in genes encoding key components of PI3K pathway, *AKT1*, *PIK3CA* ( $n = 5$ ) and *PTEN* ( $n = 4$ ) were identified in 11% (10/90) of SNTMMs. Additional sequencing data obtained in 21 cases evaluated with the Ion AmpliSeq™ CC-panel revealed mutations in *MTOR*, *PIK3C2B* ( $n = 2$ ), *PIK3CG*, *PIK3R2* and *TSC2*. The latter coincided with *PIK3C2B* mutation. Three of 14 mutations affecting PI3K pathway occurred in *NRAS* mutants.

*KIT*. Gain-of-function *KIT* p.K642E mutation was detected in 2% (2/90) of SNTMMs. In both cases, the *KIT* mutation coincided with mutation activating other oncogene (*CTNNB1*) or inactivating tumor suppressor gene (*SPRED1*).

*Receptor tyrosine kinases other than KIT*. Fifteen sequence variations affecting *CSF1R*, *EGFR* ( $n = 3$ ), *ERBB2*, *FGFR3* ( $n = 2$ ), *KDR*, *MET* ( $n = 3$ ), *NTRK3*, *RET*, *ROS-1* and *TSHR*, genes encoding RTKs, were identified in 13 SNTMMs. A protein kinase domain was frequently ( $n = 10$ ) involved. Computational techniques predicted damaging potential of all substitutions. RTK sequence variations coincided with PI3K ( $n = 5$ ), and *TP53* ( $n = 4$ ) pathway alterations and *NRAS* hot-spot mutations ( $n = 4$ ).

*Cell cycle related genes*, *CDKN2A*, *TP53* and *RB1*. *TP53* mutations were identified in 6% (5/90) of SNTMMs. *TP53* alterations coincided with *NRAS* drivers ( $n = 4$ ) and mutations affecting genes encoding RTKs ( $n = 5$ ), canonical *WNT* pathway ( $n = 2$ ), *RB1*, and *CDKN2A*. In one tumor evaluated with the Ion AmpliSeq™



**Fig. 2 Summary of most important molecular findings including gene mutations/sequence variations, gene locus deletions and fusion gene transcripts (all genetic changes identified in this study are listed in Supplemental Database).** Clinical data abbreviations: F female, M male, N nasal cavity, NS nasal cavity with sinus involvement, S sinus, NP nasopharynx, P primary, R recurrence. Results of molecular and FISH studies are marked by colors. Green indicates mutations/sequence variations detected by NGS: cancer hot spot panel (CH)-grass green, comprehensive cancer panel (CC)-spruce green and *SPRED1* panel-pastel green, empty box-missense mutation, d -in frame deletion, f\*-STOP codon/frameshift mutation, n-*NRAS* mutation, k-*KRAS*, l-low allele frequency. Blue box indicates *NF1/TP53* FISH data. Yellow indicates changes detected by ArcherDx: cis-cis fusion, i-oncogenic isoform, t-TERT fusion, nf-likely not in frame). Brown box indicates *TERT* Sanger sequencing data (u- unsuccessful PCR amplification but preserved DNA template). Black box indicates alterations detected by FISH and NGS. Other: 2 = two mutations, nd not done.

CH-panel, *TP53* p.G244D substitution was the sole genetic abnormality.

**Canonical WNT/Beta-catenin pathway.** Mutations in *CTNNB1* (n = 3) and *APC* (n = 4), genes encoding components of canonical WNT pathway, were detected in 7% (6/90) of tumors. In three tumors, *APC* and/or *CTNNB1* mutation coincided with *NRAS* (n = 2) or *KIT* driver mutations. One of 21 SNTMMs evaluated with the Ion AmpliSeq™ CC-panel revealed mutation in *AMER1* (APC Membrane Recruitment Protein 1), a canonical WNT pathway regulator. This Triple-WT tumor also harbored mutations/sequence variations in several epigenetic modifiers and components of PI3K pathway and *CNOT4::TERT* fusion transcripts.

**Epigenetic modifiers and DNA repair pathways.** SNTMMs harbored mutations/sequence variations in various genes involved in epigenetic processes such as chromatin structure regulation, transcriptional repression, or DNA repair processes. Among mutated genes encoding chromatin regulatory factors (CRF) were *SMARCB1* encoding component of ATP-dependent chromatin remodeling complex, *EZH2* and *KMT2C* encoding histone tail modifiers, *TET2* encoding DNA demethylase, *IDH1* encoding an enzyme that generates metabolite inhibiting CRFs and *BRD3* encoding protein associated with histone acetylation. All mutations except for *BRD3* p.K655R substitution represented unique

molecular events. CRF mutants often lacked mutations in canonical melanoma drivers.

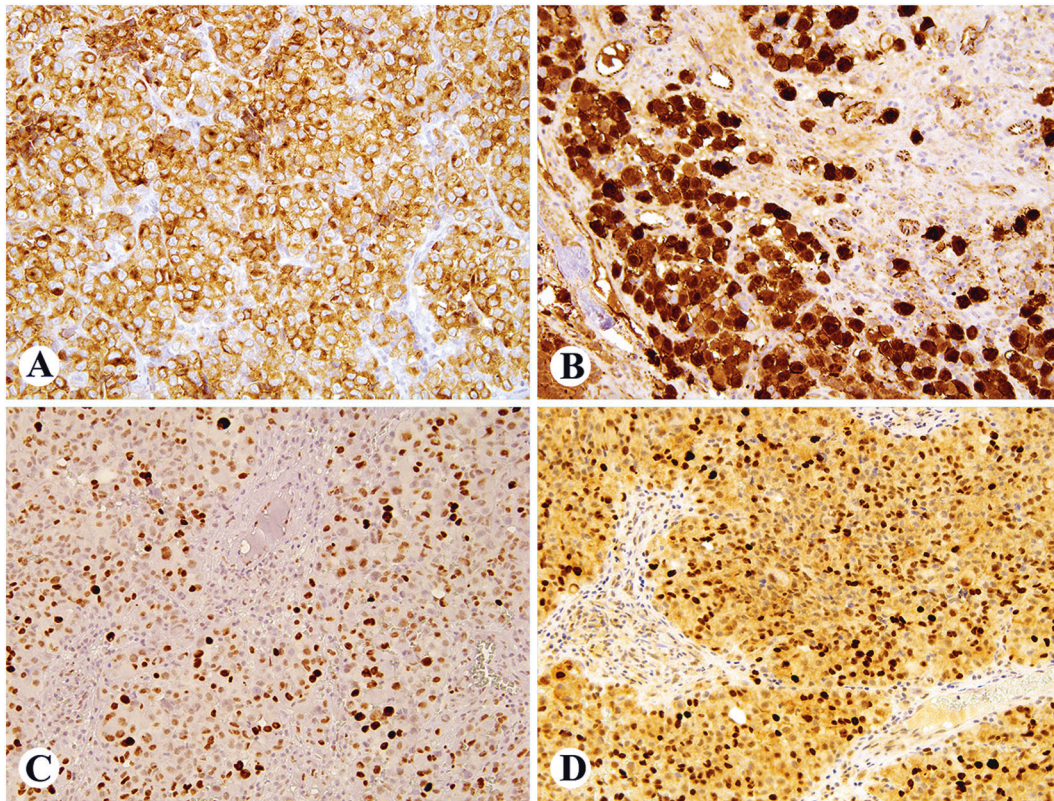
Mutations/sequence variations affecting various DNA repair pathways were identified in 10% (9/90) of SNTMMs including five *BRAF/RAS/NF1*-wild type tumors and four *NRAS* mutants. *FANCA*, *FANCC*, and *ERCC4*, components of the Fanconi anemia (FA) damage repair pathways were mutated in three cases. Two SNTMMs including a *ERCC4* mutant, harbored an identical frameshift mutation in *XRCC2*, a *RAD51* paralog involved in homologous recombination repair of DNA damage. Mutations affecting members of DNA damage response MRE11-RAD50-NBS1 complex were detected in 2 other tumors. *ATR*, *MUTYH*, *RECQL4* and *PMS1*, which function in various DNA repair pathways were mutated in four cases, one mutation in each tumor.

**TERTp Sanger sequencing study**

Two *TERTp* mutation hot spots were evaluated in 68 tumors. Of successfully PCR amplified samples, 9% (5/54) revealed c.228 C > T (n = 4) and c.250 C > T *TERTp* mutations. PCR failed to produce amplification products in 21% (14/68) of analyzed cases, although DNA/RNA quality controls indicated well-preserved nucleic acids.

**Fusion gene transcripts**

Forty SNTMMs were evaluated for fusion gene transcripts. Two tumors (5%) revealed *TERT* fusion with either *CNOT4* or *NUP50*.



**Fig. 3** Examples of oncogene and tumor suppressor gene immunohistochemistry in SNTMM. **A** Membrane and dot-like cytoplasmic KIT (CD117) expression in p.K642E mutant. **B** Beta-catenin nuclear accumulation in tumors harboring *CTNNB1* p.S45del. **C** Nuclear accumulation of TP53, mirrored by elevated nuclear expression of MDM2 (**D**) in *NRAS* p.G12D mutant.

*DCAF7*(e1)::*PRKCA*(e3) fusion transcripts, predicted to be not in-frame, were detected in one case. Eight (20%, 8/40) SNTMMs including 7 *BRAF/RAS*-WT tumors expressed *ADCK4*(e15)::*NUMBL*(e3) cis-fusion transcripts.

#### **NF1 and TP53 loci FISH study**

Integrity of *NF1* and *TP53* loci were evaluated by FISH in 48 cases. Deletion of *NF1* locus was a sole molecular change in one tumor. Heterozygous *TP53* locus deletion was detected in 13% (6/48) of tumors.

#### **Immunohistochemical analysis of pathways and oncogenes**

CMYC was commonly expressed, but 13% (11/82) of tumors were negative. KIT expression varied from focal to diffuse and was detected in 56% (46/82) of cases. Both *KIT* mutants revealed diffuse, strong KIT immunoreactivity (Fig. 3A). Most SNTMMs had prominent membranous and weak cytoplasmic  $\beta$ -catenin staining. However, four tumors, including three *CTNNB1* mutants, showed strong cytoplasmic and focal or diffuse nuclear staining (Fig. 3B). Nuclear TP53 immunoreactivity was seen in 87% (71/82) of SNTMMs. The most common reaction was mosaic staining (>10 to  $\leq$ 80% of positive nuclei) detected in 34% of cases. Nineteen (23%) SNTMMs had diffuse (>80%) TP53 expression, while focal ( $\leq$ 10% of positive nuclei) immunoreactivity was seen in 24 (29%) cases. No TP53 staining was detected in 11 SNTMMs including two cases harboring *TP53* alterations. Diffuse or mosaic MDM2 nuclear staining was seen in 40% (33/82) tumors. The pattern of MDM2 expression mirrored TP53 staining in most cases (Fig. 3C, D). Furthermore, *NTRK* and *ROS1* expression was evaluated in tumors harboring *NTRK3* and *ROS1* mutations, respectively. *NTRK3* mutant revealed focal *NTRK* expression, while *ROS1* mutant lacked *ROS1* immunoreactivity.

Mismatch repair (MMR) proteins were evaluated in 78 SNTMMs. The loss of *MLH1* and *PMS2* expression was documented in three

*BRAF/RAS*-WT SNTMMs. These tumors harbored, respectively, *EZH2*, *PTEN*, and *TP53* mutation/sequence variation. *MSH2* and *MSH6* expression was retained in all cases. None of SNTMMs harbored *MLH1* mutation. Immunohistochemistry results (*CTNNB1*, *CMYC*, *KIT*, *MDM2*, *TP53* and *MMR* proteins) for each case are available in Supplementary Table 5.

#### **DISCUSSION**

Mucosal melanoma is a rare melanoma subtype. In general, mucosal tumors are characterized by low point mutation burden and high number of structural variants. Recent studies indicated that tumors arising in different organs may have different mutation profiles<sup>15–17</sup>.

This study evaluated 90 well-documented SNTMMs using spectrum of molecular techniques including targeted-NGS, Sanger sequencing and FISH. Unfortunately, copy number variation analysis was not available for this investigation. All cases with a clinical history of a primary cutaneous or another mucosal melanoma were excluded, considering that the SNT is an uncommon site of melanoma metastases<sup>19</sup>. Primary SNT malignant peripheral nerve sheath tumor and perivascular epithelioid cell tumor was considered in the differential diagnosis and excluded based on morphology and immunophenotype, including retention of H3K27me3 or lack of nuclear TFE3 expression<sup>20,21</sup>.

The *BRAF*/MEK/ERK signaling pathway, known as the mitogen-activated-protein-kinase (MAPK) pathway and PI3K/AKT/mTOR pathway promotes cell proliferation and survival<sup>22</sup>. Gain-of-function *BRAF* or *RAS* mutations and *NF1* inactivation account for pathologic signaling of these pathways<sup>23</sup>. Recently developed cutaneous melanoma molecular classification specified four subtypes: *BRAF*-, *RAS*-, *NF1*-mutants, and Triple-WT tumors<sup>24</sup>. The latter is defined as group of molecularly heterogeneous

**Table 1.** Clinicopathologic characteristics of 13 *NF1* mutant SNTMMs described in this and previously published studies<sup>14,16,17</sup> and available at cBioPortal ([www.cbioportal.org](http://www.cbioportal.org)).

Sex	Age	Coding sequence mutation	Amino acid mutation	NF1 Locus	Ref. No.
Female	46	Null	Null		17
Female	40-50	c.919_938del	p.L307*		14
		c.6642 + 2 T > A	Splice Site		
Female	52	WT	WT	Loss	This study
Female	59	c.2407 C > T	p.Q803*		17
Female	66	c.3655 G > A	p.G1219R		This study
Female	83	c.3208 C > T	p.Q1070*		This study
		c.6561_6562insATTC	p.S2188fs		
Female	90	Unavailable	p.Q959K		16
Female	80-90	c.4558 C > T	p.Q1520*	Loss	14
Female	NA	Unavailable	p.L925Sfs*9		cBioPortal <sup>a</sup>
Female	NA	Unavailable	p.V1753Ffs*12		cBioPortal <sup>b</sup>
Male	47	c.7558_7559insAAATC	p.K2520_S2521fs		17
Male	50-60	WT	WT	Loss	14
Male	65	c.1613_1614insT	p.M538_P539fs		17

<sup>a</sup>P-0004275.<sup>b</sup>P-0012311.

tumors which lacks *BRAF* and *RAS* hot-spot mutations and *NF1* inactivation.

*BRAF* p.V600E substitution, a hallmark mutation of cutaneous melanoma was not detected in this cohort. However, one tumor harbored mutation in p.K601, another *BRAF* hot-spot<sup>24</sup>. In SNTMM, hot-spot and non-hot-spot *BRAF* mutations are occasionally reported, the latter co-occurring with canonical *RAS* mutations<sup>14,17</sup>.

*NRAS* mutations were found in 42% of SNTMM, predominantly paranasal tumors. Previous studies of 10 or more SNTMMs reported *NRAS* mutant frequency in the range of 7–22% and 26–54% for Sanger and NGS, respectively<sup>5,6,8–14,17,25</sup>. Also, the involvement of codons 61, 12, and 13 mirrored published Sanger sequencing and NGS data<sup>5,6,8,10,13,14,17,25–28</sup>. However, a very recent investigation reported 50% (8/16) of *NRAS* mutations in codons 7, 8, 17, 58, 62, 63, and 65<sup>9</sup>. Similar mutations have been described in a few tumors, including cutaneous melanomas but not in sinonasal or other mucosal melanomas. Detailed analysis is presented in Supplementary Table 6. *KRAS* hot-spot mutations are rare in mucosal melanoma<sup>15–17,29</sup>. In SNTMMs, only two cases in combined 44 SNTMMs were reported<sup>11,14</sup>. Similarly, only two such mutants were found in this cohort.

*NF1*, encoding a negative regulator of *RAS*, is the third most frequent mutated gene in UV-signature melanomas after *BRAF* and *NRAS*<sup>30</sup>. *NF1* mutations were identified in 25 to 31% of SNTMMs in relatively small cohorts of tumors by whole exome- and whole genome- sequencing studies<sup>16,17</sup>. This investigation utilizing targeted NGS, found *NF1* mutations in 10% of cases, similar to a previous SNTMM study employing a similar sequencing strategy<sup>14</sup>. Early studies suggested that *NF1* alterations were mutually exclusive with *BRAF* and *RAS* mutations<sup>30</sup>. However, the co-occurrence of *NF1* and non-hot-spot *BRAF* and hot-spot *RAS* mutations has been documented<sup>24</sup>. The latter was seen in this study and reported in head and neck mucosal melanomas including SNT tumors<sup>29,31</sup>. *NF1*-mutant cutaneous melanoma was associated with male sex and older age at diagnosis<sup>24,32</sup>. A similar correlation is not seen in SNTMM harboring *NF1* alterations. Clinicopathologic characteristics of 13 *NF1* mutant SNTMMs identified by the current and previous studies is presented in Table 1.

*SPRED1*, member of SPRED protein family, acts as another negative regulator of Ras-MAPK signaling binding directly to c-KIT

and RasGAP. Loss-of-function mutations in *SPRED1* leads to the developmental disorder, Legius syndrome, and were reported in human cancer<sup>33</sup>. More recent studies documented *SPRED1* inactivation in mucosal melanomas predominantly in anorectal (67%) and vulvovaginal (33%) and less frequently in sinonasal tumors (12.5%)<sup>12</sup>. In this cohort of SNTMMs, *SPRED1* frameshift/stop codon mutations were identified in 12% (3/25) of *BRAF*/*RAS*-WT tumors and their occurrence were mutually exclusive to mutations affecting components of Ras-MAPK signaling pathway such as PIK3CA and PTEN as previously reported<sup>12</sup>. However, *SPRED1* mutation coincided with activating *KIT* mutation in 1 of 3 cases. The latter was seen in anorectal and vulvovaginal tumor but not in SNTMM<sup>12</sup>.

Gain of function *KIT* mutations or gene amplification were reported in mucosal and acral melanomas and those arising in chronically UV-exposed skin. Most of *KIT* oncogenic mutations were detected in exon 11 and 13 with p.L576P and p.K642E substitutions being quite common<sup>34,35</sup>. In this study, 2% (2/90) of SNTMMs harbored *KIT* p.K642E mutation. The frequency of *KIT* mutations in SNTMMs appears to be low (5%; 13/246) based on the current and published studies of 10 or more cases<sup>5,6,8,10,11,13,14,17,25</sup>.

A very recent investigation reported *KIT* mutations in 22% (16/72) of SNTMMs. Furthermore, exon 11 deletions ( $n = 4$ ) and duplication accounted for 31% (5/16) of these mutations<sup>9</sup>. Such alterations are exceedingly rare in mucosal melanomas and represent <10% of all *KIT* mutations<sup>6,25,29,36–44</sup>. Frequency of reported types of *KIT* mutations in mucosal melanomas is presented in Supplementary Table 7. *KIT* expression was documented by IHC in mucosal melanomas including sinonasal tumors<sup>5,9,39</sup>. In this cohort, *KIT* immunoreactivity was common and did not correlate with mutation status. Also, there was no association between *KIT* and *CMYC* positivity and pigmentation as previously reported<sup>9</sup>. However, *KIT* mutants revealed high mitotic rates. Previous evaluation reported a correlation between *KIT* mutations and increased cell proliferation rate in metastatic oral melanomas<sup>45</sup>.

This study documented the dominant role of *NRAS* versus *KIT* oncogenesis in SNTMMs. This observation was corroborated by the review of *RAS* and *KIT* mutations reported in head and neck melanomas<sup>5,6,8–10,13,14,16,17,25,27,28</sup>. However, a reverse correlation between *RAS* and *KIT* mutations has been reported in oral tumors (Supplementary Fig. 2). Some studies combined melanomas from

nasal and oral cavities into a head and neck category, resulting in obfuscation of the differences between these two entities<sup>29,35,46,47</sup>.

Alterations of *GNAS*, *GNAQ*, and *GNA11* are widespread in different cancer types including uveal melanoma<sup>48,49</sup>. In this cohort, driver mutations in genes encoding G-protein  $\alpha$  subunits were rare; canonical *GNA11* p.Q209L substitution was detected only in one tumor.

Pathologic activation of PI3K/AKT/mTOR pathway may occur due to other than *BRAF/RAS/NF1* genetic alterations such as mutations in genes encoding pathway components and regulators<sup>50,51</sup>. This study documented mutations in 14% (13/90) of SNTMMs in a wide array of genes involved in PI3K/AKT/mTOR pathway including Class I catalytic and regulatory molecules (*PIK3CA*, *PIK3CG*, *PIK3R2*), Class II molecule *PIK3C2B*, *AKT1*, *mTOR*, *TSC2* and *PTEN*. Previous studies reported similar mutations in both cutaneous and mucosal melanomas including SNTMM<sup>14,16,29,47</sup>. In this study, only three PI3K mutants harbored canonical melanoma driver (*NRAS* or *NF1*) mutations.

The *TP53* tumor suppressor gene is the most mutated gene in solid tumors<sup>52</sup>. However, *TP53* mutations are rare in melanoma<sup>53</sup>. In this study, *TP53* mutations and *TP53* locus deletions were identified in 6% and 15% of SNTMM, respectively. Previous studies reported a similar frequency of *TP53* mutations in SNTMMs and head and neck mucosal tumors<sup>13–15,17,29</sup>. Nevertheless, nuclear accumulation of *TP53* was common, suggesting dysfunction of the *TP53* pathway. In a subset of SNTMMs, nuclear expression of MDM2, a *TP53* regulatory protein, mirrored nuclear accumulation of *TP53*. Either *TP53* mutations or overexpression of MDM2 can lead to loss of *TP53* tumor suppressor function<sup>54</sup>.

WNT/ $\beta$ -catenin signaling pathway controls a variety of biological cell processes<sup>55</sup>. Inactivating mutations of *APC* or activating mutations of *CTNNB1*, genes encoding pathway components, have been reported in cancer<sup>56</sup>. *APC* and *CTNNB1* mutations are rare in melanoma and often co-occur with other drivers<sup>57</sup>. In this study, three SNTMMs harbored mutations in *CTNNB1* exon 3 phosphorylation sites for GSK-3 $\beta$  (glycogen synthase kinase 3 beta) or casein kinase-1. A translocation of  $\beta$ -catenin to the nucleus associated with the activation of WNT/ $\beta$ -catenin pathway was documented in all three mutants as previously reported in other tumors<sup>58</sup>. *CTNNB1* mutations affecting exon 3 hot-spots have been reported at an early stage of the tumorigenesis and have a transforming potential<sup>59</sup>. No canonical melanoma drivers were identified in one tumor harboring *CTNNB1* p.S45 deletion.

A splicing factor 3b subunit 1 (*SF3B1*) gene encodes a subunit of the spliceosome factor 3b, a core component of ribonucleoprotein complex (spliceosome) responsible for removing introns from precursor mRNA. *SF3B1* hot-spot (p.R625 and p.K666) mutations have been associated with diverse alternative splicing events and reported in uveal and mucosal (anorectal, vulvovaginal, esophageal) melanomas<sup>16,60–62</sup>. More recent studies identified *SF3B1* mutations in head and neck melanomas including sinonasal tumors<sup>9,29</sup>. In this cohort, no *SF3B1* mutations were detected in 21 tumors evaluated by Ion AmpliSeq™ CC panel. A review of reported mutants (Supplementary Table 8) suggested low (<3%) frequency of *SF3B1* hot-spot mutations in SNTMMs.

Alteration of the insulin-like growth factor (IGF) axis has been implicated in carcinogenesis<sup>63</sup>. A recent study reported *IGF2R* mutations in 32% (13/41) of mucosal melanomas, including head and neck tumors<sup>47</sup>. In the current study, no mutations affecting *IGF1R* or *IGF2R* were found in 21 tumors analyzed with a comprehensive cancer panel. Also, previous NGS studies on mucosal melanomas including head and neck tumors failed to identify mutations affecting components of IGF-axis<sup>14–17,42</sup>.

Sequence variations in genes encodings RTKs, chromatin regulatory factors and histone proteins and genes encoding components of different DNA repair pathways (Fig. 2) were identified in a subset of SNTMMs. A biological significance of these changes remains undetermined because somatic versus germline

nature could not be clearly established. However, a low VAF value (< 40%) might strongly suggest former in some cases (Supplemental Database, sheet A). Presence of pathogenic germline variants such as *MET* p.T1010I and *MET* p.R988C (reported in this study) may enhance constitutive protein tyrosine phosphorylation causing tumorigenicity in-vitro and in-vivo as reported in breast and lung cancer, respectively<sup>64,65</sup>. Recently published study showed that tumors harboring pathogenic germline variants often displayed a loss of heterozygosity or biallelic event with somatic mutations affecting the same residue<sup>66</sup>. Unfortunately, this investigation could not address such issues because a scope was limited by the absence of tumor matching normal tissue and inadequate quality of nucleic acids obtained from archival FFPE tissue blocks.

*TERT* alterations, from single nucleotide mutations to complex rearrangements, have been reported in different cancers including melanoma<sup>67</sup>. In this study, mutations in two *TERT* mutation hot spots were detected in 9% of analyzed tumors. However, PCR amplification of these region yielded no amplification products in 14 cases with well-preserved nucleic acids. This could be attributed to the alteration of *TERT* sequence. *TERT* fusion transcripts, *NUP50(i1)::TERT(e2)* and *CNOT4(e2)::TERT(e2)* were detected in two SNTMMs. Previously, *TERT* fusions involving various partners were identified in different cancers including oral melanoma ([www.cbioportal.org](http://www.cbioportal.org)). *TERT* alterations reported in this study were detected in both Triple-WT tumors and SNTMM driven by *NRAS* mutations. Thus, they could act as the primary driving force as reported in non-translocation related sarcomas and clear cell sarcoma of kidney, or as a secondary driver accelerating tumor progression as reported in aggressive meningioma and metastatic Leydig cells tumor<sup>67–72</sup>.

Oncogenic gene fusion involving *ALK*, *BRAF*, *MET*, *NTRK* and *ROS-1* have been detected predominantly in younger patients in a subset of cutaneous melanomas including Spitzoid and acral tumors<sup>67,73,74</sup>. Such fusions appear to be extremely rare in mucosal melanomas, although a few has been reported including a *FGFR3::TACC3* fusion in a case of SNTMM<sup>74–76</sup>. Of the 40 tumors analyzed in this study, none showed fusion gene transcripts reported in cutaneous melanomas. However, a *DCAF7(e1)::PRKCA(e3)* fusion, predicted to be out-of-frame, was found in one case. Activation of *PRKCA* through oncogenic fusion was reported in melanocytic tumors including acral melanoma<sup>77,78</sup>. Chimeric *ADCK4::NUMBL* fusion transcripts, most likely a product of cis-splicing between adjacent genes, were found in eight cases including 7 *BRAF/RAS*-WT tumors. Cis-fusion transcripts were detected in various tumor and normal tissues and implicated in fundamental cellular mechanisms<sup>79,80</sup>. However, a role of *ADCK4::NUMBL* fusion transcripts in SNTMM is not known.

In summary, this study documented the dominant role of *NRAS* oncogenesis in SNTMM and alterations of the key components and regulators of Ras-MAPK signaling pathway such as *SPRED1* in a subset of *BRAF/RAS*-WT tumors. Also, presence of low-frequency mutations affecting KIT receptor tyrosine kinase, G-protein  $\alpha$  subunits, *TP53*-, and WNT-, pathways indicate a complexity of the molecular mechanisms underlying the pathogenesis and progression of sinonasal melanoma.

## DATA AVAILABILITY

Data available upon request subjected to NIH policies and procedures.

## REFERENCES

1. Lucke A. Die melanotischen Geschwulste. Die Lehre von de Geschwulsten in anatomischer und Ikinische Beziehung. In: Itha F, Billroth T, eds. Handbuch Der Allgemeinen und Speziellen Chirurgie, Erlangen, Band 2, Abteil 1, Seite 244 (1869)
2. Thompson LD, Wieneke JA, Miettinen M. Sinonasal tract and nasopharyngeal melanomas: a clinicopathologic study of 115 cases with a proposed staging system. *Am J Surg Pathol* 27, 594-611(2003)

3. Marcus DM, Marcus RP, Prabhu RS, Owonikoko TK, Lawson DH, Switchenko J, et al. Rising incidence of mucosal melanoma of the head and neck in the United States. *J Skin Cancer* 2012, 231693 (2012)
4. Amit M, Na'ara S, Hanna EY. Contemporary Treatment Approaches to Sinonasal Mucosal Melanoma. *Curr Oncol Rep* 20, 10 (2018)
5. Chraybi M, Abd Alsamad I, Copie-Bergman C, Baia M, André J, Dumaz N, et al. Oncogene abnormalities in a series of primary melanomas of the sinonasal tract: NRAS mutations and cyclin D1 amplification are more frequent than KIT or BRAF mutations. *Hum Pathol* 44, 1902-1911 (2013)
6. Öztürk Sari Ş, Yılmaz I, Taşkın OÇ, Narlı G, Şen F, Çomoğlu Ş, et al. BRAF, NRAS, KIT, TERT, GNAQ/GNA11 mutation profile analysis of head and neck mucosal melanomas: a study of 42 cases. *Pathology* 49, 55-61 (2017)
7. Toscano de Mendonça UB, Cernea CR, Matos LL, Monteiro de Araujo Lima RR. Analysis of KIT gene mutations in patients with melanoma of the head and neck mucosa: a retrospective clinical report. *Oncotarget* 9, 22886-22894 (2018)
8. Turri-Zanoni M, Medicina D, Lombardi D, Ungari M, Balzarini P, Rossini C, et al. Sinonasal mucosal melanoma: Molecular profile and therapeutic implications from a series of 32 cases. *Head Neck* 35, 1066-1077 (2013)
9. Wroblewska JP, Mull J, Wu CL, Fujimoto M, Ogawa T, Marszalek A, et al. SF3B1, NRAS, KIT, and BRAF Mutation; CD117 and cMYC Expression; and Tumoral Pigmentation in Sinonasal Melanomas: An Analysis With Newly Found Molecular Alterations and Some Population-Based Molecular Differences. *Am J Surg Pathol* 43, 168-177 (2019)
10. Zebary A, Jangard M, Omholt K, Ragnarsson-Olding B, Hansson J. KIT, NRAS and BRAF mutations in sinonasal mucosal melanoma: a study of 56 cases. *Br J Cancer* 109, 559-564 (2013)
11. Colombino M, Paliogiannis P, Cossu A, De Re V, Miolo G, Botti G, et al. BRAF Mutations and Dysregulation of the MAP Kinase Pathway Associated to Sinonasal Mucosal Melanomas. *J Clin Med* 8, 1577 (2019)
12. Ablain J, Xu M, Rothschild H, Jordan RC, Mito JK, Daniels BH, et al. Human tumor genomics and zebrafish modeling identify *SPRED1* loss as a driver of mucosal melanoma. *Science* 362, 1055-1060 (2018)
13. Amit M, Tam S, Abdelmeguid AS, Roberts DB, Takahashi Y, Raza SM, et al. Mutation status among patients with sinonasal mucosal melanoma and its impact on survival. *Br J Cancer* 116, 1564-1571 (2017)
14. Freiburger SN, Morand GB, Turko P, Wager U, Dummer R, Hüllner M, et al. Morpho-Molecular Assessment Indicates New Prognostic Aspects and Personalized Therapeutic Options in Sinonasal Melanoma. *Cancers (Basel)* 11, 1329 (2019)
15. Hayward NK, Wilmott JS, Waddell N, Johansson PA, Field MA, Nones K, et al. Whole-genome landscapes of major melanoma subtypes. *Nature* 545, 175-180 (2017)
16. Hintzsche JD, Gorden NT, Amato CM, Kim J, Wuensch KE, Robinson SE, et al. Whole-exome sequencing identifies recurrent SF3B1 R625 mutation and comutation of NF1 and KIT in mucosal melanoma. *Melanoma Res* 27, 189-199 (2017)
17. Newell F, Kong Y, Wilmott JS, Johansson PA, Ferguson PM, Cui C, et al. Whole-genome landscape of mucosal melanoma reveals diverse drivers and therapeutic targets. *Nat Commun* 10, 3163 (2019)
18. Stout LA, Kassem N, Hunter C, Philips S, Radovich M, Schneider BP. Identification of germline cancer predisposition variants during clinical ctDNA testing. *Sci Rep* 11, 13624 (2021)
19. Chang MH, Kuo YJ, Ho CY, Kuan EC, Lan MY. Metastatic Tumors of the Sinonasal Cavity: A 15-Year Review of 17 Cases. *J Clin Med* 8, 539 (2019)
20. Röhrich M, Koelsche C, Schrimpf D, Capper D, Sahm F, Kratz A, et al. Methylation-based classification of benign and malignant peripheral nerve sheath tumors. *Acta Neuropathol* 131, 877-887 (2016)
21. Argani P, Aulmann S, Illei PB, Netto GJ, Ro J, Cho HY, et al. A distinctive subset of PEComas harbors TFE3 gene fusions. *Am J Surg Pathol* 34, 1395-1406 (2010)
22. Guo YJ, Pan WW, Liu SB, Shen ZF, Xu Y, Hu LL. ERK/MAPK signaling pathway and tumorigenesis. *Exp Ther Med* 19, 1997-2007 (2020)
23. Davies H, Bignell GR, Cox C, Stephens P, Edkins S, Clegg S, et al. Mutations of the BRAF gene in human cancer. *Nature* 417, 949-954 (2002)
24. The Cancer Genome Atlas Network. Genomic Classification of Cutaneous Melanoma. *Cell* 161, 1681-1696 (2015)
25. Omholt K, Grafström E, Kanter-Lewensohn L, Hansson J, Ragnarsson-Olding BK. KIT pathway alterations in mucosal melanomas of the vulva and other sites. *Clin Cancer Res* 17, 3933-3942 (2011)
26. Maldonado-Mendoza J, Ramírez-Amador V, Anaya-Saavedra G, Ruiz-García E, Maldonado-Martínez H, Fernández-Figueroa E, et al. CD117 immunorepression in oral and sinonasal mucosal melanoma does not correlate with somatic driver mutations in the MAPK pathway. *J Oral Pathol Med* 48, 382-388 (2019)
27. Quek C, Rawson RV, Ferguson PM, Shang P, Silva I, Saw RPM, et al. Recurrent hotspot SF3B1 mutations at codon 625 in vulvovaginal mucosal melanoma identified in a study of 27 Australian mucosal melanomas. *Oncotarget* 10, 930-941 (2019)
28. Mikkelsen LH, Maag E, Andersen MK, Kruhøffer M, Larsen AC, Melchior LC, et al. The molecular profile of mucosal melanoma. *Melanoma Res* 30, 533-542 (2020)
29. Cosgarea I, Ugurel S, Sucker A, Livingstone E, Zimmer L, Ziemer M, et al. Targeted next generation sequencing of mucosal melanomas identifies frequent NF1 and RAS mutations. *Oncotarget* 8, 40683-40692 (2017)
30. Krauthammer M, Kong Y, Bacchiocchi A, Evans P, Pornputtpong N, Wu C, et al. Exome sequencing identifies recurrent mutations in NF1 and RASopathy genes in sun-exposed melanomas. *Nat Genet*. 2015;47:996-1002.
31. Cerami E, Gao J, Dogrusoz U, Gross BE, Sumer SO, Aksoy BA, et al. The cBio cancer genomics portal: an open platform for exploring multidimensional cancer genomics data. *Cancer Discov* 2, 401-404 (2012)
32. Cirenajwis H, Lauss M, Ekedahl H, Törngren T, Kvist A, Saal LH, et al. NF1-mutated melanoma tumors harbor distinct clinical and biological characteristics. *Mol Oncol* 11, 438-451 (2017)
33. Lorenzo C, McCormick F. SPRED proteins and their roles in signal transduction, development, and malignancy. *Genes Dev* 34, 1410-1421 (2020)
34. Curtin JA, Busam K, Pinkel D, Bastian BC. Somatic activation of KIT in distinct subtypes of melanoma. *J Clin Oncol* 24, 4340-4346 (2006)
35. Beadling C, Jacobson-Dunlop E, Hodi FS, Le C, Warrick A, Patterson J, et al. KIT gene mutations and copy number in melanoma subtypes. *Clin Cancer Res* 14, 6821-6828 (2008)
36. Satzger I, Schaefer T, Kuetler U, Broecker V, Voelker B, Ostertag H, et al. Analysis of c-KIT expression and KIT gene mutation in human mucosal melanomas. *Br J Cancer* 99, 2065-2069 (2008)
37. Torres-Cabala CA, Wang WL, Trent J, Yang D, Chen S, Galbinca J, et al. Correlation between KIT expression and KIT mutation in melanoma: a study of 173 cases with emphasis on the acral-lentiginous/mucosal type. *Mod Pathol* 22, 1446-1456 (2009)
38. Handolias D, Hamilton AL, Salemi R, Tan A, Moodie K, Kerr L, et al. Clinical responses observed with imatinib or sorafenib in melanoma patients expressing mutations in KIT. *Br J Cancer* 102, 1219-1223 (2010)
39. Alysheva SN, Iyevleva AG, Efimova NV, Mokhina YB, Sabirova FA, Ivantsov AO, et al. KIT mutations in Russian patients with mucosal melanoma. *Melanoma Res* 21, 555-559 (2011)
40. Kong Y, Si L, Zhu Y, Xu X, Corless CL, Flaherty KT, et al. Large-scale analysis of KIT aberrations in Chinese patients with melanoma. *Clin Cancer Res* 17, 1684-1691 (2011)
41. Furney SJ, Turajlic S, Stamp G, Nohadani M, Carlisle A, Thomas JM, et al. Genome sequencing of mucosal melanomas reveals that they are driven by distinct mechanisms from cutaneous melanoma. *J Pathol* 230, 261-269 (2013)
42. Hodi FS, Corless CL, Giobbie-Hurder A, Fletcher JA, Zhu M, Marino-Enriquez A, et al. Imatinib for melanomas harboring mutationally activated or amplified KIT arising on mucosal, acral, and chronically sun-damaged skin. *J Clin Oncol* 31, 3182-3190 (2013)
43. Aulmann S, Sinn HP, Penzel R, Gilks CB, Schott S, Hassel JC, et al. Comparison of molecular abnormalities in vulvar and vaginal melanomas. *Mod Pathol* 27, 1386-1393 (2014)
44. Lyu J, Song Z, Chen J, Shepard MJ, Song H, Ren G, et al. Whole-exome sequencing of oral mucosal melanoma reveals mutational profile and therapeutic targets. *J Pathol* 244, 358-366 (2018)
45. Ma X, Wu Y, Zhang T, Song H, Jv H, Guo W, et al. The clinical significance of *c-Kit* mutations in metastatic oral mucosal melanoma in China. *Oncotarget* 8, 82661-82673 (2017)
46. Hept MV, Roesch A, Weide B, Gutzmer R, Meier F, Loquai C, et al. Prognostic factors and treatment outcomes in 444 patients with mucosal melanoma. *Eur J Cancer* 81, 36-44 (2017)
47. Iida Y, Salomon MP, Hata K, Tran K, Ohe S, Griffiths CF, et al. Predominance of triple wild-type and IGF2R mutations in mucosal melanomas. *BMC Cancer* 18, 1054 (2018)
48. Parish AJ, Nguyen V, Goodman AM, Murugesan K, Frampton GM, Kurzrock R. GNAS, GNAQ, and GNA11 alterations in patients with diverse cancers. *Cancer* 124, 4080-4089 (2018)
49. Van Raamsdonk CD, Griewank KG, Crosby MB, Garrido MC, Vemula S, Wiesner T, et al. Mutations in GNA11 in uveal melanoma. *N Engl J Med* 363, 2191-2199 (2010)
50. Stahl JM, Cheung M, Sharma A, Trivedi NR, Shanmugam S, Robertson GP. Loss of PTEN promotes tumor development in malignant melanoma. *Cancer Res* 63, 2881-2890 (2003)
51. Shull AY, Latham-Schwark A, Ramasamy P, Leskoske K, Oroian D, Birtwistle MR, et al. Novel somatic mutations to PI3K pathway genes in metastatic melanoma. *PLoS One* 7, e43369 (2012)
52. Olivier M, Hollstein M, Hainaut P. TP53 mutations in human cancers: origins, consequences, and clinical use. *Cold Spring Harb Perspect Biol* 2, a001008 (2010)
53. Hocker T, Tsao H. Ultraviolet radiation and melanoma: a systemic review and analysis of reported sequence variants. *Hum Mutat* 28, 588 (2007)
54. Shangary S, Wang S. Targeting the MDM2-p53 interaction for cancer therapy. *Clin Cancer Res* 14, 5318-5324 (2008)



55. Clevers H, Nusse R. Wnt/ $\beta$ -catenin signaling and disease. *Cell* 149, 1192-1205 (2012)
56. Polakis P. Wnt signaling in cancer. *Cold Spring Harb Perspect Biol* 4, a008052 (2012)
57. Reifemberger J, Knobbe CB, Wolter M, Blaschke B, Schulte KW, Pietsch T, et al. Molecular genetic analysis of malignant melanomas for aberrations of the WNT signaling pathway genes CTNNB1, APC, ICAT and BTRC. *Int J Cancer* 100, 549-556 (2002)
58. Kim G, Kurnit KC, Djordjevic B, Singh C, Munsell MF, Wang WL et al. Nuclear  $\beta$ -catenin localization and mutation of the CTNNB1 gene: a context-dependent association. *Mod Pathol* 31, 1553-1559 (2018)
59. Gao C, Wang Y, Broadus R, Sun L, Xue F, Zhang W. Exon 3 mutations of CTNNB1 drive tumorigenesis: a review. *Oncotarget* 9, 5492-5508 (2017)
60. Lasota J, Kowalik A, Felisiak-Golabek A, Zięba S, Waloszczyk P, Masiuk M, et al. Primary malignant melanoma of esophagus: clinicopathologic characterization of 20 cases including molecular genetic profiling of 15 tumors. *Mod Pathol* 32, 957-966 (2019)
61. Harbour JW, Roberson ED, Anbunathan H, et al. Recurrent mutations at codon 625 of the splicing factor SF3B1 in uveal melanoma. *Nat Genet* 45, 133-135 (2013)
62. Kong Y, Krauthammer M, Halaban R. Rare SF3B1 R625 mutations in cutaneous melanoma. *Melanoma Res* 24, 332-334 (2014)
63. Pollak MN, Schernhammer ES, Hankinson SE. Insulin-like growth factors and neoplasia. *Nat Rev Cancer* 4, 505-518 (2004)
64. Liu S, Meric-Bernstam F, Parinyanitikul N, Wang B, Eterovic AK, Zheng X, et al. Functional consequence of the MET-T1010I polymorphism in breast cancer. *Oncotarget* 6, 2604-2614 (2015)
65. Lawrence RE, Salgia R. MET molecular mechanisms and therapies in lung cancer. *Cell Adh Migr* 4, 146-152 (2010)
66. Huang KL, Mashl RJ, Wu Y, Ritter DI, Wang J, Oh C, et al. Pathogenic Germline Variants in 10,389 Adult Cancers. *Cell* 173, 355-370 (2018)
67. Yuan X, Larsson C, Xu D. Mechanisms underlying the activation of TERT transcription and telomerase activity in human cancer: old actors and new players. *Oncogene* 38, 6172-6183 (2019)
68. Stransky N, Cerami E, Schalm S, Kim JL, Lengauer C. The landscape of kinase fusions in cancer. *Nat Commun* 5, 4846 (2014)
69. Delespaul L, Lesluyes T, Pérot G, Brulard C, Lartigue L, Baud J, et al. Recurrent TRIO Fusion in Nontranslocation-Related Sarcomas. *Clin Cancer Res* 23, 857-867 (2017)
70. Karlsson J, Lilljebjörn H, Holmquist Mengelbier L, Valind A, Rissler M, et al. Activation of human telomerase reverse transcriptase through gene fusion in clear cell sarcoma of the kidney. *Cancer Lett* 357, 498-501 (2015)
71. Juratli TA, Silverman IM, Shankar GM, Tummala SS, Ely HA, Christiansen JH, et al. TERT rearrangements to identify a subset of aggressive meningiomas. *J Clin Oncol* 36 (Suppl 15), e14028 (2018)
72. Kruslin B, Gatalica Z, Hes O, Xiu J, Florento E, Swensen J. TERT gene fusions characterize a subset of metastatic Leydig cell tumours. *Ann Oncol* 30 (Suppl 5), 981P (2019)
73. Wiesner T, He J, Yelensky R, Esteve-Puig R, Botton T, Yeh I, et al. Kinase fusions are frequent in Spitz tumours and spitzoid melanomas. *Nat Commun* 5, 3116 (2014)
74. Ross JS, Wang K, Chmielecki J, Gay L, Johnson A, Chudnovsky J, et al. The distribution of BRAF gene fusions in solid tumors and response to targeted therapy. *Int J Cancer* 138, 881-890 (2016)
75. Kim HS, Jung M, Kang HN, Kim H, Park CW, Kim SM, et al. Oncogenic BRAF fusions in mucosal melanomas activate the MAPK pathway and are sensitive to MEK/PI3K inhibition or MEK/CDK4/6 inhibition. *Oncogene* 36, 3334-3345 (2017)
76. Lee J, Lee J, Hong SD, Jang KT, Lee SJ. FGFR3-TACC3: a novel gene fusion in malignant melanoma. *Preci Future Med* 2, 71-75 (2018)
77. Bahrami A, Lee S, Wu G, Kerstetter J, Rahvar M, Li X, et al. Pigment-Synthesizing Melanocytic Neoplasm With Protein Kinase C Alpha (PRKCA) Fusion. *JAMA Dermatol* 152, 318-322 (2016)
78. Yeh I, Jorgenson E, Shen L, Xu M, North JP, Shain AH, et al. Targeted Genomic Profiling of Acral Melanoma. *J Natl Cancer Inst* 111, 1068-1077 (2019)
79. Singh S, Qin F, Kumar S, Elfman J, Lin E, Pham LP, et al. The landscape of chimeric RNAs in non-diseased tissues and cells. *Nucleic Acids Res* 48, 1764-1778 (2020)
80. Zhang Y, Gong M, Yuan H, Park HG, Frierson HF, Li H. Chimeric transcript generated by cis-splicing of adjacent genes regulates prostate cancer cell proliferation. *Cancer Discov* 2, 598-607 (2012)

## AUTHOR CONTRIBUTIONS

Conception and design: MC, JL, MM Case selection, acquisition of clinical data: AA, WB, MD, ID, AH, SI, El-S, HK, JK, JL, MM, MM, MM, RP, MP-S, AS, ST, LDRT, Immunohistochemistry: MK, JL, YL, MM, MN, Molecular genetics: MC, KH, AK, KK, AK, JL, MS, BW, Writing, review, and/or revision of the manuscript: MC, AK, JL, MM, LDRT, BW, Study supervision: JL, MM.

## FUNDING

Federal Government, National Cancer Institute.

## COMPETING INTERESTS

The authors declare no competing interests.

## ETHICAL APPROVAL AND CONSENT TO PARTICIPATE

Data/specimens used in this study have been de-identified by contributors prior to the investigation.

## ADDITIONAL INFORMATION

**Supplementary information** The online version contains supplementary material available at <https://doi.org/10.1038/s41379-022-01122-7>.

**Correspondence** and requests for materials should be addressed to Jerzy Lasota.

**Reprints and permission information** is available at <http://www.nature.com/reprints>

**Publisher's note** Springer Nature remains neutral with regard to jurisdictional claims in published maps and institutional affiliations.

Springer Nature or its licensor holds exclusive rights to this article under a publishing agreement with the author(s) or other rightsholder(s); author self-archiving of the accepted manuscript version of this article is solely governed by the terms of such publishing agreement and applicable law.