Modern Pathology (2020) 33:2269–2279
https://doi.org/10.1038/s41379-020-0588-y

ARTICLE

Molecular characterization of diffuse malignant peritoneal mesothelioma

Yin P. Hung[1,2] · Fei Dong[1] · Matthew Torre[1] · Christopher P. Crum[1] · Raphael Bueno[3] · Lucian R. Chirieac[1]

Received: 31 March 2020 / Revised: 23 May 2020 / Accepted: 24 May 2020 / Published online: 5 June 2020

Abstract

Malignant peritoneal mesothelioma is a rare aggressive tumor that arises from the peritoneal lining. While recurrent *BAP1* mutations have been identified in a subset of mesotheliomas, molecular characteristics of peritoneal mesotheliomas, including those lacking *BAP1* alterations, remain poorly understood. Using targeted next-generation sequencing, we examined the molecular features of 26 diffuse malignant peritoneal mesotheliomas. As part of an exploratory analysis, we analyzed an additional localized peritoneal mesothelioma and one well-differentiated papillary mesothelioma with invasive foci. Genomic characterization identified categories of diffuse malignant peritoneal mesotheliomas: The first group included 18 (69%) tumors with recurrent *BAP1* alterations, with eight (31%) having more than one *BAP1* alterations, and concomitant alterations in *PBRM1* (46%) and *SETD2* (35%). All tumors with complete loss of BAP1 expression by immunohistochemistry harbored *BAP1* molecular alterations. *PBRM1* alterations were significantly enriched in the *BAP1*-altered cohort. Frequent copy number loss *of BAP1*, *ARID1B*, *PRDM1, PBRM1*, *SETD2, NF2*, and *CDKN2A* was noted. The second group included eight (31%) *BAP1*-wild-type tumors: two with *TP53* mutations, one with a *TRAF7* activating mutation, one with a *SUZ12* inactivating mutation, and three with *ALK* rearrangements that we previously published. One *TP53*-mutant biphasic mesothelioma showed evidence of genomic near-haploidization showing loss of heterozygosity of all chromosomes except 5, 7, 16, and 20. The localized peritoneal mesothelioma harbored a nonsense *CHEK2* mutation, and the well-differentiated papillary mesothelioma with invasive foci harbored no reportable variants. In conclusion, we described the genetic categories of diffuse malignant peritoneal mesotheliomas, with *BAP1*-mutant and *BAP1*-wild-type groups. Our findings implicated DNA repair, epigenetics, and cell cycle regulation in the pathogenesis of peritoneal mesotheliomas, with identification of potential therapeutic targets.

Introduction

Malignant peritoneal mesothelioma is rare, with ~300 new patients annually in the United States, and accounts for ~10% of all malignant mesotheliomas (the remainder primarily pleural in origin) [1–3]. Peritoneal mesothelioma typically involves men over 50 years of age, women with a wide age range, and rarely adolescents and children [4–8]. The presentation is often diffuse, although exceptional cases of localized peritoneal mesothelioma with no evidence of diffuse serosal spread have been reported [9]. While the prognosis of malignant mesothelioma is generally dismal, with a median survival of 2–4 years despite multimodality treatment [10, 11], some patients show a protracted clinical course [4, 5, 7]. Risk factors for the development of peritoneal mesothelioma include asbestos exposure (albeit with a weaker association than its pleural counterpart) [12], exposure to non-asbestos mineral fibers

Supplementary information The online version of this article (https://doi.org/10.1038/s41379-020-0588-y) contains supplementary material, which is available to authorized users.

✉ Yin P. Hung
yphung@mgh.harvard.edu

✉ Lucian R. Chirieac
lchirieac@bwh.harvard.edu

[1] Department of Pathology, Brigham and Women's Hospital and Harvard Medical School, Boston, MA, USA

[2] Department of Pathology, Massachusetts General Hospital and Harvard Medical School, Boston, MA, USA

[3] Department of Surgery, Brigham and Women's Hospital and Harvard Medical School, Boston, MA, USA

[13, 14], therapeutic radiation for a prior malignancy, in the setting of chronic inflammatory conditions [15, 16], and in the context of germline *BAP1* inactivation syndrome or other germline mutations [17–20]. Nonetheless, the pathogenesis of peritoneal mesothelioma in many patients, particularly those with no known risk factors, remains unclear.

Recurrent mutations in tumor suppressors and epigenetic regulators, including *BAP1*, *NF2*, *SETD2*, and *TP53*, have been identified by genomic profiling studies collectively in over 900 pleural mesotheliomas [21–28] and 129 peritoneal mesotheliomas analyzed to date [20, 24, 25, 29–47] (only 61 tumors had clinicopathologic information; Table 1). In particular, recurrent somatic and/or germline *BAP1* mutations have been noted in 50–70% of both pleural and peritoneal mesotheliomas [12, 48–54]. Aside from *BAP1*, other rare distinct genetic alterations reported in a subset of diffuse malignant peritoneal mesothelioma include *EWSR1-YY1* fusion [55], *EWSR1-ATF1* and *FUS-ATF1* fusions [36], and *ALK* rearrangements [38, 40, 44, 56, 57]. However, molecular features of diffuse malignant peritoneal mesothelioma, including those lacking *BAP1* alterations, and other mesothelioma variants such as localized peritoneal mesothelioma remain poorly understood.

Table 1 Summary of prior published next-generation or other high-throughput sequencing studies of diffuse malignant peritoneal mesotheliomas and this study.

Year	Reference	Number of patients (histotype)	Types of samples	Sequencing methods (number of genes)	Genes with alterations identified
2015	Alakus et al. [29][a]	7 (all E)[b]	FFPE tumor & blood	WES	*BAP1, PBRM1*
2015	Chao et al. [30]	1 (E)	FFPE tumor & blood	NGS (48)	*TP53* (germline)
2015	Sheffield et al. [31]	2 (all B)	FF/FFPE tumor & blood	WGS, RNA expression profile	*NF2, TP53, CDKN2A, LATS2, CNTNAP3B*
2016	Kato et al. [24][a]	11 (NR)	FFPE tumor	NGS (182–236)	*BAP1, NF2, CDKN2A, TP53*, others
2016	Lai et al. [32]	1 (E)	FF tumor & blood	NGS (725)	*BAP1*, others
2016	Maki-Nevala et al. [33][a]	2 (NR)	FFPE tumor	Exome/deep seq	
2016	Ugurluer et al. [34]	4 (all E)	FFPE tumor	NGS (236)	*BAP1, SETD2, NF2, KDM6A*, others
2016	Vanni et al. [35]	1 (E)	FFPE tumor & blood	WES	*BAP1, SETD2, WT1*
2017	Desmeules et al. [36]	1 (E)[c]	FFPE tumor	NGS	*EWSR1-ATF1/FUS-ATF1*
2017	Joseph et al. [37]	13 (12E, 1B)	FFPE tumor & non-tumoral tissue	NGS (510)	*BAP1, NF2, SETD2, DDX3X*, others
2017	Ross et al. [38][a]	2 (NR)	FFPE tumor	NGS	*ALK* rearrangements
2017	Zehir et al. [25][a]	18 (NR)	FFPE tumor & blood	NGS (341–410)	*BAP1, TRAF7, NF2*, others
2018	Bochtler et al. [39]	1 (E)	FFPE tumor	NGS (35–143)	*BAP1* (germline)
2018	Hung et al. [40]	9 (7E, 2B)	FFPE tumor	NGS (275–298)	*ALK* rearrangements; *BAP1, NF2, SETD2*
2018	Loffler et al. [41]	1 (E)	NR	NGS (336)	*PTEN* (germline)
2018	Panou et al. [20]	17 (all E)[d]	FFPE tumor & blood	NGS (147–315)	*BAP1, NF2, SETD2, PBRM1*, others
2019	Belfiore et al. [42][a]	16 (all E)[e]	FFPE tumor & non-tumoral tissue	NGS (409)	*BAP1, NF2*
2019	Lund-Andersen et al. [43]	1 (NR)	FF tumor & blood	WES, RNA-seq	*BAP1, PBRM1, LATS1, LATS2*, others
2019	Ruschoff et al. [44]	1 (E)	FFPE tumor	NGS (305)	*STRN-ALK* fusion
2019	Shrestha et al. [45]	18 (all E)[f]	FF tumor & blood/ benign tissue	WES, WTS	*BAP1, KANSL1, PBRM1, SETD2*, others
2019	Smith-Hannah et al. [46]	1 (E)	FFPE tumor	NGS	*VHL*
2020	Glass et al. [47]	1 (B)	FFPE tumor	NGS (447)	*NF2* (germline and possible somatic second-hit), *BAP1, PBRM1, PTEN*
2020	This study	26 (23E, 3B)[g]	FFPE tumor	NGS (275–447)	*BAP1, PBRM1, SETD2*, others; *SUZ12*; *TRAF7*; genomic near-haploidization

B biphasic, *E* epithelioid, *FF* fresh-frozen, *FFPE* formalin-fixed paraffin-embedded, *NGS* next-generation sequencing, *NR* not reported, *S* sarcomatoid, *WES* whole-exome sequencing, *WGS* whole-genome sequencing, *WTS* whole-transcriptome sequencing.

[a]Unknown clinical outcome and/or histologic type.

[b]Only 7 of 12 cases examined by NGS.

[c]One of three peritoneal cases examined by NGS.

[d]17 of 44 peritoneal cases examined on tumor samples by NGS.

[e]16 of 22 cases examined by NGS.

[f]Outcome available in 6 of 18 patients.

[g]Including nine cases published in Hung et al. [40].

In this study, using targeted next-generation sequencing we examined the genomic characteristics of 26 diffuse malignant peritoneal mesotheliomas (including nine tumors previously published) [40]. In addition to *BAP1* mutations, we identified recurrent alterations in other DNA repair, chromatin, and cell cycle regulators. We also identified a diffuse malignant peritoneal mesothelioma with evidence of genomic near-haploidization, highlighting the genetic heterogeneity of peritoneal mesothelioma and implicating these processes in its pathogenesis and potential therapeutic targets. As part of an exploratory analysis, we analyzed one localized peritoneal mesothelioma and one well-differentiated papillary mesothelioma with invasive foci.

Materials and methods

After approval by the Institutional Review Board, cases were retrieved from the surgical pathology and consultation files of Brigham and Women's Hospital, Boston, MA. From a cohort of 88 patients with primary diffuse malignant peritoneal mesotheliomas diagnosed in 2005–2015, we previously identified three tumors with *ALK* rearrangements as selected by ALK immunohistochemistry screening and confirmatory sequencing [40] and characterized the genetic alterations of nine tumors. In this study, we identified 17 additional patient samples of diffuse malignant peritoneal mesothelioma with sufficient tissue for targeted next-generation sequencing. In addition, we analyzed a localized peritoneal mesothelioma and a well-differentiated papillary mesothelioma with invasive foci. Tumors were classified into epithelioid, biphasic, and sarcomatoid types according to the WHO criteria [1]. Evaluation for asbestos exposure and the presence of pleural plaques was based on the medical and radiologic records.

Immunohistochemistry was performed on 4-micron-thick formalin-fixed paraffin-embedded whole-tissue sections for the following antibodies (clone, dilution, antigen retrieval method, vendor): BAP1 (C4, 1:30, citrate buffer pressure cook, Santa Cruz Biotechnology, Santa Cruz, CA), calretinin (polyclonal, 1:200, citrate buffer pressure cook, Life Technologies, Carlsbad, CA), D2-40 (D2-40, 1:100, no retrieval, Biolegend, Dedham, MA), and WT1 (6F-H2, 1:50, citrate buffer pressure cook, Dako, Carpinteria, CA). BAP1 expression was scored as complete loss when the tumor cells showed >90% reduction in nuclear staining. Electron microscopy was performed in the localized peritoneal mesothelioma as previously described [58]. Fluorescence in situ hybridization testing for loss of 9p (*CDKN2A*) and 22q (*NF2*) was performed in select cases as previously described [59]. Overall survival was defined as the time of pathologic diagnosis to the time of death from any cause or to the time of last clinical follow-up, at which point the survival data were censored; survival data were analyzed using univariate Cox regression analysis. Statistical analysis of the categorical and numerical data was performed using Fisher's exact tests and unpaired *t* tests, respectively, via GraphPad InStat version 3.1 (LaJolla, CA), with a significant p value threshold of < 0.05 and Bonferroni correction applied in multiple statistical comparisons.

For targeted next-generation sequencing, DNA (at least 50 ng/μl) extracted from formalin-fixed paraffin-embedded whole-tissue sections was hybridized to capture probes (Agilent SureSelect; Santa Clara, CA), followed by sequencing using Illumina HiSeq 2500 (San Diego, CA). Over the study period, three versions of the in-house sequencing panel were used, targeting 275 genes covering 757787 base-pairs in 3 (12%) cases (#17–19), 298 genes covering 831033 base-pairs in 6 (23%) cases (#9, #11–12, #23–25), and 447 genes covering 1315708 base-pairs in 17 (65%) cases (#1–8, #10, #13–16, #20–22, and #26) of diffuse malignant peritoneal mesothelioma, one localized peritoneal mesothelioma, and one well-differentiated papillary mesothelioma with invasive foci; the protocol was previously published [60, 61], and the complete gene lists of the 275-, 298-, and 447-gene panels were in Supplementary Table 1. Single-nucleotide variant analysis was restricted to pathogenic alterations in tumor suppressor genes and oncogenes as well as loss-of-function variants (nonsense, frameshift, splice site variants, and structural/rearrangement). Single-nucleotide variants were excluded from analysis if synonymous, harboring a minor variant allele frequency of >0.1% in the Exome Sequencing Project database (University of Washington, Seattle, WA), or suspected germline based on the allele frequencies considering the tumor percentage and associated copy number changes; however, single-nucleotide variants were rescued if listed in the Catalogue of Somatic Mutations in Cancer (COSMIC) database (Wellcome Trust Sanger Institute, United Kingdom). Copy number alterations were interpreted based on the copy number VisCap plots in $\log_2$ ratio values relative to the genome baseline.

Results

Clinicopathologic characteristics of peritoneal mesotheliomas

Figure 1 summarizes the clinicopathologic and molecular characteristics of 28 peritoneal mesotheliomas included in the study: 26 diffuse malignant peritoneal mesotheliomas (23 epithelioid and 3 biphasic histologies), one localized peritoneal mesothelioma, and one well-differentiated papillary mesothelioma with invasive foci.

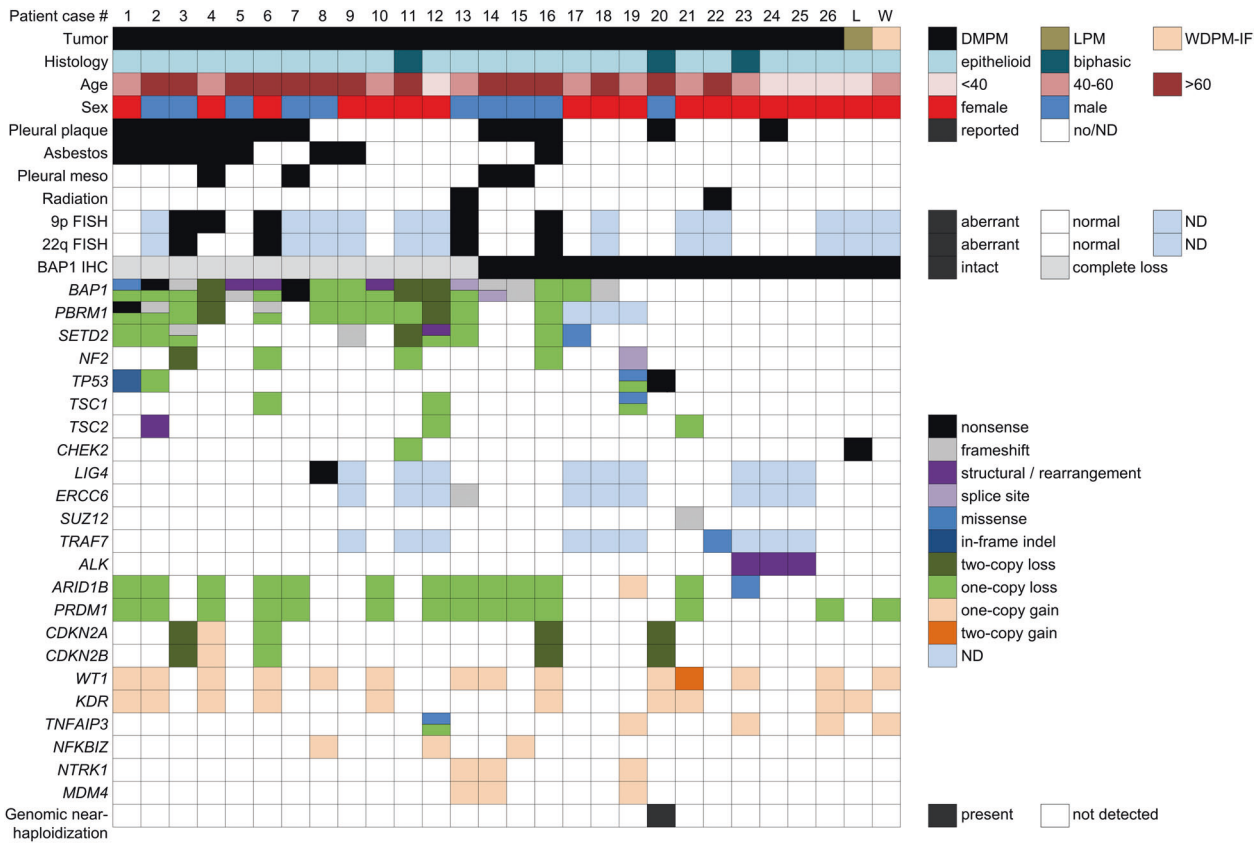

Fig. 1 Landscape of clinicopathologic and molecular features of peritoneal mesotheliomas in this study. Heatmap illustrating the characteristics of 28 peritoneal mesotheliomas, including 26 diffuse malignant peritoneal mesotheliomas (DMPM; patients #1–26), one localized peritoneal mesothelioma (LPM; patient #L) and one well-differentiated papillary mesothelioma with invasive foci (WDPM-IF; patient #W). Patients #9, #11–12, #17–19, and #23–25 were previously published [40]. ND not determined.

The diffuse malignant peritoneal mesothelioma cohort included 21 surgical resections and 5 excisional biopsies from 16 women and 10 men, with a median age of 61 years (range 17–81 years). Two patients had received therapeutic radiation to the abdomen (one for ovarian cancer 28 years prior and one for non-Hodgkin lymphoma 37 years prior to the mesothelioma diagnosis). History of asbestos exposure was documented in eight (31%) patients. Pleural plaques were noted radiographically in 12 (46%) patients, including four with subsequent development of diffuse malignant pleural mesothelioma. Of the 24 diffuse malignant peritoneal mesothelioma patients with known clinical follow-up (0.3 to 12.7 [median 3.0] years), the median overall survival was 4.1 years. This cohort included 23 (88%) epithelioid mesotheliomas (Figs. 2a, 3a–c) and 3 (12%) biphasic mesotheliomas (Fig. 3d). The three patients with biphasic mesothelioma were two women and one man, aged 52, 68, and 73 years, with a median overall survival of 1.7 years (vs 5.9 years in those with epithelioid mesothelioma; $p = 0.26$). By immunohistochemistry, tumor cells expressed calretinin, WT1, and D2–40 in 22 of 22 (100%), 20 of 20 (100%), and 13 of 17 (76%) cases, respectively. Immunohistochemistry for BAP1 showed complete loss of expression in 13 (50%) tumors (Fig. 2b), including 12 (52%) epithelioid tumors and 1 (33%) biphasic tumor. By cytogenetics and/or fluorescence in situ hybridization testing, loss of chromosomal region 9p (*CDKN2A*) and 22q (*NF2*) was noted in 5 of 16 (31%) and 4 of 16 (25%) tumors, respectively, all of epithelioid histotype.

The localized peritoneal mesothelioma involved only the fallopian tube as a solitary pedunculated mass in a woman younger than 40 years, with no other masses identified in the peritoneum radiologically or intraoperatively. The patient was alive with no evidence of disease 13.2 years after the initial diagnosis. Histologically, the tumor was characterized by tubules of epithelioid tumor cells with variably prominent nucleoli (Supplementary Fig. 1A, B), indistinguishable from that of diffuse malignant peritoneal mesothelioma. By immunohistochemistry, tumor cells were diffusely positive for WT1 (Supplementary Fig. 1C) and calretinin (Supplementary Fig. 1D), negative for D2–40, and showed intact BAP1 expression (Supplementary Fig. 1E). By transmission electron microscopy, tumor cells demonstrated prominent intercellular junctions and microvilli with an average thickness of 75 nm and a length-to-width ratio of 13:1,

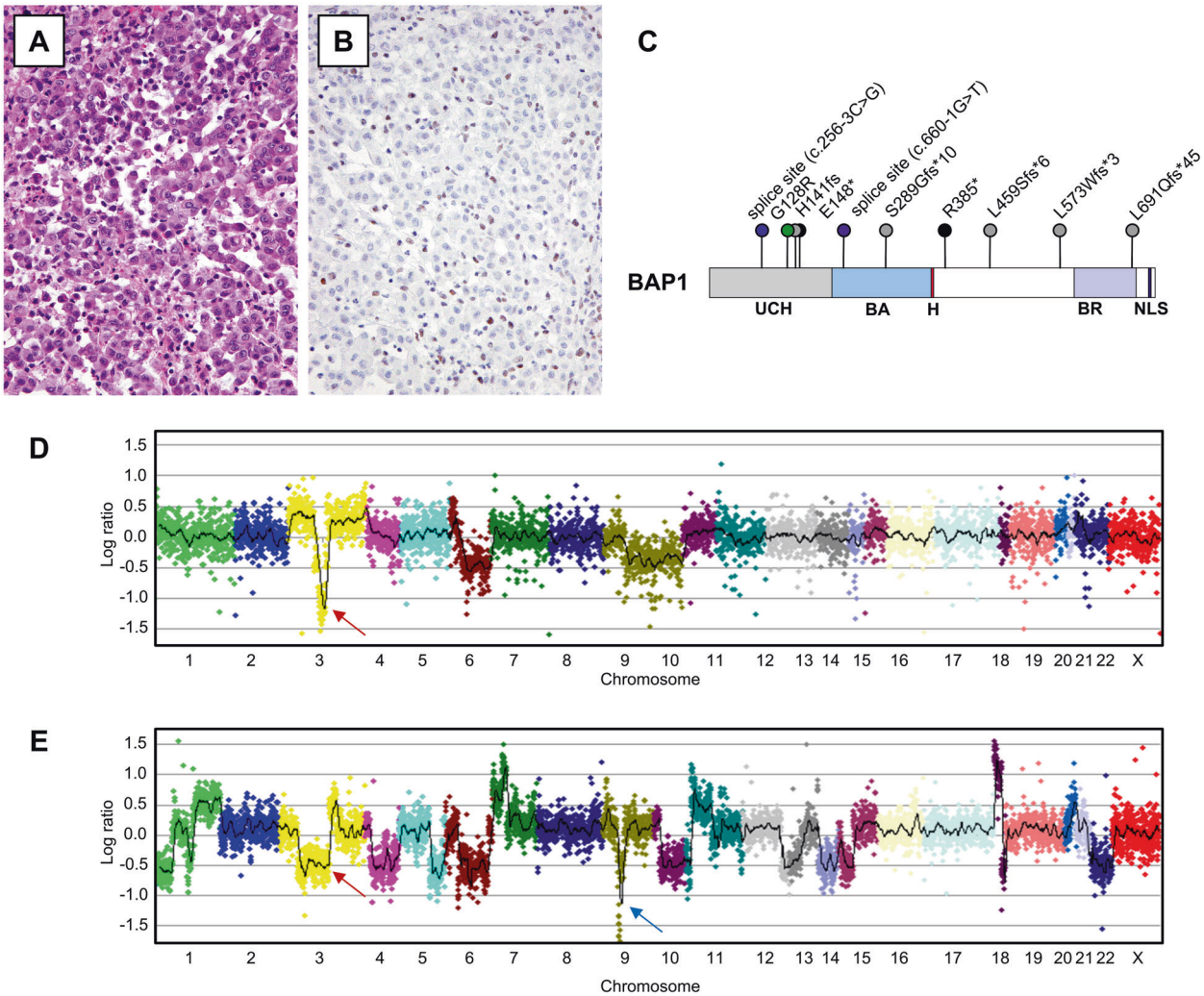

Fig. 2 Diffuse malignant peritoneal mesothelioma with *BAP1* alterations **a** Peritoneal mesothelioma (patient #7) with *BAP1* nonsense mutation showed **b** complete loss of BAP1 expression by immunohistochemistry. **c** Schematics illustrating the locations of mutations in *BAP1* identified in our study (patients #1–3, #5, #7, #13–15, #18; excluding rearrangements/deletion). UCH: ubiquitin carboxy-terminal hydroxylase domain. BA: BARD1-binding domain. BR: BRCA1-binding domain. H: HCF1-binding domain. NLS: nuclear localization sequence. **d** Copy number VisCap plot of peritoneal mesothelioma (patient #12) with two-copy loss of *BAP1* at 3p21 (red arrow). **e** Copy number VisCap plot of peritoneal mesothelioma (patient #16) with one-copy loss of *BAP1* at 3p21 (red arrow) and two-copy loss of *CDKN2A* at 9p21 (blue arrow).

characteristic of mesothelial differentiation (Supplementary Fig. 1F).

The well-differentiated papillary mesothelioma with invasive foci presented in a woman with recurrent well-differentiated papillary mesothelioma and multiple surgical debulking procedures, including most recently at 12.7 years after the initial diagnosis. Histologically, consistent with the description by Churg et al. [62], the well-differentiated papillary mesothelioma with invasive foci was characterized by papillae with central myxoid-to-edematous core covered by a single layer of epithelioid mesothelial cells (Supplementary Fig. 2A); the single-layer arrangement could be obscured by compression of the papillae (Supplementary Fig. 2B). Tumor cells were positive for WT1 (Supplementary Fig. 2C) and calretinin (Supplementary Fig. 2D), with intact BAP1 expression (Supplementary Fig. 2E). Immunohistochemistry for keratin cocktail AE1/AE3 (Supplementary Fig. 2F) highlighted the compressed papillae.

Molecular characteristics of peritoneal mesotheliomas

Among the 26 diffuse malignant peritoneal mesotheliomas, *BAP1* alterations were identified in 18 (69%) tumors (Fig. 1), including 8 (31%) harboring more than one *BAP1* alterations each. A total of 26 *BAP1* alterations detected included five frameshift mutations, two nonsense mutations, two splice site mutations, one missense mutation (Fig. 2c

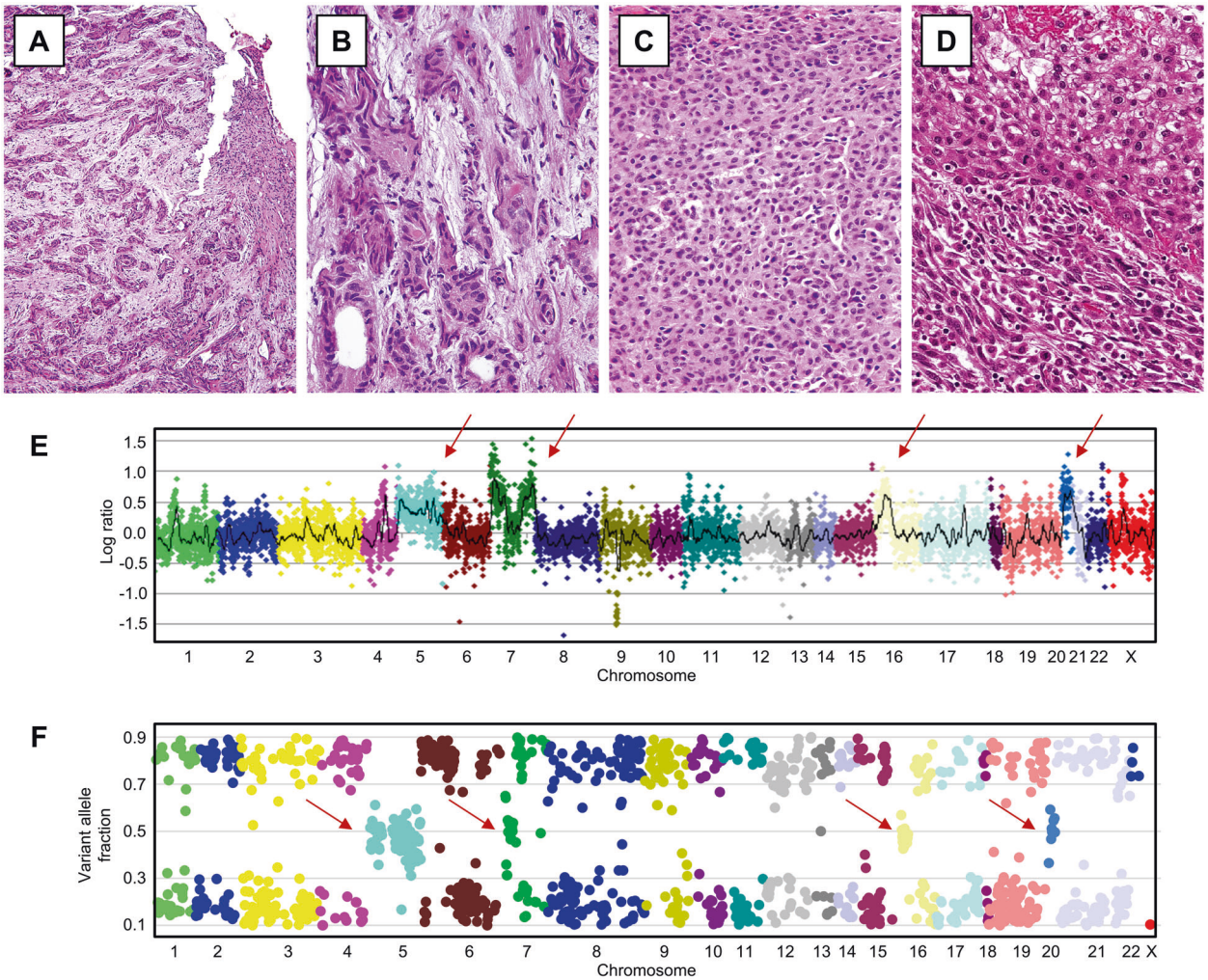

Fig. 3 Diffuse malignant peritoneal mesothelioma lacking *BAP1* alterations **a**, **b** Histologic features of *BAP1*-wild-type peritoneal mesothelioma (patient #22) with *TRAF7* activating mutation, characterized by tubules and nests of epithelioid tumor cells. **c** Histologic features of *BAP1*-wild-type peritoneal mesothelioma (patient #21) with *SUZ12* inactivating mutation and epithelioid histology. **d** Histologic features of *BAP1*-wild-type peritoneal mesothelioma (patient #20) with *TP53* nonsense mutation and biphasic histology, showing epithelioid (top) and sarcomatoid (bottom) components. **e** Copy number VisCap plot and **f** a plot of variant allele fraction in the targeted genome of this biphasic mesothelioma showed extensive loss of heterozygosity in all chromosomes except 5, 7, 16, and 20 (red arrows).

and Supplementary Table 2), three structural rearrangements/deletion (deletion of 23 base-pairs, inactivating rearrangement with an intronic region in chromosome 9, and inactivating rearrangement with a pseudogene in chromosome 10), and 13 copy number loss (monoallelic in ten, biallelic in three; including six with concurrent *BAP1* mutations). Complete loss of BAP1 protein expression was significantly associated with the presence of *BAP1* genomic alterations ($p = 0.001$), and all tumors with complete loss of BAP1 expression by immunohistochemistry harbored *BAP1* molecular alterations. The presence of *BAP1* genomic alterations (single-nucleotide, copy number, and/or structural alterations) in patients with diffuse malignant peritoneal mesothelioma was associated with older age at the time of diagnosis and worse overall survival in the entire cohort with both epithelioid and biphasic histologies (Supplementary Table 3) and in those with epithelioid histology only (Supplementary Table 4). No significant associations were observed regarding the presence of *BAP1* molecular alterations with the presence of pleural plaques or asbestos exposure, history of prior radiation, size of largest tumor nodule, histologic type, chromosomal 9p/22q status by fluorescence in situ hybridization, and treatment received in the entire cohort of diffuse malignant peritoneal mesothelioma patients (Supplementary Table 3) and in those with epithelioid histology only (Supplementary Table 4).

Recurrent alterations in other tumor suppressors and epigenetic regulators were noted in diffuse malignant peritoneal mesotheliomas (Fig. 1). *PBRM1* alterations were significantly enriched in the *BAP1*-altered cohort ($p = 0.001$; Supplementary Table 5); though this association did not reach significance in tumors with epithelioid histology only (Table 2). Single-nucleotide variants and/or copy

Table 2 Summary of molecular alterations in epithelioid-type diffuse malignant peritoneal mesothelioma.

Gene with alterations	Total epithelioid cohort ($n = 23$)		*BAP1*-altered ($n = 17$)		*BAP1*-wild-type ($n = 6$)		
	Number	%	Number	%	Number	%	*p* value
BAP1	17	73.9	17	100.0	0	0.0	
PBRM1[a]	11	55.0	11	73.3	0	0.0	0.008
SETD2	8	34.8	8	47.1	0	0.0	0.058
NF2	4	17.4	3	17.6	1	16.7	1.000
TP53	3	13.0	2	11.8	1	16.7	1.000
TSC1	3	13.0	2	11.8	1	16.7	1.000
TSC2	3	13.0	2	11.8	1	16.7	1.000
LIG4[b]	1	6.3	1	7.7	0	0.0	0.427
ERCC6[b]	1	6.3	1	7.7	0	0.0	0.427
SUZ12	1	4.3	0	0.0	1	16.7	0.261
TRAF7[b]	1	6.3	0	0.0	1	33.3	0.188
ALK	2	8.7	0	0.0	2	33.3	0.059
ARID1B	13	56.5	11	64.7	2	33.3	0.341
PRDM1	13	56.5	11	64.7	2	33.3	0.341
CDKN2A	4	17.4	4	23.5	0	0.0	0.539
CDKN2B	4	17.4	4	23.5	0	0.0	0.539
Genomic near-haploidization	0	0.0	0	0.0	0	0.0	NA

All *p* values statistically non-significant (Bonferroni corrected *p* value threshold 0.05/16 = 0.003).

[a]Data available in 20 of 23 tumors.

[b]Data available in 16 of 23 tumors.

number loss of *PBRM1*, *SETD2*, *NF2*, *TP53*, and *TSC1* were identified in 12 (52%), 9 (35%), 5 (19%), 4 (15%), and 3 (12%) tumors, respectively. Two-copy loss of *BAP1* (Fig. 2d), *CDKN2A*/*CDKN2B* (Fig. 2e), *PBRM1*, *SETD2*, and *NF2* was found in three (12%), three (12%), two (9%), one (4%), and one (4%) tumors, respectively. Copy number gains were noted involving *WT1*, *KDR*, *TNFAIP3*, *NFKBIZ*, *NTRK1*, and *MDM4* in 3–13 (12–50%) tumors. Furthermore, *DNA ligase 4* (*LIG4*) nonsense mutation (p.Y698*) and *excision repair 6* (*ERCC6*) frameshift mutation (p.R1318Gfs*12) were identified in one diffuse malignant peritoneal mesothelioma each.

Of the eight *BAP1*-wild-type diffuse malignant peritoneal mesotheliomas, one epithelioid mesothelioma (Fig. 3a, b) harbored a *TRAF7* activating mutation (p.N520S), and one epithelioid mesothelioma (Fig. 3c) harbored a *SUZ12* frameshift mutation (p.F474Ifs*13). Two tumors harbored pathogenic mutations in *TP53* (p.R196* and p.H214L), including one with concurrent alterations in both *NF2* and *TSC1*. The remainder *TP53*-mutant biphasic mesothelioma (Fig. 3d) showed evidence of genomic near-haploidization with extensive loss of heterozygosity except chromosomes 5 and 20 and parts of chromosomes 7 and 16 (Fig. 3e, f). Three *BAP1*-wild-type diffuse malignant peritoneal mesotheliomas harbored *ALK* gene rearrangements as previously reported [40]. No reportable variants were noted in the remainder *BAP1*-wild-type diffuse malignant peritoneal mesothelioma. *BAP1*-altered and *BAP1*-wild-type diffuse malignant peritoneal mesotheliomas appeared to be histologically similar (Figs. 2a, 3a–d).

The molecular features of the epithelioid diffuse malignant peritoneal mesotheliomas were summarized in Table 2. The three biphasic diffuse malignant peritoneal mesotheliomas included one with two-copy loss of *BAP1* and *SETD2* and one-copy loss of *PBRM1* and *NF2* (patient #11), one *TP53*-mutant with evidence of genomic near-haploidization as aforementioned (patient #20; Fig. 3d–f), and one with *TPM1*-*ALK* fusion as previously published (patient #23) [40].

Both the localized peritoneal mesothelioma and the well-differentiated papillary mesothelioma lacked alterations typical of diffuse malignant peritoneal mesothelioma (Fig. 1). The localized peritoneal mesothelioma (Supplementary Fig. 1) harbored a *CHEK2* nonsense mutation (p.R137*) (Supplementary Table 2). The well-differentiated papillary mesothelioma with invasive foci (Supplementary Fig. 2) harbored one-copy loss of *PRDM1* with a low-copy gain of *WT1* and *TNFAIP3*, but otherwise demonstrated no reportable single-nucleotide variants in this study.

Discussion

Our findings underscored the genetic heterogeneity of diffuse malignant peritoneal mesotheliomas and implicated

DNA repair, epigenetics, and cell cycle regulation in the pathogenesis of malignant peritoneal mesothelioma. Diffuse malignant peritoneal mesotheliomas harbored recurrent alterations, most commonly *BAP1* mutations, followed by mutations or copy number loss in other DNA repair, chromatin, and cell cycle regulators: *PBRM1*, *SETD2*, *NF2*, *ARID1B*, *PRDM1*, and *CDKN2A*, among others. In addition to the *BAP1*-mutant diffuse malignant peritoneal mesotheliomas, we uncovered the genomic alterations of *BAP1*-wild-type tumors, including *TP53* mutations, *TRAF7* activating mutation, *SUZ12* inactivating mutation, *ALK* rearrangements we previously described [40], and one tumor with genomic near-haploidization. Furthermore, while the limited number of biphasic diffuse malignant peritoneal mesotheliomas examined herein precludes definitive evaluation of their molecular differences from epithelioid peritoneal mesotheliomas, this study illustrates the genetic heterogeneity of biphasic peritoneal mesotheliomas, with two-copy loss of *BAP1* and *SETD2*, *TP53* mutation with genomic near-haploidization, and *ALK* rearrangement described in one tumor each. The case of localized peritoneal mesothelioma harbored a nonsense *CHEK2* mutation, whereas the case of well-differentiated papillary mesothelioma with invasive foci harbored no reportable variants; nonetheless, given the exploratory nature of our analysis using single cases, definitive conclusions for molecular differences between diffuse malignant peritoneal mesothelioma and other mesothelial lesions require evaluation using larger cohorts.

This single institutional study represents the largest next-generation sequencing series of diffuse malignant peritoneal mesothelioma to date (Table 1). Overall, certain genetic alterations have been noted in both pleural and peritoneal mesotheliomas with similar prevalence, such as *BAP1* mutations in 50–70% of cases and *NF2* loss in 20–40% of cases [12, 21, 23, 45, 50–54, 63], though other genetic alterations differ between peritoneal and pleural mesotheliomas. Loss of *CDKN2A* appears less frequent in peritoneal mesotheliomas (20–50%) as compared with pleural mesotheliomas (60–70%) [12, 53, 63–66]; this may be related to the stronger association between *CDKN2A* loss and sarcomatoid mesothelioma, preferentially seen in the pleura [23, 59], while sarcomatoid peritoneal mesothelioma is extremely rare [67]. Furthermore, rare diffuse malignant mesotheliomas with *EWSR1-ATF1* and *FUS-ATF1* fusions are primarily peritoneal in location [36]. *ALK* rearrangements characteristic of a small subset of peritoneal mesotheliomas [38, 40, 44, 56, 57] have not been identified in pleural mesotheliomas examined to date [23, 40]. The discovery of *ALK* rearrangements raises the possibility of treatment with ALK inhibitors [44].

Alterations in *BAP1* are a consistent finding across studies of diffuse malignant peritoneal mesothelioma, including our own. *BAP1* mutations, copy number loss, and expression loss were noted in 69%, 77%, and 85% of tumors, respectively, in Joseph et al. [37]; 32%, 42%, and 57% of tumors, respectively, in Leblay et al. [54]; and 28%, 44%, and 44% of tumors, respectively, in Shrestha et al. [45]. Our identification of *BAP1* single-nucleotide/structural variants, copy number loss, and complete expression loss in 42%, 50%, and 50% of cases appeared more in line with the studies by Leblay et al. and Shrestha et al. Patients with diffuse malignant peritoneal mesothelioma that harbored *BAP1* mutation(s) were noted to show better outcome in Leblay et al. [54] but worse overall survival in our study. This discrepancy between Leblay et al. and our study may be due to differences in the cohort baseline characteristics, such as the percentage of patients with *BAP1*-altered tumors being women (21% vs 50%) and the age of patients with *BAP1*-wild-type tumors (median > 60 vs 52). Differences in the prevalence of the somatic vs germline *BAP1* mutations may also contribute, as prolonged survival had been described in mesothelioma patients with germline *BAP1* mutations [68]. Germline *BAP1* mutation status was not available in our study and may explain the different results from Leblay et al. [54].

The identification of mutations in *DNA Ligase 4* (*LIG4*) and *excision repair 6* (*ERCC6*) in diffuse malignant peritoneal mesothelioma and *CHEK2* mutation in a localized peritoneal mesothelioma implicates defective DNA repair in their pathogenesis. Some of these alterations harbor allelic frequencies close to 0.5, raising a possibility that these represent germline alterations; however, definitive interpretation was precluded by our current assay that analyzed tumor samples only. In a study using blood samples from 198 patients with diffuse malignant mesothelioma, germline mutations involving *BAP1*, *BRCA2*, *CHEK2*, *ATM*, *VHL*, and others were identified in 7% of pleural mesothelioma patients and 25% of peritoneal mesothelioma patients [20]. Malignant peritoneal mesothelioma had been reported in an infant with germline *ATM* mutation [69]. Diffuse malignant peritoneal mesothelioma had also been described in a young patient with neurofibromatosis harboring germline *NF2* mutation, with tumor emergence after a "second-hit" somatic inactivation [47]. Collectively, these findings implicate germline and/or somatic mutations in the DNA repair pathway in the development of peritoneal mesotheliomas, including some cases of the *BAP1* wild-type tumors. Identification of DNA repair alterations raises the possibility of treatment with poly ADP-ribose polymerase inhibitors: for example, a clinical trial of using niraparib in tumors including mesothelioma with aberrant DNA repair is ongoing (NCT03207347).

In *BAP1*-wild-type peritoneal mesotheliomas, we identified mutations in *SUZ12*, *TRAF7*, and evidence of genomic near-haploidization in one tumor each. Given the small

number of cases, we could not address the question if these alterations were mutually exclusive of *BAP1* alterations in diffuse malignant peritoneal mesothelioma. Recurrent mutations in *SUZ12*, a component of the Polycomb Repressive Complex 2 (PRC2), lead to loss of downstream Histone 3 lysine 27 trimethylation (H3K27Me3) [70]. Identification of the *SUZ12* mutation in a diffuse malignant peritoneal mesothelioma suggests the importance of chromatin regulation, though seemingly contrary to the prevailing model of targeting PRC2 complex as a therapeutic strategy: BAP1 expression loss with EZH2 overexpression has been noted in 50–70% of malignant mesotheliomas [71, 72], and *BAP1* mutations have been implicated in EZH2-dependent transformation in malignant mesothelioma [73]. In contrast, our finding of *SUZ12* mutation in a *BAP1*-wild-type peritoneal mesothelioma implies that perturbed PRC2 function in either direction—and not necessarily PRC2 activation alone—may be oncogenic in the development of diffuse malignant peritoneal mesothelioma, consistent with published observations in other tumor types [74].

Recurrent activating mutations in *TRAF7*, a component of the nuclear factor kappa B (NF-kB) signaling pathway, have been described in adenomatoid tumors of genital type [75, 76], a subset of well-differentiated papillary mesothelioma of the peritoneum [77], rare diffuse malignant pleural [23] and peritoneal mesotheliomas [25], and a subset of localized pleural mesothelioma [78]. In particular, the *TRAF7* p.N520S mutation noted in one diffuse malignant peritoneal mesothelioma herein has been reported previously in two well-differentiated papillary mesotheliomas [77]. The presence of *TRAF7* mutation alone is thus not entirely specific in the distinction between benign and malignant tumors of mesothelial origin. To date, *TRAF7*-mutant malignant pleural and peritoneal mesotheliomas [23, 25] including in this study all lack *BAP1* mutations, suggesting *TRAF7* activation as one of the *BAP1*-independent mechanisms for the pathogenesis of mesotheliomas and related lesions.

Genomic near-haploidization, characterized by extensive loss of heterozygosity (or copy-number-neutral uniparental disomy secondary to genome endo-reduplication), has been described in 3% of diffuse malignant pleural mesothelioma in the TCGA/ICGC cohorts [26], one localized pleural mesothelioma [78], and one diffuse malignant peritoneal mesothelioma [79]. Notably, chromosomes 5 and 7 were often retained in these near-haploid mesothelial tumors [26, 78, 79], including the *TP53*-mutant biphasic peritoneal mesothelioma described herein; the reason for such preferential chromosomal retention remained unknown.

In conclusion, diffuse malignant peritoneal mesotheliomas harbor recurrent alterations in *BAP1* and other DNA repair, chromatin, and cell cycle regulators, with one tumor showing genomic near-haploidization. Our findings illustrate the genetic diversity of diffuse malignant peritoneal mesothelioma, with implications on their diagnosis and selection of potential therapeutic targets.

Acknowledgements We thank Ms. Mei Zheng and the immunohistochemistry laboratory; Ms. Michele Baltay at the Center for Advanced Molecular Diagnostics, Brigham and Women's Hospital, for technical support.

Compliance with ethical standards

Conflict of interest There is no disclosure from YPH, FD, MT, and CPC. RB has served on the Advisory boards for Myriad, Exosome Diagnostics, and CollaboRx and received support from the National Cancer Institute and investigator-initiated industry grants from Castle Biosciences, Exosome Diagnostics, Genentech-Roche, Gritstone, HTG, Merck, Myriad, Novartis, PamGene, Siemens, Verastem, MedGenome, and Epizyme. LRC undertakes medicolegal work related to mesothelioma. All financial disclosures listed above do not apply to the current study, which is not associated with a specific source of funding.

References

1. Galateau-Salle F, Churg A, Roggli V, Chirieac LR, Attanoos R, Borczuk A, et al. Tumours of the pleura. Mesothelial tumours. In: Travis WD, Brambilla E, Burke A, Marx A, Nicholson AG, editors. *World Health Organization classification of tumors. Pathology and genetics of tumors of the lung, pleura, thymus, and heart*, Vol., 4th edn. IARC Press: Lyon, France, 2015. p156.
2. Moolgavkar SH, Meza R, Turim J. Pleural and peritoneal mesotheliomas in SEER: age effects and temporal trends, 1973–2005. Cancer Causes Control. 2009;20:935–44.
3. Mazurek JM, Syamlal G, Wood JM, Hendricks SA, Weston A. Malignant Mesothelioma Mortality—United States, 1999–2015. MMWR Morb Mortal Wkly Rep. 2017;66:214–8.
4. Geary WA, Mills SE, Frierson HF Jr., Pope TL. Malignant peritoneal mesothelioma in childhood with long-term survival. Am J Clin Pathol. 1991;95:493–8.
5. Kerrigan SA, Turnnir RT, Clement PB, Young RH, Churg A. Diffuse malignant epithelial mesotheliomas of the peritoneum in women: a clinicopathologic study of 25 patients. Cancer. 2002;94:378–85.
6. Moran CA, Albores-Saavedra J, Suster S. Primary peritoneal mesotheliomas in children: a clinicopathological and immunohistochemical study of eight cases. Histopathology. 2008;52:824–30.
7. Thomas A, Chen Y, Yu T, Gill A, Prasad V. Distinctive clinical characteristics of malignant mesothelioma in young patients. Oncotarget. 2015;6:16766–73.
8. Boffetta P. Epidemiology of peritoneal mesothelioma: a review. Ann Oncol. 2007;18:985–90.
9. Allen TC, Cagle PT, Churg AM, Colby TV, Gibbs AR, Hammar SP, et al. Localized malignant mesothelioma. Am J Surg Pathol. 2005;29:866–73.
10. Borczuk AC, Taub RN, Hesdorffer M, Hibshoosh H, Chabot JA, Keohan ML, et al. P16 loss and mitotic activity predict poor survival in patients with peritoneal malignant mesothelioma. Clin Cancer Res. 2005;11:3303–8.

11. Nelson DB, Rice DC, Niu J, Atay S, Vaporciyan AA, Antonoff M, et al. Long-term survival outcomes of cancer-directed surgery for malignant pleural mesothelioma: propensity score matching analysis. J Clin Oncol. 2017;35:3354–62.
12. Chirac P, Maillet D, Lepretre F, Isaac S, Glehen O, Figeac M, et al. Genomic copy number alterations in 33 malignant peritoneal mesothelioma analyzed by comparative genomic hybridization array. Hum Pathol. 2016;55:72–82.
13. Carbone M, Yang H, Pass HI, Krausz T, Testa JR, Gaudino G. BAP1 and cancer. Nat Rev Cancer. 2013;13:153–9.
14. Attanoos RL, Churg A, Galateau-Salle F, Gibbs AR, Roggli VL. Malignant mesothelioma and its non-asbestos causes. Arch Pathol Lab Med. 2018;142:753–60.
15. Hillerdal G, Berg J. Malignant mesothelioma secondary to chronic inflammation and old scars. Two new cases and review of the literature. Cancer. 1985;55:1968–72.
16. Butnor KJ, Rueckert J, Pavlisko EN, Sporn TA, Roggli VL. Malignant peritoneal mesothelioma in patients with endometriosis. J Clin Pathol. 2018;71:971–4.
17. Antman KH, Corson JM, Li FP, Greenberger J, Sytkowski A, Henson DE, et al. Malignant mesothelioma following radiation exposure. J Clin Oncol. 1983;1:695–700.
18. Carbone M, Emri S, Dogan AU, Steele I, Tuncer M, Pass HI, et al. A mesothelioma epidemic in Cappadocia: scientific developments and unexpected social outcomes. Nat Rev Cancer. 2007;7:147–54.
19. Taylor S, Carpentieri D, Williams J, Acosta J, Southard R. Malignant peritoneal mesothelioma in an adolescent male with BAP1 deletion. J Pediatr Hematol Oncol. 2015;37:e323–7.
20. Panou V, Gadiraju M, Wolin A, Weipert CM, Skarda E, Husain AN, et al. Frequency of germline mutations in cancer susceptibility genes in malignant mesothelioma. J Clin Oncol. 2018;36:2863–71.
21. Guo G, Chmielecki J, Goparaju C, Heguy A, Dolgalev I, Carbone M, et al. Whole-exome sequencing reveals frequent genetic alterations in BAP1, NF2, CDKN2A, and CUL1 in malignant pleural mesothelioma. Cancer Res. 2015;75:264–9.
22. Lo Iacono M, Monica V, Righi L, Grosso F, Libener R, Vatrano S, et al. Targeted next-generation sequencing of cancer genes in advanced stage malignant pleural mesothelioma: a retrospective study. J Thorac Oncol. 2015;10:492–9.
23. Bueno R, Stawiski EW, Goldstein LD, Durinck S, De Rienzo A, Modrusan Z, et al. Comprehensive genomic analysis of malignant pleural mesothelioma identifies recurrent mutations, gene fusions and splicing alterations. Nat Genet. 2016;48:407–16.
24. Kato S, Tomson BN, Buys TP, Elkin SK, Carter JL, Kurzrock R. Genomic landscape of malignant mesotheliomas. Mol Cancer Ther. 2016;15:2498–507.
25. Zehir A, Benayed R, Shah RH, Syed A, Middha S, Kim HR, et al. Mutational landscape of metastatic cancer revealed from prospective clinical sequencing of 10,000 patients. Nat Med. 2017;23:703–13.
26. Hmeljak J, Sanchez-Vega F, Hoadley KA, Shih J, Stewart C, Heiman D, et al. Integrative molecular characterization of malignant pleural mesothelioma. Cancer Discov. 2018;8:1548–65.
27. Blum Y, Meiller C, Quetel L, Elarouci N, Ayadi M, Tashtanbaeva D, et al. Dissecting heterogeneity in malignant pleural mesothelioma through histo-molecular gradients for clinical applications. Nat Commun. 2019;10:1333.
28. Quetel L, Meiller C, Assie JB, Blum Y, Imbeaud S, Montagne F, et al. Genetic alterations of malignant pleural mesothelioma: association with tumor heterogeneity and overall survival. Mol Oncol. 2020. https://doi.org/10.1002/878-0261.12651.
29. Alakus H, Yost SE, Woo B, French R, Lin GY, Jepsen K, et al. BAP1 mutation is a frequent somatic event in peritoneal malignant mesothelioma. J Transl Med. 2015;13:122.
30. Chao A, Lai CH, Lee YS, Ueng SH, Lin CY, Wang TH. Molecular characteristics of endometrial cancer coexisting with peritoneal malignant mesothelioma in Li-Fraumeni-like syndrome. BMC Cancer. 2015;15:8.
31. Sheffield BS, Tinker AV, Shen Y, Hwang H, Li-Chang HH, Pleasance E, et al. Personalized oncogenomics: clinical experience with malignant peritoneal mesothelioma using whole genome sequencing. PLoS One. 2015;10:e0119689.
32. Lai J, Zhou Z, Tang XJ, Gao ZB, Zhou J, Chen SQ. A tumor-specific neo-antigen caused by a frameshift mutation in BAP1 is a potential personalized biomarker in malignant peritoneal mesothelioma. Int J Mol Sci. 2016;17:E739.
33. Maki-Nevala S, Sarhadi VK, Knuuttila A, Scheinin I, Ellonen P, Lagstrom S, et al. Driver gene and novel mutations in asbestos-exposed lung adenocarcinoma and malignant mesothelioma detected by exome sequencing. Lung. 2016;194:125–35.
34. Ugurluer G, Chang K, Gamez ME, Arnett AL, Jayakrishnan R, Miller RC, et al. Genome-based mutational analysis by next generation sequencing in patients with malignant pleural and peritoneal mesothelioma. Anticancer Res. 2016;36:2331–8.
35. Vanni I, Coco S, Bonfiglio S, Cittaro D, Genova C, Biello F, et al. Whole exome sequencing of independent lung adenocarcinoma, lung squamous cell carcinoma, and malignant peritoneal mesothelioma: A case report. Med (Baltim). 2016;95:e5447.
36. Desmeules P, Joubert P, Zhang L, Al-Ahmadie HA, Fletcher CD, Vakiani E, et al. A subset of malignant mesotheliomas in young adults are associated with recurrent EWSR1/FUS-ATF1 fusions. Am J Surg Pathol. 2017;41:980–8.
37. Joseph NM, Chen YY, Nasr A, Yeh I, Talevich E, Onodera C, et al. Genomic profiling of malignant peritoneal mesothelioma reveals recurrent alterations in epigenetic regulatory genes BAP1, SETD2, and DDX3X. Mod Pathol. 2017;30:246–54.
38. Ross JS, Ali SM, Fasan O, Block J, Pal S, Elvin JA, et al. ALK fusions in a wide variety of tumor types respond to Anti-ALK targeted therapy. Oncologist. 2017;22:1444–50.
39. Bochtler T, Endris V, Reiling A, Leichsenring J, Schweiger MR, Klein S, et al. Integrated histogenetic analysis reveals BAP1-mutated epithelioid mesothelioma in a patient with cancer of unknown primary. J Natl Compr Canc Netw. 2018;16:677–82.
40. Hung YP, Dong F, Watkins JC, Nardi V, Bueno R, Dal Cin P, et al. Identification of ALK rearrangements in malignant peritoneal mesothelioma. JAMA Oncol. 2018;4:235–8.
41. Loffler MW, Steinhilber J, Hilke FJ, Haen SP, Bosmuller H, Montes-Mojarro IA, et al. First case report of malignant peritoneal mesothelioma and oral verrucous carcinoma in a patient with a germline PTEN mutation: a combination of extremely rare diseases with probable further implications. BMC Med Genet. 2018;19:144.
42. Belfiore A, Busico A, Bozzi F, Brich S, Dallera E, Conca E, et al. Molecular signatures for combined targeted treatments in diffuse malignant peritoneal mesothelioma. Int J Mol Sci. 2019;20:E5817.
43. Lund-Andersen C, Nakken S, Nygard S, Fromm B, Aasheim LB, Davidson B, et al. Integrative genomic analysis of peritoneal malignant mesothelioma: understanding a case with extraordinary chemotherapy response. Cold Spring Harb Mol Case Stud. 2019;5:a003566.
44. Ruschoff JH, Gradhand E, Kahraman A, Rees H, Ferguson JL, Curioni-Fontecedro A, et al. STRN-ALK rearranged malignant peritoneal mesothelioma with dramatic response following ceritinib treatment. JCO Precis Oncol. 2019;3:1–6.
45. Shrestha R, Nabavi N, Lin YY, Mo F, Anderson S, Volik S, et al. BAP1 haploinsufficiency predicts a distinct immunogenic class of malignant peritoneal mesothelioma. Genome Med. 2019;11:8.
46. Smith-Hannah A, Naous R. Primary peritoneal epithelioid mesothelioma of clear cell type with a novel VHL gene mutation: a case report. Hum Pathol. 2019;83:199–203.

47. Glass C, Sholl LM, Landgraf JR, Chirieac L, Roggli VL. Molecular analysis of a patient with neurofibromatosis 2 (NF2) and peritoneal malignant mesothelioma. Am J Surg Pathol. 2020;44:288–92.
48. Bott M, Brevet M, Taylor BS, Shimizu S, Ito T, Wang L, et al. The nuclear deubiquitinase BAP1 is commonly inactivated by somatic mutations and 3p21.1 losses in malignant pleural mesothelioma. Nat Genet. 2011;43:668–72.
49. Testa JR, Cheung M, Pei J, Below JE, Tan Y, Sementino E, et al. Germline BAP1 mutations predispose to malignant mesothelioma. Nat Genet. 2011;43:1022–5.
50. Cigognetti M, Lonardi S, Fisogni S, Balzarini P, Pellegrini V, Tironi A, et al. BAP1 (BRCA1-associated protein 1) is a highly specific marker for differentiating mesothelioma from reactive mesothelial proliferations. Mod Pathol. 2015;28:1043–57.
51. Nasu M, Emi M, Pastorino S, Tanji M, Powers A, Luk H, et al. High Incidence of Somatic BAP1 alterations in sporadic malignant mesothelioma. J Thorac Oncol. 2015;10:565–76.
52. Sheffield BS, Hwang HC, Lee AF, Thompson K, Rodriguez S, Tse CH, et al. BAP1 immunohistochemistry and p16 FISH to separate benign from malignant mesothelial proliferations. Am J Surg Pathol. 2015;39:977–82.
53. Singhi AD, Krasinskas AM, Choudry HA, Bartlett DL, Pingpank JF, Zeh HJ, et al. The prognostic significance of BAP1, NF2, and CDKN2A in malignant peritoneal mesothelioma. Mod Pathol. 2015;29:14–24.
54. Leblay N, Lepretre F, Le Stang N, Gautier-Stein A, Villeneuve L, Isaac S, et al. BAP1 is altered by copy number loss, mutation, and/or loss of protein expression in more than 70% of malignant peritoneal mesotheliomas. J Thorac Oncol. 2017;12:724–33.
55. Panagopoulos I, Thorsen J, Gorunova L, Micci F, Haugom L, Davidson B, et al. RNA sequencing identifies fusion of the EWSR1 and YY1 genes in mesothelioma with t(14;22)(q32;q12). Genes Chromosomes Cancer. 2013;52:733–40.
56. Loharamtaweethong K, Puripat N, Aoonjai N, Sutepvarnon A, Bandidwattanawong C. Anaplastic lymphoma kinase (ALK) translocation in paediatric malignant peritoneal mesothelioma: a case report of novel ALK-related tumour spectrum. Histopathology. 2016;68:603–7.
57. Mian I, Abdullaev Z, Morrow B, Kaplan RN, Gao S, Miettinen M, et al. Anaplastic lymphoma kinase gene rearrangement in children and young adults with mesothelioma. J Thorac Oncol. 2020;15:457–61.
58. Warhol MJ, Hickey WF, Corson JM. Malignant mesothelioma: ultrastructural distinction from adenocarcinoma. Am J Surg Pathol. 1982;6:307–14.
59. De Rienzo A, Archer MA, Yeap BY, Dao N, Sciaranghella D, Sideris AC, et al. Gender-specific molecular and clinical features underlie malignant pleural mesothelioma. Cancer Res. 2016;76:319–28.
60. Sholl LM, Do K, Shivdasani P, Cerami E, Dubuc AM, Kuo FC, et al. Institutional implementation of clinical tumor profiling on an unselected cancer population. JCI Insight. 2016;1:e87062.
61. Kolin DL, Dong F, Baltay M, Lindeman N, MacConaill L, Nucci MR, et al. SMARCA4-deficient undifferentiated uterine sarcoma (malignant rhabdoid tumor of the uterus): a clinicopathologic entity distinct from undifferentiated carcinoma. Mod Pathol. 2018;31:1442–56.
62. Churg A, Allen T, Borczuk AC, Cagle PT, Galateau-Salle F, Hwang H, et al. Well-differentiated papillary mesothelioma with invasive foci. Am J Surg Pathol. 2014;38:990–8.
63. Brich S, Bozzi F, Perrone F, Tamborini E, Cabras AD, Deraco M, et al. Fluorescence in situ hybridization (FISH) provides estimates of minute and interstitial BAP1, CDKN2A, and NF2 gene deletions in peritoneal mesothelioma. Mod Pathol. 2020;33:217–27.
64. Chiosea S, Krasinskas A, Cagle PT, Mitchell KA, Zander DS, Dacic S. Diagnostic importance of 9p21 homozygous deletion in malignant mesotheliomas. Mod Pathol. 2008;21:742–7.
65. Krasinskas AM, Bartlett DL, Cieply K, Dacic S. CDKN2A and MTAP deletions in peritoneal mesotheliomas are correlated with loss of p16 protein expression and poor survival. Mod Pathol. 2010;23:531–8.
66. Borczuk AC, Pei J, Taub RN, Levy B, Nahum O, Chen J, et al. Genome-wide analysis of abdominal and pleural malignant mesothelioma with DNA arrays reveals both common and distinct regions of copy number alteration. Cancer Biol Ther. 2016;17:328–35.
67. Pavlisko EN, Roggli VL. Sarcomatoid peritoneal mesothelioma: clinicopathologic correlation of 13 cases. Am J Surg Pathol. 2015;39:1568–75.
68. Pastorino S, Yoshikawa Y, Pass HI, Emi M, Nasu M, Pagano I, et al. A subset of mesotheliomas with improved survival occurring in carriers of BAP1 and other germline mutations. J Clin Oncol. 2018;36:3485–94.
69. Mijalovsky A, Halperin D, Perez Y, Zafarov B, Shaco-Levy R, Kapelushnik J, et al. Malignant peritoneal mesothelioma in an infant with familial ATM mutations. J Pediatr Hematol Oncol. 2018;40:e511–e5.
70. Lee W, Teckie S, Wiesner T, Ran L, Prieto Granada CN, Lin M, et al. PRC2 is recurrently inactivated through EED or SUZ12 loss in malignant peripheral nerve sheath tumors. Nat Genet. 2014;46:1227–32.
71. Kemp CD, Rao M, Xi S, Inchauste S, Mani H, Fetsch P, et al. Polycomb repressor complex-2 is a novel target for mesothelioma therapy. Clin Cancer Res. 2012;18:77–90.
72. Shinozaki-Ushiku A, Ushiku T, Morita S, Anraku M, Nakajima J, Fukayama M. Diagnostic utility of BAP1 and EZH2 expression in malignant mesothelioma. Histopathology. 2017;70:722–33.
73. LaFave LM, Beguelin W, Koche R, Teater M, Spitzer B, Chramiec A, et al. Loss of BAP1 function leads to EZH2-dependent transformation. Nat Med. 2015;21:1344–9.
74. Laugesen A, Hojfeldt JW, Helin K. Role of the polycomb repressive complex 2 (PRC2) in transcriptional regulation and cancer. Cold Spring Harb Perspect Med. 2016;6:a026575.
75. Goode B, Joseph NM, Stevers M, Van Ziffle J, Onodera C, Talevich E, et al. Adenomatoid tumors of the male and female genital tract are defined by TRAF7 mutations that drive aberrant NF-kB pathway activation. Mod Pathol. 2018;31:660–73.
76. Tamura D, Maeda D, Halimi SA, Okimura M, Kudo-Asabe Y, Ito S, et al. Adenomatoid tumour of the uterus is frequently associated with iatrogenic immunosuppression. Histopathology. 2018;73:1013–22.
77. Stevers M, Rabban JT, Garg K, Van Ziffle J, Onodera C, Grenert JP, et al. Well-differentiated papillary mesothelioma of the peritoneum is genetically defined by mutually exclusive mutations in TRAF7 and CDC42. Mod Pathol. 2019;32:88–99.
78. Hung YP, Dong F, Dubuc AM, Dal Cin P, Bueno R, Chirieac LR. Molecular characterization of localized pleural mesothelioma. Mod Pathol. 2020;33:271–80.
79. Sukov WR, Ketterling RP, Wei S, Monaghan K, Blunden P, Mazzara P, et al. Nearly identical near-haploid karyotype in a peritoneal mesothelioma and a retroperitoneal malignant peripheral nerve sheath tumor. Cancer Genet Cytogenet. 2010;202:123–8.