Modern Pathology (2018) 31:1653–1660
https://doi.org/10.1038/s41379-018-0060-4

ARTICLE

Mucosal inflammation in *Candida* esophagitis has distinctive features that may be helpful diagnostically

Isabella W. Martin[1] · Aaron E. Atkinson[1] · Xiaoying Liu[1] · Arief A. Suriawinata[1] · Joel A. Lefferts[1] · Mikhail Lisovsky[1]

Received: 6 January 2018 / Revised: 28 February 2018 / Accepted: 24 March 2018 / Published online: 19 June 2018
© United States & Canadian Academy of Pathology 2018

Abstract

The diagnosis of *Candida* esophagitis can be challenging when the epithelium containing *Candida* filamentous forms is not readily seen or is entirely sloughed away. Mucosal inflammation could be helpful diagnostically, if distinctive. However it is thought to be nonspecific in *Candida* esophagitis. The goal of this retrospective study was to identify features of mucosal inflammation helpful in alerting a pathologist to the possibility of *Candida* esophagitis when *Candida* mycelia are not readily observed. The study group consisted of 99 consecutive cases of *Candida* esophagitis and a control group of 64 consecutive cases of reflux esophagitis diagnosed at our institution from 2008–2016. Band-like superficial intraepithelial neutrophils and increased intraepithelial lymphocytes were observed in 75 and 67% of *Candida* esophagitis cases, respectively and only in 14 and 19% of reflux esophagitis cases, respectively ($p < .0001$). Intraepithelial lymphocytes were peripapillary or CD4-predominant in 75% of *Candida* esophagitis cases with increased lymphocytes, in contrast to 17% of reflux esophagitis cases ($p = .0011$). Concurrent presence of intraepithelial neutrophils and increased lymphocytes showed increased specificity for *Candida* esophagitis and was observed in 61% of patients with *Candida* esophagitis and only in 2% of patients with reflux esophagitis ($p < .0001$). In addition, superficial band-like neutrophils were observed concurrently with increased peripapillary lymphocytes or CD4-predominant lymphocytes in 35 and 50% of *Candida* esophagitis cases, respectively, in contrast to no reflux esophagitis cases. Basal cell hyperplasia and elongation of stromal papillae were frequent in both groups. The data suggest that when *Candida* microorganisms are not readily observed, concurrent presence of superficial band-like neutrophils and increased lymphocytes may be indicative of *Candida* etiology of active esophagitis.

Introduction

Candida albicans (*C. albicans*) is a common commensal organism in the oropharyngeal cavity and gastrointestinal tract and is the most common cause of infectious esophagitis [1, 2]. It grows as oval-shaped budding yeast, or as pseudohyphae or true septate hyphae. Both yeast and filamentous forms are usually seen in *Candida* esophagitis, but only epithelium-invasive filamentous forms are diagnostic of infection, as yeast may superficially colonize the mucosa without causing clinical disease. Although *Candida* esophagitis may occur in normal individuals, it is more often an opportunistic infection. The development of pathogenicity is enabled by defects in host cellular immunity, such as immunodeficiency states including AIDS, steroid use, malignancy, poorly-controlled diabetes, antibiotic use and mucosal barrier injury, such as gastroesophageal reflux disease [3, 4]. Although *C. albicans* is the most commonly implicated species, others including *C. dubleniensis, C. tropicalis, C. parapsilosis and C. glabrata* have been also described as causative agents of esophagitis, but at a significantly lower rate [5–7]. Patients with *Candida* esophagitis mainly complain of odynophagia and dysphagia and demonstrate whitish plaques and exudate endoscopically [1, 3].

Pathologic diagnosis of *Candida* esophagitis is often straightforward: tissue-invasive fungal forms can be readily seen with hematoxylin-eosin stain usually within detached squamous epithelium or debris, which may be admixed with neutrophils and bacteria. Fungal organisms can then be confirmed with special stains like Gomori Methenamine Silver or Periodic Acid Schiff. However, diagnostic epithelium may be scarce and difficult to appreciate, or it may be sloughed away during either endoscopy or biopsy fixation and processing [1]. In these recurring situations, the

✉ Mikhail Lisovsky
Mikhail.lisovsky@hitchcock.org

[1] Department of Pathology, Dartmouth-Hitchcock Medical Center and Geisel School of Medicine at Dartmouth, Lebanon, NH, USA

diagnosis may become problematic, with a differential diagnosis including other causes of active esophagitis, notably reflux esophagitis. Mucosal inflammation could be helpful diagnostically, if it had distinctive features. However, mucosal inflammation is thought to be nonspecific in *Candida* esophagitis, although the supporting data are scarce [2, 8–10]. Surprisingly little is known about histologic features of *Candida* esophagitis, besides the presence of *Candida* organisms themselves.

The goal of this study was to identify characteristic features of mucosal inflammation in *Candida* esophagitis, apart from the fungal microorganisms, in order to aid in differentiating *Candida* esophagitis from other types of active esophagitis in problematic cases.

Material and methods

Case selection

This was an observational retrospective study of 99 consecutive cases of *Candida* esophagitis identified through searching the laboratory information system from 2008–2014 and during routine diagnostic work from 2015–2016 in a tertiary care academic center. Inclusion criteria consisted of (a) unequivocal presence of *Candida* filamentous forms in the epithelium; and (b) sufficient squamous mucosa in the biopsy. A control group consisted of 64 consecutive biopsy cases of histologic reflux esophagitis also selected through searching the laboratory information system. The study was approved by the Committee for the Protection of Human Subjects at Dartmouth College.

Clinical information

Clinical data were extracted from the electronic medical records of Dartmouth-Hitchcock Medical Center and included: age, sex, past medical history, results of standard manometry or barium esophagram, and use of any of the following medications during the 8 weeks preceding biopsy: corticosteroids, antibiotics, immunosuppressive drugs, chemotherapeutic drugs and biologically active agents. To ensure proper recording of retrospective data, a uniform electronic data abstraction form with data codes and a protocol to resolve ambiguous or conflicting data was created. The abstractors (IM and ML) were blinded to the clinical and histologic data.

Histologic evaluation

Candida esophagitis was defined as the presence of pseudohyphae consistent with *Candida* species invading the esophageal squamous epithelium. Diagnostic features of reflux esophagitis included basal hyperplasia (expansion of the basal zone more than 15% of the thickness of the squamous epithelium), elongated stromal papillae (lengthening of the stromal papillae to more than two thirds of the thickness of squamous epithelium) and/or intraepithelial granulocytes [11]. The following histologic features were evaluated: basal cell hyperplasia and elongation of stromal papillae, distribution and depth of localization of intraepithelial neutrophils; number of intraepithelial eosinophils and distribution, localization and number of intraepithelial lymphocytes. When no mucosal inflammation was present in the original slide, 3 deeper steps were evaluated.

Intraepithelial neutrophils were categorized as having band-like or focal distribution. Band-like neutrophils continuously involved superficial layers of the epithelium, and the depth of involvement was quantified according to the number of involved epithelial cell layers (parakeratotic layers included, when present). Focal neutrophils showed discrete, discontinuous distribution, not conforming to a band-like appearance. Intraepithelial lymphocytes were counted in the 400× field of view (high power field) with the highest density of lymphocytes. The upper limit of normal number of intraepithelial lymphocytes was 62 at 0 to 2 cm (gastroesophageal junction), 46 at 5 cm (distal esophagus) and 41 at 10 cm (mid esophagus), as previously reported [12]. The localization of increased lymphocytes was categorized as peripapillary or diffuse. Peripapillary lymphocytes centered on a stromal papilla, with interpapillary area largely devoid of lymphocytes. Diffuse lymphocytes were scattered and had no relation to the papillae. Intraepithelial eosinophils were considered rare when no more than 1 eosinophil on average was observed for every 2 high power fields; more frequent eosinophils were called multiple. Intraepithelial neutrophils and increased intraepithelial lymphocytes were called concurrent when both were present in a biopsy specimen. Intraepithelial neutrophils and increased lymphocytes were called co-localized when they overlapped in the same area of the epithelium.

Biopsies were fixed in 10% formalin, paraffin-embedded and stained with hematoxylin and eosin. Gomori Methenamine Silver stain was used where appropriate to support the diagnosis of *Candida* esophagitis. The microscopy was performed by two authors independently (IM and ML) and discrepancies were resolved by consensus. Microscopy was performed using an Olympus BX 41 microscope with a field number 22 eyepiece, resulting in a 0.237 mm^2 field of view at 400× magnification.

Immunohistochemistry

Routine CD4 and CD8 immunohistochemistry was performed on all cases of *Candida* esophagitis with increased

intraepithelial lymphocytes using Bond Polymer Refine Detection staining reagents (Leica Biosystems Newcastle Ltd, Newcastle Upon Tyne, UK) and Bond III autostainer (Leica Microsystems). The following primary antibodies were used: anti-CD4 antibody at a 1:100 dilution (clone SP35, Cell Marque, Rocklin, CA) and anti-CD8 Bond™ ready-to-use antibody (clone 4b11, Leica Biosystems). CD4 T-cells and CD8 T-cells were counted in the same field of view (400×) where lymphocytes were counted. The CD4: CD8 ratios of >1 or ≤1 indicated predominance of CD4 or CD8 T-cells, respectively.

Molecular identification of *C. albicans*

DNA from formalin-fixed paraffin-embedded biopsies was extracted as described using QIAamp DNA FFPE tissue kit (Qiagen, Germantown, MD) with the following modifications: proteinase K incubation extension to 6 h at 55 °C followed by addition of 10 units zymolase (Zymo Research, Irvine, CA; Catalog #E1004,) and 37 °C overnight incubation prior to extraction [13]. DNA primers were designed to the *C. albicans*-specific gene, *EED1* (Epithelial Escape and Dissemination 1): EED1 Forward, AGTGTTGCAAAAGAATACCC, and EED1 Reverse, CATGAGAATTAGTTTGATGAACC [14]. Beta-globin primers were also used for polymerase chain reaction (PCR), as described previously [13]. For PCR, AmpliTaq Gold (Applied Biosystems, Foster City, CA) was used per manufacturer's instructions and primers. PCR products were analyzed using 2% Egels and Egel sample buffer (Invitrogen, Carlsbad, CA).

Statistics

The distributions of baseline characteristics were compared between the groups using two sample t-test for continuous variables and Fisher's exact test for categorical variables. Statistical analyses were performed using GraphPad Prism (GraphPad Software Inc., La Jolla, CA)

Results

General characterization of biopsies with *Candida* esophagitis

Of 99 cases of *Candida* esophagitis, 88 (89%) had features of mucosal inflammation, such as basal cell hyperplasia, elongated stromal papillae, intraepithelial neutrophils, eosinophils and increased intraepithelial lymphocytes. Eleven cases had no evidence of inflammation even after evaluation of deeper levels. Comparison of cases with extensive involvement by Candida mycelia with those with scarce involvement did not reveal a noticeable difference in the extent of mucosal inflammation.

Histologic features of mucosal inflammation in *Candida* esophagitis

The data are presented in Table 1. Basal hyperplasia and elongated stromal papillae were present in 73% (64/88) and 52% (46/88) of *Candida* esophagitis cases, respectively and in 95% (61/64) and 81% (52/64) of reflux esophagitis cases, respectively ($p < .0007$). Erosions or evidence of ulcer were not observed in *Candida* esophagitis cases, but were present in 20% (13/64) of reflux esophagitis cases ($p < .0001$). These data suggest that features of epithelial regeneration are common both in *Candida* esophagitis and reflux esophagitis. However, erosions/ulcers are largely restricted to reflux esophagitis.

Intraepithelial neutrophils were found in 94% (83/88) of *Candida* esophagitis cases with mucosal inflammation and only in 22% (14/64) of reflux esophagitis cases ($p < .0001$). Band-like superficial neutrophils were observed in the majority of *Candida* esophagitis cases, 75% (66/88), and only in 14% (9/64) of reflux esophagitis cases ($p < .0001$; Fig. 1). In *Candida* esophagitis, the band width varied from two squamous cell layers to the upper half of the epithelium, with the mean of 3.7 ± 1.8 cell layers. This was significantly wider than 2.2 ± 0.4 cell layers in reflux esophagitis ($p < .018$), suggesting that band-like neutrophils are more prevalent and more prominent in *Candida* esophagitis than in reflux esophagitis.

Candida esophagitis and reflux esophagitis also differed in the content of intraepithelial lymphocytes. The latter were increased (range 50–245 lymphocytes per high power field) in 67% (59/88) of *Candida* esophagitis cases and only in 19% (12/64, range 44-130) of reflux esophagitis cases ($p < .0001$). Intraepithelial lymphocytes were peripapillary in 75% (44/59) of *Candida* esophagitis cases and only 17% (11/64) of reflux esophagitis cases ($p = .0011$; Fig. 2a). In addition, 75% (44/59) of *Candida* esophagitis biopsies with increased intraepithelial lymphocytes had predominance of CD4 T-cells (CD4:CD8 $= 2.8 \pm 1.7$; Fig. 2b–d), while 83% (10/12) of reflux esophagitis cases had predominance of CD8 T-cells (CD4:CD8 $= 0.7 \pm 0.6$, $p = .005$). In summary, increased intraepithelial lymphocytes were common, mainly peripapillary and CD4-predominant in *Candida* esophagitis, in contrast to reflux esophagitis.

Combination of several features showed increased specificity for *Candida* esophagitis. Intraepithelial neutrophils and increased lymphocytes were present concurrently in 61% (54/88) of *Candida* esophagitis cases, but only in 2% (1/64) of reflux esophagitis cases ($p < .0001$; sensitivity

Table 1 Histologic features of inflammation in *Candida* esophagitis and reflux esophagitis

	Candida esophagitis, % ($n = 88$)	Reflux esophagitis, % ($n = 64$)	*P*-value
Basal hyperplasia	73	95	.0007
Elongated papillae	52	81	.0003
Intraepithelial neutrophils			
Total	94	22	<.0001
Band-like	75	14	<.0001
Patchy/focal	19	8	.0342
Increased intraepithelial lymphocytes			
Total	67 (59/88)	19 (12/64)	<.0001
Peripapillary	75 (44/59)	17 (2/12)	.0011
Diffuse	25 (14/59)	83 (10/12)	.0011
CD4-predominant	75 (44/59)	17 (2/12)	.005
Concurrence of intraepithelial Neutrophils and increased lymphocytes	61	2	<.0001
Concurrence of band-like neutrophils and peripapillary lymphocytes	35	0	<.0001
Concurrence of band-like neutrophils and increased CD4-predominant lymphocytes	50	0	<.0001
Co-localization of intraepithelial neutrophils and increased lymphocytes	35	2	<.0001
Intraepithelial eosinophils			
No	66	25	<.0001
Rare	20	14	<.0001
Multiple	14	39	<.0001
Erosion/ulcer	0	20	<.0001

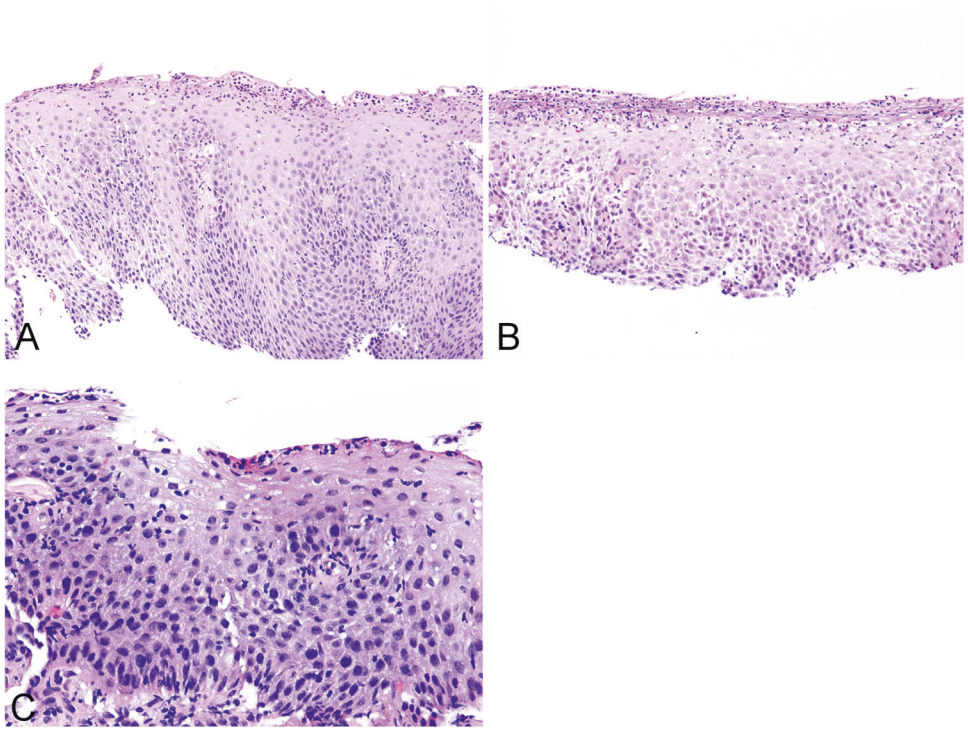

Fig. 1 Mucosal inflammation in *Candida* esophagitis. **a** A superficial band-like neutrophilic infiltrate with microabscesses. Elongated stromal papillae and increased lymphocytes are also present. **b** A superficial band-like neutrophilic infiltrate and basal cell hyperplasia. **c** An only 1–2 cells-thick band of superficial neutrophils, with basal hyperplasia and increased lymphocytes

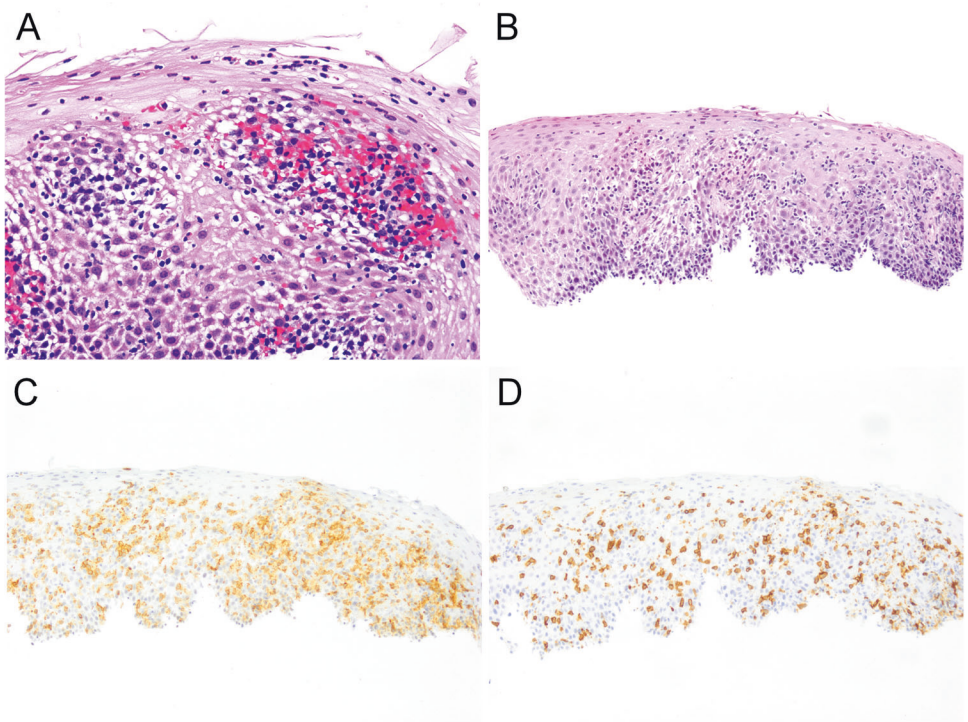

Fig. 2 **a**, **b** Increased peripapillary lymphocytes. Co-localization with superficial neutrophils is present in (**a**). **c**, **d** Immunohistochemistry performed on a specimen shown in (**b**) demonstrates that CD4 T-cells outnumber CD8 T-cells. **c** CD4 T-cells. (**d**) CD8 T-cells

Table 2 Mucosal inflammation in cases with attached to mucosal surface and detached *Candida* pseudohyphae

	Detached *Candida* pseuhyphae	Attached *Candida* pseuhyphae	*P*-value
Increased lymphocytes	83% (10/12)	71% (10/14)	.652
Peripapillary lymphocytes	70% (7/10)	60% (6/10)	1.00
CD4-predominant lymphocytes	50% (5/10)	70% (7/10)	.650
Band-like neutrophils	83% (10/12)	86% (12/14)	1.00
Number of cell layers	3.7 ± 1.7	3.5 ± 1.8	.709

61% and specificity 98%). In addition, concurrence of band-like neutrophils with increased peripapillary lymphocytes or CD4-predominant lymphocytes was observed in 35% (31/88) and 50% (44/88) of *Candida* esophagitis cases, respectively and in 0 of reflux esophagitis cases (sensitivity 35 and 50%, respectively and specificity 100%). These data suggest that *Candida*-induced inflammation is distinctively characterized by concurrent presence of band-like neutrophils and intraepithelial lymphocytes.

We next wanted to ascertain whether attachment of *Candida* pseudohyphae to mucosal surface correlated with the degree of mucosal inflammation. Of 26 available cases with Gomori Methenamine Silver stain, 12 cases showed only detached *Candida* pseudohyphae and 14 cases showed *Candida* pseudohyphae attached to the surface of mucosal fragments. There was no difference in the degree of inflammation between the groups as assessed by the proportion of cases with increased lymphocytes or band-like neutrophils (Table 2).

Evaluation of motility abnormalities in *Candida* esophagitis

Because CD4-predominant peripapillary lymphoid aggregates are characteristic of dysmotility-associated lymphocytic esophagitis [12, 15] and similar lymphoid aggregates are observed in *Candida* esophagitis, we wanted to elucidate whether *Candida* esophagitis is associated with motility abnormalities. Of 10 patients with *Candida* esophagitis and mucosal inflammation evaluated by manometry or barium esophagram, 7 (70%) showed various types of motility abnormalities (1—diffuse esophageal spasm, 1 nutcracker esophagus, 1 ineffective motility, 2 motor failure in the body of the esophagus and 2 dysmotility patterns by barium swallow). Six of 10 (60%) evaluated patients with reflux esophagitis also demonstrated various types of motility abnormalities (3 ineffective motility, 1 achalasia and 2 dysmotility patterns by barium swallow). These findings do not support an association between *Candida* esophagitis and esophageal motility abnormalities.

Table 3 Clinico-epidemiological factors in *Candida* esophagitis with and without mucosal inflammation

	Candida esophagitis with mucosal inflammation, ($n = 88$)	*Candida* esophagitis without mucosal inflammation, ($n = 11$)	*P*-value
Age (yrs)	58.3 ± 17.0	50.4 ± 22.7	.161
Sex (Male: Female)	42: 52	4: 7	.752
Primary immunodeficiency	1%	0	1.000
Diabetes	23%	18%	1.000
Malignancy	12%	18%	.625
Alcoholism	8%	0	1.000
Malnutrition	3%	0	1.000
Organ transplant	2%	10%	.287
End stage renal disease	2%	10%	.287
Antibiotics	16%	10%	1.000
Steroids	47%	36%	.541
Chemotherapeutic, immunosuppressive and bioactive drugs	8%	18%	.242
Gastroesophageal reflux disease	60%	55%	.496

Clinico-epidemiologic and microbiological features of CE with and without mucosal inflammation

To gain insight into possible causes of mucosal inflammation (or lack thereof) associated with *Candida* esophagitis, we compared multiple clinico-epidemiologic parameters in 88 patients with mucosal inflammation and 11 patients without mucosal inflammation. Analyzed variables included: age, sex, history of primary immunodeficiency, diabetes, malignancy, alcoholism, malnutrition, organ transplant, end-stage renal disease, gastroesophageal reflux disease, use of antibiotics, steroids, chemotherapeutic drugs, immunosuppressive drugs and bioactive agents. No significant differences were observed between the groups (Table 3).

We then evaluated the possibility that mucosal inflammation is associated with particular *Candida* species. With that goal, we determined the prevalence of *C. albicans* in 11 cases of *Candida* esophagitis without inflammation (DNA quality was inadequate in 1 case) and in 13 random cases of *Candida* esophagitis with inflammation using PCR to detect the *C. albicans*-specific gene, *EED1*. Similar proportion of DNA samples, 100% (10/10) and 92% (12/13), respectively were positive suggesting high prevalence of *C. albicans* in both groups (Fig. 3).

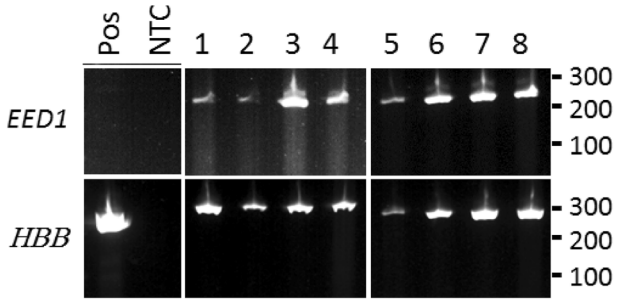

Fig. 3 PCR products (210 base pairs) of *C. albicans*-specific *EED1* gene. Lanes 1–4, samples lacking mucosal inflammation. Lanes 5–8, samples with mucosal inflammation. Also shown are a beta-globin PCR product (*HBB*, 268 base pairs) used as an internal control, beta-globin positive control (POS), no template control (NTC), and size markers

Discussion

Prior literature has deemed mucosal inflammation of *Candida* esophagitis to be non-specific. In 1972, Moulinier et al. recognized that occasionally epithelium underlying candidal exudate appeared normal, but more often demonstrated inflammatory changes with vascular congestion, exudate and mononuclear cell infiltrate [8]. A few years later, Kodsi et al. reported that histology of *Candida* esophagitis is indistinguishable from reflux esophagitis, except for the presence of *Candida* [9]. More recent reports describe frequent presence of intraepithelial lymphocytes and neutrophils in *Candida* esophagitis, but also do not propose any diagnostic value of these findings [2, 10].

Our study confirms similarity of some morphologic features between *Candida* esophagitis and reflux esophagitis, such as frequent presence of basal hyperplasia and elongated stromal papillae. However, we have also found significant differences. Superficial band-like intraepithelial neutrophils were a characteristic feature of *Candida* esophagitis in 75% of patients with mucosal inflammation in contrast to a minority of patients with reflux esophagitis (14%). Increased intraepithelial lymphocytes were also very

common in *Candida* esophagitis in contrast to reflux esophagitis (67 vs. 19%). In addition, lymphocytes were mainly peripapillary and CD4-predominant in *Candida* esophagitis, while they were predominantly diffuse and CD8-predominant in reflux esophagitis. One important distinctive feature of *Candida* esophagitis that emerged in our analysis is concurrent presence of intraepithelial neutrophils and increased lymphocytes. Even more specific was the concurrence of band-like neutrophils with increased peripapillary or CD4-predominant lymphocytes (35 and 50%, respectively), as it was observed in none of reflux esophagitis cases. Therefore, the concurrent presence of neutrophils and increased lymphocytes should raise the possibility of *Candida* esophagitis when a diagnosis of reflux esophagitis is contemplated.

In normal subjects, CD4 T-cells are mainly found in the lamina propria and CD8 T-cells in the epithelium [12, 16]. CD8-predominant intraepithelial lymphocytes are increased in reflux esophagitis and eosinophilic esophagitis and may have a role in the development of these diseases [17–19]. Conversely, the Th17 lineage of CD4 T-lymphocytes plays a key role in the response to mucosal candidiasis by activating neutrophils and antimicrobial factors [20, 21]. Co-localization of CD4-predominant T-lymphocytes with neutrophils in our study is consistent with the importance of CD4 T-cells in the immune response to *Candida* infection.

Little is known about other types of esophagitis with increased CD4-predominant lymphocytes. An association between a CD4 T-cell-predominant form of lymphocytic esophagitis and primary esophageal motility abnormalities was recently reported [12, 15, 22]. Our data does not support an association between *Candida* esophagitis and esophageal motility abnormalities, however 3 (3.4%) of our patients with *Candida* esophagitis had increased peripapillary lymphocytes and no evidence of intraepithelial granulocytes, fulfilling the criteria for lymphocytic esophagitis (data not shown) [23]. In all of these cases the lymphocytes were CD4-predominant. If *Candida* mycelia had not have been appreciated, the findings could have been interpreted as compatible with dysmotility-associated lymphocytic esophagitis. Thus, *Candida* esophagitis may join the differential diagnosis of lymphocytic esophagitis. Presence of characteristic endoscopic features of *Candida* infection (i.e., dome-shaped white plaques) would be crucial for suggesting *Candida* esophagitis in these cases in the absence of *Candida* microorganisms. Other associations of lymphocytic esophagitis are with Crohn's disease in pediatric patients and common variable immunodeficiency, however the immunophenotype of lymphocytes in these conditions remains to be fully elucidated [24, 25].

Eleven percent of patients with *Candida* esophagitis displayed a normal-appearing mucosa with no inflammation. It has been suggested that patients with *Candida* esophagitis and intact immunity develop inflammation at the infected site that limits penetration by the microorganisms [26]. We have analyzed multiple clinico-epidemiologic parameters associated with systemic or local immunodeficiency, as well as some other known risk factors for *Candida* esophagitis, however the differences between cases with and without mucosal inflammation were not statistically significant.

Candida esophagitis may be caused by other *Candida* species, such as *C. tropicalis, C. parapsilosis and C. glabrata*; therefore we considered the possibility that *Candida* esophagitis with mucosal inflammation and *Candida* esophagitis without inflammation could be caused by different *Candida* species [5, 6]. However, molecular analysis documented similarly high prevalence of *C. albicans* in both groups. The reason why some *Candida* infections do not induce mucosal inflammation remains unclear and warrants further investigation.

In conclusion, mucosal inflammation is present in the majority of *Candida* esophagitis cases commonly demonstrating epithelial regeneration, intraepithelial neutrophils and increased lymphocytes. Several histologic features may alert a pathologist contemplating the differential diagnosis of active esophagitis to the possibility of *Candida* etiology if fungal microorganisms are not appreciated. The concurrent presence of intraepithelial neutrophils and increased lymphocytes and, particularly, of superficial band-like neutrophils and peripapillary or CD4-predominant lymphocytes should trigger an active search for *Candida* microorganisms and for supportive endoscopic evidence of *Candida* esophagitis.

Compliance with ethical standards

Conflict of interest The authors declare that they have no conflict of interest.

References

1. Mathieson R, Dutta SK. Candida esophagitis. Dig Dis Sci. 1983;28:365–70.
2. Alsomali MI, Arnold MA, Frankel WL, et al. Challenges to "classic" esophageal candidiasis: looks are usually deceiving. Am J Clin Pathol. 2017;147:33–42.
3. Underwood JA, Williams JW, Keate RF. Clinical findings and risk factors for Candida esophagitis in outpatients. Dis Esophagus. 2003;16:66–9.
4. Haulk AA, Sugar AM. Candida esophagitis. Adv Intern Med. 1991;36:307–18.
5. Kliemann DA, Pasqualotto AC, Falavigna M, Giaretta T, Severo LC. Candida esophagitis: species distribution and risk factors for infection. Rev Inst Med Trop Sao Paulo. 2008;50:261–3.
6. Kakati B, Kotwal A, Biswas D, Sahu S. Fluconazole resistant Candida oesophagitis in immunocompetent patients: is empirical therapy justifiable? J Clin Diagn Res. 2015;9:DC16–18.

7. Walsh TJ, Merz WG. Pathologic features in the human alimentary tract associated with invasiveness of Candida tropicalis. Am J Clin Pathol. 1986;85:498–502.
8. Moulinier B, Lambert R, Grenier-Boley P, Bruhiere J. Esophageal mycoses. Nouv Presse Med. 1972;1:2629–32.
9. Kodsi BE, Wickremesinghe C, Kozinn PJ, Iswara K, Goldberg PK. Candida esophagitis: a prospective study of 27 cases. Gastroenterology. 1976;71:715–9.
10. Demir D, Doganavsargil B, Sarsik B, Sezak M, Tuncyurek M. Is it possible to diagnose infectious oesophagitis without seeing the causative organism? A histopathological study. Turk J Gastroenterol. 2014;25:481–7.
11. Ismail-Beigi F, Horton PF, Pope CE 2nd. Histological consequences of gastroesophageal reflux in man. Gastroenterology. 1970;58:163–74.
12. Putra J, Muller KE, Hussain ZH, et al. Lymphocytic esophagitis in nonachalasia primary esophageal motility disorders: improved criteria, prevalence, strength of association, and natural history. Am J Surg Pathol. 2016;40:1679–85.
13. Munoz-Cadavid C, Rudd S, Zaki SR, et al. Improving molecular detection of fungal DNA in formalin-fixed paraffin-embedded tissues: comparison of five tissue DNA extraction methods using panfungal PCR. J Clin Microbiol. 2010;48:2147–53.
14. Martin R, Moran GP, Jacobsen ID, et al. The Candida albicans-specific gene EED1 encodes a key regulator of hyphal extension. PLoS ONE. 2011;6:e18394.
15. Xue Y, Suriawinata A, Liu X, et al. Lymphocytic esophagitis with CD4 T-cell-predominant intraepithelial lymphocytes and primary esophageal motility abnormalities: a potential novel clinicopathologic entity. Am J Surg Pathol. 2015;39:1558–67.
16. Geboes K, De Wolf-Peeters C, Rutgeerts P, et al. Lymphocytes and langerhans cells in the human oesophageal epithelium. Virchows Arch A Pathol Anat Histopathol. 1983;401:45–55.
17. Resnick MB, Finkelstein Y, Weissler A, Levy J, Yakirevich E. Assessment and diagnostic utility of the cytotoxic T-lymphocyte phenotype using the specific markers granzyme-B and TIA-1 in esophageal mucosal biopsies. Hum Pathol. 1999;30:397–402.
18. Lucendo AJ, Navarro M, Comas C, et al. Immunophenotypic characterization and quantification of the epithelial inflammatory infiltrate in eosinophilic esophagitis through stereology: an analysis of the cellular mechanisms of the disease and the immunologic capacity of the esophagus. Am J Surg Pathol. 2007;31:598–606.
19. Dunbar KB, Agoston AT, Odze RD, et al. Association of acute gastroesophageal reflux disease with esophageal histologic changes. JAMA. 2016;315:2104–12.
20. Conti HR, Shen F, Nayyar N, et al. Th17 cells and IL-17 receptor signaling are essential for mucosal host defense against oral candidiasis. JAMA. 2016;315:2104–12.
21. Hernandez-Santos N, Gaffen SL. Th17 cells in immunity to Candida albicans. Cell Host Microbe. 2012;11:425–35.
22. Muller KE, Putra J, Gabbard S, et al. Frequency and nature of increased intraepithelial lymphocytes in biopsies from patients with achalasia. Mod Pathol. 2014;27Suppl.2:194A.
23. Rubio CA, Sjodahl K, Lagergren J. Lymphocytic esophagitis: a histologic subset of chronic esophagitis. Am J Clin Pathol. 2006;125:432–7.
24. Sutton LM, Heintz DD, Patel AS, Weinberg AG. Lymphocytic esophagitis in children. Inflamm Bowel Dis. 2014;20:1324–8.
25. Daniels JA, Lederman HM, Maitra A, Montgomery EA. Gastrointestinal tract pathology in patients with common variable immunodeficiency (CVID): a clinicopathologic study and review. Am J Surg Pathol. 2007;31:1800–12.
26. Lauwers GY, Mino-Kenudson M, Kradin RL. Infections of the gastrointestinal tract. In: Kradin RL, editor. Diagnostic pathology of infectious disease. 1st ed. Elsevier, Philadelphia, PA; 2010. p. 215–54.