Journal of Human Genetics (2019) 64:859–865
https://doi.org/10.1038/s10038-019-0637-x

ARTICLE

Phenotypic and mutational spectrum of thirty-five patients with Sjögren–Larsson syndrome: identification of eleven novel *ALDH3A2* mutations and founder effects

Mohamed S. Abdel-Hamid[1] · Mahmoud Y. Issa[2] · Hasnaa M. Elbendary[2] · Sherif F. Abdel-Ghafar[1] · Karima Rafaat[2] · Heba Hosny[3] · Marian Girgis[4] · Ghada M. H. Abdel-Salam[2] · Maha S. Zaki[2]

Received: 27 January 2019 / Revised: 21 April 2019 / Accepted: 17 June 2019 / Published online: 5 July 2019

Abstract

Sjögren–Larsson syndrome (SLS) is a rare neurocutaneous disorder characterized by congenital ichthyosis, spastic diplegia and intellectual disability. It is an inborn error of lipid metabolism caused by biallelic mutations in the *ALDH3A2* gene encoding the fatty aldehyde dehydrogenase that plays a pivotal role in metabolism of long-chain aliphatic aldehydes and alcohols. In this report, we describe the clinical, neuro-radiological and molecular findings of 35 patients with SLS. All patients shared the typical clinical manifestations of SLS including spasticity, ichthyosis and intellectual disability. Brain MRI demonstrated deep while matter affection in all patients that varied in severity. Mutational analysis of the *ALDH3A2* gene revealed 16 distinct mutations including 11 previously unreported ones. Three mutations (p.S365L, p.R9* and p.G400R) were recurrent in our patients with frequencies ranging from 12 to 24%. Interestingly, patients carrying the two new mutations p.R9* and p.G400R shared similar haplotypes suggesting possible founder effects in our population. In conclusion, we present a large cohort of patients from the same ethnicity with the characteristic clinical and brain imaging findings of SLS but with variable inter and intra familial severity and expressivity. We also identified many novel and founder *ALDH3A2* mutations thus expanding the mutational spectrum of the disorder.

Introduction

Sjögren–Larsson Syndrome (SLS, MIM #270200) is a clinically recognizable phenotype characterized by the triad of ichthyosis, spastic diplegia and intellectual disability [1]. Ichthyosis is usually congenital or appears in the first year of life. Delayed motor development due to spastic diplegia or tetraplegia often occurs by the end of the first year leading to impaired ambulation. Patients have variable degrees of intellectual disability ranging from mild to profound. Photophobia, pigmentary degeneration, retinal glistening white dots, seizures and short stature are additional findings in patients with SLS [2–5].

SLS is a rare autosomal recessive disorder and its worldwide prevalence is unknown, however, it was estimated to be 0.4 per 100,000 in Northern Sweden [6]. It is an inborn error of metabolism caused by mutations in the *ALDH3A2* gene encoding the fatty aldehyde dehydrogenase (FALDH). Deficiency of FALDH results in accumulation of aldehyde-modified lipids and fatty alcohol in the skin and in the myelin [7]. To date, *ALDH3A2* gene mutations have been described in patients from various ethnic groups. Herein, we report the clinical, neuro-radiological and molecular data of a large cohort of Egyptian patients with SLS.

Supplementary information The online version of this article (https://doi.org/10.1038/s10038-019-0637-x) contains supplementary material, which is available to authorized users.

✉ Mohamed S. Abdel-Hamid
mohamadnrc@hotmail.com

✉ Maha S. Zaki
dr_mahazaki@yahoo.com

[1] Medical Molecular Genetics Department, Human Genetics and Genome Research Division, National Research Centre, Cairo, Egypt

[2] Clinical Genetics Department, Human Genetics and Genome Research Division, National Research Centre, Cairo, Egypt

[3] National Institute of Neuromotor System, Cairo, Egypt

[4] Pediatric Department, Faculty of Medicine, Cairo University, Cairo, Egypt

Materials and methods

The present study included 35 patients referred to the neurogenetics clinics at National Research Centre (NRC) for diagnosis and counseling. All patients were subjected to a full medical history check, including prenatal, natal and postnatal histories with special emphasis on developmental history, associated neurological deficits and cutaneous morbidity. Three generations pedigree construction, complete general examination, full neurological assessment and basic anthropometric measurements (head circumference, height and weight) were done. Parents and available sibs were also examined for skin ichthyosis or dryness. Other investigations, including regular metabolic screening, auditory brain stem evoked potential, nerve conduction velocity, EEG, ophthalmological evaluation and brain MRI were also performed. Assessment of intellectual disabilities was done using Stanford-Binet Intelligence Scales version 5 and younger patients were evaluate by Portage Program.

Mutational analysis

Genomic DNA was extracted from blood lymphocytes of the patients and their parents after having a signed informed consent aligned with the guidelines of the Research Ethical Committee of the NRC. DNA was extracted using Puregene DNA extraction kit (Gentra Systems Inc., Minneapolis, MN). The *ALDH3A2* gene was amplified using 10 pairs of primers designed by ExonPrimer SOFTWARE (Supplementary Table 1). The coding region and exon/intron boundaries of approximately 100 bp sequence were investigated to identify any splice site variants as well. Our standard PCR cycling conditions were: initial denaturation at 96 °C for 5 min; 30 cycles of denaturation at 96 °C for 30 s; annealing at 61 °C for 30 s; extension at 72 °C for 30 min, and an additional extension at 72 °C for 5 min. The PCR products were purified using Exo-SAP PCR Clean-up kit (Fermentas, Germany) and sequenced in both directions using the BigDye Terminator v3.1 Cycle Sequencing Kit (Applied Biosystems, Foster City, CA, USA) and analyzed on the ABI Prism 3500 Genetic Analyzer (Applied Biosystems) according to manufacturer's instructions. The sequence data of *ALDH3A2* gene was compared with the reference genomic and cDNA sequence of the gene (NG_007095.2). The variants identified were inspected in dbSNP141 (http://www.ncbi.nlm.nih.gov/snp/), Exome Variant Server (NHLBI GO Exome Sequencing Project, Seattle, WA; http://evs.gs.washington.edu/EVS/), 1000 Genomes (http://browser.1000genomes.org/Homo_sapiens/Info/Index) and gnomAD (http://gnomad.broadinstitute.org). Moreover, the effect of mutations was predicted using MutationTaster, Polyphen2, SIFT, Meta-SNP, Align GVGD and Alamut software. Single exon deletions were confirmed using qPCR of the suspected deleted exon and one adjacent exon on DNA of the patient, parents and a control sample.

Results

The clinical, neurological assessment and neuroimaging data of our patients are summarized in Table 1.

Clinical data

Thirty-five patients derived from 25 families were evaluated in this study. They were all of Egyptian descent. Parental consanguinity was recorded in 33 patients (94.3%) and a history of similarly affected family members was noted in 7 families (20%). All patients had delayed motor milestones with distinctive increasing in muscle tones on acquiring movement. Ichthyosis (HP:0008064) and/or skin dryness were recorded early in life and preceded the neurological manifestations. Mental and speech development were variable. Cognitive impairment (HP:0001249) was mild in 68.5% of cases, moderate in 28.6% and only one patient had severe disability. Speech development was adequate in 13 patients (37.1%), defective in 48.5% (17 patients), no speech in 4 patients (11.4%) and one patient was presented before the age of 1. In general, inter and intra familial variable expressivity was evident in our series, ranging from being ambulant to severe involvement of both upper and lower limbs.

Basic growth parameters showed short stature (≥ −3 SD) in 60% of cases, underweight (≥ −3 SD) in 31.4% and unexplained postnatal microcephaly (≥ −3 SD) in 11.4%. Ambulation independently was recorded in 5 patients (14.7%), three of them had recurrent falling in a short distance walking. Skin ichthyosis was distinctive and involving the trunk in 100% of patients with variable affection of limbs, scalp and neck. Neurological assessment showed hypertonia/spasticity (HP:0001257) in all patients, nevertheless, a single one had acquired hypotonia after unsuccessful tendon release operation. Increased muscle tone involving lower limbs was noticed in all patients and 25.7% of them had upper limb hypertonia with limited hand movements. Ophthalmological evaluation conceded photophobia (12 patients), nystagmus (9 patients), glistening spots in retina (12 patients) and pale optic disc (1 patients).

Nine patients (25.7%) had seizures that developed in the first year of life. Generalized tonic-clonic is by far the prevalent type of seizures and they usually show good response to antiepileptic drugs. Brain MRI showed demyelination of the white matter (HP:0011400) in periventricular region in all patients varied from mild periventricular involvement (34.3%) to more involvement of white

Table 1 Clinical and brain imaging findings of our 35 patients with Sjogren-Larsson Syndrome

Criteria	Number of patients (35)	Percentage
Family	25	
Sex	23 M/12 F	65.7%/34.3%
Age at examination	7 m–16 6/12 y (mean: 4 8/12 y)	
Age at onset	4 m–1 6/12 y (mean: 10 m)	
Consanguinity	33	94.3%
Short stature (≥−3SD)	21	60%
Underweight (≥−3SD)	11	31.4%
Microcephaly (≥−3SD)	4	11.4%
Ichthyosis	35	100%
Neck	22	62.8%
Trunk	35	100%
Limbs	31	88.5%
Speech defect (dysarthria)/ Absent speech	17/4	48.5%/11.4%
Seizures	9	25.7%
Intellectual disability (34)		
Borderline	7	20%
Mild	16	45.7%
Moderate	10	28.6%
Severe	1	2.8%
Non ambulant	10	28.6%
Ambulation with/ Without support	20/5	57.1%/14.3%
Hypertonia/Spasticity of lower limbs	34	97.1%
Hypotonia of lower limbs	1 (after operation)	2.8%
Hypertonia/Spasticity of Upper limbs	9	25.7%
Exaggerated reflexes	35	100%
Subjected to operation of tendon release	21	60%
Brain MRI		
White matter demyelination	35	100%
Mild cortical atrophy	7	20%
Thin/hypogenesis corpus callosum	26	74.3%
Central atrophy (dilated lateral ventricles)	10	28.6%
Eye evaluation		
Photophobia	12	34.2%
Squint	5	14.3%
Nystagmus	9	25.7%
Glistening spots in Retina	8	22.8%
Iris coloboma	–	–
Pale optic disc	1	2.8%
Abnormal EEG changes	11	31.4%

matter (65.7%) (Fig. 1). Remarkable thin corpus callosum was manifested in 42.8% of cases and mild cortical atrophic changes and non-progressive dilated lateral ventricles were noted in 20 and 28.6% of patients, respectively. Investigations revealed normal metabolic screening, acylcarnitine profile, organic acid in urine, ABR and nerve conduction velocity. The detailed clinical, neuroimaging and molecular data of each of our patients are listed in Supplementary Table 2.

Molecular findings

Sequencing of the *ALDH3A2* gene identified pathogenic variants in all our patients. Sixteen distinct variants were detected including 11 novel ones (Fig. 2 and Table 2). The c.1094 C > T (p.S365L), found in 6 unrelated families (frequency = 24%), was the most common variant followed by c.25 C > T (p.R9*) and c.1198 G > A (p.G400R) that were detected in 3 families each (frequency = 12%). In addition, the missense variant c.551 C > G (p.T184R) was recurrent in two families (frequency = 8%). Other variants were unique and found in one family each. All variants were homozygous in patients, except for Patient 9 who carried two heterozygous variants, and segregated perfectly with the phenotype in all families. All novel variants were not found in dbSNP, 1000 Genomes, ExAC or gnomAD. Moreover, they were not detected in 200 normal chromosomes of Egyptian origin and deemed pathogenic by various bioinformatic tools.

In Patients 29 and patient 32, there was a repeated failure of amplification of exon 1 and exon 9, respectively. This led us to suspect homozygous deletion of such exons. To confirm our assumption, we performed copy number analysis of exons 1 and 2 in Patient 29 and exons 9 and 10 in Patient 32. In patient 29, the amplicons representing exons 2 showed normal signal intensities in all individuals analyzed (control, father, mother and the patient) while for exon 1, there was a marked reduction with almost no signal intensity in the DNA from the patient and an approximately 50% reduction in the parents indicating deletion of this exon. Similarly, the deletion of exon 9 was confirmed in Patient 32.

Discussion

Sjogren and Larsson were the first to describe a clinically distinct syndrome characterized by congenital ichthyosis, spastic diplegia or tetraplegia and intellectual disability in patients from an isolated region in Northern Sweden [1]. The disease was subsequently identified in Non-Swedish patients and the molecular defect was unraveled thereafter by identification of biallelic mutations in *ALDH3A2* [8]. To

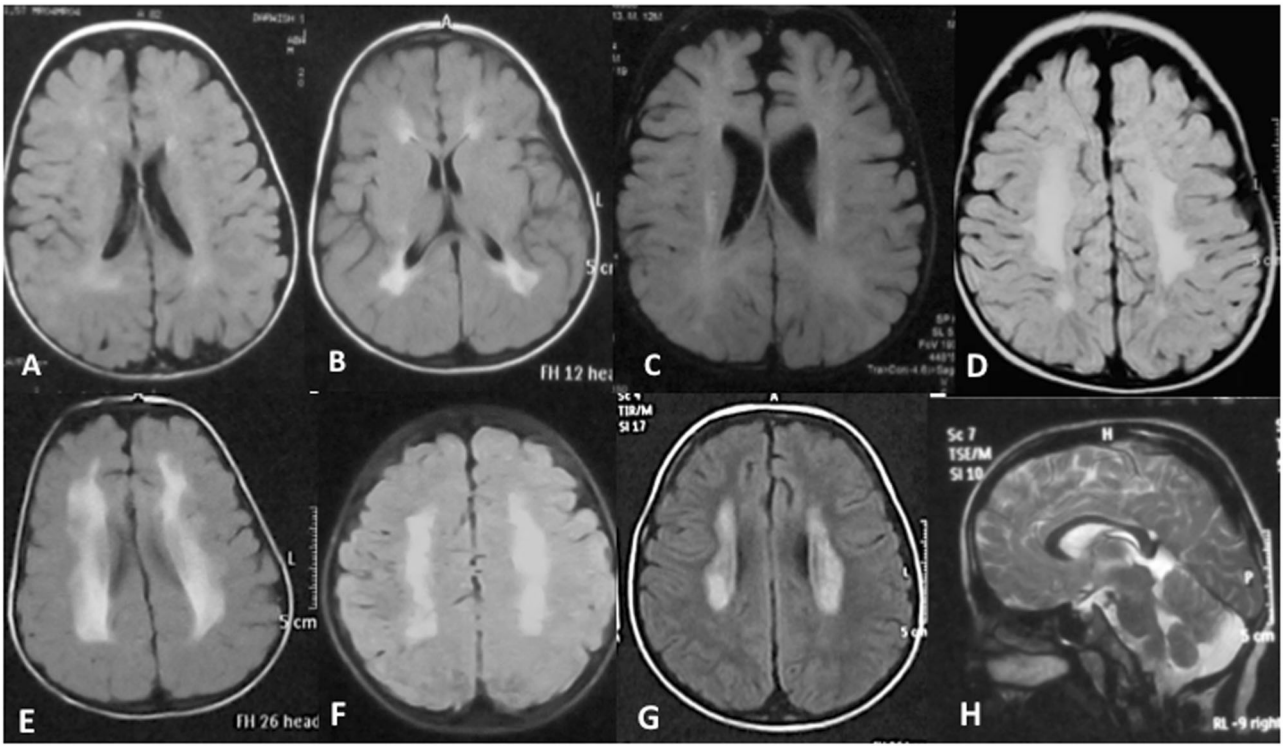

Fig. 1 MRI of patients with SLS. Note axial T2-FLAIR showing variable severity of white matter dysmyelination (**a**–**g**), dialted lateral ventricles (**c**), mild cortical atrophy (**d**). Sagittal T1 (**h**) showing thin corpus callosum

date, more than 200 patients with SLS have been described in the literature generating one of the most common neuroichthyotic disorders [2]. In the current study, we reported the clinical, neuro-radiolgoical and molecular findings of additional 35 patients with SLS from Egypt.

Our patients were derived from 25 unrelated families diagnosed based on the clinical assignment and confirmed by molecular identification of the pathogenic *ALDH3A2* variants. The present patients had the typical clinical and brain imaging characteristic of SLS but with variable clinical severity. Sixteen distinct mutations were detected including eight missense (50%), three splice site (18.75%), one nonsense (6.25%), two inframe deletions (12.5%) and two single exon deletion (12.5%). Of them, 11 mutations were novel: Exon 1 del, c.25 C > T (p.R9*), c.154–2 A > G, c.179 A > T (p.E60V), c.350 T > G (p.L117R), c.369_371delAGG (p.G124del), c.385 + 1 G > C, c.799–1 G > A, c.1067 A > G (p.E356G), c.1198 G > A (p.G400R) and c.1156_1161delAATGAC (p.N386_D387del). All mutations identified were in the homozygous form except Patient 9 who had compound heterozygous mutations (c.385 + 1 G > C and c.1067 A > G; p.E356G). The mutations were distributed across the gene in exons 1, 2, 4, 7 and 8.

The c.1094 C > T (p.S365L) was the most common mutation identified in our study (8 patients from 6 families) with a frequency of 24%. Although these patients were from different governorates in Egypt but all shared some intronic and coding non-synonymous variants strongly suggesting a similar haplotype. The c.1094 C > T (p.S365L) was reported before in few patients from Germany and Italy and expression studies have shown that the mutant FALDH has only 3% residual enzyme activity [4, 9, 10]. Interestingly, it was not reported in non-Caucasians and had been associated in the German and Italian patients with two different haplotypes (haplotypes #1 and #2). The high frequency and the shared haplotype of this mutation in our patients might led us to speculate that it has arisen independently from one ancestor and possibly has a founder effect in our population.

We identified two mutations (c.25 C > T, p.R9* and c.1198 G > A, p.G400R) that were recurrent in our patients with a frequency of 12%. The two mutations were not reported before in the public databases. The c.25 C > T (p.R9*) is located in exon 1 and is predicted to results in early protein truncation. On the other hand, the missense variant c.1198 G > A (p.G400R) is located in exon 8 and affects a fully conserved amino acid residue (Supplementary Fig. 1). Surprisingly, patients carrying the two mutations also shared similar unique haplotypes suggesting also a founder effect (Supplementary Table 3). Similarly, other *ALDH3A2* founder mutations have been described in patients from Sweden, Northern Europe, Middle East, Brazil and Honduras [3, 6, 10–16].

Although majority of the reported *ALDH3A2* mutations were missense, splice site or small indels but we identified two intragenic deletions of exon 1 in Patient 23 and Exon 9 in

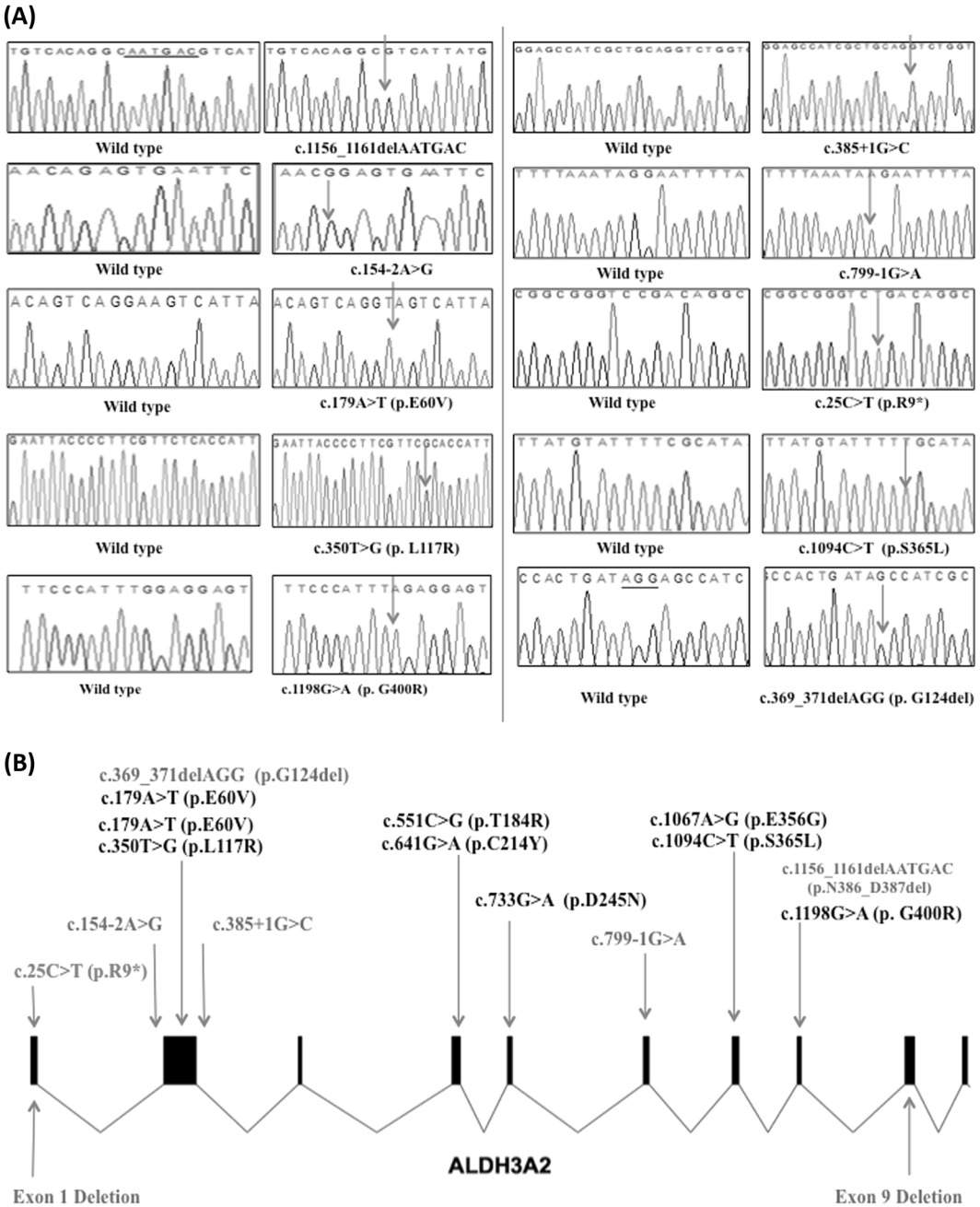

Fig. 2 **a** Portions of the sequencing electropherograms showing the novel *ALDH3A2* variants identified in our patients. The arrow indicates the site of variants. **b** Schematic diagram of the *ALDH3A2* gene showing the 10 coding exons and all variants detected in our study

Patient 30. Large deletions are rarely reported in patients with SLS. Deletions of exon 9 alone, exons 9–10 and exons 1–5 were previously described in three patients with SLS [10, 17, 18]. Moreover, Engelstad and coauthors reported a patient with homozygous deletion of 352-kb deletions involving the *ALDH3A2* and four other genes in addition to another patient with a heterozygous 1.44-Mb contiguous gene deletion in conjugation with another missense mutation [19].

Despite identical genotypes in sibship and families, a marked variability regarding the disease severity was noticed among our patients. We distinguished patients with spastic quadriparesis with few unclear words while in same sibship, cousins harboring the same mutations were ambulant independently with average speech development. This is in accordance with the observation of Davis et al. who described two families with the same mutation and concluded that variation in the neurologic phenotype of SLS is not only determined by the *ALDH3A2* mutation [16]. Formerly, Lossos and coauthors suggested the presence of compensatory factors that may explain the clinical

Table 2 The different *ALDH3A2* gene mutations identified in our patients with SLS

Mutation	Effect on protein	Type of mutation	Location	Frequency	Reference
Exon 1 Del		Large intragenic deletion	Exon 1	1 Patient (homo)	This study
c.25 C > T	p.R9*	Nonsense	Exon 1	4 Patients (homo)	This study
c.154–2 A > G	Affect splicing	Splice site	Intron 1/Exon 2	2 Patients (homo)	This study
c.179 A > T	E60V	Missense	Exon 2	2 Patients (homo)	This study
c.350 T > G	p.L117R	Missense	Exon 2	2 Patients (homo)	This study
c.385 + 1 G > C	Affect splicing	Splice site	Exon 2/Intron 2	1 Patient (Het)	This study
c.369_371delAGG	p.G124del	Inframe del of 1 amino acid	Exon 2	1 Patient (homo)	This study
c.551 C > G	p.T184R	Missense	Exon 4	3 Patients (homo)	[9]
c.641 G > A	p.C214Y	Missense	Exon 4	2 Patients (homo)	[24]
c.733 G > A	p.D245N	Missense	Exon 5	3 Patients (Homo)	[4]
c.799–1 G > A	Affect splicing	Splice site	Intron 5/Exon 6	1 Patient (homo)	This study
c.1067 A > G	p. E356G	Missense	Exon 7	1 Patient (Het)	This study
c.1094 C > T	p.S365L	Missense	Exon 7	8 Patients (homo)	[10]
c.1198 G > A	p.G400R	Missense	Exon 8	3 patients (homo)	This study
c.1156_1161delAATGAC	p.N386_D387del	Inframe del of 2 amino acids	Exon 8	1 Patient (homo)	This study
Exon 9 Del		Large intragenic deletion	Exon 9	1 Patient (homo)	This study

variability among sibs with the same mutation [20]. Therefore, we might speculate that there is no clear phenotype- genotype correlation in SLS and probably other unknown modifier genes, epigenetic or environmental factors or other mechanisms play role in the scenario.

Most of our patients had a plateau stage after a regressive onset of motor and mental milestones similarly to other reports [3, 6, 10, 14, 15, 17, 18, 20]. Nevertheless, severe neuroregression was distinctive in a single patient who had a similar deceased sib at the age of 5 and onset of the disease started at 1 year and 3 months old. Moreover, intellectual disability and cognitive skills were predominantly mild in our patients (45.7%), borderline with manifested learning disabilities in 20%, moderate in 28.6% while one patient had severe disability (2.8%).

Ophthalmological findings were thoroughly investigated in patients with SLS and the extent of macular abnormality was not correlated with the neurological manifestations [21, 22]. Bilateral retinal glistening spots are characteristic in SLS and were reported to increase with age. Glistening spots were present in only 34.2% of our patients which is less than previous reports and this could be explained by the predominant younger age of our patients. Similarly, 34.2% of patients had photophobia which is also a manifestation in a high percentage of patients with this syndrome. Of note, none of our cases had ichthyosis of upper eye lids.

Brain MRI revealed an apparent dysmyelination of white matter which were confluent in all patients and varied in severity among them. Willemsen et al. concluded that these changes posted to accumulation of lipids, periventricular gliosis, delayed myelination, and a permanent myelin deficit [23]. Furthermore, thin corpus callosum was identified in 42.8% of patients, a percentage higher than previous studies [23]. In addition, mild non-progressive cerebellar atrophy and lateral ventricles dilatation were found in 7 (20%) and 10 (28.6%) patients, respectively which is in accordance with the same study.

In conclusion, we reported a large cohort of patients with SLS and identified many novel, recurrent and founder *ALDH3A2* mutations thus expanding the mutational spectrum of the disorder. Some of our patients showed striking phenotypic variability although carrying the same mutation indicating that yet unidentified isozymes, epigenetic factors or modifier genes are involved.

Acknowledgements We thank the patients and their families for participation in this work.

Compliance with ethical standards

Conflict of interest The authors declare that they have no conflict of interest.

Publisher's note: Springer Nature remains neutral with regard to jurisdictional claims in published maps and institutional affiliations.

References

1. Sjogren T, Larsson T. Oligophrenia in combination with congenital ichthyosis and spastic disorders; a clinical and genetic study. Acta Psychiatr Neurol Scand Suppl. 1957;113:1–112.
2. Nagappa M, Bindu PS, Chiplunkar S, Gupta N, Sinha S, Mathuranath PS, et al. Child neurology: Sjögren–Larsson syndrome. Neurology. 2017;88:e1–4.
3. Rizzo WB, Carney G. Sjögren-Larsson syndrome: diversity of mutations and polymorphisms in the fatty aldehyde dehydrogenase gene (ALDH3A2). Hum Mutat. 2005;26:1–10.

4. Didona B, Codispoti A, Bertini E, Rizzo WB, Carney G, Zambruno G, et al. Novel and recurrent ALDH3A2 mutations in Italian patients with Sjögren-Larsson syndrome. J Hum Genet. 2007;52:865–70.
5. Weustenfeld M, Eidelpes R, Schmuth M, Rizzo WB, Zschocke J, Keller MA. Genotype and phenotype variability in Sjögren-Larsson syndrome. Hum Mutat. 2019;40:177–86.
6. Willemsen MA, IJlst L, Steijlen PM, Rotteveel JJ, de Jong JG, van Domburg PH, et al. Clinical, biochemical and molecular genetic characteristics of 19 patients with the Sjogren Larsson syndrome. Brain. 2001;124:1426–37.
7. Rizzo WB, Craft DA, Somer T, Carney G, Trafrova J, Simon M. Abnormal fatty alcohol metabolism in cultured keratinocytes from patients with Sjögren-Larsson syndrome. J Lipid Res. 2008;49: 410–9.
8. Rizzo WB, Dammann AL, Craft DA. Sjögren-Larsson syndrome. Impaired fatty alcohol oxidation in cultured fibroblasts due to deficient fatty alcohol:nicotinamide adenine dinucleotide oxidoreductase activity. J Clin Invest. 1988;81:738–44.
9. Rizzo WB, Carney G, Lin Z. The molecular basis of Sjogren-Larsson syndrome: mutation analysis of the fatty aldehyde dehydrogenase gene. Am J Hum Genet. 1999;65:1547–60.
10. Sillén A, Anton-Lamprecht I, Braun-Quentin C, Kraus CS, Sayli BS, Ayuso C, et al. Spectrum of mutations and sequence variants in the FALDH gene in patients with Sjögren-Larsson syndrome. Hum Mutat. 1998;12:377–84.
11. De Laurenzi V, Rogers GR, Tarcsa E, Carney G, Marekov L, Bale SJ, et al. Sjogren-Larsson syndrome is caused by a common mutation in northern European and Swedish patients. J Invest Dermatol. 1997;109:79–83.
12. Rizzo WB, Carney G, De Laurenzi V. A common deletion mutation in European patients with Sjögren-Larsson syndrome. Biochem Mol Med. 1997;62:178–81.
13. Sillén A, Jagell S, Wadelius C. A missense mutation in the FALDH gene identified in Sjögren-Larsson syndrome patients originating from the northern part of Sweden. Hum Genet. 1997;100:201–3.
14. Kraus C, Braun-Quentin C, Ballhausen WG, Pfeiffer RA. RNA based mutation screening in German families with Sjogren-Larsson syndrome. Eur J Hum Genet. 2000;8:299–306.
15. Auada MP, Puzzi MB, Cintra ML, Steiner CE, Alexandrino F, Sartorato EL, et al. Sjogren-Larsson syndrome in Brazil is caused by a common c.1108-1G > C splice site mutation in the ALDH3A2 gene. Br J Dermatol. 2006;154:770–3.
16. Davis K, Holden KR, S'Aulis D, Amador C, Matheus MG, Rizzo WB. Novel mutation in Sjogren-Larsson syndrome is associated with divergent neurologic phenotypes. J Child Neurol. 2013;28: 1259–65.
17. Bruno DL, Stark Z, Amor DJ, Burgess T, Butler K, Corrie S, et al. Extending the scope of diagnostic chromosome analysis: detection of single gene defects using high-resolution SNP microarrays. Hum Mutat. 2011;32:1500–6.
18. Gaboon NE, Jelani M, Almramhi MM, Mohamoud HS, Al-Aama JY. Case of Sjogren Larsson syndrome with a large deletion in the ALDH3A2 gene confirmed by single nucleotide polymorphism array analysis. J Dermatol. 2015;42:706–9.
19. Engelstad H, Carney G, S'Aulis D, Rise J, Sanger WG, Rudd MK, et al. Large contiguous gene deletions in Sjogren-Larsson syndrome. Mol Genet Metab. 2011;104:356–61.
20. Lossos A, Khoury M, Rizzo WB, Gomori JM, Banin E, Zlotogorski A, et al. Phenotypic variability among adult siblings with Sjögren-Larsson syndrome. Arch Neurol. 2006;63: 278–80.
21. Willemsen MAAP, Cruysberg JRM, Rotteveel JJ, Aandekerk AL, Van Domburg PHMF, Deutman AF. Juvenile macular dystrophy associated with deficient activity of fatty aldehyde dehydrogenase in Sjogren-Larsson syndrome. Am J Ophthal 2000;130:782–9.
22. Jack LS, Benson C, Sadiq MA, Rizzo WB, Margalit E. Segmentation of retinal layers in Sjogren-Larsson syndrome. Ophthalmology. 2015;122:1730–2.
23. Willemsen MA, van der Graaf M, van der Knaap MS, Heerschap A, van Domburg PH, Gabreels FJ, et al. MR imaging and proton MR spectroscopic studies in Sjögren-Larsson Syndrome: characterization of the leukoencephalopathy. AJNR Am J Neuroradiol. 2004;25:649–57.
24. De Laurenzi V, Rogers GR, Hamrock DJ, Marekov LN, Steinert PM, Compton JG, et al. Sjogren–Larsson syndrome is caused by mutations in the fatty aldehyde dehydrogenase gene. Nat Genet. 1996;12:52–7.