Journal of Human Genetics (2019) 64:689–694
https://doi.org/10.1038/s10038-019-0615-3

ARTICLE

Exome sequencing identifies a novel missense variant in *CTSC* causing nonsyndromic aggressive periodontitis

Anne Molitor[1] · Tony Prud'homme[2,3,4] · Zhichao Miao[5,6] · Solène Conrad[7] · Agnès Bloch-Zupan[8,9,10] · Angélique Pichot[1] · Antoine Hanauer[1] · Bertrand Isidor[7] · Seiamak Bahram[1,11] · Raphael Carapito[1,11]

Received: 17 January 2019 / Revised: 12 April 2019 / Accepted: 21 April 2019 / Published online: 8 May 2019

Abstract

Cathepsin C (CatC) is a cysteine protease involved in a variety of immune and inflammatory pathways such as activation of cytotoxicity of various immune cells. Homozygous or compound heterozygous variants in the CatC coding gene *CTSC* cause different conditions that have in common severe periodontitis. Periodontitis may occur as part of Papillon–Lefèvre syndrome (PLS; OMIM#245000) or Haim–Munk syndrome (HMS; OMIM#245010), or may present as an isolated finding named aggressive periodontitis (AP1; OMIM#170650). AP1 generally affects young children and results in destruction of the periodontal support of the primary dentition. In the present study we report exome sequencing of a three generation consanguineous Turkish family with a recessive form of early-onset AP1. We identified a novel homozygous missense variant in exon 2 of *CTSC* (NM_148170, c.G302C, p.Trp101Ser) predicted to disrupt protein structure and to be disease causing. This is the first described *CTSC* variant specific to the nonsyndromic AP1 form. Given the broad phenotypic spectrum associated with *CTSC* variants, reporting this novel variant gives new insights on genotype/phenotype correlations and might improve diagnosis of patients with early-onset AP1.

These authors contributed equally: Seiamak Bahram and Raphael Carapito

Supplementary information The online version of this article (https://doi.org/10.1038/s10038-019-0615-3) contains supplementary material, which is available to authorized users.

✉ Seiamak Bahram
siamak@unistra.fr

✉ Raphael Carapito
carapito@unistra.fr

1 Laboratoire d'ImmunoRhumatologie Moléculaire, plateforme GENOMAX, INSERM UMR_S 1109, Faculté de Médecine, Fédération Hospitalo-Universitaire OMICARE, Fédération de Médecine Translationnelle de Strasbourg (FMTS), LabEx TRANSPLANTEX, Université de Strasbourg, 4 rue Kirschleger, 67085 Strasbourg, France

2 Département d'Odontologie Pédiatrique, UFR Odontologie, Université de Nantes, Nantes, France

3 Unité d'Investigation Clinique Odontologie (UIC), CSERD Nantes, CHU de Nantes, France

4 INSERM, UMR 1246, MethodS in Patients-centered outcomes and HEalth ResEarch, Nantes, France

5 European Molecular Biology Laboratory, European Bioinformatics Institute (EMBL-EBI), Wellcome Genome Campus, Hinxton, Cambridge CD10 1SD, UK

Introduction

Cathepsin C (CatC), also known as dipeptidyl peptidase I, is a papain-like cysteine protease involved in a variety of

6 Wellcome Sanger Institute, Wellcome Genome Campus, Hinxton, Cambridge CB10 1SA, UK

7 Service de Génétique Médicale, Hôpital Hôtel-Dieu, CHU de Nantes, Nantes, France

8 Faculté de Chirurgie Dentaire, Université de Strasbourg, Strasbourg, France

9 Pôle de Médecine et Chirurgie Bucco-Dentaires, Centre de Référence des Manifestations Odontologiques des Maladies Rares, Hôpitaux Universitaires de Strasbourg, Strasbourg, France

10 Institut de Génétique et de Biologie Moléculaire and Cellulaire, CNRS UMR7104, INSERM U964, Centre Européen de Recherche en Biologie et en Médecine, Université de Strasbourg, Illkirch, France

11 Service d'Immunologie Biologique, Plateau Technique de Biologie, Pôle de Biologie, Nouvel Hôpital Civil, 1 place de l'Hôpital, 67091 Strasbourg, France

immune and inflammatory pathways, including activation of granule-associated proinflammatory serine proteinases in T lymphocytes, natural killers, and neutrophils [1]. Besides activation of immune cells, the proteolytic activity of CatC has been proposed to play a role in epithelial differentiation and desquamation [2]. CatC is processed into a proteolytically mature enzyme composed of three subunits (exclusion domain, light, and heavy chain) and acts as tetramers [3]. The exclusion domain is non-covalently attached to the heavy and light chains forming a heterodimeric structure [4].

Homozygous or compound heterozygous loss-of-function variants in the CatC coding gene, *i.e., CTSC*, cause Papillon–Lefèvre syndrome (PLS; OMIM#245000), a rare condition characterized by the combination of diverse degrees of palmoplantar keratoderma and prepubertal aggressive periodontitis leading to premature loss of both deciduous and permanent dentition [2, 5]. To date, over 75 causal variants have been identified in ethnically diverse populations [6]. While the vast majority (~97%) of the described variants cause typical PLS, a broad phenotypic spectrum has been described [6, 7]. *CTSC* variants have indeed also been reported in patients with Haim–Munk syndrome (HMS; OMIM#245010) that is characterized by palmoplantar hyperkeratosis, periodontal inflammation, arachnodactly, acroosteolysis, pesplanus, and onychogryposis [8]. In addition, *CTSC* variants were associated with isolated aggressive periodontitis (AP1; OMIM#170650), a nonsyndromic form of periodontitis which also leads to tooth loss due to severe periodontal inflammation [7, 9]. While additional genetic or environmental factors probably impact the expression of the disease [10, 11], the observed phenotypic heterogeneity, sometimes even observed for the same variant, complicates differential clinical diagnosis [7, 8, 12]. Despite the important number of known variants, to date no *CTSC* variant has been reported to be causing only AP1 without being also associated with the syndromic form PLS in other families.

In the present study we report a novel homozygous missense mutation in the *CTSC* gene (NM_148170; c.G302C; p.Trp101Ser) identified by whole exome sequencing in a three generations consanguineous Turkish family with AP1.

Subjects and methods

Subjects and whole exome sequencing

The subjects reported in this study were members of a three generation consanguineous family of Turkish origin. To determine the genetic etiology of aggressive periodontitis within the family we performed whole exome sequencing of the affected son (III-c, proband), his affected mother (II-b), as well as of four non-affected relatives: paternal grandmother (I-a), father (II-a), and two sisters (III-a, b). All subjects gave written informed consent to participate in the study. Genomic DNA was isolated from peripheral blood using standard protocols. The TruSeq Exome Kit (Illumina, San Diego, CA, USA) was used for the preparation and enrichment of exonic DNA libraries. Paired-end (2 × 75 bp) sequencing was performed on a NextSeq500 sequencer (Illumina, San Diego, CA, USA).

Variant analysis strategy

Sequence data was mapped on the hg19 reference genome using Isaac Genome Alignment Software 2.1.0 (Illumina, San Diego, CA, USA). For each sample, median coverage was at least 190-fold, and over 97% of target sequences were covered at a minimum of 10× (Supp. Table 1). Sequence variants were called using the Isaac Variant Caller 2.1.0 (Illumina, San Diego, CA, USA). Annotation was performed with the KGGSeq software package based on dbSNP build 135 [13]. Consecutive filtering steps were applied to variants identified in the proband (III-c) in order to focus on: (i) low frequency variants (minor allele frequency < 0.005 in 1000 Genomes project (http://www.internationalgenome.org/1000-genomes-browsers/), the genome aggregation database (gnomAD; http://gnomad.broadinstitute.org/), and an internal exome database with ~600 exomes accessed in october 2018); (ii) protein-altering variants (noncoding and synonymous variants were excluded); (iii) variants compatible with a recessive mode of transmission.

Targeted sequencing

Conventional capillary Sanger sequencing was performed to analyze and validate the genotype of the identified candidate variant in all family members. A 254 bp fragment spanning the missense mutation in position chr11:88068121 was amplified using the Expand Long Template PCR System (Roche Diagnostics, Rotkreuz, Switzerland) according to the manufacturer's recommendations and using the following PCR primers, forward: 5′-AGTGGTGTACCTTCA GAAGCTGGATACA-3′; reverse: 5′-GGGAAGAGTGGT GTCAATTCCGGT-3′. After purification with the Exostar Kit (GE Healthcare Life Sciences, Marlborough, MA, USA), PCR products were bidirectionally sequenced using the same primers and the Big Dye Terminator Kit v3.1 (Thermo Fisher Scientific, Waltham, MA, USA). All targeted sequencing reactions were run on an ABI PRISM 3730xl (Thermo Fisher Scientific, Waltham, MA, USA).

3D modeling of CatC variants

The crystal structure solved at 1.4 Å, PDB 4OEL [14], was used as the model structure for the analysis. Structure visualization, distance measurement, and mutagenesis

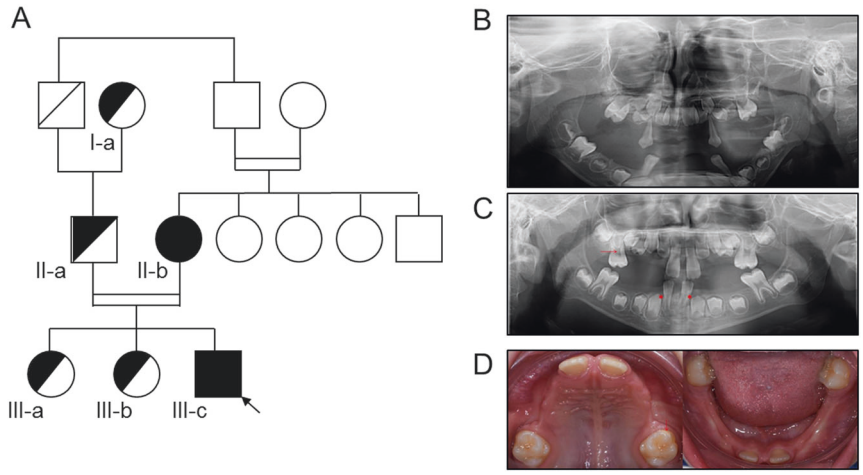

Fig. 1 Pedigree and clinical findings. **a** Pedigree of the three generation consanguineous family with autosomal recessive inheritance of aggressive periodontitis. DNA from individuals indicated by numbers was analyzed by whole exome and Sanger sequencing. The arrow denotes the proband. Solid symbols refer to affected individuals, half-solid symbols indicate unaffected, heterozygote carriers of the variant. **b–d** Clinical findings in proband (III-c). Orthopantomogram at the age of 4 (**b**) and 6 years (**c**). Photograph at the age of 6 years (**d**). Additional dental abnormalities are highlighted: hypodontia (*), taurodontism (→), and hypomineralization (↓)

analysis were performed with the *PyMOL* program (DeLano Scientific, San Carlos, CA, USA). The *RASP* program was used for side-chain analysis [15].

Results

Clinical report

The index patient is a 6-year-old boy from a consanguineous family of Turkish origin. His parents are first cousins and his mother was also born from related parents (Fig. 1a). Premature loss of deciduous teeth started at the age of 3 years and a first orthopantomogram was performed at the age of 4 (Fig. 1b). At that time, deciduous teeth, except canines were prematurely lost. Oral hygiene was progressively introduced and mechanical periodontal treatment (root scaling with ultrasonic devices) as well as intensive maintenance therapy was combined to prevent adverse periodontal evolution [16, 17]. At the time of last examination (6 years of age), the patient presented his four permanent first molars and central incisors without detectable mobility or probing depths >2 mm (Fig. 1c, d). The patient showed additional dental abnormalities: hypodontia (agenesis of the two mandibular lateral incisors), taurodontism on the first right maxillary molar and molar incisor hypomineralization (Fig. 1c, d). Except aggressive periodontitis, physical, and intellectual development was unremarkable. Pregnancy, delivery, and neonatal period were normal except that the umbilical cord fell off relatively late (1 month). Language delay with absence of sentence construction was observed at the age of 3 years, motor development was normal. Complete blood count was normal, and the patient had no history of infections at the time of presentation. Importantly, no signs of palmoplantar hyperkeratosis could be detected.

The patient's mother (II-b; 39 years old) presented, according to her statements, severe periodontitis in early childhood, requiring dental implants, bone graft, and dental prosthesis early in adolescence (Supp. Fig. 1a). Other relatives, paternal grandmother (I-a), father (II-a), and sisters (III-a, III-b) were clinically unaffected (Supp. Fig. 1b–d). The first sister (16 years old, III-a) however showed slight gingivitis and small restorations (Supp. Fig. 1c). The second sister (14 years old, III-b) showed slight gingivitis, small restorations, and microdontia on the right maxillary lateral incisor (Supp. Fig. 1d).

Whole exome sequencing and variant interpretation

We used whole exome sequencing to identify pathogenetic variants with autosomal recessive inheritance in a three generation consanguineous family of Turkish origin with isolated AP1. Appling a consecutive filtering strategy based on variant frequency, functional consequences on coding sequence and heredity, a single missense variant in the *CTSC* gene was uncovered (NM_148170; c.G302C; p.Trp101Ser). This suspected pathogenic variant was confirmed by Sanger sequencing. It was found homozygous in the two affected individuals (patients III-c and II-b), while clinically unaffected family members (I-a, II-a, III-a, b) were heterozygous carriers of the variant (Fig. 2). To our best knowledge the missense variant has not been reported so far and is absent in public databases including the 1000 Genomes project (http://www.internationalgenome.org/1000-genomes-browsers/), the genome aggregation

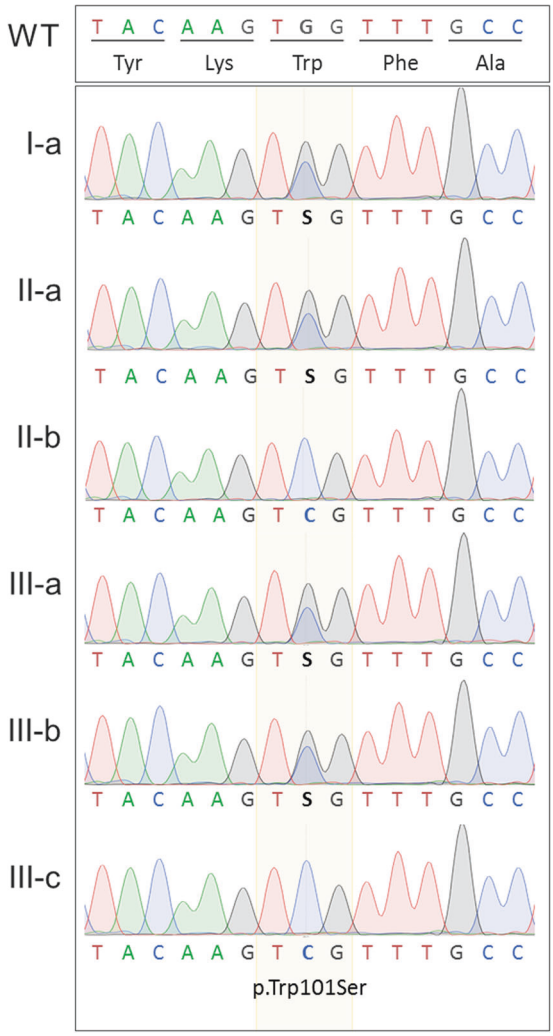

Fig. 2 Sanger validation of the disease associated c.G302C missense mutation. The electropherograms show single base pair substitutions G302C of the *CTSC* coding sequence (NM_148170). Affected individuals (II-a and III-c) are homozygous, all unaffected individual (I-a, II-a, III-a) are heterozygous carriers of the nucleotide substitution

database (gnomAD; http://gnomad.broadinstitute.org/) and our internal exome database with ~600 exomes. Moreover, the variant is highly conserved and predicted to be disease causing by several bioinformatics tools (Table 1).

The substituted residue, Trp101 is localized at the interface between the exclusion domain and the light and heavy chains of the mature CatC enzyme (Fig. 3a). Trp101 forms π–π interactions with Phe78, Trp110, and Tyr270, where lies the hydrophobic core of the protein complex. It may form a water-mediated sulfhydryl bond with Cys30 (at a distance of 3.6 Å) that stabilizes the structure of the CatC monomer (Fig. 3b). The Trp101Ser substitution is predicted to disrupt the π–π interaction based hydrophobic core and destruct the intimate interaction with Cys30, destabilizing both the three-dimensional structure of the exclusion domain and its interaction with the light and heavy chains of the mature CatC enzyme, which suggest complete or at least partially reduced enzyme function.

Table 1 Details of the variant of interest

Position (GRCh37/hg19)	Chr11:88068121
Gene symbol	*CTSC*
Refseq number	NM_001814.4
Nucleotide alteration	G>C
Genotypes of subjects	
I-a	G/C
II-a	G/C
II-b	C/C
III-a	G/C
III-b	G/C
III-c (proband)	C/C
Mutation type	Missence
Coding sequence alteration	c.302G>C
Amino acid alteration	p.Trp101Ser
GERP++[a]	5.840
PhyloP[b]	3.879
Polyphen[c]	0.999
MutationTaster	Disease causing

[a]GERP++NR score: DNA conservation score. Deleterious threshold: >4.4

[b]Values vary between −14 and +6. Sites predicted to be conserved are assigned positive scores, while sites predicted to be fast-evolving are assigned negative scores

[c]Polyphen2_HDIV_score: variants with scores between 0.85 and 1.0 are highly confidently predicted to be damaging

Discussion

In the present study, we identified by whole exome sequencing a novel homozygous missense variant in the CatC coding gene *CTSC* (NM_148170; c.G302C; p.Trp101Ser) causing isolated AP1 in a consanguineous family of Turkish origin.

Most homozygous or compound heterozygous *CTSC* variants reported in the literature are associated with PLS. To date, only three studies reported *CTSC* variants (p.Tyr347Cys, p.Arg272His, and p.Thr189fs*10) associated with the non-syndromic form AP1 [7, 9, 12]. All of these variants have however also been reported by other groups in the context of PLS [2, 18–20], suggesting that these variants may rather be linked to PLS with variable penetrance.

Here we report the first variant that is associated with only AP1 and no other syndromic form. The absence of skin manifestations cannot be explained by a potentially weak *CTSC* mutation, since predictive bioinformatics tools and the predicted effect of the Trp101Ser substitution on protein structure suggest a dramatic impact on CatC function. This

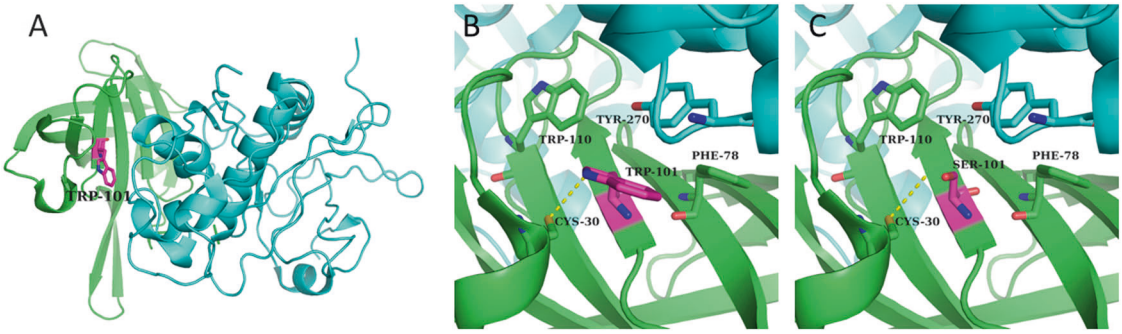

Fig. 3 Predicted impact of the Trp101Ser substitution on CatC protein structure. **a** The CatC structure forms a beta-barrel (shown in green) in complex with its substrates (shown in cyan), while the mutant residue Trp101 is highlighted in magenta. **b** In the wild-type structure, the Trp110 (magenta) is surrounded by the hydrophobic residues Phe78 and Trp110 from CatC and Tyr270 from the substrates, while Trp101 is also in intimate contacts with Cys30 at a contact distance of 3.6 Å. **c** When mutated to Ser101, which has a hydrophilic side-chain, not only all the hydrophobic interactions, but also the interaction with Cys30 was disabled

observation is in line with previous functional studies reporting significantly reduced CatC activity regardless of the phenotypic penetrance in PLS patients [7]. We can however not exclude that the Trp101Ser variant could potentially lead to PLS in other so far unknown cases.

In conclusion, our finding might contribute to decipher the complex genotype–phenotype correlation of *CTSC* pathogenicity. Furthermore, it highlights the importance to consider *CTSC* in genetic screening of subjects or families with aggressive periodontitis without other symptoms.

Acknowledgements This work was supported by grants from the Agence Nationale de la Recherche (ANR) (ANR-11-LABX-0070_TRANSPLANTEX), INSERM UMR _ S1109; the Institut Universitaire de France (IUF); and MSD Avenir grant (all to SB); the University of Strasbourg (IDEX UNISTRA, to RC and SB); and the INTERREG V European regional development fund (European Union) program (project 3.2 TRIDIAG, to RC, and SB).

Compliance with ethical standards

Conflict of interest The authors declare that they have no conflict of interest.

Publisher's note: Springer Nature remains neutral with regard to jurisdictional claims in published maps and institutional affiliations.

References

1. Perisic Nanut M, Sabotic J, Jewett A, Kos J. Cysteine cathepsins as regulators of the cytotoxicity of NK and T cells. Front Immunol. 2014;5:616.
2. Toomes C, James J, Wood AJ, Wu CL, McCormick D, Lench N, et al. Loss-of-function mutations in the cathepsin C gene result in periodontal disease and palmoplantar keratosis. Nat Genet. 1999;23:421–4.
3. Turk D, Janjic V, Stern I, Podobnik M, Lamba D, Dahl SW, et al. Structure of human dipeptidyl peptidase I (cathepsin C): exclusion domain added to an endopeptidase framework creates the machine for activation of granular serine proteases. EMBO J. 2001;20:6570–82.
4. Olsen JG, Kadziola A, Lauritzen C, Pedersen J, Larsen S, Dahl SW. Tetrameric dipeptidyl peptidase I directs substrate specificity by use of the residual pro-part domain. FEBS Lett. 2001;506:201–6.
5. Haneke E. The Papillon–Lefevre syndrome: keratosis palmoplantaris with periodontopathy. Report of a case and review of the cases in the literature. Hum Genet. 1979;51:1–35.
6. Nagy N, Valyi P, Csoma Z, Sulak A, Tripolszki K, Farkas K, et al. CTSC and Papillon–Lefevre syndrome: detection of recurrent mutations in Hungarian patients, a review of published variants and database update. Mol Genet Genom Med. 2014;2:217–28.
7. Hewitt C, McCormick D, Linden G, Turk D, Stern I, Wallace I, et al. The role of cathepsin C in Papillon–Lefevre syndrome, prepubertal periodontitis, and aggressive periodontitis. Hum Mutat. 2004;23:222–8.
8. Hart TC, Hart PS, Michalec MD, Zhang Y, Firatli E, Van Dyke TE, et al. Haim–Munk syndrome and Papillon–Lefevre syndrome are allelic mutations in cathepsin C. J Med Genet. 2000;37:88–94.
9. Hart TC, Hart PS, Michalec MD, Zhang Y, Marazita ML, Cooper M, et al. Localisation of a gene for prepubertal periodontitis to chromosome 11q14 and identification of a cathepsin C gene mutation. J Med Genet. 2000;37:95–101.
10. Sulak A, Toth L, Farkas K, Tripolszki K, Fabos B, Kemeny L, et al. One mutation, two phenotypes: a single nonsense mutation of the CTSC gene causes two clinically distinct phenotypes. Clin Exp Dermatol. 2016;41:190–5.
11. Janjua SA, Iftikhar N, Hussain I, Khachemoune A. Dermatologic, periodontal, and skeletal manifestations of Haim-Munk syndrome in two siblings. J Am Acad Dermatol. 2008;58:339–44.
12. Noack B, Gorgens H, Schacher B, Puklo M, Eickholz P, Hoffmann T, et al. Functional Cathepsin C mutations cause different Papillon–Lefevre syndrome phenotypes. J Clin Periodontol. 2008;35:311–6.
13. Li MX, Gui HS, Kwan JS, Bao SY, Sham PC. A comprehensive framework for prioritizing variants in exome sequencing studies of Mendelian diseases. Nucleic Acids Res. 2012;40:e53.
14. Rubach JK, Cui G, Schneck JL, Taylor AN, Zhao B, Smallwood A, et al. The amino-acid substituents of dipeptide substrates of cathepsin C can determine the rate-limiting steps of catalysis. Biochemistry. 2012;51:7551–68.
15. Miao Z, Cao Y, Jiang T. RASP: rapid modeling of protein side chain conformations. Bioinformatics. 2011;27:3117–22.
16. Wiebe CB, Hakkinen L, Putnins EE, Walsh P, Larjava HS. Successful periodontal maintenance of a case with Papillon–Lefevre syndrome: 12-year follow-up and review of the literature. J Periodontol. 2001;72:824–30.

17. Nickles K, Schacher B, Ratka-Kruger P, Krebs M, Eickholz P. Long-term results after treatment of periodontitis in patients with Papillon–Lefevre syndrome: success and failure. J Clin Periodontol. 2013;40:789–98.
18. Zhang Y, Hart PS, Moretti AJ, Bouwsma OJ, Fisher EM, Dudlicek L, et al. Biochemical and mutational analyses of the cathepsin c gene (CTSC) in three North American families with Papillon Lefevre syndrome. Hum Mutat. 2002;20:75.
19. Lefevre C, Blanchet-Bardon C, Jobard F, Bouadjar B, Stalder JF, Cure S, et al. Novel point mutations, deletions, and polymorphisms in the cathepsin C gene in nine families from Europe and North Africa with Papillon–Lefevre syndrome. J Investig Dermatol. 2001;117:1657–61.
20. Eickholz P, Kugel B, Pohl S, Naher H, Staehle HJ. Combined mechanical and antibiotic periodontal therapy in a case of Papillon–Lefevre syndrome. J Periodontol. 2001;72:542–9.