



Correction: *PLA2G6*-associated neurodegeneration presenting as a complicated form of hereditary spastic paraplegia

Kishin Koh¹ · Yuta Ichinose¹ · Hiroyuki Ishiura² · Haitian Nan¹ · Jun Mitsui³ · Junya Takahashi⁴ · Wakiro Sato⁵ · Yoshiaki Itoh⁶ · Kyoko Hoshino⁷ · Shoji Tsuji^{3,8} · Yoshihisa Takiyama¹ · Japan Spastic Paraplegia Research Consortium

Published online: 9 November 2018

© The Author(s) under exclusive licence to The Japan Society of Human Genetics 2018

Correction to: *Journal of Human Genetics* <https://doi.org/10.1038/s10038-018-0519-7>; published online 09 October 2018

table of this article should have read as below. This has now been corrected in the PDF and HTML versions of the article. The authors apologize for any inconvenience caused.

The originally published version of this article contained an error in Fig. 1 and Table 2. The correct figure and

✉ Yoshihisa Takiyama
ytakiyama@yamanashi.ac.jp

¹ Department of Neurology, Interdisciplinary Graduate School of Medicine and Engineering, University of Yamanashi, Yamanashi, Japan

² Department of Neurology, Graduate School of Medicine, The University of Tokyo, Tokyo, Japan

³ Department of Molecular Neurology, The University of Tokyo, Tokyo, Japan

⁴ Department of Pediatrics, National Mie Hospital, Mie, Japan

⁵ Department of Immunology, National Institute of Neuroscience, National Center of Neurology and Psychiatry, Tokyo, Japan

⁶ Department of Neurology, Osaka City University, Osaka, Japan

⁷ Department of Pediatrics, Minamiwakayama Medical Center, Wakayama, Japan

⁸ International University of Health and Welfare Graduate School, Chiba, Japan

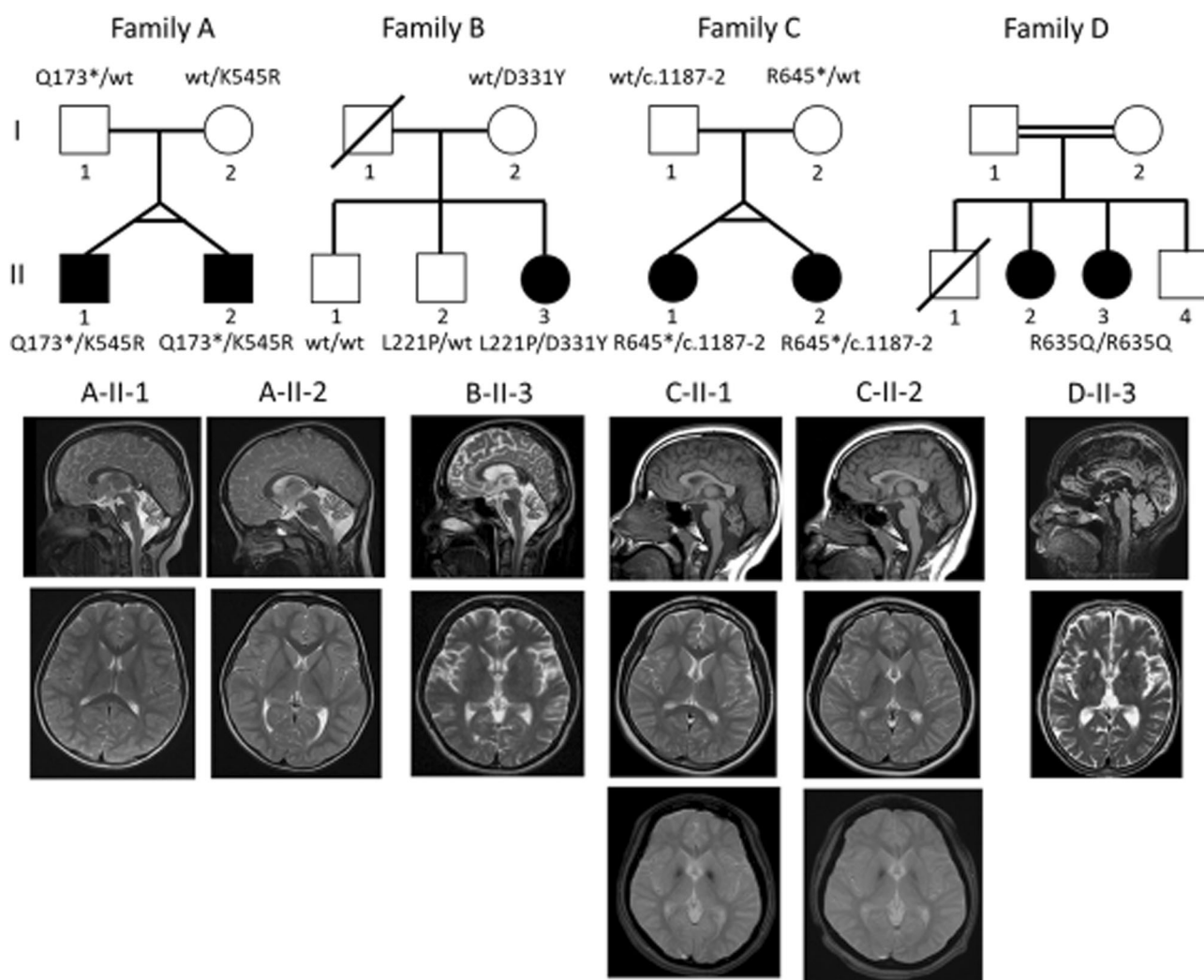


Fig. 1

Table 2

Patient	A-II-1	A-II-2	B-II-3	C-II-1	C-II-2	D-II-3
Age of onset (y.o.)	Infantile	Infantile	10	1	1	66
Gender	Male	Male	Female	Female	Female	Female
Initial symptoms	Gait impairment	Gait impairment	Gait impairment	Mental retardation	Mental retardation	Gait impairment
Pyramidal signs	+	+	+	+	+	+
Cerebellar ataxia	+	+	+	–	–	–
Extrapyramidal signs	–	–	+	–	–	+
Mental retardation	+	+	+	+	+	–
Cerebellar atrophy on brain MRI	+	+	+	+	+	–
Modified rankin scale	4	4	5	4	4	2