

16

THREE DIMENSIONAL OPTICAL IMAGING OF NEONATAL BRAIN ACTIVATION

T. AUSTIN¹, A.P. GIBSON², N.L. EVERDELL², J.C. HEBDEN², M. SCHWEIGER³, S.R. ARRIDGE³, J.H. MEEK¹, J.S. WYATT¹ ¹DEPARTMENT OF PAEDIATRICS & CHILD HEALTH, UNIVERSITY COLLEGE LONDON, ²DEPARTMENT OF MEDICAL PHYSICS & BIOENGINEERING, UNIVERSITY COLLEGE LONDON, ³DEPARTMENT OF COMPUTER SCIENCE, UNIVERSITY COLLEGE LONDON (UK)

BACKGROUND The ability to assess cerebral function at the bedside is important for our understanding of brain development in the newborn. Existing electrophysiological and optical techniques primarily measure activity near the surface of the brain, with little depth information. We have developed an optical imaging system which is able to interrogate the entire three dimensional volume of the brain.

AIMS The aim of the study was to image regional changes in haemodynamics due to functional activation.

METHODS Six preterm infants born at a median (range) postmenstrual age of 29 (29–32) weeks were studied at 38 (28–40) days of age. The stimulus involved repeatedly raising and lowering the left and right arm in turn at a frequency of 1Hz. Optical data was collected using a custom built multichannel time-resolved optical imaging system¹. Baseline data was collected for 10 seconds, before a 15 second stimulus. In order to generate 3D images each light source had to be activated sequentially. A total of 12 sources were used and therefore the stimulus was repeated 12 times. Images were generated using a linear reconstruction algorithm.

RESULTS Responses were obtained from 4 of the 6 infants. This consisted of an increase in the contralateral hemisphere of oxyhaemoglobin ([HbO₂]), deoxyhaemoglobin ([Hb]) and total haemoglobin ([HbT]). The peak response occurred a mean distance of 10.8mm from the estimated position of the primary motor cortex. The mean (± SD) increase in [HbO₂], [Hb] and [HbT] were 25±17µM, 27±20µM, and 25±11µM, respectively.

DISCUSSION This study represents the first successful attempt at reconstructing three dimensional images of functional activation from the neonatal brain. This technique will allow events deep within the brain to be imaged at the bedside and has the potential to reveal novel information on cerebral function in infants at high risk of brain injury.

¹Schmidt FEW et al. Rev Sci Instrum. 2000;71:256–265.

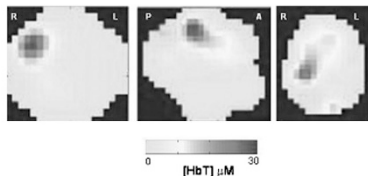


Figure 1 Coronal, parasagittal and transverse images of changes in total haemoglobin concentration ([HbT]) following passive movement of the left arm.

17

RELATIONSHIP BETWEEN CEREBRAL OXYGEN DELIVERY, CEREBRAL METABOLIC RATE AND THE MEAN CEREBRAL OXYGEN SATURATION IN PRETERM INFANTS

T. AUSTIN¹, T. LEUNG², F. WONG¹, C.E. ELWELL², J. HENTY², J.H. MEEK¹, J.S. WYATT¹ ¹DEPARTMENT OF PAEDIATRICS & CHILD HEALTH, UNIVERSITY COLLEGE LONDON, ²DEPARTMENT OF MEDICAL PHYSICS & BIOENGINEERING, UNIVERSITY COLLEGE LONDON (UK)

BACKGROUND Ensuring the adequacy of cerebral oxygen delivery to meet metabolic demand is important in the brain orientated care of newborn infants. Spatially resolved near-infrared spectroscopy (SRS) is an optical method which provides quantitative measurement of the mean cerebral oxygen saturation (SmcO₂) at the bedside¹. SmcO₂ is dependent on both cerebral oxygen delivery and consumption.

AIM The aim of this study was to use measurements of SmcO₂ obtained by SRS and cerebral blood flow (CBF) measured using differential spectroscopy to obtain absolute values of cerebral oxygen delivery (CDO₂) and cerebral metabolic rate (CMRO₂) during the first hours of life in a cohort of preterm infants undergoing intensive care.

METHODS Fifteen preterm infants born at a median (range) postmenstrual age of 25 (23–31) weeks were studied. Their median birthweight was 806 (512–1800)g and the median age at study was 12 (4–35) hours of age. All infants required ventilatory support. SmcO₂ data was collected using a NIRO300 spectrophotometer (Hamamatsu Photonics, K.K., Japan). Cerebral blood flow (CBF) was measured using the oxygen bolus technique. CMRO₂ was calculated from SmcO₂ and CBF².

RESULTS The median (range) SmcO₂ was 56.7 (46.6–78.5%), CDO₂ 1.35 (0.88–3.62) ml O₂/100g/min, CMRO₂ 0.64 (0.36–1.73) ml O₂/100g/min. There was a significant linear relationship between CMRO₂ and CDO₂ (r=0.7, p=0.004). There was also a significant correlation between SmcO₂ and age at study (r=0.63, p=0.01).

DISCUSSION The values of CMRO₂ obtained using this technique are low, but consistent with other studies in the newborn. There is evidence of some degree of perfusion-metabolism coupling in extremely preterm infants in the first hours of life. Infants with a very low SmcO₂ as a result of a mismatch between CDO₂ and CMRO₂ may be more vulnerable to hypoxic-ischaemic brain injury.

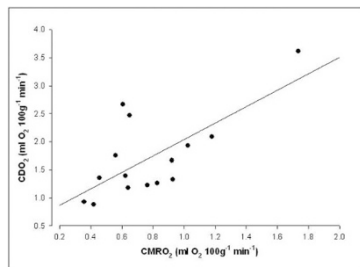


FIGURE 1 Relationship between cerebral oxygen delivery (CDO₂) and cerebral metabolic rate (CMRO₂).

¹Matcher S.J. et al. Proc SPIE. 1995;2389:486–495.

²Elwell C.E. et al. Adv Exp Med & Biol 2005: in press.

18

ULTRASTRUCTURAL ALTERATIONS OF PLACENTAL TISSUE AFTER 6H OF HYPOXIC DUAL IN VITRO PLACENTA PERFUSION

N. BACHMAIER¹, K. LINNEMANN¹, S. KUNO¹, R. WARZOK², K. MAY¹, N. SIEBERT¹, C. FUSCH¹ ¹DEPARTMENT OF NEONATOLOGY AND PAEDIATRIC INTENSIVE CARE, UNIVERSITY OF GREIFSWALD, ²INSTITUTE OF PATHOLOGY, UNIVERSITY OF GREIFSWALD (GERMANY)

Background: Periparturient asphyxia affects the foetus and the placenta with its functions. This can be studied by the dual in vitro placenta perfusion model enabling the separated ex vivo perfusion of maternal and foetal circulation and simulating asphyxia.

Aim: Examination of placental villous ultrastructure by electron microscopy before and after 6h of dual in vitro placenta perfusion with defined hypoxia to study whether morphological alterations could indicate a loss of placental function.

Methods: Placentae (n=20) after normal pregnancies were studied. Written informed consent was obtained. Villous tissue was sampled before and after 6h of normoxic (pO₂ 80–90mmHg, n=10) or hypoxic (pO₂ = 20–30mmHg, n=10) placenta perfusion. Fixation, embedding, preparation of semi- and ultrathin sections. Systematic investigation by electron microscopy of terminal villous syncytiotrophoblast with its substructures mitochondria, rough and smooth endoplasmic reticulum (ER), nucleus, golgi-apparatus and microvilli. Glucose consumption, lactate production, creatinine and antipyrin permeability as well as leptin- and hCG-release were used as control parameters during perfusion.

Results: Terminal villi of all examined placentae showed intact substructures before and after normoxic perfusion. After 6h of hypoxic placenta perfusion the terminal villi demonstrated morphological alterations: villous stroma was oedematous, cell organelles (mitochondria, ER) swollen or completely degenerated, syncytiotrophoblast interspersed with multiple vacuoles and microvilli slenderly extended or partly cut off. The foetal blood vessels appeared narrow with luminal orientated endothelial cells nuclei. The morphological results correlated with the functional data.

Conclusion: 6h of hypoxic dual in vitro placenta perfusion induces degenerative alterations of terminal villi which may impair the placental barrier and placental function.

19

MATERNAL ALLOIMMUNIZATION AND HEMOLYTIC DISEASE: ITALIAN AND FOREIGN IMMIGRANT NEWBORNS

R. BAGNA¹, S. GARBARINI¹, G. PRANDI¹, T. TESTA¹, E. BERTINO¹, A. COSCIA¹, M. PAVAN², C. FABRIS¹ ¹CATEDRA DI NEONATOLOGIA - DIPARTIMENTO DI SCIENZE PEDIATRICHE E DELL'ADOLESCENZA, ²DIPARTIMENTO G DI MEDICINA TRASFUSIONALE- AZIENDA OSPEDALIERA O.I.R.M.- S. ANNA (ITALY)

The aim of this work is to present 40 newborns affected by alloimmunization: 26 Italians (0.18%) and 14 foreign immigrants (0.56%). 23 of them had anti D antibodies, 10 anti D+C, 1 anti D+C+E, 4 anti c, 1 anti jka, 1 anti Kell. 12 italians newborns had anti D antibodies, 7 anti D+C, 1 anti D+C+E, 4 anti c, 1 anti Kell, 1 anti jka. 11 foreign immigrants newborns had anti D antibodies, 3 anti D+C. Exchange transfusion (ET), immunoglobulin infusion, phototherapy, and red cell transfusion (T) were performed depending on the severity of the immunization. Italian women direct Coombs' titer was <1/4096, foreign immigrants women's was >1/64. A titer >1/8000 was found only in foreign immigrants women. 9 patients required fetal transfusions (FT). Mean gestational age was 36.2 weeks, mean neonatal weight was 2795 grams. Mean hemoglobin at birth was 14.2 g/dl. Mean hematocrit was 41.6%. 15 newborns received 1 ET. Greatest bilirubin value was 39 mg/dl. After discharge blood samples were collected every 3 weeks for hemoglobin, hematocrit, reticulocyte count and direct Coombs test. All the patients presented regular neurologic development and growth. 15 newborns required at least 1 T. According to our experience, a newborn requires FT if Coombs' titer of the mother at birth is >1/256, ET if it is >1/128, T if it is >1/128. It was always performed one of them if the titer was >1/2048. Because a increasing number of foreign immigrants, the incidence of Rh isoimmunization is raising. Foreign immigrants newborns developed the majority of alloimmunization because of the lack of maternal prophylaxis, with highest titers and most severe illnesses. It would be important to create an international screening and prophylaxis program in order to obtain again a reduction of Rh isoimmunization and to avoid fetal death and severe handicap.

20

PREMATURITY AND BREAST MILK: A NEW METHOD TO EVALUATE ITS PROTEIN CONTENT

ME BALDASSARRE¹, F. INDRIO¹, ML VALENZANO¹, L. MARVULLI¹, FG RUSSO¹, A. MAUTONE¹, M. DELVECCHIO¹, N. LAFORGIA¹ ¹DEPARTMENT OF PEDIATRIC NEONATOLOGY SECTION UNIVERSITY OF BARI (ITALY)

Preterm newborns frequently have a slow postnatal growth and a close relationship between growth and both energy and protein intake has been demonstrated. The evaluation of the protein content of breast milk after a preterm delivery, using a quick and simple method, could be very useful to decide how to reach preterm nutritional needs. To evaluate the protein content of preterm breast milk by turbidimetric method. From April 2003 to March 2005 we collected breast milk from mothers who delivered preterm (G.A.24.8–35wks). The protein content (PC) in colostrum, transition milk (3 days after the beginning of lactation), and mature milk (1 week after the beginning of lactation) was measured. Maternal age, parity, diet, social status, as well as the cause of premature delivery, the mode of delivery, and gemellarity have been recorded. Milk was stored in plastic bottles at 4 C (max 12 hours) or at -20 C. PC was measured by a modified turbidimetric Kingsbury method (Milk screen, Callegari, Italy). 97 milk samples were collected. PC was 1.39–2.13 g/dl in colostrum, 1.23–2.04 g/dl in transition milk and 1.26–2.01 g/dl in mature milk. These results are consistent with published data using a spectrophotometric method, a technique neither simple nor easily available. PC gradually diminished from the beginning of lactation until mature milk: colostrum PC was higher compared to both transition milk (p=0.014) and mature milk (p=0.0001); similarly, transition milk PC was higher compared to mature milk (p=0.001). A positive correlation has also been found between colostrum and transition milk PC. No correlations have been found between breast milk PC with other factors considered.

REFERENCES

Adv Exp Med Biol 2001; 501: 409.

Br J Nutr 2002; 88: 29.

Acta Paediatr 2001; 90: 772.