

Enzyme Augmentation in Moderate to Life-Threatening Gaucher Disease

SHARI FALLET, MARIE E. GRACE, ARLYN SIBILLE, DAVID S. MENDELSON,
ROBERT S. SHAPIRO, GEORGE HERMANN, AND GREGORY A. GRABOWSKI

*Department of Pediatrics, Division of Medical and Molecular Genetics [S.F., M.E.G., A.S., G.A.G.], and
Department of Radiology [D.S.M., R.S.S., G.H.], Mount Sinai School of Medicine,
New York, New York 10029-6574*

ABSTRACT. Gaucher disease type 1 (GD type 1) is the most prevalent lysosomal storage disease and has its highest frequency in the Ashkenazi Jewish population. Deficiency of the enzyme, acid β -glucosidase, results in the deposition of glucocerebroside primarily in macrophages. The accumulation of such "Gaucher cells" leads to visceromegaly, hepatic and bone marrow dysfunction, hypersplenism, and bony disease. Eleven GD type 1 patients, ages 4–52 y, with moderate to life-threatening manifestations, received 6–12 mo of enzyme augmentation with a macrophage-targeted acid β -glucosidase preparation. Within 6 mo, substantial increases in Hb levels (mean = +30%) and platelet counts (mean = +39%) were observed. Hepatic and splenic volumes decreased by ~20% (range = 3–35%) and ~35% (20–52%), respectively. Hematologic and hepatic volume improvements were similar in the splenectomized ($n = 4$) and nonsplenectomized ($n = 7$) patient groups. In this patient population, no major differences were observed in the hematologic and visceral improvements with enzyme doses of 30, 50, or 60 IU/kg administered every 2 wk. Normal levels of acid β -glucosidase activity were present in hepatic autopsy samples from one patient 11 d after enzyme infusion. In comparison, exogenous activity was absent from brain and lung specimens of the same patient. High levels (~10-fold normal) were present in bone marrow samples from two patients obtained at 1 and 11 d after infusions. These studies demonstrate biochemical and clinical improvements by targeted enzyme augmentation in GD type 1, even in far advanced, life-threatening involvement. These and previous studies indicate that earlier intervention in patients with more mild signs may be warranted to obviate the need to rescue extraordinarily ill patients with GD type 1. (*Pediatr Res* 31: 496–502, 1992)

Abbreviations

ANC, absolute neutrophil count
SGPT, serum glutamic pyruvic transaminase

not absence, of the enzyme acid β -glucosidase and results from numerous point mutations at that locus (3). Accumulation of its major substrate (glucocerebroside), primarily within cells of reticuloendothelial origin, leads to the clinical manifestations (1–4). In the nonneuronopathic (type 1) variant, the markedly variable phenotype results from the progressive hypertrophy and, probably, hyperplasia of tissue-bound macrophages containing glucocerebroside in the liver (Kupffer cells), spleen, and bone marrow (1, 4). Dysfunction of these organs leads to clotting abnormalities, cirrhosis, hypersplenism, anemia, thrombocytopenia, and bony abnormalities (1, 4, 5). In addition, many patients experience excruciating bony and splenic "crisis" due to episodic infarction of these organs (4). Until recently, supportive medical and surgical interventions have provided the primary symptomatic relief for the disease manifestations.

Recently, Barton *et al.* (6, 7) reported clinical and biochemical improvement from enzyme augmentation in Gaucher disease type 1. The glycosylated enzyme had been purified from human placenta and was modified to expose terminal α -mannosyl residues (8, 9). This approach was used to target the enzyme to the reticuloendothelial system via the macrophage α -mannosyl recognition receptor (10, 11) and to augment the level of residual enzyme activity in those cells. In their study, the patients all had intact spleens, significant anemia, and mild to moderate thrombocytopenia (7). However, because of the design of this pilot trial, the influence of the spleen, the severity of the disease, the dose of the drug, and tissue distribution were not evaluated. In this study, we report the results of varying doses of Ceredase (Genzyme Corp., Cambridge, MA) in 11 patients with or without spleens and with moderate to life-threatening Gaucher disease type 1. In addition, the death of one severely ill patient from causes unrelated to enzyme augmentation provided the opportunity to assess the tissue distribution of the administered enzyme.

MATERIALS AND METHODS

Patient population. Eleven patients with Gaucher disease type 1 (nonneuronopathic) were entered into the trial (6–12 mo) of enzyme augmentation with Ceredase, an α -mannosyl-terminated, human serum albumin-solubilized preparation of acid β -glucosidase (EC 3.2.1.45). All patients had been followed at the Mount Sinai Medical Center for 2 to 12 y. Deficiency of acid β -glucosidase (5–15% of mean normal activity) was demonstrated with the natural and artificial substrates in peripheral blood mononuclear cells, cultured skin fibroblasts and/or lymphoblastoid lines from each patient. All patients were free of hepatitis B surface antigen and human immunodeficiency virus infection during the course of the study. Female patients had negative pregnancy tests. Enzyme augmentation was initiated after informed consent and/or assent of minors was obtained according to institutional guidelines.

Gaucher disease is the most prevalent lysosomal disease (1) and has its highest frequency (~1 in 450) in the Ashkenazi Jewish population (2). The disease is due to the inherited deficiency, but

Received August 8, 1991; accepted December 18, 1991.

Correspondence: Gregory A. Grabowski, M.D., Professor of Pediatrics and Genetics, Mount Sinai School of Medicine, One Gustave L. Levy Place, New York, NY 10029-6574.

Supported by grants from the National Institutes of Health (DK36729), the National Gaucher Foundation (NGF-19), and the General Clinical Research Resources of the National Institutes of Health (RR-71).

Study design. The general characteristics of the patient population are listed in Table 1. Seven patients (ages 4–52 y) with intact spleens were selected to approximate those of Barton *et al.* (7). Four (cases 2, 4, 6, and 7, ages 12–38) were chosen because of their rapidly progressing or life-threatening involvement. One patient (case 3) had had a partial splenectomy 2 y before this study (12). Patients were evaluated by monthly history and physical and laboratory examinations. The latter included complete blood counts, reticulocyte count, urinalysis, serum creatinine, blood urea nitrogen, total alkaline phosphatase, SGPT, serum glutamic oxaloacetic transaminase, total and direct bilirubin, total acid phosphatase, serum total creatinine phosphokinase, serum lactic acid dehydrogenase, total protein, angiotensin-converting enzyme, serum iron, and total iron binding capacity. No patient was iron deficient. The long bone surveys were conducted every 3–6 mo. Volumes of the liver and spleen were determined by established computerized tomographic techniques every 5–12 mo (13–15). The initial and final volumes for each patient are shown in Table 1. Genotype analyses for several known point mutations at the acid β -glucosidase locus were conducted by sequence-specific hybridizations as described (16). Acid β -glucosidase activities in autopsy tissues from case 2 and from other individuals were determined with glucocerebroside and synthetic substrates as described (17). All tissues were obtained within 6–24 h of death.

Patients received either 30, 50, or 60 IU of Ceredase/kg body wt every 2 wk by i.v. infusion as follows: the requisite amount of Ceredase was diluted to a total volume of 100 mL in 0.9% NaCl (U.S.P.) and infused (60 mL/h) through a blood transfusion filter. A test dose of 5 mL was given, followed by a rest period of 10–15 min, and then the infusion was completed. No adverse effects were observed in any patient.

Patient profile. Case 1 was a 14-y-old Ashkenazi Jewish female. Gaucher disease was diagnosed at age 4 y when massive splenomegaly and pancytopenia were found. Severe growth and pubertal delay were present at 14 y, *i.e.* height = 128 cm and weight = 29.6 kg were at the 50th percentile for an 8- to 9-y-old. Her sexual development was Tanner stage 1 and she had a cachectic habitus. Extensive endocrinologic evaluation was unrevealing. Skeletal x-rays revealed diffuse moderate osteopenia. Enzyme augmentation was started in May 1990.

Case 2 was a 12-y-old Hispanic male. Gaucher disease was diagnosed at age 15 mo when massive hepatosplenomegaly was found. Total splenectomy for pancytopenia was performed at age 3 y. Transfusion-dependent anemia developed at age 5 y. Progressive central cyanosis, hypoxemia [$PO_2 \sim 50$ mm Hg (6.67 kPa)], and clubbing of the fingers and toes also developed. Lung biopsy confirmed interstitial and alveolar infiltration with Gaucher cells. Several bone marrow examinations over the past 8 y showed complete replacement by Gaucher cells. His severe bone involvement has been reported and included numerous infarcts and severe osteopenia (case 1 in Ref. 18). He was severely cachectic and growth retarded [height = 130 cm and weight = 25 kg (both 50th percentile for a 7- to 8-y-old)]. Enzyme augmentation was started in May 1990. Clinical improvement was dramatic until December 1990, when he experienced a fatal, idiopathic, subarachnoid hemorrhage. Extensive histologic and ultrastructural studies of autopsy specimens demonstrated the lack of adverse immunologic or systemic effects of the enzyme augmentation and showed the lack of primary CNS involvement by this patient's Gaucher disease.

Case 3 was a 26-y-old Italian male. Gaucher disease was diagnosed at age 23 after protracted bleeding following a tooth extraction. Progressive splenomegaly, anemia, and thrombocytopenia necessitated a partial splenectomy at age 24. Since then, his spleen has regrown with reappearance of hypersplenism. Skeletal x-rays revealed severe generalized osteopenia as well as deformities and infarctions of the long bones. He has had recurrent bone crises involving the right hip and left knee. For the past year, he has had unremitting pain in the left upper arm,

which has severely limited its use and resulted in disuse atrophy. Bone biopsy revealed Gaucher disease involvement without infection. Enzyme augmentation was started in June 1990.

Case 4 was a 37-y-old Russian Ashkenazi Jewish female. Gaucher disease was diagnosed at age 3 y. A total splenectomy was done at that time. Her complicated medical history includes massive hepatomegaly with persistently abnormal liver function tests and hyperbilirubinemia. She also has complained of severe pruritus for the past several years. Large esophageal varices were present and have required sclerotherapy on several occasions for massive bleeding. Her bony involvement included diffuse severe osteopenia, deformities of the distal femora, and a lytic lesion of the right tibia that had eroded through the cortex of the bone with extension of Gaucher cells into the surrounding tissue. She had severe growth delay and resultant severe short stature. An open liver biopsy was performed in April 1991 during surgery for closure of a large ventral hernia. Histologic examination demonstrated massive infiltration by Gaucher cells as well as nodular cirrhosis. Enzyme augmentation was started in October 1990.

Case 5 was a 36-y-old male of Irish/Portuguese ancestry. Gaucher disease was diagnosed at age 5 y when he presented with splenomegaly. A bone marrow examination performed at that time revealed the presence of Gaucher cells. He has had bony involvement since age 28, with pains in the hips, legs, knees, feet, shoulders, and arms. He has had chronic anemia as well as progressive thrombocytopenia. During the 2 y preceding institution of enzyme augmentation, he had rapid enlargement of his spleen and significant worsening of his bone involvement due to Gaucher disease. A left hip core decompression was performed in September 1990 for avascular necrosis. Enzyme augmentation was started in October 1990.

Case 6 was a 38-old Ashkenazi Jewish female. Gaucher disease was diagnosed at age 5 y when she presented with splenomegaly and epistaxis secondary to thrombocytopenia. A splenectomy was performed at that time. Subsequently, she developed aseptic necrosis of the femoral heads during childhood and required a wheelchair for several years. She has reported no further bone problems since adolescence, although she still walks with a limp. Recently, her problems have involved massive hepatomegaly as well as transfusion-dependent anemia from bone marrow failure, which was unresponsive to erythropoietin and various androgens. Enzyme augmentation was started in December 1990.

Case 7 was a 30-y-old Russian Jewish male. Gaucher disease was diagnosed at age 5 y when he presented with abdominal pains and hepatosplenomegaly. He experienced multiple bone crises involving the lower extremities, which resulted in several hospitalizations. A total splenectomy was performed at age 26 for severe anemia and thrombocytopenia. After splenectomy, he reported much more frequent bony crises involving the knee and ankle, with frequent painful swelling of these joints. He developed left hip pain, and destruction of that joint required total left hip replacement at age 29. Enzyme augmentation was started in January 1991.

Case 8 was a 40-y-old Ashkenazi Jewish male. Gaucher disease was diagnosed pathologically at age 35 after left humeral head replacement. The right humeral head required replacement 4 y later. He had experienced episodic upper and lower extremity pains for many years. Many of these episodes lasted for several days. He has had moderate hepatosplenomegaly, and mild anemia and thrombocytopenia. Enzyme augmentation was started in January 1991.

Case 9 was a 48-y-old Ashkenazi Jewish male. Gaucher disease was diagnosed at age 11 y when splenomegaly was found on physical exam. He had a history of "polyarthritis" involving the hips, ankles, and knees during early childhood, as well as thrombocytopenia. He has had pancytopenia and massive splenomegaly with splenic infarcts on nuclear medicine scans. His medical history has been complicated by renal impairment, hypertension,

Table 1. Characteristics of Gaucher disease patients receiving enzyme augmentation*

Variable	Patient number										
	1	2	3	4	5	6	7	8	9	10	11
Clinical findings											
Sex	F	M	M	F	M	F	M	M	M	M	M
Age (y)	14.5	12	26	37	36	38	30	40	48	52	4
Date of birth	11/5/76	8/9/78	6/9/65	11/18/53	5/29/55	6/11/53	7/31/61	12/12/50	9/7/43	4/17/39	5/12/87
Ethnic group	AJ	Hispanic	Italian	AJ	Portuguese/Irish	AJ	AJ	AJ	AJ	AJ	AJ
Genotype	N370S/?	??	N370S/L444P	N370S/?	N370S/Complex A	N370S/?	N370S/N370S	N370S/?	N370S/?	N370S/IVS	N370S/?
Weight (kg) (initial/final)	27/29.6	25/28.2	69.8/69.5	47.6/49.2	69.6/74	42.2/48.1	80.5/82.2	69.6/73.3	71.9/71.6	74.4/74.1	15.6/16.0
Major signs	↓ Hb, ↓ WBC, ↓ Plt, severe ↓↓ growth, ↑↑ H-S megaly	BM failure, lung disease, Po ₂ ~50, ↓↓ growth, splenectomy (3 y)	Partial splenectomy (24 y), ↑↑ bony pain	Splenectomy (3 y), cirrhosis, esophageal varices, ↑↑ bony disease	Progressive hypersplenism, hip infarction	BM failure, transfusion dependent, ↑↑ liver	Splenectomy, 28 y, rapidly progressive bony disease	Bilateral shoulder replacement, progressive bony disease	H-S megaly, ↓ Hb, ↓ Plt	H-S megaly, ↓ Hb, ↓ Plt, humeral head collapse	H-S megaly, ↓ Hb, ↓ Plt, ↓ growth
Number of infusions	29	17	22	18	16	15	14	14	16	14	14
Dose (IU/kg)	30–60	60	30	60	60	60	60	50	50	50	30
Hb (g%) [initial/final]	7.4/11.5	9.4†/15.2	11.9/15.2	11.2/13.1	11.9/13.8	7.4†/14.8	13.1/14.8	12/14.9	9.6/10.7	8.8/10.9	11.7/10.9
Platelets (10 ³ /mL) [initial/final]	88/118‡	82/197	165/220	280/271	118/184	47/121	295/460	128/174	88/112	61/55	88/87‡
Hepatic volume											
Initial (% BW)	1603 (5.9)	2868 (11.4)	3770 (5.4)	4136 (8.7)	2967 (4.3)	4341 (10.3)	4552 (5.7)	2180 (3.1)	5399 (7.5)	3546 (4.8)	771 (4.9)
Final (% BW)	1156 (3.9)	2974 (10.5)	2966 (4.3)	3696 (8.0)	2471 (3.3)	4028 (8.4)	3037 (3.7)	2240 (3.0)	4346 (6.0)	2548 (3.4)	653 (4.1)
Splenic volume											
Initial (% BW)	3340 (12.4)		1090§ (1.6)		1997 (2.9)			1082 (1.6)	4626 (6.4)	6450 (8.7)	590 (3.8)
Final (% BW)	1740 (5.9)		707 (1.0)		1146 (1.5)			797 (1.1)	3604 (5.0)	5257 (7.0)	462 (2.9)

* AJ, Ashkenazi Jewish; BM, bone marrow; WBC, white blood cells; Plt, platelets; H-S megaly, hepatosplenomegaly; and % BW, % of body weight. N370S, L444P, IVS, and ? refer to alleles with the following substitutions: Asn³⁷⁰ to Ser, Leu⁴⁴⁴ to Pro, an intronic mutation leading to aberrant splicing, and "unknown," respectively. Complex A refers to an allele with three point mutations that result in Leu⁴⁴⁴ to Pro, Ala⁴⁵⁶ to Pro, and Val⁴⁶⁰ to Val.

† Transfusion dependent (see case descriptions).

‡ Highly variable platelet count (range = 35 000–136 000/mL); see Figure 1B.

§ Partial splenectomy with regrowth and progressive hypersplenism.

gout, and a monoclonal IgM gammopathy. Enzyme augmentation was started in March 1991.

Case 10 was a 52-y-old Ashkenazi Jewish male. Gaucher disease was diagnosed at age 36 y when splenomegaly was noted on physical exam. A bone marrow examination performed at that time revealed Gaucher cells. In addition to massive splenomegaly, he has pancytopenia and also pain and stiffness in his right shoulder, hips, ankles, and knees. X-rays revealed diffuse osteopenia with evidence of avascular necrosis and partial collapse of the right humeral head. Enzyme augmentation was started in April 1991.

Case 11 was a 4-y-old Ashkenazi Jewish male. Gaucher disease was diagnosed at age 3 y when progressive splenomegaly, anemia, and thrombocytopenia were observed. Enzyme augmentation was started in April 1991.

RESULTS

Hematologic and blood chemistry responses. Before beginning enzyme therapy, moderate to severe anemia was present in 10 of 11 patients (Table 1). Persistent thrombocytopenia also was present in eight cases (cases 1, 2, 5, 6, and 8–11). Normal platelet counts were consistently present in three cases (cases 3, 4, and 7). Case 7, a splenectomized 30-y-old male, had low normal Hb and normal platelet counts before beginning enzyme augmentation. In all patients, the Hb levels increased by 6–8 mo (Table 1, Fig. 1A and C). However, the time required for persistent increases and the degree of increase were not consistent (Fig. 1A and C). The responses were independent of the Ceredase dose. Cases 1, 3, and 11 each received 30 IU/kg during the first ~150–200 d. A 25% increase in Hb was found in case 1 by about d 50, whereas cases 3 and 11 abruptly increased by that degree at about 180 d or did not change, respectively. In comparison, the platelet count in case 3 increased to 125% of baseline by 3 mo, whereas wide fluctuations in the platelet count occurred in cases 1 and 11 (Fig. 2). These fluctuations in case 1 provided an impetus for the dosage increase to 60 IU/kg at 210 d. Subsequently, the increase in Hb level continued at about the same rate, but the platelet count now consistently increased. Case 3 had continued increases in the Hb levels and platelet counts without a change in dose (30 IU/kg). Cases 4, 5, and 7–10 (dose = 50–60 IU/kg) showed a mean increase of 19% (range = 14–27%) from baseline Hb levels by 6–8 mo (Fig. 1A). The platelet counts were unchanged (cases 4 and 10) or increased by 21–56% (cases 5 and 7–9). In these six patients, the presence or absence of the spleen had no major influence on the degree or rate of increase in Hb level or platelet count.

Two very ill patients (cases 2 and 6) had different, dramatic patterns of hematologic responses (Table 1, Fig. 1C). Their anemias were no longer transfusion-dependent after the first dose of Ceredase. The Hb levels and platelet counts in case 2 promptly increased so that normal values were obtained by about 50 d. For case 6, the responses of Hb level and platelet count were delayed until 75 and 150 d, respectively. Normal Hb levels were attained by 120 d and the platelet count doubled by 180 d.

Only case 1 was persistently neutropenic (ANC ~600–1000/mL). The changes in her ANC have been erratic and similar to those for her platelet count. Her neutropenia resolved by 300 d with persistent ANC >1400/mL. Three splenectomized patients (cases 2, 4, and 7) had persistent leukocytosis (white blood cell count >11 000/mL). In cases 2 and 4, this abnormality resolved by 6 mo, whereas in case 7 leukocytosis (>14 000) has persisted.

Total serum acid phosphatase values in 11 patients were mildly elevated [mean = 2.6-fold (range = 1.1–3.7) above the upper limit of normal] and the corresponding value in one patient (case 1) was 12.6. The mean increase for all eight patients was 3.4-fold (range = 1.1–12.6). In the seven patients with mildly elevated initial values, reductions of total serum acid phosphatase to nearly normal values [1.0-fold (0.5–1.6)] were obtained by 6 mo. In case 1, the value declined from 12.6-fold to 3.4-fold by 6 mo.

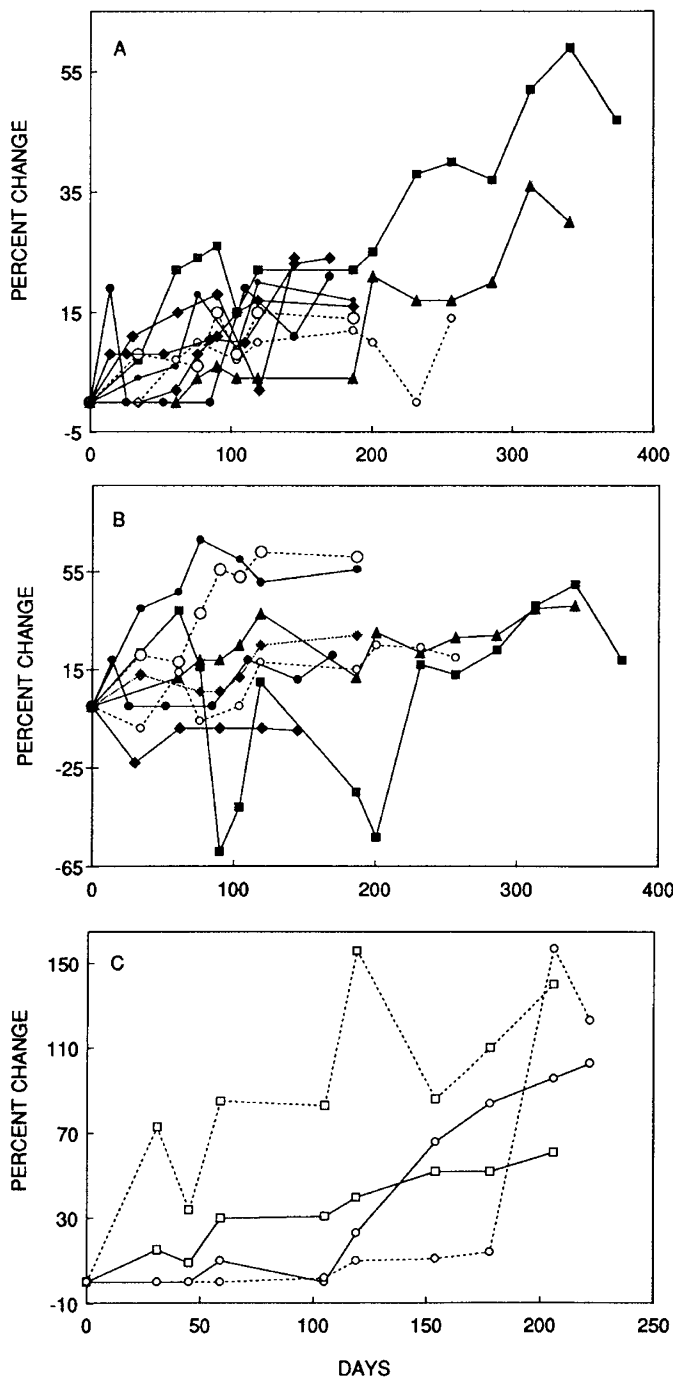


Fig. 1. The % change from initial Hb level (A) and platelet count (B) as a function of days after institution of enzyme augmentation in six patients with Gaucher disease type 1. The solid and open symbols indicate patients with and without spleens, respectively. In C, cases 2 and 6 are shown; both had been splenectomized. For C, Hb (—) and platelet (---) changes are indicated. Cases 1 (■), 2 (□), 3 (▲), 4 (○), 5 (●), 6 (○), 7 (◇), 8 (◆), 9 (◆), 10 (●), and 11 (■) are indicated.

Effect of Ceredase on visceral organs. As shown in Table 1 and Figure 2, all patients had marked hepatosplenomegaly. Assuming 1 g/mL volume and relative to body wt, these patients had an initial mean of 3-fold (range = 1.3–4.6, n = 11) and 28-fold (range = 8–62, n = 6) increases in volume of the liver and spleen, respectively (Table 1). As shown in Figure 2, the organ volumes, relative to body wt, decreased in all patients by 6–12 mo of enzyme augmentation. Aggregate values were 20% (range = 3–35%, n = 11) and 35% (range = 20–52%) decreases in volumes of the liver and spleen, respectively, at 6–13 mo. In cases 2, 4,

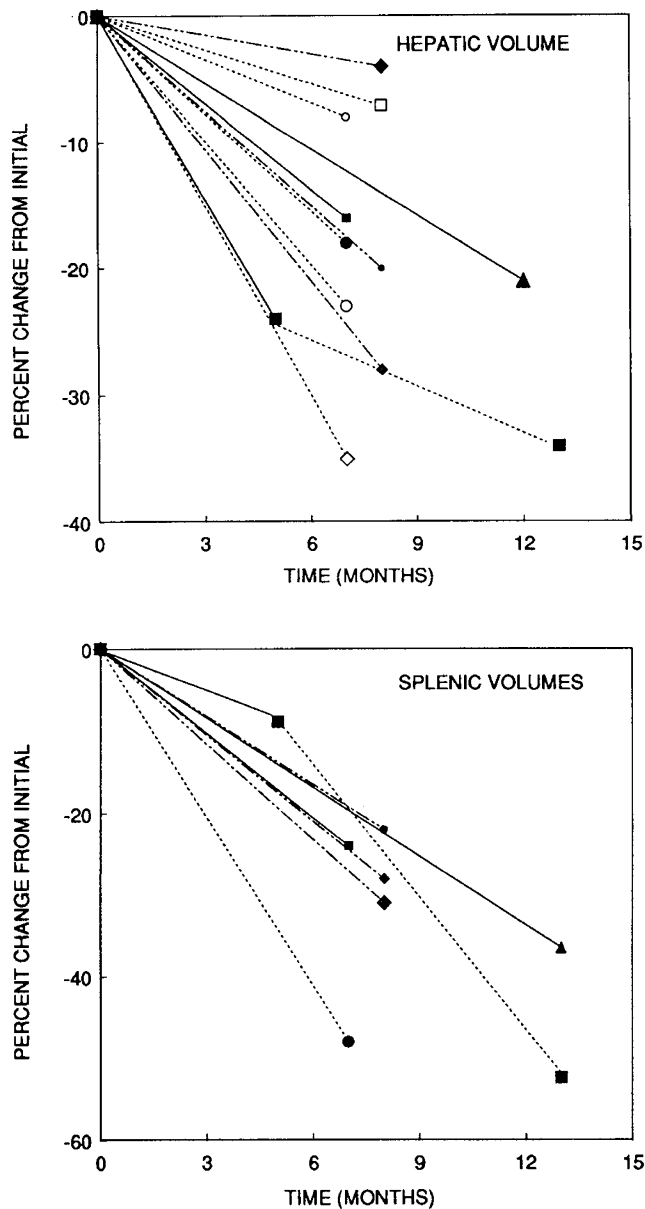


Fig. 2. The % change from initial hepatic or splenic volumes as determined by computed tomography as a function of months after institution of enzyme augmentation in eight patients with Gaucher disease type 1. Doses are indicated by — (30 IU/kg), --- (50 IU/kg), and ··· (60 IU/kg). Cases 1 (■), 2 (□), 3 (▲), 4 (◊), 5 (●), 6 (○), 7 (◇), 8 (◆), 9 (◈), 10 (◉), and 11 (◓) are indicated. Solid and open symbols indicate patients with and without spleens, respectively.

and 8, these changes in liver volumes were at the limits of detectability. In this patient population, no clear difference in the decreases in hepatic volumes were noted between the splenectomized and nonsplenectomized patients (Fig. 2). The decreases in liver volume were unrelated to dose (Fig. 2). The normalcy or minimal abnormalities in serum SGPT, serum glutamic oxaloacetic transaminase, bilirubin, PT/PTT, or serum albumin (cases 1–3, 6–8) precluded assessment of the relationship of these decreases in volume on hepatic function. However, in case 4, the 3- to 4-fold elevations in SGPT and bilirubin became persistently normal or nearly normal by 6 mo (data not shown). In the six patients with intact spleens, major decreases in splenic volumes were found with all doses by 6–13 mo [mean = 35% (range = 20–52) decreased]. However, a greater rate of splenic volume decrease was found in case 1 after increasing the dose from 30 to 60 IU/kg.

The six patients (cases 3, 4, 5, 7, 8, and 10) with complaints of intermittent pain and/or chronic discomfort in the long bones reported a decrease in intensity and/or frequency of these symptoms. All but case 3 are now free of bony symptoms. Case 3 also had chronic intermittent episodic pains, which have resolved. However, the left humeral and shoulder pain, without joint involvement, which has been present for the past 16 mo, has not been alleviated. Radiographic examination of the long bones in all patients demonstrated no changes in architecture, mineralization, or cortical thickness.

Tissue distribution and levels of Ceredase. The death of case 2 from an idiopathic subarachnoid hemorrhage provided samples for analysis 10 d after his last infusion of 60 IU enzyme/kg and about 18 h after death (Table 2). In addition, case 3 had a core decompression of the left humerus about 19 h after a dose of 30 IU/kg enzyme (Table 2). In liver and bone marrow from case 2, substantial acid β -glucosidase activity was present, but not in lung or brain samples. Based on liver weight (2898 g) at autopsy (case 2), about 4–5% of the administered dose still was present in the liver. The levels of enzyme activity in bone marrow aspirates from cases 2 and 3 were 7 and 12 times normal values, respectively. Although these bone marrow samples are not strictly comparable, they clearly indicate that Ceredase is distributed there and persists for a substantial period in that tissue.

DISCUSSION

Until recently, only supportive therapy was available for patients afflicted with Gaucher disease. The advent of mannose-terminated acid β -glucosidase (Ceredase) for enzyme augmentation in Gaucher disease type 1 (nonneuronopathic) was shown to improve the anemia and thrombocytopenia as well as to decrease the visceromegaly in affected patients (6, 7). All patients in the previous study received 60 IU/kg Ceredase and had moderate to moderately severe Gaucher disease with intact spleens and no evidence of the additional visceral complications (7). Consequently, the effectiveness of different doses of enzyme, the efficacy of such enzyme augmentation in very severe (end-stage) Gaucher disease type 1, and the influence of the spleen on effectiveness were unknown.

The present results indicate similar efficacy with Ceredase and demonstrate its efficacy in moderate to very severe Gaucher disease. This latter group included patients with pulmonary involvement, hepatic cirrhosis, and bone marrow failure with myelofibrosis. As shown in Figures 1 and 2, the rates of improvement in Hb level, platelet counts, and hepatic volume appeared independent of the dose of Ceredase. In case 1, a greater rate of splenic volume decrease was observed after an increase in dose from 30 to 60 IU/kg. Excluding cases 2 and 6 with bone marrow failure and transfusion-dependent anemias, the average increases in Hb levels and platelet counts were 21% (range 0–55%) and 25% (range = –10–63) over baseline in 6–12 mo, respectively. These results compare very well with those obtained at 9–12 mo by Barton *et al.* (7), *i.e.* Hb level and platelet count increases of 36% (range = 12–84) and 39% (range = –16–90), respectively. In two of the present patients with life-threatening complications of Gaucher disease (cases 2 and 6), the hematologic responses were very dramatic. Neither patient required transfusions to support their Hb levels after a single dose of Ceredase, even though there was a lag in Hb response in case 6 for about 2 mo. The normalization of Hb levels in these two patients (~100 d) and dramatic increases in platelet counts (~50–150 d) were unexpected, especially because case 6 had failed androgen and erythropoietin therapy for her myelofibrosis. The mechanisms responsible for these responses in the two severely ill patients are unknown, but in case 2, the patient who has hypoxemia, the increase in Hb could have been erythropoietin mediated.

In comparison, during the same time period, improvement was not observed by radiographic examination of the bones, although bony discomfort and pain decreased in all symptomatic

Table 2. Tissue distribution of Ceredase in Gaucher disease patients*

Source	Liver (nmol/h/mg)	Bone marrow† (nmol/h/mL)	Lung (nmol/h/mg)	Brain (nmol/h/mg)
Case 2				
4MUGlc‡	57	47	0.29	2.67
GC	142		4.2	14.5
Case 3 (4MUGlc)		80		
Normal (n = 11)				
4MUGlc	84 ± 25	6.6	23 ± 9	61 ± 21
GC	71 ± 18		56 ± 12	69 ± 25
Gaucher disease (n = 5)				
4MUGlc	9 ± 5	0.0§	4 ± 2	2 ± 1
GC	14 ± 7		3 ± 2	11 ± 7

* Tissue samples were obtained at autopsy of normals between 8 and 24 h of death.

† The bone marrow aspirates were frozen as whole aspirates and thawed to approximate the aspiration specimens obtained on cases 2 (at autopsy) and 3 (at surgery).

‡ 4MUGlc and GC refer to the synthetic and glucosylceramide substrates, respectively.

§ One specimen was obtained from the iliac crest of an untreated Gaucher disease patient.

patients. Similar symptomatic relief was reported by Barton *et al.* (7), but one child was shown to have remodeling of the femur to near normalcy and remineralization during a longer course of enzyme augmentation (6). Case 2 had no demonstrable bone marrow by technetium-99 sulfur colloid scans before enzyme infusions. Histologic examination at autopsy demonstrated the presence of large areas of productive and highly cellular marrow in the femur, vertebral bodies, and pelvis (data not shown). Similarly, no improvements in the pulmonary involvement in case 2 were demonstrated by increases in blood gas measurements or pulmonary function studies at 6 mo into enzyme augmentation. Histologic comparison of a lung biopsy obtained about 3 y before and lung samples obtained at autopsy 8 mo after beginning enzyme augmentation suggested fewer Gaucher cells in the autopsy specimens, but the lungs were still massively infiltrated. These findings indicate clear effects on bone marrow reconstitution and suggest that architectural changes in bone and reversal of pulmonary involvement require more prolonged treatment.

Ceredase has been designed for targeting to the site of pathology in Gaucher disease, the macrophage, via an α -mannosyl receptor on the surface of these cells (10). Because of this and the massive (60 times the expected normal size in case 1) enlargement of the spleen in many affected patients, we had expected that the presence of the spleen might influence the response to the enzyme because this organ could trap enzyme in the large number of Gaucher cells there. As shown in Figures 1 and 2, the hematologic or hepatic changes were not different in patients with or without spleens. Indeed, the change in hepatic volumes was small in cases 2 and 4, involving patients who were splenectomized early in life. Consequently, these data do not support the use of splenectomy as an adjunct to lowering the enzyme dose required. In addition, the morbidity associated with splenectomy (19–23), *per se*, and in Gaucher disease, in particular (24, 25), would indicate that reduction of splenic size by enzyme augmentation would be preferable to the surgical approach for the hematologic management of Gaucher disease patients. Importantly, extensive hepatic fibrosis (case 2) and cirrhosis (case 4) were present in severely involved patients who had splenectomies early in life. Similarly, case 6 with massive hepatomegaly and bone marrow failure underwent splenectomy at age 5 y, but had a moderate decrease in hepatic volume (18%) with enzyme augmentation. Three patients who were younger (case 1), generally more moderately involved (case 5), or recently splenectomized (case 7) had the largest reductions in hepatic volume. Although improvements were observed in hematologic and/or visceral measurements in all patients, the above findings do suggest that early institution of enzyme augmentation may be more efficacious and may prevent irreversible visceral organ damage. However, a prospective study in patients with mild

disease manifestations will be needed to provide support for this proposal.

From these and previous investigations (6, 7), Ceredase has now been demonstrated to be efficacious in the reversal of several manifestations of Gaucher disease. Both chemical and clinical improvements have been observed in all patients, even those with bone marrow failure or active cirrhotic processes due to Gaucher disease (case 4). However, the cost of the enzyme is high; *i.e.* at 60 IU/kg, the cost is \$210/kg body wt every 2 wk. The present studies demonstrate that similar responses can be achieved with 30 IU/kg every 2 wk, *i.e.* at one half of the cost. The substantial variability in hematologic and visceral organ changes at any dose of enzyme and with any degree of disease involvement indicates that the minimal effective dose will be difficult to determine from single cases. Furthermore, in the absence of turnover data for the enzyme in tissues, it is difficult to determine an optimal dosing schedule (26), which could lower the cost substantially. The analyses of autopsy tissues from case 2 indicated that the enzyme activity was present at normal levels in liver and high levels in bone marrow 10 d after the infusion and 18 h after death. This result demonstrates a prolonged half-life for the administered enzyme in hepatic tissue and bone marrow, at least in this splenectomized patient. This result correlated with the recovery of functional bone marrow by hematologic parameters and histologic demonstration of normal marrow elements (data not shown) in this patient, who had complete replacement of bone marrow by Gaucher cells before enzyme augmentation. The presence of elevated levels of acid β -glucosidase activity in humeral bone marrow from case 3 further indicates the distribution of the exogenous enzyme to this tissue in a patient with an intact and enlarged spleen. These findings indicate that the enzyme is distributed to and is functional in two of the major sites of pathology in this disease, *i.e.* the liver and bone marrow. The deficiency of the enzyme in autopsied lung and brain from case 2 may indicate organ-specific distribution (*i.e.* not to brain) or, at least in lung, differential turnover of the exogenous enzyme. This finding may have implications for enzyme delivery in the subacute neuropathic (type 3) variant or in patients with severe pulmonary involvement from Gaucher disease.

REFERENCES

1. Desnick RJ, Gatt S, Grabowski GA (eds) 1982 Gaucher Disease: A Century of Delineation and Research. Alan R Liss, New York
2. Zimran A, Gelbart T, Westwood B, Grabowski GA, Beutler E 1991 High frequency of the Gaucher disease mutation at nucleotide 1226 among Ashkenazi Jews. *Am J Hum Genet* 49:855–859
3. Grabowski GA, Gatt S, Horowitz M 1990 Acid β -glucosidase: enzymology and molecular biology of Gaucher disease. *Crit Rev Biochem Mol Biol* 25:385–414
4. Fredrickson DS, Sloan HR 1972 Glucosyl ceramide lipodosis: Gaucher disease.

- In: Stanbury JB, Wyngarden JB, Fredrickson DS (eds) *The Metabolic Basis of Inherited Disease*, 3rd Ed. McGraw-Hill, New York, pp 730-759
5. Goldblatt J, Sachs S, Beighton P 1978 The orthopaedic aspects of Gaucher disease. *Clin Orthop* 137:208-214
 6. Barton NW, Furbish FS, Murray GJ, Garfield M, Brady RO 1990 Therapeutic response to intravenous infusions of glucocerebrosidase in a patient with Gaucher disease. *Proc Natl Acad Sci USA* 87:1913-1916
 7. Barton NW, Brady RO, Dambrosia JM, Di Bisceglie AM, Doppelt SH, Hill SC, Mankin HJ, Murray GJ, Parker RI, Argoff CE, Grewal RP, Yu K-T, Graham OC, Holder CA, Howard KD, Kaneski CR, Oliver KL, Riesz S, Verderese CL, Zirzow GC 1991 Replacement therapy for inherited enzyme deficiency: macrophage-targeted glucocerebrosidase for Gaucher's disease. *N Engl J Med* 324:1464-1470
 8. Furbish FS, Steer CJ, Krett NL, Barranger JA 1981 Uptake and distribution of placental glucocerebrosidase in rat hepatic cells and effects of sequential deglycosylation. *Biochim Biophys Acta* 673:425-434
 9. Furbish FS, Blair HE, Shiloah J, Pentchev PG, Brady RO 1977 Enzyme replacement therapy in Gaucher's disease: large scale purification of glucocerebrosidase suitable for human administration. *Proc Natl Acad Sci USA* 74:3560-3564
 10. Achord DT, Brot FE, Bell CE, Sly WS 1978 Human β -glucosidase: *in vivo* clearance and *in vitro* uptake by a glycoprotein recognition system on reticuloendothelial cells. *Cell* 15:269-278
 11. Stahl PD, Rodman JS, Miller MJ, Schlesinger PH 1978 Evidence for receptor-mediated binding of glycoproteins, glycoconjugates, and lysosomal glycosidases by alveolar macrophages. *Proc Natl Acad Sci USA* 75:1399-1403
 12. Fleshner PR, Aufses AH, Grabowski GA, Elias R 1991 A twenty-seven year experience with splenectomy for Gaucher's disease. *Am J Surg* 161:69-75
 13. Heymsfield SB, Fulenwider T, Nordlinger B, Barlow R, Sones P, Kutner M 1979 Accurate measurement of liver, kidney and spleen volume by computerized axial tomography. *Ann Intern Med* 90:185-187
 14. Everson GT, Scherzinger A, Berger-Leff N, Reichen J, Lezotte D, Manco-Johnson M, Gabow P 1988 Polycystic liver disease: quantitation of parenchymal and cyst volumes from computed tomography images and clinical correlates of hepatic cysts. *Hepatology* 8:1627-1634
 15. Tarao K, Hoshino H, Motohashi I, Iimiro K, Tamai S, Ito Y, Takagi S, Oikawa Y, Unagama S, Fujiwara T, Otagiri K, Ikeda T, Hayashi K, Sckurai A, Uchikishi T 1989 Changes in liver and spleen volume in alcoholic liver fibrosis of man. *Hepatology* 4:589-593
 16. Theophilus B, Latham T, Grabowski GA, Smith FI 1989 Gaucher disease: molecular heterogeneity and phenotype-genotype correlations. *Am J Hum Genet* 45:212-225
 17. Grabowski GA, Goldblatt J, Dinur T, Kruse J, Svennerholm L, Gatt S, Desnick RJ 1985 Genetic heterogeneity in Gaucher disease: physicochemical and immunologic studies of the residual enzyme in cultured fibroblasts from non-neuropathic and neuropathic patients. *Am J Med Genet* 21:529-549
 18. Hermann G, Goldblatt J, Levy RN, Goldsmith SJ, Desnick RJ, Grabowski GA 1986 Gaucher's disease type I: assessment of bone involvement by CT and scintigraphy. *AJR* 147:943-948
 19. King H, Shumacker MB 1952 Splenic studies. I. Susceptibility to infection after splenectomy performed in infancy. *Ann Surg* 136:239-242
 20. Eraklis AJ, Kevy SV, Diamond LK, Gross RE 1967 Hazard of overwhelming infection after splenectomy in childhood. *N Engl J Med* 276:1225-1229
 21. Diamond LK 1969 Splenectomy in childhood and the hazard of overwhelming infection. *Pediatrics* 43:886-889
 22. Singer DB 1973 Postsplenectomy sepsis. *Perspect Pediatr Pathol* 1:285-311
 23. Gopal V, Bisno AL 1977 Fulminant pneumococcal infections in "normal" splenic hosts. *Arch Intern Med* 137:1526-1530
 24. Rose JS, Grabowski GA, Barnett SH, Desnick RJ 1982 Accelerated skeletal destruction after splenectomy in Gaucher type I disease. *AJR* 139:1202-1204
 25. Ashkenazi A, Zaizov R, Matoth Y 1986 Effect of splenectomy on destructive bone changes in children with chronic (type I) Gaucher disease. *Eur J Pediatr* 145:138-141
 26. Beutler E, Kay A, Saven P, Garver D, Thurston A, Dawson A, Rosenbloom B 1991 Enzyme replacement therapy for Gaucher disease. *Blood* 78:1183-1189