PATENT FORAMEN OVALE

nature REVIEWS DISEASE PRIMERS

For the Primer, visit doi:10.1038/nrdp.2015.86

Patent foramen ovale (PFO) is the consequence of failed closure of the foramen ovale — a fetal structure that directs blood flow from the right to left atrium, bypassing the pulmonary circulation.

MECHANISMS

Before birth, the fetus depends on the maternal circulation for oxygenation, and the blood bypasses the fetal lungs through the foramen ovale and the ductus arteriosus — a structure that shunts blood from the pulmonary artery directly to the aorta. When the neonate starts breathing independently after birth, the pulmonary vascular resistance drops and blood flows to the lungs. The ductus arteriosus regresses within 2–3 weeks after birth and the foramen ovale should close within a few years, but remains open in ~25% of people. The exact reason for failed closure remains unknown, but other anatomical abnormalities (including atrial septal aneurysms, persistent Eustachian valve and Chari networks) are associated with the presence of PFOs and might affect closure.

PFOs have historically been associated with an increased risk of stroke through paradoxical embolisms that possibly shunt through the PFO to the left atrium and into the systemic circulation. However, although the frequency of PFOs in patients with cryptogenic stroke is higher than in individuals who have not had a stroke, cohort studies have failed to show an increased stroke risk in asymptomatic individuals with a PFO. The Risk of Paradoxical Embolism (RoPE) study identified that the fewer other risk factors present, the more likely it is that an associated PFO is the cause of a stroke. However, if a stroke is due to a PFO, the risk for recurrence of a stroke is lower than for strokes caused by other reasons.

DIAGNOSIS

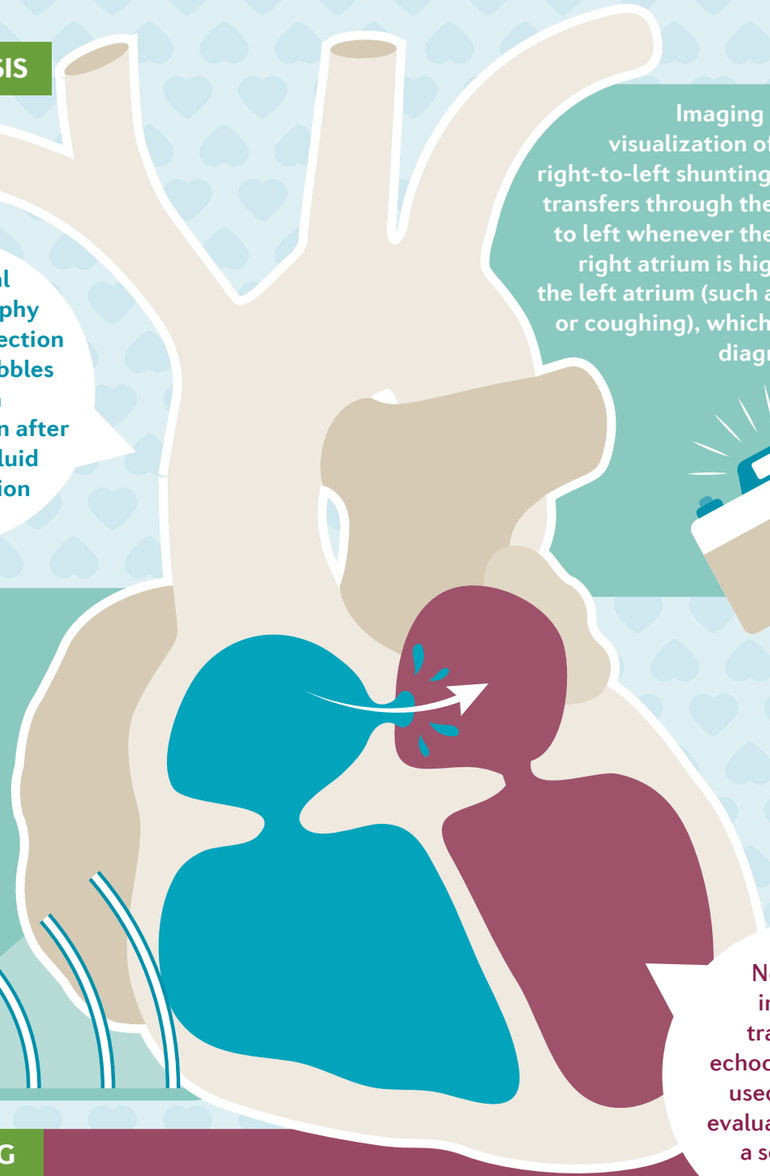

Transcranial echocardiography relies on the detection of microbubbles in the brain circulation after contrast fluid injection

Imaging methods enable visualization of the PFO and of right-to-left shunting of blood. Blood transfers through the PFO from right to left whenever the pressure of the right atrium is higher than that of the left atrium (such as with straining or coughing), which can be used for diagnostic purposes.

Transoesophageal echocardiography has a sensitivity of nearly 100% when combined with contrast fluid injection (mainly aerated saline) and colour Doppler technologies.

Noninvasive imaging by transthoracic echocardiography is used as an initial evaluation tool, with a sensitivity of 80–90%

SCREENING

Screening for a PFO should be restricted to individuals who have had a recent clinical event that might indicate the presence of a PFO, who would benefit from treatment of the PFO or who have a condition that predisposes to paradoxical embolism if a PFO is present. Screening should also be considered for patients who have had a stroke with an attributable cause and who also have a condition that predisposes to paradoxical embolism (presence of deep venous thrombosis, pulmonary embolism, hypercoagulable state, pulmonary hypertension or pulmonary embolism).

EPIDEMIOLOGY

PFOs are common; the prevalence in adults is estimated to be 15–25%. Men and women are affected equally and no clear-cut ethnic differences are observed with regard to prevalence. An association between PFOs and several pathologies has been found; the association with stroke is the most studied, followed by other conditions, including migraine.



MANAGEMENT

PFO management mainly aims to prevent stroke or transient ischaemic events via medical treatment to avoid thrombus formation or via interventions to close the PFO. Medical treatment is recommended for all patients with a PFO. Several studies have compared antiplatelet agents (aspirin) and anticoagulation agents (warfarin) for secondary stroke prevention, but no significant differences have been found. Antiplatelet therapy might be preferred owing to a lower risk of bleeding complications. With the advent of minimally invasive, catheter-based procedures to close PFOs, the number of interventions has steadily increased. However, three large randomized controlled studies have not shown any significant benefit of PFO closure on the prevention of stroke or ischaemic transient attacks.

Designed by Laura Marshall

Article number: 15087; doi:10.1038/nrdp.2015.87; published online 21 Jan 2016