Modern Pathology (2016) 29, 1173–1182

Peripheral T-cell lymphomas of follicular helper T-cell type frequently display an aberrant $CD3^{-/dim}CD4^{+}$ population by flow cytometry: an important clue to the diagnosis of a Hodgkin lymphoma mimic

Mir Alikhan[1,12], Joo Y Song[2,12], Aliyah R Sohani[3], Julien Moroch[4], Anne Plonquet[5], Amy S Duffield[6], Michael J Borowitz[6], Liuyan Jiang[7], Carlos Bueso-Ramos[8], Kedar Inamdar[9], Madhu P Menon[9], Sandeep Gurbuxani[1], Ernest Chan[1], Sonali M Smith[10], Alina Nicolae[11], Elaine S Jaffe[11], Philippe Gaulard[4] and Girish Venkataraman[1]

[1]Department of Pathology, University of Chicago, Chicago, IL, USA; [2]Department of Pathology, City of Hope Medical Center, Duarte, CA, USA; [3]Department of Pathology, Massachusetts General Hospital, Boston, MA, USA; [4]Department of Pathology, University of Paris-Est, Hôpital Henri Mondor, Créteil, France; [5]Department of Immunology, University of Paris-Est, Hôpital Henri Mondor, Créteil, France; [6]Department of Pathology, Johns Hopkins University, Baltimore, MD, USA; [7]Department of Pathology, Mayo Clinic, Jacksonville, FL, USA; [8]Department of Pathology, MD Anderson, Houston, TX, USA; [9]Department of Pathology, Henry Ford Health systems, Detroit, MI, USA; [10]Department of Hematology/Oncology, University of Chicago, Chicago, IL, USA and [11]National Cancer Institute, Section of Hematopathology, National Institutes of Health, Bethesda, MD, USA

Nodal follicular helper T-cell-derived lymphoproliferations (specifically the less common peripheral T-cell lymphomas of follicular type) exhibit a spectrum of histologic features that may mimic reactive hyperplasia or Hodgkin lymphoma. Even though angioimmunoblastic T-cell lymphoma and peripheral T-cell lymphoma of follicular type share a common biologic origin from follicular helper T-cells and their morphology has been well characterized, flow cytometry of peripheral T-cell lymphomas of follicular type has not been widely discussed as a tool for identifying this reactive hyperplasia/Hodgkin lymphoma mimic. We identified 10 peripheral T-cell lymphomas of follicular type with available flow cytometry data from five different institutions, including two cases with peripheral blood evaluation. For comparison, we examined flow cytometry data for 8 classical Hodgkin lymphomas (including 1 lymphocyte-rich classical Hodgkin lymphoma), 15 nodular lymphocyte predominant Hodgkin lymphomas, 15 angioimmunoblastic T-cell lymphomas, and 26 reactive nodes. Lymph node histology and flow cytometry data were reviewed, specifically for the presence of a $CD3^{-/dim}CD4^{+}$ aberrant T-cell population (described in angioimmunoblastic T-cell lymphomas), besides other T-cell aberrancies. Nine of 10 (90%) peripheral T-cell lymphomas of follicular type showed a $CD3^{-/dim}CD4^{+}$ T-cell population constituting 29.3% (range 7.9–62%) of all lymphocytes. Five of 10 (50%) had nodular lymphocyte predominant Hodgkin lymphoma or lymphocyte-rich classical Hodgkin lymphoma-like morphology with scattered Hodgkin-like cells that expressed CD20, CD30, CD15, and MUM1. Three cases had a nodular growth pattern and three others exhibited a perifollicular growth pattern without Hodgkin-like cells. Epstein–Barr virus was positive in 1 of 10 cases (10%). PCR analysis showed clonal T-cell receptor gamma gene rearrangement in all 10 peripheral T-cell lymphomas of follicular type. By flow cytometry, 11 of 15 (73.3%) angioimmunoblastic T-cell lymphomas showed the $CD3^{-/dim}CD4^{+}$ population (mean: 19.5%, range: 3–71.8%). Using a threshold of 3% for $CD3^{-/dim}CD4^{+}$ T cells, all 15 nodular lymphocyte predominant Hodgkin lymphoma controls and 8 classical Hodgkin lymphomas were negative (Mann–Whitney $P = 0.01$, F-PTCL *vs* Hodgkin lymphomas), as were 25 of 26 reactive lymph nodes. The

Correspondence: Dr G Venkataraman, MD, Department of Pathology, Section of Hematopathology, The University of Chicago, 5841S. Maryland Ave, TW055, MC0008, Chicago, IL 60637, USA.
E-mail: Girish.Venkataraman@uchospitals.edu
[12]These authors contributed equally to this work.
Received 6 February 2016; revised 5 May 2016; accepted 6 May 2016; published online 17 June 2016

high frequency of CD3$^{-/dim}$CD4^{+} aberrant T cells is similar in angioimmunoblastic T-cell lymphomas and peripheral T-cell lymphomas of follicular type, and is a useful feature in distinguishing peripheral T-cell lymphomas of follicular type from morphologic mimics such as reactive hyperplasia or Hodgkin lymphoma.
Modern Pathology (2016) **29,** 1173–1182; doi:10.1038/modpathol.2016.113; published online 17 June 2016

Peripheral T-cell lymphomas of follicular type[1,2] are one of the several novel forms of peripheral T-cell lymphomas recognized in the last decade. Although a relationship between peripheral T-cell lymphoma of follicular type and angioimmunoblastic T-cell lymphoma was suspected based on morphologic similarities, it was not until significant advances were made in the understanding of follicular helper T-cell biology[3,4] that it became apparent that both angioimmunoblastic T-cell lymphoma and the peripheral T-cell lymphoma of follicular type share a common biologic derivation from follicular helper T cells.[5,6]

Typical angioimmunoblastic T-cell lymphomas are often straightforward to recognize, given the characteristic morphologic features (vascular arborization, dilated peripheral cortical sinus, clear cells, and extrafollicular dendritic cell meshworks), and ancillary flow cytometry or molecular genetic studies are often not needed. However, a proportion angioimmunoblastic T-cell lymphomas exhibit unusual cytologic features, including: (1) associated Hodgkin-like cells of a B-lineage derivation variably expressing EBV;[7] and (2) early 'reactive hyperplasia' growth pattern (so-called 'pattern 1') described by Attygalle co-workers.[8,9] These reports expand our understanding of the range of histologic patterns that may be observed in angioimmunoblastic T-cell lymphomas and additionally serve to highlight that some cases may be difficult to distinguish from either reactive conditions or Hodgkin lymphoma. Similar difficulties may be encountered with peripheral T-cell lymphomas of follicular type, as evidenced by the recent series of cases described by Moroch *et al*, demonstrating striking resemblance to Hodgkin lymphoma.[10] Thus, better ancillary tools are needed to distinguish these entities.

Existing literature on flow cytometry in angioimmunoblastic T-cell lymphomas describes the classic occurrence of two distinct atypical T-cell populations, including CD3^{+}/CD10^{+} co-expressing T cells, and a CD3$^{-/dim}$CD4^{+} population that is not as well recognized. The latter population was initially described by Serke *et al*[11] and although not routinely assessed in daily practice, it is nevertheless reported to be frequently present in angioimmunoblastic T-cell lymphoma in over 50% of cases,[8,12–14] with a recent report demonstrating its detection in nearly 100% of cases.[15]

We thus undertook this study to assess these two T-cell populations, in cases of peripheral T-cell lymphomas of follicular type because in spite of the number of reports detailing histologic findings,[6,10] there is limited literature on the flow cytometric characteristics of this entity. On one hand, we sought to compare these cases to angioimmunoblastic T-cell lymphoma to further explore the relationship between these two neoplasms. In addition, we also investigated control cases that included non-neoplastic lymphadenopathy, as well as both classical Hodgkin lymphoma and nodular lymphocyte predominant Hodgkin lymphoma to determine if identification of these T-cell populations could aid in the distinction of angioimmunoblastic T-cell lymphoma and peripheral T-cell lymphoma of follicular type from Hodgkin lymphoma and reactive hyperplasia.

Materials and methods

We retrospectively identified 10 well-characterized cases of peripheral T-cell lymphoma of follicular type with available multi-parameter flow cytometry data from five institutions, none of which had any features of overt angioimmunoblastic T-cell lymphoma. The histologic findings on formalin-fixed paraffin embedded tissues were reviewed and the diagnosis was confirmed using a comprehensive immunohistochemistry panel including: CD20, CD3, CD4, CD8, CD5, CD7, CD2, ICOS, and CXCL13, and PD1. PCR for T-cell receptor gamma gene rearrangement (*TRG*) was performed in all cases by the respective institutions. This study was approved by the the University of Chicago Medicine Institutional Review Board (IRB#1133), as well as by the IRBs of the collaborating institutions. Parts of the data reported in cases 1–4 were published in separate reports previously.

Multi-parameter flow cytometry was performed on equivalent 4-, 5-, 6-, or 8-color instruments by the participating institutions, including a comprehensive panel targeting T-cell antigens. Testing was performed on lymph node samples when available. Peripheral blood was analyzed in cases 3 and 4. Bone marrow aspirate was studied in case 2, in addition to the lymph node. For analysis, cell populations were gated according to characteristic CD45 *vs* side scatter properties for primary gating of lymphocytes. Specifically, list mode files were evaluated using either CXP, CellQuest, Paint-a-Gate (Becton Dickinson), or Kaluza v1.2 software (Beckman Coulter, Brea, CA, USA) to assess angioimmunoblastic T-cell lymphoma-specific T-cell aberrancies, including (1) the presence of a CD3$^{-/dim}$CD4^{+} T-cell

Table 1 Immunohistology and flow cytometry data for F-PTCL cases

Case	*Age/sex*	*Stage*	*Architecture*	*HRS-like cells*	*% $CD3^{-(dim)}CD4^{+}$ of lymphocyte population*	*$CD3^{+}/CD10^{+}$ by FC*	*Positive T_{FH} markers*
1	85/M	III	Nodular	–	50	–	BCL6
2	51/M	IV	Nodular (NLPHL-like)	+	62	–[a]	PD1, ICOS, CXCL13, BCL6, and CD10
3	80/F	III	Nodular (LRCHL-like)	+	22.6	–	PD1, ICOS, CXCL13, and BCL6
4	50/F	IV	Nodular (LRCHL-like)	+	12.7	–[a]	PD1, ICOS, CXCL13, BCL6, and CD10
5	67/F	III	Nodular (MCCHL-like)	+	31	–	PD1, ICOS, and CXCL13
6	84/F	—	Nodular (LRCHL-like)	+	48	–	PD1 and CD10
7	64/F	IV	Nodular	–	7.9	–	PD1, ICOS, and CXCL13
8	72/F	—	Perifollicular	–	0	+[a]	PD1, ICOS, CXCL13, BCL6, and CD10
9	56/F	IV	Perifollicular	–	15.3	+[a]	PD1, BCL6, and CD10
10	61/F	III	Perifollicular	–	14.1	+	PD1, ICOS, CXCL13, and CD10

Abbreviations: +: present; –: absent; F: female; FC: flow cytometry; HRS: Hodgkin/Reed-Sternberg; NLPHL: nodular lymphocyte predominant Hodgkin lymphoma; LRCHL: lymphocyte-rich classical Hodgkin lymphoma; M: male; MCCHL: mixed cellularity classical Hodgkin lymphoma; PD1: programmed death-1 immunostain.
[a]$CD10^{+}$ lymphoid cells were seen corresponding to the T-cell areas by immunohistochemistry.

population; (2) $CD3^{+}/CD10^{+}$ co-expression; and (3) T-cell antigen loss including CD2, CD5, or CD7. List mode files were re-evaluated for all cases, where files were available for review.

Normal lymphoid cells within specimens served as internal positive and negative controls (eg, B cells served as negative controls for T-cell-directed antibodies), as well as for antibody-binding intensity. Although no definitive cutoff was used for intensity of expression, bright expression was defined as higher expression than normal T cells, whereas dim expression was defined as lower expression than that observed in normal T cells in concordance with the 1997 US–Canadian consensus guidelines[16] and 2006 Bethesda International Consensus Guidelines.[17] Partial expression was defined as a sub-population of neoplastic cells staining more intensely with an antibody than observed in the internal negative control cells.

Controls Cases

For comparison, 15 typical angioimmunoblastic T-cell lymphomas (reviewed by K.I, M.P.M, G.V, A. S.D, and M.J.B) and 8 typical classical Hodgkin lymphoma cases (reviewed by G.V. and M.A.) were analyzed at the University of Chicago using the FC500 flow cytometer for acquisition (Beckman Coulter). An additional confirmatory tube (CD45/CD19/CD3/CD4/CD14) was performed in one classical Hodgkin lymphoma case to ascertain that we were not misinterpreting monocytes ($CD3^{-}CD4^{dim}$) as an abnormal lymphoid population. In this analysis, we observed no monocyte contamination and thereafter concluded that CD45 *vs* side scatter itself afforded sufficient exclusion of monocytes expressing dimmer CD4 compared with T cells. In addition, 15 nodular lymphocyte predominant Hodgkin lymphoma cases and 26 reactive lymphoid tissues representing a variety of histologic patterns were examined using the FACSCalibur flow cytometer with data acquisition using CellQuest software (BD Biosciences, San Jose, CA, USA).

Statistical Analysis

Basic descriptive statistics comparing median percentages between two groups (Wilcoxon rank-sum test) were performed using Stata 11 (Statacorp, College Station, TX, USA).

Results

Diagnosis and Characterization of Peripheral T-Cell Lymphoma of Follicular Type Cases

Table 1 depicts a summary of the clinical and histologic features of all 10 cases of peripheral T-cell lymphoma of follicular type. Five had lymphocyte-rich classical Hodgkin lymphoma- or nodular

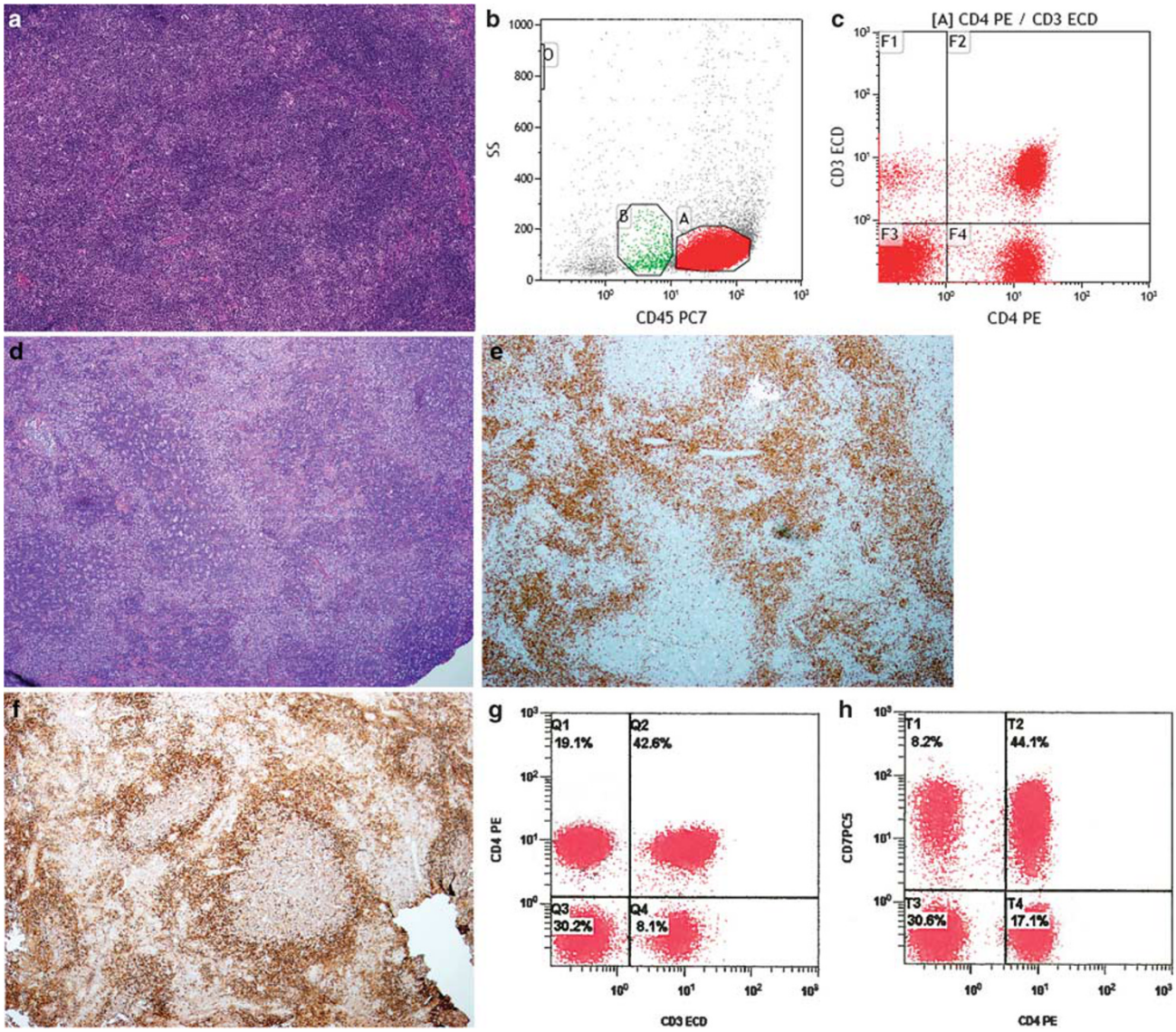

Figure 1 (**a**) Representative peripheral T-cell lymphoma of follicular type in a lymph node biopsy (case 2) that showed a vaguely nodular grown pattern and lymphocyte-rich classical Hodgkin lymphoma-like morphology (H&E, original magnification X200). (**b**) Flow cytometry showed lymphocytes (gate A colored red) with a significant population of $CD3^{-/dim}CD4^{+}$ T cells (quadrant F4), constituting over 40% of $CD4^{+}$ lymphocytes. In this case, most of the T cells were found to be predominantly $CD4^{+}$ with only few $CD8^{+}$ events. There were no other T-cell antigenic aberrancies in this case. (**d**) Representative peripheral T-cell lymphoma of follicular type with a perifollicular growth pattern (case 9), showing a serpiginous follicular pattern with reactive germinal centers and a prominent cuff of clear perifollicular cells. This cuff of lymphoid cells expressed CD3 (**e**) and PD1 (**f**). (**g**) Flow cytometry identified an expanded aberrant $CD3^{-/dim}CD4^{+}$ T-cell population (quadrant Q1) with loss of CD7 (quadrant T4, **h**).

Figure 2 (**a**) Another case of peripheral T-cell lymphoma of follicular type (case 5) showing a vaguely nodular architecture and capsular fibrosis (H&E, ×40). (**b**, **c**) There were singly scattered Hodgkin/Reed-Sternberg-like cells in a lymphocyte-rich background without significant vascularity (H&E, ×200), but with focal clusters of neutrophils (**d**, **h**, **e**, ×200) and eosinophils (not shown). (**e**) Single nodule with only few scattered $CD20^{+}$ small background B cells; the large cells were negative for CD20 (arrow; CD20 immunoperoxidase, ×100). (**f**) Most of the background lymphoid cells were $CD3^{+}$ T cells (**f**), of which the $CD4^{+}$ population (**g**) predominated over $CD8^{+}$ cells (**h**), and most expressed PD1 (**i**). The Hodgkin/Reed-Sternberg-like cells expressed Pax-5 (**j**), weak Mum1 (**k**), Bob.1 (**l**), and CD30 (**m**). However, flow cytometry showed a large population of T-cells expressing CD4 without surface CD3 (**n**, colored red) that clustered with the normal T-cells expressing CD2 and CD7 (**o**), and that were negative for CD8 and CD56 (**p**). This abnormal population demonstrated negative-dim surface CD3 and positive cytoplasmic CD3 expression, whereas the normal T cells demonstrated moderate surface and cytoplasmic CD3 (**q**). This case was initially thought to represent a classical Hodgkin lymphoma with some features reminiscent of mixed cellularity subtype. However, PCR for T-cell receptor gamma gene rearrangement performed in view of the atypical T-cell population identified a clonal T-cell gene rearrangement, allowing for the correct diagnosis of peripheral T-cell lymphoma of follicular type with EBV-negative Hodgkin/Reed-Sternberg-like cells.

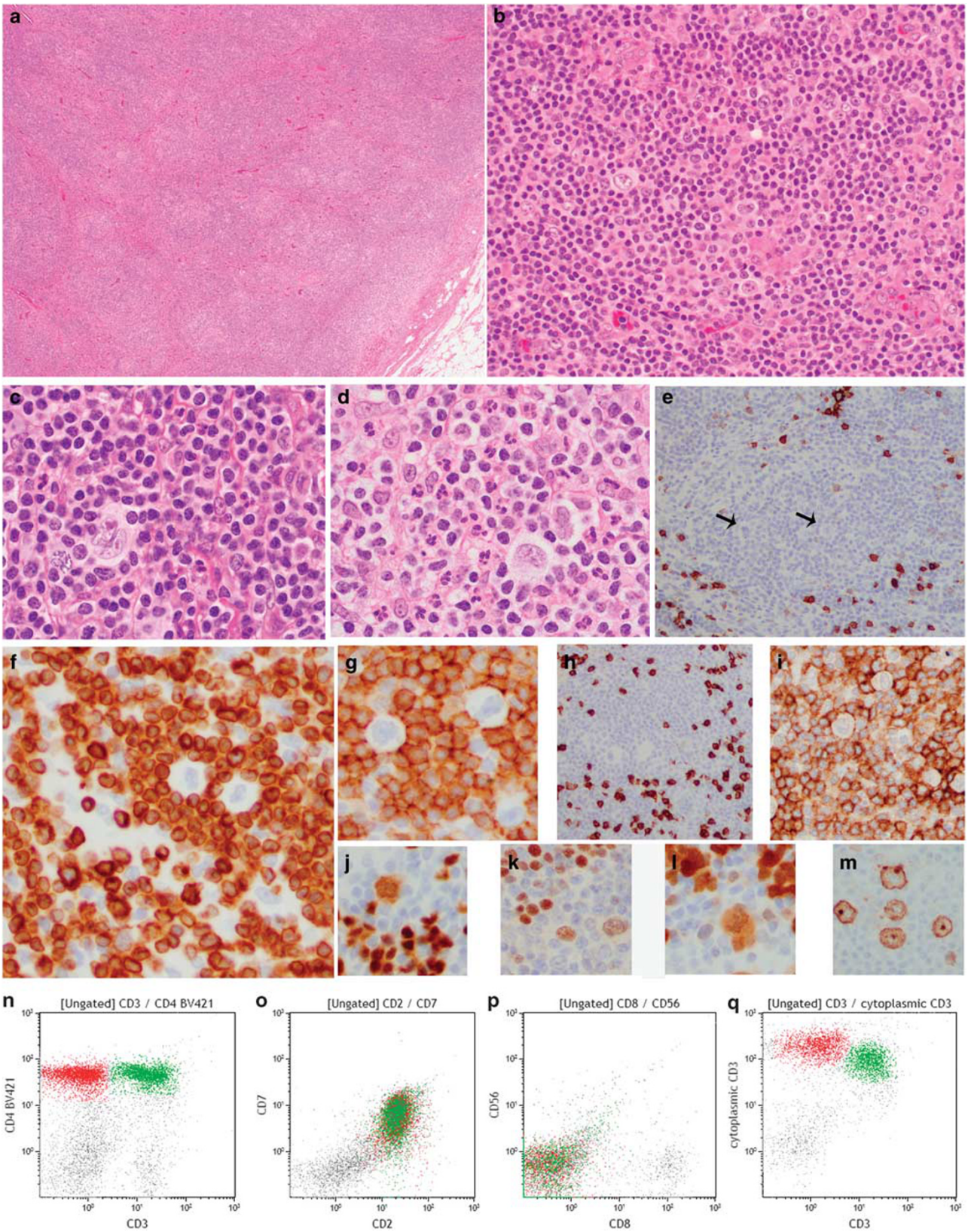
a
b
c
d
e
f
g
h
i
j
k
l
m
n
[Ungated] CD3 / CD4 BV421
CD4 BV421
CD3
o
[Ungated] CD2 / CD7
CD7
CD2
p
[Ungated] CD8 / CD56
CD56
CD8
q
[Ungated] CD3 / cytoplasmic CD3
cytoplasmic CD3
CD3

lymphocyte predominant Hodgkin lymphoma-like architecture with associated Hodgkin/Reed-Sternberg-like cells that showed positivity for CD20, CD30, and MUM1. Case 5 showed foci with neutrophils and eosinophils with some features of mixed cellularity classical Hogdkin lymphoma. Three additional cases had a nodular architecture and three others exhibited a perifollicular growth pattern with reactive appearing follicles, but without associated Hodgkin/Reed-Sternberg-like cells. None of the peripheral T-cell lymphomas of follicular type with nodular architecture exhibited fibrosis in a pattern to suggest nodular sclerosis classical Hodgkin lymphoma. Immunohistochemistry was performed extensively in all 10 cases, which shared a predominance of CD4+ T cells (10/10 cases) with increased PD1$^+$ cells in 9 of 10 cases tested. The three cases with a perifollicular pattern had prominent CD10+/BCL6+ lymphoid cells in the perifollicular areas spatially corresponding to CD3+ T cells (Figure 1). Testing for Epstein–Barr virus by *in situ* hybridization was positive in 1 of 10 cases. More extensive T-cell/follicular helper T-cell-specific stains were performed in cases 1, 3, and 4; these results are discussed in detail in the reports by Jiang[18] and Moroch,[10] and not further elaborated here.

Flow Cytometry Findings in Peripheral T-Cell Lymphomas of Follicular Type

Flow cytometry findings are summarized in Table 1. In 9 of 10 (90%) cases, we identified a distinct population of CD3$^{-/dim}$CD4$^+$ T cells that constituted a mean of 29.3% (range 7.9–62%) of all lymphocytes gated (Figures 1 and 2). A normal population of CD3$^+$ T cells was also present in all cases. Both CD3$^{-/dim}$ and CD3$^+$ subsets expressed pan-T-cell markers CD2 and CD5. CD7 was lost in 1 of 10 cases. For two cases in which B cells were examined further, we did not identify any associated monotypic B-cell population. Flow cytometry on cases 3 and 4 was performed on peripheral blood specimens, although the remaining cases were done on involved lymph nodes. Case 2 showed bone marrow involvement by the CD3$^{-/dim}$CD4$^+$ population, although morphologic evidence of bone marrow involvement was not present. Peripheral blood was not tested in this case. There was no correlation between the percentages of CD3$^{-/dim}$CD4$^+$ T cells and the presence of morphologic features approximating typical/advanced angioimmunoblastic T-cell lymphoma. CD10 expression on the atypical T-cell population by flow cytometry was restricted only to the three cases with a perifollicular histologic growth pattern, two of which also harbored a distinct CD3$^{-/dim}$CD4$^+$ T-cell population. CD10 expression was absent in all cases with a nodular growth pattern.

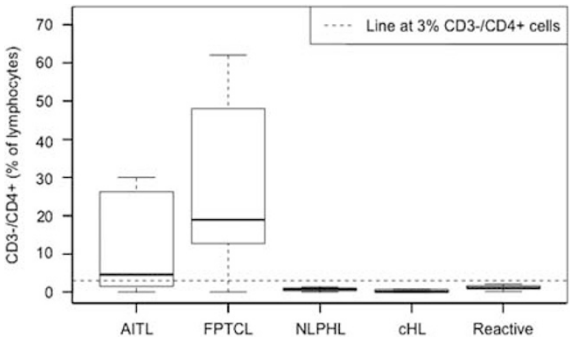

Figure 3 Box plot depiction of peripheral T-cell lymphoma of follicular type, angioimmunoblastic T-cell lymphoma, nodular lymphocyte predominant Hodgkin lymphoma, classical Hodgkin lymphoma, and reactive hyperplasia cases for the percentage of CD3$^-$CD4$^+$ population (with horizontal line representing the median) in each of the diagnostic categories. Both angioimmunoblastic T-cell lymphoma and peripheral T-cell lymphoma of follicular type contained significantly higher median CD3$^-$CD4$^+$ lymphoid cells compared with the other three groups; angioimmunoblastic T-cell lymphoma *vs* peripheral T-cell lymphoma of follicular type ($P = 0.51$) or a follicular helper T-cell proliferation *vs* Hodgkin lymphoma ($P = 0.001$).

Flow Cytometry Findings of Control Angioimmunoblastic T-Cell Lymphoma, Hodkgin Lymphoma, and Reactive Hyperplasia Cases

Figure 3 depicts angioimmunoblastic T-cell lymphoma and Hodgkin lymphoma control cases, as compared with peripheral T-cell lymphomas of follicular type with respect to the atypical CD3$^{-/dim}$ CD4+ T-cell population. Eleven of 15 (73.3%) angioimmunoblastic T-cell lymphoma controls harbored an aberrant CD3$^{-/dim}$CD4+ T-cell population (mean: 19.5%, range: 3–71.8% of all lymphocytes). Of these, only 5 of 15 showed a CD3$^+$/CD10$^+$ T-cell population (average 14.1%, range 2.5–51% of all lymphocytes; Figure 4). T cells were predominantly CD4$^+$, with an average CD4:CD8 ratio of 3.7. Ten of 15 cases showed loss of CD7, with normal expression of CD2 and CD5 in all cases. In another case without CD3 and CD4 in one tube, we observed a small CD3$^-$/CD5$^+$ population negative for CD19. This population of 3% of all lymphocytes was identified in another tube based on the CD3$^+$/CD2$^+$/CD7$^-$ phenotype to be exclusively CD4$^+$.

By flow cytometry, all eight classical Hodgkin lymphomas showed CD4$^+$ T-cell predominance with an average CD4:CD8 ratio of 3.2. All showed $< 2\%$ CD3$^{-/dim}$CD4$^+$ T cells (mean 0.45% of all lymphocytes; range 0–1.9%). For assessment of CD10 coexpression on T cells, CD5 was used as a surrogate for CD3$^+$ T cells, as a separate tube combining CD3 with CD10 was not available. CD5$^+$/CD10$^+$ populations were minimal in all eight cases analyzed (mean 2.9% of lymphocytes, range 0–9%), without distinct clusters in the dot plots. These cells were not CD19$^+$ B cells.

The 15 nodular lymphocyte predominant Hodgkin lymphomas showed CD4$^+$ T-cell predominance with a CD4:CD8 ratio of 4.1. The CD3$^{-/dim}$CD4$^+$ T-cell

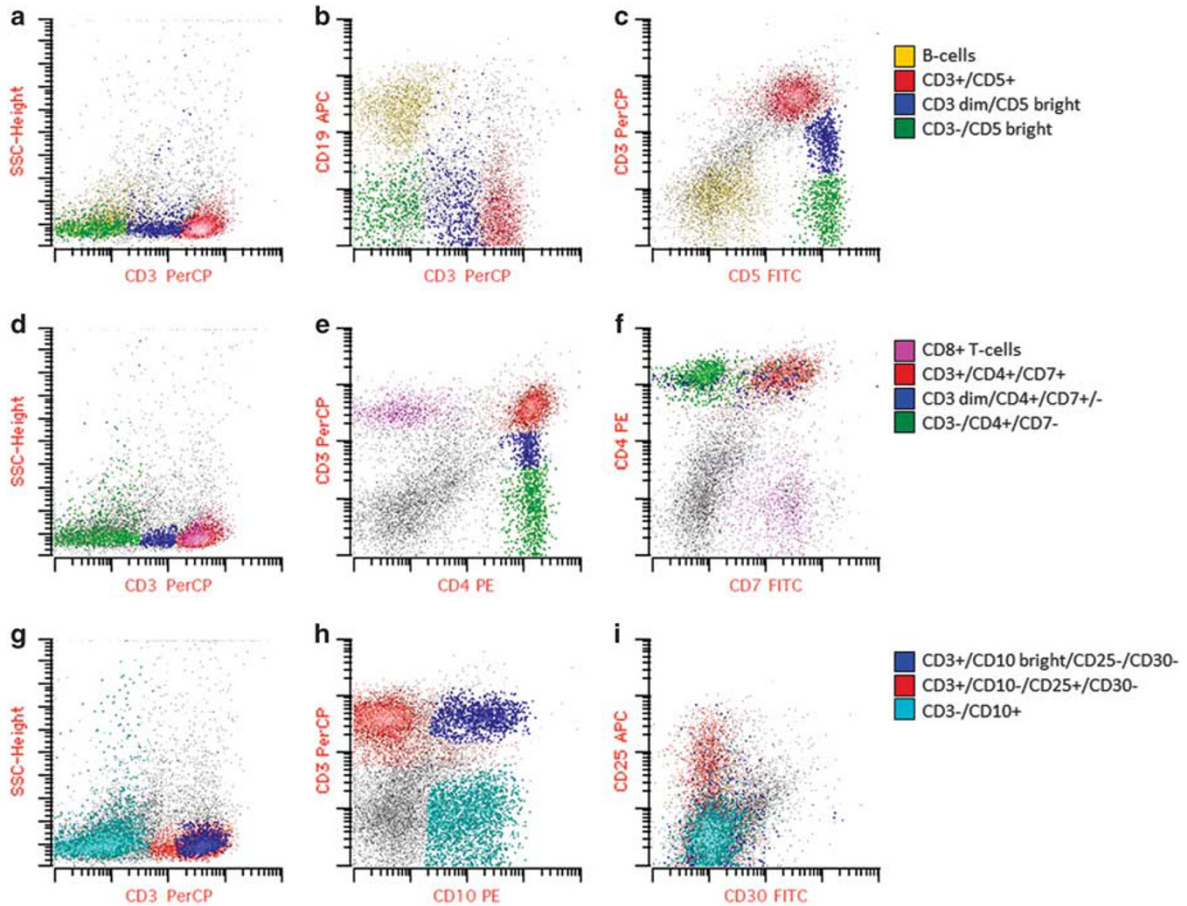

Figure 4 Representative FC findings of a control angioimmunoblastic T-cell lymphoma case (lymph node). (**a–c**) The node contained a mixture of B- and T cells with an unusual T-cell population, showing loss of surface CD3 expression (cyan and green). (**d–f**) This abnormal CD3 $^{-/dim}$ T-cell population was CD4^{+} and negative for CD7. (**g**, **h**) A subset of the CD10-bright cells coexpressed CD3. SSC, side scatter; FSC, forward scatter; FITC, fluorescein isothiocyanate; PE, phycoerythrin; PerCP, peridinin chlorophyll protein; APC, allophycocyanin. In another case (not depicted), there were overall 3% abnormal CD3^{-}CD4^{+} cells among all lymphocytes with a CD4:CD8 ratio of 4:1 and a 35% CD7^{-} subset. Examination of the CD7^{-} subset of T cells in this case showed a CD4:CD8 ratio of 10:1 with nearly 10% CD3^{-}CD4^{+} T cells.

population was minimal, averaging 0.73% of the total lymphocyte population in these cases (range: 0.05–1.43%) did not form distinct clustering in the dot plots. Ten of 15 cases showed a significant (>3%) population of dual CD4^{+}/CD8^{+} T cells, described previously as a characteristic flow cytometric finding in nodular lymphocyte predominant Hodgkin lymphoma.[19]

Of the 26 reactive lymphoid tissues examined by FC, the CD3$^{-/dim}$CD4^{+} T-cell averaged 1.2% of the total lymphocyte population (range: 0.19–3.0%). Histologic finding in some of these included follicular hyperplasia ($n=8$, including two with well-controlled human immunodeficiency virus infection), progressive transformation of germinal centers ($n=3$), and others with a non-specific mixed pattern.

Discussion

In this study, we present flow cytometry findings from histologically well-characterized peripheral T-cell lymphomas of follicular type, including three perifollicular cases and five with a nodular pattern, resembling classical Hodgkin lymphoma/nodular lymphocyte predominant Hodgkin lymphoma. We identified the frequent presence of a CD3$^{-/dim}$CD4^{+} T-cell population in 90% of peripheral T-cell lymphomas of follicular type, a similar frequency to that reported in angioimmunoblastic T-cell lymphomas, in keeping with their common origin from follicular helper T cells. A smaller proportion of peripheral T-cell lymphomas of follicular type in our series (30%) showed CD3/CD10 co-expression, a feature reported in over 80% of angioimmunoblastic T-cell lymphoma cases.[20] This finding appeared to be restricted to cases with a perifollicular growth pattern, and was not seen in cases with nodular growth and Hodgkin/Reed-Sternberg-like cells.

de Leval and co-workers first described three cases of peripheral T-cell lymphomas with a striking nodular or predominant follicular growth pattern associated with follicular dendritic cell meshworks.[2] The authors noted that these cases were distinct from

bona fide angioimmunoblastic T-cell lymphomas owing to the lack of the vascularity, extrafollicular dendritic cell meshworks, and absence of B-cell blasts. By immunohistochemistry, these tumors were described as having a $CD3^+CD4^+$ phenotype. The difference between immunophenotypic findings by immunohistochemistry *vs* flow cytometry may be related to the detection of cytoplasmic, but not surface CD3 with the former technique. In one of the cases in that series, flow cytometry was performed although $CD3^-CD4^+$ cells were not described. Since then, flow cytometry data was not reported or discussed in subsequent larger series on peripheral T-cell lymphomas of follicular type.[6,21]

Diagnosis of peripheral T-cell lymphomas may be difficult and there are two specific situations, in which our findings can contribute to more accurate diagnosis. The first is in cases of early angioimmunoblastic T-cell lymphomas with a reactive hyperplasia pattern, wherein the neoplastic follicular helper T-cell proliferation is restricted topographically to the perifollicular regions in the vicinity of the perifollicular sinus with largely preserved germinal center architecture; such cases may be misinterpreted as a benign process if this focal proliferation is overlooked. The second situation is a predominantly nodular lymphoproliferation with or without associated $CD30^{\pm}$ and/or $CD20^+$ Hodgkin/Reed-Sternberg-like cells, in which the differential diagnosis includes both peripheral T-cell lymphoma of follicular type and Hodgkin lymphoma, including nodular lymphocyte predominant Hodgkin lymphoma and lymphocyte-rich classical Hodgkin lymphoma.

In reference to the former situation, cases of peripheral T-cell lymphomas of follicular type with a reactive perifollicular growth pattern have been reported previously[1,9,21] and may be misinterpreted as a reactive follicular hyperplasia owing to the relative preservation of nodal architecture in such cases. Although our series is small, it is notable that two of three cases with the perifollicular pattern showed the $CD3^{-/dim}CD4^+$ T-cell population. Although all three cases demonstrated an aberrant $CD3^+CD10^+$ T-cell population, recent data indicates that CD10 expression may be less specific in as much as certain normal T-cells subsets (in reactive nodes, as well as some B-cell lymphomas) may express CD10.[22,23] In one of the larger series examining 10 angioimmunoblastic T-cell lymphomas with a perifollicular 'pattern 1' morphology, flow cytometry findings were not available.[9] More recent larger series reporting flow cytometry data on angioimmunoblastic T-cell lymphomas focus only on the sensitivity and specificity of the $CD3^+CD10^+$ T-cell population for an overt angioimmunoblastic T-cell lymphoma phenotype and did not include cases of peripheral T-cell lymphomas of follicular type with either follicular or perifollicular growth patterns.[15]

Challenges in making a diagnosis of peripheral T-cell lymphoma of follicular type include its predominant nodular growth pattern and the occasional presence of Hodgkin/Reed-Sternberg-like cells that raise the differential diagnosis of nodular lymphocyte predominant Hodgkin lymphoma or lymphocyte-rich classical Hodgkin lymphoma with a nodular growth pattern (so-called 'follicular Hodgkin's disease' described by Ashton-Key *et al*).[24] In our series, cases 2, 5, and 6 were initially diagnosed as Hodgkin lymphoma, but molecular studies confirmed the diagnosis of a peripheral T-cell lymphoma. On the basis of our findings, we would like to suggest the use of a flow cytometry panel comprising CD3, CD14, CD4, CD5, and CD10. Although a basic panel with CD3/CD4/CD8/CD10 would likely be sufficient in making the diagnosis, the combination with the addition of CD14 and CD5, helps to identify $CD3^{-/dim}CD4^+$ T cells, excludes possible monocytic derivation of this population, and identifies $CD3^+CD10^+$ T cells, whereas the pan-T-cell antigen CD5 would pick up the CD3-negative T-cell population. Although the absence of the $CD3^{-/dim}CD4$ population does not exclude a follicular helper T-cell proliferation, its presence at $>3\%$ of all lymphocytes in a lymphoma histologically resembling Hodgkin lymphoma should certainly lead one to question the diagnosis of Hodgkin lymphoma and prompt further molecular genetic studies for the presence of a clonal T-cell gene rearrangement.

Our study demonstrates that identification of this characteristic $CD3^{-/dim}CD4^+$ T-cell population can be helpful in peripheral T-cell lymphomas with either a reactive hyperplasia-like or a nodular Hodgkin-like growth pattern. Our results are consistent with the growing evidence that the $CD3^{-/dim}$ $CD4^+$ T-cell population is frequently associated with an angioimmunoblastic T-cell lymphoma phenotype, observed in 50–100% of cases in prior series.[15,25,26] Given our finding of this population in the great majority of cases of peripheral T-cell lymphoma of follicular type, our results further emphasize the relationship between these two entities, although others have shown that there may be some unique molecular genetic differences between angioimmunoblastic T-cell lymphoma and non-angioimmunoblastic T-cell lymphoma follicular helper T-cell proliferations.[27–29]

One limitation of our study is that it is a retrospective analysis of flow cytometry data collected from multiple institutions and not all T-cell marker combinations could be uniformly examined on all cases via flow cytometry. Nevertheless, the fact that similar findings were detected in cases diagnosed at several different laboratories using various flow cytometry methodologies suggests the widespread utility of this population in supporting a diagnosis of peripheral T-cell lymphoma of follicular helper T-cell derivation. The diagnosis typically requires immunostains to demonstrate a follicular helper T-cell phenotype, such as PD1, CXCL13, and ICOS.[30,31] Although the diagnosis of peripheral

T-cell lymphoma of follicular type requires the confirmation of follicular helper T-cell derivation through expression of follicular helper T-cell-specific markers, these antibodies may not be routinely available in all laboratories; however, flow cytometry can be readily performed in such cases using commonly available antibodies such as CD3, CD4, and CD10, allowing for more rapid evaluation of these challenging cases. It also provides an important clue for the pathologist and would prompt the ordering of the follicular helper T-cell markers needed to make the diagnosis.

In summary, our findings demonstrate that a $CD3^{-/dim}CD4^{+}$ T-cell population is commonly found in cases of peripheral T-cell lymphomas of follicular type and angioimmunoblastic T-cell lymphomas, further supporting the relationship between these two follicular helper T-cell-derived neoplasms. In both sets of cases, the $CD3^{-/dim}CD4^{+}$ T-cell population was more frequently identified than a $CD3^{+}$ $CD10^{+}$ co-expressing population, and was absent or rare in control cases of Hodgkin lymphoma and reactive hyperplasia, underscoring its utility as a clue to the diagnosis of a peripheral T-cell lymphoma of follicular helper T-cell derivation, particularly in cases with morphologic and immunophenotypic features mimicking Hodgkin lymphoma. Hence, we strongly recommend performing flow cytometry in all cases morphologically resembling nodular lymphocyte predominant Hodgkin lymphoma or lymphocyte-rich classical Hodgkin lymphoma on initial evaluation, to exclude the possibility of a peripheral T-cell lymphoma of follicular helper T-cell derivation.

Disclosure/conflict of interest

The authors declare no conflict of interest.

References

1 Rüdiger T, Ichinohasama R, Ott MM, *et al.* Peripheral T-cell lymphoma with distinct perifollicular growth pattern: a distinct subtype of T-cell lymphoma? Am J Surg Pathol 2000;24:117–122.
2 de Leval L, Savilo E, Longtine J, *et al.* Peripheral T-cell lymphoma with follicular involvement and a CD4+/bcl-6+ phenotype. Am J Surg Pathol 2001;25:395–400.
3 Dupuis J, Boye K, Martin N, *et al.* Expression of CXCL13 by neoplastic cells in angioimmunoblastic T-cell lymphoma (AITL): a new diagnostic marker providing evidence that AITL derives from follicular helper T cells. Am J Surg Pathol 2006;30:490–494.
4 de Leval L, Rickman DS, Thielen C, *et al.* The gene expression profile of nodal peripheral T-cell lymphoma demonstrates a molecular link between angioimmunoblastic T-cell lymphoma (AITL) and follicular helper T (TFH) cells. Blood 2007;109:4952–4963.
5 Krenacs L, Schaerli P, Kis G, *et al.* Phenotype of neoplastic cells in angioimmunoblastic T-cell lymphoma is consistent with activated follicular B helper T cells. Blood 2006;108:1110–1111.
6 Huang Y, Moreau A, Dupuis J, *et al.* Peripheral T-cell lymphomas with a follicular growth pattern are derived from follicular helper T cells (TFH) and may show overlapping features with angioimmunoblastic T-cell lymphomas. Am J Surg Pathol 2009;33:682–690.
7 Quintanilla-Martinez L, Fend F, Moguel LR, *et al.* Peripheral T-cell lymphoma with Reed-Sternberg-like cells of B-cell phenotype and genotype associated with Epstein-Barr virus infection. Am J Surg Pathol 1999;23: 1233–1240.
8 Attygalle AD, Kyriakou C, Dupuis J, *et al.* Histologic evolution of angioimmunoblastic T-cell lymphoma in consecutive biopsies: clinical correlation and insights into natural history and disease progression. Am J Surg Pathol 2007;31:1077–1088.
9 Rodriguez-Justo M, Attygalle AD, Munson P, *et al.* Angioimmunoblastic T-cell lymphoma with hyperplastic germinal centres: a neoplasia with origin in the outer zone of the germinal centre? Clinicopathological and immunohistochemical study of 10 cases with follicular T-cell markers. Mod Pathol 2009;22:753–761.
10 Moroch J, Copie-Bergman C, de Leval L, *et al.* Follicular peripheral T-cell lymphoma expands the spectrum of classical Hodgkin lymphoma mimics. Am J Surg Pathol 2012;36:1636–1646.
11 Serke S, van Lessen A, Hummel M, *et al.* Circulating CD4+ T lymphocytes with intracellular but no surface CD3 antigen in five of seven patients consecutively diagnosed with angioimmunoblastic T-cell lymphoma. Cytometry 2000;42:180–187.
12 Attygalle AD, Diss TC, Munson P, *et al.* CD10 expression in extranodal dissemination of angioimmunoblastic T-cell lymphoma. Am J Surg Pathol 2004;28: 54–61.
13 Grogg KL, Attygalle AD, Attygale AD, *et al.* Expression of CXCL13, a chemokine highly upregulated in germinal center T-helper cells, distinguishes angioimmunoblastic T-cell lymphoma from peripheral T-cell lymphoma, unspecified. Mod Pathol 2006;19: 1101–1107.
14 Zhou Y, Attygalle AD, Chuang S-S, *et al.* Angioimmunoblastic T-cell lymphoma: histological progression associates with EBV and HHV6B viral load. Br J Haematol 2007;138:44–53.
15 Singh A, Schabath R, Ratei R, *et al.* Peripheral blood $sCD3^{-}$ $CD4^{+}$ T cells: a useful diagnostic tool in angioimmunoblastic T cell lymphoma. Hematol Oncol 2014;32:16–21.
16 Borowitz MJ, Bray R, Gascoyne R, *et al.* U.S.-Canadian Consensus recommendations on the immunophenotypic analysis of hematologic neoplasia by flow cytometry: data analysis and interpretation. Cytometry 1997;30:236–244.
17 Greig B, Oldaker T, Warzynski M, *et al.* 2006 Bethesda International Consensus recommendations on the immunophenotypic analysis of hematolymphoid neoplasia by flow cytometry: recommendations for training and education to perform clinical flow cytometry. Cytometry B Clin Cytom 2007;72(Suppl 1):S23–S33.
18 Jiang L, Jones D, Medeiros LJ, *et al.* Peripheral T-cell lymphoma with a "follicular" pattern and the perifollicular sinus phenotype. Am J Clin Pathol 2005;123: 448–455.
19 Rahemtullah A, Reichard KK, Preffer FI, *et al.* A double-positive CD4+CD8+ T-cell population is

commonly found in nodular lymphocyte predominant Hodgkin lymphoma. Am J Clin Pathol 2006;126: 805–814.
20 Baseggio L, Traverse-Glehen A, Berger F, *et al.* CD10 and ICOS expression by multiparametric flow cytometry in angioimmunoblastic T-cell lymphoma. Mod Pathol 2011;24:993–1003.
21 Ikonomou IM, Tierens A, Troen G, *et al.* Peripheral T-cell lymphoma with involvement of the expanded mantle zone. Virchows Arch 2006;449:78–87.
22 Amé-Thomas P, Hoeller S, Artchounin C, *et al.* CD10 delineates a subset of human IL-4 producing follicular helper T cells involved in the survival of follicular lymphoma B cells. Blood 2015;125:2381–2385.
23 Cook JR, Craig FE, Swerdlow SH. Benign CD10-positive T cells in reactive lymphoid proliferations and B-cell lymphomas. Mod Pathol 2003;16:879–885.
24 Ashton-Key M, Thorpe PA, Allen JP, *et al.* Follicular Hodgkin's disease. Am J Surg Pathol 1995;19:1294–1299.
25 Merchant SH, Amin MB, Viswanatha DS. Morphologic and immunophenotypic analysis of angioimmunoblastic T-cell lymphoma: Emphasis on phenotypic aberrancies for early diagnosis. Am J Clin Pathol 2006;126: 29–38.
26 Stacchini A, Demurtas A, Aliberti S, *et al.* The usefulness of flow cytometric CD10 detection in the differential diagnosis of peripheral T-cell lymphomas. Am J Clin Pathol 2007;128:854–864.
27 Piccaluga PP, Fuligni F, De Leo A, *et al.* Molecular profiling improves classification and prognostication of nodal peripheral T-cell lymphomas: results of a phase III diagnostic accuracy study. J Clin Oncol 2013;31: 3019–3025.
28 Iqbal J, Wright G, Wang C, *et al.* Gene expression signatures delineate biological and prognostic subgroups in peripheral T-cell lymphoma. Blood 2014;123: 2915–2923.
29 Cairns RA, Iqbal J, Lemonnier F, *et al.* IDH2 mutations are frequent in angioimmunoblastic T-cell lymphoma. Blood 2012;119:1901–1903.
30 Zhan H-Q, Li X-Q, Zhu X-Z, *et al.* Expression of follicular helper T cell markers in nodal peripheral T cell lymphomas: a tissue microarray analysis of 162 cases. J Clin Pathol 2011;64:319–324.
31 Swerdlow SH, Campo E, Pileri SA, *et al.* The 2016 revision of the World Health Organization (WHO) classification of lymphoid neoplasms. Blood 2016;127: 2391–2405.