

Stentless BPs: cause and mode of SVD					
Stentless BP model	Nr	Mean patient age (yrs)	Time in place (mos)	Major pathology	Dysfunction
Toronto S. Jude Medical	10	46.9±9.98	119.1±25.08	Calcific dystrophy, commissural tearing, lipidoses, fibrous pannus, primary tearing	INCOMPETENCE
Cryolife	11	62.09±14.90	113.09±33.22	Calcific dystrophy, commissural tearing, lipidoses, perforations	INCOMPETENCE
BioCor	5	67.2±5.44	113.8±35.20	Calcific dystrophy, commissural tearing, primary tearing	INCOMPETENCE STENOSIS/INCOMPETENCE
Freedom Stentless Sorin	6	65.66±13.58	76.83±14.49	Calcific dystrophy, commissural tearing, lipidoses	INCOMPETENCE STENOSIS
Prima Plus Carpenter-Edwards	2	65.5±6.36	134±65.05	Calcific dystrophy, commissural tearing, lipidoses	INCOMPETENCE

Figure 1

**Conclusions:** Dystrophic calcification, lipid insudation, with cusp tearing and incompetence are the substrate and mode of failure of stentless BPs. Longest durability was observed in stentless valves with anticalcification treatment. Surgical pathology is in keeping with a redo by valve-in-valve TAVI.

### 376 Temporal Small Arterial Inflammation Is Common in Patients with Giant Cell Arteritis

CL Zhao, A Amin. Rhode Island Hospital, Providence, RI.

**Background:** Giant Cell Arteritis (GCA) is considered a systemic arteritis mainly involving medium to large arteries. There is little information about arteriolar arteritis in GCA with unknown implications.

**Design:** Between 2008 and 2013, 90 temporal artery specimens were found in the archives of Rhode Island Hospital. The slides and medical records were reviewed retrospectively, comparing the manifestations and clinical correlates. The following parameters were reviewed: age, gender, fever, headache, scalp tenderness, jaw claudication, visual symptom (diplopia, blurred vision and diminished acuity), weight loss, ESR, hemoglobin, p-ANCA, ANA, and polymyalgia rheumatica. Statistical analysis was performed utilizing SigmaStat software, version 3.5 for Man-Witney Rank-Sum test and Fisher Exact test.  $P < 0.05$  was considered as statistically significant.

**Results:** Sixty-two patients met the 1990 American College of Rheumatology (ACR) criteria for the diagnosis of GCA and were included in the analysis [sex distribution: 16 males and 46 females ( $p=0.477$ ); age range 51-90 years (mean of  $76.5 \pm 1.067$ )]. Twenty-six specimens (5 male, 21 female) demonstrated temporal arteritis and small arterial inflammation (TSAI) and 36 specimens (11 male and 25 female) demonstrating temporal arteritis without small arterial inflammation (T-non-SAI). Binary logistic regression was applied with the attributes found to be significantly related with TSAI; however there was no statistical difference in signs and symptoms and hemoglobin level between the TSAI and T-non-SAI groups. ESR was 80 mm/hour in TSAI and 62 mm/hour in T-non-SAI;  $p=0.095$ ). Serum p-ANCA was assessed in 12 patients and 2 patients were positive ( $\geq 1:20$ ). Both cases showed severe clinical manifestation of temporal arteritis including polymyalgia rheumatica and vision loss that required Emergency Room admission and high-dose steroids.

**Conclusions:** Simultaneous involvement of arterioles and medium to large sized arteries is common in GCA. Despite a postulation for coexisting microscopic polyangiitis and GCA, the disease manifestations and course is similar between TSAI and T-non-SAI cases in our series. We believe that in the context of GCA, involvement of smaller arteries should be expected. TSAI with p-ANCA positive may have more severe symptoms and require aggressive therapy.

## Cytopathology

### 377 Immunolocalization of Pancreatic Epithelial Cells from EUS-FNA with Magnetic Beads for Downstream Molecular Application

A Affify, S Urayama. UC Davis, Sacramento, CA.

**Background:** Evaluation of pancreatic masses is routinely performed by endoscopic ultrasound-guided fine needle aspiration (EUS-FNA). However, molecular analyses of the tumor cells in FNA samples are limited by the significant cellular heterogeneity. The goal of the current study is to evaluate a magnetic immunoconcentration technique for isolating pancreatic epithelial cells from needle aspirates and to demonstrate that the isolated cells could be utilized for molecular analysis.

**Design:** All samples included in the study were obtained by EUS-FNA. After adequate sampling for cytopathological evaluation, three additional needle passes were collected individually into a microfuge tube with RNAlater and stored at  $-80^{\circ}\text{C}$ . Based on the final cytopathological diagnosis, 17 adenocarcinoma, 2 lymphoma, and 2 benign cases were retrieved from the collection for further analyses. After thawing the frozen specimen, a cytospun slide was prepared and stained with Pap stain for cytology evaluation to confirm the diagnosis and determine the types of cells present. Epithelial cells were isolated using anti-human epithelial cell specific antibody-bound magnetic beads

(Invitrogen, Carlsbad, CA). The isolated cellular component was examined cytologically and Genomic DNA was extracted, quantitated and evaluated with methylation-specific PCR for methylation of the promoter region of the cyclin D2 gene.

**Results:** Evaluation of cytospun slides prepared directly after thawing the frozen specimen confirmed the original diagnosis and the presence of the neoplastic cells admixed with histiocytes, lymphocytes, fibro-connective tissue, and RBCs. After optimization of the technique, we isolated malignant epithelial cells successfully from all adenocarcinoma cases. Normal pancreatic ductal cells were isolated from the 2 benign cases. No cells could be isolated from the cases of lymphoma. The mean DNA yields was 357 ng. Methylation-specific PCR for cyclin D2 showed a methylated state at the promoter region, demonstrating feasible evaluation of the methylation status.

**Conclusions:** Magnetic immunoconcentration of pancreatic EUS-FNA specimens, as described in this study, is a practical method of isolating pancreatic epithelial cells from needle aspirates. This methodology is a relatively easy allowing molecular analysis of pancreatic neoplasms, which may be adaptable for future molecular signal or biomarker assays.

### 378 Proteomic Analysis and Characterization of Effusion Fluid

A Affify, A Eldridge, B Chromy. UC Davis, Sacramento, CA.

**Background:** Tumor cells in malignant effusion shed surface proteins and secrete growth factors and cytokines, which leads to changes in the proteome of effusions. Expression pattern analysis of these proteins could be used to differentiate malignant from benign effusions and provide potential diagnostic biomarkers. The purpose of this study was to compare the expression profiles of fractionated proteins from benign and malignant effusions in order to detect and identify proteins that show differential expression.

**Design:** Effusion samples were centrifuged and the supernatant was retained and stored at  $-80^{\circ}\text{C}$ . Removal of six high abundant proteins was performed using affinity chromatography. The remaining portion of each sample was individually labeled with fluorescent dyes and proteins were separated using two-dimensional differential gel electrophoresis technique. The gels were scanned using specific excitation/emission wavelengths for each dye using a Typhoon 9410 scanner. Image analysis was performed using Amersham DeCyder 7.0 software for spot detection, quantitation and gel-to-gel matching. Differential expression of proteins between benign and malignant effusions was determined based on set of selection criteria include t-test score, average ratio and one-way ANOVA. Selected gel spots were subjected to protein identification by liquid chromatography-tandem mass spectrometry. Peak lists were generated for each protein spot and searched against the human International Protein Index database using Mascot search engine.

**Results:** We analyzed 28 effusion samples including 12 malignant (breast, lung and ovary, 4 cases each) and 16 benign. The mean number of protein gel spots identified among all cases was  $1400 \pm 200$ . Thirty five protein spots showing differential protein expression levels between benign and malignant effusions were further evaluated using principle component analysis and hierarchical clustering. Malignant effusions showed 19 up-regulated and 16 down-regulated protein spots. Of the 35 differential protein spots, 24 were successfully identified and was subjected to functional analysis and correlated to the cause of the effusion.

**Conclusions:** Our results represent a first step toward understanding the complexity of effusion proteomes. This work provides a baseline expression profile for future use in determining key proteins that can differentiate between benign and malignant effusions. We expect that this work will ultimately contribute to improved biomarker discovery. In addition, proteins that change in expression may lead to additional clues to help our understanding of cancer.

### 379 EUS-FNA of Focal Liver Lesions: A Retrospective Study from an Academic Tertiary Center

R Albadine, G Soucy, B Nguyen, S Paquin, A Sahai, G Garipey. Centre Hospitalier de l'Université de Montréal, Montreal, QC, Canada.

**Background:** EUS-FNA of the liver is a safe procedure with high diagnostic yield and impact on patient management (Evidence level 2+ according to European Society of Gastrointestinal Endoscopy). Only a few studies with large cohort were identified in the literature. We report our experience of EUS-FNA cytology of focal liver lesions.

**Design:** All liver lesions with EUS-FNA, performed by 2 gastroenterologists, between 2003 to 07-2013 were retrieved in our lab. All available data were collected. Rapid on site cytopathology evaluation (ROSE) was available for almost all cases. Immunohistochemistry (IHC) study was performed when cell block was available. Cases were classified as inadequate (acellular, non-representative), negative for malignant cells (adequate and benign), atypical, suspicious and positive for malignant cells.

**Results:** We identified 593 EUS-FNA specimens. Of these, 429 were positive, 130 were negative, 12 were atypical, 5 suspicious and 17 (2%) were non diagnostic. There were 403 carcinomas included: 313 adenocarcinomas (cholangio and metastatic), 2 squamous cell carcinomas, 27 neuroendocrine tumors, 25 small cell carcinomas (SCC), 26 non SCCs and 9 hepatocellular carcinomas (HCC). A precise diagnosis was possible in 9 of the 26 other positive cases: 3 gastrointestinal stromal tumors; 5 Lymphomas: 4 non-Hodgkin lymphomas and 1 Lymphocyte-depleted classical Hodgkin lymphoma; and 1 Melanoma. The benign lesions were 10 abscesses, 2 granulomas and 2 with steatotic hepatocytes. Of the 5 cases with suspicious cytology: 2 patients were submitted to biopsy and the diagnosis was HCC in one case and metastatic mucinous adenocarcinoma, in the other. Most atypical cytology diagnosis was post-radiation. Discrepancies were seen in 3 cases of HCCs: one HCC with lipidic changes was misdiagnosis as steatosis, and 2 well differentiated HCC, where cytologic diagnosis was on smears only without cell block for IHC. EUS-FNA was repeated in 13 patients with inadequate, negative or atypical cytology. Four were reclassified as positive.

**Conclusions:** EUS-FNA of the liver is a safe and sensitive procedure. Positive cases were often metastatic adenocarcinomas from pancreas and colorectal cancers. The ROSE reduces the inadequate cases and is very helpful when lymphoma is suspected. Well differentiated HCC is a diagnostic challenge especially without IHC. Correlation of cytomorphologic features and ancillary studies with the clinico-radiological information is essential to establish an accurate diagnosis.

### 380 Inter-Observer Variability of Two-Tiered Atypia Grading in Endoscopic Ultrasound Guided Fine Needle Aspirations of Cystic Mucinous Pancreatic Neoplasms

*B Arville, H Evans, S Al Diffalha, G Barkan, S Pambuccian, M Atieh.* Loyola University Medical Center, Maywood, IL.

**Background:** An emerging topic in fine needle aspirations (FNAs) of pancreatic mucinous neoplasms is reporting the grade of atypia, if present. Clinical management may be impacted by the degree of atypia. We studied the inter-observer variability of grading atypia according to the criteria proposed by the Papanicolaou Society of Cytopathology and the follow up histopathologic correlation on the cases.

**Design:** Pancreatic FNAs with subsequent surgical biopsy/resection (2010-2013) were examined. Pancreatic FNAs with a diagnosis of adenocarcinoma, suspicious for adenocarcinoma, neuroendocrine tumor, or solid pseudopapillary tumor were excluded. Three cytopathologists (CPs), blinded to the original cytologic diagnosis and the follow-up surgical biopsy/resection final diagnoses, graded each FNA for atypia. All participants were board certified CPs with varying levels of experience who received training at different institutions; conditions which reflect the overall cytopathology community. All CPs based their grading on examination of all available slides, modeling clinical signout conditions. Cases were graded as either negative/low grade (LG) or high grade (HG) (moderate or severe). Surgical pathology diagnosis was considered to be the definitive histopathologic diagnosis. Inter-observer variability was evaluated by Randolph free marginal multirater kappa (RFMMK). The consensus cytologic grade was that chosen by at least two CPs. A diagnosis of HG atypia was considered concordant with a histopathologic diagnosis of at least moderate dysplasia and LG atypia was considered concordant with LG dysplasia and benign entities. Sensitivity, specificity, PPV, and NPV were analyzed for consensus grading.

**Results:** A total of 39 FNAs were collected for review. The RFMMK coefficient for three observers was 0.18. Consensus grading had a sensitivity of 53.6% for the detection of HG atypia or malignancy. Specificity of consensus cytopathologic grading was 72.7%. The PPV of a consensus positive atypia grading was 65.2% and the NPV was 38.1%. All three CPs agreed on the grading of atypia in 10 of 39 cases.

**Conclusions:** Inter-observer variation and correlation with histology show substantial variability, which may reflect training and experience. Well-illustrated guidelines for grading of atypia may be useful to improve inter-observer variability. Although the RFMMK value is low, a consensus diagnosis has a fair predictive value for HG dysplasia which suggests review by two or more CPs is warranted in such cases.

### 381 The Significance of Repeated Cytology at the Time of First Colposcopy for ASC-H Patients

*SM Bakhiet, R O'Brien, A Kelly, N Bolger, C White, C Martin, T Darcy, JJ O'Leary.* Coombe Womens and Infants University Hospital, Dublin, Ireland; Trinity College Dublin, Dublin, Ireland.

**Background:** Since a high grade squamous intraepithelial lesion (HSIL) cannot be excluded in ASC-H, triage directly to colposcopy is recommended by the ASCCP for ASC-H diagnosis. The value of repeat cytology in the detection of high-grade cervical dysplasia was investigated at first time of colposcopy in women with ASC-H referral cytology.

**Design:** Retrospectively collected data from 255 women with an ASC-H referral to colposcopy were assessed. In order to determine the utility of repeat cytology in ASC-H referral, patients with a valid repeat cytology result at initial colposcopy were included. Corresponding histological diagnosis, taken at initial colposcopy or follow up, was also available. This resulted in 120 ASC-H referrals accessible for analysis. The data was assessed to determine agreement between referral cytology (ASC-H) and repeat cytology, taken at first visit to colposcopy. The clinical sensitivity and specificity of a repeat cytology for detection of CIN 2+ was calculated using histology as a gold standard.

**Results:** Repeat cytology results from 120 patients indicated 18.3% (22) were negative, 24.1% (29) were LSIL and 57.5% (69) were HSIL. The level of agreement between referral cytology and repeat cytology was 57.5%. Histologically confirmed Negative, CIN 1 and CIN 2+ was identified in 7.5% (9), 34.2% (41), and 58.3% (70) respectively. Those with a referral ASC-H followed by repeat HSIL represented 57.5% (69) of the overall population, 75.4% (52) of which had a high grade lesion detected by histology. Women with referral ASC-H and repeat cytology showing negative or minor abnormal cytology represented 42.5% (51) of the population, of whom 65.3% (34) had no high grade lesion detected on concurrent or follow up histology and could be managed more conservatively. Sensitivity and specificity of repeat cytology for the histological diagnosis of CIN 2+ was 74.3% and 67.3% respectively.

**Conclusions:** Repeat cytology has a potential role to offer further risk stratification for ASC-H patients, leading to alternative clinical management options at colposcopy.

### 382 Follow-Up Outcomes in a Large Cohort of Patients with HPV-Negative LSIL Cervical Pap Test Results

*SL Barron, Z Li, C Zhao.* Magee-Womens Hospital of University of Pittsburgh Medical Center, Pittsburgh, PA.

**Background:** New cervical cancer screening guidelines recommend that women aged 30 to 65 years should be screened with cytology and HPV testing (co-testing) every

5 years. Approximately 20-30% of women with LSIL cytology have a negative HPV testing result (LSIL/HPV-). The new ASCCP guidelines recommend repeat co-testing at 1 year (preferred) or colposcopy (accepted) for this category; however, very limited follow-up data are available.

**Design:** A retrospective database search was conducted at a large academic women's hospital to identify women with LSIL on ThinPrep cytology and a concurrent negative HC2 hrHPV test result from June 2005 to June 2013. Patients' age, histologic and cytologic follow-up results were collected from the CoPath archive.

**Results:** Among 588 patients with LSIL/HPV- results, 406 patients had follow-up results within 1 year, including 271 patients with histologic follow-up and 135 patients with cytologic follow-up only. All patients were stratified by age and the follow-up results are detailed in Tables 1 & 2.

Table 1. Age-Stratified (10 year) Follow-Up in Women with hrHPV-Negative LSIL Results

Age	Total Patients	CIN2/3/HSIL (%)	CIN1/LSIL (%)
20-29	53	1 (1.9%)	22 (41.5%)
30-39	135	4 (3.0%)	54 (40.0%)
40-49	105	2 (1.9%)	39 (37.1%)
50-59	87	3 (3.4%)	39 (44.8%)
60-69	22	0 (0)	13 (59.1%)
≥ 70	4	0 (0)	2 (50.0%)
Total	406	10 (2.5%)	169 (42.6%)

Table 2. Summary of Follow-Up Results of 406 Patients with hrHPV-Negative LSIL Results

Follow-Up Method	# Patients	CIN2/3/HSIL (%)	CIN1/LSIL (%)
Histopathology	271	9 (3.3%)	143 (52.7%)
Cytology only	135	1 (0.7%)	26 (19.3%)

Overall, only 2.5% of patients were found to have a high-grade squamous lesion while 41.6% of patients were found to have a low-grade squamous lesion. There is no significant difference among different age groups, although no high-grade lesions were identified in patients with an age of 60 years or older. 321 patients had follow-up HPV testing, including 50 patients (15.6%) with positive results and 271 patients (84.4%) with negative results.

**Conclusions:** This is the first large study investigating the follow-up results in patients with LSIL on liquid-based cytology and concurrent negative HPV testing. Similar to the data from Kaiser-Permanente, our data also indicate that the occurrence rate of high-grade squamous lesions within 1 year in this group of patients is very low, supporting that repeat co-testing at 1 year is appropriate for these women.

### 383 EGFR Mutation and ALK Rearrangement Analysis of Non-Small Cell Carcinoma of Lung: Comparison of Fine Needle Aspiration Biopsy and Surgical Specimens

*CT Bernadt, BT Collins.* Washington University in St. Louis, St. Louis, MO.

**Background:** Fine needle aspiration (FNA) biopsies are increasingly being used for molecular testing; however, there remain some questions about their adequacy for this purpose. There are limited studies comparing FNA biopsies with surgical specimens. In this study, both the adequacy of specimens and frequency of *EGFR* mutations and *ALK* translocations between FNA biopsies and surgical specimens in non-small cell carcinoma (NSCCA) of lung were compared.

**Design:** Pathology reports of FNA biopsies and surgical specimens (biopsies and excisions) of the thorax and regional lymph nodes for which either *EGFR* mutation or *ALK* translocation analysis was performed from a two and a half year were retrospectively reviewed. All cases with a diagnosis of NSCCA of lung (adenocarcinoma, squamous cell carcinoma and NSCCA NOS) were included. FNA biopsies (cell block) and surgical specimens were compared for adequacy of testing (inadequate if reported as "inconclusive" or "could not be performed"), frequency of *EGFR* mutations and frequency of *ALK* translocations. *EGFR* mutation analysis was performed using PCR-based methods with tumor micro-dissection, where necessary. *ALK* translocation analysis was performed for rearrangement at chromosomal locus 2p23 with the Vysis *ALK* Break Apart FISH probe (Abbott Molecular, Inc. Des Plaines, IL). Fisher's exact tests were used to evaluate the association between categorical variables with statistical significance determined to be less than  $p=0.05$ .

**Results:** *EGFR* mutation analysis was performed on 125/133 (94%) of FNA biopsies and 133/184 (72%) of surgical specimens; *ALK* translocation analysis was performed on 112/133 (84%) of FNA biopsies and 149/184 (81%) of surgical specimens. Inadequate results were obtained slightly more often for both *EGFR* and *ALK* testing with FNA biopsies, but this was not statistically significant. ( $p=0.20$  and  $0.08$ , respectively). The frequency of *EGFR* mutations (9.6% in FNA versus 8.3% in surgical) and *ALK* translocations (3.6% in FNA versus 5.4% in surgical) was not statistically significant ( $p=0.83$  and  $0.56$ , respectively).

**Conclusions:** FNA biopsy shows similar adequacy rates for *EGFR* and *ALK* testing in comparison with surgical specimens. FNA biopsy is comparable to surgical specimens for identifying *EGFR* mutations and *ALK* translocations in non-small cell carcinoma of lung.

### 384 Cytomorphologic Correlates with Molecular Analyses in Thyroid Fine Needle Aspirates with Indeterminate Cytology – An Institutional Experience

*SJ Bloechl, K Hannah, K Amin.* University of Minnesota, Minneapolis, MN.

**Background:** Molecular analyses are a recent adjunct to the cytologic evaluation of clinically suspicious thyroid nodules. In this study, we report our initial experience with molecular studies in thyroid fine needle aspirations (FNA) with indeterminate cytology.

**Design:** Thyroid FNAs diagnosed as indeterminate for malignancy: atypia of undetermined significance, suspicious for follicular lesion, and suspicious for malignancy were submitted to an outside facility for evaluation of mutations in BRAF, NRAS, HRAS and KRAS genes by PCR, and RET/PTC1, RET/PTC3 and PAX8/PPAR

rearrangements by RT-PCR. The cases were reviewed retrospectively and divided into weak, moderate or marked atypia based on the cytologic and architectural features. The degree of atypia was then correlated with molecular analyses and histologic specimens. **Results:** 276 thyroid FNAs were performed over an 8 month period. Fifty-seven aspirates (15.1%) had an indeterminate diagnosis and were submitted for molecular studies. Mutations were identified in 13 of 57 specimens (23%). BRAF was the most common mutation (n=9) followed by NRAS (N=2), HRAS (N=1) and KRAS (N=1). No rearrangements were identified. Thirteen specimens were indeterminate for molecular analysis due to low cellularity (N=13; 28%). All BRAF mutations were found to be papillary carcinoma on excision. NRAS, HRAS and KRAS mutations were adenomas or the follicular variant of papillary carcinoma on excision. The overall sensitivity and specificity for molecular studies based on follow-up histologic correlation, available in 17 cases, was 71.4% and 100%, respectively. These results are consistent with previously published studies. The degree of cytologic atypia correlated with positive mutation status and/or malignancy on surgical excision. Nine out of eleven samples in the markedly atypical groups were found to be malignant on excision as opposed to six out of six cases with weak or moderate cytologic atypia that were subsequently diagnosed as adenomas.

**Conclusions:** In patients with indeterminate thyroid cytology, molecular studies aid in the clinical decision making process by streamlining risk stratification. Additionally, cytomorphologic-molecular correlation can help refine cytologic criteria and develop an institutional threshold that could potentially decrease the number of indeterminate thyroid diagnoses.

### 385 Utility of GATA3 and P40 Immunostains in the Diagnosis of Metastatic Urothelial Carcinoma in Cytology Specimens

*TC Brandler, MS Aziz, L Rosen, TA Bhuiya, O Yaskiv.* Hofstra North Shore - LIJ School of Medicine, Lake Success, NY.

**Background:** The transcription factor GATA3 (GATA binding protein 3) is a member of a zinc finger transcription factor family. GATA3 expression in urothelial and mammary carcinomas has been recently reported. However, studies examining GATA3 staining of metastatic urothelial carcinoma (MUC) in cytology specimens are generally lacking. Delta NP63 (p40) has been shown to be highly specific in squamous cell carcinoma (SCC) but is not well studied in urothelial carcinoma (UC). We chose to evaluate the utility of GATA3 and p40 in the diagnosis of MUC in cytology specimens, and in differentiating MUC from SCC. P63 was also evaluated.

**Design:** A search was conducted in our information system for cytology cases of confirmed or suspected MUC in non-genitourinary organs between 1/1/05-6/16/13, which generated 48 potential cases. 34 cases had cell blocks which were retrieved and stained for GATA3, p40 and p63. 22 UC bladder surgical specimens and 25 SCC surgical specimens were selected as controls. Nuclear staining intensity (weak, moderate or strong) and percentage of positive cells were recorded. The chi-square test or Fisher's Exact test, as appropriate, was used to assess the association between positive staining and specimen diagnostic category.

**Results:** MUC cytology cases stained positive for GATA3, P40 and P63 in 78.13%, 80.65%, and 61.29% of cases respectively, with moderate/strong staining intensity in 96%, 100% and 84.21% respectively. MUC cases had a significantly higher percentage of GATA3 positivity as compared to SCC controls (9.09%, in rare cells with weak staining.) (chi-square,  $P < 0.001$ ), but GATA3 positivity was not significantly different from UC controls (90.91%) ( $P = 0.28$ ). For p40 positivity, there was no significant difference between MUC cases, UC controls (95.45%), and SCC controls (90.91%) ( $P = 0.29$ ). P63 positivity was significantly lower in MUC cases than UC controls (95.45%) ( $P < 0.01$ ) and SCC controls (95.45%) ( $P < 0.01$ ).

**Conclusions:** Our study shows that GATA3 can be very useful in confirming the diagnosis of MUC in cytology specimens and in distinguishing between MUC and SCC. P40 demonstrated moderate/strong staining in 81% of MUC specimens indicating that this marker can be a very valuable adjunct to GATA3 in the diagnosis of MUC in cytology specimens, especially when SCC is not part of the clinical differential diagnosis.

### 386 Does GATA-3 Immunohistochemistry (IHC) for Metastatic Breast Carcinoma Correlate with Prognostic Markers in Cytology Specimens?

*DR Braxton, C Cohen, MT Siddiqui.* Emory University School of Medicine, Atlanta, GA.

**Background:** GATA binding protein 3 (GATA-3) is a transcription factor that is highly expressed in breast epithelium. The utility of GATA-3 as a diagnostic marker of metastatic breast carcinoma in cytology specimens has not been assessed. The purpose of this study is to assess GATA-3 IHC in the diagnosis of metastatic breast carcinoma in cytology specimens and to correlate GATA-3 IHC characteristics to prognostic markers in breast carcinoma.

**Design:** Metastatic breast carcinoma cases were retrospectively assessed for GATA-3 IHC (clone L50-823) on cell block preparations. GATA-3 staining was scored qualitatively (positive vs. negative), by intensity (0 – negative; 1 – weak positive; 2 – moderate positive; 3 – strong positive), and by staining area (0-100%). Results were correlated with specimen type (Fine Needle Aspiration [FNA] vs. body fluid), and breast prognostic markers Estrogen Receptor (ER), Progesterone Receptor (PR), Her-2/Neu (H2N), and Ki67 performed by routine clinical IHC. The cases were categorized by the profile of these markers (see table). Statistical significance was determined by chi-squared or ANOVA. Alpha was set as 0.05.

**Results:** A total of 40 cytology cell block specimens containing metastatic breast carcinoma were studied. Of these, 28(70%) were FNA, and 12 (30%) were body fluid specimens. GATA-3 was positive in 32 (80%) cases. All ER positive cases (n=25) were positive for GATA-3. Conversely, all GATA-3 negative cases (n=8) were triple negative breast cancers. On univariate analysis, GATA-3 was associated with ER ( $p = 0.0001$ ), and PR ( $p = 0.0468$ ). GATA-3 intensity was associated with ER ( $p < 0.0001$ ), PR ( $p = 0.0157$ ),

H2N ( $p = 0.0256$ ), and cancer category ( $p < 0.0001$ ). GATA-3 staining area was associated with ER ( $p < 0.0001$ ), PR ( $p = 0.0160$ ), H2N ( $p = 0.0451$ ), and cancer category ( $p = 0.0002$ ). There was no significant difference for GATA-3 positivity, intensity, and staining area across specimen types.

Covariate	GATA-3 Qualitative Scoring		
	Negative N=8	Positive N=32	P-value <sup>1</sup>
<b>Specimen Type</b>			0.2272
Body Fluid	1	11	
FNA	7	21	
<b>ER</b>			<b>0.0001</b>
Negative	8	7	
Positive	0	25	
<b>PR</b>			<b>0.0384</b>
Negative	8	20	
Positive	0	12	
<b>Her-2/Neu</b>			0.2320
Negative	8	27	
Positive	0	5	
<b>Ki67</b>			0.9834
High	3	11	
Intermediate	2	8	
Low	3	13	
<b>Category</b>			<b>0.0008</b>
ER+/H2N +	0	1	
Hormone Receptor positive	0	20	
Triple Negative	8	7	
Triple Positive	0	4	

<sup>1</sup>p-value was determined by pearson's Chi-square test.  
Bold case = statistically significant

**Conclusions:** GATA-3 is a useful diagnostic marker of metastatic breast carcinoma in cytology cell block specimens. GATA-3 staining intensity and area is correlated with ER positive, PR positive, and H2N positive breast carcinomas. GATA-3 is not a sensitive marker for metastatic triple negative breast carcinomas.

### 387 Investigation of High and Low Risk HPV Existence in Oral Cavity in Association with Cervical Dysplasia

*G Burkadze, N Shonia, I Meparishvili, K Gogilashvili.* N. Kipshidze Central University Clinic, Tbilisi, Georgia; Iliia State University, Tbilisi, Georgia.

**Background:** HPV virus is known to be the initiator of neoplastic processes in cervix and because of histological and behavioral similarities of cervical and oral epithelium we consider the question of the possible existence of low and high risk HPV virus in oral cavity in women with cervical dysplasia.

**Design:** For a cohort study 49 women with cervical pathology (ASCUS, CIN1, CIN2, CIN3) were selected from our database. An informed consent was obtained from all women participating in the study. The smears from the oral cavity were taken using the cytobrush and colored using PAP method. After estimation of sample adequacy HPV detection was performed using CISH (chromogenic in situ hybridization) method. For detection of HPV, HPV type 6/11 and HPV type 16/18/31/35/45/51/82 probes and visualization system Zyto Fast PLUS CISH Implementation Kit AP-NBT/BCIP were used.

**Results:** According to the study in women with cervical lesions 7 case of ASCUS (14.3%), 21 case of CIN1 (42.9%), 15 case of CIN 2 (30.6%), 6 case of CIN3 (12.3%) were detected. Detection of high risk HPV in oral samples show that in ASCUS diagnostic cases high risk HPV was positive in 3 samples (42.8%), in CIN 1 cases - in 16 samples (76%), in CIN2 cases - 13 samples (87%) were positive and in CIN 3 cases - 5 samples (83%) were positive for high risk HPV. There were no cases with positive low risk HPV in oral epithelium. Numbers of HPV positive cases were different in different age groups - in older age, number of high risk HPV positive cases decreases 5 times. Cytological analysis of samples taken from oral cavity show that 10 cases (20.4%) were evaluated as inadequate, 14 cases (28.6%) were normal, and 25 cases (52%) ASCUS. Results of detection of high risk HPV positive cases in samples taken from oral cavity show this kind of distribution: inadequate cytological diagnosis - 40% were positive; normal cytology - 64% were positive; ASCUS high risk HPV was positive in 96%.

**Conclusions:** In women with cervical squamous intraepithelial lesion, samples from oral cavity show high risk HPV expression often depending on cervical epithelial lesion type. In particular, the higher the level of damage in cervix (from ASCUS to CIN 3) the more the high risk HPV expression is, that can be the result of high risk HPV persistence. Consequently, in case of squamous epithelial lesion of cervix monitoring of high risk HPV presence in samples from oral cavity is highly recommended, but HPV detection using only cytological evaluation is not reliable.

### 388 Direct Cytologic Smears Are an Accurate and Reliable Substrate for Fluorescence In Situ Hybridization Testing in Synovial Sarcoma

*SM Calkins, R Balassanian, J Hou, AB Berry.* University of California, San Francisco, San Francisco, CA.

**Background:** Synovial sarcoma (SS) is a malignant mesenchymal tumor that commonly exhibits chromosomal rearrangements involving the SS18 gene located in the breakpoint region of chromosome 18q11.2. Several studies have indicated that the t(X;18)(p11.2;q11.2) translocation, resulting in fusion of SYT and SXX1 or SXX2, arises exclusively in SS. SS18 gene break-apart probes are a reliable diagnostic tool to identify SYT disruption in SS. Fine needle aspiration biopsy (FNAB) cell block material can be evaluated by traditional fluorescence in situ hybridization (FISH) methods for SS18 translocations, but is often insufficient for this type of analysis,

requiring surgical excision/biopsy procedures. We have designed an alternative FISH protocol for use in direct smears in these instances. In this study we attempt to validate this protocol for clinical use.

**Design:** Archival Pap stained smears from FNAB cases of SS were identified from our case files, along with a similar number of other spindle cell lesions (to serve as negative controls). The lesional cells were identified and marked, the slides were de-coverslipped and de-stained, and dual-color break-apart FISH testing for SS18 translocation was performed using our modified protocol. For each slide, 25 cells were scored by at least two observers.

**Results:** 19 FNAB smears were submitted for FISH testing. 17 of the 19 cases exhibited signals that were strong and clear enough to score, and all yielded definitive results. Of the 9 presumably positive cases scored, 8 were positive. Of the 8 presumably negative cases scored, all 8 were negative. Using the final excision diagnosis as the gold standard, in this limited number of cases, the sensitivity was 88% and specificity was 100%. The only discordant case was a high grade sarcoma originally called positive by traditional cytogenetic karyotyping (not FISH), and the report noted that the t(X;18) cells were a small population in a sample dominated by aneuploidy and many other abnormalities. The sample we evaluated was from a recurrence more than a year later and most likely represented further dedifferentiation of this tumor.

**Conclusions:** Dual-color breakapart FISH testing for SS18, performed on previously Pap-stained direct cytologic FNAB smears is technically feasible, accurate, and reliable for the diagnosis of synovial sarcoma. Use of this technique could improve the accuracy of pre-treatment diagnosis and could aid in avoiding unnecessary additional surgical procedures.

### 389 Endoscopic Ultrasound-Guided Fine Needle Aspiration with Cytopathologist Guidance and Rapid On-Site Evaluation Is Highly Accurate for Diagnosis of Pancreatic Masses

RL Cantley, W Li, U Ahmad, E Rafiq, S Molnar, LE De Las Casas. University of Toledo Medical Center, Toledo, OH.

**Background:** Endoscopic ultrasound-guided fine needle aspiration (EUS-FNA) is increasingly utilized in the diagnosis of pancreatic masses. Accurate diagnosis is critical, as this cytologic material is often the only specimen used to determine management. Rapid on-site evaluation (ROSE) of EUS-FNA material coupled with cytopathologist guidance (CG) to the endoscopist allows for adjustments in technique and acquisition of additional passes when needed, potentially improving sensitivity and accuracy. A recent study of pancreatic EUS-FNA without ROSE found false negativity due to sampling error in 23% of cases when matched to subsequent surgical resections. The goal of this study is to evaluate the sensitivity and accuracy of EUS-FNA with ROSE and CG in the diagnosis of pancreatic masses.

**Design:** We searched our anatomic pathology archives for all cases of EUS-FNA performed on pancreatic lesions for 25 months (1/1/2011-1/31/2013). Patient age and sex, location and nature of lesion (solid or cystic), ROSE result, and final diagnosis were recorded, as well as any follow-up surgical or autopsy diagnosis, which was considered the gold standard. Cases called "atypical" on EUS-FNA were considered negative for sensitivity/accuracy calculations.

**Results:** 203 EUS-FNA cases were identified: 127 positive for malignancy/neoplasm (80 adenocarcinoma, 37 mucinous neoplasm, 7 endocrine neoplasm, 1 solid pseudopapillary tumor), 7 "atypical cells present," 70 negative for neoplasm/benign and 1 unsatisfactory. No "suspicious" cases were found. ROSE was performed by an on-site cytopathologist in all cases. 30 cases had matched surgical or autopsy follow-up. In 57% (17/30), ROSE resulted in additional passes at the time of EUS-FNA. The surgical/autopsy findings included 19 adenocarcinoma, 3 pancreatic endocrine neoplasm, 1 solid pseudopapillary tumor, 1 intraductal papillary mucinous neoplasm, 1 mucinous cystic neoplasm, and 5 negative for neoplasm. The overall sensitivity of EUS-FNA for pancreatic malignancy/neoplasm was 96% (24/25) (solid lesions 95% [18/19], cystic lesions 100% [6/6]). The false negative case was an adenocarcinoma called "atypical" on EUS-FNA. The 5 cases called "negative/benign" on EUS-FNA were confirmed by surgery. Overall accuracy was 97% (29/30).

**Conclusions:** EUS-FNA with ROSE and CG is highly accurate and sensitive for diagnosing pancreatic masses. ROSE/CG frequently results in acquisition of additional material, likely improving sensitivity.

### 390 Comparative Study of ProEx C and Urovysion™ FISH Assays on Urine Samples

S Chang, E Smith, M Levin, NA Moatamed. David Geffen School of Medicine at UCLA, Los Angeles, CA.

**Background:** Detection of urothelial cell carcinoma (UCC) by urine cytology can be challenging. Adjunctive tests such as FISH (Urovysion™) have been utilized to increase the sensitivity of detecting UCC. Recently, we introduced ProEx C as an additional molecular marker to improve the detection of UCC. ProEx C is an antibody cocktail targeting expression of topoisomerase II- $\alpha$  and minichromosome maintenance protein-2, and originally was developed to assess squamous dysplasia in gynecologic specimens. The two proteins are overexpressed in the cell nucleus during aberrant S-phase induction in neoplastic cells. The current study compares assay performance of ProEx C and Urovysion™ on urine samples.

**Design:** Among 127 ThinPrep slides that were previously stained with ProEx C, 27 cases had concurrent Urovysion™ assay analysis and surgical follow up biopsy within one year of cytologic examination. ProEx C was recorded as positive when nuclear staining was seen in morphologically atypical urothelial cells. FDA criteria were used for assessing Urovysion™ (polyploidy of chromosomes 3, 7, 17 in four or more cells or homozygous deletion of P16 on chromosome 9 in at least 12 cells). The surgical

pathology follow-up was 7 benign, 3 low grade UCC, and 17 high grade UCC. The surgical pathology diagnoses were used as gold standard for comparative evaluation of the two assays.

**Results:** The overall results and the assay performances are summarized in Table 1. The sensitivity for the two assays was 88.9% for ProEx C and 50% for Urovysion™, while the specificity for ProEx C was 77.8% and 44.4% for Urovysion™. Positive predictive values (PPV) were 88.9% and 64.3% for ProEx C and Urovysion™ respectively. Negative predictive values (NPV) were 77.8% and 30.8% for ProEx C and Urovysion™. Using McNemar Fisher exact Chi-square analysis in a 2x2 table, a P-value of 0.016 was obtained when the ProEx C stain was compared to the Urovysion™ assay.

Test Performance of ProEx C & Urovysion Assays™

	ProEx C	Urovysion
True Positive	16	9
True Negative	7	4
False Positive	2	5
False Negative	2	9
Sensitivity	88.9%	50.0%
Specificity	77.8%	44.4%
PPV	88.9%	64.3%
NPV	77.8%	30.8%

2 Tail Paired T-test P-Value: 0.0016

**Conclusions:** Based on this study as outlined in Table 1, ProEx C is a better ancillary test and would serve well as a second adjunct marker for the analysis of urothelial specimens.

### 391 Cytomorphologic Features That Distinguish Schwannoma from Other Low-Grade Spindle Cell Lesions

I Chebib, GP Nielsen, V Deshpande. Massachusetts General Hospital and Harvard Medical School, Boston, MA.

**Background:** Low-grade spindle cell neoplasms are difficult to interpret on fine needle aspiration biopsy (FNAB). Although ancillary studies are important in soft tissue neoplasms, we sought to identify cytomorphologic features that distinguish schwannoma from other low-grade spindle cell lesions.

**Design:** 135 FNAB of low-grade spindle cell lesions with surgical pathology follow-up were collected (50 schwannomas, 17 fibromatosis, 16 gastrointestinal stromal tumor, 7 solitary fibrous tumor, 7 thymoma, 6 leiomyosarcoma, 6 neurofibroma, 4 low-grade fibromyxoid sarcoma, 4 scar, 3 synovial sarcoma, 2 leiomyoma, 3 nodular fasciitis, 1 each of extraskeletal myxoid chondrosarcoma, fibroma of tendon sheath, dermatofibroma, dermatofibrosarcoma protuberans, myofibroma, myoepithelioma, pleomorphic hyalinising angiectatic tumor, angiomylipoma, spindle neuroendocrine tumor, and organized hematoma). Those with high-grade atypia, biphasic lesions and those with prominent myxoid background were excluded. Each case was semi-quantitatively graded for cellularity, number of cohesive clusters, cluster size, architecture (non-fascicular, fascicular, palisading, Verocay bodies), presence of single cells, naked nuclei, bipolar/fibre cells, stromal features (fibrillary, fibrous), nuclear morphology (round/oval, wavy, pointed tips, fish hook, intranuclear inclusions, nucleoli, anisonucleosis, hyperchromasia, diffuse atypia). Statistical comparison was performed with  $\chi^2$  ( $p \leq 0.05$  statistically significant).

**Results:** There were 50 schwannomas and 85 other low-grade spindle cell lesions. Comparing schwannoma to other low-grade spindle cell lesions, features that were significantly different between the two groups included: high number of cell clusters ( $p=0.009$ ), rare or no single cells ( $p=0.003$ ), prominent fibrillary stroma ( $p=0.004$ ), nuclei with tapered/pointed tips ( $p=0.01$ ), intranuclear cytoplasmic inclusions ( $p=0.01$ ), some to significant anisonucleosis ( $p=0.002$ ), and lack of hyperchromasia ( $p=0.01$ ). When 5 criteria are present (high number of clusters, few to no single cells, fibrillary stroma, nuclei with pointed tips, anisonucleosis), schwannoma can be distinguished from other low-grade spindle cell neoplasms with a specificity of 98% (sensitivity 32%, positive predictive value 89%, negative predictive value 71%).

**Conclusions:** Presence of cohesive cell clusters with fibrillary stroma, tapered nuclei, anisonucleosis and rare/no single cell population distinguish schwannoma from other low-grade mimickers with high specificity.

### 392 Reliability of Immunocytochemical Staining of SOX10, MITF and Pan-Melanoma Cocktail in Confirming Melanoma on Fine-Needle Aspiration Smears

J Clevenger, C Joseph, M Dawlett, Y Gong. MD Anderson Cancer Center, Houston, TX.

**Background:** Accurate fine-needle aspiration (FNA) diagnosis of metastatic melanoma is of therapeutic and prognostic significance. Pan-melanoma cocktail immunostaining is traditionally used to confirm a diagnosis of melanoma, but it has suboptimal sensitivity. SOX10 and MITF are two newly emerged melanoma markers that are highly accurate in diagnosing melanoma on histologic sections. However, their utility and accuracy in cytologic samples have never been studied.

**Design:** We retrospectively searched our pathology database between February 2009 and May 2012 for FNA cases that had a definitive diagnosis of melanoma and had spare Papanicolaou-stained slides (direct smears) with high cellularity. Fifty such cases were identified. Each case was immunostained with SOX10, MITF, or pan-melanoma cocktail. Staining intensity and percentage of positive cells were recorded.

**Results:** Twenty-one cases exhibited spindle cell morphology with or without an epithelioid component (group 1), and 29 cases had pure epithelioid morphology (group 2). SOX10 was positive in all the 50 (100%), MITF in 45 (90%), and pan-melanoma in 43 (86%) cases. SOX10 and MITF displayed nuclear staining and tended to be strong and diffuse with little or no background staining, whereas pan-melanoma displayed cytoplasmic staining with relatively high background staining. For SOX10 and pan-melanoma, the detection rate was identical between group 1 and group 2, but for MITF, the detection rate was higher in group 2 than in group 1 (Table 1).

**Conclusions:** In FNA smears of melanoma, SOX10 had the highest detection rate, followed by MITF and then pan-melanoma. In addition, SOX10 and MITF were superior to pan-melanoma owing to their relatively strong and diffuse nuclear staining with minimal background staining. SOX10 and pan-melanoma performed equally well for both epithelioid and spindle cell melanomas, but MITF had a relatively better detection rate for epithelioid melanomas.

Melanoma Type and Marker	No. (%) of Positive Cases	No. (%) of Positive Cells	No. (%) of Positive Cells	No. (%) of Cases with Staining Intensity Score	0	1+	2+	3+
Spindle cell, with or without epithelioid component (n = 21)		1-50%	51-100%	0		1+	2+	3+
Pan-melanoma	18 (86%)	4 (22%)	14 (78%)	3 (14%)	6 (29%)	3 (14%)	9 (43%)	
SOX10	21 (100%)	1 (5%)	20 (95%)	0	1 (5%)	2 (10%)	18 (86%)	
MITF	18 (86%)	1 (6%)	17 (94%)	3 (14%)	0	2 (10%)	16 (76%)	
Epithelioid (n = 29)								
Pan-melanoma	25 (86%)	2 (8%)	23 (92%)	4 (14%)	2 (7%)	4 (14%)	19 (66%)	
SOX10	29 (100%)	2 (7%)	27 (93%)	0	1 (3%)	2 (7%)	26 (90%)	
MITF	27 (93%)	3 (11%)	24 (89%)	2 (7%)	3 (10%)	6 (21%)	18 (62%)	

### 393 Predictive Value of Intra-Abdominal Lymph Nodes in Pancreatic Endoscopic Ultrasound Guided Fine Needle Aspiration Biopsy

*BT Collins, CT Bernad, JP Wang, LJ Adhikari.* Washington University in St. Louis, Saint Louis, MO.

**Background:** Endoscopic ultrasound guided (EUS) fine needle aspiration (FNA) biopsy is a commonly utilized method for the evaluation of pancreatic lesions. During the course of EUS evaluation, intra-abdominal lymph nodes (LN) can be visualized, and based on their endoscopic appearance selected for FNA biopsy. While varying EUS visual features raise suspicion for LN metastasis, FNA biopsy is necessary for definitive diagnosis. EUS FNA of the LNs can provide critical diagnostic information important for clinical management and tumor staging. The purpose of the study was to determine the predictive value of intra-abdominal LN EUS FNA biopsy associated with pancreatic lesions.

**Design:** Over a consecutive ten year period (2001-2010), the pathology database was searched for patients with pancreas and intra-abdominal LN EUS FNA biopsy. When present, corresponding or subsequent pertinent surgical pathology reports were collected. Pathology reports were reviewed, and clinical information and diagnostic results were recorded. Where appropriate, the subsequent clinical course and follow up was ascertained.

**Results:** There were 252 cases where a pancreas lesion and intra-abdominal LN were sampled together. Of this group, 182 LNs were classified as negative (72%), 47 positive (19%) and 23 atypical (9%). Within the negative LN cohort (182 cases), the pancreas lesion FNA correlated with the following diagnostic categories; 84 cases benign (47%), 55 cases malignant (30%), and 43 cases atypical/suspicious (23%). Within the positive LN cohort (47 cases), the pancreas lesion EUS FNA correlated with the following diagnostic categories; 42 cases malignant (89%), 2 cases atypical (4%), and 3 cases suspicious (6%). Including surgical follow up and clinical outcome, a positive LN EUS FNA biopsy had a 98% positive predictive value (PPV) for malignancy. Within the atypical LN cohort (23 cases), the pancreas lesion EUS FNA correlated with the following diagnostic categories; 13 cases malignant (57%), 6 cases atypical/suspicious (26%), and 4 benign (17%). Including surgical follow up and clinical outcome, an atypical LN EUS FNA biopsy had a 78% PPV for malignancy.

**Conclusions:** An atypical lymph node diagnostic category is strongly associated with a malignant pancreas diagnosis. A positive LN EUS FNA biopsy has a 98% positive predictive value for pancreatic malignancy and can be used as evidence of malignancy in cases where the pancreas does not have a definitive categorization.

### 394 WT-1/Cytokeratin Dual Color Immunostaining Reveals Distinctive Staining Patterns in Metastatic Melanoma, Metastatic Carcinoma, and Reactive Mesothelial Cells in Pleural Fluid: Implication as an Effective First Line Test for Workup of Malignant Effusions

*JR Conner, ES Cibas, X Qian.* Brigham and Women's Hospital and Harvard Medical School, Boston, MA.

**Background:** Workup of a malignant effusion from an unknown primary site or in patients with multiple malignancies usually requires immunostaining with a panel of markers. Recent studies have demonstrated that Wilms' tumor-1 (WT-1) is expressed in the cytoplasm of tumor cells in a spectrum of melanocytic lesions on histology. WT-1 expression is known to be predominantly nuclear in mesothelial cells and absent in most epithelial tumors. We evaluated the utility of a WT-1/AE1-AE3 dual color immunostain to distinguish metastatic melanoma from metastatic carcinoma and reactive mesothelial cells in pleural fluids.

**Design:** Forty-four pleural effusions, including 11 melanomas, 11 breast carcinomas, 10 non-small cell lung carcinomas, and 12 negative specimens, were immunostained using a peroxidase-based brown chromogen for WT-1 and an alkaline phosphatase-based red chromogen for AE1/AE3 on cell block sections. Malignant cells were identified by H&E and evaluation of confirmatory immunostains. Staining for a given immunohistochemical pattern was considered positive when observed in relevant cells within each population.

**Results:** Cytoplasmic reactivity for WT-1 (brown) without nuclear staining was observed in 11 of 11 (100%) melanomas. A perinuclear, dot-like pattern was seen in all cases with 7 (64%) also showing diffuse cytoplasmic staining in some cells. AE1/AE3 (red)

reactivity was absent in melanoma tumor cells. Carcinomas exhibited cytoplasmic staining for AE1/AE3 and were negative for WT-1 in tumor cells in 21 of 21 (100%) cases. Reactive mesothelial cells in negative pleural fluids and malignant effusions displayed a pattern of nuclear WT-1 and cytoplasmic AE1/AE3 reactivities. Cytoplasmic WT-1 staining was absent in all metastatic carcinoma cases and negative samples.

**Conclusions:** Melanomas exhibit a distinct pattern of cytoplasmic immunoreactivity for WT-1 in pleural fluid specimens, which, in combination with the absence of keratin expression, can distinguish melanoma, carcinoma, and reactive mesothelial cells using a single immunohistochemical stain with two markers conjugated with two different chromogens. This may be especially useful in evaluating malignant effusions from patients with an unknown primary, or in those with a history of both melanoma and carcinoma, as a cost effective and efficient means of directing further workup.

### 395 HNF1 $\beta$ and S100 $\alpha$ 1 Are Useful Biomarkers for Distinguishing Renal Oncocytoma and Chromophobe Renal Cell Carcinoma in FNA and Core Needle Biopsies

*JR Conner, MS Hirsch, VY Jo.* Brigham and Women's Hospital and Harvard Medical School, Boston, MA.

**Background:** Morphologic overlap between renal oncocytoma (RO) and chromophobe renal cell carcinoma (ChRCC) can pose diagnostic challenges. This may be especially true in fine needle aspiration (FNA) or small core biopsy specimens when the quantity of lesional material may be limited, architectural features are not well represented, and gross examination is not possible. Hepatocyte nuclear factor one alpha and beta (HNF1 $\alpha$  and HNF1 $\beta$ ) and S100 $\alpha$ 1 have been shown to be differentially expressed in RO and ChRCC in resection specimens by immunohistochemistry (IHC). We evaluated the utility of these markers in FNA and core biopsy samples of RO and ChRCC.

**Design:** Paraffin sections from 62 RO (36 FNA cell block specimens and 26 core biopsies, 21 of which were concurrent) and 14 ChRCC (10 FNA cell block specimens and 4 core biopsies, 1 of which was concurrent) were immunostained using antibodies against HNF1 $\alpha$ , HNF1 $\beta$ , and S100 $\alpha$ 1. IHC was scored semi-quantitatively as follows: 0-3 for negative, weak, moderate, and strong reactivity, respectively, and 0-4 for extent of positive tumor cells (0%, 1-25%, 26-50%, 51-75%, and 76-100%, respectively).

**Results:** Normal renal tubular cells were positive for S100 $\alpha$ 1, HNF1 $\alpha$  (weak), and HNF1 $\beta$ . Forty-four (71%) RO displayed moderate to strong nuclear reactivity for HNF1 $\beta$  compared to 3 (21%) ChRCC ( $\chi^2=7.84$ ,  $p=0.005$ ), with mean intensity scores of 1.9 and 0.9 respectively ( $p=0.001$ ). Moderate or strong staining was present in greater than 50% of tumor cells in 33 (53%) RO and 2 (14%) ChRCC ( $\chi^2=7.25$ ,  $p=0.007$ ). S100 $\alpha$ 1 was moderately or strongly positive in 45 (73%) RO and 1 (14%) ChRCC ( $\chi^2=8.08$ ,  $p=0.004$ ), with 36 (58%) and 0 cases respectively showing positive staining in greater than 50% of tumor cells ( $\chi^2=15.45$ ,  $p<0.0001$ ). No cases of ChRCC were positive for both markers. There was no statistically significant difference in intensity or extent of HNF1 $\alpha$  staining between RO and ChRCC.

**Conclusions:** Moderate to strong immunoreactivity for HNF1 $\beta$  and S100 $\alpha$ 1 was present in a significantly greater proportion of RO than ChRCC in small biopsy specimens. Using IHC with both of these markers may be useful, in combination with morphologic features and other studies, even with limited material from minimally invasive sampling procedures. Immunoreactive normal renal tubules should not be misinterpreted as positive tumor cells. Accurate diagnosis of RO and ChRCC in these specimens is of increasing clinical importance as tumor-ablative procedures and active surveillance become more widely adopted.

### 396 Comparison of Cytopathologist-Performed, Ultrasound-Guided Fine Needle Aspiration with Cytopathologist-Performed, Palpation-Guided Fine Needle Aspiration: A Single Institutional Experience

*R Conrad, M Bhasin, S Chang, DY Lu.* UCLA, Los Angeles, CA.

**Background:** The use of ultrasound by the pathologist during fine needle aspiration (FNA) is a relatively new practice that is starting to gain more widespread acceptance within pathology institutions. To date, there have only been few published studies discussing the utility of pathologist-performed, ultrasound-guided FNAs. We report our institutional experience with cytopathologist-performed, ultrasound-guided FNAs and compare the findings with those from our cytopathologist-performed, palpation-guided FNAs.

**Design:** A retrospective study examining all cytopathologist-performed FNAs conducted from January 2010 to August 2013 at the University of California, Los Angeles (UCLA) Medical Center. The UCLA Pathology Department computer database was searched for all such cases for that time period. FNAs performed by non-pathologists were excluded from the study. Data collected included: FNA type (palpation- or ultrasound-guided), adequacy (non-diagnostic or diagnostic), location of lesion, and patient demographics. The pathology results from corresponding follow-up surgical biopsies/excisions were also searched and, if available, used as the "gold standard" to determine sensitivity, specificity, positive predictive value (PPV), negative predictive value (NPV), and diagnostic accuracy. These parameters for ultrasound-guided FNAs were compared to those for palpation-guided FNAs.

**Results:** 780 FNA cases were performed (361 male, 419 female; average age 51 years). The lesions assessed by FNA were located in the neck 41%, soft tissue 15%, breast 13%, salivary 11%, thyroid 9%, face 5%, groin 3%, and axilla 3%. The cytology results in lesions aspirated by palpation (n=553) versus ultrasound-guidance (n=227) were as follows: malignant 28% vs 32%, atypical 7% vs 6%, benign 54% vs 58%, and nondiagnostic 11% vs 4%. Corresponding surgical specimens were available for 231 cases. In the palpation-guided group (161 cases), the sensitivity of FNA was 96%, specificity 87%, PPV 92%, NPV 93%, and diagnostic accuracy 92%. In the ultrasound-guided group (70 cases), the sensitivity was 100%, specificity 93%, PPV 96%, NPV 100%, and diagnostic accuracy 97%.

**Conclusions:** Ultrasound use significantly decreases the non-diagnostic rate compared to palpation-guided FNAs ( $p=0.009$ ) and is slightly more accurate ( $p=0.24$ ). There was also a trend towards increased sensitivity, specificity, PPV, and NPV with ultrasound guidance, though this was not statistically significant. Larger population sample size may result in this being statistically significant.

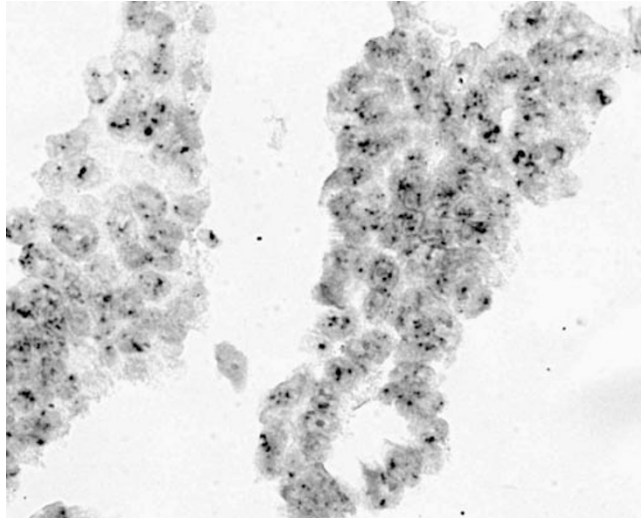
### 397 HSATII as a Biomarker of Papillary Thyroid Carcinoma

A Deshpande, JNM Tan, K Arora, V Deshpande, D Ting, A De Las Morenas. MGH, Boston, MA; Boston Medical Center, Boston, MA.

**Background:** HSATII is a repetitive non-coding RNA (ncRNA) that is primarily concentrated in pericentromeric regions of the genome. Recent work with single molecule sequencing had identified aberrant expression of HSATII transcripts in a variety of epithelial malignancies of pancreas, lung, kidney, ovary and colon origin, but not in normal human control tissues. HSATII ncRNA expression was on the order of 20-50 fold higher than the housekeeping gene GAPDH in tumor tissues. This has implications as a novel cancer biomarker and in particular may have utility in clinical situations where diagnosis is challenging. To this end, we have developed an HSATII RNA in-situ hybridization (ISH) assay applicable to standard formalin fixed paraffin embedded tissue specimens demonstrating high sensitivity and specificity in solid tumors. In this study we evaluate the potential of HSATII ISH as a biomarker for papillary thyroid carcinoma.

**Design:** HSATII specific probes were developed and validated for routine paraffin embedded tissue processing. Two tissue arrays were identified, one composed of benign thyroid nodules and a 2nd of papillary thyroid carcinomas. Additionally, 20 cellblocks samples from fine needle aspiration biopsy cases, 10 of them with histologically proven papillary thyroid carcinoma and the remaining 10 with benign nodules were also identified. The stained slides were evaluated at a brightfield microscope. Nuclear positivity was distinguished from cytoplasmic signal.

**Results:** 54 of the 66 papillary thyroid carcinomas on the tissue microarray showed cytoplasmic reactivity for HSATII, while only 2 of the 79 benign nodules showed cytoplasmic reactivity yielding a sensitivity of 82% and a specificity of 98%. Within the fine needle aspiration biopsy cohort 7 of the 10 papillary thyroid carcinomas showed cytoplasmic reactivity.



In comparison, none of the 10 benign thyroid nodules showed cytoplasmic reactivity, yielding a sensitivity of 70% and specificity of 100%. Nuclear reactivity was identified in 9 of 10 benign lesions and 5 of the 10 malignant lesions.

**Conclusions:** The detection of cytoplasmic HSATII transcript using a in situ hybridization platform shows promise in distinguishing papillary thyroid carcinoma from benign thyroid nodules.

### 398 Molecular Testing for EGFR Mutations and ALK Rearrangements in Cytology Specimens of Lung Carcinoma – A Review of Experience in Our Institution

R Dietz, R Madan, M O'Neil, O Tawfik, F Fan. University of Kansas Medical Center, Kansas City, KS.

**Background:** Recently developed targeted inhibitors against epidermal growth factor receptor (EGFR) and anaplastic lymphoma kinase (ALK) prolong survival of patients with advanced stage adenocarcinoma that harbor EGFR mutations or ALK translocations. We revised our protocol to improve the yield of material for EGFR and ALK testing in cytology specimens. Here we report our data in diagnosing lung carcinoma in cytology and summarize our experience in sending cytology specimens for EGFR and ALK molecular testing.

**Design:** We performed a retrospective chart review to identify all patients diagnosed with lung carcinoma at our institution between January 2011 and August 2013. Patients were then further selected by a diagnosis of adenocarcinoma. For all adenocarcinoma cases, the tissue type and diagnostic methods were summarized. We then identified cases on which oncologists requested EGFR and ALK testing and reviewed those for specimen type, adequacy of tissue for testing, mutation rates and clinical follow-up.

**Results:** Out of a total 208 lung carcinomas, there were 111 adenocarcinomas (53%), 24 squamous cell carcinomas (12%), 61 non-small cell carcinomas NOS (29%) and 12

small cell carcinomas (6%). Of the 111 adenocarcinomas, 51 (46%) were lung FNAs, 35 (32%) were lymph node FNAs, 17 (15%) were fluids and 8 (7%) were FNAs of other organs. The diagnosis was confirmed by immunohistochemistry (IHC) in 58 cases (52%), concurrent core biopsy in 36 cases (32%) and morphology alone in 17 cases (15%). For 75 cases, only cytology specimens were available for testing. EGFR and ALK analysis was requested on 30 of them (21 FNAs and 9 pleural fluids) and was not clinically indicated in the remaining cases. 25 cases had sufficient material for EGFR testing with 7 harboring a mutation. 21 cases had sufficient material for ALK testing with 1 harboring the translocation. 5 of the 7 EGFR mutation positive patients and the 1 ALK positive patient received corresponding targeted therapy.

**Conclusions:** Adenocarcinomas were the most frequently diagnosed lung carcinomas in cytology specimens. We confirmed the majority of these diagnoses by IHC. Most cytology specimens contained sufficient material for EGFR/ALK testing. However less than half of our cytology cases was requested for testing indicating reflex testing being unnecessary. It remains an oncologist-driven test and requires effective communication and a team-type approach to achieve timely and successful molecular testing in limited cytology samples.

### 399 There Is No Significant Difference in Diagnostic Accuracy of Cytopathologist- and Interventional Radiologist-Performed Ultrasound-Guided Fine Needle Aspiration of Head and Neck Lesions: An Analysis of Outcomes by Two Practices at One Institution

PJ DiMaggio, D Molina, J Orfanidis, DI Kutler, RS Hoda. New York Presbyterian Hospital, Weill Cornell Medical College, New York, NY.

**Background:** Ultrasound-guided fine needle aspiration (US-FNA) improves the diagnostic yield of suspicious nodules. It is usually performed by an interventional radiologist (IR) and only rarely by a cytopathologist (CP). The diagnostic outcomes of these two groups have not been evaluated to date.

**Design:** Data from US-FNA of head and neck lesions over a 33-month-period (1/2011-9/2013) in two practice settings from one institution were reviewed. At Practice 1, US-FNA was performed by a CP who also performed rapid on site evaluation (ROSE) in a hospital-based clinic. At Practice 2, US-FNA was performed by an IR and ROSE performed by a CP at an outreach radiology practice. Practice 1 utilized the portable Sonosite NanoMaxx System with a flat, linear transducer (Sonosite Inc., Bothell, Washington). Practice 2 utilized the Philips IU22 ultrasound machine with both flat and hockey-stick linear transducers (Royal Philips, Amsterdam, The Netherlands). Both used similar US-FNA technique. Procedure duration was not analyzed due to different practice settings. Final histologic diagnosis was used to determine accuracy. Outcomes from each practice were compared using Fisher's exact test.

**Results:** The diagnostic accuracy of IR-performed US-FNA was 71% versus 84% for CP-performed cases. The sensitivity and specificity of IR-performed US-FNA was 77% (95% CI=46-94%) and 63% (95% CI=26-90%), respectively (resp.) versus 92% (95% CI=72-99%) and 75% (95% CI=43-93%) for CP, resp. The differences in these results were not statistically significant (defined as  $p<0.05$ ) when compared by either the number of true positives or the sensitivity and specificity ( $p=0.74$  and  $p=0.83$ , resp.).

Table 1: Overview of Patients and Cases by Practice Location and US-FNA Site

Features	Totals	Practice 1	Practice 2
Number of cases	175	108	67
Number of Patients with Histologic F/U	58	37 (M,16:F, 21)	21 (M,7:F,14)
Sampling Sites			
Thyroid	28	16	12
Salivary Gland	15	10	5
Lymph Node	8	6	2
Other	7	5	2
Passes to Achieve Adequacy			
1	40	26 (70%)	14 (67%)
≥ 2	18	11(30%)	7 (33%)
Inadequate Cases		2 (5.4%)	1 (5%)
Earliest Report to Clinicians		Immediately	2 days
Cytological Diagnosis			
Negative/Non-Diagnostic	19	11	8
Atypical	11	9	2
Neoplastic/Suspicious	4	2	2
Positive (including metastasis)	24	15	9

F/U: Follow-up

**Conclusions:** Diagnostic accuracy of cytopathologist-performed US-FNA is comparable to that of interventional radiologist-performed US-FNA.

### 400 Arginase-1 and HepPar-1 Expression in Fine Needle Aspiration Specimens of Primary Lung Adenocarcinoma

R Draganova-Tacheva, C Solomides, S Ren, M Bibbo. Thomas Jefferson University Hospital, Philadelphia, PA.

**Background:** Arginase-1 is a novel immunohistochemical marker for hepatocellular differentiation. The purpose of the study was to evaluate the expression of Arginase-1 and HepPar-1 of lung adenocarcinomas to assess the potential value of these markers to enhance the accuracy of diagnosing metastatic lung tumors, especially to the liver in fine needle aspiration (FNA) cytology specimens.

**Design:** 44 cytology specimens of lung adenocarcinoma, obtained by Endobronchial Ultrasound-Guided (EBUS) FNA were retrospectively reviewed and the diagnosis was confirmed by four cytopathologists. Immunohistochemical (IHC) stains for Arginase-1 and HepPar-1 were performed on formalin fixed paraffin embedded cell blocks. Tissue from confirmed hepatocellular carcinoma was used as positive control for both stains. TTF-1 IHC stain with adequate controls was performed in all cases.

**Results:** All 44 (100%) lung adenocarcinoma cell blocks were negative for IHC stain for Arginase-1, whereas HepPar-1 expression was detected in 3 (7%) of lung adenocarcinoma cases and negative in 41 (93%). The 3 HepPar-1 positive lung

adenocarcinoma cases demonstrated positive nuclear TTF-1 IHC stain performed on the same cell block. Although both Arginase-1 and HepPar-1 are useful diagnostic IHC markers to differentiate lung adenocarcinoma from hepatocellular carcinoma, Arginase-1 IHC stain showed better specificity than HepPar-1 (Arginase-1 specificity 100% and HepPar-1 specificity 93%).

Arginase-1 and HepPar-1 IHC stains of 44 cases of lung adenocarcinoma

	Negative	Positive
Arginase-1	44 (100%)	0
HepPar-1	41 (93%)	3 (7%)
TTF-1	3 (7%)	41 (93%)

**Conclusions:** Arginase-1 IHC can be utilized in combination with other markers in the workup of metastatic lung adenocarcinoma, especially to the liver, in small FNA specimens.

#### 401 Utility of STAT6 Immunohistochemistry to Distinguish Solitary Fibrous Tumor from Cytomorphologic Mimics in Fine Needle Aspiration and Core Needle Biopsies

MG Drage, JL Hornick, X Qian. Brigham and Women's Hospital, Boston, MA.

**Background:** Solitary fibrous tumor (SFT) is a distinctive fibroblastic neoplasm with a ubiquitous anatomic distribution and a broad range of histologic appearances. Although most cases of SFT are clinically benign, a small subset pursue an aggressive course. This tumor type can be difficult to distinguish from some malignant spindle cell neoplasms, most notably synovial sarcoma and malignant peripheral nerve sheath tumor (MPNST), particularly in limited biopsy material. Recently, transcriptome sequencing revealed consistent *NAB2-STAT6* gene fusions in SFT. Nuclear accumulation of STAT6 detected by immunohistochemistry performed on whole tissue sections has recently been shown to be a sensitive and specific surrogate for STAT6 rearrangement. The aim of this study was to assess the utility of STAT6 immunohistochemistry in distinguishing SFTs from mimics on fine needle aspirations (FNAs) and core needle biopsies (CNBs).

**Design:** In total, 28 cases were evaluated for STAT6 expression, including 10 cases of SFT (5 with concurrent FNA and CNB, 4 cases FNA only, and 1 case CNB only), 6 cases of MPNST, and 12 cases of synovial sarcoma. Immunohistochemistry for STAT6 was performed on cell block and core biopsy sections following pressure cooker antigen retrieval using a rabbit polyclonal antibody directed against the C-terminus of STAT6. Positive nuclear staining was scored both by extent (1+ <25%, 2+ 25-75%, 3+ >75%) and intensity (weak, moderate, strong).

**Results:** The 10 cases of SFT (6 conventional, 4 malignant) were from 8 patients (5 primary tumors, 3 metastases). Primary anatomic sites included perianal, pre-sacral, bladder, popliteal fossa, and lung; whereas metastases were in the proximal femur, proximal thigh soft tissue, and liver. Positive nuclear staining for STAT6 was identified in all 10 (100%) of the SFTs (both primary and metastatic, sampled by FNA and/or CNB) including 2 cases which were not diagnosed definitively as solitary fibrous tumor. Among the SFTs, 6 cases (60%) had strong 3+ staining, 3 cases (30%) had moderate to strong 2+ staining, and 1 case (10%) had moderate 1+ staining. None of the MPNSTs (0/6) or synovial sarcomas (0/12) showed any reactivity for STAT6.

**Conclusions:** Nearly all small biopsies of SFT in this study showed strong, diffuse nuclear staining for STAT6. As previously documented in resection specimens, nuclear STAT6 expression is a highly sensitive and specific marker for SFT in limited biopsy material. This novel marker should prove extremely useful in clinical practice.

#### 402 Utility of GATA-3, Mammaglobin, GCDFFP-15 and ER in Detection of Intrathoracic Metastatic Breast Carcinoma

KS Dyhdalo, CN Booth, JA Brainard, MC Croyle, AM Kolosiwsky, JP Reynolds. Cleveland Clinic, Cleveland, OH.

**Background:** Confirmation of metastatic breast carcinoma to the intrathoracic cavity in pleural effusion (PE) or endobronchial ultrasound (EBUS) guided fine needle aspirates (FNA) is difficult due to the low sensitivity of immunohistochemistry (IHC) stains currently used. Mammaglobin, gross cystic disease fluid protein-15 (GCDFFP-15) and estrogen receptor (ER) show variable results. GATA-3 is a recently described marker that is sensitive for detecting urothelial or breast cancer. Our goal is to test its utility in cell blocks (CB) of PE or FNA specimens.

**Design:** A search of the Anatomic Pathology database for PE and EBUS FNA cases with a diagnosis of breast carcinoma from January 2005 to September 2013 was conducted. IHC was performed on the paraffin embedded CB for GATA-3 (Biocare, 1:100), ER (Ventana, prediluted), GCDFFP-15 (Covance, 1:3), and mammaglobin (Cell Marque, 1:40). IHC were scored quantitatively and qualitatively.

**Results:** Fifty cases of metastatic breast carcinoma in PE and EBUS FNA were identified in 48 patients (all female, mean age 60 years, range 30-90 years). 34 cases had sufficient material on the CB for the study (19 PE, 15 EBUS). All cases had surgical resections confirming a history of breast carcinoma. GATA-3 showed strong nuclear positivity in 31/34 cases (91.2%). Mammaglobin (23/34, 67.6%, p=0.0001) and GCDFFP-15 (11/34, 32.6%, p=0.0001) stained fewer cases.

Sensitivities of immunohistochemical markers for breast carcinoma

Immunohistochemical stain	Number Positive/Total Cases (%)
GATA-3	31/34 (91.2)
ER	25/34 (73.5)
Mammaglobin	23/34 (67.6)
GCDFFP-15	11/34 (32.6)

GATA-3 and ER were concordant in 77% of cases (25 ER/GATA-3 positive, 2 ER/GATA-3 negative). 7 cases (20%) were GATA-3 positive/ER negative and 1/35 case (2.8%) was GATA-3 negative/ER positive.


**Conclusions:** GATA-3 is more sensitive than ER, mammaglobin or GCDFFP-15 in detecting metastatic breast cancer in cytologic specimens. ER shows correlation with GATA-3 in cytologic specimens (27/35, 77%). GATA-3 may be positive when ER is

negative. In cytologic specimens with limited diagnostic material, GATA-3 may be used as a first-line marker as part of a limited IHC panel to confirm tumor origin from breast carcinoma.

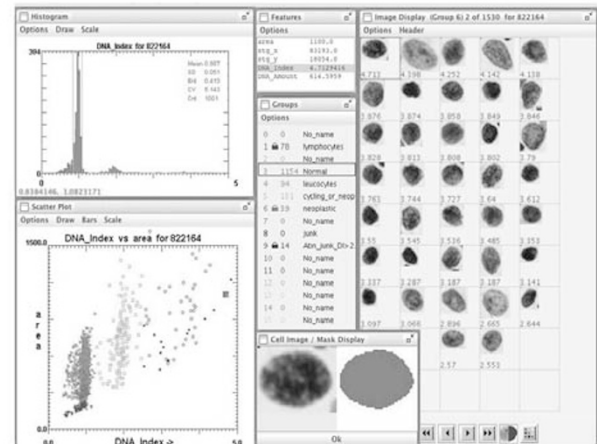
#### 403 Pathologist Goes to Work: Affordable Automation of Cervical Cancer Screening in Developing Countries

S El Hallani, H El Attar, D Garner, CE Marginean, S Islam, H Sekhon. The Ottawa Hospital, Ottawa, ON, Canada; Moulay Idriss Laboratory, Casablanca, Morocco; BCCA, Vancouver, BC, Canada.

**Background:** Our group has developed an inexpensive and portable DNA assisted cytometry automate to assist cervical cancer screening programs in countries where there is a shortage of skilled cytotechnologists. The purpose of device is to identify only high-grade lesions with immediate clinical impact. The aim of this study is to determine the feasibility of implementing a short cycle of training in a pilot laboratory in Casablanca (Morocco) and to demonstrate the value of automation in low resources setting.



**Design:** The local technologists enrolled in a 2-week training program which provided knowledge from slide preparation, staining and result interpretation. A total of 404 women were enrolled in the validation study. Two liquid-based slides were prepared manually from each cervical sample: one stained with Papanicolaou stain for visual cytology examination, the other with a DNA specific stain (Feulgen), which determined the relative amount of nuclear DNA. A sample was declared positive by the automate if presence of more than 3 cells with 5c DNA and/or the proliferative fraction of nuclei exceeding 10%. Follow up biopsies were performed for positive cases.



**Results:** From 404 patients, the automate identified as: positive 33 (8%), equivocal 51 (13%), negative 218 (54%), and inadequate sampling 102 (25%). If visual cytology was to be used alone, only 11 cases would have been referred to colposcopy. Visual cytology would have missed 22 cases that were initially diagnosed as NILM (n=6), inflammatory (n=6), severe atrophy (n=1), immature squamous metaplasia (n=2), condyloma (n=2) and LSIL (n=5). Follow-up biopsies confirmed CIN2-CIN3 in positive cases.

**Conclusions:** This study suggests that affordable DNA assisted cytometry could be easily implemented with minimal training in developing countries where it is difficult to introduce population-based Pap test screening.

#### 404 Does Bilateral vs. Unilateral Fine Needle Aspiration Improve the Detection Rate of Thyroid Carcinoma in Multinodular Goiter? A Single Center Study

J El Masri, N Shabb, F Boulos. American University of Beirut Medical Center, Beirut, Lebanon.

**Background:** Bilateral thyroid fine needle aspiration (FNA) of dominant nodules in multinodular goiter (MNG) has recently been the procedure of choice at our institution. No clear cut recommendations are however available for FNA of MNG in regions where goiter is endemic. The objective of this study is to compare the rate of detection of

malignancy in MNG between unilateral and bilateral FNA at a single referral center in a region endemic for goiter, and to verify whether bilateral FNA is justified.

**Design:** A retrospective review of FNA results between 1996 and 2012 was performed, and the rate of detection of malignancy in unilateral versus bilateral FNA was determined. Results were reported as benign, malignant, or suspicious. Only cases where MNG was specifically described in the history were included in the study. The sonographic characteristics of bilateral aspirated nodules were recorded when available. **Results:** Out of 4000 FNA results examined, 1397 that satisfied inclusion criteria were studied. In the bilateral FNAs sampled, 5% proved to be malignant in comparison to 2.8% in the unilateral FNA ( $p=0.0396$ ). Bilateral FNAs had a 7.75% rate of results suspicious for malignancy compared to 8.57% in unilateral FNA ( $p=0.6254$ ).

**Conclusions:** The rate of detection of malignancy is significantly higher when sampling both lobes of the thyroid gland by FNA. The rate of suspicious nodules was however not significantly different. It is therefore recommended to perform bilateral FNA of dominant nodules even in regions endemic for goiter. Since the sonographic features of the nodules sampled in this study were not always available, it may be useful to perform prospective studies with detailed sonographic information to further refine criteria for FNA in MNG.

#### 405 Abnormal RedPath Results Are Associated with a Higher Likelihood of Mucinous Pancreatic Neoplasms on Surgical Follow Up, but Do Not Seem to Be a Major Factor in Selecting Patients for Surgery

*RE Emerson, X Wang, L Cheng.* Indiana University School of Medicine, Indianapolis, IN.

**Background:** Cytologic evaluation of cystic lesions of the pancreas remains difficult due to low specimen cellularity. A molecular test (RedPath Integrated Pathology, Pittsburgh, PA PathFinderTG® Pancreas) that evaluates *KRAS* mutation, loss of heterozygosity (LOH), and DNA quantity has been used to identify preinvasive lesions of the pancreas. **Design:** This is a single institution 5.5 year retrospective review of all RedPath results and associated specimens. RedPath results were categorized as a mucinous process (i.e., positive for one or more of the following: *KRAS* mutation, two or more LOH mutations, or greatly elevated DNA content), negative (lacking all three features), or inadequate. Specimens with both *KRAS* and LOH abnormalities were considered the aggressive subgroup. Cytology was grouped as negative, mucin only, or abnormal.

**Results:** RedPath testing was performed on 453 specimens. Five were inadequate, 303 were negative, and 145 were mucinous lesion. Among the negative cases, 46 (15%) were followed by a resection. There were 15 nonmucinous lesions (6 serous cystadenoma, 5 chronic pancreatitis/pseudocyst, 2 other cyst, and 2 endocrine neoplasm) and 31 mucinous lesions/carcinomas (15 intraductal papillary mucinous neoplasm (IPMN), 7 pancreatic intraepithelial neoplasia, 5 mucinous cystic neoplasm (MCN), and 4 adenocarcinoma). Among the RedPath mucinous cyst cases, 24 (17%) were resected with 4 nonmucinous specimens (2 serous cystadenoma and 2 endocrine neoplasm) and 20 mucinous lesions/carcinomas (14 IPMN, 3 MCN, 3 adenocarcinoma). Only 6 cases had both *KRAS* mutation and LOH (the aggressive subgroup). Three of these patients (50%) had resections with IPMN (2 patients) or adenocarcinoma (1 patient). Among cases with negative cytology and abnormal RedPath results, there were 3 cases (4% of resected cases) of a mucinous lesion by histology and 1 case (1.4% of resected cases) of adenocarcinoma.

**Conclusions:** Pancreas resections had a mucinous neoplasm or adenocarcinoma in 67% of cases following negative RedPath results and in 83% of cases following mucinous process RedPath results. Only 17% of patients with an abnormal molecular result underwent a resection (compared to 15% of patients without molecular abnormalities), so mucinous cyst RedPath test results do not seem to be a major factor in selecting patients for surgical treatment. Half of the patients with both *KRAS* and LOH abnormalities had surgery, but this combination is rare (1.3% of tests).

#### 406 Diagnostic Value of Fine-Needle Aspiration Cytology in a Pediatric Oncology Population: A Retrospective 5-Year Study

*J Ferreira, M Rito, A Figueiredo, C Calle, MM Lemos, R Fonseca, S Andre.* Instituto Português de Oncologia de Lisboa Francisco Gentil, Lisboa, Portugal; Hospital Curry Cabral - Centro Hospitalar de Lisboa Central, Lisboa, Portugal; Faculdade de Medicina de Lisboa, Lisboa, Portugal.

**Background:** Fine-needle aspiration cytology (FNA) has become an invaluable diagnostic tool in the screening, evaluation and follow-up of pediatric lesions. Ancillary diagnostic techniques have been increasingly used to improve the diagnostic yield of cytology in the pediatric population. We reviewed our institution's FNAs performed in the population under 18 years of age for a 5-year period (2008-2012).

**Design:** A computerized search of our hospital's laboratory information system was performed for a 5-year period (2008-2012). All FNAs in patients younger than 18 years were retrieved and cytology, histopathology and clinical data were reviewed. Cytological diagnoses were correlated with histopathology and clinical follow-up in order to evaluate the utility of FNA in the management of these patients.

**Results:** We evaluated a total of 620 FNAs from 506 patients with a mean age of 9.8 years, 232 being females (37%) and 274 males (35%). Ninety-five cases (15.3%) were insufficient for diagnosis. Ancillary techniques were performed in 29% of cases, mainly flow cytometry (82%). Among the 620 lesions, 230 (37.1%) were diagnosed as malignant and 295 (47.6%) as benign or non-neoplastic. The most frequently biopsied organs were lymph nodes (44%) and soft tissues (20%). The most frequent malignant diagnoses included the following entities: Hodgkin lymphoma (8.8%), Non-Hodgkin lymphoma (5.2%), neuroblastoma (5.1%) and rhabdomyosarcoma (4.4%). The most common non neoplastic condition was reactive lymph node hyperplasia (28% of all FNAs). When analyzing the available histological ( $n=278$ ) and clinical ( $n=247$ ) data, the overall sensitivity of cytology for detecting malignancy in this pediatric oncology population was 91.1%, with a specificity of 93.8%. The positive predictive value was 96.5%, with a negative predictive value of 85.1%. Major cyto-histological discrepancies

were observed in the setting of Hodgkin Lymphoma (25% of total discrepant cases). Complications were rare ( $n=3$ ) and were associated with the anesthesia.

**Conclusions:** In our series, FNA had an excellent diagnostic accuracy and therefore, may avoid unnecessary surgical biopsies and its potential complications, a significant consideration for this age group. In our experience, therapeutic decisions for many pediatric patients have been solely based on the cytologic diagnosis.

#### 407 Aberrant Staining for Mesothelial Markers Calretinin and WT-1 in Triple Negative Breast Cancers

*B Firetag, G Krings, MJ Nystrom, AB Berry, Y-Y Chen, R Balassanian.* University of California San Francisco, San Francisco, CA; UCSF Mt. Zion Hospital, San Francisco, CA.

**Background:** Triple negative breast cancers (TNBC) may have aberrant immunohistochemical (IHC) expression of mesothelial markers calretinin and WT-1. In cases of TNBC metastatic to the pleura, positive IHC staining for calretinin and WT-1, and may lead to a misinterpretation of reactive mesothelial cells rather than metastatic TNBC. We performed an IHC study of tumor microarrays (TMA) comparing TNBC to benign reactive mesothelial cells in order to identify a panel suitable for distinguishing TNBC cells from reactive mesothelial cells.

**Design:** We reviewed tumor microarrays of TNBC with 122 total TNBC cores from 122 separate cases. As a control we used a TMA of mesothelial cells from 33 benign pleural effusion samples of patients without a history of carcinoma. IHC for calretinin, WT-1, Moc31, and GATA-3 were performed on both sets of TMAs. Individual TMA cores were reviewed and scored as positive or negative for each marker.

**Results:** Calretinin and WT-1 were positive in 41.6% and 2.6% of TNBC cores, respectively, compared to 100% positivity for each marker in mesothelial cell cores ( $p<0.001$  each). Moc31 and GATA-3 were positive in 98.1% and 64% of TNBC cores respectively, whereas none of the mesothelial cell cores were positive for either marker ( $p<0.001$  each).

**Conclusions:** For patients with TNBC metastatic to the pleura, positive staining for calretinin and WT-1 may lead to the misinterpretation of tumor cells as benign reactive mesothelial cells. Positive staining for Moc31 in 98.1% of cases of TNBC, suggests that this stain is a sensitive marker and may help distinguish between tumor cells and reactive mesothelial cells in cases of metastasis to the pleura. GATA-3 staining showed lower sensitivity, with only 64% positivity in cases of TNBC. These results suggest a panel of IHC stains including WT-1, calretinin and Moc31 may be helpful in distinguishing TNBC cells from reactive mesothelial cells in pleural effusion samples.

#### 408 The Diagnostic Utility of Electromagnetic Navigation Bronchoscopy (ENB) in Evaluating Peripheral Lung Lesions: A Single Institution Study

*AB Frey, TA Wiese, H Alatassi, M Moghadamfalahi, M Fraig.* University of Louisville Hospital, Louisville, KY.

**Background:** ENB is a new modality using an electromagnetic field to guide a probe into the terminal bronchioles of the lung to evaluate peripheral lung lesions. The goal of this study is to evaluate the diagnostic utility of lung cytologic specimens obtained by ENB procedures.

**Design:** A computer-based search of all cytologic lung specimens procured by navigational procedure from a tertiary care center was performed spanning the period from January 2012 to July 2013. Radiographic impression, final diagnosis, operational notes and pathological and clinical follow-up were reviewed.

**Results:** The search revealed 259 specimens from 141 patients. The specimens obtained included 60 brushings, 37 fine needle aspirations (FNA), 13 washings, 101 core needle biopsies (CBX), and 48 touch imprints. Radiographic evidence of a lesion was present prior to all procedures. Of the 62 patients with available follow-up, 8 were diagnosed with malignancy and were confirmed by surgical specimens. One patient was initially diagnosed as suspicious for carcinoma and later downgraded to atypical on a repeat ENB procedure. Of the remaining 53 patients that were diagnosed as benign, 5 were converted to malignant diagnoses on follow-up and 48 were confirmed as benign. No false positive cases were identified. On-site evaluation was provided to all these procedures with on-site diagnosis rendered whenever possible as fiducial markers for subsequent radiation are frequently placed at the same setting. None of our patients suffered a pneumothorax as a result of the procedure.

**Conclusions:** This study demonstrates that ENB is a useful modality in evaluating peripheral lung lesions and offers an alternative to CT-guided fine needle aspiration. The variety of sampling methods may increase the yield of diagnostic material. Being performed in real-time imaging decreases the time of the procedure and lowers the rate of pneumothorax, decreasing the morbidity from the procedure, saving cost and increasing safety. There are many advantages and applications for the technology which will help spread its usage. Cytopathologists should familiarize themselves with this new technology.

#### 409 How Effective Is Acetic Acid Wash Protocol as a Tool to Improve Interpretation of Bloody Cervical Cytology ThinPrep® Specimens?

*NK Frisch, D Neill, Y Ahmed, T Kalinicheva, S Vinod.* Detroit Medical Center/Wayne State University, Detroit, MI.

**Background:** ThinPrep (TP) cervical cytology has several benefits compared to conventional cervical smears including improved cytomorphology without air-drying artifact and the opportunity to send residual specimen for HPV testing as indicated. One barrier with TP is the relatively high unsatisfactory (UNS) rates due to debris/lubricant contamination and presence of blood. These contaminants can clog the TP filter and prevent the epithelial cells from depositing on the slide. Acetic acid wash (AAW) is



used in many labs to lyse the red blood cells before preparing the TP slides. We wanted to quantitatively study the usefulness of this tool, as well as compare the interpretative results of cases which underwent AAW and which did not.

**Design:** From 23,291 TP specimens in a 4 month period, we identified 2,739 cervical cytology specimens which were initially UNS with scant cellularity due to blood and underwent the AAW protocol. We then randomly selected a matched set of 2,739 cases which did not undergo AAW from the same time period. We reviewed the cases for adequacy and final interpretation. The cases which underwent AAW were compared to the non-AAW cases for each interpretation category (ASCUS, LSIL, HSIL, & UNS) using chi square test.

**Results:** 94.2% of the 2,739 cases which underwent AAW (because of initial UNS) became satisfactory for evaluation and the interpretations were 135 (4.9%) ASCUS, 102 (3.7%) LSIL, & 28 (1%) HSIL. Amongst the 2,739 cases which did not undergo AAW, 96.3% were satisfactory for evaluation with 151 (5.5%) ASCUS, 139 (5.1%) LSIL & 19 (0.7%) HSIL. The difference in the percentages of the ASCUS cases was statistically insignificant (p 0.33). There were 68% more HSIL cases in the AAW group (28 v. 19); however, the difference was statistically insignificant (p 0.18). AAW category, however, has less cases of LSIL with statistical significance (p 0.02). The percentage of UNS cases was significantly higher in the AAW group (p<0.01).

**Conclusions:** While AAW cases had a significantly higher percent of UNS interpretations, the protocol is still of benefit. AAW greatly increased the satisfactory rate of bloody TP specimens (0% to 94.2%), allowing interpretation which would otherwise have been UNS. This improved patient care by avoiding a repeat test. The percentage of cases in the categories of ASCUS and HSIL was not significantly different between AAW and non-AAW groups. There were significantly fewer cases of LSIL in the AAW group and although not statistically significant, cases of HSIL were relatively higher in the AAW group.

#### 410 Differentiating Small Cell Carcinoma from Squamous Cell Carcinoma on Fine Needle Aspiration: A Head-To-Head Comparison of p40 and p63 Using Cell Block Immunocytochemistry

MP Gailey, AM Bellizzi, CS Jensen. University of Iowa Hospitals and Clinics, Iowa City, IA.

**Background:** Distinguishing small cell carcinoma (SCC) from poorly differentiated squamous cell carcinoma (SCCA) is an ongoing challenge on fine needle aspiration (FNA). Immunocytochemistry is common, if not the rule, and p63 (a p53 analogue) is a very common marker used to prove squamous differentiation as part of a panel of markers. However, issues relating to specificity have arisen, and the common p63 clone 4A4 (specific for TAp63) has begun to be supplanted by antibodies specific to ΔNp63 (p40), which show superior specificity for SCCA in histologic sections. Although anecdotal evidence suggests p40 is superior to p63, to date, these markers have not been studied head-to-head in cytology cases. We struck out to determine if p40 was better than p63 in differentiating SCCA from SCC.

**Design:** We queried the cytology files and identified 50 SCC and 25 SCCA in which cell block material was available for immunocytochemical staining. Cell blocks were stained with antibodies for p40 (PC373 (5-17); 1:1500 dilution; Calbiochem/EMD Biosciences) and p63 (4A4; 1:200 dilution; Biocare Medical). For both markers, both extent (percentage of nuclei staining) and intensity (1+,2+,3+) of immunoreactivity were recorded, blinded to final diagnosis. Positive cases had any definite nuclear staining within tumor cell nuclei.

**Results:** Thirty-four percent (17/50) of SCC showed positive staining for p63, while 2 cases (2/50; 4%) showed staining for p40 (p=0.00006). Staining ranged from 1-90% and 1-40% for p63 and p40, respectively. Twenty-two (22/25; 88%) and 23/25 (92%) SCCAs stained positively for p63 and p40, respectively, and the proportion of cells staining was similar, 50-100% for p63 and 60-100% for p40.

**Conclusions:** Although p40 is only marginally more sensitive (92% vs 88%) than p63, it is much more specific (96% vs 66%) in distinguishing SCC from SCCA (NPV=96%; p=0.00006) on cytology specimens. Only 4% of SCC showed staining for p40 while 34% showed significant expression of p63. Our rate of p40 and p63 staining in cytologic specimens of SCCA is similar to prior histologic studies. This difference in specificity in aspiration biopsies between these two antibodies indicates p40 is superior to p63 to exclude SCC and confirm SCCA. Therefore, we recommend that p40 supplant p63 on immunocytochemical panels used to differentiate SCC from SCCA on FNA.

#### 411 FGFR3 Mutation in Archival Urinary Tract Cytology Specimens: A Simple Method for Detection with Preservation of Cytomorphology

L Gao, JA Pruessner, AA Stence, NV Guseva, MT Zubcic, JR Hackman, F Sue, C Jensen, A Bossler. University of Iowa, Iowa City, IA.

**Background:** Although not without controversy, cytology of urinary tract specimens is widely used for detection of urothelial carcinoma (UC) or recurrence. Unfortunately, the sensitivity for detecting low grade UC (LGUC) is low. Recent studies have shown that fibroblast growth factor receptor (FGFR) 3 mutations are common in LGUCs and may be a promising therapeutic target. To date the feasibility of detecting FGFR3 mutations from archived urinary tract cytology slides has not been well documented. Detection of the mutation may have potential to enhance detection of LGUC in cytologic specimens. Our goal was to develop an easy and economical way to detect FGFR3 mutations using a technique which preserves a portion of the cytologic specimen for morphologic correlation.

**Design:** We identified 16 archived cytology specimens (atypical urothelial cells (AUC; 4), high grade urothelial carcinoma (HGUC; 10), no tumor cells (NTC; 2)) with corresponding histology specimens. Approximately half of the cells from each cytology slide were harvested using a microdissection solution (PinPoint, Zymo, Inc), and coverslips were reapplied to preserve the remaining archival material. Patient

matched paraffin-embedded tissue sections were manually microdissected and DNA from tumor and normal tissue was extracted (Qiagen, Inc). FGFR3 mutations in exon 7, 10 and 15 were tested using primer extension SNaPshot assay (based on assay design by Kompier LC et al).

**Results:** All of the cytology specimens demonstrated sufficient DNA yield for amplification. Known FGFR3 activating mutations were detected in five cytology specimens (p.S249C, p.R248C, p.Y375C, G382R) corresponding to cytologic results of AUC (n=2), NTC (1) and HGUC (2). An identical mutation was identified in three corresponding histologic specimens (all LGUC). The remaining two corresponding histologic samples had insufficient DNA for FGFR3 mutation testing. Conversely, all but one of the pairs lacking FGFR3 mutations by cytology had a negative result from the corresponding histologic specimen (one case with p.S249C mutation, histology low grade UC). Notably all cytology specimens retained sufficient cellularity and morphologic integrity for cytologic correlation or future additional testing.

**Conclusions:** This study demonstrates the feasibility of testing for FGFR3 mutations from urinary tract cytology specimens while preserving a portion of the archived cytology specimen for morphologic comparison or potential future testing. The combination of cytology and FGFR3 mutation may potentially increase the sensitivity for detection of LGUC.

#### 412 GATA3 Is a Useful Marker to Identify Breast Origin in FNA Samples

Z Ghorab, N Hosseini, G Han, V Dube, J Wong, S Nofech-Mozes. Sunnybrook Health Sciences Centre, Toronto, ON, Canada.

**Background:** Recent data suggest that GATA3 is a sensitive and specific marker in primary urothelial and breast cancer. Fine needle aspiration (FNA) cytology is a common diagnostic tool in breast cancer used to establish diagnoses of primary, metastatic or recurrent lesions. Limited data are available on the utility of GATA3 expression in cytology. We aimed to assess the value of adding GATA3 testing to ER and PgR in the consideration of breast origin in FNA specimens.

**Design:** 52 FNA samples (35 breast and 17 axillary FNAs) with predetermined biomarkers status were identified from a previous set used for HER2 testing validation. FNA samples were fixed in alcohol based preservative. Immunocytochemistry studies were performed on cell blocks. GATA3 (sc-268; Santa Cruz Biotech, Santa Cruz, CA) was evaluated for intensity and percentage of immunoreactive cells in semi-quantitative groups (negative; 1-25%; 26-50%; >50%). ER (SP1) and PgR (IE2) (Ventana Medical Systems, Tucson AZ, USA), were scored positive when ≥1% of cells were immunoreactive. HER2 gene amplification was determined by INFORM HER2 DNA and Chromosome 17 (both by Ventana Medical Systems, Tucson AZ, USA) in our previous study.

**Results:** Gata3 was successfully evaluated in 51 cases in which 24 cases were ER+ (16PgR+ and 9 PgR-) and 27 were ER-/PgR-. Gata3 was positive in 20/24 (83.3%) ER+ cases compared with in 7/27 (25.9%) ER- cases. Among the ER-/GATA3+ cases: 3 were positive in >50%, one in 26-50% and 3 in 1-25% of neoplastic cells. The intensity was strong only in one of these cases. Among the 27 ER- cases, GATA3 was negative in all 15 HER2- cases and positive in 7/12 (58.3%) HER2+ cases. By adding GATA3 to the panel we increased the proportion of samples in which breast origin is suggested from 47% to 60%.

**Conclusions:** Although GATA3 expression among ER- cases is limited to one quarter of the cases in our study, the inclusion of this marker in immunocytochemical panel applied to malignant aspirates of unknown origin is warranted. In majority of the ER+ cases, GATA3 expression further confirms breast origin. Absence of GATA3 expression in ER+ aspirates does not rule out breast origin, however other sites of origin need to be considered. The expression of GATA3 in triple negative tumors has to be further studied on a larger cohort.

#### 413 Molecular Cytology: Validation of a Method for the Direct Molecular Evaluation of Pap Stained Cellular Material

WE Gibson, JA Nowak. NorthShore University HealthSystem and The University of Chicago Pritzker School of Medicine, Evanston, IL.

**Background:** Biomarker evaluation of malignant tumors has become an essential component in tumor classification and treatment selection. Frequently, tissue obtained through biopsy is insufficient in quantity or quality for molecular testing. Cellular specimens prepared as cell blocks can sometimes suffice for molecular analysis, but relatively few laboratories have attempted testing of selected groups of cells removed from cytologic smears, most after Diff-Quick staining. We report here a method for the molecular analysis of groups of cells removed from Pap stained smears prepared from FNA specimens from thyroid nodules.

**Design:** A series of thyroidectomy specimens with BRAF V600E mutation positive papillary thyroid carcinoma was identified. Pre-surgical FNA specimens were reviewed and select groups of malignant cells were microdissected from uncovered Pap stained smears for molecular evaluation of the BRAF gene. Select foci were photographed and characterized for total cellularity and tumor cell fraction.

**Results:** Evaluation of FNA obtained Pap stained cellular material for BRAF showed 100% correlation (43/43) with post-surgical testing using FFPE tissue. Molecular analysis was not inhibited by Pap staining. Cellular foci with as few as 100 cells returned interpretable results.

**Conclusions:** 1. Molecular evaluation of previously Pap stained cytologic cells is feasible, extending the capabilities of molecular testing to cytologic specimens. 2. Direct testing of select cytologically identified cell groups enhances the specificity and sensitivity of molecular biomarker testing. 3. The high correlation for BRAF mutation detection between FFPE specimens and small cellular samples does not support significant clonal heterogeneity for BRAF in papillary thyroid carcinoma.

#### 414 Role of Epstein-Barr Virus (EBV) Status and Immunophenotypic Studies in the Evaluation of Exfoliative Cytology Specimens from Patients with Post-Transplant Lymphoproliferative Disorders (PTLD)

SE Gibson, J Picarsic, SH Swerdlow, L Pantanowitz. University of Pittsburgh School of Medicine, Pittsburgh, PA.

**Background:** Although PTLD are well characterized in tissue sections, their evaluation in cytologic fluid specimens has received little attention. This study reports our experience with PTLD in a series of exfoliative cytology specimens.

**Design:** All solid organ or allogeneic stem cell transplant recipients with PTLD and exfoliative cytology specimens between January 1987 and December 2011 were identified. The cytomorphologic findings, EBV status, results of flow cytometry (FC), immunohistochemistry (IHC), and molecular studies were reviewed.

**Results:** There were 434 cytology specimens from 55 patients (age 1-72 years) with prior or subsequent PTLD, of which 65% (36 patients) had atypical specimens. 26 patients had material available for review (15 CSF, 12 peritoneal, 9 pleural, and 1 BAL fluids). 11/37 (30%) specimens appeared reactive with rare atypical cells, but lacked sufficient ancillary studies to exclude PTLD. 15/37 (41%) specimens were suspicious for PTLD, including 5 cases cytologically compatible with monomorphic PTLD (M-PTLD) and 10 cases with a polymorphous appearance and fewer atypical cells. However, only 6 of these specimens had ancillary studies, none of which were diagnostic (Table). 11/37 (30%) specimens were diagnostic of PTLD, including 8 M-PTLD with monomorphic proliferations and abnormal B/T-cell populations detected by FC/IHC, and 3 specimens with previously diagnosed M-PTLD that had polymorphic EBV+ proliferations that could represent either polymorphic PTLD (P-PTLD) or M-PTLD.

Cytology Diagnosis	Tissue Biopsy Diagnosis	FC (# diagnostic)	IHC (# diagnostic)	EBV (# positive)	B-cell/T-cell clonality (# positive)
Atypical, suspicious for PTLD (n=15)	13 M-PTLD	1 (0)	2 (0)	4 (1)*	0
	1 P-PTLD	0	0	0	0
	1 CHL-PTLD	0	0	0	0
M-PTLD (n=8)	8 M-PTLD	4 (4)	5 (5)	6 (3)	1 (1)
P-PTLD vs. M-PTLD (n=3)	3 M-PTLD	1 (0)	0	3 (3)	0

CHL-PTLD = Classical Hodgkin lymphoma-type PTLD. \*1 case with rare atypical cells and qualitative PCR EBV+, but not considered definite for PTLD.

**Conclusions:** Atypical lymphoid proliferations are commonly found in exfoliative cytology specimens from patients with PTLD. A diagnosis of PTLD requires sufficient material for ancillary studies, including immunophenotyping and EBV evaluation, whereas a lack of such studies may result in equivocal diagnoses. Ancillary studies are of particular utility in the categorization of atypical polymorphic-appearing fluids in transplant patients as the differential diagnosis includes benign disorders, as well as early PTLD, P-PTLD, and M-PTLD.

#### 415 Is the Molecular Profile of Pulmonary Adenocarcinoma Stable?

D Grunes, M Wu. The Mount Sinai School of Medicine, New York, NY.

**Background:** Early characterization of pulmonary adenocarcinoma for Kirsten Rat Sarcoma (KRAS), Epidermal Growth Factor Receptor (EGFR), and Anaplastic Lymphoma Kinase (ALK) mutations is becoming more common. Our recent study shows that the majority of small FNA samples are sufficient for cytology diagnosis as well as molecular profiling. This allows for immediate treatment and increased chance of cure. However, it has yet to be established if this molecular signature changes as the tumor progresses and metastasizes. This directly impacts the clinical management of the patient as well as our use of scant material retrieved from smaller nodules. We hypothesize that if the expression of KRAS, EGFR, and ALK changes as the disease progresses, then we may see a difference in the molecular profiles of tumors at different stages.

**Design:** We searched our databank for primary adenocarcinomas diagnosed by FNA cytology and submitted for molecular characterization of KRAS, EGFR, and ALK between 1/2009 -9/2013. The mutational status and stage of the tumor were recorded. We compared the mutation frequency in lesions confined to the lung, with those that had metastasized.

**Results:** We identified 108 primary adenocarcinomas that were diagnosed by FNA cytology and sent for molecular characterization; 7 cases were insufficient for molecular testing, and 4 cases had no stage recorded. Of the 97 cases, 46 were confined to the lung, 51 had nodal or distant metastasis. No known mutation was identified in 18 (40%) tumors confined to the lung, 22 (43%) metastasis; KRAS was mutated in 17 (36%) localized tumors, 13 (25%) metastases; EGFR in 10 (21%) localized and in 14 (27%) metastases; ALK in 1 (2%) local and 2 (4%) metastatic lesions. The p value between these profiles is 0.4166; there was no statistical difference.

**Conclusions:** The distribution of mutations was similar in localized as well as metastatic tumors. Our data indicate that key mutations do not appear to be lost or gained as the tumor evolves and spreads. The major limitation of this study is that it compares different tumors; a longitudinal study would be more conclusive. We also acknowledge the heterogeneity inherent in malignancy. However, the lack of a statistical significance between mutations found in localized vs metastatic tumors strongly supports the practice of molecular characterization of small adenocarcinomas diagnosed on FNA cytology.

#### 416 The Role of Interventional Cytopathologist in the Cytologic Diagnosis of Thyroid Nodules – An Experience of a Community FNA Clinic of 1,424 Nodules in 958 Patients

M Gu. FNA Clinic, PathCare Diagnostics Inc, Corona, CA.

**Background:** An accurate cytologic diagnosis of thyroid nodules is pivotal in guiding proper clinical management. However, unsatisfactory/non-diagnostic and indeterminate categories account for up to 15% and 25% of cases, respectively. This hinders to optimize the clinical utility of FNA in the diagnosis of thyroid nodules and increases the cost when FNA needs to be repeated or unnecessary ancillary testing performed.

**Design:** A community-based, free-standing FNA clinic operated by interventional cytopathologist is functioning to optimize the clinical utility of FNA and to improve the diagnostic accuracy in patients with palpable and non-palpable lesions, such as thyroid nodules. Patients are referred from community primary care physicians and specialists for ultrasound-guided FNA biopsy. The Bethesda system is used to report thyroid cytopathology. Preliminary results are discussed with the patients at the end of the procedure. Follow up information is collected from either patients or referring physicians.

**Results:** During January 2009 - December 2012, 958 patients including 137 men and 821 women were evaluated for nodular thyroid disease and 1,424 nodules were aspirated. The average age of patients was 55.3 years old (9-91 years). The average size of nodules was 18 mm (2-80 mm). Nineteen nodules were unsatisfactory/non-diagnostic (1.3%), 1,293 benign (90.8%), 5 FLUS (0.4%), 60 follicular neoplasm (4.2%), 10 suspicious for malignancy (0.7%), and 37 positive for malignancy (2.6%). Preliminary results were the same as the final diagnoses in all but one patient, which was changed from benign to suspicious. Histology confirmed 10 positive nodules all to be papillary carcinoma; 9 suspicious nodules to be papillary carcinoma and 1 Hürthle cell adenoma; 3 FLUS nodules to be papillary carcinoma, 1 follicular adenoma, and 1 intrathyroidal parathyroid adenoma; 23 follicular neoplasm nodules to be follicular adenoma, 1 papillary carcinoma, 5 nodular hyperplasia, and 1 parathyroid adenoma. Twelve patients with follicular neoplasm cytology did not have surgery but were doing well. Twenty-four patients with benign cytology underwent surgery and all showed nodular hyperplasia.

**Conclusions:** Cytologic diagnosis of thyroid nodules is not only reliable, but also efficient when ultrasound-guided FNA biopsy is performed by interventional cytopathologist. Since the unsatisfactory/nondiagnostic and indeterminate rates are significantly decreased, better clinical services are provided with patient satisfaction, diagnostic accuracy, and cost effectiveness.

#### 417 Cervicovaginal Cytology for the Postirradiation of Women with Gynecologic Malignancies – An Institutional Experience

H Guo, D Rudomina, K Park, AL Moreira. Memorial Sloan-Kettering Cancer Center, New York, NY.

**Background:** The difficulties in morphologically discriminating tumor cells from radiation effects in benign cells have long been recognized. Although cervicovaginal cytology is performed in many centers as part of patients' management, the problems encountered in postirradiation cytology have led some authors to question its diagnosis value in patients following radiotherapy. Here, we represent our cytology experience, with the distribution of cytologic results, hrHPV (high risk human papillomavirus) detection rates and the histologic outcomes.

**Design:** A database search was conducted from January 2003 to January 2011 for patients with endometrial and cervical cancer treated with primary or adjuvant radiotherapy. Clinical information, the results of concurrent hrHPV testing if available, and histologic follow-up if any, were compiled. Statistical analysis was performed using chi-square test and Fisher's exact test and a p value of < 0.05 was considered as statistically significant.

**Results:** A total of 1618 ThinPrep cytologic samples from 245 women were evaluated. 152 cases (9.4%) were identified as abnormal, including 3.8% ASCUS, 0.2% ASC-H, 0.3% AGC, 1.5% LSIL, 1.9% HSIL, 0.6% favor neoplasia and 1.2% carcinoma results. Histologic follow-up was available in 97 cases (97/1618=6%).

#### Histologic and cytologic results correlation

Histologic Diagnosis	Cytologic Diagnosis						
	ASCUS	AGC	LSIL	HSIL	Favor Neoplasia	Carcinoma	Benign with treatment effect
Benign	60.9%	0%	53.8%	6.7%	66.7%	0%	77.1%
LSIL	13%	0%	23.1%	6.7%	0%	6.9%	0%
HSIL	17.4%	0%	15.4%	66.6%	0%	6.9%	5.3%
Carcinoma	8.7%	100%	7.7%	20%	33.3%	86.2%	17.6%
Total	23	1	15	15	9	17	17

The difference between the detection rates for high-grade dysplasia or above in the following groups was not statistically significant- ASC-US vs. LSIL, HSIL vs. LSIL. The sensitivity for the detection of SIL was 91.4%, the specificity 50%, and the positive predictive value (PPV) 76.8%. In a total of 34 ASCUS cases which the hr HPV DNA testing was conducted, the follow-up histologic material was available in 20 cases. The detection rates for SIL was strongly associated with the detection rates for hrHPV (p=0.019).

**Conclusions:** Our study reveals cervicovaginal cytology for the surveillance of women with gynecologic malignancies after radiotherapy is a reliable test for the diagnosis of SIL with the sensitivity of 91.4% and PPV 76.8%. The hr HPV testing may play a significant role in the triage of the patients with a diagnosis of ASCUS since they are strongly associated with dysplasia of any grade.

#### 418 Secondary Tumors Involving the Thyroid Gland: A Multi-Institutional Analysis of 21 Cases Diagnosed on Fine Needle Aspiration (FNA)

K Hoo Kim, J Gaitor, MD Reid. Louisiana State University HSC-Shreveport, Shreveport, LA; Georgia State University, Atlanta, GA; Emory University School of Medicine, Atlanta, GA.

**Background:** While FNA is an established tool in the diagnosis of primary thyroid nodules/tumors (PTNTs), its role in the diagnosis of secondary thyroid neoplasms (STNs) is not. This is because such tumors rarely involve the thyroid and are even less frequently diagnosed on FNA. Their radiologic appearance and cytopathology may simulate PTNTs leading to misdiagnosis and inappropriate management. We examined the clinical and cytopathologic features of STNs diagnosed on FNA, and present the largest series in the literature.

**Design:** A retrospective review of the pathology departments' archives (1985-2012) yielded 21 STNs from 9,700 thyroid FNAs. Pertinent clinical, cytologic and ancillary studies were reviewed. All primary thyroid lymphomas (LYMs) were excluded.

**Results:** Of 9,700 FNAs, 21 STNs were found, from 5 males and 16 females, ranging from 32-85 years. Tumors were right (n=11, 52%), left (n=5, 24%), bilateral (n=2, 10%) and NOS (n=14%); size was 1.3-7.0cm (9 cases) and unknown in 12. Cytologic results are shown in Table 1.

Table 1. Site of Origin and Type of Secondary Thyroid Tumor

Primary Tumor	Tumor Type	Number	Percentage
Kidney (n=5)	RCC	4	19
	Renal carcinoid	1	4.76
Lymphoma (n=5)	Follicular lymphoma	2	9.5
	Diffuse large B-cell lymphoma	1	4.76
	CLL/SLL	1	4.76
	T-cell lymphoma	1	4.76
Head & Neck (n=4)	Squamous carcinoma	4	19
Soft tissue (n=2)	Pleomorphic sarcoma	1	4.76
	Malignant fibrous histiocytoma	1	4.76
Breast (1)	Ductal adenocarcinoma	1	4.76
? Skin (1)	Melanoma	1	4.76
Colon (1)	Adenocarcinoma	1	4.76
Endometrial (1)	Serous carcinoma, high-grade	1	4.76
Lung (1)	Adenosquamous carcinoma	1	4.76
Total		21	100%

CLL/SLL, chronic lymphocytic leukemia/small lymphocytic lymphoma, RCC, renal cell carcinoma.

History of prior cancer was known in 15 (72%) cases and had metastasized 3 weeks-20 years after diagnosis. Primary malignancy was diagnosed concurrently in 3 (14%) LYMs, and was unknown in 3 other STNs (14%). Thyroidectomy was performed in 4 cases (2 RCC, 1 breast and 1 squamous carcinoma).

**Conclusions:** STNs are extremely rare tumors which despite highly variable cytology can be accurately diagnosed on FNA. Most are lymphomas followed by RCC. They are more common in women and may develop concomitantly or many years after initial diagnosis. Prior history of malignancy and a high index of suspicion are therefore critical for appropriate workup, accurate diagnosis and prevention of unnecessary surgery in these tumors.

#### 419 SOX10: A Novel Marker with High Sensitivity and Specificity for Diagnosis of Melanoma in Cytology Specimens

*N Hosseini, V Dube, J Wong, S Raphael, N Ismail, Z Ghorab.* Sunnybrook Health Sciences Centre, Toronto, ON, Canada.

**Background:** SOX10 has been recently proven of diagnostic value for melanoma in histology specimens. Differentiating melanoma from its mimics can be challenging in cytologic preparations, and S100, a sensitive marker with limited specificity, can become falsely negative in alcohol-fixed cytology specimens. The need for a more sensitive marker which can potentially substitute S100 has prompted us to evaluate the diagnostic usefulness of SOX10 for melanoma in cytologic specimens.

**Design:** 72 cytology specimens (70 FNA and two effusions) with established diagnosis of melanoma were evaluated for the following immunostains: SOX10 (A-2, Santa Cruz Biotech, Santa Cruz, CA), S100, HMB45 and Melan A (4C4, HMB45, A103 respectively) (Ventana Medical Systems, Tucson, AZ, USA). Based on the percentage of neoplastic cells showing immunoreactivity for each of these markers, cases were classified into 5 semi-quantitative categories: negative, 1-25%, 25-50%, 50-75% and 75-100%. Furthermore, we evaluated SOX10 in a control group composed of 34 melanoma mimics (24 FNAs and 11 effusions) including: 7 lymphomas, 7 adenocarcinomas, 5 squamous cell carcinomas, 3 neuroendocrine tumors, 2 mesotheliomas, 2 small cell carcinomas, 1 hepatocellular carcinoma, 1 schwannoma, 1 urothelial carcinoma, 1 GIST, 1 angiosarcoma, 1 high grade sarcoma, 1 poorly differentiated carcinoma and 1 Merkel cell carcinoma.

**Results:** 71/72 melanoma cases were positive for SOX10. Among the positive cases, 68/71 showed positivity in >50% of cells. Six melanoma cases (including one desmoplastic melanoma) showed immunoreactivity only to SOX10 and were negative for all the other melanoma markers. Among the control group, only one melanoma mimic (schwannoma) was positive for SOX10. SOX10 sensitivity and specificity were 98.61% and 97.06%, respectively.

Melanoma Immunomarkers in Cytologic Specimens of Melanoma

Antibody	Immunostaining (%)	Melanoma (n)	Positivity/Negativity, n/total (%)
SOX10	75-100	59	Positive, 71/72 (98.7)
	50-75	9	
	25-50	1	
	1-25	2	
	<1	1	
S100	75-100	2	Positive, 27/72 (37.5)
	50-75	2	
	25-50	6	
	1-25	17	
	<1	45	
Melan A	75-100	30	Positive, 63/72 (87.5)
	50-75	12	
	25-50	10	
	1-25	11	
	<1	9	
HMB45	75-100	43	Positive, 62/72 (86.1)
	50-75	3	
	25-50	7	
	1-25	9	
	<1	10	

**Conclusions:** To the best of our knowledge this is the first study evaluating SOX10 in cytologic specimens of melanoma. We found SOX10 to be a highly sensitive and specific immunomarker for the cytological diagnosis of melanoma. This is particularly important considering the limitations of S100 in alcohol fixed specimens.

#### 420 Value of Quantitative Cytomorphologic Features in Distinguishing Nodular Hyperplasia from Neoplastic Lesions in Fine Needle Aspiration Biopsies of the Thyroid

*JB Hudson, BT Collins, JF Wang.* Washington University School of Medicine, Saint Louis, MO.

**Background:** Follicular neoplasm (FN) is a category for thyroid fine needle aspirations (FNAs) intended to identify follicular carcinomas (FCs). A proportion will be classified as nodular hyperplasia on thyroidectomy. The aim of this study is to examine FNA biopsies categorized as FN and determine which cytomorphologic features are predictive of nodular hyperplasia (NH).

**Design:** The pathology database was searched for thyroid FNAs from 2010 to 2013. Thyroid FNAs classified as FN with surgical excisions were chosen. These were re-reviewed for colloid (qualitative and quantitative), number of micro- and macro follicles, and qualitative assessment of nuclear crowding. The surgical resection diagnosis was reviewed. Student's t-tests were used for statistical analyses and a p value of <0.05 was considered significant.

**Results:** 83 cases qualified and 32/83 cases (39%) were non-neoplastic thyroid lesions (29 NH, 1 biopsy site changes, 1 Grave's disease, 1 Hashimoto's thyroiditis), 3/83 (4%) were hypercellular parathyroid, 20/83 (24%) were follicular adenoma (FA) or Hurthle cell adenoma (HCA), 8/83 (10%) were FC, 17/83 (20%) were papillary thyroid carcinoma (PTC), 2 (3%) were poorly differentiated carcinomas and 1 was a hyalinizing trabecular carcinoma. Of the 52 benign thyroid nodules, 16 (30%) had incidental papillary microcarcinomas. Of the morphologic features examined in these lesions, only the total number of follicular groups (combined microfollicles/macro follicles) was significantly different between NH and neoplastic lesions. On average, the NH cases had 223 follicular groups (median number of 140), while the neoplasms had an average of 339 (median number of 300) (p=0.007). The degree of nuclear crowding was significantly different between benign and malignant lesions (p<0.0003), but not between FA and NH groups. There was no difference in colloid between either the neoplasms and NH or between benign and malignant lesions. The percentage of microfollicles was not significantly different between NH and the neoplasms.

**Conclusions:** The findings show that the amount of colloid and percentage of microfollicular groups are not helpful in predicting which lesions classified as FN will be NH on resection. Nuclear crowding can help distinguish between benign and malignant lesions. Quantification of follicular groups shows that neoplasms are significantly more cellular in comparison to NH and this degree of cellularity is a helpful feature for distinguishing NH from neoplastic lesions.

#### 421 Morphologic Feature Score: A Diagnostic Approach for Pancreatic Cytology

*BM Huffman, M Esebu, BL Witt, BE Chadwick, RJ Schmidt, LJ Layfield.* University of Missouri, Columbia, MO; University of Utah and ARUP Laboratories, Salt Lake City, UT.

**Background:** EUS-FNA has become the predominate method to obtain a tissue diagnosis for pancreatic lesions. The technique has excellent specificity and acceptable sensitivity but criteria for the diagnosis of ductal adenocarcinoma remain incompletely described.

**Design:** We searched the cytology files of the University of Missouri and the University of Utah for all EUS-FNAs of the pancreas with either histologic or two years clinical follow-up. A training set of fifty-seven cases was obtained from the University of Missouri and was independently evaluated by three cytopathologists. A separate validation set of 119 cases from the University of Utah was subsequently reviewed by the cytopathologists. Sixteen diagnostic features were coded as present or absent. Final diagnoses were classified as benign or malignant with "atypical" classified as benign and "suspicious" classified as malignant. Agreement was analyzed using both absolute agreement and Kappa statistic. Discriminatory power of diagnostic features was evaluated comparing odds ratios, receiver operating characteristic analysis (ROC) and recursive partitioning. A scoring model was developed using the training set and subsequently tested on the validation set.

**Results:** Sixteen diagnostic features were evaluated using the training cases. Average absolute agreement in the training set was 72%. Anisonucleosis, nuclear crowding, macronucleoli, single atypical epithelial cells and mucinous metaplasia had the highest inter-rater reliability. Statistical analysis showed that anisonucleosis, nuclear membrane irregularity, single atypical epithelial cells, nuclear enlargement, macronucleoli and mucinous metaplasia had the greatest discriminatory power. A scoring model was developed with four features (score= anisonucleosis + macronucleoli + single atypical epithelial cells+ mucinous metaplasia) each graded as "0" or "1" which gave a discriminatory power (area under receiver operator curve) of 0.88. The scoring model was applied to the validation data. The discriminatory power of the scoring model for the validation set was 0.93. The model demonstrated better discrimination for the validation set than the training set.

**Conclusions:** A scoring model based on anisonucleosis, macronucleoli, single atypical epithelial cells and mucinous metaplasia gives excellent discrimination between benign and malignant with the area under ROC curve of 0.93.

#### 422 Cell Block p16 Immunohistochemistry in Metastatic Oropharyngeal Squamous Cell Carcinoma

JB Jalaly, C Bernadt, J Lewis. Washington University, Saint Louis, MO.

**Background:** Human papillomavirus (HPV)- related oropharyngeal squamous cell carcinoma (SCC) is a biologically unique form of carcinoma that is important to identify for prognosis, patient counseling, and treatment. Immunohistochemistry (IHC) for p16 is commonly used as a surrogate marker for transcriptionally-active high risk HPV. The vast majority of HPV-related oropharyngeal SCCs demonstrate strong and diffuse p16 staining. In the minority of cases where p16 staining is not diffuse, a cut-off of 75% has been recommended since this level of staining has an excellent correlation with both HPV status and patient survival. To our knowledge, no study has correlated p16 IHC of cell blocks from fine needle aspirations (FNAs) with surgical pathology specimens of HPV-related oropharyngeal SCC.

**Design:** All patients with an established diagnosis of oropharyngeal SCC who also had an FNA demonstrating metastatic SCC were identified over a 5 year period (2008-2012) from the pathology databases of Washington University in St. Louis. The level of positive p16 staining (strong nuclear and cytoplasmic staining) was estimated in 5% increments for both the FNA cell blocks and separately for surgical pathology specimens.

**Results:** A total of 102 patients with FNA confirmed metastatic oropharyngeal SCC were identified. A cell block with diagnostic material for p16 IHC was available for 35 cases. The surgical pathology specimen of all 35 cases demonstrated positive p16 IHC staining. Although the FNA cell blocks showed a high correlation (97%) with the surgical pathology specimens, the proportion of positive staining is distinctly different between the FNA cell blocks and the surgical pathology specimens. Whereas partial p16 staining is seen only in ~5% of surgical pathology specimens, partial p16 staining was seen in 94% of FNA specimens (median 65%, range 15-100%). Only one FNA cell block had diffuse (100%) staining. All cases had at least one focus of clustered positive cells.

**Conclusions:** There is excellent correlation (97%) between p16 IHC on oropharyngeal SCCs in FNA cell blocks and surgical pathology specimens; however, there is greater variation in the proportion of p16 positive staining of FNA cell blocks. The recommended threshold (75% positive staining) for surgical pathology specimens would yield too many false negatives when applied to FNA cell blocks. Although this study did not have enough cases to define a new threshold for FNA cell blocks, p16 positive staining in as few as 15% of cells and with a focal confluent pattern did correlate with positive staining on the surgical pathology specimens.

#### 423 The Relationship of Molecular Alterations and Clinical Findings to Cytologic Atypia in FNA of Pancreatic Cysts

X Jianwu, B Corcoran, S Finkelstein, JF Silverman. Allegheny General Hospital, Pittsburgh, PA; RedPath Integrated Pathology, Inc, Pittsburgh, PA.

**Background:** Cytologic atypia is critical in the diagnostic work-up of the aspirated pancreatic cyst (PC) fluid. However, assessment of atypia can be challenging when the cellularity is low and/or the cytologic features overlap between reactive versus neoplastic atypia. We assessed the utility of ancillary molecular testing of the PC aspirate to better define the significance of atypia.

**Design:** A consecutive series of 608 cases of PC FNAs were retrospectively evaluated. EUS findings accessed as potentially aggressive included PC size > 3 cm, duct dilation > 1 cm, solid component formation and CEA level over 1000 ng/ml. Molecular analysis targeted 3 abnormalities associated with aggressive disease: 1) high DNA concentration, 2) oncogene point mutations of KRAS/GNAS and 3) the presence of multiple tumor suppressor genes loss assessed by loss of heterozygosity (LOH) using a panel of 24 microsatellite markers. PC were classified as high risk by correlating molecular and clinical findings with epithelial cellularity and atypia.

**Results:** The relationship of clinical and molecular features to the four test groups is shown in the Table. The incidence of high DNA concentration, KRAS mutation, multiple LOH mutations and "high risk" are statistically significant higher among the atypia group compared to the no atypia group (P < 0.05, Chi Square test). Acellular specimens showed findings similar to no atypia group without statistical significance except when the cyst size ≥ 3cm (P < 0.05, Chi Square); however, both cohorts contained a subset of PCs with potentially aggressive disease in the acellular and no atypia groups.

Table

	Acellular %	No Atypia %	Atypia %	Positive Control %
Cyst size ≥ 3cm	19	9	21	50
Duct dilation ≥ 1cm	3	2	3	0
Solid component formation	11	10	21	50
CEA level 192-1000 ng/ml	22	15	28	0
CEA level >1000 ng/ml	21	29	38	63
High DNA concentration	17	21	38	75
KRAS mutation	20	28	52	75
GNAS mutation	3	7	0	0
Multiple LOH mutations	4	7	24	50
"High Risk" by integrated clin/mol	11	12	45	88

The numbers of acellular, no atypia, atypia and positive control cases are 456, 123, 29 and 8, respectively

**Conclusions:** 1) As expected, cytologic atypia identifies patients having high risk pancreatic disease; 2) However, the lack of cytologic atypia does not exclude aggressive biology which can also be present in cytologic specimens lacking epithelial cells or showing no atypia; 3) Molecular testing complements cytology in the work-up of PC and identifies patients with potentially aggressive disease with and without atypia.

#### 424 Assessment of Anal Cytology Screening in HIV-Positive Patients in an Inner-City Hospital

G Johnson, S Seydafkan, T Guillory, S Ehdavand, M Mosunjac. Emory University, Atlanta, GA.

**Background:** Anal carcinoma is highly prevalent in HIV+ patients, with rates rising due to persistent immunosuppression & long term survival with HAART therapy. There are no guidelines for anal carcinoma screening in the US. In this study we assessed the value of cytology screening & HPV testing in an HIV+ population at an inner-city hospital by correlating anal cytology specimens (ACS) with the histology findings on anal biopsies.

**Design:** Retrospective review of 174 patients with 209 ACS & anal biopsy was evaluated over 10 years (2003-2013). Demographic data for age, gender, HIV status, HPV-status, cytologic & histologic results were collected & analyzed.

**Results:** 209 ACS & anal biopsies were collected from 171 men & 3 women with a median age of 44 years (range 24-64). At the time of first ACS, 97% (n=168) of patients were HIV+, 43% (73) of those diagnosed with AIDS, & only 3% (6) unknown status. Of the 174 patients, 166 (95%) had abnormal ACS. Of 53 ASCUS cases 42 were tested for HPV, & 81% tested positive. The most commonly diagnosed lesion on ASC was LSIL (54%; n=113) followed by ASCUS (25%; 53) & HSIL (10%; 22). There were 8 (5%) NILM & 1 SCC on ASC. The lesion most diagnosed on biopsy was HSIL (52%; n=108) & LSIL (34%; 71). Correlation was confirmed by biopsy in 43% of LSIL & 16% of HSIL ACS. ACS had 97% sensitivity in detecting anal dysplasia & carcinoma with PPV of 92%.

Table 1. Anal Cytology Results with Corresponding Histologic Diagnosis (n= cases)

Histology Results	Cytology Results							Total Histology Results
	NILM	ASCUS	ASCH	LSIL	HSIL	IC	Unsat	
NILM	2	8	0	7	1	0	0	18
LSIL	2	16	1	48	1	0	3	71
HSIL	4	23	7	55	18	0	1	108
IC	0	1	0	0	2	0	0	3
Unsat	0	5	0	3	0	1	0	9
Total cytology results	8	53	8	113	22	1	4	209

Key: IC-Invasive carcinoma, Unsat-Unsatisfactory

**Conclusions:** In this study, most patients were HIV+ men with a high prevalence of atypical ACS. The majority displayed HSIL on histology, regardless of ACS severity. These data show that in contrast to cervical screening, it may be prudent to perform anoscopy & biopsy in all patients with atypical ACS. Furthermore, the diagnostic ACS criteria need to be more sensitive. Also, HPV testing may not be needed in this population, as almost all are HPV+. This study is useful in confirming that anal screening with cytology & biopsy in high-risk populations detects a large burden of high-grade lesions. Further study is warranted to develop national screening guidelines.

#### 425 The Clinical and Diagnostic Impact of Using BSRTC Diagnostic Criteria on FNA Diagnosis of Thyroid Nodules

S Kantola, N Virani, C Haus, J Hipp, X Jing. The University of Michigan, Ann Arbor, MI.

**Background:** FNA of thyroid nodules has been a growing practice within our institution and we have implemented BSRTC diagnostic criteria since January 2011. This study was conducted to investigate the impact of using BSRTC diagnostic criteria on FNA diagnosis and clinical management of thyroid nodules.

**Design:** We compared thyroid FNAs performed 2.5 years prior to and 2.5 years after implementing BSRTC diagnostic criteria. The parameters including non-diagnostic rate, distribution of diagnostic categories, rate of surgical follow-up along with rate of cyto-histologic concordance were calculated. Statistical analysis will be performed later.

**Results:** Upon using BSRTC diagnostic criteria for FNA diagnosis of thyroid nodule:

- 1) There was a slight change in distribution of all diagnostic categories.
- 2) The rate of surgical treatment was markedly reduced for FLUS category (42.4% vs. 61.5%).
- 3) The rate of cyto-histologic concordance was improved for both FLUS (44.8% vs. 39.6%) and FN/SFN (69.4% vs. 58.4%) categories.
- 4) Benign category showed a reduced rate of cyto-histologic concordance (75.9% vs. 88.9%) which most likely resulted from failure to diagnose papillary microcarcinoma by FNA.
- 5) There was no marked change in overall rate of cyto-histologic concordance (75.4% vs. 77.4%).

Parameters for the Pre-BSRTC Period

Cytologic Diagnosis	No. of Specimen (%)	No. of Surgical Follow-up (%)	Cyto-histologic Concordance (%)
Non-diagnostic	358 (19.9)	71 (19.8)	- - -
Benign	1171 (65.3)	162 (13.8)	144 (88.9)
FLUS	78 (4.3)	48 (61.5)	19 (39.6)*
FN/SFN	101 (5.6)	77 (76.2)	45 (58.4)
SFM	20 (1.2)	17 (85.0)	14 (82.4)
Malignant	66 (3.7)	59 (89.4)	59 (100)
Total	1794	434 (24.2)	281 (77.4)**

FLUS: follicular lesion of undetermined significance; FN/SFN: positive or suspicious for follicular neoplasm; SFM: suspicious for malignancy; \*Histologically confirmed neoplasm/malignancy; \*\*Excluding non-diagnostic.

Parameters for the Post-BSRTC Period

Cytologic Diagnosis	No. of Specimen (%)	No. of Surgical Follow-up (%)	Cyto-histologic Concordance (%)
Non-diagnostic	341 (15.8)	62 (18.2)	- - -
Benign	1496 (69.2)	112 (7.5)	85 (75.9)
FLUS	158 (7.3)	67 (42.4)	30 (44.8)*
FN/SFN	46 (2.1)	36 (78.2)	25 (69.4)
SFM	15 (0.7)	12 (80.0)	9 (75)
Malignant	105 (4.9)	95 (90.5)	94 (98.9)
Total	2161 (100)	384 (17.8)	243 (75.4)**

Abbreviations are the same as pre-BSRTC period

**Conclusions:** Adhering to BSRTC diagnostic criteria yields a higher prediction of histologically confirmed neoplasia for both FLUS and FN/SFN categories despite the lack of change in overall rate of cyto-histologic concordance in all diagnostic categories.

#### 426 Vaginal Cytology in Hysterectomized Women with Endometrial Carcinoma, a Large Cohort Study from an Academic Women Center

*A Karunamurthy, S Jain, C Zhao.* University of Pittsburgh Medical Center, Pittsburgh, PA.

**Background:** Women with prior cervical cancers are at an increased risk for primary vaginal cancers, but similar association in endometrial cancer patients is largely unknown. Unlike women who have history of cervical intraepithelial neoplasia grade 2+ (CIN2+) where vaginal cuff cytology (VCC) is recommended, guidelines on VCC for women hysterectomized for endometrial carcinomas are not clear and definite. We aimed to study the risk of women with endometrial carcinoma for primary vaginal cancers and the utility of VCC in women hysterectomized for endometrial carcinomas. **Design:** Clinico-pathological data of 607 women hysterectomized for endometrial carcinomas with 5 to 7 year of available follow up period were retrospectively studied. **Results:** Of the total 607 patients, mean age of 62.4 years (range 27-91 years), who underwent total hysterectomy for endometrial carcinomas, 186 women (31%) did not have any surgical or cytological follow up. The hysterectomy specimens included 490 (80%) endometrioid carcinomas, 74 (12%) serous papillary carcinomas, 24 (4%) clear cell carcinomas, 10 (2%) malignant mixed mullerian tumors and 9 (2%) other types of carcinomas. 421 patients were followed up with vaginal histological and/or cytological results with a mean follow-up period of 41 months (range: 3 to 80 months) and the number of follow up Pap smears visits averaged 7.3 times (range: 1 to 16 times). Follow-up histological and cytological results were summarized in Table 1. Recurrent endometrial adenocarcinoma in vagina was found in 12 (3%) patients, at a mean interval of 16 months (range 2 to 50 months). VAIN1/LSIL and VAIN2/3/HSIL were detected in 9 (2%) and 3 (1%) patients, respectively. 8 out of 147 (5.4%) women with HPV testing were HPV-positive.

	CARCINOMA		VAIN1 & LSIL	VAIN2/3 & HSIL	ATYPICAL SQUAMOUS LESION	NEGATIVE
	PRIMARY VAGINAL	RECURRENT ENDOMETRIAL				
<b>FOLLOW UP</b>						
<b>BIOPSY ONLY (N=8)</b>	0	6	0	0	0	2
<b>BIOPSY (WITH PRIOR CYTOLOGY) (N=47)</b>	0	6	1	6	0	34
<b>CYTOLOGY ONLY (N=366)</b>	0	0	2	3	76	285
<b>TOTAL (N=421)</b>	0	12 (3%)	3 (1%)	9 (2%)	76 (18%)	321 (76%)

**Conclusions:** Vaginal screening cytology for women with endometrial carcinoma after hysterectomy serves two functions including surveillance of endometrial carcinoma recurrences and the screening of vaginal dysplasia or cancer. The majority of recurrences occur within three years after hysterectomy. No increased incidence of high-grade dysplasia or primary vaginal cancer was noted in these women. Our data suggest that these women should not be regularly screened after three years of hysterectomy. HPV testing is not necessary for these women.

#### 427 Cytologic Features of Gastric Type Adenocarcinoma of the Uterine Cervix

*F Kawakami, Y Mikami, T Sudo, K Fujiwara, T Hirose, T Itoh.* Kobe University Hospital, Kobe, Hyogo, Japan; Kyoto University Hospital, Kyoto, Japan; Hyogo Cancer Center, Akashi, Hyogo, Japan.

**Background:** Gastric type mucinous adenocarcinoma (GAS) of the uterine cervix is a distinct entity because of its aggressive clinical course. Morphologically, GAS is defined as mucinous carcinoma showing (i) clear and/or pale eosinophilic and (ii) voluminous cytoplasm, and (iii) distinct cell borders. However, its cytological characteristics have been poorly recognized. The aim of this study is to describe the cytologic findings of GAS in detail.

**Design:** We reviewed 14 cases of pre-treatment cervical and endometrial smears of the histologically diagnosed GAS which were retrieved from the pathology file. Total numbers of the diagnostic slides sufficient for evaluation were 26. All slides were smeared by conventional method. We included 9 control cases of usual type adenocarcinoma of the cervix.

**Results:** Age of the patients of GAS ranged from 35 to 68 years (mean: 56.5 years). Follow-up period of them were 3 to 46 months (mean: 18.3 months). Seven patients were relapsed during the follow-up period and 3 of them were died of the disease. According to the original cytology reports, 11 cases were diagnosed as adenocarcinoma and 3 cases were categorized as AGC. Monolayered and honeycomb sheets were observed in 78.6% (11/14) of GASs, and were prominent in 7 cases. Papillary pattern, resulting in 3-D clusters, was more prominent in usual type adenocarcinoma compared to GAS. Vacuolar and/or foamy cytoplasm was seen in 71.4% (10/14) of GAS, whereas was only rarely seen in usual type (1/9). Marked intracytoplasmic neutrophil entrapment was common in cases of GAS (7/14) compared to usual type (1/9). Intracytoplasmic mucin was present in 8 GASs. Nuclear vesicular pattern hyperchromasia was seen in 8 cases of GAS. On the other hand, nuclei of all 9 usual type adenocarcinoma showed homogenous moderate to high degree hyperchromasia. Distinct nucleoli were seen in 9 cases of GASs and were prominent in 5 cases. However, nucleoli were rather obscure finding in usual type.

**Conclusions:** The characteristic cytological findings of GAS are: (i) monolayered and honeycomb sheets, (ii) vacuolar and/or foamy cytoplasm, (iii) intracytoplasmic neutrophil entrapment, and (iv) vesicular pattern hyperchromatic nuclei with prominent nucleoli. Based on these characteristic cytologic features, GAS may be suggested on cytology.

#### 428 Losing Your Touch? Depletion of Core Needle Biopsies by Touch Preparations: Ex-Vivo Modeling of an Adverse Consequence of On-Site Assessment

*S Kazi, J Yao, S Dogan, CS Sigel, P Andrade, O Lin, M Silk, T Silk, JC Durack, SB Solomon, DS Klimstra, N Rekhtman.* Memorial Sloan-Kettering Cancer Center, New York, NY.

**Background:** Touch preparations (TP) of core needle biopsies (CNB) are becoming widely used for on-site assessment of CNB adequacy. We noticed in our clinical practice that in a subset of cases, TPs result in substantial depletion of CNB cellularity. Here we investigate this phenomenon ex-vivo.

**Design:** We performed 18 ex-vivo CNBs on 3 nephrectomy specimens for renal cortical neoplasms using 18-gauge side-notch needles. From each nephrectomy, 3 CNBs were obtained from tumors and 3 from non-tumor tissue. Each CNB was subjected to one of three TP methods: imprint, 1-cm drag or 2-cm drag. Post-TP CNBs were formalin-fixed and paraffin-embedded, and CNB size was measured on H&E-stained sections. Diff-Quick-stained TPs were blindly reviewed by 5 cytopathologists/cytotechnologists. DNA content in 12 TPs and corresponding post-TP CNBs was quantified by Qubit.

**Results:** Average DNA content of imprint, 1-cm and 2-cm TPs was 1.5ug (range 0.5-4ug), 2.1ug (range 0.5-5ug) and 2.8ug (range 1.6-6.6ug), respectively, whereas average DNA content of corresponding post-TP CNBs was 8.5ug (range 1.9-22.1ug), 3.5ug (range 1.6-5.9ug) and 3.2ug (range 2.3-5.6ug), respectively. Increasingly vigorous TPs of 1-cm and 2-cm resulted in the reduction of the average size of CNBs by 25% and 40%, respectively, compared to the size of CNBs subjected to imprints. Accuracy of cytologic assessment of TPs was not inferior for imprints compared to more vigorous TPs.

**Conclusions:** Touch preparations contain a substantial fraction of CNB DNA content. More vigorous TPs result in marked depletion of cellularity from CNBs, as measured by the reduction in CNB size and DNA content. Given the growing importance of multimodality (immunohistochemical, molecular, and cytogenetic) ancillary studies, for which a single TP has limited or no utility, preservation of diagnostic material in CNBs is essential. We suggest that if TP adequacy must be performed, that forceful manipulation of CNBs is avoided, and that additional "untouched" CNB and/or fine needle aspirate are procured whenever clinically feasible. This study suggests that imprints are a less destructive method of CNB assessment, that is suitable for cytologic interpretation, but further in-vivo validation is warranted.

#### 429 Fine Needle Aspiration of Granulomas: A View of the World beyond Infectious Etiologies

*ME Keeney, MP Gailey, CS Jensen.* University of Iowa Hospitals and Clinics, Iowa City, IA.

**Background:** Granulomas can be readily identified by fine needle aspiration (FNA) and are associated with a wide variety of infectious and non-infectious etiologies. Reports and series of granulomas identified on FNA have predominantly focused on infectious entities and the accurate identification of organisms. With the advent of endobronchial ultrasound (EBUS) guidance, we have noted a marked increase in the frequency of cytologic identification of granulomas by FNA at pulmonary sites; however, granulomas are commonly identified by FNA at sites outside the lung and mediastinum. Our goal was to characterize the spectrum of diseases in patients with granulomas identified by FNA and to compare the character of FNAs and relative frequency of diagnoses at pulmonary and nonpulmonary sites.

**Design:** A computer search identified all cytology cases with granulomas identified since 2000. Cases were reviewed for the presence/absence of necrosis, fungal or other organisms and the character of the granulomas. Medical records for all patients were reviewed for demographic, clinical, histologic and laboratory data, as well as the final clinical diagnosis based on last patient clinical contact.

**Results:** 338 cases containing granulomas were identified. See tables 1 and 2:

Case Distribution Based on Granuloma Type

	Pulmonary Cases	Non-pulmonary cases
Total	221	117
Female	125	75
Male	96	42
NG on FNA	51	17
Infectious, n (%)	49 (96)	9 (53)
Indeterminate, n (%)	2 (4)	8 (47)
NNG on FNA	170	100
Non-infectious, n (%)	78 (46)	32 (32)
Infectious, n (%)	54 (32)	23 (23)
Indeterminate, n (%)	38 (22)	55 (55)

Final Clinical Diagnosis of Cases

Diagnosis	Pulmonary Cases, n (%)	Non-pulmonary Cases, n (%)
Sarcoidosis	76 (34)	19 (16)
Non-infectious, other	1 (0.5)	12 (10)
Histoplasmosis	94 (43)	9 (8)
Mycobacterium	2 (1)	6 (5)
Cat scratch disease	0 (0)	5 (4)
Fungus, other	7 (3)	2 (2)
Infectious, other	0 (0)	8 (7)
Malignancy	1 (0.5)	1 (1)
Indeterminate	40 (18)	55 (47)

**Conclusions:** 1. Granulomas are frequently identified by FNA at both pulmonary and nonpulmonary sites.  
2. Non-necrotizing granulomas (NNG) are far more common than NG at both pulmonary and nonpulmonary sites.  
3. Although sarcoidosis is the most common cause of NNG at pulmonary sites, infectious etiologies were more common than expected.  
4. An etiology can be identified in the majority of cases; however, a significant percentage, especially of non-pulmonary granulomas, remain indeterminate as to etiology.  
5. Further study is necessary to determine if morphologic or clinical features can better delineate etiology or reduce the percentage of indeterminate cases.

#### 430 Detection of Elevated Levels of Periostin as a Potential Biomarker in Airway Fluid (Bronchoalveolar Lavage) and Tumor Tissue Using ELISA and IHC Assays from Lung Cancer Patients

AH Khararjian, MH Ao, E Gabrielson, F Askin, H Zhang, QK Li. The Johns Hopkins Medical Institutions, Baltimore, MD.

**Background:** Periostin is a newly identified, unique, and important extracellular matrix protein involved in cell development and adhesion. Its elevated expression has been linked to advanced tumor stage, large tumor size, and poor prognosis. Our group recently found periostin to be overexpressed in lung cancer tissue using quantitative glycoproteomics and mass spectrometry. In the present study, we evaluated the expression of periostin in airway fluid (bronchoalveolar lavage (BAL)) of lung cancer patients, and further correlated its expression with lung tumor tissue and tumor-matched normal lung tissue using tumor microarray (TMA) and immunohistochemistry (IHC). The purpose of this study was to evaluate the potential utility of periostin in the diagnosis of lung cancers, particularly in patients with small lung nodules.

**Design:** 45 BAL specimens were collected during bronchoscopic procedures, including 19 adenocarcinomas (ADCs), 12 squamous cell carcinomas (SQCCs), 7 small cell lung carcinomas (SCCs), and 7 benign BALs. The lung cancer TMAs (0.6 mm in diameter, 3-4 cores per case) were constructed using surgically resected specimens retrieved from our department's archive. Represented on the TMA were 60 cases of ADC, 91 cases of SQCC, and tumor-matched normal lung tissue. Periostin levels in BAL and tumor tissue were determined by ELISA and IHC assays, respectively. Rabbit polyclonal antihuman periostin was used. For IHC, levels of periostin were semiquantitatively scored using a four tier system (0-3+).

**Results:** The mean BAL periostin levels in benign tissue, ADCs, SQCCs, and SCCs were  $255 \pm 104$  (mean  $\pm$  SE),  $4,002 \pm 218$ ,  $3,496 \pm 1,765$ , and  $1,772 \pm 1,119$  ng/g. These values represent a 15.6, 13.7, and 6.9 fold increase for periostin levels in ADCs, SQCCs, and SCCs when compared to benign BALs. The overall expression of periostin in lung tumor tissues such as ADCs and SQCCs was statistically significantly higher than that of non-tumor controls ( $p < 0.05$ ).

**Conclusions:** Our data demonstrates that periostin is expressed in tumor tissues and its level can be detected in airway fluid specimens. Furthermore, levels of periostin are significantly increased in different types of primary lung tumors. The findings in this study suggest possible clinical utility of periostin as a potential tumor marker in BAL specimens to increase the detection specificity of lung cancers when small lung nodules are biopsied and tumor tissue is limited.

#### 431 Rapid On-Site Evaluation (ROSE) of Touch Preparations from CT-Guided Bone Biopsies: Retrospective Evaluation Reveals That Cases Accompanied by ROSE Have a Higher Diagnostic Yield

BK Kim, NC Mooney, H Mulcahy, W Cohen, V Hawkins, HM Linden, SC Schmechel. University of Washington, Seattle, WA.

**Background:** ROSE of biopsy specimens may improve specimen adequacy rates. Prior reported experience of the utility of ROSE from bone biopsy touch preparations performed for possible primary or metastatic neoplasms is lacking. We postulated that onsite cytopathology for ROSE would improve the quality of clinical service by ensuring that bone biopsies adequately reflect the underlying disease, without oversampling the clinical/radiological lesion. We hypothesized that ROSE may reduce cost if fewer patients returned for bone re-biopsy after an initial inadequate/unsatisfactory (unsat) result.

**Design:** A retrospective study was performed to search pathology reports and corresponding medical charts for patients undergoing CT-guided bone biopsies for suspected primary or metastatic neoplasms, with or without ROSE, over a consecutive 13-year period. Cost was estimated based on Medicare reimbursement for ROSE, CT scan, bone biopsy, and pathology fees.

**Results:** 354 CT-guided bone biopsies were performed over a 13-year period: 262 with cytopathologist ROSE and 92 without ROSE. CT-guided bone biopsies accompanied by ROSE led to a lower percentage (6.5%) of unsat final diagnoses, versus those without ROSE (18.5%;  $p = 0.001$ ). Among touch preparation cases with ROSE, the percentage interpreted as adequate for neoplastic cells onsite was 59.2%, and a definitive final diagnosis was rendered in 100% of these cases (positive predictive value [PPV] 100%). Among the 40.8% of cases with ROSE for which no neoplastic features were seen on touch preparations, a definitive diagnosis was rendered in 84.1% (negative predictive value [NPV] 15.9%). ROSE increased cost by \$134.47 per case.

**Conclusions:** Our study suggests that ROSE performed at the time of CT-guided bone biopsy increases the rate of satisfactory diagnoses, with modestly increased costs per case. Finding no neoplastic features on site touch preparations was associated with low NPV, suggesting that radiologists were assured of target tissue acquisition despite unsat ROSE diagnoses. ROSE has the potential to expedite diagnosis, and reduce costs not measured in this study by averting further testing and delay in diagnosis.

#### 432 MIB-1 Proliferation Index of FNA Biopsies Correlates with Histological Grade on Resected Gastric GISTs

HM Ko, AD Polydorides, F Salem. Icahn School of Medicine at Mount Sinai, New York, NY.

**Background:** Endoscopic ultrasound guided fine needle aspiration biopsy (EUS-FNAB) is a useful tool in the primary diagnosis of gastrointestinal stromal tumors (GISTs), particularly during the decision for conservative or possibly neoadjuvant treatment. However, mitotic rate, an important prognostic indicator in these tumors, is difficult to assess on cytology specimens due to the limited material. MIB-1 proliferation index is a potentially useful adjunct, provided a representative sample of the tumor. We sought to examine the correlation between the proliferation index of gastric GISTs in EUS-FNAB cytology specimens with the final grading on the subsequent resections.

**Design:** Seventeen gastric GISTs diagnosed on EUS-FNAB with subsequent surgical resection were identified between 2004-2013. Sufficient cell block material was available for 13 of these cases which were evaluated by immunohistochemical staining for Ki-67 (percentage of tumor cells with positive staining). Prognostic data on the subsequent resections (size of the tumor and mitotic rate per 50 HPF) were reviewed. Data were analyzed by Fischer's exact test.

**Results:** The average MIB-1 proliferation index in the EUS-FNAB material was 4.08% (Range 0-20%). Of 3 cases with an index score  $> 5\%$ , 2 were higher grade GISTs on subsequent histology ( $> 5$  mitoses per 50 HPF). Conversely, all remaining 10 cases with a MIB-1 rate  $\leq 5\%$ , were of low malignant risk ( $\leq 5$  mitoses per 50 HPF and size  $< 5$  cm). Ki-67 staining  $> 5\%$  was significantly more prevalent in higher grade compared to lower grade GISTs ( $p = 0.0385$ ), yielding a sensitivity of 100% and a specificity of 91%.

**Conclusions:** MIB-1 proliferation index in EUS-FNAB specimens of gastric GISTs correlates well with the histological grade of the subsequent resections. In particular, a Ki-67 staining score of  $> 5\%$  confidently identifies lesions of higher malignant risk. MIB-1 proliferation index may be used as an adjunct in triaging gastric GISTs to treatment at the time of EUS-FNAB diagnosis with high specificity and sensitivity.

#### 433 Frequency of Discordance between Touch Preparations and Corresponding Lung Core Biopsies in Patients with Adenocarcinoma

EM Kurian, G Ewing. UT Southwestern Medical Center, Dallas, TX.

**Background:** On-site cytologic assessment of core biopsies has become routine practice to ensure specimen adequacy for diagnosis and for molecular testing. In our experience, it is possible to have cases with carcinomatous cells on touch preparation and a negative lung core biopsy. The frequency or cause of this discrepancy has not been previously described. As a quality assurance project, we retrospectively assess the frequency of negative lung core biopsies with touch preparations positive for adenocarcinoma.

**Design:** A retrospective search in the University of Texas Southwestern pathology database between October 2011-2013 for lung core biopsies with touch preparations and a diagnosis of adenocarcinoma identified 41 cases. Thirty-eight cases were available for review.

**Results:** The cohort included an age range of 29-90 years with 14 males and 24 females. The targeted lesions ranged in size from 0.8 cm to 4.4 cm with the average of 2.0 cm. Of the 38 cases, there were 4 (10.5%) cases with cytologic adenocarcinoma on the touch preparation and insufficient or no tissue for diagnosis on the corresponding core biopsies.

**Conclusions:** The frequency (11%) of cases having an inadequate core based on adequate touch preparations is higher than expected. While some cells are lost by aggressive touch preparation, the exact cause for the discrepancy is still not clear. These findings suggest that touch preparations should be limited; with additional cores submitted directly into formalin to ensure diagnostic cells are retained.

#### 434 Diagnostic Features and Subtyping of Papillary Renal Cell Carcinoma on Limited Biopsy Specimens

KA La Fortune, EB Stelow, RM Bhatti, HF Frierson, YD Mo, HP Cathro. University of Virginia Health System, Charlottesville, VA.

**Background:** Most studies have found that subtyping papillary renal cell carcinoma (PRCC) provides added prognostic information to Fuhrman nuclear grading (FNG). Type 1 PRCC with increased eosinophilic cytoplasm and both types of PRCC with oncocytic features are more difficult to subtype. We investigated whether accurate subtyping and grading of PRCC can be performed on limited biopsy specimens obtained by fine needle aspiration (FNA) or core needle biopsy (CNB).

**Design:** Eleven primary and 3 metastatic PRCC diagnosed on FNA or CNB and the corresponding surgical resections were reviewed by two cytopathologists (HPC and EBS) and two genitourinary (GU) pathologists (HPC and HFF), respectively. PRCC with oncocytic features were defined by abundant granular eosinophilic cytoplasm without consideration of nuclear characteristics. Fourteen cases from 1996 to 2013 were reviewed; 9 FNA cases (4 cases with a cell block preparation and 2 cases with a CNB), and 5 CNB cases. None of the cases demonstrated the cytologic features of translocation carcinomas.

**Results:** Cytologically, PRCC was characterized by papillae and small clusters of cells. Nuclei ranged from small and bland to pleomorphic with marked anisocytosis. Variably prominent nucleoli were better appreciated on FNA than CNB. Concordance was reached between GU pathologists on resections in 12/14 (86%) for subtyping, 10/14 (71%) for FNG, and 3/3 (100%) for tumors displaying oncocytic features. In the 2 cases for which concordance was not reached on subtyping, the resections demonstrated eosinophilic cytoplasm with hyalinized cores. Concordance between cytopathologists on FNA and CNB was 11/14 (79%) for subtyping, 4/14 (29%) for FNG, and 12/14 (86%) for the presence/absence of oncocytic features. Tumors with oncocytic features were accurately identified on FNA and CNB in 1/3 (33%) cases. Evaluation of limited biopsy and resection specimens by the same reviewer (HPC) demonstrated concordance in 11/14 (79%) cases for subtyping and 9/14 (64%) cases

for FNG. Evaluation of limited biopsy and resection specimens by different reviewers (EBS versus HPC, respectively) demonstrated concordance in 10/14 (71%) cases for subtyping and 3/14 (21%) cases for FNG.

**Conclusions:** Subtyping PRCC can be accurately performed on FNA and CNB specimens in the majority of cases. Intraobserver and interobserver variability is low for subtyping, but high for FNG when comparing limited biopsies to resections. Eosinophilic tumors confound subtyping and grading, even on surgical specimens. Finally, FNG is not reliable on limited biopsy material.

#### 435 Implications of a Suspicious AFIRMA® Test Result in Thyroid Fine Needle Aspiration Cytology

*RR Lastra, MR Pramick, CJ Cramer, VA LiVolsi, ZW Baloch.* Hospital of the University of Pennsylvania, Philadelphia, PA.

**Background:** Fine needle aspiration (FNA) biopsy is essential for the management of thyroid nodules. Up to 30% of cases are diagnosed as indeterminate for a significant lesion; including follicular lesion of undetermined significance (FLUS), follicular neoplasm (FN), and suspicious for malignancy. The AFIRMA® gene expression classifier (GEC) is a proprietary molecular test (Veracyte, Inc., South San Francisco, CA) for the preoperative classification of thyroid nodules with indeterminate FNA diagnoses. This study reviews our institutional experience with AFIRMA® GEC analysis for thyroid nodules diagnosed as indeterminate on FNA.

**Design:** A cohort of 95 cases of thyroid FNA with concomitant AFIRMA® testing was selected from our files (2011-2013). Information including demographics, ultrasound features, FNA diagnosis, AFIRMA® results and surgical follow-up (when available) was recorded.

**Results:** The cohort included 73 (77%) female and 22 (23%) male patients (ratio 3.3:1) (range 19-81 years). The average size of the thyroid nodule biopsied was 2.05 cm (range 0.8-7.0 cm). Cytologic diagnoses were FLUS in 46 (48%), FN in 16 (17%), follicular neoplasm with oncocytic features (FNOF) in 31 (33%) and unsatisfactory in 2 (2%) cases. AFIRMA® results were benign in 53 (56%) and suspicious in 42 (44%) cases. Surgical follow-up was available in 30 cases: 28 cases reported as suspicious and 2 as benign. Of the cases with suspicious AFIRMA® results and surgical follow up (28 cases), 15 (53%) were malignant (follicular variant of papillary thyroid carcinoma (FV-PTC) 12, classic PTC 1 and follicular carcinoma (FC) 2) and 13 (47%) were benign (follicular adenoma (FA) 3, Hurthle cell adenoma (HA) 8 and adenomatoid nodule (AN) 2). Of the FLUS cases with suspicious AFIRMA® and follow up (10 cases), 8 (80%) cases were malignant (6 FV-PTC, 1 classic PTC, 1 FC) and 2 (20%) cases were benign (1 HA, 1 AN). Of the FN cases with suspicious AFIRMA® and follow up (10 cases), 6 (60%) cases were malignant (all FV-PTC) and 4 (40%) were benign (3 FA, 1 AN). Of the FNOF cases with suspicious AFIRMA® results and surgical follow up (8 cases), 1 (12%) case was malignant (FC) and 7 (88%) were benign (all HA).

**Conclusions:** Our results show that the utility of AFIRMA® testing in cases diagnosed as FNOF is limited, since even with suspicious AFIRMA® results, these lesions are more likely to be benign. Conversely, a suspicious AFIRMA® result in cases diagnosed as either FN or FLUS has a good predictive value in diagnosing malignancy (80% & 60%, respectively).

#### 436 Cytotechnologist Screening of Fine Needle Aspiration Specimens: Impact on Turnaround Time and Diagnostic Accuracy

*LJ Layfield, M Eseba, BL Witt.* University of Missouri, Columbia, MO; University of Utah School of Medicine and ARUP Laboratories, Salt Lake City, UT.

**Background:** Fine-Needle Aspiration (FNA) is widely utilized due to its short turnaround time, diagnostic accuracy and low-cost. Controversy exists as to what role cytotechnologists should play in evaluation of FNAs. Some authorities believe all FNAs should be screened by cytotechnologists while others believe that cytotechnologist review is unnecessary.

**Design:** Sixty sequentially performed FNAs without initial review by cytotechnologists were selected from the files of the University of Utah, Department of Pathology. The slides were obtained along with the associated final diagnoses. The slides were reviewed by cytotechnologists given patient history and specimen site but were blinded to the initial pathologist's diagnoses. The initial cytopathologist's diagnoses and subsequent cytotechnologists' diagnoses were recorded and correlated. Turnaround times for these cases were calculated and compared with turnaround times in a second set of randomly selected FNAs where cytotechnologists had initially screened the cases.

**Results:** Correlation of initial cytopathologists' diagnoses with those of cytotechnologists revealed no instances where cytotechnologists identified diagnostically significant findings not noted by the original pathologist. Turnaround time for the FNAs reviewed only by a cytopathologist averaged 25.9 hours with a mode of 6 hours. Turnaround times for cases with initial cytotechnologist screening averaged 44.1 hours with a mode of 25 hours.

**Conclusions:** Pre-sign-out screening of FNA specimens by cytotechnologists does not appear to increase detection of cytologic abnormalities. Cytotechnologist screening does substantially increase turnaround time from a mean of 26 hours to approximately 44 hours. Such an extensive delay may reduce the overall clinical utility of the FNA technique.

#### 437 Malignancy Risk Associated with Diagnostic Categories Defined by the Papanicolaou Society of Cytopathology Pancreatic Biliary Guidelines

*LJ Layfield, L Dodd, R Factor, RL Schmidt.* University of Missouri, Columbia, MO; University of North Carolina at Chapel Hill, Chapel Hill, NC; University of Utah and ARUP Laboratories, Salt Lake City, UT.

**Background:** Endoscopic Ultrasound Guided Fine-Needle Aspiration (EUS-FNA) is currently the predominant method for obtaining a preoperative tissue diagnosis for pancreatic lesions suspicious for malignancy. The diagnostic sensitivity and specificity of EUS-FNA are well documented but malignancy risk associated with the diagnostic categories proposed by the Papanicolaou Society of Cytopathology is poorly defined.

**Design:** The records of the Departments of Pathology at Duke University and University of Utah were searched for all cases of EUS-FNAs performed for the investigation of pancreatic lesions. All cases with follow-up surgical diagnosis or greater than three years clinical follow-up were selected. Cytologic diagnostic categories were "non-diagnostic", "benign", "atypical (not otherwise specified)", "suspicious for malignancy", "neoplasm" and "malignant". Correlation of cytologic diagnosis with surgical and/or clinical follow-up was made and risk of malignancy calculated for each category.

**Results:** 317 EUS-FNAs with adequate surgical or clinical follow-up were obtained. Risk of malignancy for non-diagnostic specimens was 21%, benign specimens 13%, atypical cases 74%, suspicious for malignancy 82%, the neoplasm category 14% and for the malignant category 97%.

**Conclusions:** The cytologic categories proposed by the Papanicolaou Society of Cytopathology demonstrate an increasing risk for malignancy extending from benign to malignant. Aspirates designated benign have the lowest risk of malignancy (13%) and aspirates designated malignant the highest (97%). The proposed categorization scheme stratifies risk for malignancy giving useful information to clinicians treating patients with pancreatic lesions.

#### 438 The Diagnostic Value of Sure Path Pap Test in Endometrial Lesions: A Retrospective Study with Histologic Follow-Up

*K Lee, F Haste.* University of California, San Diego, CA.

**Background:** The cervical Pap test is a very effective cancer screening test; however the Bethesda System emphasizes that "cervical cytology is primarily a screening test for squamous epithelial lesions and squamous cell carcinoma and it is unreliable for the detection of endometrial lesions". The purpose of this study is to look at our institution's experience with detecting endometrial adenocarcinomas (EMADC) in cervical cytology (Sure Path).

**Design:** A retrospective analysis was performed using a computerized search of the electronic database over a 2 year period (01/2009-12/2010). The inclusion criteria were one of five diagnoses: adenocarcinoma, atypical endocervical cells, atypical glandular cells, atypical endometrial cells or endometrial cells in a woman >40 years old. The initial search yielded 344 cases; however after excluding cases with no histologic follow-up a total of 169 cases were included in the final analyses. The histologic specimens were placed into categories of benign or malignant and the malignant cases were further subclassified as squamous carcinoma or adenocarcinoma.

**Results:**

Cytologic Diagnosis	Histologic Diagnosis		
	Benign	Squamous Carcinoma	Adenocarcinoma
Adenocarcinoma	25	0	25
Atypical Glandular Cells	9	8	1
Atypical Endometrial Cells	15	7	8
Endometrial Cells >40 years old	104	102	2
Atypical Endocervical Cells	16	8	0

For all 25 cases interpreted cytologically as positive, EMADC was confirmed histologically. Among cases classified cytologically as atypical glandular cells, 8 were benign and one had EMADC on follow-up. Among cases classified cytologically as atypical endometrial cells, 7 were benign and 8 were EMADC on follow up. Among cases classified cytologically as endometrial cells in a woman >40 years old, 102 cases were benign and 2 cases were EMADC on follow-up. Among cases classified cytologically as atypical endocervical cells, 8 were benign, 8 had a squamous carcinoma and 0 had EMADC on follow-up.

**Conclusions:** A total of 36 cases of EMADC were diagnosed on histologic follow up to cervical cytology. Of these, 33 cases were called either adenocarcinoma or atypical endometrial cells and 3 cases were classified in one of the other categories. Therefore cervical Pap test appears to be effective for diagnosis of EMADC when morphologic features that are either consistent with or suggestive of endometrial adenocarcinoma are present; interestingly, only 2 of 104 patients with benign endometrial cells turned out to have EMADC on follow-up. None of the cases with atypical endocervical cells showed endometrial abnormalities.

#### 439 Comparison of Differential Expressions of p40 and p63 in Non-Small Cell Lung Cancers (NSCLC) Using Fine Needle Aspiration (FNA) Cases and Tumor Tissue Microarray (TMA)

*MT Lilo, CJ VandenBussche, MH Ao, E Gabrielson, F Askin, QK Li.* The Johns Hopkins Medical Institutions, Baltimore, MD.

**Background:** Personalized treatment of lung cancers necessitates sub-classification of NSCLC into squamous cell carcinoma (SQCC), non-SQCC such as adenocarcinoma (ADC), and other diagnostic categories such as small cell lung carcinoma (SCLC). Fine-needle aspiration (FNA) biopsy is an established, accurate method for diagnosing and staging of lung cancers, although the majority of FNA cases can be subclassified by H&E sections alone, immunohistochemical (IHC) markers are needed in difficult cases. In this study, we compared the performance of p40 and p63 for the sub-classification of

NSCLC using both FNA cases and samples represented in tissue microarrays (TMAs). **Design:** Using pathology archives from our academic center, 134 consecutive FNA cases with diagnoses of lung cancers and p40/p63 stains were identified, including 50 ADCs, 56 SQCCs, 8 small cell lung carcinomas (SCLCs), and 20 other carcinomas. 10 benign FNA lung lesions were included as controls. In addition, lung SQCC TMAs (0.6 mm in diameter, 3 cores per case) were constructed using other surgically resected specimens, and total of 91 SQCCs were included. p40 and p63 were used at dilutions recommended by manufactures, and staining was performed by automated stainer. Nuclear staining patterns were scored semi-quantitatively as 0 (negative), 1 (weak and focal), or 2 (strong and diffuse).

**Results:** In SQCC TMA, p40 and p63 were positive in 80.5% and 93.5% cases, respectively. Similarly, in primary lung SQCC FNA cases, p40 and p63 were positive in 80% and 93.6% cases, respectively. The sensitivity and specificity of p40 in SQCC FNA cases were 82% and 90%, whereas, they were 94% and 75% for p63. In FNA ADC cases, p40 was weakly and focally positive in 6.1% cases and p63 was variably positive in 54.3% cases, respectively. All 8 cases of SCLC were negative for p40, but 1 of 8 cases was focally positive for p63. In other carcinomas (non-SQCC, non-SCLC, n=20), p40 was weakly positive in 11.1% and p63 was variably positive in 7.7% cases. In addition, basal cells of normal lung also expressed p40.

**Conclusions:** Our study demonstrates that p40 has a better specificity, but a lower sensitivity, than that of p63 for the classification of SQCC. A positive staining pattern with both markers was also found in certain non-SQCC cases. Recognizing limitations of these stains are particularly important in the interpretation of p40/p63 IHC patterns in FNA cases, due to their different sensitivities and specificities in the classification of SQCCs.

#### 440 Next Generation Sequencing in Effusion Fluids from Patients with Ovarian Serous Carcinoma. A Comparison with TCGA Findings

*O Lin, AR Brannon, DA Levine, ME Arcila, SN Scott, M Edelweiss, MF Berger.* Memorial Sloan-Kettering Cancer Center, New York, NY.

**Background:** Mutation analysis for personalized treatment has become increasingly important in the management of different types of cancer. Cytology material is usually not the first option for this analysis due to the need for large quantities of DNA by traditional sequencing platforms. The advent of new DNA extraction protocols and sequencing platforms with reduced DNA yield requirements might allow the use of cytology specimens for high throughput mutation analysis. Ovarian serous carcinomas are aggressive high grade tumors frequently associated with malignant effusions. We propose to evaluate the use of effusion fluid (EF) specimens for next generation sequencing-based multi-gene mutation profiling.

**Design:** Four specimens from each of five patients with ovarian serous carcinoma previously analyzed by The Cancer Genomic Atlas (TCGA) were selected for this study: EF, frozen tumor (FT), formalin fixed paraffin embedded tumor (FFPET) and matched normal blood. FT and FFPET from the resected tumor and alcohol fixed EF specimens were used. EF specimens were represented by ascitic and pleural fluid specimens obtained at the time of surgery or recurrence. Morphological confirmation of the presence of tumor cells was performed in all specimens. DNA was extracted from all specimens and evaluated by an Illumina based genomic profiling platform (IMPACT). This platform enables the characterization of tumor specimens for somatic base mutations and copy number changes involving 279 key cancer-associated genes. The EF analysis results were compared with the mutations found in FT, FFPET, and the findings reported in TCGA for the same tumors.

**Results:** A total of 24 mutations were identified in our cohort of patients. Twelve mutations were called in all 3 specimen types containing tumor. Ten of these 12 mutations were also called in the corresponding FT by TCGA, accounting for all TCGA mutations detected in these tumors and included in the set of 279 genes analyzed. The other 12 mutations were detected in at least 1 out of 3 specimens. Five mutations were found in EFs but not detectable in FT or FFPET samples. These mutations range in allele frequency from 3% (44/1296 reads) to 26% (25/98 reads). Seven additional mutations were identified in either the corresponding FT or FFPET when analyzed by IMPACT, but they were absent in EF or TCGA.

**Conclusions:** Cytology specimens represent suitable specimens for high throughput sequencing as no mutation described by TCGA in these samples was missed in EF. Differences in mutations detected in FT, FFPET and EF might represent tumor heterogeneity.

#### 441 Correlation between Fine Needle Aspiration Biopsies (FNA) and Surgical Specimens in the Diagnosis of Fibroepithelial Lesions of the Breast – A Large Retrospective Study

*JM Lindsey, Y-Y Chen, JM Taylor, M Vohra, P Vohra.* University of California San Francisco, San Francisco, CA; ECC, Burlingame, CA.

**Background:** Fibroepithelial lesions (FEL) of the breast include a morphologic spectrum ranging from fibroadenoma (FA) to phyllodes tumor (PT) with different clinical behavior and management. FNA is a useful tool for identifying those patients with mammary FEL who need further intervention. The objective of this study is to determine the correlation between FEL diagnosed by FNA with surgical excision and core needle biopsy (CNB).

**Design:** We identified 1311 patients from 1997-2013 who received a diagnosis of FA, FEL, or PT on FNA. We compared the FNA diagnosis with any subsequent surgical specimens including CNB and excision. For cytology specimens, we looked at two denominators: (1) All cases of FAs with no histologic follow up; and (2) FA with follow-up surgical specimens.

**Results:** 1134 cases had FA on FNA and no histologic follow up: it is reasonable to assume that these lesions are likely to remain FA. 177 cases had follow-up (22 CNB and 155 excisions). We found agreement in 100% of cases diagnosed as PT on FNA and

subsequent excision and/or CNB. A diagnosis of FEL on FNA was called PT at excision in 86% of cases and FA in 14%. 86% of FAs on FNA agreed with the corresponding surgical specimen. The other 13% of cases (24 cases) of FAs turned out to be PT on subsequent excision. Out of these 24 cases, 23 were low grade phyllodes tumor and one was a case of malignant phyllodes tumor, which was subsequently discovered to be due to a sampling error. Of the 155 excisions, 99% of surgically diagnosed FAs agreed with the FNA diagnosis.

**Conclusions:** FNA is an excellent screening tool for FEL. A diagnosis of FA on FNA may be followed if we incorporate clinical/imaging/pathologic correlation. However, it is prudent to excise those diagnosed as FEL on FNA. The incidence of borderline PT and malignant PT subsequent to a diagnosis of FA on FNA is extremely low (a maximum of 0.56% in our sample) with most cases categorized as low grade PT. This is a large retrospective histopathologic correlation study between FNA and surgical specimens for the evaluation of FEL of the breast. Based on the concordance found, we conclude that FNA is an excellent screening tool for FEL if we incorporate clinical/ imaging/pathologic correlation. It is prudent to recommend excision of any FEL on FNA as low grade phyllodes can resemble FA and can lead to diagnostic under-interpretation.

#### 442 Expression of ProEx C in Metastatic and Primary Urothelial Carcinoma

*L Liu, C Cohen, MT Siddiqui.* Emory University, Atlanta, GA.

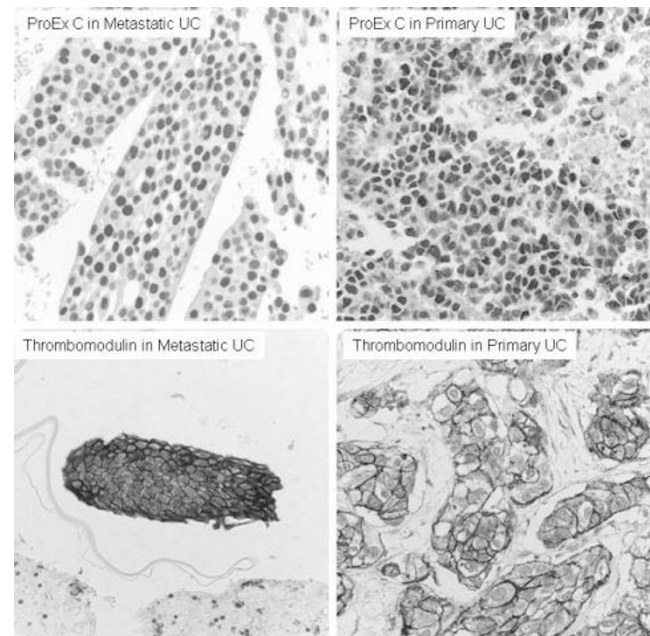
**Background:** ProEx C is an antibody cocktail targeting the expression of topoisomerase II $\alpha$  (TOP2A) and minichromosome maintenance protein-2 (MCM2). Both TOP2A and MCM2 are over-expressed in the cell nucleus during aberrant S-phase induction of neoplastic cells, which leads to cell proliferation. Their overexpression is well documented in cervical carcinoma and more recently in urothelial carcinoma. The primary aim of this study was to determine whether ProEx C expression can detect metastatic urothelial carcinoma (UC).

**Design:** Immunohistochemical (IHC) staining for ProEx C (BD, ready to use) was performed in formalin-fixed, paraffin-embedded FNA cell blocks from 31 cases of metastatic UC. Staining of thrombomodulin, an established urothelial marker, was performed as well for comparison. In addition, ProEx C and thrombomodulin staining was performed in tissue microarrays (TMA) of 46 cases of primary UC. Nuclear staining of ProEx C and membrane staining of thrombomodulin in at least 10% tumor cells was considered a positive result. Fisher's exact test was used for statistical analysis.

**Results:** ProEx C yielded a high sensitivity of 84% for metastatic UC in FNA specimens, and 93% for primary UC in TMA (table 1). In metastatic UC in FNA specimens, the sensitivity of ProEx C is similar to that of thrombomodulin (77%, p=0.75). However, in the primary UC, the sensitivity of ProEx C is significantly higher than that of thrombomodulin (72%, p=0.01).

Sensitivity of ProEx C and thrombomodulin in metastatic vs. primary urothelial carcinoma

	ProEx C Positive# / Total# (Sensitivity)	Thrombomodulin Positive# / Total# (Sensitivity)	p value
Metastatic UC (FNA)	26/31 (84%)	24/31 (77%)	0.75
Primary UC (TMA)	43/46 (93%)	33/46 (72%)	0.01



**Conclusions:** ProEx C yields high sensitivity for metastatic UC in FNA specimens. Staining is strong and diffuse in most of the cases. ProEx C is at least as sensitive as thrombomodulin for detecting metastatic UC in FNA specimens, and more sensitive than thrombomodulin for detection of primary UC in TMA. Utilization of both ProEx C and thrombomodulin would be clinically useful for detection/confirming metastatic UC.



#### 443 Assessment of Cytotechnologist-Cytopathologist Interpretative Agreement Using the Bethesda System for Reporting Thyroid Cytopathology

P Lokhandwala, C Abendroth, N Williams, H Mani, M Walls, M Wang, D Zander. PSHMC, Hershey, PA.

**Background:** The Bethesda System for Reporting Thyroid Cytopathology (TBSRTC) was proposed in 2007 to provide a clinically relevant framework for interpretation that was intended to improve interobserver agreement. Limited data is available regarding the level of interobserver agreement between groups of cytotechnologists and cytopathologists examining the same thyroid fine needle aspirate (FNA) samples. **Design:** 1229 thyroid FNAs were obtained from 976 patients at our institution between March, 2010 and August, 2012. Each FNA received a preliminary evaluation by a cytotechnologist followed by a final interpretation by the cytopathologist. We calculated a kappa statistic to measure overall interpretative agreement between the cytotechnologist and cytopathologist groups, and analyzed each diagnostic category individually.

**Results:** Compared to cytotechnologists, cytopathologists tended to downgrade the level of the FNA interpretation (see table). For overall interpretative agreement between the cytotechnologist and cytopathologist groups, the Kappa value was 0.79 (95% confidence interval: 0.76–0.83). Kappa values for the individual diagnostic categories were higher for the Non-Diagnostic, Benign, and Malignant categories than for the other categories.

Category	Cytotechnologist	Cytopathologist	Kappa	Agreement
Non-diagnostic	114	107	0.89	Excellent
Benign	822	863	0.83	Excellent
Atypia of undetermined significance	93	76	0.60	Fair
Follicular neoplasm/Suspicious for follicular neoplasm	93	83	0.72	Good
Suspicious for malignancy	24	24	0.49	Fair
Malignant	84	76	0.91	Excellent

**Conclusions:** Overall, for thyroid FNAs, there was a high level of interpretative agreement between cytotechnologists and cytopathologists using TBSRTC. Perhaps not surprisingly, agreement was most robust for the Benign and Malignant categories. Opportunities may exist for refinement of criteria for the intermediate categories to improve consistency in their application. Comparison also showed a trend for downgrading of cytotechnologists' interpretation by cytopathologists.

#### 444 Electromagnetic Navigation Bronchoscopy-Guided Fine Needle Aspiration Cytology of Peripheral Lung Lesions: Results in 50 Lesions

FL Loo, AM Halligan, JL Port, RS Hoda. New York-Presbyterian Hospital, Weill Cornell Medical College, New York, NY.

**Background:** The study evaluates fine needle aspiration (FNA) performed with guidance of electromagnetic navigation (ENB) system (*superDimension, Inc., Minneapolis, MN*), an image-guided localization device capable of targeting peripheral lung lesions (PLL) beyond the reach of the standard bronchoscope. Literature on diagnostic yield (DY) of ENB-FNA in PLL is sparse. To our knowledge, the DY of ENB-FNA for PLL when performed together with four other ancillary modalities, has not previously been published.

**Design:** ENB-FNA performed in conjunction with positron-emission tomography-computed tomography (PET-CT), rapid on-site evaluation (ROSE), bronchial brushings (ENB-BB) and transbronchial biopsy (ENB-TBx) over a 2-year-period (July 2011 to June 2013) were retrospectively reviewed. ENB-FNA diagnosis reflects final cytological interpretation. Details of ENB-FNA technique have been published (*Weiser et al. Ann Thorac Surg, 2008;85:S797*).

**Results:** Fifty PLL from 40 patients (pts), mean size, available in 45 PLL, was 2.6cm: ≤2cm, 24; >2.0 cm, 21. ENB-FNA diagnosis was: malignant, 17; atypical, 1; benign, 31 and non-diagnostic, 1. Based on size DY of PLL was 87% in ≤2cm and 100% in >2.0cm (not significantly different,  $p=0.5$ ). Follow-up (F/U) available in 49/50 PLL from 39 pts showed an overall DY of 94% for ENB-FNA. PET-CT, available in 31/50 PLL, had an overall DY of 61% in combination with ENB-FNA. ROSE was performed in 46/50 PLL and overall sensitivity of ROSE and ENB-FNA was 85% and 89.4% and specificity of 96.5% and 100% respectively. ENB-BB and ENB-TBx were available in 40/50 PLL. The DY of these procedures was 95%. There were no procedure-related complications. Five PLL for which size was not available are factored in the calculations as lesion size did not influence results.

Diagnostic Yield in 45/50 Peripheral Lung Lesions by Size

Lesion Size (cm)	Lesions of This Size	Diagnostic Yield (%)
≤1	8	100
1.1 - 2	16	80
2.1 - 4	12	100
>4	9	100

Five PLL without size information had a 100% DY

**Conclusions:** The overall diagnostic yield (DY) of ENB-FNA was 94%. The DY of 87% for PLL ≤2cm is similar to the published 92% for CT-FNA with fewer complications and better compared to the published DY of 14% for bronchoscopy (*Baakli et al. Chest, 2000;117:1049*). ROSE in conjunction with ENB-FNA was the only ancillary modality that contributed to the high DY of ENB-FNA.

#### 445 A Five Year Analysis of the Indeterminate Bethesda Category of Thyroid Cytology

H Lugo, S Bose. Department of Pathology and Laboratory Medicine, Cedars-Sinai Medical Center, Los Angeles, CA.

**Background:** The Follicular Lesion of Undetermined Significance (FLUS) and Follicular Neoplasm (FN) categories established by the Bethesda System (BS) are reported at rates of 3% to 18% of all thyroid fine needle aspirations (FNA). Established guidelines suggest watchful waiting with repeat testing for FLUS cases and surgery for

FN cases. This study reports the results of a retrospective review conducted to evaluate the impact of the BS on management of nodular thyroid lesions classified as FLUS and FN at our institution over the last 5 years.

**Design:** After IRB approval, all thyroid FNAs reported as FLUS and FN between 7/1/2008 and 6/30/2013 were retrieved from our database. Cases with surgical intervention or cytology follow up were included in the study. The surgical pathology and follow up FNA diagnoses were documented. On cases with multiple FNA follow ups the last result was recorded. A comparative analysis of cytopathologic diagnoses with subsequent surgical pathology results and rates of repeat FNAs and malignancy was completed.

**Results:** A total of 6,903 thyroid FNAs were evaluated during the study period. Of these 11% (734) were diagnosed as FLUS and 2% (136) as FN. Follow up was available in only 32% (232) of FLUS and 55% (75) of FN cases. Of the FLUS, 22% (158) had surgery, lobectomy or total thyroidectomy, while only 10% (74) were followed up with repeat FNAs. Malignancy was identified in 26% (41) of the excised cases. Of the excised FLUS 87% (138) were operated on after the initial FLUS result with malignancy detected in 27% (37). The remaining 13% (20) had surgery after a second FLUS diagnosis with malignancy identified in 25% (5). Of the FN, 50% (68) had surgery while 5% (7) were followed up with repeat FNAs. Surgical pathology of the FN cases showed malignancy in 36% (25) of cases. 99% (135) of FN cases had surgery after the initial FN result.

Final diagnosis in FLUS/FN cases (%)

	Benign	Adenoma	Papillary carcinoma	Follicular carcinoma	Other
FLUS	74	43	29	11	1
FN	12	31	11	13	1

FLUS and FN cases followed up by repeat FNA showed findings suspicious for papillary carcinoma in one case. No further follow up is available.

**Conclusions:** 1. The FLUS and FN rate at our institution is 11% and 2% respectively. 2. Surgery was performed in 22% of FLUS and 99% of FN cases, with malignancy detected in 26% and 36% respectively. 3. Majority of the FLUS cases were excised after the initial FNA. 4. The rate of malignancy in FLUS cases excised after the first FLUS diagnosis and those excised after two FLUS diagnosis were similar.

#### 446 New ACOG Cervical Cancer Screening Guidelines in Women >65 Years of Age: A 10-Year Retrospective Analysis

C Mafnas, A Lam, P Tauchi-Nishi. University of Hawaii/Hawaii Pathologists Laboratory, Honolulu, HI.

**Background:** In 2012, ACOG issued new screening guidelines for cervical cancer. In these recommendations, the majority of women older than 65 with adequate negative prior screening no longer require Pap testing. The aim of this study is to examine the prevalence of Pap abnormalities, precancerous lesions, and gynecologic malignancies in our >65 population. We also aspire to determine pathologies that may be missed utilizing these new screening guidelines.

**Design:** From 2002-2011, a total of 1,026,470 Pap tests were examined. 92,247(10%) were from the >65 year old age group. Cases were designated as "potentially missed" in this group with the new 2012 ACOG screening guidelines if the patient exhibited criteria for exclusion from Pap screening, i.e., 3 consecutive prior negative Paps on file, no record or history of CIN2+, and no symptoms of abnormal bleeding at the time of Pap testing. Statistical analysis was performed utilizing chi-square testing.

**Results:** There were proportionately more cancers and glandular lesions, and fewer squamous lesions in the >65 age group (Table 1). Subsequent biopsies yielded 172 (3.2%) precancerous lesions and malignancies in the >65 patients, compared to 5175 (96.8%) in the general population (Table 2). HSIL and squamous cancer comprised the majority of these biopsies (59%). By employing the 2012 ACOG screening guidelines, 21(12%) of these histologically confirmed lesions would not have been detected. 16 (23%) of the glandular abnormalities would have been missed, versus only 5 (5%) of the squamous lesions ( $P=0.0001$ ).

Table 1: Abnormal Pap Smear Diagnoses/Rates (2002-2011)

Cytologic Diagnosis	>65 Age Group	General Population	P-value
Total # Paps	92,247	934,223	--
ASC-US	434(0.5%)	14,889(1.6%)	<0.0001
ASC-H	42(0.05%)	1,070(0.1%)	<0.0001
LSIL	210(0.2%)	18,071(1.9%)	<0.0001
HSIL	62(0.07%)	1,801(0.2%)	<0.0001
SCCA	11(0.01%)	34(0.004%)	0.0003
AGUS	41(0.04%)	219(0.02%)	<0.0001
ADENOCA	47(0.05%)	63(0.007%)	<0.0001

Table 2: Histologically Confirmed Precancerous Lesions/Cancers in >65 Age Group

Histologic Diagnosis	Total cases	Potentially Missed Cases
HSIL (CIN 2-3 & VAIN 2-3)	87	5(6%)
SCCA	15	0(0%)
ENDOCERVICAL AIS	4	0(0%)
ENDOCERVICAL ADENOCA	1	0(0%)
COMPLEX ATYPICAL HYPERPLASIA	2	1(50%)
ENDOMETRIAL ADENOCA	59	15(25%)
METASTATIC CA	4	0(0%)
TOTAL	172	21(12%)

**Conclusions:** There were significantly more cancers and glandular lesions detected on Pap testing in our >65 population. The cessation of Pap screening would result in the missed diagnoses of 12% of the precancerous lesions and cancers in this age group, with significantly higher misses of endometrial cancers.

#### 447 Application of Returned Cell Block Method for the Evaluation of Fine Needle Aspiration Cytology of Mammary Lesions

T Matsumoto, Y Aoki, A Sakaguchi, K Ogura. Juntendo University Nerima Hospital, Tokyo, Japan.

**Background:** In the fine needle aspiration cytology (FNAC) for mammary lesions, the evaluation is frequently difficult by the blood inclusion, the thick layer or high cellular clusters. Such problems may be resolved by the returned cell block method, so we examined the application of returned cell block method in the cases with the difficulty of the evaluation of FNAC for mammary lesions.

**Design:** Among 2,739 cases with FNAC examination for mammary lesions in our hospital, we selected 22 cases with the difficulty of the evaluation of FNAC and examined the usefulness of the application of returned cell block method. The process of the method as follows: (1) Take off cover glass, (2) Pick up cell clusters, (3) Paraffin wax infiltrate, (4) Embedding, (5) Sectioning, (6) Staining, conventional and immunohistochemical stains.

**Results:** Among the 22 cases, correct diagnosis was made in 20 cases by returned cell block method, but in 2 cases correct diagnosis could not be made because of the tiny tumor cells. In the 20 cases with the correct diagnosis by returned cell block method, reasons of the difficulty by FNAC consisted of thick layer or high cellular clusters (12 cases; 60%), blood inclusion (4 cases; 20%) and specific types of carcinoma (4 cases; 20%).

**Conclusions:** The application of returned cell block method is useful for the precise evaluation of cytological diagnosis for mammary lesions. The coupling of conventional FNAC and returned cell block method leads to the increase in accuracy in cytological diagnosis in mammary lesions.

#### 448 Prostatic Adenocarcinoma in the Urine Specimen, Cytomorphologic Characteristics: A Review of 8 Cases

Z McCroskey, M Shaar, E Wojcik, G Barkan. Loyola University Medical Center, Maywood, IL.

**Background:** Although a common malignancy in men, prostatic adenocarcinoma (PA) is a rare diagnosis in exfoliative urine cytology. It is a diagnostic pitfall, especially in patients with no history of PA and low levels of serum prostate specific antigen (PSA). The purpose of our study was to describe cytologic features and ancillary studies that are helpful to diagnose PA in urinary tract specimens prepared with ThinPrep® technique.

**Design:** The pathology database was searched for PA diagnoses in urine specimens and their concurrent biopsy/resection specimens in 2000-2013. Cases were matched with patients' previous PA history and serum PSA levels. All urine cytology specimens were evaluated including immunohistochemical (IHC) stains and available cell blocks.

**Results:** A total 8 ThinPrep® urine specimens, 4 cell-blocks, and 11 IHC-stained slides (from 8 patients/cases) were collected for review. Three patients did not have previous PA history with serum PSA levels within normal/slightly elevated ranges (3.3-4.7ng/ml). They presented with gross hematuria and urinary obstruction. IHC stains were originally performed in 6 cases (3 cell blocks, 6 destained ThinPrep® specimens). Evaluation of all specimens revealed clusters of round/oval tumor cells with increased nuclear/cytoplasmic (NC) ratio with eccentrically placed nuclei and prominent nucleoli. The most typical features were finely granular chromatin pattern and a centrally located, dark staining single prominent nucleolus. Confirmatory IHC stains were available in 6 cases. Two cases were morphologically compared with the previous biopsy. Molecular studies (DNA Ploidy/FISH) were performed in 4 cases and all were positive.

Table1. Patient's Demographics, Previous History and Serum PSA levels.

Case	Age	Previous PA history	Serum PSA (ng/ml)	IHC/PSA	Gleason score
1	63	Yes	14.35	Not done	N/A
2	68	Yes	0.11	Positive	9(5+4)
3	71	Yes	1.01	Positive	9(5+4)
4	80	No	3.3	Positive	7(3+4)
5	88	Yes	18.8	Positive	7(3+4)
6	59	Yes	7.2	Negative	6(3+3)
7	84	No	3.4	Positive	N/A
8	66	No	4.7	Positive	10(5+5)

UBB, urinary bladder barbotage; BW, bladder washing; PSA, prostate specific antigen

**Conclusions:** The cytomorphologic characteristics of PA can be identified in urine specimens with reasonable confidence. The most important features are finely granular chromatin pattern and a centrally located, dark staining single prominent nucleolus. IHC stains can be easily done on cell blocks/destained ThinPrep® specimens. In patients with no previous history of PA this should prompt close follow-up, and prostate biopsy.

#### 449 Nephrogenic Adenoma in the Urinary Tract Cytology: Can We Diagnose It?

Z McCroskey, M Shaar, V Mehta, E Wojcik, G Barkan. Loyola University Medical Center, Maywood, IL.

**Background:** Nephrogenic adenoma (NA) is a rare benign lesion that is believed to develop as a result of traumatic injury and implantation of the exfoliated renal tubular epithelium. NA can be encountered in patients followed for urothelial carcinoma (UC) and mistaken for it. The purpose of our study was to evaluate if the cytologic criteria of NA were applicable in daily cytology sign out.

**Design:** The pathology electronic medical records were searched for NA diagnosis in lower urinary tract biopsies between 2006 and 2013 and their concomitant urine cytology specimens were reviewed. Cases with concurrent UC were excluded. The cytologic features of NA described in the rare case reports were used: vacuolated polygonal cells with only mild nuclear atypia, including signet-ring-like cells; forming papilla/loose groups or isolated cells.

**Results:** A total 35 Thin Prep urine specimens (from 15 patients) were collected for review. These were originally diagnosed as negative for malignancy (28), atypical urothelial cells (AU) present (6), suspicious for UC (1). Evaluation of the specimens showed the following results: 14 revealed loose and tight clusters of 10 to 30 cells with increased nuclear/cytoplasmic ratio, prominent nucleoli, cytoplasmic vacuolization and eccentrically placed nucleus, consistent with features of NA.

Table1. Patient's Demographics

Cytology diagnosis	Total # of specimens	Original cytologic Diagnosis	Original cytologic Diagnosis	Original cytologic Diagnosis	History of bladder cancer	History of renal stones	Molecular study
NA	14	9	AU	9	10	4	2/neg
No NA	21	19	2	0	12	9	2/neg

Neg = negative; AU = atypical urothelial cells; Susp. = suspicious for urothelial carcinoma

Remaining 21 specimens showed benign urothelial cells only. Molecular studies (DNA Ploidy/FISH) were performed in 4/35 specimens and they were all negative.

**Conclusions:** NA is a difficult diagnosis in exfoliative urine cytology specimens. Although rare, it can be a diagnostic pitfall in urine specimens in patients who have been followed for UC. NA cells are usually mildly atypical, have round to oval shape and have cytoplasmic vacuolization, features that can help to distinguish them from UC. Cytopathologists should be cognizant of NA as a potential differential diagnosis for UC in urinary tract specimens.

#### 450 Post-Menopausal Squamous Atypia: A Cytologic Description and Hybrid Capture 2 Correlation within ASCUS

KE McHugh, D Cohen, AA Suarez. The Ohio State University Wexner Medical Center, Columbus, OH.

**Background:** Postmenopausal squamous atypia (PMSA) is a benign histologic change unrelated to high-risk Human Papilloma Virus (HPV). PMSA may be a confounding factor in cervico-vaginal cytology (Pap tests) leading to reflex HPV testing. However, the Hybrid Capture 2 (HC2) test interpretation does not take age, a main determinant of HPV infection prevalence, into account. Hence, PMSA and HC2 may both contribute to inappropriate patient management but the magnitude of the problem is unknown. We attempt a cytologic description of PMSA and propose an age adjusted HC2 signal threshold (Relative light unit/cutoff value, RLU/CO) that distinguishes it from HPV-related lesions.

**Design:** 386 Pap tests with a diagnosis of atypical squamous cells of undetermined significance (ASCUS) in women ≥55 years were reviewed to select those with koilocyte-like cells and/or atypical parakeratosis. Corresponding RLU/CO data were obtained. A positive follow-up was defined as a subsequent positive HC2 or a biopsy with CIN. In situ hybridization (ISH) with two HPV probes (16/18 and 31/33/51) was performed on subsequent surgical specimens.

**Results:** 17 out of 55 (29.8%) ASCUS were HC2 positive. Follow-up was available for 12 (70.6%). Seven cases had a positive follow up and 5 had a negative follow up. Cytologic comparison revealed overlap, but peripherally reinforced perinuclear halos, unevenly clumped chromatin, and irregular nuclear contours were better demonstrated in cases with a positive follow-up. ISH was performed on surgical specimens from 6 (35.3%) of the 17 initially HC2 positive ASCUS Pap tests. 4 cases without CIN (3 PMSA, 1 normal) were ISH negative while 2 CIN1 were ISH positive. PMSA associated RLU/CO ranged from 0.64 to 2.94. Cases with HPV related lesions had RLU/CO from 6.22 to 831.77.

**Conclusions:** PMSA represented 0.78% of ASCUS Pap tests in women ≥55 years. HC2 testing can resolve the cytologic overlap between ASCUS leading to a positive follow up and ASCUS leading to detection of PMSA if the RLU/CO threshold is adjusted from the currently used 1 to >2.94-6.22. Study of a larger number of cases is clearly in order.

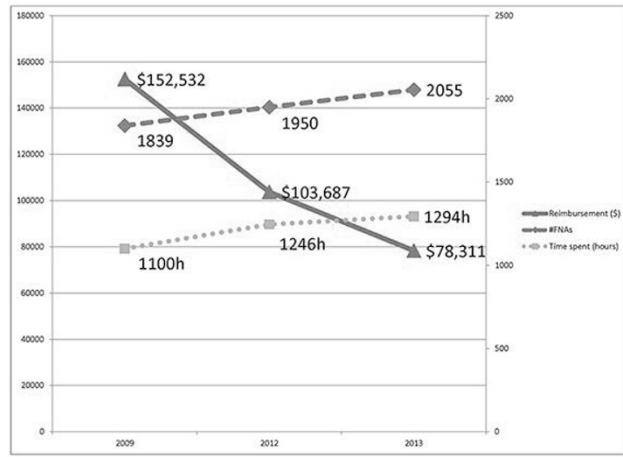
#### 451 Rapid On-Site Evaluation (ROSE) – Is It Affordable to Provide This Service?

S Mehrotra, GA Barkan, RM Wafai, SE Pambuccian, EM Wojcik. Loyola University Medical Center, Maywood, IL.

**Background:** Rapid On-Site Evaluation (ROSE) is a proven adjunct for optimal sample collection and triage during Fine Needle Aspiration Biopsy (FNAB). Recent years have witnessed a decline in work Relative Value Units (wRVU) and thereby reimbursements for pathologists providing this service. CMS transmittal version 15.3 of the NCCI manual limited billing for one unit of CPT code 88172 per specimen site. It also introduced and defined "evaluation episode" and CPT code 88177. The wRVU and average reimbursements for CPT code 88177 was 0.42 and \$17.38 vs. 0.64 (2012), 0.68 (2013) and \$33.32 for CPT code 88172. This decline in addition to several other Medicare cuts looming on the horizon has lead pathology practices to reconsider the affordability of providing the service.

**Design:** The present study was undertaken to evaluate the decline in compensation for ROSE at our institution. Data was extracted from calendar year 2009 (before the implementation of CMS transmittal 15.3) and fiscal years 2012 and 2013. We looked at the number of FNABs requiring ROSE, calculated the wRVUs and compensation. Published data was utilized in calculating pathologist time spent in providing ROSE vs. other anatomic pathology service. The average time spent in providing ROSE was taken to be 45 minutes (range 35-55 minutes) and 4.1 minutes for reading a surgical biopsy (CPT code 88305, wRVU=0.75, \$38.43).

**Results:** We have seen a rise in the number of FNABs over the course of last four years. The wRVUs and compensation have declined to show almost a 50% reduction in dollar amount from 2009 to 2013. Using an average salary of \$250,000 for midlevel pathologist, the calculated per hour compensation is \$135. Providing ROSE barely compensates at about \$42/hour vs. reading surgical biopsy which does so at \$556/hour.



**Conclusions:** Pathologists providing ROSE are poorly compensated for their time and expertise. Our data highlights steady decline in reimbursement and an increase in time spent in providing ROSE. As pathologists we fully understand the significance of ROSE and realize that patient care decisions should not be based on compensation alone; however the business aspect of pathology questions its affordability. Discontinuation of ROSE may have an undue effect on patient care and academic training of our residents.

**452 Anal Cytology as a Predictor of Anal Intraepithelial Neoplasia; an Institutional Experience**

**R Mehta, KK Khurana.** SUNY UPstate Medical University, Syracuse, NY.  
**Background:** The role of anal cytology in early detection of anal cancer is still evolving. Currently, there are no nationally accepted guidelines for epithelial cell abnormality detected in anal cytology smears. The purpose of this study was to evaluate whether anal cytology is valuable screening test for identifying anal intraepithelial neoplasia (AIN).  
**Design:** A search in the computerized database of the pathology department for results of all anal cytology smears between January 2011 and December 2012 was conducted. Anal cytology smears were classified using 2001 Bethesda system terminology and smears with follow up biopsies within a 6 month period were identified. Sensitivity for detecting AIN was calculated. Correlation between cytologic and histologic grade of dysplasia was performed using Kappa statistics.  
**Results:** The cohort included 290 patients (283 = males; 7 = females) with 398 anal cytology specimens. The mean patient age was 46 years (range, 23 to 71 years). Out of 398 cases, follow-up biopsies were available in 75 cases (18.9%). Table 1 shows the distribution of cytological and histological diagnosis. Atypical squamous cells of undetermined significance were distributed as follows: Negative 33.3%, low grade AIN 57.1% and high grade AIN 9.5%. The sensitivity of low grade (ASCUS or LSIL) cytology detecting low grade AIN (AIN I) on biopsy was 82.8% (24/29). The sensitivity of high grade (HSIL) cytology detecting high grade AIN (AIN 2-3) on biopsy was 28% (7/25). The strength of agreement between cytologic and histologic grading was poor (weighted Kappa+.045, 95% confidence interval -0.043 to 0.226). High grade AIN was diagnosed in 42.2% of LSIL cases, 41.1% of HSIL cases and 9.5 % of ASCUS cases.

PAP Results and Histologic Follow-Up

	Negative	Low Grade	High Grade	High Grade
Cytologic Diagnosis (# of cases)	AIN 1	AIN 2	AIN 3	
Negative (4)	1	2	0	
ASCUS (21)	7	12	0	
LSIL (33)	7	12	6	8
HSIL (17)	6	4	4	3
TOTAL	21	29	14	11

**Conclusions:** Histologic grade of dysplasia may be underestimated by anal cytology. High rate of detection of high grade AIN following LSIL cytology in our study is supportive of high resolution anoscopy and biopsy for management of anal cytology with LSIL interpretation.

**453 Negative Computer-Imaged ThinPrep Pap Test and Positive Hybrid Capture2 HPV Cotesting Results: A Quality Assurance Review**

**D Molina, AM Halligan, B Vakil, SA Alperstein, RS Hoda.** New York Presbyterian Hospital, Weill Cornell Medical College, New York, NY.  
**Background:** Women ≥30 years of age with negative (NILM) Pap tests and positive (+) HPV cotesting results have a higher absolute risk of 2–10% of developing CIN 3 in the next 2 years. For this reason, the American Society for Colposcopy and Cervical Pathology (ASCCP) recommends repeat cotesting in 12 months or reflex genotyping for HPV16 or HPV 16/18 (Saslow et al. *CA Cancer J Clin.* 2012;62:147). If genotyping is not an option, timely quality assurance (QA) re-screen of such Pap tests may be a valuable alternative.  
**Design:** Over the past 3 year-9-month-period (10/2009-06/2013) all ThinPrep (TP) Pap tests (PT) interpreted as NILM or NILM with reactive cellular changes (NILM/RCC) and a (+) HPV [Hybrid Capture 2 (HC2), Qiagen, Hilden, Germany] cotesting result, undergo monthly QA review by the cytology supervisor and medical director. All TPPT were screened by the TP Imaging System [(TIS), Hologic Inc., Bedford, MA]. Results were also stratified by age for the HPV (+) group. Follow-up (F/U) was obtained for re-classified cases.

**Results:** A total of 25,675 (NILM, 22,580; NILM/RCC, 3095) TPPT underwent HPV cotesting. Overall, HPV test was (+) in 2300 (8.96%) TPPT cases: NILM, 1,889 (8.37%) and NILM/RCC, 411 (13.28%). HPV (+) cases by age group were: ≤29, 486 (21%) and ≥30, 1,814 (79%). Upon QA review 10/2300 (0.43%) cases were reclassified as: ASCUS, 7 and ASC-H, 3. The 10 pts. were: ≤29, 1 with ASCUS and ≥30, 9 (ASCUS, 6 and ASC-H, 3). F/U was available in 8/10 (80%) cases within 3-12 months in 5/7 ASCUS and all 3 ASC-H cases. The F/U for 5 ASCUS cases was: NILM on repeat Pap, 1 and negative biopsy (Bx), 4. F/U for 3 ASC-H cases was: HSIL on repeat Pap, 2 and endocervical adenocarcinoma in situ (AIS) on Bx, 1.

Pap & HPV Cotest Results by Age Group: Original & QA Review Pap Test Diagnosis

Primary Pap Review	Pap Diagnosis	Age Group	HPV Positive	No Change on QA Review	Re-classified on QA Review
TPPT-TIS only 22 FOV	NILM	≥30	699	693	6
		≤29	107	106	1
TPPT-TIS & Manual Re-screen	NILM	≥30	815	815	0
		≤29	268	268	0
TPPT-TIS, Manual & MD	NILM/RCC	≥30	300	297	3
		≤29	111	111	0
Total			2300	2290	10

HPV: Human papillomavirus; QA: Quality assurance; TPPT-TIS: Computer-assisted screening of ThinPrep Pap test using ThinPrep Imaging System; FOV: Field of view; NILM, negative; RCC, reactive; MD, pathologist

**Conclusions:** Timely QA review of HPV positive, cytology negative Pap tests is a valuable monitor for patient care. 90% of reclassified cases were in ≥30 age group and 70% were signed out by using TIS 22 Field of View only.

**454 Atypical Urine Cytology and the Johns Hopkins Hospital Template: The University of Chicago Experience**

**E Morency, T Antic.** The University of Chicago Hospital, Chicago, IL.  
**Background:** Urine cytology is excellent for detection of high-grade urothelial carcinoma (HGUC), but in low-grade urothelial carcinoma (LGUC), low-grade lesions and reactive processes can lead to equivocal results. To stratify this large, heterogeneous group a new classification scheme has been proposed by the Johns Hopkins Hospital (JHH), based on the Bethesda System for cervical cytology. It includes the categories of atypical urothelial cells of unknown significance (AUC-US) and atypical urothelial cells, favor high grade lesion (AUC-H). The goal was to apply the new JHH criteria to our cohort of atypical urine specimens and correlate them with bladder biopsies to validate this new scheme.  
**Design:** All atypical urines with concurrent biopsy diagnosed from 2007-2011 were collected. In total, 213 urines from 157 patients were included and reclassified as AUC-H and AUC-US based on JHH criteria. The number of patients diagnosed with AUC-H who developed HGUC during the study was documented (highest grade cytology used in patients with multiple urines) then all urine specimens were examined independently to calculate statistical correlation between JHH categories and histology.  
**Results:** Of 69 patients diagnosed with AUC-H, 68% were diagnosed with HGUC and 13% with LGUC (overall PPV for diagnosis of carcinoma=81%). AUC-H was more predictive of HGUC in patients with hematuria versus those in the surveillance group (Sens 91% vs 72% and PPV 100% vs 67%, respectively). Examining all 213 specimens, the JHH categories showed high correlation with the histology [1]. AUC-H was predictive of HGUC (PPV=68%, NPV=85%) and AUC-US for LGUC and benign conditions (PPV=86%, NPV=69%).

1. JHH categories and histology

Cytology dx	Negative	LGUC	HGUC
AUC-US (n=144)	53%	33%	13%
AUC-H (n=69)	16%	13%	68%

They also correlated with our existing atypical designations; with atypical urothelial cells and atypical urothelial cells, suspicious for neoplasm, corresponding to AUC-US and AUC-H [2].

2. U of C categories and histology

Cytology dx	Negative	LGUC	HGUC
Atypical (n=129)	50%	29%	20%
Atypical, suspicious (n=84)	32%	21%	46%

**Conclusions:** The study demonstrated when applied to the U of C cohort of specimens, the JHH reporting system successfully predicted which atypical specimens were more likely to represent a high-grade urothelial lesion. It also correlated with our current terminology suggesting easy adoption of this scheme at our institution. By developing a more standardized classification scheme, pathologists can better convey clinical concern to clinicians, making the screening process more efficient and cost-effective.

**455 The Impact of On-Site Cytopathology on Head and Neck Surgical Mission Trips in Rural Kenya**

**J Mueller.** University of Chicago, Chicago, IL.  
**Background:** Each fall for three consecutive years a team of Head & Neck surgeons along with anesthesiologists, supporting staff and a pathologist travelled to rural Kenya and provided surgical services for two local hospitals in Malindi, where there is no on-site pathology support. A pathologist and pathology resident performed preoperative fine needle aspiration (FNA) and/or intraoperative touch prep on the majority of the patients for surgical treatment planning. The results from these three years are summarized and the overall impact of on-site pathology is assessed.  
**Design:** A FNA was performed on most patients for primary diagnosis or confirmation of the clinical diagnosis. The results were discussed with the surgical team and treatment decisions were then made. In many cases intraoperative touch preps were performed including intraoperative assessment of lymph nodes. Gross examination was performed including gross description and photos were taken. Diagnostic tissue was collected into 15 ml formalin containers and transported to the home institution where subsequent histologic examination was performed. All clinical and pathologic data were reviewed.

**Results:** Approximately 300 patients received surgical care by the team and 208 received pathologic diagnosis. The sites were: Thyroid, Salivary, Lymph Node, Soft Tissue, Jaw, Oral Cavity and Cyst/Other. Of these, 184 were diagnosed as benign and 24 as malignant. Common benign diagnoses included thyroid colloid nodules, salivary mixed tumors and reactive cervical lymph nodes. Uncommon lesions included sinus histiocytosis (Rosai-Dorfman) and ameloblastoma of the jaw. Malignant tumors varied from oral squamous cell carcinoma, salivary adenoid cystic and acinic carcinoma and papillary thyroid carcinoma. Cytologic/histologic correlation was >98%.

**Conclusions:** In the majority of cases the on-site cytologic diagnosis confirmed the clinical impression. However, in a significant number of cases the pathologic diagnosis was markedly different from the clinical impression. Examples include a patient with a clinical diagnosis of lymphoma and a cytologic diagnosis of Rosai-Dorfman. Another example was a patient with a clinical diagnosis of metastatic oral squamous cell carcinoma and the pathologic diagnosis of necrotizing granulomas. Without on-site pathology support, many patients would likely receive improper treatment which may result in harm to the patient. In our experience, the pathologist plays a key and central role in the overall success of a surgical mission trip.

#### 456 Utility of PAX8 and WT1 in the Differential Diagnosis of Metastatic Mullerian Carcinomas in Effusion Specimens

WR Munday, R Carr, G Cai, X Guo, N Buza, X Sun, M Harigopal. Yale University, New Haven, CT.

**Background:** Mullerian carcinomas are routinely detected in effusions specimens, and distinction among the various subtypes by cytomorphology alone is diagnostically challenging. An accurate diagnosis is critical for staging and treatment purposes. Neoadjuvant chemotherapy may be warranted given the propensity of these cancers to present at an advanced stage, and treatment regimens vary amongst Mullerian carcinomas. The aim of this study is to evaluate the usefulness of PAX8 and WT1 in the differential diagnosis of malignant effusions from Mullerian primary.

**Design:** Twenty-five effusion specimens with their corresponding cell blocks were retrospectively retrieved from our hospital pathology database for a 2 year period, including 12 serous carcinomas, 4 malignant mixed mullerian tumors (MMMT), 4 endometrioid adenocarcinomas, 2 clear cell carcinomas, 2 mucinous carcinomas, and 1 poorly differentiated adenocarcinoma. Corresponding surgical resection was available in 24 cases. Primary sites included ovary (14), uterus (8), peritoneum (2), and unknown primary (1). Cell blocks from were formalin-fixed and immunostained for PAX8, WT1, and MOC31. MOC31 was used to confirm malignancy. The staining intensity was graded as either positive or negative, with strong staining intensity in greater than 25 percent malignant cells qualifying as a positive stain.

**Results:** Metastatic serous carcinomas showed positive immunoreactivity to PAX8 in 12/12 (100%), and WT1 in 11/12 cases (92%) cases. MMMTs showed positivity to PAX8 in 4/4 (100%), and WT1 in 0/4 (0%) cases. Endometrioid adenocarcinomas showed positivity to PAX8 in 1/4 (25%), and WT1 in 0/4 (0%) cases. Mucinous adenocarcinomas demonstrated positivity to PAX8 in 1/2 (50%), and WT1 in 0/2 (0%) cases. Clear cell carcinomas showed a similar pattern to MMMT, with positivity to PAX8 in 2/2 (100%), and WT1 in 0/2(0%) cases. The case of poorly differentiated adenocarcinoma showed positivity to MOC31 but no staining for PAX8 and WT1.

**Conclusions:** Our results show distinct staining profiles of malignant effusions from mullerian primary. Serous carcinomas are uniquely positive for PAX8 and WT1 immunostains, while MMMTs and clear cell carcinomas showed positivity for PAX8, and were negative for WT1. Endometrioid carcinomas did not stain for PAX8 and WT1 in most cases. Immunohistochemical studies with PAX8 and WT1 are useful in both identifying and distinguishing metastatic Mullerian carcinomas in effusions specimens.

#### 457 A Questionnaire Survey of for the Clinical Impact of the Use of Follicular Lesion of Undetermined Significance (FLUS)

A Nassar, SM Jenkins, V Bernet. Mayo Clinic, Jacksonville, FL; Mayo Clinic, Rochester, MN.

**Background:** The indeterminate atypia or follicular lesion of undetermined significance category is controversial due to variation in how this category is applied in cytopathology practice and uncertainty about how these patients should be managed. According to published guidelines, the rate of AUS/FLUS should be less than 7% of all reported thyroid FNAs within the laboratory. However, published series show that practices vary in rates of AUS/FLUS from 1% to greater than 25%.

**Design:** The aim of the current survey is to assess the percentage of the AUS/FLUS category in the different practice settings (community, academic, etc.), and determine the follow-up outcome of those patients.

**Results:** See attached table.

Variable	Frequency (percent)	Median (range)
<b>Thyroid FNA procedure</b>		
US-image guided	55 (64.0%)	
Both palpation and US	30 (34.9%)	
Palpation	1 (1.2%)	
<b>Bethesda reporting system</b>		
Yes	77 (89.5%)	
No	6 (7.0%)	
Other	3 (3.5%)	
<b>Rate of AUS/FLUS</b>		
≤2%	12 (14.0%)	
3-10%	41 (47.7%)	
11-20%	22 (25.6%)	
21-30%	1 (1.2%)	
31-40%	2 (2.3%)	
Don't know	8 (9.3%)	
Follow-up rate of patients with initial AUS/FLUS diagnosis		70.0% (10-100%)
<b>Follow-up diagnosis after repeat FNAB for AUS/FLUS</b>		
Non-diagnostic		1.00% (0-90%)
Benign		52.00% (0-100%)
AUS/FLUS		11.50% (0-80%)
Suspicious for malignancy		10.00% (0-100%)
Positive for malignancy		7.50% (0-100%)
Don't know		1.00% (1-1%)
<b>Common cause of AUS/FLUS diagnosis</b>		
Pathologist's experience	13 (15.7%)	
Poor technique	18 (21.7%)	
Vascularity of nodule	8 (9.6%)	
Nodule type	37 (44.6%)	
Sampling/scant cellularity	7 (8.4%)	
<b>FNA performance</b>		
Radiologists	69 (80.2%)	
Endocrinologists	45 (52.3%)	
Cytopathologists	32 (37.2%)	
Surgeons and ENT physicians	14 (16.3%)	
<b>Specialty</b>		
Cytopathologists	42 (48.3%)	
cytotechnologists	37 (42.5%)	
General pathologists	6 (6.9%)	

**Conclusions:** Almost all thyroid FNAs are done under ultrasound-guided imaging. The Bethesda reporting system for thyroid FNA is widely used in almost two-third of practices. The rate of FLUS/AUS is widely variable among different institutions and practices. Almost half of repeat FLUS/AUS thyroid FNA cases would be called benign; and 18% would be called suspicious or positive for malignancy on follow-up. Nodule type accounts for one-third of thyroid cases categorized as AUS/FLUS followed by poor aspiration technique and pathologist's experience. Therefore the use of AUS/FLUS should be standardized, and strict cytologic criteria should be adopted.

#### 458 The Role of GATA3 in Identifying Metastatic Carcinoma of the Breast in Pleural Fluid

KE Natale, DN Nguyen, A Cimino-Mathews, JA Bishop, PB Illei. The Johns Hopkins Hospital, Baltimore, MD.

**Background:** An estimated 20% of pleural effusions are malignant with carcinomas of the breast and lung being the two most common primary sites in women. The distinction between reactive and malignant mesothelial cells and metastatic breast and lung carcinoma is a common diagnostic problem. GATA3 is a zinc finger transcription factor, which has been shown to be superior to more traditional immunohistochemical stains such as ER, PR, GCDFP-15 and mammaglobin A for detecting both primary and metastatic breast carcinomas in histologic specimens. GATA3 has been shown to be nonreactive in non-small cell lung cancer. We investigated the rate of GATA3 immunoreactivity in reactive and malignant mesothelial cells, and metastatic breast carcinoma, and its role in differentiating these entities from lung carcinoma.

**Design:** We evaluated GATA3 expression in 22 cases of reactive pleural effusions, and 29 cases of malignant pleural mesothelioma. We also investigated GATA3 and GCDFP-15 expression in 27 breast carcinomas. GATA3 was considered to be immunoreactive if there was nuclear staining of any intensity in > 5% of the cells of interest.

**Results:** Twelve of 14 primary breast carcinomas (86%) and 7 of 13 metaplastic breast carcinomas (54%) were immunoreactive for GATA3, compared to 10 of 14 (71%), and 4 of 14 (29%) for GCDFP-15. GATA3 immunoreactivity was maintained in all twelve metastatic pairs (100%) whereas GCDFP-15 immunoreactivity was maintained in 10 of 12 (83%) pairs. Ten of 29 (34%) malignant mesotheliomas were immunoreactive for GATA3 with 7 of 29 (24%) showing at least moderate intensity reactivity. No GATA3 reactivity was seen in any of the reactive mesothelial cells.

**Conclusions:** As previously demonstrated GATA3 is more helpful in identifying breast carcinomas, including metastatic triple negative and metaplastic breast carcinomas than GCDFP-15. As expected GATA3 was non-reactive in all cases of reactive mesothelial cells. Interestingly GATA3 was immunoreactive in a subset of malignant pleural mesotheliomas. Furthermore, GCDFP-15 immunoreactivity is often only focal, while GATA3 reactivity is nuclear and more diffuse making it more reliable and easier to interpret. When used singly GATA3 has limited utility for differentiating the aforementioned entities, however in the proper clinical setting it can be a valuable addition to a small panel of antibodies composed of calretinin and TTF-1 to differentiate between mesothelioma and adenocarcinoma of the breast and lung.

**459 Human Papilloma Virus Genotype 53 (HPV53): High or Low Risk? Follow-Up in Our Institution**

*A Navarro, P Jimenez, R Palhua, J Hernandez-Losa, C Iglesias, M Alberola, C Dinare, S Ramon y Cajal, N Tallada.* Vall d'Hebron University Hospital, Barcelona, Spain.

**Background:** Cervicovaginal high-risk HPV persistent infection is a key factor in the development of cervical cancer. In different studies, HPV53 has been considered and/or classified as an intermediate/high risk virus, although its isolated presence in dysplastic lesions has been scarcely reported. Our aim was to evaluate the cytological results in women with an exclusive HPV53 infection and their follow-up.

**Design:** 94 women aged between 17 and 64 years (mean 38.2 years) with exclusively HPV53 infection were selected in our institution in a period of 6 years. Interpretation of cytology results was performed using the Bethesda criteria. HPV detection was performed in liquid cytologies (Clart®HPV2, Genomica) with PCR amplification of specific viral genome fragments and subsequent hybridization with specific probes for the 35 genotypes of greatest clinical importance. The initial cytological diagnosis and its subsequent controls were analyzed over a period of 1 to 6 years (with a mean follow-up of 3 years).

**Results:** From 94 cases, 53 has a first negative report and 41 has a first abnormal cytology: 17 ASC-US, 23 L-SIL and 1 H-SIL. To evaluate the follow-up we have defined four groups: I. Patients with persistent negative cytology 43.62% (41/94). II. Patients with isolated abnormal cytology and subsequent negative results 24.46% (23/94). III. Patients with persistent abnormal cytology that becomes negative 11.70% (11/94). IV. Patients with persistent abnormal cytologies 20.22% (19/94).

**Conclusions:** HPV53 behaves as a low risk virus in our series and in our demographic area because 79.78% of patients had a normal cytology from the beginning of HPV53 infection (43.62%) or were regressed over time (36.16%). Only 20.22% (19 patients) had a persistent abnormal cytology in their follow-up. Most of these lesions were ASC-US or L-SIL and only one case developed H-SIL histologically confirmed and it becomes negative after therapeutic conization. Our experience supports the reclassification of HPV53 as low risk HPV virus, but further studies and follow-up are needed to confirm our impression.

**460 NapsinA/p40 Antibody Cocktail to Distinguish Adenocarcinoma from Squamous Cell Carcinoma of the Lung on Cytology and Small Biopsy Specimens**

*M Nishino, M Hoang, C Boussahmain, P Della Pelle, V Morales-Oyarvide, EJ Mark, M Mino-Kenudson.* Beth Israel Deaconess Medical Center, Boston, MA; Massachusetts General Hospital, Boston, MA.

**Background:** Subtyping non-small cell lung carcinomas (NSCLC) into adenocarcinoma (ACA) or squamous cell carcinoma (SQCC) is critical for treatment and specimen triaging for molecular studies. However, subtyping NSCLC can be difficult in cell block/small biopsy specimens. Recent studies have shown that TTF-1, NapsinA (NapA), cytokeratin 5/6 (CK5/6), and Anp63 (p40) antibodies are specific for distinguishing lung ACA and SQCC. To preserve tissue for molecular studies in cytology/small biopsy specimens, we developed a two-antibody cocktail for single-slide subtyping of NSCLC.

**Design:** Semiquantitative analysis of TTF-1, NapA, CK5/6, and p40 expression was performed on tissue microarrays (TMA) of 142 lung ACA and 102 SQCC. Pairs of complementary markers (nuclear vs. cytoplasmic) were evaluated, and the NapA/p40 combination was selected as a specific marker for NSCLC subtyping. The specificity and sensitivity of the NapA/p40 cocktail for subtyping NSCLC was determined in the TMAs, and its performance was validated on a new cohort of 87 cellblock/small biopsy specimens of poorly differentiated NSCLC. The subtype of the subsequent resection specimen (49 ACA, 28 SQCC, 6 large cell carcinomas [LCC], 1 pleomorphic carcinoma [PC], and 3 adenosquamous carcinomas [ASQ]) served as the gold standard for evaluating the accuracy of the NapA/p40 cocktail.

**Results:** TMA analysis showed that the NapA+/p40± immunophenotype identified ACA with 94% sensitivity and 100% specificity, while NapA-/p40+ identified SQCC with 98% sensitivity and 100% specificity. Double-negative staining was seen in only a few tumors. Seven ACA were positive for both NapA and p40, five of which showed coexpression of these markers in the same tumor cells. On a validation cohort of cellblocks/small biopsies, the NapA/p40 cocktail subtyped NSCLC on a single slide in 67/87 (77%) of cases. Of cases that could not be subtyped by the cocktail, 17 were NapA-/p40- (8 ACA, 5 LCC, 2 SQCC, 1 PC, and 1 ASQ on subsequent resection) and 1 was NapA+/p40+ (LCC). Two additional cases of ASQ were not classified as such based on the cocktail staining pattern (1 case each of NapA-/p40+ and NapA+/p40-).

**Conclusions:** A NapA/p40 two-antibody cocktail can subtype NSCLC into ACA and SQCC with high specificity in a majority of cellblock/small biopsy specimens of poorly differentiated NSCLC. In the minority of cases where the NapA/p40 immunophenotype is indeterminate, additional stains may be necessary for precise classification.

**461 Molecular Testing on Cytology Smears: The Assessment of Mutational Detection and Analysis of EGFR in Pulmonary Adenocarcinoma**

*L Ogden, A Miller, R Pyles, V Schnadig, R Nawgiri.* University of Texas Medical Branch, Galveston, TX; Galveston National Laboratory, Galveston, TX.

**Background:** Current recommendations for testing *EGFR* mutations in pulmonary adenocarcinoma (PA) are based on formalin fixed paraffin embedded material (FFPE). However, 75% of Lung cancers present as clinically advanced disease and are frequently diagnosed by cytology. FFPE (cell block or core biopsy) is not always obtainable. The purpose of this study is to design *EGFR* pyrosequencing assays for diverse cytology samples from PA for eventual in-house routine testing and to investigate *EGFR* mutational variances with next-generation sequencing analysis for potential correlation tumor clinical behavior and therapeutic outcome.

**Design:** Electronic search for PA from 2000-2009 with ready-for-discard slides was conducted. Slides that contained cellular material with >20% tumor and minimal normal bronchial contaminant or necrosis were selected. Bronchoalveolar lavages (BALs), bronchial brushes (BB), and fine needle aspirations (FNAs) were included. DNA amplification and pyrosequencing was conducted with study-designed primers to target *EGFR* exon 19 deletions and exon 21 point mutations or single nucleotide polymorphisms with human *GAPDH* as an internal control. 4 negative cytology slides and 5 known FFPE L858R-positive (exon 21) were used as controls.

**Results:** After review of slides from 112 patients, 63 samples from 43 patients were selected for *EGFR* testing and included 29 air-dried Romanowski stained and 34 ethanol-fixed Papanicolaou stained slides. PCR amplification was successful in all samples. Pyrosequencing was successful in cases with as few as 9 neoplastic cells. All FFPE L858R-positive samples and all negative samples were confirmed. Limit of detection mixing studies were also performed. Exon 19 sequencing was possible in 94% (59/63) of test cases. Two experimental deletions were detected. Exon 21 sequencing was achieved in 95% (60/63) test samples. Four experimental mutations were detected: 3 L858R and 1 L858M. All L858R mutations were confirmed. The L858M mutation was proven to be L858Q on verification and cloning.

**Conclusions:** *EGFR* hotspot codons can be successfully amplified and genotyped in cytology samples. DNA amplification was not limited by specimen age or type of fixation. Use of cytologic samples for molecular testing is a valuable asset to patients because it could preclude the necessity for repeat invasive procedures.

**462 Utility of Immunohistochemistry to Differentiate Gastrointestinal Contaminant from Mucinous Neoplasms on Fine Needle Aspiration Cell Blocks of Pancreatic Cystic Lesions**

*JL Olivella, N Fukami, C Marshall, SB Sams.* University of Colorado, Aurora, CO.

**Background:** Mucinous neoplasms (MN) of the pancreas include intraductal papillary mucinous neoplasms (IPMN) and mucinous cystic neoplasms (MCN). Subtypes of IPMN have varied rates of progression and specific profiles of MUC gene expression. Endoscopic ultrasound guided (EUS) fine needle aspiration (FNA) is an established procedure to obtain diagnostic fluid and tissue to diagnose pancreatic MNs, however, differentiating these entities from normal gastrointestinal (GI) and benign pancreatobiliary (PB) epithelium may be difficult. We evaluated an immunohistochemical panel of antibodies as an adjunct to differentiate MN from benign contaminant.

**Design:** Immunohistochemical (IHC) analysis with MUC1, MUC2, MUC5AC and MUC6 was performed on FNA cell blocks containing GI contaminant only (N=10; fluid CEA <5ng/mL; mean=2.4ng/mL) and FNA cell blocks from MN (N=10; IPMN=8, MCN=2). Selected MNs included subtypes intestinal (n=4), gastric (n=2) and pancreatobiliary (n=2) and were confirmed by histologic specimen with appropriate MUC profile. IHC was scored as: negative <10%, focal 10-50%, and positive >50%.

**Results:** IPMNs showed appropriate immunoprofile of Intestinal type (MUC1+/-, MUC2+, MUC5AC+, MUC6-). Gastric type (MUC1-, MUC2-, MUC5AC+, MUC6+), and pancreatobiliary (MUC1+, MUC2-, MUC5AC+, MUC6+). MN's showed an indeterminate profile (MUC1+/-, MUC2-, MUC5AC+, MUC6-). Non-neoplastic showed appropriate staining pattern for the type of epithelial contaminant.

IHC Profile of Contaminant

Age/Sex	MUC1	MUC2	MUC5AC	MUC6	MUC profile
51/M	focal	-	+	+	Gastric
55/F	-	-	+	-	Foveolar
53/M	+	-	-	+	Pancreatobiliary
52/F	+gastric/-SI	-gastric/+goblet	-gastric,-SI	+gastric/-SI	Gastric and SI
83/F	focal	-	+	+	Gastric and Foveolar
49/F	-	-	+	-	Foveolar
51/F	focal	-	+foveolar,-gastric	+gastric/-foveolar	Gastric and Foveolar
44/M	focal	-	+	+	Gastric
46/F	-	-foveolar/+goblet	+foveolar/-gastric	-	SI and Foveolar
46/M	+	-	-	+	Pancreatobiliary

**Conclusions:** GI and non-neoplastic PB contaminant had a predictable MUC staining pattern supporting the morphologic impression of contaminant and is distinct from intestinal type IPMN. However, it is limited by inability to differentiate contaminant from gastric or pancreatobiliary type IPMN. MUC IHC panel has utility as an adjunct to differentiate non-neoplastic epithelium from intestinal type IPMN and could prove useful at identifying a specific subset of patients for selecting appropriate management strategies.

**463 Towards a Tissue Management Diagnostic Algorithm Incorporating Molecular Profiling in Cytological Samples: Clinical Utility of the 92-Gene Assay to Identify Tumor Type and Direct Predictive Biomarker Testing**

*TN Operana, BE Schroeder, CA Schnabel.* bioTheranostics, Inc, San Diego, CA.

**Background:** Tissue preservation to afford comprehensive molecular and genomic analyses of patient material is critical for individualized cancer management. Tissue-sparing platforms, such as the 92-gene assay which requires approximately 300 cells for molecular diagnosis of tumor type and subtype, may improve the efficiency of tissue usage as a complement to immunohistochemistry (IHC) in cases with limited diagnostic material. In this study, the reporting rate and utility of molecular classification in cytology specimens, as well as the frequency of directed predictive biomarker testing, were examined.

**Design:** The analysis included 644 FFPE cytopathology cases (fine needle aspirates, pleural effusions, ascites) with indeterminate diagnosis in which the 92-gene assay

(CancerTYPE ID, bioTherapeutics, Inc.) was used in standard clinical care. The 92-gene assay reporting rate and tissue availability to perform downstream biomarker testing were analyzed.

**Results:** The 92-gene assay provided a molecular diagnosis in 87% (n=558) of cytopathology specimens submitted for diagnostic testing. Twenty-three distinct tumor types were predicted including: 19% pancreaticobiliary (n=105) 11% lung (n=60), 9% ovary (n=49), 8% urinary bladder (n=47), 7% gastroesophageal (n=39), 5% intestine (n=30), 4% breast (n=24) and 1% melanoma (n=6). In 102 patients with molecular diagnoses where reflex biomarker testing was applicable (lung, colorectal, gastric, breast, melanoma), 32% of cases had additional predictive biomarker testing performed, and 2 or more biomarker tests were performed on 52% of these cases. The most common biomarker tests performed were EGFR mutations (n=18), KRAS mutations (n=10), BRAF mutation (n=8), and ALK rearrangement (n=7).

**Conclusions:** These findings demonstrate the suitability and high reporting rate of the 92-gene assay in limited tissue cytological specimens and successful predictive biomarker testing in appropriate cases. With the growing number of molecularly-targeted therapies requiring predictive biomarker testing, use of the 92-gene assay may have increased utility in cancer cases where limited tissue specimens are the only option for diagnosis and treatment planning.

#### 464 Low Grade Squamous Intraepithelial Lesion Morphology Correlates with High-Risk HPV Status

*LN Parsons, N Rao, B Hunt.* Medical College of Wisconsin, Milwaukee, WI.

**Background:** Cervical cytology is essential in identifying precursor lesions of squamous cell carcinoma. Human papillomavirus (HPV) molecular testing helps stratify patient risk for development of cancer. We have observed that low grade squamous intraepithelial lesions (LSIL) display a wide morphologic spectrum and postulated that this variation may be due in part to high-risk (HR) HPV infection status in these patients. Therefore, we sought to systematically examine cases of LSIL with concurrent HPV molecular testing to determine whether there are significant cytomorphologic differences between HR HPV positive LSIL and HR HPV negative LSIL.

**Design:** A database search identified cases diagnosed as LSIL with concurrent HPV molecular test results from 2008-2012. Each case was reviewed to confirm LSIL diagnosis per Bethesda Criteria and for the presence of the following: koilocytes, binucleation, multinucleation, karyorrhectic debris, and cytomegaly (defined as overall cell size >1.5x normal intermediate squamous cell). Koilocytes were defined according to degree of cytoplasmic clearing as follows: Type 1 – clearing encompassing > ½ cell cytoplasm, and Type 2 – clearing encompassing < ½ cell cytoplasm. Chi square analysis and Fischer's exact test were used for statistical analysis.

**Results:** 82 HR HPV positive LSIL cases and 75 HR HPV negative LSIL cases were identified. 80.5% of HR HPV positive cases had koilocytes compared with only 53.3% of HR HPV negative cases (p=0.0003). In cases with koilocytes, Type 1 koilocytes were more commonly seen in HR HPV positive cases (69.7% vs 27.5%, p<0.0001); conversely, Type 2 koilocytes were more frequently present in HR HPV negative cases (72.5% vs 30.3%, p<0.0001). Karyorrhectic debris was less frequent in HR HPV positive cases (30.5% vs 52.0%, p=0.0091). Binucleation and multinucleation were both more commonly seen in HR HPV positive cases (67.1% vs 30.2%, p= <0.0001 and 22.0% vs 6.67%, p=0.0071). Cytomegaly was not statistically significant (30.5% vs 25.3%, p=0.4836).

**Conclusions:** Our study indicates that koilocytes and bi- and multinucleate cells are more frequently associated with HR HPV positive LSIL. Furthermore, Type 1 koilocytes are more strongly associated with HR HPV positive LSIL while Type 2 koilocytes are more often associated with HR HPV negative LSIL. These morphologic characteristics may provide clues to patients who are at high risk for progression to more advanced squamous epithelial lesions and could help guide additional testing and patient management.

#### 465 The Utility of Repeated Cytologic Evaluation of CSF Fluid in Individuals with Metastatic Breast Cancer

*JB Patel, J Xing, D Deeds, GT Budd, CN Booth, FW Abdul-Karim.* Cleveland Clinic, Cleveland, OH.

**Background:** Approximately 30% of all patients with localized breast cancer develop metastatic disease, and of them 10-16% may develop symptomatic brain metastasis. Cytologic evaluation of cerebral spinal fluid (CSF) is submitted for confirmation of metastatic disease, or to monitor response to intrathecal chemotherapy (ITC). There is little literature and no standard guidelines for repeated CSF cytologic evaluation. We evaluated the utility and rationale for repeated CSF cytologic evaluation in women with metastatic breast cancer.

**Design:** A retrospective review of the Anatomic Pathology database was performed for all adenocarcinoma cases diagnosed by CSF cytology from 1990 thru 2012. Electronic medical records were reviewed and the following data were recorded: age (> or < 60 years old), number of repeated CSF cytology specimens, radiologic findings (radiographic mass lesion (RML) vs. no radiographic mass lesion (NRML)), and treatment modality (ITC or whole brain radiotherapy (WBRT)).

**Results:** Within the search interval there were 92 patients with CSF cytology specimens with a diagnosis of adenocarcinoma. Of these, 51 (55.4%) had metastatic breast cancer and 41 (44.6%) had other malignancies. Of the 51, 23 (45.1%) had multiple CSF cytology samples (range 2-25, mean= 5.5). Six (26.1%) patients > 60 years old and 17 (73.9%) patients < 60 years old had multiple CSF cytology samples. Of the 51 cases, 9 (17.6%) had a RML (range 1-4), 28 (54.9%) had NRML, and 14 (27.5%) had no clinical data. No patients with mass lesions had multiple CSF cytology samples, while 17 (60.7%) patients with NRML had multiple CSF cytology samples. Twenty-seven (52.9%) WBRT and ITC combined treatment cases involved patients < 60 years, and only 3 (11.1%) had only one CSF cytology sample. Despite interval negative CSF

cytology specimens, all patients with multiple samples had persistent positive cytology. The average survival time after the first CSF sample was 3.6 months in the 29 patients with information available.

**Conclusions:** All patients with multiple CSF cytology samples were in those with NRML. Possibly a result of an aggressive treatment strategy, patients younger than 60 years old had a greater tendency to receive intrathecal chemotherapy, each requiring removal of CSF prior to injection; thus, submitting multiple CSF cytology samples. Despite interval negative CSF cytology samples, all patients had persistent positive cytology. The majority of patients had a poor prognosis with an average survival time of 3.6 months.

#### 466 Characterization of Parainfluenza Virus Type 3 Cytopathic Changes in Bronchial Fluid Cytology

*J Peltola, E Sell, K Amin.* University of Minnesota, Minneapolis, MN.

**Background:** Viral cytopathic changes of certain viruses are poorly defined and are underdiagnosed in bronchial fluid cytology. Parainfluenza virus type 3 (PIV-3) is a common respiratory virus occurring most frequently in the spring and summer months. It is a member of the Paramyxoviridae family of viruses that until recently, has not been described in bronchial fluid cytology. The aim of this study was to analyze bronchial fluid cytology for viral cytopathic changes in patients with positive PIV-3 respiratory viral cultures. In this study, we describe characteristic and reproducible viral cytopathic changes yet to be established for PIV-3.

**Design:** A retrospective search was performed on all patients with positive PIV-3 respiratory shell vial cultures and concomitant bronchial fluid cytology from January 2009 – July 2013. The patient's original diagnoses were reviewed and the Papanicolaou stained slides were examined for characteristic cytopathic changes.

**Results:** Of the 3427 bronchial fluid cytology specimens identified during the study period, 26 cases (19 patients) had concomitant respiratory shell vial cultures positive for PIV-3. Viral cytopathic changes were identified in 17 of the 26 cases (65%). None of the cases with cytopathic changes were diagnosed in the original report. All cases positive for viral cytopathic changes were generated from immunocompromised patients undergoing bronchial washings/lavage within the months of January – September. Two predominant cytopathic features were identified. The most characteristic finding was that of syncytial cells showing multiple hyperchromatic nuclei and numerous round, pink cytoplasmic inclusions. Also identified were individual columnar cells that displayed a single hyperchromatic nucleus with cytoplasmic inclusions identical to those seen in the syncytial cells. The majority of the cases with PIV-3 cytopathic change contained both cytopathic features (10 cases) with 3 cases showing only cytopathic syncytial cells and 4 cases showing only cytopathic columnar cells.

**Conclusions:** PIV-3 exhibits characteristic cytopathic changes seen mostly in immunocompromised patients during the high incidence infective period that can be identified in bronchial fluid cytology.

#### 467 Ocular Malignant Melanoma Diagnosed by Fine Needle Aspiration Biopsy: Incidence of Metastases and Morphologic Survival Analysis

*CM Perrino, BT Collins, JF Wang.* Washington University, St. Louis, MO.

**Background:** Ocular malignant melanoma (MM) is the most common primary intraocular malignancy in adults and frequently biopsied by FNA during radioactive plaque insertion. We review ocular FNA biopsy to examine the rate of metastases and impact of morphology on overall survival.

**Design:** A search of the pathology database for ocular FNA biopsies was performed (1998 to 2012). Data collected from reports included patient sex, age, race, and diagnosis. Chart review determined treatment, metastases, follow-up, and death. Survival analysis was performed using Kaplan-Meier survival curves followed by log-rank test for trend with GraphPad Prism (v6.02 Windows).

**Results:** 454 cases of ocular FNA biopsies from 441 patients were identified. Diagnoses were as follows: MM in 274/454 (60.4%), suspicious for MM (5.3%, 24/454), and alternative diagnosis (34.4%, 156/454). The majority of MM cases were the mixed cell subtype (44.9%, 123/274). Among 156 cases with alternative diagnoses, 38.5% (60/156) were non-diagnostic, 12.2% (19/156) atypical, 33.3% (52/156) benign, 14.7% (23/156) positive for non-melanoma malignancy, and 1.3% (2/156) were suspicious for malignancy. 12.8% (35/274) of patients with FNA biopsy-proven MM developed metastases, most frequently to the liver (91.4%, 32/35). 8.3% (2/24) cases suspicious for melanoma developed metastases. 8.3% (13/156) of cases with atypia/non-diagnosis developed metastases, most commonly to the liver (38.5%, 5/13), lung (38.5%, 5/13), and brain (23.1%, 3/13). Of 23 cases of non-melanoma malignancy, 70% (16/23) were metastatic carcinoma and 21% (5/23) were malignant lymphoma. Of the 16 carcinoma cases, lung was the most common primary followed by the gastrointestinal tract. Survival analyses comparing the histologic subtypes of MM showed patients with the epithelioid subtype had the lowest overall survival rate, with a median survival of 66.9 months.

MM Subtypes		
	MM	Suspicious for MM
Epithelioid	68	4
Spindle Cell	63	4
Mixed	123	1
NOS	20	15

Metastases							
	Adrenal	Bone/ST	Brain	Liver	Lung	LN	Other
MM	1	12	2	32	10	3	5
Suspicious for MM	0	0	0	1	0	0	1
Atypical	0	0	0	0	0	0	0
Benign	0	2	1	1	2	1	0
Non-Diagnostic	0	0	1	3	2	0	0
Carcinoma	1	1	1	2	1	1	0
Lymphoid	0	0	0	0	0	0	0
Malignancy NOS	0	0	0	0	0	0	0
Suspicious for Malignancy	0	0	0	0	0	0	0

**Conclusions:** Ocular FNA biopsies were frequently diagnostic for MM. A minority of both melanoma and non-melanoma patients developed metastases, with the most common site being the liver. Lung was the most common primary site for ocular metastatic carcinoma. Patients with the epithelioid subtype of ocular melanoma on FNA had the lowest overall survival rate.

#### 468 Cytology as a Primary Diagnostic Modality for Lung Cancer. How Much Can We Offer? A Tertiary Care Center Retrospective Review

*MR Phillips, R Flowers, M Baliga, I Akhtar.* University of Mississippi Medical Center, Jackson, MS.

**Background:** Non-small cell lung carcinoma (NSCLC) is a leading cause of cancer-related death worldwide. Mississippi ranks fifth in the United States for lung cancer incidence and mortality rate, and first for male lung cancer death rate. Advances in lung cancer diagnostics and targeted therapy analysis place increased value on small cytology specimens. This study aims to review our recent experience with endoscopic and image-guided tissue biopsy and the role of cytopathologists in maximizing the diagnostic utility of these limited samples.

**Design:** A retrospective review of 560 consecutive patients (July 2010-September 2013) with thoracic endoscopic and/or image-guided fine needle aspiration (FNA) or needle core biopsy (NCB) was performed. Board-certified cytopathologists performed on-site specimen adequacy and determined final diagnoses. Cases were considered for molecular studies via clinician request and reflex protocols. Cytopathologists reviewed H&E slides of paraffin blocks for tumor cell adequacy. Blocks were subsequently sent to a reference laboratory for analysis of epidermal growth factor receptor (EGFR) mutations and anaplastic lymphoma kinase (ALK) gene rearrangements.

**Results:** 253 NCB and 307 FNA were retrieved. 340 men and 220 women ranging in age from 22-90 years were represented. Biopsy sites included 358 lung, 198 thoracic lymph node and 4 mediastinum. Cases were categorized as malignant (n=299), suspicious (n=17), non-diagnostic (n=50) and negative for malignancy (n=194). Malignant cases were comprised of 228 NSCLC, 29 small cell carcinoma and 42 other. NSCLC were further sub-classified with 89 squamous cell carcinoma, 101 adenocarcinoma, 5 adenocarcinoma and 33 NSCLC, NOS. Tumor cell adequacy was deemed sufficient in 38/54 NSCLC considered for molecular analysis. Analysis was attempted on all 38 specimens (34 adenocarcinoma, 4 NSCLC, NOS). 84% (31/37) of EGFR tests and 83% (29/35) of ALK tests were successful. 5 EGFR mutations and 1 ALK rearrangement were identified.

**Conclusions:** The role of cytology is critical in achieving current personalized medicine goals with minimally invasive, state of the art small tissue biopsy methods. On-site cytomorphologic adequacy assessment maximizes the diagnostic yield of endoscopic and image-guided FNA and NCB. Cytopathologists possess the expertise required to triage minute tissue samples, diagnose lung tumors with conservative ancillary testing techniques and assess tumor cell adequacy for molecular studies, thereby achieving personalized medicine goals in an efficient and cost-effective manner.

#### 469 MYB Immunostaining Is a Useful Ancillary Test for Distinguishing Adenoid Cystic Carcinoma from Pleomorphic Adenoma in FNAB Specimens

*M Pusztaszeri, PM Sadow, A Ushiku, TA McKee, WC Faquin.* Geneva University Hospital, Geneva, Switzerland; Massachusetts General Hospital, Boston, MA; Harvard Medical School, Boston, MA.

**Background:** The distinction between adenoid cystic carcinoma (ACC) and pleomorphic adenoma (PA) on fine-needle aspiration biopsy (FNAB) material is among the most common diagnostic problems, with significant clinical implications, in salivary gland cytology. Because of cytomorphological overlap, microscopy alone cannot always provide a definitive distinction. Recently, a specific translocation (t(6;9) involving *MYB* and *NFIB* genes has been identified in ACCs where it contributes to *MYB* overexpression. The aim of the study was to investigate the use of *MYB* immunocytochemistry in FNAB specimens as an ancillary test for distinguishing ACC from PA.

**Design:** We assessed the expression of *MYB* in alcohol-fixed cytological smears of histologically confirmed ACC (N=20) and PAs (N=20) using immunocytochemistry with a commercially available anti-*MYB* monoclonal antibody. The corresponding ACCs and PAs from formalin-fixed paraffin embedded (FFPE) surgical resection specimens were also immunohistochemically stained for *MYB*. The nuclear expression of *MYB* was assessed semi-quantitatively using a scoring system (from 0 to 6), combining the proportion and the intensity of staining. A score  $\geq 4$  was considered positive while a score  $\leq 3$  was considered negative.

**Results:** On FNAB material, 80% of ACCs (N=16/20) were positive for *MYB*. In contrast, all PAs (N=20/20) were negative for *MYB* (P<0.0001). The sensitivity and specificity of *MYB* for ACC relative to PA on FNAB were 80% and 100%, respectively. Results on corresponding histology were similar to cytology; however, there was often a zonal staining pattern with central areas of tumor (from 20 to 90%) lacking immunoreactivity. Thus, suggesting that *MYB* immunoreactivity was better maintained on FNAB material, possibly due to different fixation methods.

**Conclusions:** In contrast to PAs, a majority of ACCs are immunocytochemically positive for *MYB*. The test is more effective using alcohol-fixed FNAB material, and is potentially useful for the distinction of ACC from PA. Future immunohistochemical studies investigating the usefulness of *MYB* as part of a panel with other antibodies including *PLAG1* in distinguishing different basaloid neoplasms including ACC and PA on FNAB would also be useful.

#### 470 CD117 May Be Useful as an Ancillary Marker for Papillary Thyroid Carcinoma in FNAB Specimens

*M Pusztaszeri, PM Sadow, WC Faquin.* Geneva University Hospital, Geneva, Switzerland; Massachusetts General Hospital, Boston, MA; Harvard Medical School, Boston, MA.

**Background:** Few studies have evaluated c-KIT status in thyroid cancer and its potential role as a diagnostic marker, especially in fine-needle aspiration biopsies (FNABs). A downregulation of c-KIT has been shown in papillary thyroid carcinoma (PTC), which may be linked to the upregulation of some microRNAs. In this study, we investigated the potential diagnostic role of c-KIT (CD117) in FNAB specimens of PTCs using immunocytochemistry.

**Design:** We assessed the expression of CD117 in cytological smears of histologically confirmed PTC (n=35) and in a control group of benign thyroid nodules (BTN) (n=30) using immunocytochemistry with a monoclonal anti-c-KIT antibody. The corresponding PTCs and BTNs from surgical resection specimens were also immunohistochemically stained for CD117. The expression of CD117 was assessed semi-quantitatively using a previously described scoring system (from 0 to 5), combining the proportion and the intensity of staining, akin to the Allred and Remmele immunostaining scoring systems.

**Results:** On FNAB material, 74% of PTC cases (n=26/35) were completely negative for CD117 while 26% of PTC cases (n=9/35) had less than 2% of tumor cells faintly stained for CD117 (score 0). In contrast, all BTNs (n=30/30) were variably positive for CD117 (score 2-4); 100% (n=30/30) and 79% (n=23/30) of BTNs were faintly to moderately positive in at least 20% and 50% of the cells, respectively (P<0.0001). Results on corresponding histology were similar to cytology with 88.5% of PTC cases (n=31/35) being entirely negative for CD117 (score 0) and all BTN cases (n=30/30) being variably positive for CD117 (score 2-4). Normal follicular epithelium on histology was also variably positive for CD117, akin to BTNs (score 2-4).

**Conclusions:** CD117 is expressed by the normal follicular epithelium and in BTNs. In contrast, the expression of CD117 is absent or nearly absent in PTCs. This phenomenon is maintained in FNAB specimens, and as such, our results suggest that CD117 may be a useful marker for the cytologic diagnosis of PTC.

#### 471 Verification Bias-Adjusted Cervical Screening Test Sensitivity for Histopathologic High Grade Cervical Intraepithelial Neoplasia and Cervical Cancer in a Large Academic Womens Hospital Laboratory

*G Quiroga-Garza, A Onisko, RM Austin.* Magee-Womens Hospital of University of Pittsburgh Medical Center, Pittsburgh, PA.

**Background:** Sensitivity estimates for screening tests based only on patients with verified disease are generally inflated by verification bias (VB). In published data from the ATHENA study, VB adjustment using Zhou's method decreased calculated cervical screening tests sensitivity for detection of histopathologic high grade cervical intraepithelial neoplasia or more severe lesions (CIN2+) by around 30%.

**Design:** The database of Magee Women's Hospital (MWH) was examined from Jan 1, 2005 to Aug 31, 2012, including 730,800 cervical Pap test results, 179,768 Hybrid Capture 2 (HC2) Human Papillomavirus (HPV) test results, and 48,165 cervical histopathologic results. Histopathologic cervical diagnoses were identified in patients recently screened ( $\leq 1$  year) with Pap and HPV testing as correlated screening tests. Zhou's method utilizing a maximum likelihood estimator was then applied to the MWH database to estimate VB-adjusted cervical screening tests' sensitivity for CIN2+.

**Results:** Within one year of prior cervical screening test results 1,643 histopathologic CIN2+ diagnoses were documented after 1,567 HPV(+)/abnormal (ASCUS+) Pap results, 55 HPV(-)/Pap(+) results, 16 HPV(+)/Pap(-) results, and 5 HPV(-)/Pap(-) results. Within one year of prior cervical screening test results, 18,691 benign or CIN1 histopathologic diagnoses were documented after 11,773 HPV(+)/Pap(+) results, 3,906 HPV(-)/Pap(+) results, 369 HPV(+)/Pap(-) results, and 2,643 HPV(-)/Pap(-) results. Patients without both Pap and HPV test results were not included. No cervical histopathologic follow-up diagnoses were documented after 159,481 cervical screening tests. The estimated VB-adjusted Pap sensitivity for histopathologic CIN2+ was 94.3% compared to crude unadjusted Pap sensitivity of 98.7%. The estimated VB-adjusted HPV sensitivity for histopathologic CIN2+ was 79.7% compared to a crude unadjusted HPV sensitivity of 96.3%.

**Conclusions:** VB adjustment decreased estimated cervical screening test sensitivity. VB-adjusted Pap sensitivity for CIN2+ around 94% has only been documented in a few other published studies, including one earlier study from MWH using different mathematical methods for VB adjustment. Estimated VB-adjusted HC2 HPV sensitivity of 79.7% for CIN2+ detection was higher than the 61.7% calculated VB-adjusted CIN2+ sensitivity published in the ATHENA trial.

#### 472 Thyroid FNA Sample *NRAS61*, *HRAS61*, and *KRAS12/13* Mutation Subtypes Show Contrasting Cytopathologic and Histopathologic Characteristics

L Radkay, SI Chiosea, RR Seethala, SP Hodak, L Yip, KL McCoy, SE Carty, KE Schoedel, MN Nikiforova, YE Nikiforov, NP Otori. University of Pittsburgh Medical Center - Presbyterian, Pittsburgh, PA.

**Background:** Point mutations in *RAS* gene result in activation of the MAPK and alternate signaling pathways. They are seen commonly (up to 50%) in follicular patterned lesions and are associated with carcinoma outcome in approximately 80% of cases with these mutations. While previous studies have investigated the clinico-pathologic features of *RAS* mutated thyroid nodules, specific cytopathologic and histopathologic features of the subtypes (*NRAS61*, *HRAS61*, and *KRAS12/13*) have not been investigated.

**Design:** Malignant, indeterminate, and selected benign thyroid cytology cases were tested for the presence of *RAS* mutations. Thyroid cytopathology FNA cases demonstrating *NRAS61*, *HRAS61*, and *KRAS12/13* mutations were identified in our cytopathology files from September 2008 to June 2013. For each case, the Bethesda System thyroid cytopathology diagnosis, additional cytologic descriptors, and the surgical pathology outcome were documented. Fisher exact test was used for statistical comparison between the groups.

**Results:** One-hundred ninety-eight (198) thyroid FNA cases with *NRAS61*, *HRAS61*, and *KRAS12/13* mutations with corresponding surgical pathology resection specimens were identified. Correlation with cytologic and histologic features are shown in the table below.

Correlation of *RAS* mutations and cytologic and histologic features

Pathologic Features	<i>NRAS61</i>	<i>HRAS61</i>	<i>KRAS12/13</i>	Statistical difference between groups
Cytology with FNHCT Diagnosis or Oncocytic Features Described	24/132 (18.2%)	2/44 (4.5%)	14/22 (63.6%)	p < 0.001
SP with Oncocytic features	22/132 (16.7%)	2/44 (4.5%)	18/22 (81.8%)	p < 0.001
SP with Carcinoma Outcome	112/132 (84.8%)	42/44 (95.5%)	9/22 (40.9%)	p < 0.001
SP with FVPTC	102/132 (77.3%)	37/44 (84.1%)	3/22 (13.6%)	p < 0.001

FNHCT: follicular neoplasm Hürthle cell type, SP: surgical pathology, FVPTC: follicular variant papillary thyroid carcinoma

**Conclusions:** Subtyping of *RAS* mutations in thyroid nodules has potential implications. *KRAS* mutations are more likely to be associated with oncocytic (Hürthle cell) features on cytology and surgical pathology specimens and are less likely to be associated with a carcinoma (in particular FVPTC) diagnosis. Nodules with *HRAS* mutation have a high probability of carcinoma outcome and are associated strongly with FVPTC. Nodules with *NRAS* mutation show features that are intermediate between *KRAS* and *HRAS*.

#### 473 Fine Needle Aspiration Cytology of Carcinoma Ex-Pleomorphic Adenoma: A Study of 20 Cases with Correlating Histopathology

M Rito, R Fonseca, I Fonseca, S Andre. Instituto Português de Oncologia de Lisboa Francisco Gentil, Lisboa, Portugal; Universidade de Lisboa, Lisboa, Portugal.

**Background:** Carcinoma ex-pleomorphic adenoma (CPA) is a rare malignant salivary gland tumor defined as a pleomorphic adenoma (PA) from which an epithelial malignancy is derived. The clinical utility of fine needle aspiration (FNA) in diagnosing salivary gland lesions is well established. However, the histologic complexity and morphological variability of this tumor may lead to interpretative difficulties on cytologic examination. In this study, we retrospectively analyzed the cytologic features of a cohort of histologically proven CPAs in order to characterize the diagnostic features of these tumors, emphasizing the diagnostic problems.

**Design:** A retrospective search of the archives of a tertiary care center, for a 31-year period (1982-2013), revealed fifty-eight cases of CPA, of which 22 had performed FNA. All clinical data, reports and all available cytology and histology slides were reviewed. Two cases were excluded as the material was insufficient for diagnosis.

**Results:** Eighteen tumors were from the parotid gland and 2 from minor salivary glands. A diagnosis of malignancy on FNA was performed in 65% of the cases, 10% were suspicious and 25% were negative for malignancy (diagnosed as PAs and 1 myoepithelioma). Ten patients had CPA with high-grade histological subtype carcinoma and 10 a low-grade subtype. The overall sensibility of FNA for neoplasia was 100% and for malignancy (or suspicious) of 75%. The high grade tumors were correctly diagnosed in 90% of the cases. On the contrary, the low grade carcinomas were suspicious only for malignancy in 20%, due to the presence of slight cellular atypia and abnormal matrix fragments, and negative in 40%. All the false negative cases had at least 25% of the lesion composed of PA area (range 25-63%). A diagnosis of CPA was achieved in 20% with unequivocal malignant cells in a background of biphasic components of PA.

**Conclusions:** FNA is an accurate technique for diagnosing high grade CPA. However, inadequate sampling and low grade malignancies still remain important pitfalls. Any degree of atypia in a PA and clinically suspicious cases should alert the cytopathologist to the possibility of a CPA.

#### 474 Cytologic Analysis of Lymphoproliferative Disorders in Body Cavity Effusions

V Robila, CG Uram-Tuculescu. Virginia Commonwealth University, Richmond, VA.

**Background:** Serous effusions are a common complication of lymphomas. Cytologic analysis of the fluid offers a rapid and optimal diagnostic tool; however, it poses diagnostic challenges because reactive lymphocytic effusions can mimic small cell lymphomas and large cell lymphomas may be hypocellular, with limited material for further testing. This study analyzes the diagnostic performance of cytologic examination of serous effusions with lymphocytosis (SEL), with special emphasis on atypical and malignant effusions, in order to evaluate the contribution of various ancillary methods to achieve a definitive and subtype specific classification.

**Design:** SELs with a final diagnosis of "lymphocytic effusion", "atypical lymphoid" or "lymphoma" were selected from cases diagnosed between 2008-2013. Site of involvement, immunohistochemistry (IHC) and flow cytometry (FC) findings, and follow-up with repeat fluid cytology and/or concurrent or subsequent tissue biopsy/ Fine Needle Aspirate (FNA) were recorded for all cases.

**Results:** 155 SEL cases were identified from 111 patients (4.3 % of all body cavity fluids). The most common site of involvement was pleural (84.5%), followed by peritoneal (11.6%) and pericardial (3.9%). The majority of SELs were benign (64.5%), 18.6% were diagnosed as atypical, and 16.9% as lymphomas. Additional sampling and/or ancillary studies were performed in 20% of the reactive fluids and a final diagnosis of lymphoma was rendered in 5% of cases. In contrast, in 36% of cases with atypical morphology, follow-up studies were essential for a definitive diagnosis of lymphoma, majority of which were established on tissue biopsy/ FNA (33%), with only 3% on subsequent fluid FC. Finally, fluid immunophenotyping was successful in rendering a specific lymphoma diagnosis in 88.4% of cases, with IHC and FC most useful for small B and T cell lymphomas and IHC alone for large B cell and Hodgkin lymphomas (see Table 1).

Table 1. Cytologic diagnosis for 52 SELs (percentage cases)

	Small cell cytology (61.5 %)	Large cell cytology (38.5 %)
Subtype	CLL (3.8%)	DLBCL (27%)
	MCL (27%)	HL (7.7%)
	FCL (7.7%)	ALCL (3.8%)
	BL (7.7%)	
	TCL (11.5%)	
	HCL (3.8%)	
Cytology + IHC	27%	30.8%
Cytology + FC	19.2%	0
Cytology + IHC+ FC	7.7%	3.8%
Cytology + concurrent biopsy/ FNA	7.7%	3.8%

CLL=Chronic Lymphocytic Leukemia, MCL=Mantle Cell Lymphoma, FCL=Follicular Cell Lymphoma, BL=Burkitt Lymphoma, TCL=T Cell Lymphoma, HCL=Hairy Cell Leukemia, DLBCL=Diffuse Large B Cell Lymphoma, HL=Hodgkin Lymphoma, ALCL=Anaplastic Large Cell Lymphoma

**Conclusions:** Our study indicates that a lymphoma diagnosis with specific subtyping can be achieved on SEL using cytology with ancillary studies. In contrast, repeat fluid sampling and ancillary studies performed on atypical effusions have only a marginal contribution in further characterization and these cases will require subsequent tissue sampling for additional work-up.

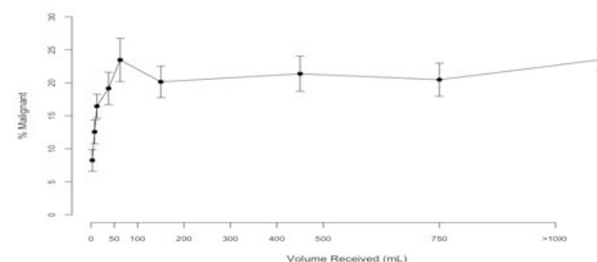
#### 475 A Minimum Volume of 50 mL Is Necessary to Ensure That a Pleural Effusion Is Benign: A Retrospective Review of 2,536 Cases

L Rooper, SZ Ali, MT Olson. The Johns Hopkins Hospital, Baltimore, MD.

**Background:** Although the importance of pleural fluid cytology for identifying malignant pleural effusion is well established, no consensus exists regarding optimal specimen volume. While no minimum volume is necessary if cytologic findings are malignant, the distinction between absence of disease and under-sampling of malignancy is not straightforward in low-volume specimens. Older literature suggests volumes of 250mL are necessary to ensure benign diagnoses, but recent papers conclude that as little as 25mL is sufficient. Moreover, no studies have previously evaluated the adequacy of a large series of pleurocentesis specimens across a wide distribution of volumes. We aim to determine the optimal volume of pleural fluid necessary for cytopathological diagnosis.

**Design:** We identified all 2,536 pleural fluid specimens received at our institution between January 2000 and December 2009 and tabulated their diagnoses and characteristics. Because the range of volumes received was large (1-6500mL), we binned the cases into nine groups of roughly equivalent sample sizes. We then calculated the malignancy fraction (percentage of cases with malignant diagnoses) for each group along with 95% confidence intervals, defined by the inverse square root of the bin count. Finally, we compared the malignancy fraction across all groups.

**Results:** The 2,536 pleural fluid specimens had a median volume of 200mL and an overall malignancy fraction of 19.9%. As shown in Figure 1, the malignancy fraction increased from 8.2(6.7-9.9)% for volumes less than 5mL to 23.4(20.2-26.8)% for volumes between 50 and 75mL, p=0.003. Specimens with volumes greater than 75mL had malignancy fractions that were independent of volume. Additionally, ratios of definitive benign or malignant diagnoses compared to non-diagnostic and atypical diagnoses continued to increase with volume.





**Conclusions:** A fluid volume of greater than 50mL is required to eliminate the influence of specimen size on diagnostic adequacy. While larger volumes do not impact malignancy fraction, they do correlate with a decreased rate of non-diagnostic and atypical results. This data suggests that submission of less than 50mL of a pleurocentesis specimen increases the risk of an indeterminate or false negative diagnosis.

#### 476 Fine-Needle Aspiration of Hurthle Cell Neoplasm: A Retrospective Cyto-Histologic Correlation of 224 Cases

*J Ross, D Chhieng, K Schofield, AJ Adeniran.* Yale University School of Medicine, New Haven, CT.

**Background:** Hurthle cell neoplasm is classified under the category of "follicular neoplasm" according to the Bethesda System. There are conflicting reports on the true rate of malignancy and behavior of lesions in this subcategory in comparison with follicular neoplasm (FN). The distinction between malignant and benign lesions still presents a diagnostic challenge on FNA. This study was designed to correlate the cyto-histologic findings in Hurthle cell neoplasm and to make a case for continued inclusion in the FN category.

**Design:** Based on retrospective review of cytologic diagnosis between January 2008 and December 2012, all thyroid FNA cases with the diagnosis of Hurthle cell neoplasm and the corresponding surgical pathology reports were reviewed. The cytologic criteria included a predominance of Hurthle cells and a lack of nuclear features of papillary thyroid carcinoma (PTC). Cases without corresponding thyroidectomies after FNA were excluded from the study. Demographic data and tumor characteristics were obtained from the reports. Based on the follow-up diagnosis, the risk of malignancy was calculated.

**Results:** A total of 224 cases of HCN were analyzed over a 5-year period, with the corresponding surgical pathology reports. The patient ages ranged from 12 to 85 years (median = 54 years). The female to male ratio was 3.5:1. The size of the lesions aspirated ranged from 0.1 cm to 7.0 cm (median = 1.9 cm). All the cases were diagnosed as Hurthle cell neoplasm on FNA. Distribution of cases on surgical resection were as follows: 59 malignant, 102 benign neoplastic and 63 benign non-neoplastic. Incidental microcarcinomas were identified in 6 of the benign cases. Seventeen of the malignant cases were diagnosed as Hurthle cell carcinoma, while PTC and medullary carcinoma accounted for 41 and 1, respectively. The overwhelming majority (101/102) of the benign neoplastic cases were Hurthle cell adenomas. Of the 63 cases diagnosed as benign non-neoplastic by FNA, there were 50 cases of goiter, 10 Hashimoto's thyroiditis, 2 hemorrhagic cysts and 1 treated Grave's disease. The 41 cases of PTC were distributed as follows: Classic variant -17; follicular variant -20; tall cell variant -3 and poorly differentiated -1. Thirteen malignant cases demonstrated vascular invasion, which was disproportionately more in Hurthle cell carcinoma. Two of ten PTC cases tested harbored BRAF mutation.

**Conclusions:** The risk of malignancy in HCN is 26%, therefore this risk of malignancy is within the 15-30% suggested for follicular neoplasm, as described in the Bethesda System for Reporting Thyroid Cytopathology.

#### 477 The Comparative Analysis of Molecular BRAF V600E with the Intensity of Immunocytochemical Positivity in Prospective Thyroid Malignant FNACs

*ED Rossi, M Martini, B Angrisani, P Straccia, T Bizzarro, C Ricci, A Pontecorvi, CP Lombardi, LM Larocca, G Fadda.* Catholic University of Sacred Heart, Rome, Italy.

**Background:** The diagnostic and prognostic role of the BRAF V600E mutation has been largely demonstrated in papillary thyroid carcinoma (PTC). Such mutation can be identified with DNA-based techniques which include both direct DNA sequencing and allele-specific Polymerase Chain Reaction (PCR). A new emerging antibody (VE-1) related to the BRAF V600E mutation has been developed and studied on both histological and cytological samples. The grading of its expression may represent a challenging issue mainly when a weak positivity is assessed. We investigated the correlation between the molecular and the immunocyto/histochemical (IHC) status of BRAF V600E in PTC.

**Design:** From January to June 2013, 55 prospective cytological samples were diagnosed as positive for malignancy on liquid based cytology (LBC). All the cases were histological confirmed as 7 tall cell variant (TCV), 11 follicular variant (FVPC) and 37 classic variant (PTC). All cases underwent mutational analysis (Pyrosequencing, Diatech, Italy) for BRAF V600E and immunocytochemistry for BRAF VE-1 (UCS Diagnostics, Italy) on LBC. The intensity was graded from 0 to 3+ (strong positivity) based on both the intensity of expression and its distribution in the tumor cells. Furthermore we evaluated the immunohistochemical results.

**Results:** Out of the 55 cases 36 were BRAF mutated and 19 wild-type (wt). The VE-1 expression resulted in 16 negative, 9 weak (1+), 16 moderate (2+) and 14 strong expressions (3+). All the 2+ and 3+ positive cases showed a perfect match with BRAF mutation. Four cases (7.2%) showed discrepancies between BRAF mutation and VE1 (both cytological and histological) expression including 1 BRAF wt with weak (1+) IHC expression and 3 mutated BRAF negative for VE1. Further four wt BRAF cases had a discordant immunocyto-histochemical VE1 correlation.

**Conclusions:** The VE1 BRAF antibody represents a valid alternative approach in the evaluation of BRAF-mutated PTC when a moderate or strong positivity is present. In our experience BRAF mutation is more accurate in diagnosing cases resulted VE1 negative whereas in cases with weak positivity, mainly histological diagnosed as FVPC, BRAF mutation shows less accurate results. VE-1 may be used as the first screening test for deciding of performing molecular analysis although rarer/complex BRAF mutations (not on codon600) or alterations of gene copy number cannot be evaluated by VE1.

#### 478 Scrape Preparation Cytology Shows Fewer Positive Margins Than Histologic Margin Assessment in Pancreatic Cancer Surgery

*RM Roth, PE Wakely, N Jones, M Bloomston, WL Frankel.* The Ohio State University Wexner Medical Center, Columbus, OH.

**Background:** Pancreatic cancer has a poor prognosis, and resection margin status impacts survival. Pancreatic (Pan) and uncinate/superior mesenteric artery (Unc) margins are vital in the assessment of Whipple resections, but cautery and fixation artifact can hamper assessment. Cytologic examination of margins can be performed on resection specimens or tissues left in the patient and may be more indicative of true margin status. Herein, we evaluated pancreas surgical margins to determine the concordance rates of cytologic versus histologic examination. Additionally, we compared specimen to in-situ margins by cytology.

**Design:** Fifty-five patients with pancreatic tumors who were undergoing surgical resection were studied at our institution. Eight had undergone neoadjuvant therapy. Both specimen and in-situ margins were evaluated using scrape preparation cytology and compared with traditional histologic evaluation for Pan and Unc resection margins.

**Results:** Six of 55 cases were discarded due to insufficient cytology. The cytologic specimen and in-situ margins were concordant at both margins in all cases. Of the 49 cases, 37 (76%) had concordant histologic and cytologic results. All discordant cases had positive histology, with either adenocarcinoma or high grade dysplasia (2 cases) at the corresponding margin, and negative cytology with 2 of 49 (4%) discordant Unc margins and 10 of 49 (20%) discordant Pan margins. To confirm that cells could be scraped from all tumors, scrape preparation was performed on the tumor in all 49 cases, and malignant cells were found in 43 (88%).

Cytology vs. Histology Margin Status

	Cytology	Histology
+ Pan Margin	0/49 (0%)	10/49 (20%)
+ Unc Margin	0/49 (0%)	2/49 (4%)

**Conclusions:** To our knowledge, this is the first study to compare in-situ to specimen margins using cytology in pancreatic cancer. We found that specimen and in-situ cytologic margin assessment is equivalent. Margin assessment by histology identifies a greater number of positive margins than evaluation by cytology. Discrepant cases could be due to false negative cytologic margins from extensive fibrosis, which could interfere with the scrape preparation. However, malignant cells were seen in scrape preparation from all tumors in discrepant cases. On the contrary, discrepant margins could be false positive histologic margins due to retraction after fixation. It remains unclear whether cytology or histology is a better measure of margin status, and outcome data will be essential.

#### 479 PAX 8 as a Reliable Marker to Differentiate a Reactive Mesothelial Cells from Metastatic Gyn Carcinoma in Serous Effusion Cytology

*AM Sanguino, Y Liu, A Mohanty, U Krishnamurti, J Silverman.* Allegheny General Hospital, Pittsburgh, PA.

**Background:** PAX 8 a transcription factor for the development of the kidney, Mullerian organs and thyroid has shown to be sensitive and specific marker for malignancies of Gyn origin. However, there is a single report of 2 of 23 (9%) peritoneal malignant mesotheliomas and 3 cases of well-differentiated peritoneal mesothelioma showing focal and weak staining for PAX8 (Laury A.R. et al., Am. J. Surg. Pathol. 2010;34:627-635). Since there is limited literature of PAX8 staining of reactive mesothelial cells in effusion cytology we analyzed 45 serous effusion specimens to determine PAX 8 positivity of reactive mesothelial cells.

**Design:** 45 benign body cavity serous effusions, consisting of 15 pleural, 15 pericardial and 15 cases each underwent immunohistochemical (IHC) staining for PAX 8. The Cell Marque, anti PAX8 (MRQ-50) mouse monoclonal primary antibody was utilized on FFPE cell blocks.

**Results:** In all specimens, the mesothelial showed weak, diffuse positive cytoplasmic staining, but diagnostic nuclear staining was not present.

**Conclusions:** 1) In contrast to a rare report of positive staining of PAX 8 in malignant mesothelioma and well-differentiated malignant mesothelioma, PAX8 is negative in reactive benign mesothelial cells.

2) Therefore, PAX 8 is an excellent IHC marker to differentiate metastatic Gyn malignancies in effusion cytology and should not be confused with reactive mesothelial cells.

#### 480 Abdominal Fat Pad Aspiration for Diagnosis of Systemic Amyloidosis: A Retrospective Review

*TA Saunders, A van Zante.* University of California San Francisco, San Francisco, CA.

**Background:** Fine needle aspiration of the abdominal fat pad (FNAFP) is a relatively noninvasive, rapid and economical method for detection of systemic amyloid deposition. Unequivocal diagnosis requires microscopic demonstration of amyloid deposition, which can be confirmed by evaluation of a Congo Red histochemical stain. Few published studies have reported the sensitivity and specificity of FNAFP for detection of systemic amyloidosis; methods are quite variable with reported sensitivities of 52-88%, with one study as low as 19%. No "gold standard" exists for the diagnosis of systemic amyloidosis, making the calculation of sensitivity and specificity problematic.

**Design:** The pathology database at our institution was searched for abdominal fat pad biopsies obtained via fine needle aspiration. FNAFP biopsy reports issued for 9 years (1997-2005) were collected and reviewed. Corresponding surgical specimens and clinical histories were reviewed (mean follow-up 9.2 years). Using tissue biopsy, immunohistochemistry, or autopsy results as the "gold standard," the false negative rate, sensitivity and specificity for FNAFP were calculated. In a second analysis, the sensitivity and specificity were also calculated including cases where follow up biopsies were not performed or a clinical diagnosis was not available, as this data likely represents cases in which the FNAFP diagnosis was in accord with the clinical impression.

**Results:** 170 FNAPF biopsies representing 165 patients were performed in the 9 years under study. 19 (11%) of the biopsies were interpreted as positive; 149 (88%) of the biopsies were interpreted as negative; 2 (1%) were insufficient for interpretation. Using tissue biopsy, immunohistochemistry, or autopsy findings as the "gold standard," the false negative rate was 56%; the sensitivity was 44%; the specificity was 100%. If cases where no surgical specimen or clinical diagnosis was available were included in the calculation, the sensitivity increased to 65%.

**Conclusions:** FNAPF biopsy is a relatively well-tolerated and economical option for the evaluation of systemic amyloidosis. As performed at our institution, this test has a relatively low sensitivity, but high specificity. Given its performance characteristics, clinicians should be aware through our reporting that false negative results are common and further evaluation (either through surgical biopsy or other clinical testing) is warranted when clinical concern persists.

#### 481 DOG1 Immunohistochemical (IHC) Analysis: A Useful Marker for Diagnosing Acinic Cell Carcinoma (AcICC) in Fine Needle Aspiration (FNA) Cell Blocks (CB)

AC Schmitt, C Cohen, MT Siddiqui. Emory University School of Medicine, Atlanta, GA.

**Background:** DOG1 is a calcium-activated chloride channel which may have a potential role in secretory cells of salivary gland, and tumors derived from them. Its role in cytologic specimens is not well documented. This study was performed to evaluate its role in detecting AcICC, which are derived from acinic secretory cells, and to see if it has utility in separating AcICC from other closely related differential diagnoses on cytologic samples.

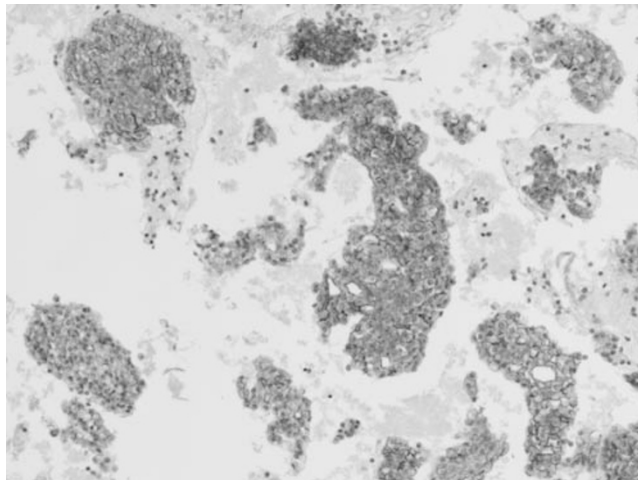
**Design:** 31 FNA CB of salivary gland neoplasms were selected: 10 AcICC, 16 Warthin's tumor (WT), 3 mucoepidermoid carcinoma (MEC), and 2 oncocytoma (ONC). DOG-1, P63, and S100 protein IHC was performed.

#### Results:

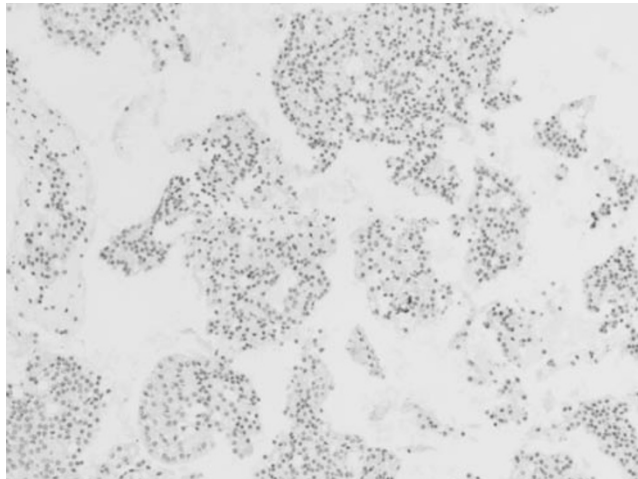
DOG-1, P63, and S-100 IHC in Oncocytic Salivary Gland Neoplasms

N=31	DOG-1 + (%)	P63 + (%)	S-100 + (%)
AcICC (10)	7/10 (70%)	0/10 (0%)	0/10 (0%)
WT (16)	0/16 (0%)	14/16 (87.5%)	0/16 (0%)
MEC (3)	0/3 (0%)	3/3 (100%)	0/3 (0%)
ONC (2)	0/2 (0%)	1/2 (50%)	0/2 (0%)

AcICC DOG1 IHC



AcICC P63 IHC



**Conclusions:** DOG1 expression was strongly detected in 70% of AcICC. The IHC staining was diffuse and intense, and displayed a membranous and cytoplasmic distribution. DOG1 was very helpful in separating AcICC from WT, MEC and ONC. The pitfalls to be aware of when using DOG1 to characterize AcICC is that benign

acini may display IHC expression and pose a diagnostic challenge. P63 and S100 IHC were negative in AcICC. Hence, this panel of stains may be helpful in confirming diagnostically challenging AcICC diagnoses.

#### 482 Mediastinal Germ Cell Tumor: A 20-Year Retrospective Study of 43 Cases Diagnosed by Fine Needle Aspiration Cytology

Q Shi, H Cramer, S Chen, R Emerson, X Wang. Indiana University School of Medicine, Indianapolis, IN.

**Background:** Image-guided fine needle aspiration (FNA) has routinely been used for diagnosing anterior mediastinal lesions. There are, however, only a few reports describing the use of FNA for the diagnosis of germ cell tumors (GCTs) at extragonadal sites. In this study, we retrospectively reviewed 43 cases of primary or metastatic mediastinal GCT diagnosed by FNA over a 20-year period and determined the accuracy and clinical utility of this diagnostic technique.

**Design:** A computerized search of our cytology database was performed from 1990 through 2010 and all FNAs of the anterior mediastinum diagnosed as germ cell tumors were identified. All cytology and correlating surgical reports as well as the clinical histories were reviewed and slides from selected cases were re-examined. Non-diagnostic FNA cases without correlating histology were not included in this study.

**Results:** A total of 43 cases of germ cell tumor diagnosed by FNA were retrieved and histologic correlation was available for 31 cases (72%). The FNA diagnoses were classified as: seminoma in 12 (28%) and non-seminomatous GCT in 31 (72%). Thirty-one non-seminomatous GCT cases included: 8 (26%) mixed GCTs, 9 (29%) yolk sac tumors, 8 (26%) teratomas, 1 (3%) embryonal carcinoma, 1 (3%) choriocarcinoma, and 4 (13%) unclassified malignancies. The FNA diagnoses for 7 of 12 (58%) seminomas had histologic confirmation. The FNA diagnoses for 24 of 31 (77%) non-seminomatous GCTs that had histologic correlation included 3 mixed GCTs (13%), 5 yolk sac tumors (20%), 6 teratomas (25%), and 4 malignancies (17%). Two teratomas (8%) were misdiagnosed by FNA; one proved to be a mesenchymal component of yolk sac tumor and the other was a case of lymphangioleiomyomatosis. The histologic diagnoses for 4 FNA cases diagnosed as malignancy included 1 seminoma, 2 choriocarcinomas, and 1 mixed choriocarcinoma with embryonal carcinoma. For 4 FNA cases (17%) (2 mixed GCTs, 1 yolk sac tumor, 1 embryonal carcinoma), histologic follow-up demonstrated only necrosis, a finding that was attributed to either chemotherapy effect or surgical pathology sampling error.

**Conclusions:** FNA is a minimally invasive method for diagnosing mediastinal germ cell tumors. In this study, the overall diagnostic accuracy for the FNA diagnosis of GCTs was high and the misclassification rate was low (5%). Therefore, FNA should be considered as the biopsy method of first choice for the diagnosis of mediastinal GCTs, particularly in the patients with a previous history of GCT.

#### 483 Anterior Mediastinal Lymphoma: A 20-Year Retrospective Review of 44 Cases Diagnosed by Fine Needle Aspiration Cytology

Q Shi, S Chen, H Cramer, R Emerson, H Wu, X Wang. Indiana University School of Medicine, Indianapolis, IN.

**Background:** The role of fine needle aspiration (FNA) cytology for the diagnosis of malignant lymphoma continues to be controversial. The accuracy and clinical value of FNA for the diagnosis of mediastinal lymphoma is assessed in this 20-year, retrospective, single-institution study.

**Design:** A computerized search of our pathology database was performed from 1990 to 2010 and all mediastinal lymphomas with correlating FNAs were identified. All FNA, correlating flow cytometry and surgical reports as well as the clinical histories were reviewed and slides from selected cases were re-examined.

**Results:** A total of 44 cases of mediastinal lymphoma sampled by FNA were identified and correlating histology was available for 33 cases (75%). The FNA diagnoses were positive (lymphoma) in 34 (77%) and non-diagnostic in 10 (23%). The 34 positive FNAs included 28 cases of non-Hodgkin lymphoma (82%), 5 cases of Hodgkin lymphoma (15%), and 1 case of granulocytic sarcoma (3%). The 28 cases of non-Hodgkin lymphoma were further subclassified into 16 large B-cell lymphomas, 2 low-grade B-cell lymphomas, 2 high-grade B-cell lymphomas, 2 B-cell lymphomas NOS, and 6 lymphoblastic lymphomas/leukemias. Histopathologic follow-up was available in 23 of 34 positive FNA cases (68%) including 11 large B-cell lymphomas (48%), 5 lymphoblastic lymphomas (22%), 3 Hodgkin lymphomas (13%), 2 B-cell lymphomas NOS (9%), and 1 granulocytic sarcoma (4%). One case of small cell carcinoma was misdiagnosed as large cell lymphoma by FNA (4%) and immunostains were not performed in this case. Follow-up histologic diagnoses for the 10 non-diagnostic FNA cases included 5 Hodgkin lymphomas (50%) and 4 non-Hodgkin lymphomas (40%) (3 large B-cell lymphomas, 1 mantle cell lymphoma). In 1 case (10%), the final histopathologic diagnosis was atypical lymphoid proliferation.

**Conclusions:** FNA is a safe and valuable method for the evaluation of patients with mediastinal lymphoproliferative disorders. When an adequate sample can be obtained, the overall diagnostic accuracy for the FNA diagnosis was 96%. Our one significant error occurring during this 20-year period could have prevented had confirmatory immunostains been performed. Of interest, in 11 of our 34 positive FNA cases (32%), treatment was initiated solely on the basis of the FNA diagnosis without a confirmatory surgical biopsy. When combined with immunophenotypic analysis by flow cytometry and/or immunocytochemistry, the FNA diagnosis of mediastinal lymphoma is highly accurate and can serve as a basis for treatment obviating the need for a major diagnostic procedure.

**484 Human Papillomavirus (HPV) Genotypes and Anal Squamous Intraepithelial Neoplasia (AIN)**

Q Si, AH Szepon, D Zhang, Z Zhang, F Salem, M Wu, N Patil, TL Kalir. Icahn School of Medicine, New York, NY.

**Background:** The incidence of anal squamous cell carcinoma has increased over the past 20-30 years, especially in high risk patients (HIV positive and/or men having sex with men). Anal cytology screening and HPV testing among high risk populations have been proposed. The purpose of this study is to investigate the association of HPV genotyping and cytologic diagnosis with histologic diagnosis and to provide fundamental information about how to manage patients with HPV positive abnormal cytology.

**Design:** Between 7/2012 and 3/2013, 344 patients had Papanicolaou-stained ThinPrep® anal slides diagnosed and HPV testing. Anal HPV genotyping was performed by real time polymerase chain reaction (cobas® HPV Test, Roche) and positive HPV results were reported as 16, 18 and Other (OhrHPV)) (12 high-risk HPV genotypes: 31/33/35/39/45/51/52/56/58/59/66/68). 200 patients had anal biopsy follow-up.

**Results:** In 344 patients (295 male, 49 female, age 19-79 years), the anal cytologic diagnoses were: Negative 88 (25.6%), ASCUS 174 (50.6%), ASC-H 9 (2.6%), LSIL 7 (19.5%) and HSIL 6 (1.7%). HPV infection was found in 280 patients (81.4%). By HPV genotyping, HPV 16, 18 and OhrHPV accounted for 22%, 17.3% and 60.7%, respectively. Of 200 patients with anal biopsy, the histologic diagnoses were: Negative 46 (23%), AIN1 76 (38%) and AIN2-3 78 (39%). Based on 200 biopsy results, the sensitivity, specificity, PPV and NPV was 87.1%, 52.1%, 86% and 60%, respectively. HPV infection was found in 69.6% of biopsy negative patients, 89.5% of AIN1 patients and 98.7% of AIN2-3 patients. AIN2-3 was found in 1 of 23 (4.3%) HPV negative patients, but in 78 of 172 (43.5%) HPV positive patients and AIN2-3 was detected in 26.4% of cytology negative patients, 48.4% of ASCUS patients, 47.5% of LSIL patients, 71.4% of ASC-H patients and 100% of HSIL patients. The sensitivity, specificity, PPV and NPV in HPV positive patients was 88.3%, 53%, 89.5% and 50% respectively. The distribution of HPV genotypes was similar regardless of biopsy results. However, co-infection of HPV (16 or 18 with OhrHPV) was significantly different, 37.5% in biopsy negative patients, 32.8% in AIN1 patients and 73.6% in AIN2-3 patients.

**Conclusions:** (1) Anal HPV infection is common in high risk patients and OhrHPVs are the most common genotypes detected in anal specimens. (2) AIN2-3 is more frequently found in HPV positive patients, especially in patients with abnormal cytology. (3) Co-infection of HPV in AIN2-3 is higher compared to lesion negative cases and AIN1. (4) Cytology and HPV testing together slightly improves the sensitivity, specificity, PPV compared to cytology only.

**485 Low Interobserver Agreement in Cytology Grading of Mucinous Pancreatic Neoplasms**

C Sigel, M Edelweiss, LC Tong, J Magda, H Oen, K Sigel, M Zakowski. Memorial Sloan-Kettering Cancer Center, New York, NY; Royal Alexandra Hospital, Edmonton, AB, Canada; Mount Sinai School of Medicine, New York, NY.

**Background:** Pancreatic mucinous neoplasms (MN) are often seen as small incidental lesions on radiology. Management has incorporated cytology to identify high risk lesions. High grade (HG) cytologic atypia has been shown to correlate with significant histology and accurate diagnosis may lead to timely resection. It is not clear whether cytologic atypia can be reliably assessed. We tested cytology interobserver agreement (IOA) in grading histologically confirmed MNs.

**Design:** 54 FNAs with MNs (N=44) or GI contamination sampled from a non-mucinous lesion (NML) (N=10) were included. Histology diagnoses included: IPMN low grade (LG) (N=4); MCN-LG (N=5); IPMN intermediate grade (IG) (N=14); IPMN-HG (N=10); IPMN with focal invasion (N=3); colloid carcinoma (N=5); adenocarcinoma (AD) (N=3); serous cystadenoma (N=6); chronic pancreatitis (N=4). 5-15 representative areas (RA) were marked on 1-6 slides (mean=2.6) including areas of highest atypia. Observers (3 cytopathologists, 2 cytotechnologists, 1 cytology fellow) received a tutorial on MN diagnosis/grading and clinical history for each case. Observers were blinded to the histologic diagnosis, independently reviewed RAs and recorded 1) diagnosis according to a 6-tiered system (TS): (nondiagnostic (NDX), atypical (ATP), mucinous cyst LG (MCLG), mucinous cyst HG (MCHG), suspicious for AD (SPA), positive for AD (PA)); 2) if diagnosis changed with CEA (CEADX); and 3) presence of neoplastic mucin. IPMN-IG was considered MCLG in the analysis. IOA was analyzed by Kappa coefficient.

**Results:** IOA was lowest for 6-TS (K=0.13, P<0.001). CEADX was available for 18 (33%) cases, including 6/24 (25%) of MCLG and 0/9 NMLs. CEADX modestly improved IOA for any variation that combined tiers of the 6-TS while keeping ATP and MCLG separate. CEADX did not affect IOA for MCHG, SPA or PA. Highest overall IOAs used CEADX in a 4-TS (NDX, ATP, MCLG, MCHG/SPA/PA; K=0.23, P<0.001) and 3-TS (NDX, ATP/MCLG (K=0.23, P<0.001), MCHG/SPA/PA; K=0.26, P<0.001). IOA was better for combined HG tier (MCHG/SPA/PA) (K=0.35, P<0.001) than LG or ATP (K=0.17, P<0.001) and (K=0.20, P<0.001), respectively). IOA was low for neoplastic mucin (K=0.15, P<0.001). Agreement between observer diagnosis and histologic diagnosis ranged from 17-44%.

**Conclusions:** In a study using simulated cytology practice, experienced observers showed fair IOA for grading MNs and slight IOA for identifying neoplastic mucin. Knowledge of CEA modestly improved IOA for LG MNs.

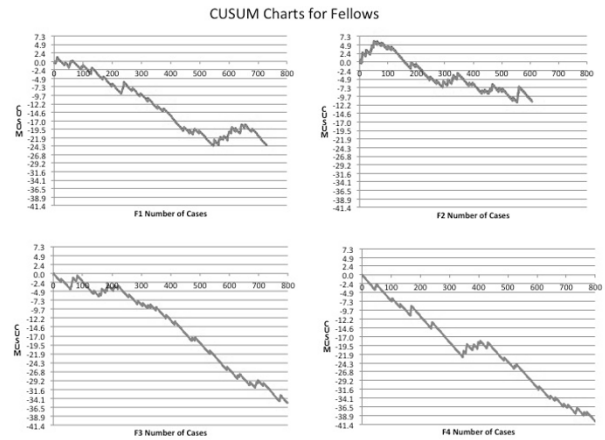
**486 The Use of CUSUM Procedure in the Assessment of Diagnostic Competency of Cytopathology Fellows**

SD Simmons, JA Levesque, IA Eltoum, A Wrenn. University of Alabama at Birmingham, Birmingham, AL.

**Background:** The objective of this study is to evaluate cytopathology diagnostic performance using the Cumulative Sum (CUSUM) chart. The objective of this study is to (1) assess the learning curve of new cytopathology fellows and the number of cases that are needed to attain competency at an acceptable level of diagnostic disagreement with the attending pathologist and (2) Compare the performance of new fellows to fellows who had been in training for six months. Our goal is to devise a tool kit for real time assessment of trainees during their fellowship training.

**Design:** The study includes four cytopathology fellows: two who just started their fellowship (F1,F2) and 2 who have just ended it (F3, F4). All consecutive cytology cases reviewed by the new fellows during the first two months and cases reviewed by the senior fellows in the second half of their training were included in the study. We use standardized Bethesda- like format for our diagnosis categories. We calculated the disagreement rates of these two categories between the fellow and the attending pathologist. Using Excel spreadsheet, we constructed a CUSUM chart at an acceptable (0.05) and unacceptable (0.15) disagreement rate with a type I and type II statistical error rate of 0.05.

**Results:** The overall disagreement rates were higher for new fellows (46/615, 7.5% and 43/731, 6.0%) compared to the senior fellows (32/800, 4% and 46/844, 5.4%) p<0.001. Similar results were obtained when specimens were classified into Gyn (8/82, 9.7%; 9/112, 8.0%, 3/70, 4.3%, 19/116, 16%) versus NonGyn cytology (38/533, 7.1%; 34/629, 5.4%; 29/730, 4.0%, 27/844, 3.1%). The CUSUM curve shows details of performance during the study period. Unlike the curve for the senior fellow, the curve for the new fellows passes through a learning period after which competency was observed after 128 and 112 cases for the new fellows compared to 26 and 38 for the senior fellows. Competency of the non-Gyn cytology was reached at 103 and 91 cases for the new fellows 25 and 37 for the senior fellows.



**Conclusions:** CUSUM is a useful procedure to track the learning curve for new pathology trainees. It serves as a data driven tool kit for self-assessment and provides explicit information for training evaluation and competency.

**487 Image-Guided Fine Needle Aspiration (FNA) Versus Core Needle Biopsy (CNB) of Malignant Neoplasms: A Comparative Study of Tumor Cell Yield for Ancillary Molecular Testing**

C Singh, S Krishnamurthy, A Cortes, MJ Wallace. UT MD Anderson Cancer Center, Houston, TX.

**Background:** The success of molecular testing relies on tumor cellularity & purity of DNA extracted from image-guided biopsies. The aim of this study was to ascertain the tissue-dependent factors responsible for suboptimal DNA yield from CNB and role of concurrent FNA in such cases.

**Design:** We retrospectively reviewed cases in which image-guided CNB & FNA were performed concurrently & molecular analysis failed. The cellularity of tumor cells in the FNA specimen was scored on a scale of 1-4 (0, <50, 50-300, >300 cells, respectively). CNB tissue sections were scored for tumor cellularity, degree of fibrosis, normal tissue, blood clot, necrosis, and extracellular mucin on a scale of 1-4 (0%, <25%, 25-50%, >50% respectively, for each parameter). Tumor cellularity of ≥50 cells (score 3 or 4) in FNAs and ≥25% (score 3 or 4) in CNBs was considered optimal for molecular testing. The performance of CNB & FNA in obtaining optimal tumor cellularity for ancillary molecular testing was compared using SAS software.

**Results:** 61 patients underwent concurrent FNA & CNB of either primary (26%) or metastatic lesions (74%). At least 2 FNA passes, and cores with mean length of 1.22 ± 0.47 cm were procured.

	Cellularity Score			
	1	2	3	4
CNB	5 (8.3%)	36 (59%)	17 (27.9%)	3 (4.9%)
FNA	4 (6.5%)	14 (23%)	18 (29.5%)	25 (41%)

Cellularity was suboptimal in 41 (67.2%) CNBs and 18 (29.5%) FNAs, and optimal in 20 (32.8%) CNBs and 43 (70.5%) FNAs. Of the 41 cases in which CNB had suboptimal cellularity, 26 (42.6%) had FNA with optimal cellularity. Conversely, of the 18 cases

with suboptimal FNA, only 3 (4.9%) had CNB with optimal cellularity. The core lengths of the CNBs with suboptimal or optimal cellularity did not differ significantly ( $1.18 \pm 0.43$  cm vs.  $1.31 \pm 0.56$  cm;  $P=0.32$ ). The proportion of CNBs with necrosis  $\geq 25\%$  between groups with suboptimal & optimal cellularity was not significant (12% vs. 0%;  $P=0.16$ ). The proportion of CNBs with  $\geq 25\%$  fibrosis, normal tissue, blood clot, and/or extracellular mucin was significantly higher in suboptimal cellularity group (80.5% [33]) versus optimal cellularity group (25% [5];  $P<0.0001$ ).

**Conclusions:** Suboptimal cellularity of CNBs was significantly associated with presence of fibrosis, normal tissue & mucin but not necrosis or core length; Optimal tumor cellularity was procured by FNA when CNB was suboptimal more often, in comparison to CNB in suboptimal FNAs (43% vs 5%. If technically feasible, FNA should be performed in addition to CNB to obtain optimal amounts of tumor cells, thereby avoiding repeat biopsy procedures.

#### 488 Fine Needle Aspiration Experience in Cases of Myeloid Sarcoma

*RL Singhal, SE Monaco, L Pantanowitz.* University of Pittsburgh Medical Center, Pittsburgh, PA.

**Background:** The diagnosis of myeloid sarcoma (MS) in cytology samples is challenging, especially if these tumors occur prior to a diagnosis of acute myeloid leukemia (AML). Tumor specimens with mixed hematopoietic cells may mask blasts. Also, the differential diagnosis is broad, including other hematologic entities and neoplasms. The aim of this study was to review our fine needle aspiration (FNA) service experience with a series of MS cases.

**Design:** Archival records were searched from which 15 FNA cases of MS, obtained from 14 patients over 8 years, were identified and reviewed. Patient demographics, tumor location, diagnosis (leukemia type and temporal relationship to presentation) and ancillary studies were analyzed. Recorded cytologic parameters included cellularity, blasts, other precursor cells, proliferation (mitoses, apoptosis) and background (necrosis, blood contamination).

**Results:** There were 11 males and 3 females of mean age 53 years. Aspiration sites included subcutaneous/soft tissue (11;73%), lymph nodes (3;20%) and bone (1 case). MS was secondary to AML in 12 cases (5 monocytic, 4 not otherwise specified, 2 mixed lineage, 1 myelomonocytic), chronic myeloid leukemia (CML) in 1 case, chronic myelomonocytic leukemia (CMML) in 1 case, and myelodysplastic syndrome in another. FNA diagnoses in all cases was made at or after a prior leukemia diagnosis (1 day to 8 years, 7 months later; mean 2 years, 6 months later), and were either indeterminate (9; 60%) or positive for malignancy (6; 40%). Three cases had histological confirmation. Flow cytometry was supportive in 12 cases, immunostains performed in 4 cases, and in 1 CML case FISH showed t(9;22). Identifying *FLT3* and *NPM1* mutations helped in 1 AML case. Cellularity was variable in all leukemia subtypes. Blasts had round or cleaved nuclei with indistinct nucleoli. Maturing granulocytes were present only in patients with CMML and CML, or with peripheral blood contamination (5 cases). Other blood precursors were absent. Apoptosis and lymphoglandular bodies were present in almost half the cases, which correlated with numerous blasts. Mitoses were infrequent (4 cases) and necrosis was not seen.

**Conclusions:** The diagnosis of MS in FNA specimens can be made in cases with adequate cellularity and supportive ancillary studies in the correct clinical context. MS was harder to diagnose in FNA cases with low cellularity, blood contamination and few blasts. Cytologic features that pose diagnostic pitfalls are lymphoglandular bodies suggestive of lymphoma and mixed granulocytes that mimic infection.

#### 489 Fine Needle Aspiration of Subcentimeter Thyroid Nodules: Should It Be Done?

*LA Smith, S Mehrotra, R Wafai, S Pambuccian, GA Barkan.* Loyola University of Chicago, Maywood, IL.

**Background:** Clear cut guidelines exist for the management of thyroid nodules  $>1$ cm; however management of thyroid nodules  $\leq 1$ cm is highly debated. The aim is to determine the malignancy rate (MR) in thyroid nodules  $\leq 1$ cm, ascertain specific radiological characteristics that can be utilized to triage for fine needle aspiration (FNA), and highlight trends for use as evidence based guidelines to decrease unnecessary FNA.

**Design:** A systematic PubMed search using the keywords "FNA, non-palpable, small size, subcentimeter, infracentimeter, and thyroid nodule" was performed. Papers using FNA of thyroid nodules  $<1$ cm were included; case reports, reviews, and studies without pathology information were excluded. The findings tabulated and pooled values evaluated.

**Results:** The PubMed search yielded 17 original articles (12 clinical, 5 radiology) amenable for evaluation. The data included  $>24,000$  patients. MR of thyroid nodules  $\leq 1$  cm and  $>1$ cm ranged from 2.2-55.3% (mean 17.3%) and 1.5-67.6% (mean 18.39%) respectively. Inadequate sampling of thyroid nodules  $\leq 1$ cm and  $>1$ cm ranged from 1.5-72% (mean 25.72%) and 5.0-28% (mean 19.29%) respectively.

#### Evaluation by Nodule Size

Reference	Patients	$\leq 1$ cm		$>1$ cm	
		% malignant	% inadequate	% malignant	% inadequate
Berker et. al. 2008	426	4.9	16.6	11.5	22.3
Bo et. al. 2011	9861	19.7	19.3	7.8	13.8
Kim et. al. 2009	253	16.3	14.3	15.5	4.8
Kwak et. al. 2009	NP	47.8	10.5	NP	NP
Gul et. al. 2009	2082	5.1	5	1.5	1.5
Papini et. al. 2002	494	9.1	16.6	7	22.5
Kim et. al. 2009	180	8	19	NP	NP
Kim et. al. 2008	1009	55.3	53	44.7	52.1
Cappelli et. al. 2007	5198	3	26.1	5.5	12.5
Sharma et. al. 2011	104	15	10	NP	NP
Moon et. al. 2012	1403	18.2	17.8	NP	NP
Taddeus et. al. 2011	122	5.6	NA	14.4	NA
Leenhardt et. al. 1999	450	NA	NA	NA	NA
Sahni et. al. 2006	207	NA	NA	NA	NA
Slowinska-Klencna et. al. 2008	2112	32.4	28	67.6	72
Butros et. al. 2007	485	2.2	14.6	NP	NP
Nam-Goong et. al. 2004	267	NA	NA	NA	30
	24653 total	17.33 mean	19.29 mean	18.39 mean	25.72 mean

NP = not performed; NA = not available

Radiologic characteristics found helpful in triaging include solid structure, hypoechogenicity, ill-defined margins, vascularity, and microcalcifications.

**Conclusions:** The MR in thyroid nodules  $\leq 1$ cm is not significantly different than nodules  $>1$ cm. However, the inadequacy rate rises with decreasing size. In patients with thyroid nodules  $<1$  cm, and especially  $<0.5$  cm; a collective assessment of US findings including echogenicity, shape, increasing size, margins, vascularity, calcification pattern, and lymphadenopathy may help guide further invasive intervention. This would eventually reduce unnecessary invasive procedures and reduce health care costs.

#### 490 The Utility of BRAF V600E Monoclonal Mutation Specific Antibody for Detection of BRAF V600E Mutation on Cell Block Specimens of Thyroid Fine Needle Aspiration

*CC Solomides, R Draganova-Tacheva, M Bibbo, S Ren, M Tuluc, R Birbe, Z-X Wang, SC Peiper.* Jefferson Medical College, Philadelphia, PA.

**Background:** BRAF gene encodes a cytoplasmic serine/threonine protein kinase that regulates the MAPK signaling cascade, which controls differentiation and proliferation.

The BRAF V600E mutation is the most common mutation in papillary thyroid carcinoma (PTC). The reported prevalence of BRAF V600E ranges from 28% to 77% with an average of 45%. Fine Needle Aspiration (FNA) is the initial diagnostic test in evaluating thyroid nodules. Analysis for the BRAF V600E mutation is usually tested on FNA specimens with indeterminate cytology results. The presence of BRAF V600E mutation is an indication of malignancy. This mutation is currently detected by Sanger sequencing in our Molecular Lab. In this study we examine the utilization of the recently described BRAF V600E (VE1) monoclonal mutation-specific antibody for the identification of BRAF mutations in cytology cell block specimens.

**Design:** Cell block specimens with adequate cellular material from 60 patients with confirmed PTC and known BRAF V600 mutation status by DNA sequencing were selected. 11 cases were negative and 49 were positive for this mutation by molecular detection. These specimens were stained by immunohistochemistry (IHC) with the mouse anti-human monoclonal antibody specific for the BRAF V600E mutation (Spring Bioscience, Pleasanton, CA), using the Ventana BenchMark Ultra immunohistochemical stainer platform (Ventana Medical Systems, Inc, Tucson AZ). Moderate-to-strong cytoplasmic staining by IHC was scored as positive, and absent or equivocal staining was considered negative. The results were obtained by consensus of independent examination by four pathologists.

**Results:** All eleven (11) cases with wild type BRAF by sequencing were also negative by IHC, thus no false positive cases were observed. Forty one (41) of forty nine (49) cases that were positive for BRAF V600E by Sequencing were also positive by IHC (Sensitivity 84%).

**Conclusions:** The newly described BRAF V600E monoclonal mutation specific antibody may be a cost-effective, efficient approach for the detection of the BRAF V600E mutation in cell block preparations from Thyroid FNA specimens. Added advantage is that IHC staining can be correlated with cell morphology and be integrated into pathology routine workflow. This test may be utilized when the material available for molecular testing is limited or for triaging specimens for sequencing. Follow up analysis of specimens negative by IHC using molecular techniques is recommended.

#### 491 Cytologic Features of Angiosarcoma: A Review of 22 Cases Diagnosed on Fine Needle Aspiration (FNA)

*HC Sullivan, LN Stuart, K Hoo Kim, MA Edgar, MD Reid.* Emory University School of Medicine, Atlanta, GA; Louisiana State University HSC-Shreveport, Shreveport, LA.

**Background:** Angiosarcomas (AS) are rare malignant neoplasms most commonly seen in the skin and soft tissue. Histologic diagnosis can be challenging as other malignant neoplasms show overlapping features especially with the epithelioid variant. This dilemma is even greater on cytology where cells are limited and supporting architectural changes are absent. We describe the cytologic features of 22 AS cases diagnosed on FNA.

**Design:** Air-dried and alcohol-fixed smears, cell blocks and immunostained slides from 22 AS cases were reviewed by a cytopathologist(MR) and a soft tissue pathologist(ME) and the diagnosis of AS was confirmed. Established histologic features as well as new cytomorphologic features were sought (see Table 1).

**Results:** There were 13(59%) females and 9(41%) males, ranging in age from 2- 94 years (mean 50 years). FNA sites included 5 skin (23%), 5 soft tissue (23%), 4 bone

(18%), 2 lung, 2 lymph nodes, 2 liver (each 9%) and 1 heart FNA (5%) as well as 1 pleural effusion (5%). The frequency of key cytologic features is shown in Table 1.

Table 1. Cytologic Findings in Angiosarcoma

Finding	Number (%)
Abnormal Mitoses	18 (82)
Single cells	17 (77)
Epithelioid cells	16 (73)
Cytoplasmic vacuoles	16 (73)
Endothelial wrapping	15 (68)
Spindle cells	14 (64)
Multiple prominent nucleoli	14 (64)
Bar-shaped nucleoli	13 (59)
3-D Clusters	12 (55)
Cytoplasmic RBCs	12 (55)
RBCs in Vacuoles	12 (55)
Chromatin stranding	8 (36)
Neutrophils in Vacuoles	7 (32)

The most common features (in >70% of cases) were abnormal mitoses and single epithelioid cells with cytoplasmic vacuoles (CV). Less common but established features of AS, including spindling, cell wrapping and CVs with RBCs, were seen in >50%. Distinctive nuclear features including chromatin stranding and bar-shaped nucleoli (3 times longer than wide) were common but inconsistent. Interestingly epithelioid features and 3-dimensional (3D) groups were seen in >50%.

**Conclusions:** Given the rarity of FNA of AS there is a need to establish cytologic criteria to aid in their diagnosis. We found several key features helpful in diagnosing AS. In addition cytoplasmic RBCs and bar-shaped nucleoli are newly described findings in AS. Interestingly, >70% of AS show epithelioid features, 3D groups and CVs, which may lead to misdiagnosis as carcinoma, if AS is not previously suspected. We propose that the presence of a constellation of the above cytologic findings should trigger suspicion of AS, and be followed by appropriate confirmatory ancillary stains.

**492 The Utility of ERG, CD31 and CD34 in the Cytologic Diagnosis of Angiosarcoma: An Analysis of 22 Cases**

HC Sullivan, MA Edgar, C Cohen, CK Kovach, K HooKim, MD Reid. Emory University, Atlanta, GA; Louisiana State University Health Sciences Center-Shreveport, Shreveport, LA.

**Background:** ETS-related gene (ERG) is a proto-oncogene member of the erythroblast transformation specific (ETS) transcription factor family and is expressed in prostate cancer, acute myeloid leukemia and Ewing sarcoma. ERG is also highly specific for endothelial cells and is expressed in benign and malignant vascular tumors, including angiosarcomas (AS). Immunohistochemistry (IHC) is useful to the diagnosis of AS and is often necessary in fine needle aspirates (FNAs) where low cellularity and lack of preserved tissue architecture can impede diagnosis. The aim of this study was to assess the utility of an ERG-enriched IHC panel in the cytological diagnosis of AS.

**Design:** 22 AS diagnosed on FNA were stained with ERG, CD31, CD34, and AE1/AE3. Staining intensity (weak, moderate, strong) and percentage tumor cell positivity (1:0-25%; 2:26-50%; 3:51-75%; 4:>75%) were assessed for each stain. Additionally, Spearman's correlation was used to assess for significant correlations between antibodies.

**Results:** There were 13 (59%) females and 9 males (41%) with a mean age of 50 yrs (range 2 - 94 yrs). The number of positive cases, sensitivity, and stain intensity are shown in Table 1. Spearman's analysis revealed that CD31 and ERG staining correlated significantly (p=0.0005), while there was no significant correlation between CD31 and CD34 staining (p=0.462) (Table 2).

Table 1

Stain	Positive cases no. (Sensitivity %)	Negative cases no. (%)	Cases with strong intensity staining no. (%)	Cases with moderate intensity staining no. (%)	Cases with weak intensity staining no. (%)
CD31	22 (100)	0 (0)	15 (68)	6 (27)	1 (5)
ERG	22 (100)	0 (0)	16 (73)	5 (23)	1 (5)
CD34	12 (45)	10 (55)	3 (14)	5 (23)	4 (18)
AE1/AE3	5 (24)	16 (76)	1 (5)	1 (5)	3 (14)

No. = number

Table 2

Stains	Variable	Spearman coefficient	P-value
CD31 vs ERG	% staining	0.6833	0.0005
	Intensity	0.5146	0.0143
CD31 vs CD34	% staining	0.1653	0.4623
	Intensity	0.3321	0.1311
ERG vs CD34	% staining	0.0391	0.8627
	Intensity	-0.0775	0.7319

**Conclusions:** With equal sensitivity to and strong correlation with CD31, ERG staining is highly suitable for the cytologic diagnosis of AS. Both ERG and CD31 are more sensitive vascular markers than CD34. Also, ERG is a nuclear stain, which complements the cytoplasmic/membranous staining of CD31. Thus, when used in conjunction with CD31, ERG can corroborate the diagnosis of AS. AE1/AE3 is occasionally expressed by AS and so is a potential diagnostic pitfall on FNA and in cases where the diagnosis is not suspected.

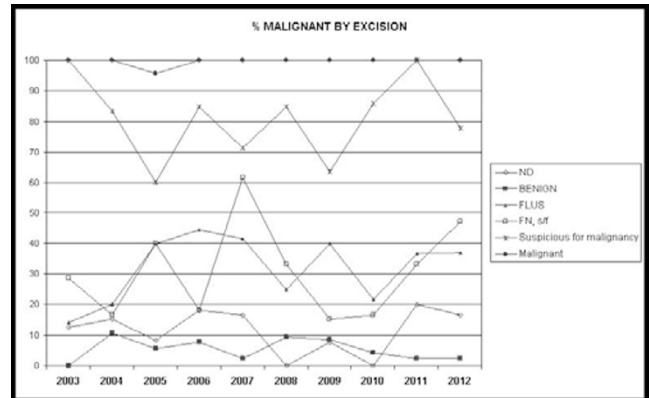
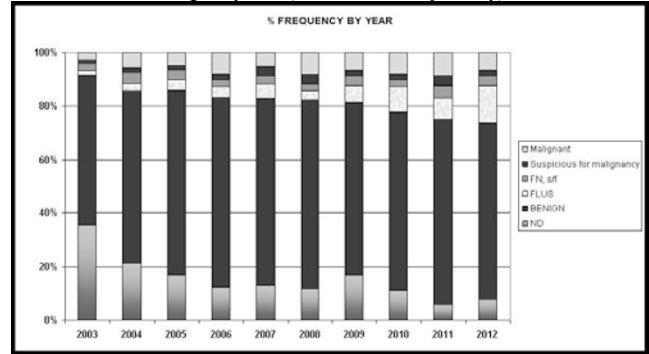
**493 Before and after the Bethesda System: Frequency and Malignancy Rates in Reporting Thyroid Cytopathology**

PS Sullivan, SL Hirschowitz, PC Fung, SK Apple. David Geffen School of Medicine at UCLA, Los Angeles, CA.

**Background:** Since implementation of the Bethesda System for Reporting Thyroid Cytopathology (TBS), few studies have examined its impact on diagnosis and malignancy rate. We examine the frequency and outcome of reporting thyroid

cytopathology at a single institution 5 years before and after implementation of TBS. **Design:** Thyroid fine needle aspirations (FNAs) performed from 2003 to 2012 at a single large academic center were reviewed. Patients with a previous diagnosis of thyroid cancer or total thyroidectomy were excluded. Diagnoses made prior to implementation of TBS at UCLA (January 2008) were re-classified into the most appropriate TBS category by consensus between two cytopathologists. Surgical follow-up results were matched by side and size of targeted thyroid nodule as available. Incidental microcarcinomas were not considered "malignant" on follow-up. Malignancy rates were based on excision only.

**Results:** 5665 thyroid FNAs were classified into the following TBS categories: 15% Non-Diagnostic (ND), 67% Benign, 6% Follicular lesion of undetermined significance/Atypia of undetermined significance (FLUS), 3% Follicular Neoplasm (FN), 2% Suspicious for Malignancy, 6% Malignant. By comparing reporting rates before and after TBS, we found that the ND category decreased from 19% to 11% (p=0.03). The FLUS category doubled from 4% to 8% (up to 12% by 2012, p=0.04) (Figure 1). Malignancy rates for all categories remained relatively constant (Figure 2). FLUS and FN categories had similar overall malignancy rates (35% and 33%, respectively).



**Conclusions:** Implementation of TBS was associated with a decrease in the ND category and an increase in the FLUS category without a significant change of malignancy rate in all categories. Similar (and elevated) malignancy rates for FLUS and FN call into question the utility of a repeat aspirate for FLUS cases.

**494 Evaluation of Matched Lavage Fluids and Paraffin-Embedded Samples in BRAF Mutational Analysis of the Thyroid**

X Sun, D Chieng, P Hui, K Schofield, AJ Adeniran. Yale University School of Medicine, New Haven, CT.

**Background:** Several studies have evaluated the use of cytologic preparations for molecular analysis, with different approaches for obtaining cellular samples. At our institution, we use lavage fluid obtained from washing the needles after preparation of direct smears. There are concerns that the sensitivity of the molecular analysis may be compromised because the quantity and composition of the cellular materials are unknown. The objective of this study was to compare the BRAF status of the FNAs with their corresponding histologic specimens with a view to determining the limitations of this method.

**Design:** A retrospective search of our database for cases of positive for papillary thyroid carcinoma (PTC), suspicious for PTC and FLUS/AUS with concurrent BRAF V600E mutation analysis between January 2010 and December 2012 was done. Cases with malignant outcomes formed the cohort for this study. BRAF mutation analysis was performed by PCR combined with single strand conformation polymorphism gel electrophoresis using the remnant of samples collected for thin-layer processing in each case. BRAF V600E mutation analysis was repeated on a thyroidectomy specimen if it was negative on the cytology specimen. The BRAF mutation status was compared between cytology and surgical specimens. Final histologic diagnosis was reviewed for the final outcomes in these patients.

**Results:** A total of 346 specimens with a diagnosis of FLUS/AUS or above with concurrent BRAF V600E mutation analysis and surgical follow-up of malignancy were identified. 323 (94%) of the 346 aspirate specimens were satisfactory for molecular analysis. BRAF V600E mutation was detected in 157 (49%) and absent in 166 (51%) aspirates. Fifty eight (35%) of 166 BRAF wild-type aspirates had repeat BRAF mutation analysis on surgical specimens. Six cases of BRAF-mutated aspirates all showed BRAF

mutation in surgical specimens (100%). Thirty one (53%) cases of BRAF wild-type aspirates showed similar negative BRAF mutation status on surgical specimens; while 27 (47%) cases with BRAF wild-type aspirates showed BRAF mutation on surgical specimens.

**Conclusions:** While this method offers prospective molecular analysis by the use of residual lavage fluid for BRAF mutational analysis, a major drawback is the discordance of BRAF mutation status between matched FNA and formalin-fixed, paraffin-embedded samples and hence a high false negative rate.

#### 495 Frequency of BRAF Mutation in the Thyroid Follicular Lesion of Undetermined Significance and Implications for Patient Management

X Sun, D Chhieng, P Hui, E Holt, G Callender, T Carling, R Udelsman, AJ Adeniran. Yale University School of Medicine, New Haven, CT.

**Background:** The Bethesda Thyroid Classification System estimates the risk of malignancy in the diagnostic category of follicular lesion of undetermined significance/atypia of undetermined significance (FLUS/AUS) to be 5-15%. However, the actual risk of malignancy is difficult to ascertain because only a minority of patients in this category have surgical follow-up. At our institution, this diagnostic category is sub-categorized into two based on the presence or absence of nuclear atypia. We have previously shown that the detection of BRAF gene mutation in FNA material assists in the pre-operative diagnosis of papillary thyroid carcinoma. This study was designed to evaluate the frequency of BRAF mutation in the FLUS/AUS category and to assess its implications for patient management.

**Design:** Thyroid FNA cytology specimens with FLUS/AUS diagnosis and a concurrent BRAF V600E mutation analysis between January 2010 and December 2012 were selected from our files. BRAF mutation analysis was performed by PCR combined with single strand conformation polymorphism gel electrophoresis using the remnant of samples collected for liquid-based processing in each case. Surgical pathology reports were reviewed and correlated with the cytology and molecular analysis results.

**Results:** A total of 231 specimens with FLUS/AUS diagnosis with surgical follow-up were identified. Concurrent BRAF V600E mutation analysis was performed in 154 cases. Malignancy was identified in 134 cases (58%). Malignancy rate was disproportionately higher in the group with nuclear atypia (126/190; 66.3%) compared with the group without nuclear atypia (8/41; 19.5%). BRAF V600E mutation was present in 15 cases, with a malignancy rate of 100%. Malignancy rate in the BRAF negative cases was 46.9% (61/130) with a 5:1 predominance in the group with nuclear atypia.

**Conclusions:** Although the actual risk of malignancy is difficult to ascertain in the FLUS/AUS category, overall malignancy rate in the subgroup with nuclear atypia is three times higher than that without atypia. Total thyroidectomy is indicated in the BRAF positive FLUS/AUS cases. Negative BRAF status by itself is not helpful in triage of patients for surgery. However, the presence of nuclear atypia on cytology connotes substantial malignancy risk in patients with FLUS/AUS diagnosis.

#### 496 KRAS Mutation Analysis in the Cytological Specimens of Cystic and Solid Pancreatic Lesions and Its Correlation with Surgical Follow-Up

X Sun, J Bernstein, P Hui, HR Aslanian, D Chhieng, G Cai. Yale University School of Medicine, New Haven, CT.

**Background:** Pancreatic lesions are increasingly detected due to improvement of imaging techniques and are frequently evaluated by endoscopic ultrasound-guided final needle aspiration (EUS-FNA). The cytological diagnosis of solid and cystic pancreatic lesions can be indeterminate due to scant cellularity and/or subtle cytomorphologic changes. KRAS mutation has frequently been found in hyperplastic foci associated with pancreatic cancer, precursor lesions and adenocarcinoma. KRAS mutation has also been shown in cystic pancreatic lesions with mucinous differentiation. In this study, we evaluated the diagnostic value of KRAS mutation in cystic and solid pancreatic lesions sampled by EUS-FNA and correlated with surgical follow-up.

**Design:** From 2005 to 2013, 162 pancreatic cystic fluid specimens obtained were submitted for KRAS mutation analysis at the codon 12/13 based on clinical characteristics while KRAS mutation analysis was performed in 83 solid pancreatic lesions with equivocal (atypical and suspicious) cytology as a reflex test. Surgical follow-up was available for comparison in 37 patients with cystic lesions (23%) and 26 patients with solid lesions (31%). The cystic lesions included 32 mucinous lesions (16 intraductal papillary mucinous neoplasms [IPMN] and 16 mucinous cystic neoplasms [MCN]) and 5 non-mucinous lesions. The solid lesions consisted of 21 adenocarcinomas and 5 benign lesions.

**Results:** For pancreatic cystic lesions, KRAS mutation was detected in 53 of 162 (33%) of patients. In 37 cystic lesions with surgical follow-up, KRAS mutation was found in 14 patients (38%), all of which were cystic mucinous lesions. The calculated sensitivity and specificity of KRAS mutation for diagnosis of mucinous lesions were 44% and 100%, respectively, similar for IPMN and MCN. For pancreatic solid lesions with indeterminate cytology, KRAS mutation was detected in 26 of 83 (31%) patients. In 26 solid lesions with surgical follow-up, 8 lesions are KRAS-mutated (31%), all of which were adenocarcinomas. The calculated sensitivity and sensitivity of KRAS mutation for diagnosis of adenocarcinomas were 38% and 100%, respectively.

**Conclusions:** KRAS mutation has a high specificity but a relatively low sensitivity for diagnosis of mucinous neoplasms in cystic pancreatic lesions and diagnosis of adenocarcinoma in solid pancreatic lesions with equivocal cytology. Additional ancillary tests such as cyst fluid CEA level and other molecular analysis may be helpful for increasing diagnostic accuracy.

#### 497 Pitfalls in the Diagnosis of Benign Renal Fine Needle Aspiration (FNA) Cytology Cases: Analysis of 2080 Responses from the College of American Pathologists (CAP) Nongynecologic Cytopathology Education (NGC) Program

ZL Tabatabai, R Laucirica, GA Barkan, DFI Kurtycz, R Souers, RH Tambouret. University of California San Francisco, San Francisco, CA; Baylor College of Medicine, Houston, TX; Loyola University Medical Center, Maywood, IL; University of Wisconsin Hospital & Clinics, Madison, WI; College of American Pathologists, Northfield, IL; Massachusetts General Hospital, Boston, MA.

**Background:** Studies have shown that nearly 20% of small renal masses are benign and that a benign diagnosis can make a significant difference in patient management. This study was undertaken to better understand pitfalls in the diagnosis of benign renal FNA cytology by assessing participant responses in the CAP NGC program.

**Design:** 2080 participant responses based on 43 benign renal FNA cases evaluated in the CAP NGC Program between the years 2000-2012 were analyzed for concordance to the general category of benign/negative and exact reference diagnosis. Two nonlinear mixed models were used to analyze the concordance rates. The general category concordance model was fit with three factors—participant type, preparation type, and program year; the reference diagnosis concordance model was additionally fit with participant reference diagnosis. A significance level of .05 was used for the analyses.

**Results:** The overall general category and reference diagnosis concordance rates were 81.8% and 68.9%, respectively. There were significant differences in concordance to the reference diagnosis. Concordance was lowest for a diagnosis of normal kidney components (NKC) (16.9%), followed by malakoplakia (MP) (61.8%), angiomyolipoma (AML)(78.3%), cyst, NOS (CyN) (83.8%), and inflammatory/abscess (100%). The most common discordant diagnoses for NKC were renal cell carcinoma (RCC) (49.4%), oncocytic renal neoplasm (13.0%) and urothelial carcinoma (10.4%). RCC was the most common discordant diagnosis for AML (13.2%) and CyN (7.2%) and the second most common discordant diagnosis for MP (9.1%). There were also significant differences ( $P<.001$ ) in concordance to the general category and reference diagnosis between pathologists and cytotechnologists (84.5% vs. 75.9% and 77.8% vs. 48.3%, respectively).

**Conclusions:** The greatest diagnostic challenge in benign renal FNA cytology is distinguishing NKC from RCC. RCC is the most common clinically significant misdiagnosis in the setting of AML, CyN, and MP. Better education of pathologists and cytotechnologists in the recognition and diagnosis of NKC and benign entities is needed to avoid pitfalls in this setting.

#### 498 Combined Cytology and HPV Testing after Loop Electrosurgical Excision Procedure (LEEP)/Conization of the Cervix Increases the Rate of Detection of Residual Cervical Intraepithelial Neoplasia in Patients with Negative Margins

JNM Tan, D Kamel, H Xu. Boston University Medical Center, Boston, MA, Turks and Caicos Islands.

**Background:** The key component to confirming the clearance of cervical intraepithelial neoplasia (CIN) is documented by cytology or colposcopy biopsy according to recommended follow up timetable. The patient is considered free of disease if there is no clinical or pathologic evidence of CIN at one-year follow up. Cytology is the main diagnostic tool but recently HPV testing is gaining edge as the main follow up modality. High viral load at pretreatment and infection with HPV type 16 have been associated with persistence even in cases with negative margins. Despite data favoring HPV testing over cytology, Pap smear continues to be ordered without HPV testing more frequently during follow up. This study aims to evaluate the detection rate of residual disease in cases followed up with cervical cytology only versus cervical cytology and HPV testing after treatment by Loop Electrosurgical Excision Procedure (LEEP) or conization for CIN.

**Design:** We performed an 11-year (2000-2011) retrospective review of the cervical pathology of 110 women age 14-83 treated by LEEP or conization. We recorded all cytology and HPV testing results within 1 year of follow-up. Outcome of cases with cytology alone are compared to outcome of cases with both cytology and HPV testing. The rates of detection of residual disease are compared between cases with positive and negative margins.

**Results:** The rate of residual CIN for cases with positive margins (13/43, 30%) is slightly higher than cases with negative margins (16/67, 24%). In cases with positive margins, the difference in the rate of detection by either cytology or combined cytology and HPV testing is not statistically significant ( $p=0.7357$ ). In contrast, combined cytology and HPV testing increases the rate of detection of residual CIN in patients with negative margins ( $p=0.0043$ ).

Table 1. Cytology and HPV results within 1 year of follow up after LEEP/conization with positive margins

	Cytology	Cytology and HPV	P
Positive	7 (27%)	6 (35%)	0.7357
Negative	19 (73%)	11 (65%)	

Table 2. Cytology and HPV results within 1 year of follow up after LEEP/conization with negative margins

	Cytology	Cytology and HPV	P
Positive	6 (13%)	10 (48%)	0.0043
Negative	40 (87%)	11 (52%)	

**Conclusions:** This study suggests that HPV testing should be performed in addition to cytology in every follow up for patients treated with LEEP/conization particularly those with negative margins to increase detection rate of residual CIN.

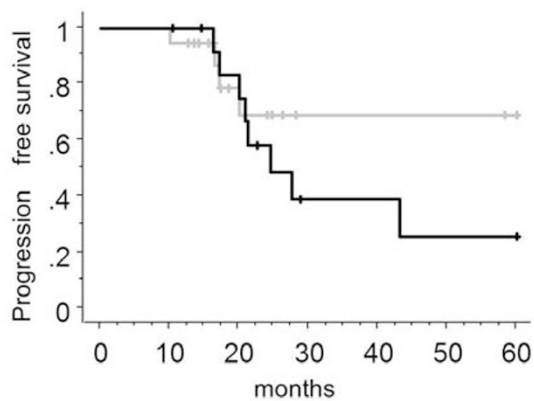
#### 499 Significance of Implantable Port System Cytology for Advanced Stage Mullerian Cancer

S Tate, K Nishikimi, N Yamamoto, T Uehara, H Ushui, A Mitsuhashi, M Shozu. Chiba University Hospital, Chiba, Japan.

**Background:** Neoadjuvant chemotherapy (NAC) followed by interval debulking surgery (IDS) for advanced ovarian cancer is not inferior to primary debulking surgery. In this prospective pilot study, we performed IDS after each patient had achieved negative implantable port system cytology (IPS-cytology). This study demonstrated the prognostic relevance of IPS-cytology for advanced-stage mullerian cancer.

**Design:** Thirty-eight patients who were eligible for this study had unresectable residual disease at the time of primary surgery. At the time of primary surgery, the IPS was placed in the abdominal wall. We performed IPS-cytology every 3-4 weeks during NAC. IDS was performed after patients had achieved negative IPS-cytology. We determined the morphologic changes in cancer cells based on IPS-cytology during the response to chemotherapy.

**Results:** Thirty-two patients underwent IDS after they had achieved negative IPS-cytology. We observed the following morphologic changes in cancer cells. At the time of primary surgery, numerous large clusters of cancer cells were observed. The clusters were arranged in papillary aggregates. After several chemotherapy cycles were administered, the papillary clusters had decreased papillosity. Subsequently, the cancer cells were arranged in smaller clusters. After the isolated cancer cells were observed, IPS-cytology was negative. The median period of change to negative IPS-cytology was 19.1 weeks from the date of initiating chemotherapy. Five patients had pathological CR (pCR). We set the cut-off of the period changing to negative IPS-cytology, to optimize the discrimination of pCR. Receiver operating curve demonstrated that a best accuracy (sensitivity 55%, specificity 55%) was achieved for 18.1 weeks. We defined an early negative group: less than 18.1 weeks, and as late negative group: more than 18.1 weeks. We found five patients of early negative group (n=18) had pCR (23%), none of late negative group had pCR, significantly (p=0.03). Three-year progression free survival rate in patients with early negative group was higher than that in patients with late negative group (69%, 39%, respectively, p=0.32).



**Conclusions:** IPS-cytology is effective in evaluating the direct response to NAC for advanced-stage mullerian cancer. The period of change to negative IPS-cytology may predict chemo-sensitivity.

#### 500 What Is the Value of 'Suspicious for Urothelial Carcinoma' Cytology Category? A Correlative Study of Four Years Including 324 Patients

TN Ton Nu, M Charbonneau, M Auger, F Brimo. McGill University Health Center, Montreal, QC, Canada.

**Background:** In urine cytology, the diagnostic category of 'suspicious for urothelial carcinoma (S)' has historically been used in our institution in cases with abnormal cells falling short quantitatively or qualitatively for a definitive diagnosis of malignancy. We aimed to evaluate the significance of this category in comparison to a cytology diagnosis of 'positive for urothelial carcinoma (P)'.

**Design:** All urine cytology cases with a diagnosis of 'S' or 'P' for four consecutive years were included. A correlative event consisted of the correlation between a cytology and a subsequent biopsy result as long as the interval between the two did not exceed 6 months. When a correlative event included several cytological specimens, the worse diagnosis (P rather than S) was included for the correlation.

**Results:** 1115 cytologies / 561 patients were captured. 340 cytologies / 237 patients were excluded due to absence of a follow-up biopsy. 67% of the excluded cases were of the 'S' group. Included were 324 patients corresponding to 775 cytologies and 429 correlative events (S=163, P=266). Most patients were males (75%) and the mean age was 73 years. A diagnosis of 'S' was more often assigned in voided specimens (voided to non-voided = 4.4:1) in comparison to the 'P' category (voided to non-voided = 1.8:1). The mean interval between cytology and biopsy was 31 days. Cyto-histological correlation showed that the rate of having a cancer diagnosis on repeat biopsy was comparable between the 'S' and 'P' categories (93% and 90%, respectively).

**Conclusions:** Although it seems that many patients with a cytological diagnosis of 'suspicious for urothelial carcinoma' are not considered for routine biopsy, our data show that it has a similar significance as a diagnosis of 'positive for urothelial carcinoma'. Those results question the value of the 'suspicious' category and suggest that it could

be included in the 'positive' category. However, if a 'suspicious' diagnosis was to be used, the urologists should be aware of its strong association with cancer and patients should be investigated accordingly.

#### 501 HHV8-Negative Primary Effusion Lymphoma: A Series of 17 Cases at a Single Institution

A Usmani, AE Walts, S Alkan, S Kitahara. Cedars-Sinai Medical Center, Los Angeles, CA.

**Background:** Primary effusion lymphoma (PEL), characterized by human herpesvirus-8 (HHV8) positivity, is a well-recognized clinical entity. In contrast, HHV8-negative PEL is incompletely characterized and under-recognized. We describe 17 consecutive cases of HHV8-negative PEL at our institution.

**Design:** Cases of large cell lymphoma involving an effusion were retrieved from our pathology database. After all cases that were HHV8+, had a prior lymphoma diagnosis, and/or evidence of extracavitary lymphoma had been excluded, 17 HHV8-negative cases remained for study. The cytology and available immunocytochemistry and cytogenetics were reviewed. Patient demographics, history, and outcome were obtained from electronic medical records.

**Results:** Most patients were elderly (median age 86 yrs) and 13 (76%) were female. 4 of 17 were HIV negative; an HIV test result was not available for 13 patients. 7 (41%) had CHF. 2 had prior diagnoses of CLL and 1 had a prior diagnosis of follicular lymphoma, but the HHV8-negative PEL was clinically thought to be unrelated in each case. 2 were heart transplant recipients. The effusion was pleural in 9 (53%), peritoneal in 4 (24%), pericardial in 3 (18%) cases and pleural and pericardial in 1 (6%) case. 15 (88%) cases were CD20+. EBER in-situ hybridization for EBV was negative in 16 (94%) cases and positive in 1 heart transplant recipient. 15 cases had sufficient information for classification by Hans algorithm (CD10, BCL6, MUM1): 11 (73%) were non-germinal center phenotype, while 4 (27%) were germinal center phenotype. 3 of 14 cases were MYC+ by IHC. FISH/karyotyping was performed on 5 of 17 cases. 1 case had a MYC rearrangement and 2 cases had a BCL6 rearrangement by FISH. 2 cases had normal karyotypes by conventional analysis. Follow-up (5 days-12 yrs) was available in 8 patients. 3 survived at least 8 years, while 5 died within 4 months post-HHV8-negative PEL diagnosis, including 4 from conditions unrelated to lymphoma.

**Conclusions:** Large cell lymphomas that occur in body cavity effusions without detectable lymphomatous masses can be HHV8-negative. These HHV8-negative PEL are usually composed of large malignant CD20+ lymphoid or lymphoplasmacytoid cells and are infrequently MYC+ by IHC. Compared to HHV8+ PEL, HHV8-negative PEL primarily affect the elderly, lack a documented HIV+ history and are associated with a longer survival.

#### 502 A Detailed Method for Cytology Workflow Tracking

LJ Vaickus, R Tambouret. Massachusetts General Hospital, Boston, MA.

**Background:** Due to increasing demands on pathology services to be both efficient and relatively free of significant errors much interest has been focused on the monitoring the workflow of personnel. In cytopathology, the highest throughput employees are the cytotechnologists who pre-screen a high percentage of the cases which are accessioned. Many past studies have sought to determine the characteristics of their day to day workflow to establish guidelines for aspects of their job such as maximum allowable case load. While the data collected was valuable in determining practice guidelines for cytotechnologists, the studies suffered in that they did not represent a "real" workday, had limited temporal resolution, were obtrusive to the participant and were prone to recording error. We report the development of a program for tracking cytotechnologist workflow which significantly increases the quantity, quality and resolution of workload data while reducing error and inconvenience.

**Design:** The study included all cytotechnologists at Massachusetts General Hospital. Participants were provided with a laptop with Excel2003 and the program TimeStamper. TimeStamper was designed to minimize manual input. Single clicks recorded a time stamped datapoint for the various tasks performed in screening a case. These steps were Pre-screen (medical record and ID), Screen (slide screening) and Post-screen (signout work). Additionally, specimen number was recorded for all cases, type of screening (e.g. field of view, full slide review or both) was recorded for GYN cases and slide number was recorded for Non-GYN cases.

**Results:** We found that the participants had very few difficulties in using the software. We generated a large dataset which demonstrated that all aspects of Non-GYN cases (slide-adjusted) take significantly longer than GYN (Total time = 398.3 ± 13.7s vs 348.6 ± 3.9s, p < 0.0001) with the exception of post screening work. Additionally we found that GYN cases took significantly longer to complete in the afternoon than the morning (Total time = 357.3 ± 5.8s versus 338.4 ± 4.9s, p = 0.015). Interestingly, no correlation was found between day of the week and time taken to complete cases suggesting that fatigue occurred in the afternoon on a daily basis, but there was no additive effect during the week.

**Conclusions:** We have developed a software tool for collecting large amounts of high quality workload data in a real world cytopathology department with minimal manual input and reduced inconvenience to the user. Many interesting analyses remain including correlating screening errors with case type and time spent screening.

#### 503 Cytotechnologist Performance at Screening for Nuclear Atypia in Thyroid Fine Needle Aspirates

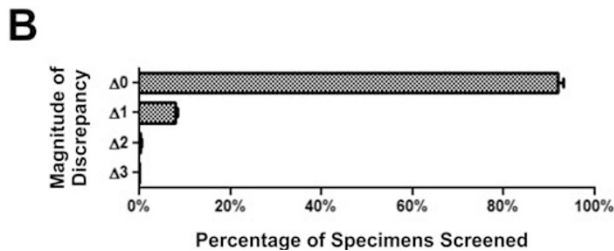
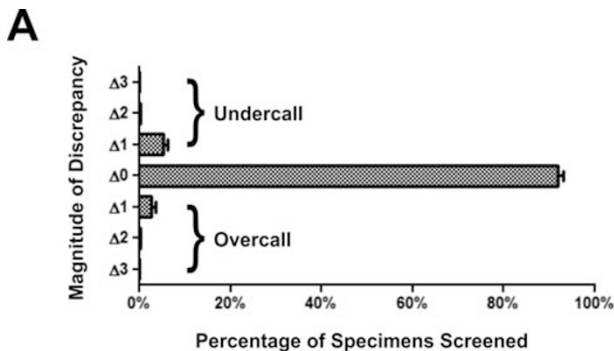
CJ VandenBussche, SZ Ali, C Adams, MT Olson. The Johns Hopkins Medical Institutions, Baltimore, MD.

**Background:** The cytotechnologist (CT) position has significantly evolved from Pap test screening to include multiple roles, such as the screening of non-gynecological specimens, on-site evaluation (OSE), and interfacing cytopathology with molecular

methods. While CT performance has been well-established in the screening of Pap smears, more recent studies have focused on CT performance in these new roles. Here we examine our institutional CT performance at screening for nuclear atypia in thyroid fine needle aspirates (FNA).

**Design:** Our archives were searched over a 10 year period for all thyroid FNA specimens. The CT and cytopathologist (MD) diagnoses were collected. The diagnoses were compared and a discrepancy analysis was performed, which included 6274 nodules screened by 11 CTs.

**Results:** Specimens screened as atypical cells of unknown significance (AUS) with nuclear atypia (AUS-N) or suspicious for malignancy (SFM) by CT were more likely to differ from the final MD diagnosis than cases screened as PTC. 85.6% of cases screened as papillary thyroid carcinoma (PTC) were diagnosed as PTC, while 7.0% were downgraded to SFM and 4.4% were downgraded to AUS. By contrast, 19.4% of cases screened as SFM were upgraded to PTC, 29.6% downgraded to AUS, and 10% were downgraded to the benign category. For cases screened as AUS-N, most cases were downgraded to the benign category (39.8%), while 35.1% were diagnosed as AUS, 7.6% were upgraded to SFM and 2.4% were upgraded to PTC. Overall, less than 10% of cases were discrepant. 1-category discrepancies were the most common (7.8%), while 2-category discrepancies were rare (0.5%). Only 4 cases were 3-category discrepancies. When screening diagnoses of CTs are compared to MD diagnoses, 5.5% were undercalls and 2.8% were overcalls. The overall ratio of 1-category overcalls to undercalls ("Δ1-ratio") was -2.1. The 1-category discrepancy rate correlated with CT experience, as defined by number of thyroid nodules screened.



**Conclusions:** At our institution CTs perform excellently when screening for nuclear atypia in thyroid FNAs and are rarely discrepant with the MD diagnosis by more than 1 category. The 1-category discrepancy rate can track individual CT performance and appears to correlate with CT experience.

#### 504 Is IHC for Fibulin-3 Specific for Malignant Mesothelioma in Effusion Cytology?

C Velosa, U Krishnamurti, A Mohanty, Y Liu, JF Silverman. Allegheny General Hospital, Pittsburgh, PA; West Penn Hospital, Pittsburgh, PA.

**Background:** The distinction between reactive mesothelial cells (RM) and malignant mesothelioma (MM) in serous fluid cytology remains a diagnostic challenge due to overlapping cytologic features. Although immunohistochemical (IHC) studies have been reported to aid in the differential diagnosis, the ultimate gold standard is evidence of tissue invasion. Recently fibulin-3 has been reported to be a specific serum and effusion biomarker for MM (Pass et al. *Fibulin-3 as a blood and effusion biomarker for pleural mesothelioma*. *N Engl J Med*. 2012; 367(15):1417-27). We investigated the utility of IHC staining of fibulin-3 for MM in effusion cytology specimens.

**Design:** 68 effusion cytology cases (22 RM, 12 atypical mesothelial cells (AM), 13 MM and 21 metastatic adenocarcinoma (AC)) were evaluated. All cases of MM had concordant histologic confirmation. Staining for BER-EP4, mCEA, MOC31, calretinin, CK5/6 and fibulin-3 was performed on cell blocks. Membranous and/or cytoplasmic staining for all antibodies was independently scored as negative (<5% positivity) or positive (>5% moderate strong positivity).

**Results:** RM showed positive staining for fibulin-3 and calretinin in all cases and in 21/22 (95%) for CK 5/6. 10/12 (83.3%) of AM were positive for fibulin-3 and all cases showed positive staining for calretinin and CK 5/6. Of the MM cases, 12/13 (92.3%) were positive for fibulin-3, calretinin and CK 5/6. In addition, there was no difference on the intensity of staining for fibulin-3 between RM, AM and MM. All cases of RM and AM were negative for MOC-31, BER-EP4 and mCEA. 3/21(14.3%) AC cases showed positive staining for fibulin-3, 1/21 (4.8%) for CK 5/6 and all AC cases were negative for calretinin. MOC-31 and BER-EP4 were positive in all AC cases and mCEA in 12/21 (57%).

**Conclusions:** 1. Although serum and effusion levels of fibulin-3 have been reported as specific for MM, IHC for fibulin-3 is not specific for MM, since it showed similar staining in RM, AM and MM.

2. However, fibulin-3 is a sensitive (93%) and specific (86%) marker for identification of mesothelial proliferations compared to AC.

3. Therefore, fibulin-3 can be helpful as part of a IHC panel in addition to calretinin and CK5/6 for the work up of mesothelial proliferations versus AC in effusion cytology specimens, but should not be used as a specific IHC marker for MM in contrast to its utility as a serum and effusion biomarker.

#### 505 Microphthalmia-Associated Transcription Factor (MITF) Immunohistochemistry in the Diagnosis of Ocular Malignant Melanoma (MM)

JF Wang, CM Perrino, BT Collins. Washington University, Saint Louis, MO.

**Background:** Microphthalmia-associated Transcription Factor (MITF) is a highly sensitive and specific melanocytic cell marker commonly used in the work-up and diagnosis of cutaneous melanoma. The purpose of this study was to examine the utility MITF in the evaluation of ocular melanoma sampled by fine needle aspiration (FNA) biopsy and to compare it with other frequently used melanoma markers (Melan-A, HMB-45, S-100).

**Design:** A search of the pathology database for ocular FNA biopsies was performed (1998 to 2012). Data was collected from reports including diagnosis and immunohistochemistry (IHC) stains performed. All available H&E slides prepared from cell blocks of cases signed out as positive and suspicious for MM were reviewed. MITF IHC was performed on cell blocks with identifiable tumor cells.

**Results:** 454 cases of ocular FNA biopsies from 441 patients were identified (F = 225; M = 216; Race = 425 Caucasian; Age Range = 7 mo to 93 yr). The following diagnoses were rendered: MM (60.4%, 274/454), suspicious for MM (5.3%, 24/454), and alternative diagnosis (34.4%, 156/454). Among cases suspicious for MM, IHC was obtained in 20.8% (5/24) of cases. 8 IHC stains were performed, with Melan-A being the most common and positive in 100% (5/5) of cases. Among MM cases, IHC was obtained in 22.3% (61/274) of cases. 18 IHC stains were performed, with Melan-A being the most common (80.3%, 49/61) and positive in 85.7% (42/49) of cases. For this study, MITF was performed on 33.3% (8/24) of suspicious cases; it was positive in 50% (4/8) and non-contributory in 50% (4/8) of cases. MITF was performed on 36.9% (101/274) of MM cases; it was positive in 89.1% (90/101), negative in 2.0% (2/101), and non-contributory in 8.9% (9/101) of cases. Non-contributory results were due to insufficient tumor cells. In comparison to other MM markers, MITF has 97.8% sensitivity (HMB-45 92.9%; Melan-A 87%; S-100 78.6%) and 100% positive predictive value.

**Conclusions:** A variety of IHC stains performed on cell blocks were utilized in the evaluation of ocular FNA biopsy specimens and contributed significantly in providing a specific diagnosis. MITF demonstrated a high degree of sensitivity and is useful in the work-up of ocular melanoma sampled by FNA biopsy.

Immunostains Obtained in Work-Up of Cases Positive for MM

	Positive	Negative	Total
Melan-A	42	7	49
S-100	10	3	13
HMB-45	26	2	28
Mart-1	3	0	3
MITF	1	0	1

Comparison between Melanoma Markers

	Sensitivity	Specificity	PPV	NPV
MITF (study)	97.8	NA	100	NA
HMB-45	92.9	100	100	75
Melan-A	87	90.9	97.9	58.8
S-100	78.6	100	100	57.1

#### 506 The Use of 3q26 Gain in Triage of Patients with Low Grade Squamous Epithelial Lesions on Pap Smear

RJ Wong, A Levi, K Duch, D Chhieng. Yale School of Medicine, New Haven, CT.

**Background:** Approximately 20% of patients with low grade squamous abnormalities (i.e. LSIL/ASCUS) on cytology are found to have a high grade lesion (CIN2+) on follow up. Previous studies have shown that patients with low grade squamous abnormalities and 3q26 gain are more likely to harbor CIN2+ on histologic follow up. The goal of this study is to determine the effectiveness of the 3q26 gain assay in triaging patients with low grade squamous abnormalities in order to reduce unnecessary referrals to colposcopy.

**Design:** From 2011-2013, 200 patients with a diagnosis of LSIL/ASCUS and positive HR HPV were subjected to 3q26 gain assay (Ikonyis, Inc., New Haven, CT). Samples were collected as part of routine cervical screening using the Surepath and ThinPrep systems. Slides were hybridized using the OncoFISH cervical probe kit. The 3q26 gain assay was considered positive if two or more cells showed more than four 3q26 FISH signals. Histologic or cytologic follow up occurred within 12 months.

**Results:** Of the 200 cases analyzed, 6 cases were QNS for 3q26 gain assessment and were excluded from further analysis. A total of 23 cases (23/194) were positive for the 3q26 gain assay. Follow up data was available in 148 patients, with histologic and cytologic follow up in 94 and 54 cases, respectively. Patient ages ranged from 20-66 (mean 35) years. Of index cytologic cases, 10 of 76 (13%) LSIL cases and 6 of 66 (9%) of ASCUS cases were positive for 3q26 gain. Table 1 summarizes the results of the 3q26 gain assay and follow up outcomes. Sensitivity of 3q26 gain assay as a triage test for patients with low grade squamous abnormalities was 33.3% (95% CI 14.4-58.9%); specificity was 90.8% (95% CI 84.1- 94.9%); positive predictive value was 33.3% (95% CI 14.4-58.9%); and negative predictive value was 90.8% (95% CI 84.1-94.9%).



	NILM/CIN1	CIN2 or CIN3	Totals
3q26 gain present	12	6	18
3q26 gain absent	118	12	130
Totals	130	18	148

Table 1. Presence of 3q26 gain in index cytologic specimens compared to histologic/cytologic follow-up. (p<0.01, Chi Square Test)

**Conclusions:** To our knowledge, our study of 194 patients is the largest study to date in assessing 3q26 gain in patients with LSIL/ASCUS on cytology with subsequent follow up. Although there is a statistically significant difference in the incidence of CIN2+ lesions on follow up among patients with or without 3q26 gain, the sensitivity (33.3%) and negative predictive value (90.8%) of 3q26 gain as a marker for CIN2+ lesions on follow up are undesirably low as a negative triage test for women with low grade squamous abnormalities on Pap smear.

### 507 Histopathologic Follow-Up Outcomes and Prevalence of HPV 16/18 Genotypes in Women with Negative Cytology and Positive High Risk HPV Test Results in a Large Academic Womens Hospital Laboratory

AH Woodard, Z Li, M Austin, J Beere, C Zhao. Magee-Womens Hospital of University of Pittsburgh Medical Center, Pittsburgh, PA.

**Background:** Recently updated ASCCP guidelines recommend that women 30 and older with cytology negative and positive high risk (hr) HPV results undergo either repeat co-testing within one year or HPV genotype testing for HPV 16/18 and colposcopic evaluation of those positive for HPV 16/18. Limited clinical data is available for assessing the effectiveness of this management strategy.

**Design:** A retrospective database search was conducted to retrieve Pap-/HPV+ co-testing cases between May 2010 and June 2013 at our institution where ThinPrep Pap tests are routinely performed using the ThinPrep Imaging system. The Hybrid Capture 2 (HC2) method was used to detect hrHPV from residual PreservCyt samples. Genotyping for HPV 16/18 was performed using the Cervista 16/18 Genotyping Test. Clinical information, HPV 16/18 genotyping results and histopathologic follow-up results were also collected.

**Results:** Among a total of 992 Pap-/HPV+ cases, 824 had valid HPV 16/18 genotyping results with 101 (12.3%) positive for HPV 16, 18 or both. HPV 16 was detected most frequently (9.1%), followed by HPV 18 (2.4%) and both 16 and 18 (0.7%). All HPV 16/18-positive cases were in women 30 years or older, except for one case (Table 1). 51 of 101 (50.5%) women had documented histopathologic follow-up results over an average follow-up period of 3.5 months (range of 0.5 to 22.5 months). Histopathologic CIN 2/3 was diagnosed in 5 cases (9.8%) and CIN 1 was diagnosed in 13 cases (25.5%). All 5 CIN 2/3 cases were diagnosed within one year of the initial Pap-/HPV+ result. No patients were diagnosed with invasive cervical carcinoma.

HPV 16/18 detection in 824 cases with Pap-negative/HPV-positive results

Age group	Case #	HPV 16+ (%)	HPV 18+ (%)	Both positive
<30	9	1 (11.1%)	0	0
≥30	815	74 (9.1%)	20 (2.5%)	6 (0.7%)
Total	824	75 (9.1%)	20 (2.4%)	6 (0.7%)

**Conclusions:** This is a large study demonstrating that HPV 16/18 accounted for 12% of hrHPV types in Pap-/HPV+ cases in our population. Approximately 50% of women with positive HPV 16/18 had colposcopy documented in our system, and high grade CIN was diagnosed in 10% of those colposcoped within 12 months. Our data support routine HPV 16/18 genotyping for Pap-/HPV+ women and the current guidelines recommending that HPV 16/18 positive patients should undergo immediate colposcopy.

### 508 Ultrasound Guided FNA of Thyroid Performed by Cytopathologists Enhances Bethesda Diagnostic Accuracy

M Wu, Z Zhang, Q Si, F Salem, A Szporn. Icahn School of Medicine at Mount Sinai, New York, NY.

**Background:** Ultrasound (US) guided fine needle aspiration (FNA) biopsy of thyroid can be performed by either a radiologist, or an endocrinologist or a cytopathologist. All samples are examined and reported by cytopathologists based on The Bethesda System for Reporting Thyroid Cytopathology (BS). A question is whether there is any performer-dependent difference. This study is designed to answer such question.

**Design:** 651 thyroid US-FNA cases including 283 performed by cytopathologists and 368 by non-cytopathologists during the period of 09/01/2010 to 5/30/2012. All the cases from the non-cytopathologist group were done without immediate cytologic evaluation. The cases from the cytopathologist group were all performed, onsite evaluated and finally signed out by cytopathologists. For each case, BS was applied for diagnostic classification. The cases was also correlated with surgical follow-up (SFU). The statistical analysis for the cases with SFU was made by using surgical diagnosis as the gold standard.

**Results:** Among the 283 cases performed by cytopathologists, there were 8(2.8%) non-diagnostic/unsatisfactory (BS 1), 197(69.6%) benign (BS 2), 31(11%) atypical/follicular lesion of undetermined significance (BS 3), 14(5%) follicular neoplasm (FN)/suspicious for FN (BS 4), 12(4.2%) suspicious for malignancy (BS 5), and 21(7.4%) malignant (BS 6), and there were 55(19.4%) cases with SFU. The 368 cases performed by others showed 76 (21%) BS 1, 238 (65%) BS 2, 26 (7%) BS 3, 10 (3%) BS 4, 9 (2.5%) BS 5, and 9 (2.5%) BS 6, and there were 26 (7%) cases with SFU. In comparison, cytologists performed group showed fewer unsatisfactory cases (2.8% vs. 21%); considerably higher percentage of cases falling in to BS2-6; and markedly high rate of SFU (19.4% vs. 7%). The Statistical results based on SFU revealed that the cytopathologist group achieved better sensitivity (91.3% vs. 78%); better PPV (87.5% vs. 70%); similar NPV (88.2% vs. 88%); slightly better specificity (83.3% vs. 82%); and better overall accuracy (87.8% vs. 81%) comparing with the non-cytopathologist group.

**Conclusions:** US-FNA performed by cytopathologists showed a lower unsatisfactory rate, higher rate of SFU, higher sensitivity, better PPV and greater overall accuracy.

Having actual hands-on experience gives cytopathologists more precise knowledge of the lesion before aspiration. On site cytologic evaluation can help to triage a specimen appropriately. Whereas in the non-pathologist group, some information may have been lost between the aspiration and interpretation.

### 509 The Diagnostic Utility of Urine Cytology for Detection of BK Polyomavirus in Transplant Patients: A Comparison of Urine Cytology with Real-Time Quantitative Serum BK Polymerase Chain Reaction

J Xing, J Reynolds, GW Procop, Y Zhang. Cleveland Clinic, Cleveland, OH.

**Background:** BK polyomavirus infection is one of the leading causes for irreversible graft failure in transplant patients. Screening and early intervention including appropriate reduction in immunosuppressive therapy is critical. The presence of decoy cells in the urine is a characteristic feature for BK viraemia. It has been suggested that urine cytology can be used as a screening test. However, the sensitivity and specificity of urine cytology for early detection of BK viral infection is not well established. To further investigate the significance of decoy cells in urine cytology, we compared the results between the urine cytology (UC) and the real-time quantitative BK virus polymerase chain reaction test (Qt-BK PCR) in patients after the transplantation.

**Design:** A cohort of post-transplantation patients with serum BK polyomavirus levels >5000 copies/ml determined by Qt-BK PCR from 2008 to 2013 were studied. 35 total patients were identified with both urine cytology sample and PCR results. Review of clinical and pathologic reports for each patient was performed. The urine cytology slides were retrieved and reviewed. The time span between Qt-BK PCR test and UC less than one week is defined as co-testing.

**Results:** 35 patients (24 Male and 11 female) had transplant, (30 with renal transplant, 4 with bone marrow/stem cell transplant and 1 with a lung transplant). The mean age at transplant was 44 years (range 21- 75 years). A total of 44 UC specimens had either concurrent or remote Qt-BK PCR test. Thirty-seven UC specimens had a correlative Qt-BK PCR within 5 weeks and seven UC had Qt-BK PCR test more than 5 weeks apart. Compared to Qt-BK PCR for patients who had both UC and Qt-BK PCR within 5 weeks, the sensitivity of UC was 71%, the specificity was 75%, positive predictive value was 79% and the negative predictive value was 67%. A total 23 co-tested specimens were identified. Compared to Qt-BK PCR, the sensitivity of UC was 86%, the specificity was 56%, positive predictive value was 75% and the negative predictive value was 74%. The accuracy of UC was 74%.

**Conclusions:** Urine cytology for detection of BK polyomavirus is a sensitive, inexpensive diagnostic test that is complimentary to Qt BK- PCR for the monitoring of patients at risk for BK virus infection.

### 510 Prostatic Adenocarcinoma (PCa) in Urine Cytology: A Clinicopathologic Analysis

Y Zhang, J Xing, JK McKenney. Cleveland Clinic, Cleveland, OH.

**Background:** Malignant cells of PCa may occasionally exfoliate in urine. Rarely, PCa may be first diagnosed by urine cytology. The aim of our study is to investigate the significance of finding PCa tumor cells in the urine cytology specimens with regard to other clinicopathologic variables.

**Design:** Cases with urine cytology positive for prostatic adenocarcinoma were identified from an archival search (1983-2013). For each patient, clinical and histopathologic data were reviewed. Age and year of initial diagnosis, Gleason scores, tumor stage, tumor location, and patient outcomes were recorded when available. Available urine cytology slides were retrieved and reviewed.

**Results:** 15 patients were identified. The patient's age at initial diagnosis ranged from 53 to 84 years old (mean: 68). 9 patients had a long history of prostate carcinoma, but re-presented with secondary involvement of the bladder. 4 patients had primary involvement of bladder at the presentation. These patients frequently presented with hematuria and urinary retention. The initial diagnosis of PCa was first suggested by urine cytology in the other 2 cases. Cytomorphologically, the tumor cells were often single or in cell groups with high nuclear/cytoplasmic ratio, large round and uniform nuclei, and conspicuous nucleoli. All patients had surgical tissue diagnosis (2 patients had prostatectomy and 13 with core biopsy). 13 patients had a documented Gleason score and all were >=8; 12 of these had documented clinical stage IV and one stage II disease. The patient with stage II disease showed ductal histology. Interestingly, UroVysion test was positive in the two cases tested. Follow-up information available on 12 patients (range: 2-156 months; mean: 46.8 months.) showed that 8 patients died of disease, 4 patients are still alive (3 alive with disease and 1 disease free).

**Conclusions:** The identification of PCa cells in urine cytology is rare, but is associated with high grade, high stage disease. Correlation of positive urine cytology results with biopsy findings might aid in patient risk stratification.

### 511 The Role of SOX11 Immunostaining in Confirming the Diagnosis of Mantle Cell Lymphoma on Fine-Needle Aspiration Samples

YH Zhang, C Liu, M Dawlett, M Guo, X Sun, Y Gong. The University of Texas MD Anderson Cancer Center, Houston, TX.

**Background:** Diagnosing and subtyping B-cell non-Hodgkin lymphoma (BC-NHL) usually requires immunophenotyping by flow cytometry and/or immunohistochemistry. Fine-needle aspiration (FNA) is often used to document the stage or recurrence of a lymphoma, but immunophenotyping may not be performed due to limited cellularity. Mantle cell lymphoma (MCL) shows cytologic features that overlap with other types of mature BC-NHL that have small- to medium-sized cells. However, accurate diagnosis of MCL is important because MCL has relatively more aggressive biologic behavior and thus requires specific treatment regimens. SOX11 immunorepression has been

shown to be helpful in the diagnosis of MCL in formalin-fixed paraffin-embedded material. However, its value in the diagnosis of MCL on FNA samples has not been previously studied.

**Design:** A total of 63 FNA samples were retrospectively immunostained with mouse monoclonal antibody against SOX11 (MRQ-58, Cell Marque, CA; 1:200) on cytospins that contained Ficol-Hypaque-enriched mononuclear cells. The cytospins were prepared and stored in our tumor bank during FNA samples were collected. The final diagnoses of the cases, based on a multidisciplinary approach, were MCL (n = 9), marginal zone lymphoma (n = 8), follicular lymphoma (n = 10), small lymphocytic lymphoma (n = 10), Burkitt lymphoma (n = 9), plasma cell myeloma (n = 7) and benign reactive lymph nodes (n = 10).

**Results:** Eight of the 9 cases of MCL (89%) showed positive nuclear staining for SOX11 with a diffuse pattern. Cases of other types of BC-NHL, plasma cell lymphoma, and benign lymph nodes did not demonstrate any immunoreactivity. The sensitivity of SOX11 staining was 89% and the specificity was 100%.

**Conclusions:** SOX11 immunostaining on FNA samples is highly sensitive and specific for MCL and can be used as a reliable adjunctive diagnostic test to confirm MCL, especially in patients with a history of MCL.

## 512 HPV Testing and Reporting Rates in 2012

*C Zhao, AT Moriarty, RH Tambouret, M Ghofrani, M Husain, R Laucirica, A Laser, A Fischer, IT Ocal, RJ Souers, DK Russell, BA Crothers.* University of Pittsburgh Medical Center, Pittsburgh, PA; AmeriPath, Indianapolis, IN; Massachusetts General Hospital, Boston, MA; PeaceHealth Lab, Vancouver, WA; University of Central Florida, Orlando, FL; Baylor College of Medicine, Houston, TX; North Shore LIJ Health System, New Hyde Park, NY; University of Massachusetts Medical School, Worcester, MA; Mayo, Scottsdale, AZ; CAP, Chicago, IL; Rochester Medical Center, Rochester, NY; Col Mil US WRNMMC, Washington, DC.

**Background:** The CAP surveys aid in establishing national benchmarks for diagnostic categories and other practice parameters. The last CAP HPV testing survey was in 2006.

**Design:** This CAP HPV Survey was distributed to the laboratories participating in either CAP HPV proficiency testing or PAP education program in 2012.

**Results:** 1022 laboratories responded to the Questionnaire. 54% Labs send HPV testing to reference labs and only 15% perform the test in the cytology lab. HC2 is the most commonly used method (42%); Cervista is the second most commonly used method (37%). HPV testing was offered as a reflex for a Pap test reported as ASC-US in 90% of labs, as co-test for women  $\geq 30$  years in 60%, for reflex of ASC-H in 43%, for reflex AGC in 27.8%. HPV positive rates for the Pap categories are listed in Table 1. HPV16/18 genotype testing is performed for women with positive HR-HPV testing and negative Pap cytology (HPV+/Pap-) in 41% of labs; for women  $< 30$  years with HPV+/Pap- co-test in 35% of labs; for women with HPV+/ASC-US in 38% of labs. Cervista is the most common (49%) and Roche is the second most common method (27%) used for HPV16/18 genotyping. 93% labs use CAP CHPV as their HPV proficiency testing.

HR HPV Positive Rate Percentiles

Categories	#Labs	25th	50th	75th	90th
ASC-US ( $\geq 30$ y)	43	25.0	30.7	38.3	53.3
ASC-US ( $< 30$ y)	32	42.1	51.3	56.5	63.2
ASC-US	110	26.4	38.3	47.8	54.7
ASC-H	103	1.0	53.8	68.1	79.0
NILM ( $\geq 30$ co-test)	81	4.4	6.5	11.0	22.5
AGC	90	0.0	13.2	27.0	39.3
LSIL (postmenopausal)	41	0.8	20.0	64.1	76.8

**Conclusions:** Reflex HPV testing remains the most common pattern of HPV testing, but co-testing for women  $\geq 30$  is significantly increased compared to 2006. The most common reflex indication is ASC-US. However reflex testing is used variably for other categories. HPV positive rates are similar between women  $\geq 30$  with ASC-US and postmenopausal women with LSIL, significantly lower than that for women  $< 30$  with ASC-US. 41% of laboratories perform HPV16/18 genotyping for women with HPV+/Pap- co-test. The data provides a glimpse into newer trends of HPV testing practices.

## 513 Comparison of TBS Reporting Rates for LBCs and CT in China's Largest CAP Certified Laboratory: Analysis of 1,394,389 Pap Reports

*B Zheng, X Liang, MR Austin, C Chen, S Yan, Z Li, C Zhao.* Kingmed Diagnostics, Guangzhou, Guangdong, China; University of Pittsburgh Medical Center, Pittsburgh, PA.

**Background:** There is no well established national cervical screening program and standard for cytology quality control in China. Data on Pap reporting rates for categories of cytologic abnormality in China is very limited.

**Design:** A retrospective study was designed to summarize all Pap test reports at Kingmed cytology Lab in Guangzhou from 2007 to 2012. Four types of LBCs and CT were used. Pap tests were reported using TBS 2001 terminology. All Pap test screening and final interpretations were performed by about 30 pathologists whose practices are limited to cytology. Most attended a half to one year training course in the our Cytology School.

**Results:** A total of 1,394,389 Pap cytology reports were completed, including 1,068,092 LBC (76.6%) and 326,297 CT (23.4%). Reporting rates for various TBS 2001 categories and specific Pap test methods are summarized in Table 1. Abnormality rates reported were higher with LBC than with CT in all TBS categories ( $p < 0.001$ ). Among LBC, LSIL rates were highest with SurePath and lowest with LPT. HSIL rates were similar with ThinPrep and SurePath and significantly higher than with either LPT or LCT. ASC-US rates were highest with SurePath and lowest in LPT. TBS reporting rates from the Lab in general were compatible with CAP 2006 survey benchmarks, although AGC rate in was low compared to CAP benchmarks. A total of 665 SCC were reported during the study period.

## Reporting Rates

	ThinPrep	SurePath	LPT (USA)	LITUO (China)	CT	Total
Case #	928884	63465	50422	25321	326297	1394389
ASCUS	5.02	6.36	4.04	7.01	2.26	4.42
ASC-H	0.37	0.35	0.32	0.34	0.20	0.33
LSIL	2.46	3.09	1.57	2.64	0.67	2.03
HSIL	0.81	0.88	0.45	0.76	0.30	0.68
SCC	0.07	0.02	0.02	0.008	0.005	0.05
AGC	0.08	0.04	0.03	0.06	0.006	0.06
AIS/ADC	0.004	0	0	0	0	0.002
ASC/SIL	1.62	1.68	2.13	2.16	2.52	1.75
UNSAT %	3.18	1.43	5.49	0.84	0.02	2.40

**Conclusions:** The largest data may contribute to establishing a baseline for better understanding of the current status of cervical screening in China. The results show that LBCs have significantly higher SIL and ASC report rates than with CT. The LBC formulation made in China had similar overall abnormal cytology reporting rates compared to USA LBC products, but the Chinese product is much less expensive. SCC was identified in 48 per 100,000 women. The incidence of cervical cancer in China may be higher than expected. AGC reporting rate was very low compared to CAP benchmarks. Mostly, this reflects the need for additional education on this subject. National standardization and quality control based on the CAP Accreditation Program may be considered.

## 514 Sensitivity of the High-Risk HPV Hybrid Capture II (hrHPV HC2) Test Using SurePath Specimens in Detection of Cervical High Grade Precancerous and Cancerous Lesions

*F Zhou, R Pulinthanathu, P Elgert, A Simsir.* New York University School of Medicine, NY, NY.

**Background:** HPV testing is now "standard of care" in the detection/management of cervical squamous cell cancer (SCC) and its high grade precursors (CIN II-III). Prevalence of HPV is 95-99% in cervical cancer and 70-90% in CIN II-III. SurePath and ThinPrep are the 2 current FDA-approved cervical cancer pap screening methods. Though SurePath is NOT FDA-approved for HPV testing, labs use it with proprietary self-validation processes. Recently there is concern in the media/literature about the high false negative rate of HPV testing with SurePath. This is very important as new guidelines base patient screening intervals/management on HPV testing. Our lab has used SurePath since 2004. This study aims to calculate the sensitivity of the high-risk HPV Hybrid Capture 2 (hrHPV HC2) test on SurePath specimens.

**Design:** We searched our laboratory information system for surgical cases diagnosed from 2009 to 2013 as CIN II, CIN III and cervical SCC. For each case, we recorded screening test results from SurePath pap and Digene hrHPV HC2 tests in the 5 years before surgical diagnosis. Using the surgical diagnosis as gold standard, we calculated the sensitivities of pap and HPV tests. Abnormal pap (ASC & above) and positive HPV results were counted as true positives, while cases with only normal pap and only negative HPV results were counted as false negatives.

**Results:** There were 565 cases of CIN II, CIN III & cervical SCC. 447 had prior pap tests; of these, 61.7% were age  $\geq 30$ . 199 had prior HPV tests; of these, 60.8% were age  $\geq 30$ .

**Table 1: Sensitivity (SN) & False Negative Rate (FNR) of Pap and HPV Tests in the Detection of CIN II, CIN III, and SCC**

	Screening Results (# of Women)	Overall SN/FNR	SN/FNR for Ages $< 30$	SN/FNR for Ages $\geq 30$
Total # of Women w/ Prior Pap Tests:	Any Abnormal (True Positive) Pap Result:	SN: 437	SN: 97.8%	SN: 98.8%
	Only Normal (False Negative) Pap Results:	FNR: 10	FNR: 2.2%	FNR: 1.2%
Total # of Women w/ Prior HPV tests:	Any True Positive HPV Result:	SN: 189	SN: 95%	SN: 98.7%
	Only False Negative HPV Results:	FNR: 10	FNR: 5%	FNR: 1.3%

**Table 2: Sensitivity (SN) of Pap & HPV Tests, Per Diagnosis**

Surgical Diagnosis	# of Women	Women w/ Any Prior Pap Test	Women w/ Any Abnormal Pap Result	Women w/ Any Prior HPV Test	Women w/ Any +ve HPV Result	SN of Pap Test	SN of HPV Test
CIN II	265	227	222	111	106	97.8%	95.5%
CIN III	280	213	209	86	82	98.1%	95.3%
SCC	20	7	6	2	1	85.7%	50%

**Conclusions:** Our results show the following:

1. The overall sensitivity of HPV testing on SurePath specimens is within acceptable range.
2. Pap and HPV tests should continue to be used complementarily as both have low but clinically significant false negative rates in the detection of cervical SCC and its high grade precursors.

### 515 The Value of Smoking, Nodule Number and Known Extrapulmonary Adenocarcinoma in Distinguishing Primary Lung Adenocarcinoma from Metastatic Adenocarcinoma

*B Zhu, S Dalal, D DeFrias, X Lin.* University of Illinois at Chicago, Chicago, IL; Northwestern University, Chicago, IL.

**Background:** Lung cancer is one of the most common cancer and the leading cause of death world-wide. The lung is also the organ that is most frequently involved by metastatic adenocarcinoma (MA). It is important to distinguish primary lung adenocarcinoma (PLA) from MA to optimize therapy. We assess the value of clinical information (smoking, nodule number and known extrapulmonary adenocarcinoma (EPA) in differentiating PLA from MA.

**Design:** 204 cases with lung nodules diagnosed as adenocarcinoma by FNA and/or needle core biopsy were retrieved. The prior history of EPA, smoking and nodule number detected by CT scan was also retrieved. Based on morphology, IHC results and surgical resection, the patients were divided into 3 groups, PLA-EPA, PLA-without EPA (PLA-WOEPa) and MA.

**Results:** See Table 1 and Table 2.

Correlation of PLA with smoking and multiple nodules

Group	No.	Smoker (%)	Multiple Nodules (%)
PLA-EPA	55	37 (37.3)	30 (54.5)
PLA-WOEPa	88	71 (80.7)	48 (54.5)
MA	61	24 (39.3)	52 (85.2)
P1		< 0.005	< 0.005
P2		< 0.005	< 0.005

Chi-square test. P1: Comparison of PLA-EPA with MA; P2: Comparison of PLA-WOEPa with MA.

Bayesian probabilities of PLA in patients smoking, multiple nodules and EPA

Category	No. (Total 143)	Prior Probability (%)	Posterior Probability (%)
Smoker	108	75.5	87.8
Non-smoker	35	24.5	43.2
Multiple Nodules	78	54.5	73.7
Single Nodule	65	45.5	66.2
EPA	55	38.5	59.5
WOEPa	88	61.5	78.9

**Conclusions:** 1. The incidence of smoking in PLA was much higher than MA, and smoker had a higher posterior probability to be PLA than a non-smoker, indicating that smoking plays a significant role in PLA no matter with or without a history of EPA.

2. The incidence of smoking in PLA-EPA was less than PLA-WOEPa, suggesting that besides smoking, other factors, such as occupational exposure, hereditary factors, genomic mutations of tumor suppressor genes, etc., also play a role in the increased incidence of PLA in the patients with a history of EPA.

3. The incidence of multiple nodules in PLA was less than MA. However, a patient with multiple nodules had a similar posterior probability to be PLA to a single nodule.

4. A patient with EPA had a lower posterior probability to be PLA than WOEPa.

5. Although our data suggested that a patient with smoking, single lung nodule or WOEPa had higher chance to be PLA, all these clinical information are not reliable and helpful in differentiating PLA from MA as the incidence of non-smoking history, multiple nodules and presence of EPA is still high in PLA, 24.5%, 45.5% and 38.5%, respectively.

## Dermatopathology

### 516 Monocytic Leukemoid Papulosis: A Self Limiting Cutaneous Proliferation Associated with Clonal Myeloproliferative Disorders

*RM Abraham, S Verma, CS Friedman, W Tam, NM Drucker, CM Magro.* Weill Cornell Medical College, New York, NY; Memorial Sloan-Kettering Cancer Center, New York, NY; Yale University, New Haven, CT.

**Background:** We propose a new clinical entity, monocytoid leukemoid papulosis (MLP), characterized clinically by self-remitting papules akin to lymphomatoid papulosis (LyP), a cutaneous, self-remitting lymphoproliferative disorder. Morphologically and immunophenotypically, MLP can resemble blastic plasmacytoid dendritic cell neoplasm (BPDCN), a highly aggressive neoplasm which primarily presents in the skin, due to histopathologic and immunophenotypic overlap. However, in contrast to BPDCN, the cells of interest in MLP express myelomonocytic markers and are monocytic morphologically, conferring a myeloid dendritic cell (MDC) phenotype. MLP is associated with chronic myeloproliferative disorders (MPD).

**Design:** 9 cases of MLP were prospectively encountered in the routine and referral practices of one author (CMM). Their light microscopic appearances were correlated with immunohistochemistry and clinical features.

**Results:** Patients ranged from 64 to 84 years of age with 6 males and 3 females. All patients had a waxing and waning papular skin rash. Four patients had underlying chronic myelomonocytic leukemia (CMML), 1 with myelodysplastic syndrome, 2 with myelofibrosis and 2 patients with no history of MPD. The clinical courses were variable; 1 patient died of transformation to acute myeloid leukemia and one patient experienced CMML relapse. The other 7 patients are alive and stable. At least 6 of the patients had a peripheral blood monocytosis. In each case, biopsies showed a well differentiated monocytoid infiltrate with a distinctive immunophenotype overlapping with BPDCN with variable CD4, MXA, CD56, TCL1 and CD123 positivity. However, in contrast to BPDCN, the cells expressed the myeloid markers CD68, CD11c, and lysozyme which are characteristically negative in BPDCN. The cases also variable positivity for the terminally differentiated dendritic markers CD14, CD83, HLADR and BDCA-3.

**Conclusions:** MLP presents as an indolent, papular, cutaneous infiltrate of mature monocytes with myeloid dendritic cell differentiation. They are seen in the setting of

underlying chronic myeloproliferative disorders and are associated with peripheral blood monocytosis. There is no definitive association between MLP and a more aggressive clinical course at least in the majority of cases studied in this series. MLP should not be confused with BPDCN or with acute myeloid leukemia cutis, two far more aggressive conditions.

### 517 Borderline Deep Penetrating Nevi: A Unique Subset of Ambiguous Melanocytic Tumors with Malignant Potential and Normal Cytogenetics

*RM Abraham, R Guo, S Li, X Wang, S Proper, M Mihm, AN Crowson, CM Magro.* Weill Cornell Medical College, New York, NY; Memorial Sloan-Kettering Cancer Center, New York, NY; University of Oklahoma Health Sciences Center, Oklahoma City, OK; Brigham and Women's Hospital and Harvard Medical School, Boston, MA; Regional Medical Laboratories, Tulsa, OK; Center for Dermatology and Skin Surgery, Tampa, FL.

**Background:** Deep penetrating nevi (DPN) are a relatively uncommon subtype of melanocytic nevi with characteristic morphologic features. A small subset of these lesions exhibit atypical features (cytologic and architectural atypia, mitotic activity) seen in melanoma that create a histopathologically and biologically ambiguous category. These nevi we term the DPN variant of borderline melanocytic tumor (borderline DPN). Unequivocal melanomas can show morphologic features of DPN, which have been termed plexiform melanomas. There is little literature on borderline DPN and whether these lesions progress to overt clinical melanoma with fatal outcomes.

**Design:** 40 cases of borderline DPN lesions were identified along with 6 cases of plexiform melanoma. Clinical follow up was obtained, along with cytogenetic analysis in the form of fluorescent in situ hybridization (FISH) and/or comparative genomic hybridization (CGH).

**Results:** The borderline DPN cases included 24 females and 16 males (mean age of 36 years). Common sites included the face and arm. Of sentinel lymph node biopsies performed, 1/3 of cases showed lymph node involvement. All patients in whom a more aggressive clinical approach was adopted remain free of disease. All 7 borderline DPN cases tested by CGH showed normal cytogenetics as did 7 of 9 cases tested by FISH. Of the plexiform melanomas, 4/6 patients died of disease. In 3 cases there was morphologic progression from a borderline DPN to overt melanoma. In one case of progression, cytogenetics was normal in the borderline DPN and then abnormal in the progressed melanoma; the other two fatal cases of progressive disease had normal cytogenetics.

**Conclusions:** Borderline DPNs are a unique subset of ambiguous melanocytic tumors associated with a high incidence of regional lymph node disease and exhibiting the potential for melanoma progression despite a normal cytogenetic profile. Patients with these lesions should be aggressively managed, with at least complete re-excision and consideration of sentinel node biopsy, regardless of cytogenetic data.

### 518 Comparison of Immunohistochemistry and Polymerase Chain Reaction in Detection of BRAF p.V600E Mutations in Melanomas

*A Al Habeeb, R Jin, S Kamel-Reid, E Torlakovic, C Wei, D Ghazarian.* University Health Network, Toronto, ON, Canada.

**Background:** As the major type of BRAF point mutation, BRAF p.V600E mutation recently emerged as a critical biomarker greatly utilized in the treatment of metastatic melanoma, which is most commonly assessed with an allele-specific polymerase chain reaction (PCR) methodology. A novel method in detecting BRAF mutation by immunohistochemical staining was developed recently with a BRAF pV600E mutation-specific monoclonal antibody (named VE1 antibody).

**Design:** This study compares the detection of BRAF p.V600E mutation between PCR and immunohistochemistry using the VE1 antibody. A total of 61 tissue samples from melanoma patients were evaluated by these two methods.

**Results:** PCR analyses revealed 32 positive, 26 negative and 3 inconclusive cases in the BRAF p.V600E/K mutation detection. Immunohistochemistry identified 91% and 88% of positive and negative cases respectively compared to that from PCR results. Further, 3 inconclusive cases in PCR detection were identified as BRAF p.V600E mutation positive by immunohistochemical staining.

**Conclusions:** In conclusion, the correlation rate between these two methods is excellent (89.6%) and immunohistochemistry can play an important role in detecting BRAF pV600E mutation, especially in PCR inconclusive cases.

### 519 Evaluation of Advanced Stage Squamous Cell Carcinoma of the Skin by Next Generation Sequencing Opens the Door for New Routes to Targeted Therapies

*RN Al-Rohil, AJ Tarasen, K Wang, CE Sheehan, GA Otto, G Palmer, R Yelensky, D Lipson, G Palmer, SM Ali, D Morosini, VA Miller, PJ Stephens, JS Ross.* Albany Medical College, Albany, NY; Foundation Medicine Inc, Cambridge, MA.

**Background:** Although skin squamous cell carcinomas (SSCC) are rarely high stage, on occasion they can be life threatening both due to local extension or metastasis. We hypothesized that comprehensive genomic profiling of high stage SSCC could identify genomic-derived drug targets of therapy for patients with conventional therapy-resistant disease.

**Design:** Hybridization capture of 3,769 exons from 236 cancer-related genes and 47 introns of 19 genes commonly rearranged in cancer was applied to  $\geq 50$ ng of DNA extracted from 25 SSCC FFPE specimens and sequenced to high, uniform coverage. Genomic alterations (base substitutions, small indels, rearrangements, copy number alterations) were determined and then reported for these patient samples. Actionable GA was defined as those identifying anti-cancer drugs on the market or in registered clinical trials (CT).

**Results:** There were 23 male and 2 female SSCC patients with a median age of 70 years (range 48-91 years). Fourteen (56%) SSCC were grade 2 and 11 (54%) grade 3. Fourteen (46%) SSCC were stage III and 11 (54%) were stage IV at time of sequencing.