Modern Pathology (2014) 27, 1386–1393

Comparison of molecular abnormalities in vulvar and vaginal melanomas

Sebastian Aulmann[1,7], Hans P Sinn[1,7], Roland Penzel[1], C Blake Gilks[2], Sarah Schott[3], Jessica C Hassel[4], Dietmar Schmidt[5], Friedrich Kommoss[5], Peter Schirmacher[1] and Stefan Kommoss[6]

[1]Institute of Pathology, Heidelberg University Hospital, Heidelberg, Germany; [2]University of British Columbia, Department of Pathology and Laboratory Medicine, Vancouver, British Columbia, Canada; [3]Department of Gynecology, Heidelberg University Hospital, Heidelberg, Germany; [4]Department of Dermatology, Heidelberg University Hospital, Heidelberg, Germany; [5]Institute of Pathology, Mannheim, Germany and [6]Department of Gynecology, Tuebingen University Hospital, Tuebingen, Germany

Malignant melanoma of the vulva and vagina is relatively uncommon and accounts for <5% of all melanomas in women. The aim of our study was to establish the biological properties and evaluate potential therapeutic targets in these tumors. We collected a series of 65 cases from three centers and re-evaluated the tumor tissue for predominant growth pattern (superficial spreading, nodular, and mucosal lentiginous) and tumor thickness. KIT (CD117) expression was detected immunohistochemically. In addition, tumors were screened for *BRAF*, *NRAS,* and *KIT* mutations by PCR and DNA sequencing as well as for *KIT* amplifications by fluorescence *in situ* hybridization. None of the cases contained *BRAF* mutations. *NRAS* mutations and *KIT* amplifications were detected in similar frequency (~12%) in tumors of the vulva and vagina. In contrast, *KIT* mutations were present in 18% of primary melanomas of the vulva, but in none of the tumors arising in the vagina. Moderate or strong KIT protein expression was detected in 30 cases, including all tumors with *KIT* mutations and 6 of the 7 with *KIT* amplifications. In conclusion, *BRAF* mutations are virtually absent in melanomas originating from the vulva or vagina, whereas *NRAS* mutations and *KIT* amplifications occur in both locations. *KIT* mutations appear to be specific for melanomas of the vulva, suggesting that in spite of the anatomic proximity, the development of vulvar and vaginal melanomas involves different molecular alterations which may be targeted by novel treatment approaches.
Modern Pathology (2014) **27,** 1386–1393; doi:10.1038/modpathol.2013.211; published online 7 March 2014

Keywords: melanoma; mutation; pathology

Malignant melanoma of the vulva and vagina are uncommon tumors representing <1% of all female genital tract malignancies. Typically, older women are affected; in population-based series, an average patient age of 70 years has been reported.[1] Overall prognosis largely depends on tumor stage and is poor in cases with an increased tumor thickness, ulceration, or lymph node metastases.[2,3]

Recently, there has been a substantial increase in understanding the biology of malignant melanoma. It has become clear that ultraviolet irradiation-induced melanoma differs in clinical presentation, location, and underlying biological alterations from non-sun-induced tumors. Furthermore, melanomas arising in different mucosal sites have been shown to differ not only from cutaneous tumors but also from site to site with a substantial heterogeneity of alterations in a number of genes, some of which such as *BRAF* or *KIT* may be targeted by specific pharmacological inhibitors.

In the present study, we evaluated a large series of melanomas arising in the female genital tract and assessed mutations of the *BRAF*, *NRAS*, *KIT*, and *EGFR* genes as well as *KIT* amplifications.

Materials and Methods

A total of 65 primary malignant melanomas of the vulva or vagina were collected from the archives of the Pathology Department at Vancouver General

Correspondence: Dr S Aulmann, PD, Gemeinschaftspraxis für Pathologie, Ginnheimer Landstraße 86, 60487 Frankfurt, Germany. E-mail: s.aulmann@pathologie-frankfurt.de
[7]These authors contributed equally to this work.
Received 24 June 2013; revised 6 October 2013; accepted 6 October 2013; published online 7 March 2014

Table 1 Clinical, pathological and molecular features of 50 vulvar melanomas

Case no.	*Age*	*Localization*	*Tumor type*[a]	*Ulceration*	*Cellularity*[b]	*Pigmentation*	*Tumor depth*[c]	*Lymph node status*	*Molecular findings*	*KIT IHC*[d]	*Follow-up time*[e]	*Follow-up status*[f]
1	81	Clitoris	MLM	−	E	+	3.8	n.i.		+ + +	n.i.	n.i.
2	73	Clitoris	NM	+	E	+	1.4	n.i.		+ +	n.i.	n.i.
3	76	Clitoris	MLM	+	S	+	1.2	0/22		+ + +	188	A/L
4	68	Clitoris	SSM	−	E	+	1.1	0/1		+ +	3	A/L
5	83	Clitoris	NM	+	E	−	20.5	0/14	NRAS Q61L, Kit amplification	+ +	3	DOD
6	76	Clitoris/paraclitorial	MLM	n.d.	n.d.	+	n.d.	0/1		+ +	n.i	n.i
7	73	Clitoris and bilateral labia	MLM	+	S	−	9.5	0/16		+	23	DOD
8	66	Paraclitorial	SSM	−	E	+	2.1	0/4		+	129	DOD
9	74	Introitus	NM	−	E	−	5	0/19		+	2	A/L
10	73	Introitus	NM	+	E	+	3.4	0/16	KIT V560D	+ + +	13	DOD
11	78	Introitus	NM	+	E	−	12.4	n.i.	KIT amplification	+ + +	40	DOD
12	66	Introitus	NM	+	E	+	12	2/9		+ +	11	DOD
13	84	Introitus, both labiae minorae and majorae	NM	+	E	−	9	n.i.		+	8	DOD
14	87	Left labia minora	NM	+	E	−	4	n.i.		+	1	A/L
15	71	Left labia minora	MLM	+	S	−	13	n.i.	KIT amplification	+ + +	12	A/L
16	77	Right labia minora	SSM	−	E	−	12	n.i.		+ + +	n.i.	n.i.
17	56	Left labia minora	NM	+	E	−	5.5	0/1		+	92	A/L
18	56	Left labia minora	SSM	+	E	−	1.2	0/1	KIT D820V	+ + +	28	DOD
19	49	Left labia majora/ junction labia minora	MLM	+	E	−	2.6	4/14	KIT amplification	+ +	9	DOD
20	88	Right labia minora and majora	NM	+	E	−	10.7	n.i.		+ + +	25	DOD
21	66	Left labia majora/ junction labia minora	MLM	+	E	−	4.8	0/1		−	24	A/L
22	72	Right labia majora	MLM	+	E	+	9	n.i.		+ +	n.i.	n.i.
23	74	Left labia majora	MLM	+	E	+	13.1	5/15		+	3	DOD
24	60	Left labia	SSM	−	E	−	0.9	n.i.		+	n.i.	n.i.
25	82	Right labia	NM	−	E	+	11.5	1/13		−	9	DOD
26	62	Right labia	SSM	+	E	−	3.4	n.i.		+	39	DOD
27	64	Left labia	SSM	+	S	−	4.7	1/1	KIT W557R	+ + +	51	DOD
28	83	Right labia	NM	+	E	−	9.8	0/11	KIT Y578-H580dup	+ + +	84	DOD
29	74	Right labia	MLM	−	E	+	7.4	0/6	NRAS Q61L, KIT P585insREF	+ +	42	DOD
30	77	No information	NM	+	E	−	n.d.	n.i.		+	3	DOD
31	79	No information	NM	+	S	−	0.5	n.i.		−	n.i.	n.i.
32	82	No information	MLM	−	E	+	1	n.i.		+ +	n.i.	n.i.
33	73	No information	NM	+	E	−	10	n.i.	NRAS G12A + KIT R586I	+ + +	n.i.	n.i.
34	61	No information	NM	n.d.	E	+	n.d.	5/23		−	22	DOD
35	72	No information	NM	−	E	+	1.9	n.i.		−	n.i.	n.i.
36	67	No information	SSM	−	E	+	0.1	n.i.		+ +	n.i.	n.i.
37	91	No information	NM	+	E	+	2.6	n.i.		−	n.i.	n.i.
38	92	No information	NM	+	S	+	16.4	n.i.		+ +	n.i.	n.i.
39	86	No information	NM	+	E	−	11.9	n.i.	NRAS G13D	−	4	DOR
40	89	No information	NM	+	E	+	10.9	1/1		+ +	3	DOD
41	82	No information	SSM	+	E	−	4.1	1/23	KIT V559D	+ +	7	DOD
42	78	No information	n.d.	n.d.	E	+	n.d.	n.i.		+	33	DOD
43	40	No information	NM	−	E	+	8.5	0/13	NRAS G12V	−	18	DOD
44	74	No information	NM	−	E	+	13	n.i.		+ +	10	DOD
45	74	No information	NM	+	E	+	7.2	0/14		+	11	DOD
46	68	No information	NM	+	E	−	5.2	0/1	KIT amplification	+ + +	21	DOD
47	85	No information	n.d.	n.d.	E	+	n.d.	1/1		+	8	DOR
48	80	No information	NM	+	E	−	14.6	n.i.		−	71	DOD
49	76	No information	NM	+	E	−	6.6	n.i.		+ +	68	A/L
50	46	No information	MLM	−	E	+	1.5	0/13		−	9	A/L

n.d., not determined; n.i., no information.
[a]MLM, mucosal lentiginous melanoma; NM, nodular melanoma; SSM, superficial spreading melanoma.
[b]E, epithelioid; S, spindle cell morphology.
[c]Tumor depth (Breslow) in millimeters.
[d]KIT immunohistochemistry (semiquantitative).
[e]Follow-up time in months.
[f]DOD, died of disease; DOR, died for other reasons; A/L alive or lost to follow-up.

Table 2 Clinical, pathological, and molecular features of 15 vaginal melanomas

Case no.	*Age*	*Tumor type*[a]	*Ulceration*	*Cellularity*[b]	*Pigmentation*	*Tumor depth*[c]	*Lymph node status*	*Molecular findings*	*KIT IHC*[d]	*Follow-up time*[e]	*Follow-up status*[f]
1	75	MLM	+	E	−	2	n.i.		−	28	DOD
2	69	NM	+	E	−	10	n.i.		+	13	DOD
3	79	NM	+	S	+	35	n.i.		+ +	12	DOD
4	51	NM	+	E	+	6.8	n.i.	NRAS G12V, KIT amplification	−	n.i.	n.i.
5	75	NM	+	E	−	9.2	n.i.		−	n.i.	n.i.
6	65	NM	+	E	−	3.6	n.i.		+	n.i.	n.i.
7	83	NM	−	S	−	9.8	n.i.		−	n.i.	n.i.
8	59	NM	+	E	−	3.8	0/5		−	117	A/L
9	74	SSM	−	E	+	11.3	n.i.	Heterogeneous KIT amplification (sub-clone)	− / + + + (sub-clone)	23	DOD
10	76	NM	+	E	−	4.5	n.i.		+	14	DOD
11	78	NM	+	E	−	6.1	n.i.	NRAS Q61H	−	6	DOD
12	73	NM	−	E	−	5.6	n.i.		+	16	DOD
13	50	NM	+	E	−	11	0/10		−	8	DOD
14	64	NM	+	E	−	26	0/3		−	19	DOD
15	76	NM	+	E	+	14.8	n.i.		−	28	DOD

n.d., not determined; n.i., no information.
[a]MLM, mucosal lentiginous melanoma; NM, nodular melanoma; SSM, superficial spreading melanoma.
[b]E, epithelioid; S, spindle cell morphology.
[c]Tumor depth (Breslow) in millimeters.
[d]KIT immunohistochemistry (semiquantitative).
[e]Follow-up time in months.
[f]DOD, died of disease; DOR, died for other reasons; A/L alive or lost to follow-up.

Hospital, Vancouver, British Columbia, Canada (39 cases diagnosed between 1985 and 2010), the Institute of Pathology, A2,2, Mannheim, Germany (16 cases diagnosed between 2000 and 2010) and the Institute of Pathology of the University Hospital, Heidelberg Germany (10 cases diagnosed between 1998 and 2012). Patients with a history of extragenital melanoma or with synchronous extragenital melanomas detected on clinical examination were excluded. Of the 65 tumors, 50 were located on the vulva and 15 originated in the vagina. The slides were reviewed for tumor depth according to Breslow, tumor type (superficial spreading, mucosal lentiginous or nodular), the presence of ulceration or pigmentation and the predominant cell type (epitheloid or spindle cell). Follow-up information was available in 48 cases (median follow-up 15 months, range 1–188 months), within this time, 35 patients had died of disease, 11 were alive, and 2 had died of unrelated causes.

KIT immunostains were performed according to standard procedures. In brief, deparaffinized slides were subjected to heat-induced epitope retrieval (citrate buffer, pH 6.0, Dako, Hamburg, Germany) followed by incubation with a polyclonal KIT antiserum (Dako) at a dilution of 1:50. For visualization, a modified avidin-biotin-complex method was employed using the LSAB + Kit (Dako) according to the manufacturer's instructions.

For PCR analysis, tumor tissue was microdissected using glass capillaries and digested as described previously.[4] After heat inactivation of the enzyme, the lysate was directly used for PCR under standard conditions using previously published primer combinations for *NRAS* (exons 2 and 3,[5]), *BRAF* (exon 15,[5]), *KIT* (exons 11, 13, 17, and 18,[6]) and *EGFR* (exons 18, 19, 20, and 21,[4]). PCR products were directly sequenced on an ABI Prism 377 sequencer (Applied Biosystems, Darmstadt, Germany).

To assess copy number alterations of the *KIT* gene, a fluorescence *in situ* hybridization (FISH) probe was generated from BAC clones RP11-586A2 and RP11-273B19 (obtained from Imagenes, Berlin, Germany). In brief, BAC-DNA was isolated (Maxi Prep Kit, Quiagen, Hilden, Germany), fragmented using sonification and fluorescent-labeled using the Platinum Bright 547 nucleic acid labeling kit (Kreatech, Amsterdam, Netherlands). Following co-precipitation of the probe with COT1-DNA (Roche, Mannheim, Germany), the DNA mixture was hybridized onto pre-treated paraffin sections of the tumors as described previously.[7]

Results

Patient and tumor characteristics are summarized in Tables 1–3. The average patient age at the time of diagnosis was 72 years (range, 40–89 years). The predominant growth pattern was nodular (63%) followed by mucosal lentiginous (21%), and superficial spreading (16%). Ulceration was present in 72% of cases. In all, 59 of 65 cases (91%) showed an

Table 3 Comparison of clinical and pathological features between vulvar and vaginal melanomas

n	*Total* 65	*Vulvar melanomas* 50	*Vaginal melanomas* 15	P
Average patient age	72.5	73.3	69.8	0.296
Tumor type				
Superficial spreading	10 (16%)	9 (19%)	1 (7%)	
Mucosal lentiginous	13 (21%)	12 (25%)	1 (7%)	
Nodular	40 (63%)	27 (56%)	13 (87%)	
Not determined	2	2	0	0.016
Ulceration				
Absent	17 (28%)	14 (30%)	3 (20%)	
Present	44 (72%)	32 (70%)	12 (80%)	0.524
Not determined	4	4	0	
Growth pattern				
Polypoid/exophytic	42 (69%)	32 (70%)	10 (67%)	
Flat	19 (31%)	14 (30%)	5 (33%)	0.745
Not determined	4	4	0	
Cellularity				
Epitheloid	59 (91%)	44 (88%)	15 (100%)	0.480
Spindle-cell	6 (9%)	6 (12%)	0	
Pigment production				
Absent	35 (54%)	24 (48%)	11 (73%)	
Present	30 (46%)	26 (52%)	4 (27%)	0.150
Tumor depth				
<0.75 mm	2	2	0	
0.75–1.49 mm	6	6	0	
1.50–2.49 mm	4	3	1	
2.50–3.49 mm	4	4	0	
3.50–4.99 mm	8	5	3	
5.00–9.99 mm	18	11	5	
> =10 mm	18	14	6	0.613
Not determined	5	5	0	
Lymph node status				
Negative	20	17	3	
Positive	8	9	0	0.532
No information	37	24	12	

epithelioid morphology, spindle cell differentiation was seen in 6 tumors. Production of melanin was observed in 30 tumors (46%), the majority of cases were deeply infiltrative (36 of 60 informative cases, 60%), a tumor depth of >10 mm was seen in 18 cases (30%). Tumor depth and the presence of lymph node metastases were significantly associated with poorer patient outcome (overall survival) in univariate analysis (Figure 1); multivariate analysis was not performed owing to the low numbers of patients. Vulvar melanomas differed from tumors originating within the vagina with respect to the growth pattern. The superficial spreading and mucosal lentiginous types were significantly associated with vulvar location while most vaginal tumors were nodular melanomas ($P=0.016$). In addition, spindle cell morphology was only seen in six tumors of the vulva. Vaginal tumors showed a tendency toward greater tumor depth, but these differences failed to reach significance (Table 3). Typical histological features, exemplary immunostains and FISH results are shown in Figure 2.

The immunohistochemical and molecular findings are summarized in Table 4. Using immunohistochemistry, moderate or strong cytoplasmic KIT expression was detected in 30 of the 65 cases (46%). In 54 cases, *KIT* sequence analysis was successfully performed revealing four exon 11 point mutations (W557R, V559D, V560D, and R586I), two exon 11 insertions (Y578-H580dup and P585 ins REF), and one exon 17 point mutation (D820V). All of these seven tumors showed strong KIT immunostaining ($P=0.0014$). Increased *KIT* gene copy numbers defined as more than four FISH signals per nucleus on average were seen in 7 of 57 successfully hybridized tumors (12%), in 4 of the 7 cases more than 10 signals arranged in clusters were observed, whereas in the remaining 3 tumors an average of between 4 and 8 signals was seen. In one of these cases (a deeply infiltrating vaginal melanoma), a high-level *KIT* amplification resulting in KIT overexpression was observed in approximately half of the tumor cells showing a sharp demarcation from the (superficial) rest of the tumor (Figure 2). No intratumoral heterogeneity was observed in any of the other amplified cases. Six of the seven tumors with increased *KIT* copy numbers showed moderate or strong KIT staining ($P=0.045$), whereas one case with an average of 5.5 signals per nucleus was only weakly positive. Seven melanomas harbored *NRAS* mutations affecting codons 12, 13, or 61 (G12A, 2 × G12V, G13D, 2 × Q61L, and Q61H), no mutations in the sequenced *BRAF* or *EGFR* exons were detected. None of the molecular features was associated with patient survival (Figure 3). Although *KIT* mutations were exclusively observed in vulvar melanomas ($P=0.171$), *KIT* amplifications and increased KIT protein levels were seen in both locations. No difference was observed between vulvar and vaginal tumors regarding *NRAS* mutations.

Discussion

Over the past years, a surprising molecular heterogeneity of malignant melanoma has emerged. Activating V600E or V600K mutations in the *BRAF* kinase have been observed in up to 62% of melanomas arising in sun-exposed skin.[8] Targeting BRAF using specific inhibitors such as dabrafenib or vemurafenib has led to substantially increased survival rates in *BRAF* mutated, but not in *BRAF* wild-type melanoma.[9,10] However, in melanomas arising on mucosal surfaces or non-sun-exposed skin, *BRAF* mutations have only infrequently been reported.[8] Accordingly, none of the gynecological melanomas in our series harbored a *BRAF* mutation.

As somatic *BRAF* and *NRAS* mutations are mutually exclusive,[11] we next screened our series

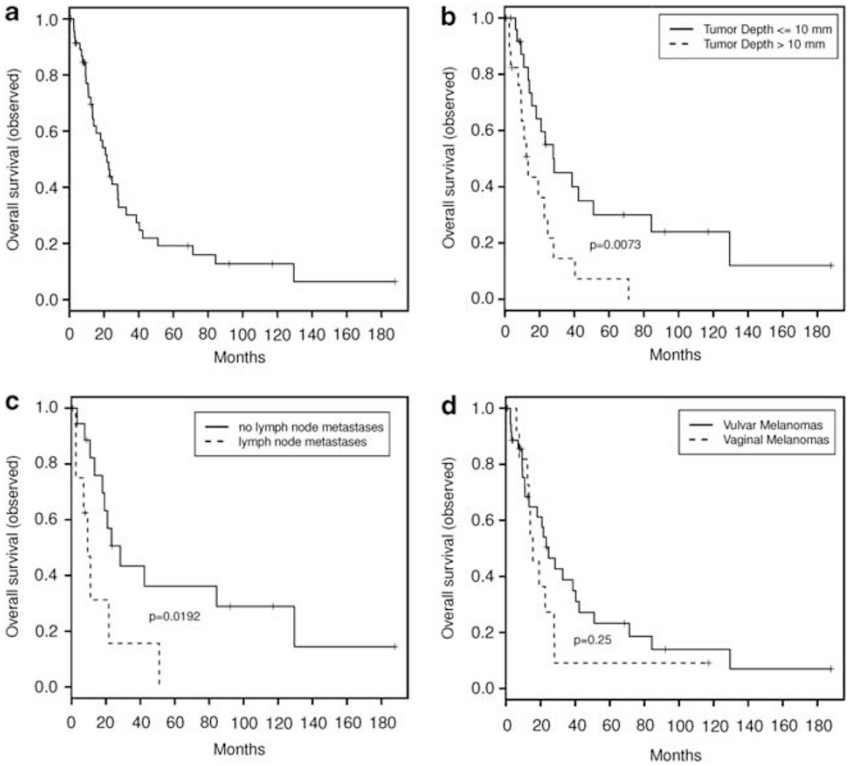

Figure 1 (**a**) Overall survival for all patients with vulvar or vaginal melanomas. Greater tumor depth (**b**) and the presence of lymph node metastases (**c**) were significantly associated with poorer patient outcome (univariate analysis, log rank test), whereas location (vulva *vs* vagina) was not (**d**).

for mutations in exons 2 and 3 (including codons 12, 13, and 61) of *NRAS*. *NRAS* mutations were present in four (three vulvar and one vaginal) tumors indicating a mutation frequency of ~12% in gynecological melanomas which is notably lower than in melanomas arising in chronic sun-damaged skin where mutation rates of up to 24% have been reported.[12] Interestingly, in contrast to some *TP53*, *CCKN2A*, or *PTEN* mutations that also may be present in melanomas, *NRAS* alterations typically are not classical ultraviolet irradiation-induced G:C>A:T exchanges or GG:CC>AA:TT exchanges at dipyrimidine sites which points to a more complex mechanism leading to these mutations.[13] In fact, in contrast to melanomas in other mucosal sites, esophageal melanomas were reported to harbor *NRAS* mutations in >30% of cases[14] further underlining the lack of direct association with ultraviolet irradiation. Recently, MEK-inhibition was shown to demonstrate therapeutic activity in *NRAS*-mutated melanoma opening a novel therapeutic option for these tumors.[15]

KIT mutations and amplifications have been observed in varying frequencies in melanomas arising from different primary sites.[16–18] In addition, KIT protein expression or overexpression as detected by immunohistochemistry has been reported to show some correlation with *KIT* mutations or amplifications[16] but has been insufficient to predict response to KIT-targeted therapy with imatinib.[19] In a recent phase II study, response rates for metastatic melanomas treated with imatinib mesylate were 64.7% in patients with *KIT* exon 11 mutations, 40% for exon 17 mutations, and 33% for *KIT* amplifications.[20] The frequency of *KIT* mutations in mucosal melanomas has been reported to be as high as 39%.[16] We observed five *KIT* point mutations (exons 11 and 17) and two in-frame insertions (exon 11) in vulvar melanomas, but none in vaginal tumors indicating an important difference in the underlying biology. Although some authors interpret vulvar tumors as melanomas of the non-sun-exposed skin,[8] vaginal melanomas show molecular and morphological similarities to esophageal primaries[14] that typically lack *KIT* mutations but may harbor *NRAS* alterations.

In conclusion, malignant melanomas of the vulva and vagina typically are aggressive tumors associated with a poor overall survival. Tumors in both locations frequently are deeply infiltrating at the time of diagnosis, highlighting the need for novel adjuvant treatment approaches. As overall survival in patients with gynecological melanomas is very poor, our data provide a rationale for *KIT* mutation testing and targeted treatment approaches in melanomas of the vulva. Targeting of *NRAS*-mutated tumors with MEK inhibitors may be beneficial in melanomas of the vulva and vagina.

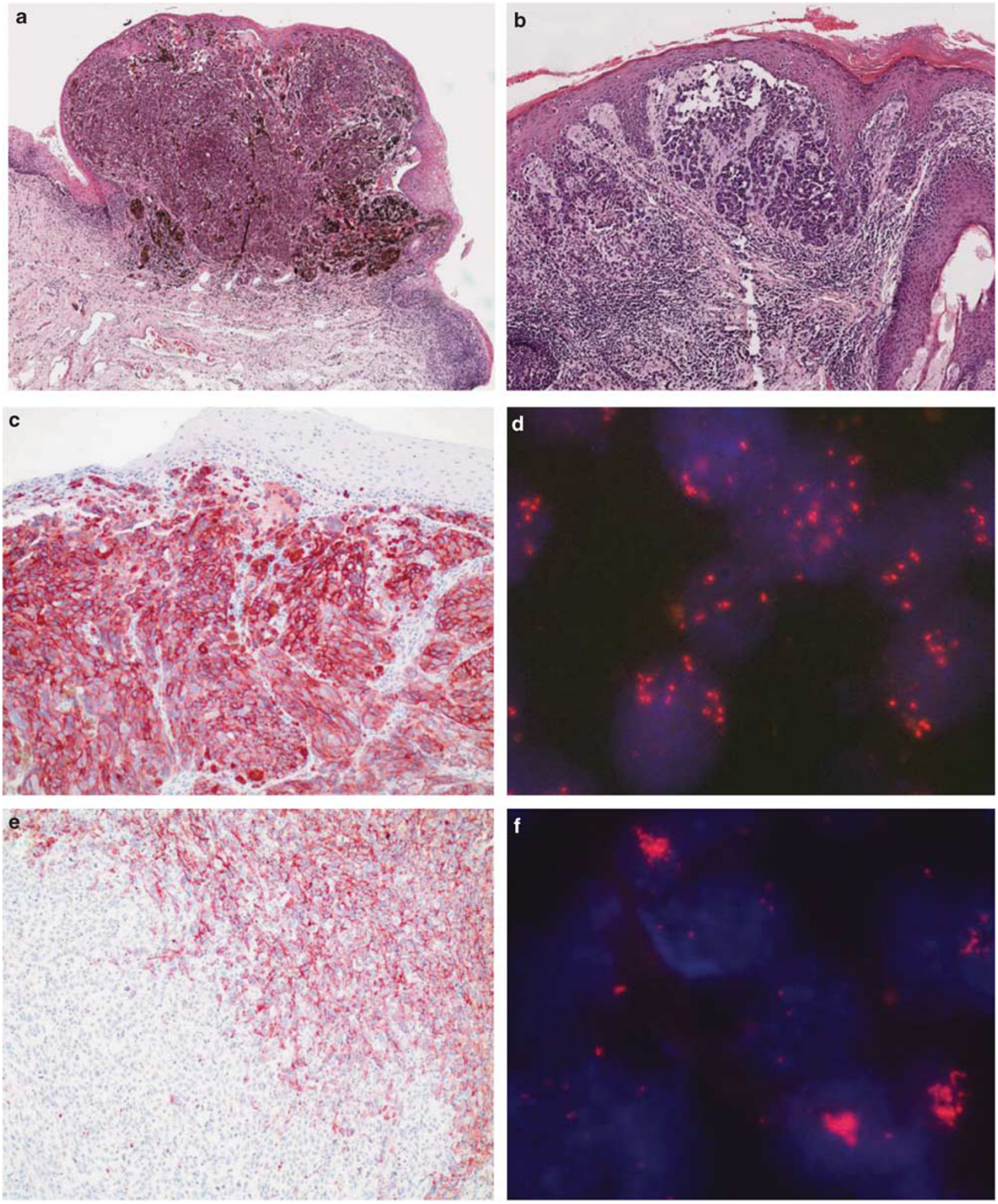

Figure 2 Representative histology of a nodular ((**a**) hematoxylin and eosin, original magnification ×40) and mucosal lentiginous melanoma ((**b**) hematoxylin and eosin, original magnification ×100). (**c**,**d**) KIT overexpression ((**c**) KIT-Immunostain, original magnification ×100) and amplification ((**d**) FISH, original magnification ×1000) in a case of vulvar melanoma (case 28). (**e**,**f**) Heterogeneous KIT overexpression (KIT-IHC, original magnification ×100) and amplification (FISH, original magnification ×1000) in a malignant melanoma of the vagina (case 9).

Table 4 Comparison of immunohistochemical and molecular findings between vulvar and vaginal melanomas

	Total	*Vulvar melanomas*	*Vaginal melanomas*	P
KIT IHC[a]				
Negative/weak	35 (54%)	22 (44%)	13 (87%)	
Positive	30 (46%)	28 (56%)	2 (13%)	0.007
KIT sequencing analysis (exons 11, 13, 15, and 17)				
Wild type	47 (87%)	32 (82%)	15 (100%)	
Mutation	7 (13%)	7 (18%)	0	0.171
Not informative	11	11	0	
KIT FISH[b]				
No amplification	50 (88%)	37 (88%)	13 (87%)	
Amplification	7 (12%)	5 (12%)	2 (13%)	1
Not informative	8	8	0	
NRAS exons 2/3				
Wild type	50 (88%)	37 (88%)	13 (87%)	
Mutation	7 (12%)	5 (12%)	2 (13%)	1
Not informative	8	8	0	
BRAF exon 15				
Wild type	54 (100%)	39 (100%)	15 (100%)	
Mutation	0	0	0	
Not informative	11	11	0	
EGFR exons 18, 19, 20, and 21				
Wild type	45 (100%)	30 (100%)	15 (100%)	
Mutation	0	0	0	
Not informative	20	20	0	

[a]IHC, immunohistochemistry.
[b]FISH, fluorescence *in situ* hybridization.

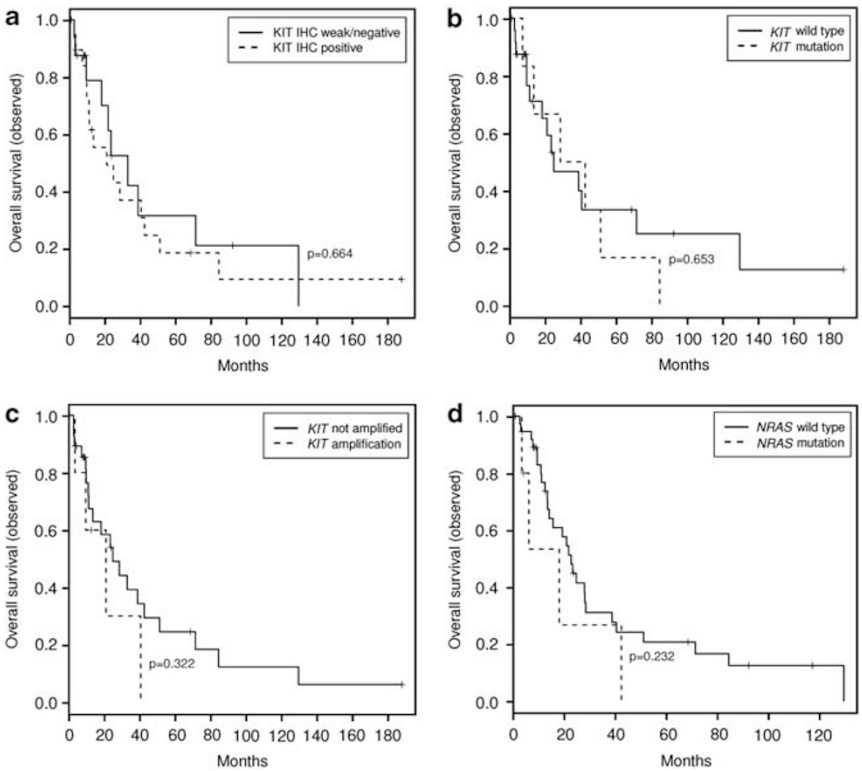

Figure 3 Neither KIT alterations (overexpression (**a**), mutation (**b**), or amplification (**c**)) nor *NRAS* mutations (**d**) are associated with a significantly better or worse overall survival (univariate analysis, log-rank test).

Disclosure/conflict of interest

The authors declare no conflict of interest.

References

1 Stang A, Streller B, Eisinger B, *et al.* Population-based incidence rates of malignant melanoma of the vulva in Germany. Gynecol Oncol 2005;96:216–221.
2 Ragnarsson-Olding BK, Nilsson BR, Kanter-Lewensohn LR, *et al.* Ringborg UK.Malignant melanoma of the vulva in a nationwide, 25-year study of 219 Swedish females: predictors of survival. Cancer 1999;86: 1273–1284.
3 Tcheung WJ, Selim MA, Herndon JE II, *et al.* Clinicopathologic study of 85 cases of melanoma of the female genitalia. J Am Acad Dermatol 2012;76: 598–605.
4 Warth A, Macher-Goeppinger S, Muley T, *et al.* Clonality of multifocal non-small cell lung cancer: implications for staging and therapy. Eur Respir J 2011;39:1437–1442.
5 Davies H, Bignell GR, Cox C, *et al.* Mutations of the BRAF gene in human cancer. Nature 2002;417:949–954.
6 Penzel R, Aulmann S, Moock M, *et al.* The location of KIT and PDGFRA gene mutations in gastrointestinal stromal tumours is site and phenotype associated. J Clin Pathol 2005;58:634–639.
7 Aulmann S, Longerich T, Schirmacher P, *et al.* Detection of the ASPSCR1/TFE3 gene fusion in paraffin embedded alveolar soft part sarcomas. Histopathology 2007;50:881–886.
8 Cohen Y, Rosenbaum E, Begum S, *et al.* Exon 15 BRAF mutations are uncommon in melanomas arising in nonsun-exposed sites. Clin Cancer Res 2004;10: 3444–3447.
9 Falchook GS, Long GV, Kurzrock R, *et al.* Dabrafenib in patients with melanoma, untreated brain metastases, and other solid tumours: a phase 1 dose-escalation trial. Lancet 2012;379:1893–1901.
10 Menzies AM, Haydu LE, Visintin L, *et al.* Distinguishing clinicopathologic features of patients with V600E and V600K BRAF-mutant metastatic melanoma. Clin Cancer Res 2012;18:3242–3249.
11 Palmieri G, Casula M, Sini MC, *et al.* Issues affecting molecular staging in the management of patients with melanoma. J Cell Mol Med 2007;11:1052–1068.
12 Van Elsas A, Zerp SF, van der Flier S, *et al.* Relevance of ultraviolet-induced N-ras oncogene point mutations in development of primary human cutaneous melanoma. Am J Pathol 1996;149:883–893.
13 Hocker T, Taso H. Ultraviolet radiation and melanoma: a systematic review and analysis of reported sequence variants. Hum Mutation 2007;28:578–588.
14 Sekine S, Nakanishi Y, Ogawa R, *et al.* Esophageal melanomas harbor frequent NRAS mutations unlike melanomas of other mucosal sites. Virchows Arch 2009;454:513–517.
15 Ascierto PA, Schadendorf D, Berking C, *et al.* MEK162 for patients with advanced melanoma harbouring NRAS or Val600 BRAF mutations: a non-randomised, open-label phase 2 study. Lancet Oncol 2013;14: 249–256.
16 Curtin JA, Busam K, Pinkel D, *et al.* Somatic activation of KIT in distinct subtypes of melanoma. J Clin Oncol 2006;24:4340–4346.
17 Satzger I, Schaefer T, Kuettler U, *et al.* Analysis of c-KIT expression and KIT gene mutation in human mucosal melanomas. Br J Cancer 2008;99:2065–2069.
18 Omholt K, Grafström E, Kanter-Lewensohn L, *et al.* KIT pathway alterations in mucosal melanomas of the vulva and other sites. Clin Cancer Res 2011;17: 3933–3942.
19 Alexis JB, Martinez AE, Lutzky J. An immunohistochemical evaluation of c-kit (CD-117) expression in malignant melanoma, and resulst of imatinib mesylate (Gleevec) therapy in three patients. Melanoma Res 2005;15:283–285.
20 Guo J, Si L, Kong Y, *et al.* Phase II, open-label, single-arm trial of imatinib mesylate in patients with metastatic melanoma harboring c-Kit mutation or amplification. J Clin Oncol 2011;29:2904–2909.