Modern Pathology (2011) 24, 1368–1379

Molecular markers and clinical behavior of uterine carcinosarcomas: focus on the epithelial tumor component

Renske A de Jong[1], Hans W Nijman[1], Tera F Wijbrandi[1], Anna KL Reyners[2], H Marike Boezen[3] and Harry Hollema[4]

[1]*Department of Gynecologic Oncology, University Medical Center Groningen, University of Groningen, Groningen, The Netherlands;* [2]*Department of Medical Oncology, University Medical Center Groningen, University of Groningen, Groningen, The Netherlands;* [3]*Department of Epidemiology, University Medical Center Groningen, University of Groningen, Groningen, The Netherlands and* [4]*Department of Pathology, University Medical Center Groningen, University of Groningen, Groningen, The Netherlands*

Carcinosarcomas (malignant mixed Müllerian tumors) of the uterus are rare and aggressive malignancies consisting of an epithelial (carcinoma) and a mesenchymal (sarcoma) tumor component and are considered as metaplastic endometrial carcinomas. This study evaluated molecular characteristics and clinical behavior of uterine carcinosarcomas to improve treatment regimens in the future. Immunohistochemical expression of estrogen receptor-α and -β, progesterone receptor-A and -B, MLH1, MSH2, MSH6, PTEN (phosphatase and tensin homolog deleted on chromosome 10), p53, β-catenin and cyclin D1 was determined in 40 uterine carcinosarcomas. Immunostaining was compared between epithelial and mesenchymal tumor components. To determine the prognostic role of the epithelial component, clinicopathological data and survival were compared between patients with endometrioid and non-endometrioid epithelial tumor components. To determine prognosis of carcinosarcomas compared with high-risk endometrial carcinomas, clinicopathological characteristics and survival were compared between these patients. Hormone receptor expression occurred infrequently: estrogen receptor-α (8%) and -β (32%), progesterone receptor-A (0%) and -B (23%), next to β-catenin (4%) and cyclin D1 (7%). PTEN, MLH1, MSH2 and MSH6 mutations occurred in 39%, 33%, 22% and 21%, respectively (based on absent immunostaining). Overexpression of p53 was observed in 38%. Expression patterns of p53, MSH2 and MSH6 corresponded between epithelial and mesenchymal tumor components. In our cohort, the epithelial component caused the majority of metastases (72%) and vascular invasion (70%). Survival tended to be worse for patients with a non-endometrioid epithelial component compared with an endometrioid epithelial component (5-year survival: 26% and 55%, respectively). Survival was worse for patients with uterine carcinosarcomas compared with high-risk endometrial carcinomas (grade 3 endometrioid and non-endometrioid); 5-year survival rates: 42%, 77% and 57%, respectively. Our results support the monoclonal origin of uterine carcinosarcomas. The epithelial component determines prognosis by causing the majority of metastases and vascular invasion. To improve prognosis, treatment should focus on the epithelial tumor component of uterine carcinosarcomas.
Modern Pathology (2011) **24,** 1368–1379; doi:10.1038/modpathol.2011.88; published online 13 May 2011

Keywords: carcinogenesis; clinical behavior; epithelial component; immunohistochemistry; uterine carcinosarcomas

Uterine carcinosarcomas (malignant mixed Müllerian tumors) are rare malignancies of the female genital tract, accounting for 1–5% of uterine malignancies.[1,2] Microscopically, carcinosarcomas consist of two histological malignant components: an epithelial (carcinoma) and a mesenchymal (sarcoma) component. The epithelial component is usually a

Correspondence: RA de Jong, MD, Department of Gynecologic Oncology, University Medical Center Groningen, University of Groningen, PO 30.001, 9700 RB Groningen, The Netherlands.
E-mail: r.a.de.jong@og.umcg.nl
Received 24 December 2010; revised 28 February 2011; accepted 28 February 2011; published online 13 May 2011

high-grade carcinoma such as papillary serous or clear cell.[3] The mesenchymal component may be either homologous or heterologous. The homologous mesenchymal component contains cell types that are normally found in the uterus: stromal sarcoma, fibrosarcoma, undifferentiated sarcoma and leiomyosarcoma. These cell types can either occur as single or mixed tissue type. The heterologous component is composed of other components such as rhabdomyosarcoma, chondrosarcoma, osteosarcoma and liposarcoma.[4,5] The proportion of the epithelial and mesenchymal component can vary between individual cases.

Several theories about the origin of the coexistence of two distinctive malignant components in the same tumor have been proposed during the past decades. The 'collision' theory suggests that the epithelial and mesenchymal component originated separately and finally collided in one 'mixed' tumor. The 'combination' theory comprises the assumption of a common (epithelial) precursor stem cell with bidirectional differentiation. The 'conversion' theory suggests that the epithelial component is 'the driving force': the mesenchymal component is derived from the epithelial component via a metaplastic process.[6,7] Molecular and immunohistochemical studies suggest that most, but not all, carcinosarcomas are monoclonal, supporting the conversion theory.[6,8,9] Therefore, uterine carcinosarcomas are considered as metaplastic endometrial carcinomas. Endometrial carcinomas can be divided into two types based on clinicopathological characteristics: type I consists of endometrioid carcinomas and type II consist of clear-cell and serous papillary carcinomas.[7,10] Type I endometrial carcinomas are associated with mutations of DNA *mismatch repair* (*MMR*) genes, PTEN (phosphatase and tensin homolog deleted on chromosome 10) mutations, estrogen receptor expression, progesterone receptor (PR) expression and aberrant Wnt/β-catenin signaling pathway. Type II endometrial carcinomas are characterized by p53 mutations and have a worse prognosis compared with type I endometrial carcinomas. High-risk subtypes of endometrial carcinomas (grade 3 endometrioid and non-endometrioid) show resemblance to the aggressive biological behavior of uterine carcinosarcomas, although prognosis of uterine carcinosarcomas is worse.[11,12]

Uterine carcinosarcomas predominantly occur in postmenopausal women and a higher incidence is found among black women compared with white women.[1] Risk factors are similar to endometrial carcinomas: advanced age, obesity, nulliparity and exposure to exogenous estrogen. Furthermore, long-term use of tamoxifen after breast cancer has been associated with the development of a uterine carcinosarcoma.[4] Stage of disease, myometrial invasion and vascular invasion are important prognostic factors. Owing to a high tendency to early extra-uterine spread, advanced disease is usually present at the time of diagnosis.[4,13] Prognosis is poor: 5-year survival rates have been reported between 30% and 45.8% in early-stage carcinosarcoma (FIGO stage I/II) and between 0% and 10% in advanced stage carcinosarcoma (FIGO stage III/IV).[11,12]

Until recently, uterine carcinosarcomas were considered as a subtype of uterine sarcomas and were treated correspondingly. However, hardly any improvement of prognosis was observed. Based on the fact that uterine carcinosarcomas are currently considered as metaplastic endometrial carcinomas, uterine carcinosarcomas are treated as high-risk endometrial carcinomas. Surgical treatment consists of a total abdominal hysterectomy, bilateral salpingo-oopherectomy, dissection of pelvic and para-aortic lymph nodes and collection of peritoneal cytology. However, responses to present-day adjuvant radiotherapy and chemotherapy are poor and clinical trials are conducted to improve prognosis by new treatment strategies. Treatment with adjuvant combined chemotherapy seems the most promising compared with single-agent chemotherapy[14,15] or radiotherapy.[16] However, more research is needed to develop the most effective treatment for patients with uterine carcinosarcomas.

This study aimed to gain more insight into the molecular characteristics and clinical behavior of carcinosarcomas to improve treatment regimens in the future. Therefore, immunohistochemical expression of hormone receptors (estrogen receptor-alpha (ER-α), estrogen receptor-beta (ER-β), progesterone receptor-alpha (PR-A), progesterone receptor-beta (PR-B), MMR proteins (MLH1, MSH2 and MSH6), PTEN, p53, β-catenin and cyclin D1 was determined in a well-defined cohort of uterine carcinosarcomas. Expression levels were compared between epithelial and mesenchymal tumor components and between primary and metastatic tumor tissue. To determine whether treatment modalities should focus on characteristics of the epithelial tumor component, the prognostic role of the epithelial component was determined. Therefore, clinicopathological data and survival were compared between patients with endometrioid and non-endometrioid epithelial tumor components of uterine carcinosarcomas. Next, clinicopathological characteristics and survival were compared between patients with high-risk endometrial carcinomas and carcinosarcomas to determine if carcinosarcomas have a worse prognosis compared with high-risk endometrial carcinomas.

Materials and methods

Patients and Treatment

Since 1980, tissue samples of patients with gynecological malignancies treated at the Department of Gynecologic Oncology of the University Medical Center Groningen are collected and stored in the tissue storage system of the Pathology Department of the University Medical Center Groningen.

Clinicopathological characteristics and follow-up data of these patients were prospectively collected during standard treatment and were stored in a computerized registration database. For this study, patients with grade 3, non-endometrioid endometrial carcinoma and carcinosarcomas were selected if diagnosed and treated by a gynecological oncologist in the University Medical Center Groningen between 1980 and 2006. Of these patients, clinicopathological data were retrieved from hospital and pathology records and compared. For carcinosarcoma patients, it was assessed whether sufficient tissue material was available from the primary tumor location and metastatic lesions. Staging occurred after surgical treatment according to the FIGO guidelines.[17] Tumors were classified and graded by pathologists according to the World Health Organization (WHO) criteria.[18] Follow-up data were completed until February 2010.

Institutional Review Board Approval

For this study, all relevant data were retrieved from our computerized database and transferred into a separate, anonymous, password-protected database. Patient identity was protected by study-specific, unique patient codes, which were only known to two dedicated data managers, who also have daily responsibility for the larger database. In case of uncertainties with respect to clinicopathological and follow-up data, the larger databases could only be checked through the data managers, thereby ascertaining the protection of patients' identity. Using the registration database, all tissue specimens were identified by unique patient numbers and retrieved from the archives of the Department of Pathology. Therefore, according to Dutch law no further Institutional Review Board approval was needed for this study (http://www.federa.org/).

Tissue Microarray Construction

The tissue microarray method allows simultaneous evaluation of several markers on paraffin-embedded tissues from hundreds of tumors.[19] For this study, archival slides of all cases were reviewed and the histopathological classifications of the carcinosarcomas were confirmed by an experienced gynecological pathologist (HH). Morphologically representative areas of the epithelial and mesenchymal tumor component were marked on hematoxylin- and eosin-stained slides of the paraffin-embedded tissue. Areas of necrosis and areas with severe leukocyte infiltration were avoided. Three core biopsies of 0.6 mm were taken from each tumor component and arrayed on a recipient paraffin block using a tissue microarrayer (Beecher instruments, Silver Spring, MD, USA). Adhesion of cores to the recipient block was accomplished by placing the blocks in a 37°C oven for 15 min.

Immunohistochemistry

For immunohistochemistry, 4 μm sections were cut from the tissue microarrays and mounted on aminopropyl-ethoxy-silan-coated glass slides (Sigma-Aldrich, Diessenhofen, Germany). In total, 11 primary antibodies were used for immunohistochemical assessment. Antibodies, antigen retrieval methods and detection techniques are summarized in Table 1.

Table 1 Antibodies used for immunohistochemical staining

Antigen	*Antigen retrieval*	*Primary antibody*	*Company*	*Dilution*	*Detection method*
PTEN	Citrate (pH 6)[a]	28H6	Neomarkers[b]	1:50	Envision
P53	Tris/EDTA (pH 9)[a]	DO-7	DAKO[c]	1:1000	Dako EnVision+
β-Catenin	Citrate (pH 6)[a]	Clone 14	BD Transduction Laboratories[d]	1:1000	RAM^{hrp} 1:100, GAR^{hrp} 1:100
ER-α	Citrate (pH 6)[e]	6F11	Serotec[f]	1:20	Goat anti-mouse IgG1/HRP 1:40
ER-β	Citrate (pH 6)[e]	ppg5/10	Serotec[f]	1:20	RAM^{bio} 1:300, streptavidin/HRP 1:100
PR-A	EDTA (pH 8)[a]	hPRa7	Neomarkers[b]	1:50	RAM^{po} 1:100, GAR^{po} 1:100
PR-B	Autoclave[e]	hPRa2	Neomarkers[b]	1:50	RAM^{po} 1:100, GAR^{po} 1:100
Cyclin D1	Tris-HCl[a]	AM29	Zymed Laboratories[g]	1:500	RAM^{po} 1:100, GAR^{po} 1:100
MSH2		G219-1129	Ventana[h]	[i]	
MSH6		G70220	BD Transduction Laboratories[d]	1:400	
MLH1		G168-728	Ventana[h]	[i]	

[a]Sections were boiled in a microwave for 15 min.
[b]Neomarkers, Lab Vision Corporation, Fremont, CA, USA.
[c]DAKO, Netherlands BV, Heverlee, Belgium.
[d]BD Biosciences, Lexington, KY, USA.
[e]Sections were treated in an autoclave three times for 5 min at 115°C in blocking reagent (2% block+0.2% SDS in maleic acid, pH 6.0; Boehringer Mannheim, Mannheim, Germany).
[f]Serotec, AbD Serotec, Dusseldorf, Germany.
[g]Zymed, San Fransisco, CA, USA.
[h]Ventana, Tucson, AZ, USA.
[i]The antibody was ready to use.

Sections were deparaffinized in xylene and rehydrated in ethanol. Endogenous peroxidase was blocked by incubation in a 0.3% H_2O_2 solution for 30 min. Staining was visualized with 3,3′-diaminobenzidine (Vector Laboratories, Burlingame, CA, USA) and slides were counterstained with hematoxylin.

Evaluation of Staining

Immunohistochemical expression was determined based on intensity and extent of the staining. Intensity was scored as negative (0), weak (1+), positive (2+) or strong positive (3+). Immunostaining for p53 was scored as follows: tumors showing at least 50% positive nuclear expressions were considered as having aberrant p53 expression. Positive staining of PTEN was defined as the presence of >10% cytoplasmic immunostaining.[20] Cyclin D1 and hormone receptor expression was considered positive when >10% tumor cells had moderate to strong nuclear expression. MSH2, MSH6 and MLH1 expression was scored as either negative (ie, total absence of detectable nuclear staining of tumor cells) or positive. β-Catenin was considered positive when at least 10% tumor cells showed nuclear immunohistochemical expression. Two independent researchers (TW and HH) scored all immunohistochemical stained slides without previous knowledge of clinicopathological data. Discordant cases were reviewed and scores were reassigned on consensus of opinion. Staining was only analyzed when two or more cores were available, each containing more than 20% tumor tissue. In this way, resemblance to whole tissue slides was warranted.

Statistics

All continuous variables were checked for normality of the distribution using P–P plots. In case of skewed distributions, the median and interquartile ranges (IQR, 25th–75th percentile) were presented. To establish whether clinicopathological characteristics were associated with the expression of MLH1, MSH2, MSH6, PTEN, p53, hormone receptors, β-catenin and cyclin D1, univariate logistic regression analyses were performed. Expression of the markers was dichotomized according to negative and positive immunostaining and analyzed as dependent variables and clinicopathological characteristics (Table 2) were used as independent variables; odds ratios (ORs) and 95% confidence intervals (95% CI) were calculated. Associations of immunohistochemical expression (Table 3) between epithelial and mesenchymal tumor component and between primary and metastatic tumor tissue were tested using χ^2 tests (or Fisher's exact tests, if appropriate). Spearman's rank correlation analyses were used to determine correlations between the expression of

Table 2 Clinicopathological characteristics of 40 patients with uterine carcinosarcoma

Characteristics	*Patient no. (n = 40) (%)*[a]
Stage	
I	17 (42%)
II	3 (8%)
III	13 (33%)
IV	7 (17%)
Tumor type (epithelial)	
Endometrioid	25 (68%)
Serous papillary	7 (19%)
Clear cell	2 (5%)
Undifferentiated	3 (8%)
Missing[b]	3
Tumor grade (epithelial)	
Grade 1	1 (3%)
Grade 2	8 (23%)
Grade 3	23 (66%)
Undifferentiated	3 (8%)
Missing[b]	5
Tumor type (mesenchymal)	
Homologous	27 (75%)
Leiomyosarcoma	3 (11%)
Stromal sarcoma	6 (22%)
Not otherwise specified (NOS)	18 (67%)
Heterologous	9 (25%)
Rhabdomyosarcoma	4 (45%)
Chondrosarcoma	1 (11%)
Osteosarcoma	3 (33%)
Stromal sarcoma+chondrosarcoma	1 (11%)
Missing[b]	4
Tumor grade (mesenchymal)	
Low	3 (8%)
High	34 (92%)
Missing[b]	3
Myometrial invasion	
<50%	21 (60%)
>50%	14 (40%)
Missing[c]	5
Vascular invasion	
Negative	12 (34%)
Positive	23 (66%)
By carcinoma	16 (70%)
By sarcoma	6 (26%)
By carcinoma and sarcoma	1 (4%)
Missing[c]	5
Recurrent disease	
No[d]	25 (62%)
Yes	15 (38%)
Local	2 (13%)
Pelvic region	3 (20%)
Distant	10 (67%)

[a]Percentages exclude missing cases.
[b]Missing cases include cases of which no primary tumor tissue was available for analysis (only metastatic tumor tissue present on tissue microarray). When one component accounted for <5% of the entire tumor, exact tumor type or grade could not be determined.
[c]Missing cases represent patients not treated with primary surgery.
[d]Include patients with residual disease after primary treatment.

Table 3 Summary of immunohistochemistry expression in primary and metastatic tumor tissue of uterine carcinosarcomas

Marker	*Primary tumor tissue*				*Metastatic tumor tissue*		
	Entire tumor (n = 31) (%)[a]	*Epithelial component (n = 37) (%)*[a]	*Mesenchymal component (n = 33) (%)*[a]	P-*value*[b]	*Epithelial component (n = 17) (%)*[a]	*Mesenchymal component (n = 5) (%)*[a]	P-*value*[c]
ER-α							
No expression	23 (92%)	22 (67%)	25 (83%)	0.656	10 (71%)	5 (100%)	0.631
Expression[d]	2 (8%)	11 (33%)	5 (17%)		4 (23%)	0 (0%)	
Missing	6	4	3		3	0	
ER-β							
No expression	17 (68%)	20 (63%)	12 (44%)	**0.041**	4 (33%)	2 (40%)	0.571
Expression[d]	8 (32%)	12 (37%)	15 (56%)		8 (67%)	3 (60%)	
Missing	6	5	6		5	0	
PR-A							
No expression	30 (100%)	35 (95%)	27 (90%)	0.735	14 (93%)	5 (100%)	NA
Expression[d]	0 (0%)	2 (5%)	3 (10%)		1 (7%)	0 (0%)	
Missing	1	0	3		2	0	
PR-B							
No expression	23 (77%)	22 (59%)	20 (65%)	0.132	8 (53%)	1 (20%)	0.293
Expression[d]	7 (23%)	15 (41%)	11 (35%)		7 (47%)	4 (80%)	
Missing	1	0	2		2	0	
MLH1							
No expression[e]	8 (33%)	19 (61%)	11 (40%)	0.134	1 (8%)	1 (25%)	0.377
Expression	16 (67%)	12 (39%)	16 (59%)		12 (92%)	3 (75%)	
Missing	7	6	6		4	1	
MSH2							
No expression[e]	6 (22%)	12 (35%)	9 (29%)	**0.033**	3 (21%)	1 (20%)	0.522
Expression	21 (78%)	22 (65%)	22 (71%)		11 (79%)	4 (80%)	
Missing	4	3	2		3	0	
MSH6							
No expression[e]	6 (21%)	13 (36%)	8 (27%)	**0.050**	4 (31%)	0 (0%)	0.317
Expression	22 (79%)	23 (64%)	22 (73%)		9 (69%)	5 (100%)	
Missing	3	1	4		4	0	
PTEN							
No expression[e]	12 (39%)	23 (64%)	16 (52%)	0.100	8 (53%)	4 (100%)	0.835
Expression	19 (61%)	13 (36%)	15 (48%)		7 (47%)	0 (0%)	
Missing	0	1	2		2	1	
P53							
No expression	18 (62%)	20 (54%)	14 (47%)	**<0.001**	6 (46%)	1 (25%)	**0.002**
Expression[d]	11 (38%)	17 (46%)	16 (53%)		7 (54%)	3 (75%)	
Missing	2	0	3		4	1	
β-*Catenin*							
No expression	27 (96%)	31 (89%)	26 (87%)	0.270	10 (77%)	4 (100%)	**0.038**
Expression[d]	1 (4%)	4 (11%)	4 (13%)		3 (23%)	0 (0%)	
Missing	3	2	3		4	1	
Cyclin D1							
No expression	28 (93%)	28 (76%)	24 (77%)	0.565	8 (62%)	4 (80%)	**0.035**
Expression[d]	2 (7%)	9 (24%)	7 (23 %)		5 (38%)	1 (20%)	
Missing	1	0	2		4	0	

Abbreviation: NA, not applicable.
[a]Percentages exclude missing cases.
[b]χ^2 test comparing expression between epithelial and mesenchymal component in primary tumor tissue (metastatic was not compared owing to small sample size).
[c]χ^2 test comparing expression between primary and metastatic tumor tissue.
[d]Expression was considered positive when both components showed positive immunostaining.
[e]Expression was considered negative when both components showed absent immunostaining.
Bold values indicate $P<0.005$.

PTEN and MLH1, MSH2 and MSH6. χ^2 tests (or Fisher's exact tests, if appropriate) or Mann–Whitney *U*-tests were used to assess differences in clinicopathological characteristics (Tables 4 and 5) between tumor types. Differences in disease-specific survival based on immunohistochemical expression

Table 4 Characteristics according to histological subtype of the epithelial tumor component of uterine carcinosarcomas

Characteristics	*All cases* (n = *40*)[a] *(%)*[b]	*Endometrioid* (n = *25*) *(%)*[b]	*Non-endometrioid* (n = *9*) *(%)*[b]	P-*value*[c]
Age				0.183[d]
Median (IQR)	66 (59–76)	66 (59–75)	67 (63–84)	
Peritoneal washing				0.518
Negative	15 (71%)	9 (75%)	4 (45%)	
Positive	4 (19%)	1 (8%)	2 (22%)	
Suspect	2 (10%)	2 (17%)	3 (33%)	
Missing[e]	19	13	0	
Omental metastases				0.156
No	25 (81%)	19 (95%)	5 (71%)	
Yes	6 (19%)	1 (5%)	2 (29%)	
Missing	9	5	2	
Peritoneal metastases				0.063
No	30 (83%)	21 (95%)	6 (67%)	
Yes	6 (17%)	1 (5%)	3 (33%)	
Missing	4	3	0	
Recurrent disease				0.224
No	25 (63%)	18 (72%)	4 (44%)	
Yes	15 (38%)	7 (18%)	5 (56%)	
Local	2 (13%)	1 (14%)	1 (20%)	
Pelvic region	3 (20%)	2 (29%)	1 (20%)	
Distant	10 (67%)	4 (57%)	3 (60%)	
Follow-up				0.083
Alive	9 (22%)	9 (36%)	0 (0%)	
Death due to disease	23 (58%)	11 (44%)	6 (67%)	
Death due to other disease	8 (20%)	5 (20%)	3 (33%)	
Missing	0	0	0	

[a]An epithelial component consisting of undifferentiated tumor type ($n = 3$) or unknown tumor type ($n = 3$) were excluded for further analysis.
[b]Percentages exclude missing cases.
[c]χ^2 test used, characteristics divided into two categories.
[d]Mann–Whitney *U*-test used.
[e]Missing cases: patients without primary surgery ($n = 5$) or material not enough for definitive conclusion.

or tumor types were plotted using Kaplan–Meier survival curves and evaluated by log-rank tests. Disease-specific survival was defined as the time from diagnosis until death owing to disease (endometrial carcinoma or uterine carcinosarcoma) or date of last follow-up. All tests were performed two-sided and *P*-values of <0.05 were considered statistically significant. Analyses were performed using the software package SPSS, version 16.0 for Windows (SPSS Inc., Chicago, IL, USA).

Results

Patients

Between 1980 and 2006, 725 patients were diagnosed and treated for endometrial cancer in the University Medical Center Groningen. A total of 99 patients (14%) were diagnosed with high-risk endometrial carcinoma: grade 3 endometrioid carcinoma ($n = 56$, 8%), serous papillary carcinoma ($n = 17$, 2%) and clear-cell carcinoma ($n = 26$, 4%). In all, 43 patients (6%) were diagnosed with carcinosarcoma of the uterus. From a total of 40 carcinosarcoma patients, sufficient paraffin-embedded tumor tissue was available for construction of a tissue microarray. Tumor tissue from the primary tumor location was available of 38 patients and in 32 cases both the epithelial and mesenchymal component could be incorporated on the tissue microarray. Metastatic tumor tissue was available of 18 patients.

Patient Characteristics of Carcinosarcoma Patients

Clinicopathological characteristics of carcinosarcoma patients are summarized in Table 2. Median age at the time of diagnosis was 66 years (IQR: 59–76). Median time of follow-up was 1.5 years (IQR: 0.8–6.1). Patients were diagnosed with advanced stage of disease (FIGO stage III/IV) in 50% of the cases. In the majority of cases, both tumor components were poorly differentiated (epithelial: 74%; mesenchymal: 92%). Vascular invasion was present in 23 cases (66%). In 13 out of 18 cases (72%), metastases

Table 5 Comparison of characteristics between high-risk endometrial carcinomas and uterine carcinosarcomas

Characteristics	*Grade 3 endometrioid (n = 56) (%)*[a]	*Non-endometrioid (n = 43) (%)*[a]	*Carcinosarcoma (n = 40) (%)*[a]	P-*value*
Age				NS[b,c]
Median (IQR)	61 (55–72)	67 (59–74)	66 (59–76)	
Stage				NS[c,d]
I	18 (32%)	14 (33%)	17 (42%)	
II	11 (20%)	4 (9%)	3 (8%)	
III	20 (36%)	15 (35%)	13 (33%)	
IV	7 (12%)	10 (23%)	7 (17%)	
Myometrial invasion				**0.009**[d,e]
<50%	18 (32%)	22 (54%)	21 (60%)	
>50%	38 (68%)	19 (46%)	14 (40%)	
Missing	0	2	5	
Vascular invasion				0.072[d,f]
Negative	25 (45%)	20 (56%)	12 (34%)	
Positive	30 (55%)	16 (44%)	23 (66%)	
Missing	1	7	5	
Peritoneal washing				NS[c,d]
Negative	40 (80%)	23 (70%)	15 (71%)	
Positive	10 (20%)	10 (30%)	4 (19%)	
Missing	6	10	21	
Recurrent disease				NS[c,d]
No	39 (70%)	32 (74%)	25 (63%)	
Yes	17 (30%)	11 (26%)	15 (38%)	
Local	3 (18%)	3 (27%)	2 (13%)	
Pelvic region	2 (11%)	1 (9%)	3 (20%)	
Distant	12 (71%)	7 (64%)	10 (67%)	
Follow-up				**<0.001**[c,d]
Death due to disease	11/56 (20%)	16/43 (37%)	23/40 (58%)	

Abbreviation: NS, not significant.
[a]Percentages exclude missing cases.
[b]Mann–Whitney *U*-test used.
[c]Carcinosarcoma compared with grade 3 endometrioid and non-endometrioid carcinoma.
[d]χ^2 test used, characteristics divided into two categories.
[e]Carcinosarcoma compared with grade 3 endometrioid carcinoma.
[f]Carcinosarcoma compared with non-endometrioid carcinoma.
Bold values indicate $P<0.05$.

were caused by the epithelial component only; both components were present in 4 out of 18 cases (22%) and in 1 case (6%) only the mesenchymal component represented metastatic tissue. Total abdominal hysterectomy and bilateral salpingo-oopherectomy was performed in 30% of the patients; more extended surgery with pelvic and/or para-aortic lymph node dissection was performed in 58%. Adjuvant radiotherapy was given to 19 patients (48%) and adjuvant chemotherapy was given to five patients (13%). Owing to metastatic disease, five patients (13%) were not treated with total abdominal hysterectomy and bilateral salpingo-oopherectomy, but received palliative chemotherapy (two patients) or radiotherapy (three patients) only. Recurrent disease developed in 15 patients (38%), with a median time to recurrence of 5 months (IQR: 3–11). Three patients (8%) did not have a disease-free interval after surgery. In total, 23 patients (58%) died as a result of disease during our follow-up. The median time between diagnosis and death of disease was 1 year.

Immunohistochemistry

Immunohistochemical results are summarized in Table 3.

Hormonal receptors (ER-α, ER-β, PR-A, PR-B)
Positive ER-α expression was observed in 33% of the epithelial component and 17% of the mesenchymal component. Positive immunostaining was present in both components in 8% of the cases. ER-α expression was associated with low tumor grade (OR: 5.4; 95%-CI: 1.1–27.8), an endometrioid epithelial component (OR: 7.4; 95%-CI: 0.8–68.1) and no vascular invasion (OR: 7.2; 95%-CI: 1.5–34.1)

(data not shown). ER-α expression was observed in 23% of the metastatic tissue samples. Positive ER-β expression was more frequently observed in the mesenchymal component compared with the epithelial component (56% *vs* 37%, respectively). In 8 of 25 cases (32%), positive expression was seen in both components ($P=0.041$). In metastatic tumor tissue, positive ER-β expression was observed in 67% (epithelial component) and 60% (mesenchymal component). No associations were found between ER-β expression and clinicopathological characteristics. PR-A expression was observed in 5% (epithelial component) and in 10% (mesenchymal component). PR-A expression was not observed in both tumor components simultaneously. No associations were found between PR-A expression and clinicopathological characteristics.

PR-B expression was found in 41% and 35% in the epithelial and the mesenchymal component, respectively. When paired tumor components were present for evaluation, positive PR-B expression was seen in 23% of the tumors. Furthermore, percentages of positive expression were higher in metastatic tissue: 47% and 80% positivity in epithelial and mesenchymal components, respectively. PR-B expression was significantly associated with an endometrioid epithelial component (OR: 11.2; 95%-CI: 1.2–104.3) and low tumor grade (OR: 4.5; 95%-CI: 0.9–22.7) (data not shown).

MMR proteins (MLH1, MSH2 and MSH6)
Loss of expression of ≥ 1 MMR protein was observed in 12 of 29 carcinosarcomas (41%). In the epithelial tumor component, absent immunostaining of MLH1, MSH2 and MSH6 was observed in 61%, 35% and 36%, respectively. Percentages were slightly lower in the mesenchymal component (MLH1: 40%; MSH2: 29%; and MSH6: 27%, respectively). When comparing expression patterns between both tumor components, similarities were observed in the majority of the cases: MLH1 (63%, $P=0.134$), MSH2 (74%, $P=0.033$) and MSH6 (68%, $P=0.050$). Tumors showed completely negative immunohistochemical expression for MLH1 in eight of 24 cases (33%), for MSH2 in 6 of 27 cases (22%) and for MSH6 in 6 of 29 cases (21%). No associations were found between the expression of MLH1, MSH2, MSH6 and clinicopathological characteristics.

PTEN
Complete loss of PTEN expression was observed in 12 of 31 cases (39%). Expression levels differed slightly between epithelial (64% absent expression) and mesenchymal components (52% absent expression). In the majority of cases, expression was similar in both tumor components (65%, $P=0.100$). No associations were found between expression of PTEN and clinicopathological characteristics. PTEN expression correlated with MLH1 ($r_s=0.722$; $P<0.001$) and MSH2 expression ($r_s=0.440$; $P=0.010$, respectively) in the epithelial component. Furthermore, absent PTEN expression was more frequently detected in tumors with loss of expression of ≥ 1 MMR protein (7/12; 58%) compared with tumors without loss of MMR protein expression (4/17, 24%), although this was not significant ($P=0.119$) (data not shown).

p53
p53 overexpression was observed in 46% and 53% in the epithelial and the mesenchymal component, respectively. In the majority of cases, expression was similar in both tumor components (83%, $P<0.001$). Furthermore, p53 expression was similar in primary tissue and paired metastatic tissue ($P=0.002$). Overexpression of p53 was more often observed in a non-endometrioid epithelial tumor component (OR: 16.0; 95%-CI: 1.7–151.1).

β-Catenin
Nuclear β-catenin expression was observed in 11% (epithelial component) and 13% (mesenchymal component). In only one case, nuclear β-catenin expression was observed in both tumor components. β-Catenin expression was associated with an endometrioid tumor type ($P=0.035$) (data not shown). Furthermore, β-catenin expression was similar in primary tissue and paired metastatic tissue ($P=0.038$).

Cyclin D1
Cyclin D1 expression was observed in 24% (epithelial component) and 23% (mesenchymal component). In 7% of the cases, both tumor components showed positive cyclin D1 expression. Similar expression patterns were observed in primary and paired metastatic tumor tissue ($P=0.035$). No associations were observed between cyclin D1 and clinicopathological parameters. Simultaneous co-expression of nuclear β-catenin and cyclin D1 was found in one case (3%).

No associations were found between immunohistochemical expression of molecular markers and disease-specific survival of uterine carcinosarcoma patients.

Comparison of Endometrioid and Non-Endometrioid Epithelial Tumor Components of Carcinosarcomas

In the majority of carcinosarcoma patients, the epithelial tumor component accounted for metastases (72%) and vascular invasion (70%). We investigated whether clinicopathological characteristics and disease-specific survival of patients differed between an endometrioid and a non-endometrioid epithelial tumor component. For this analysis, undifferentiated tumor type ($n=3$) or unknown tumor type ($n=3$) in the epithelial component were excluded. As shown in Table 4, frequencies of positive peritoneal washings (tumor

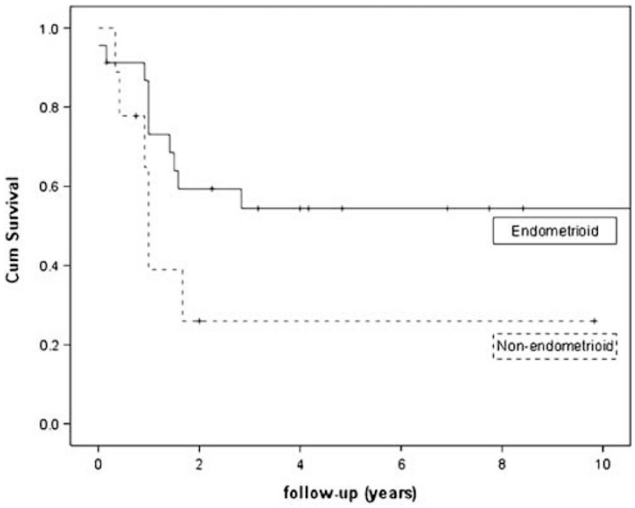

Figure 1 Disease-specific survival according to tumor type in the epithelial component of uterine carcinosarcoma (endometrioid *vs* non-endometrioid) ($P=0.104$, log-rank).

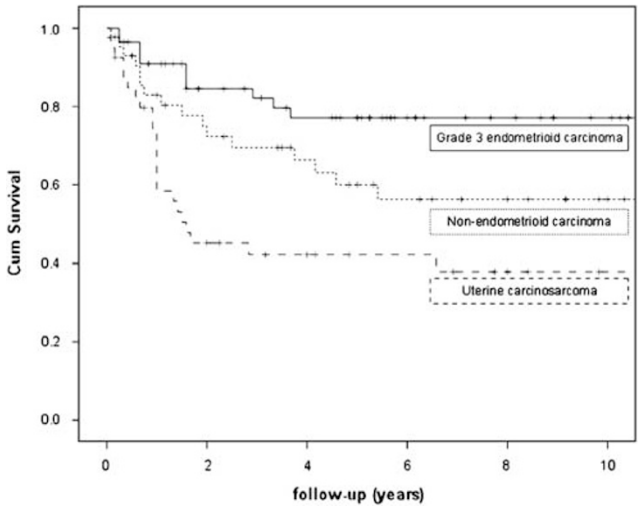

Figure 2 Disease-specific survival according to tumor type (grade 3 endometrioid carcinoma, non-endometrioid carcinoma and uterine carcinosarcoma) ($P<0.001$, log-rank).

cells present), omental metastases and recurrent disease were not significantly different between endometrioid and non-endometrioid epithelial components of carcinosarcomas. However, peritoneal metastases tended to occur more frequently in patients with a non-endometrioid epithelial tumor component ($P=0.063$). During follow-up, nine patients were still alive without evidence of disease. All these patients were diagnosed with an endometrioid epithelial tumor component ($P=0.083$). Patients with a non-endometrioid epithelial component tended to have a worse disease-specific survival (5-year survival: 26%) compared with patients with an endometrioid epithelial component (5-year survival: 55%) ($P=0.104$) (Figure 1).

Comparison of Characteristics between Carcinosarcomas and High-Risk Endometrial Carcinomas

Clinicopathological characteristics and disease-specific survival were compared between high-risk endometrial carcinomas ($n=99$) and uterine carcinosarcomas ($n=40$) (Table 5). Grade 3 endometrioid endometrial carcinomas more frequently showed $>50\%$ myometrial invasion compared with uterine carcinosarcomas ($P=0.009$). Other clinicopathological characteristics did not differ between these subtypes. Patients with uterine carcinosarcomas had a worse disease-specific survival (5-year survival: 42%) compared with non-endometrioid carcinoma (5-year survival: 57%) and grade 3 endometrioid carcinoma (5-year survival: 77%) ($P<0.001$) (Figure 2).

Discussion

This study investigated immunohistochemical expression of 11 markers in a well-defined cohort of patients with carcinosarcomas of the uterus, all treated at the University Medical Center Groningen. Immunohistochemical expression was compared between the epithelial and mesenchymal tumor components of uterine carcinosarcomas.

Overexpression of p53 (a tumor suppressor gene, located on chromosome 17q13.1) showed a high concordance between both tumor components. In addition, p53 overexpression highly correlated between primary and metastatic tumor tissue. Next to p53, mutations in *MMR* genes are an early event in tumorigenesis.[21] It has been shown that loss of immunohistochemical staining of MMR proteins (MLH1, MSH2 and MSH6) correlates to the corresponding *MMR* gene mutation.[22] We observed that expression levels of MSH2 and MSH6 correlated between epithelial and mesenchymal tumor components. Above-mentioned results are in line with other studies and confirm the monoclonal origin of uterine carcinosarcomas.[8,9,23–25]

The ER and PR are important in growth, differentiation and function of reproductive tissues. In the past decade, two subtypes of ER (ER-α and ER-β) and PR (PR-A and PR-B) have been discovered. Its importance in tumor development and prognosis has been studied in endometrial carcinomas, but reports in uterine carcinosarcomas are scarce.[26–29] In this study, ER-α expression was associated with low tumor grade, an endometrioid epithelial tumor component and no vascular invasion, which is in agreement with results in endometrial carcinomas.[30] Furthermore, we observed that ER-α was mainly expressed in the epithelial component in contrast to ER-β, which was more predominantly expressed in the mesenchymal component. Overall, ER-β was more frequently expressed than ER-α in our population. These results are in line with two previous reports.[26,27] To our knowledge, we are the first to determine subtype expression of PR (PR-A and

PR-B) in uterine carcinosarcomas. PR-A was less frequently expressed than PR-B (5% and 10% *vs* 41% and 35% in epithelial and mesenchymal components, respectively). Expression of PR-B was associated with an endometrioid epithelial tumor component, similar to results in endometrial carcinomas.[31] Two developmental pathways can be distinguished in endometrial carcinomas: type I endometrial cancers arise on background of hyperplasia after unopposed estrogen stimulation and type II endometrial cancers are not estrogen driven.[10] The fact that ER-α and PR-B are associated with low grade and an endometrioid tumor type in our population suggest a similar pathway in uterine carcinosarcomas. Probably, tumors with an endometrioid epithelial tumor type develop under the influence of estrogen and tumors with a non-endometrioid tumor type develop independent of estrogen. During dedifferentiation to the sarcomatous component, loss of ER-α expression occurs, whereas ER-β is more frequently expressed during progression of disease, a mechanism that has been shown previously in endometrial carcinomas.[30]

In type I endometrial carcinoma, microsatellite instability is a frequent phenomenon with incidences ranging from 20% to 90% compared with 0% to 11% in type II endometrial carcinoma.[2,32,33] Microsatellite instability is caused by an inability of the MMR system to cut out and replace the mismatching DNA strains due to methylation or mutation of its proteins (MLH1, MSH2 and MSH6).[34] Two previous studies showed that microsatellite instability was present in 5%[35] and 23.3%[21] of uterine carcinosarcomas. The latter study observed that microsatellite instability is mainly a feature of the epithelial component.[21] This is in agreement with our finding; loss of MMR protein expression was more frequently observed in the epithelial component compared with the mesenchymal component, although expression levels corresponded between both tumor components in the majority of the cases. Furthermore, we observed that tumors with loss of expression of ≥ 1 MMR protein more frequently had absent PTEN immunostaining, which is in agreement with previous reports in endometrial carcinomas.[36,37] PTEN acts as a tumor suppressor gene through the action of its phosphatase protein product. PTEN mutations more frequently occur in type I endometrial carcinomas (35–55%) compared with type II endometrial carcinomas (5–11%).[2,37,38] Mutation or dysfunction of PTEN can be seen as negative immunohistochemistry staining, which was the case in 39% of our study population. One previous study reported PTEN mutations in 14.3% of uterine carcinosarcomas.[38] A possible explanation for these different percentages is that the latter study was performed in a smaller study population and different detection methods for PTEN mutations were used.

Previous reports have shown that p53 overexpression was present in 28–84% of carcinosarcomas[8,9,23,25,39] compared with 38% in our population. Mutant or altered p53 gene protein has a prolonged half-life and accumulates to detectable immunohistochemical levels. Overexpression of p53 is typically present in 90% of non-endometrioid endometrial carcinomas compared with 10% in endometrioid endometrial carcinomas.[3] In our cohort, overexpression was associated with a non-endometrioid epithelial tumor component of uterine carcinosarcomas.

Aberrant activation of the Wnt signaling pathway has an important role in the tumorigenesis of a wide range of tumors,[40] in which β-catenin has a crucial role. Mutations of β-catenin result in stabilization of a protein that resists degradation, leading to nuclear accumulation that can be shown by immunohistochemistry.[41] Mutations of β-catenin are considered an early event in tumorigenesis.[2] The reported frequency of β-catenin mutations in type I endometrial carcinomas ranges from 14% to 44% compared with 0% to 5% in type II endometrial carcinomas.[3] To date, only two studies reported on this subject in uterine carcinosarcomas.[24,41] To determine the function of the aberrant Wnt signaling in carcinosarcomas of the uterus, we determined β-catenin and cyclin D1 expression (which is a direct target gene of β-catenin). In our population, nuclear β-catenin expression was present in 11% and 13% in the epithelial and mesenchymal component of carcinosarcomas, respectively. Percentages resemble results found in type I endometrial carcinoma.[3] In only one tumor, simultaneous expression of nuclear β-catenin in both tumor components was observed. Expression differences between tumor components were reported previously, but exact percentages are lacking.[24] Previously, positive nuclear β-catenin immunostaining was detected in 86% of uterine carcinosarcomas,[41] which is higher compared with our result. However, this study population was smaller ($n = 7$) and different techniques for immunohistochemistry analysis were used. To our knowledge, we are the first to determine cyclin D1 expression in uterine carcinosarcomas. Positive expression was found in 24% and 23% (epithelial and mesenchymal component, respectively). Co-expression of nuclear β-catenin and cyclin D1 was an infrequent observation: 3% of epithelial components and 3% of mesenchymal components. These results suggest that an activated Wnt/β-catenin pathway is a rare event in uterine carcinosarcomas.

We and others showed that uterine carcinosarcomas have a more aggressive biological behavior compared with high-risk endometrial carcinomas, resulting in a worse disease-specific survival.[11,12] Evidence is emerging that the epithelial component is the 'driving force' in this tumor type.[5,42] In our population, we observed that the epithelial component was responsible for the majority of metastases (72%) and vascular invasion (70%). In addition, patients with a non-endometrioid epithelial tumor component tended to have more peritoneal metastases compared to patients with an endometrioid

tumor component. Next, patients with non-endometrioid epithelial component tended to have a worse disease-specific survival compared to patients with an endometrioid epithelial component. Although not statistically significant, these findings suggest that the developmental pathway of uterine carcinosarcomas is similar to endometrial carcinomas and can be divided into type I and type II (according to the epithelial tumor component).

In summary, this study investigated molecular markers and clinical characteristics of uterine carcinosarcomas. Immunohistochemistry expression of p53, MSH2 and MSH6 highly corresponded between epithelial and mesenchymal components, confirming the monoclonal origin of uterine carcinosarcomas. Furthermore, immunohistochemistry results showed similarities to endometrial carcinomas: p53 expression was associated with a non-endometrioid epithelial tumor component and expression patterns of MMR proteins, PTEN and hormone receptors resembled results previously found in type I endometrial carcinomas. In our population, the epithelial component caused the majority of metastases and vascular invasion. Above-mentioned results show that uterine carcinosarcomas are metaplastic endometrial carcinomas with similar developmental pathways. Currently, uterine carcinosarcomas are treated as high-risk endometrial carcinoma, which is justified based on these results. However, patients with uterine carcinosarcomas have a worse disease-specific survival compared with high-risk endometrial carcinomas. Therefore, future research is needed to improve therapy and should focus on characteristics of the epithelial component of carcinosarcomas.

Acknowledgement

We thank Mrs Tineke van der Sluis for her assistance with the construction of the tissue microarrays and immunohistochemistry.

Disclosure/conflict of interest

The authors declare no conflict of interest.

References

1 Brooks SE, Zhan M, Cote T, *et al.* Surveillance, epidemiology, and end results analysis of 2677 cases of uterine sarcoma 1989–1999. Gynecol Oncol 2004;93:204–208.
2 Lax SF. Molecular genetic changes in epithelial, stromal and mixed neoplasms of the endometrium. Pathology 2007;39:46–54.
3 Samarnthai N, Hall K, Yeh IT. Molecular profiling of endometrial malignancies. Obstet Gynecol Int 2010; Article ID 162363.
4 McCluggage WG, Abdulkader M, Price JH, *et al.* Uterine carcinosarcomas in patients receiving tamoxifen. A report of 19 cases. Int J Gynecol Cancer 2000;10:280–284.
5 Silverberg SG, Major FJ, Blessing JA, *et al.* Carcinosarcoma (malignant mixed mesodermal tumor) of the uterus. A Gynecologic Oncology Group pathologic study of 203 cases. Int J Gynecol Pathol 1990;9:1–19.
6 McCluggage WG. Uterine carcinosarcomas (malignant mixed Mullerian tumors) are metaplastic carcinomas. Int J Gynecol Cancer 2002;12:687–690.
7 McCluggage WG, Robboy SJ. Mesenchymal uterine tumors and adenomyosis. In: Robboy SJ, Mutter GL, Prat J, Bentley RC, Russell P, Anderson MC (eds). Pathology of the Female Reproductive Tract, 2 edn. Churchill Livingstone Elsevier: Amsterdam, 2009, pp 427–456.
8 Kounelis S, Jones MW, Papadaki H, *et al.* Carcinosarcomas (malignant mixed Mullerian tumors) of the female genital tract: comparative molecular analysis of epithelial and mesenchymal components. Hum Pathol 1998;29:82–87.
9 Wada H, Enomoto T, Fujita M, *et al.* Molecular evidence that most but not all carcinosarcomas of the uterus are combination tumors. Cancer Res 1997;57:5379–5385.
10 Bokhman JV. Two pathogenetic types of endometrial carcinoma. Gynecol Oncol 1983;15:10–17.
11 Amant F, Cadron I, Fuso L, *et al.* Endometrial carcinosarcomas have a different prognosis and pattern of spread compared to high-risk epithelial endometrial cancer. Gynecol Oncol 2005;98:274–280.
12 George E, Lillemoe TJ, Twiggs LB, *et al.* Malignant mixed Mullerian tumor *versus* high-grade endometrial carcinoma and aggressive variants of endometrial carcinoma: a comparative analysis of survival. Int J Gynecol Pathol 1995;14:39–44.
13 D'Angelo E, Prat J. Uterine sarcomas: a review. Gynecol Oncol 2010;116:131–139.
14 Homesley HD, Filiaci V, Markman M, *et al.* Phase III trial of ifosfamide with or without paclitaxel in advanced uterine carcinosarcoma: a Gynecologic Oncology Group Study. J Clin Oncol 2007;25:526–531.
15 Powell MA, Filiaci VL, Rose PG, *et al.* Phase II evaluation of paclitaxel and carboplatin in the treatment of carcinosarcoma of the uterus: a Gynecologic Oncology Group study. J Clin Oncol 2010;28: 2727–2731.
16 Wolfson AH, Brady MF, Rocereto T, *et al.* A gynecologic oncology group randomized phase III trial of whole abdominal irradiation (WAI) *vs* cisplatin–ifosfamide and mesna (CIM) as post-surgical therapy in stage I–IV carcinosarcoma (CS) of the uterus. Gynecol Oncol 2007;107:177–185.
17 FIGO Cancer Committee. Staging Announcement: FIGO Cancer Committee. Cancer Committee of the International Federation of Gynaecology and Obstetrics (1986). Gynecol Oncol 2008;25:383–385.
18 Silverberg SG, Kurman RJ, Nogales F, *et al.* Tumours of the uterine corpus. In: Tavassoli FA, Devilee P (eds). Pathology and Genetics of Tumours of the Breast and Female Genital Organs (World Health Organization Classification of Tumours) 1st edn. IARC Press: Lyon, 2003, pp 217–257.
19 Kononen J, Bubendorf L, Kallioniemi A, *et al.* Tissue microarrays for high-throughput molecular profiling of tumor specimens. Nat Med 1998;4:844–847.
20 Noordhuis MG, Eijsink JJ, ten Hoor KA, *et al.* Expression of epidermal growth factor receptor (EGFR)

and activated EGFR predict poor response to (chemo)radiation and survival in cervical cancer. Clin Cancer Res 2009;15:7389–7397.
21 Taylor NP, Zighelboim I, Huettner PC, *et al.* DNA mismatch repair and TP53 defects are early events in uterine carcinosarcoma tumorigenesis. Mod Pathol 2006;19:1333–1338.
22 Niessen RC, Berends MJ, Wu Y, *et al.* Identification of mismatch repair gene mutations in young patients with colorectal cancer and in patients with multiple tumours associated with hereditary non-polyposis colorectal cancer. Gut 2006;55:1781–1788.
23 Abargel A, Avinoach I, Kravtsov V, *et al.* Expression of p27 and p53: comparative analysis of uterine carcinosarcoma and endometrial carcinoma. Int J Gynecol Cancer 2004;14:354–359.
24 Saegusa M, Hashimura M, Kuwata T, *et al.* Requirement of the Akt/beta-catenin pathway for uterine carcinosarcoma genesis, modulating E-cadherin expression through the transactivation of slug. Am J Pathol 2009;174:2107–2115.
25 Sherman ME, Bur ME, Kurman RJ. p53 in endometrial cancer and its putative precursors: evidence for diverse pathways of tumorigenesis. Hum Pathol 1995;26:1268–1274.
26 Ansink AC, Cross PA, Scorer P, *et al.* The hormonal receptor status of uterine carcinosarcomas (mixed Mullerian tumours): an immunohistochemical study. J Clin Pathol 1997;50:328–331.
27 Huang GS, Arend RC, Li M, *et al.* Tissue microarray analysis of hormonal signaling pathways in uterine carcinosarcoma. Am J Obstet Gynecol 2009;200:457.e1-457.e5.
28 Ioffe YJ, Li AJ, Walsh CS, *et al.* Hormone receptor expression in uterine sarcomas: prognostic and therapeutic roles. Gynecol Oncol 2009;115:466–471.
29 Jazaeri AA, Nunes KJ, Dalton MS, *et al.* Well-differentiated endometrial adenocarcinomas and poorly differentiated mixed Mullerian tumors have altered ER and PR isoform expression. Oncogene 2001;20:6965–6969.
30 Jongen VH, Briet JM, de Jong RA, *et al.* Aromatase, cyclooxygenase 2, HER-2/neu, and p53 as prognostic factors in endometrioid endometrial cancer. Int J Gynecol Cancer 2009;19:670–676.
31 Shabani N, Kuhn C, Kunze S, *et al.* Prognostic significance of oestrogen receptor alpha (ERalpha) and beta (ERbeta), progesterone receptor A (PR-A) and B (PR-B) in endometrial carcinomas. Eur J Cancer 2007;43:2434–2444.
32 Catasus L, Machin P, Matias-Guiu X, *et al.* Microsatellite instability in endometrial carcinomas: clinicopathologic correlations in a series of 42 cases. Hum Pathol 1998;29:1160–1164.
33 Karamurzin Y, Rutgers JK. DNA mismatch repair deficiency in endometrial carcinoma. Int J Gynecol Pathol 2009;28:239–255.
34 Arabi H, Guan H, Kumar S, *et al.* Impact of microsatellite instability (MSI) on survival in high grade endometrial carcinoma. Gynecol Oncol 2009;113:153–158.
35 Amant F, Dorfling CM, Dreyer L, *et al.* Microsatellite instability in uterine sarcomas. Int J Gynecol Cancer 2001;11:218–223.
36 Bilbao C, Rodriguez G, Ramirez R, *et al.* The relationship between microsatellite instability and PTEN gene mutations in endometrial cancer. Int J Cancer 2006;119:563–570.
37 Risinger JI, Hayes K, Maxwell GL, *et al.* PTEN mutation in endometrial cancers is associated with favorable clinical and pathologic characteristics. Clin Cancer Res 1998;4:3005–3010.
38 Amant F, de la Rey M, Dorfling CM, *et al.* PTEN mutations in uterine sarcomas. Gynecol Oncol 2002;85:165–169.
39 Lee SJ, Kim HS, Kim HS, *et al.* Immunohistochemical study of DNA topoisomerase I, p53, and Ki-67 in uterine carcinosarcomas. Hum Pathol 2007;38:1226–1231.
40 Kurihara S, Oda Y, Ohishi Y, *et al.* Coincident expression of beta-catenin and cyclin D1 in endometrial stromal tumors and related high-grade sarcomas. Mod Pathol 2010;23:225–234.
41 Ng TL, Gown AM, Barry TS, *et al.* Nuclear beta-catenin in mesenchymal tumors. Mod Pathol 2005;18:68–74.
42 Sreenan JJ, Hart WR. Carcinosarcomas of the female genital tract. A pathologic study of 29 metastatic tumors: further evidence for the dominant role of the epithelial component and the conversion theory of histogenesis. Am J Surg Pathol 1995;19:666–674.