Well-differentiated spindle cell liposarcoma ('atypical spindle cell lipomatous tumor') does not belong to the spectrum of atypical lipomatous tumor but has a close relationship to spindle cell lipoma: clinicopathologic, immunohistochemical, and molecular analysis of six cases

Thomas Mentzel[1], Gabriele Palmedo[1] and Cornelius Kuhnen[2]

[1]*Dermatopathologie, Friedrichshafen, Germany and* [2]*Institute of Pathology, Medical Center, Münster, Germany*

Well-differentiated spindle cell liposarcoma represents a rare atypical/low-grade malignant lipogenic neoplasm that has been regarded as a variant of atypical lipomatous tumor. However, well-differentiated spindle cell liposarcoma tends to occur in subcutaneous tissue of the extremities, the trunk, and the head and neck region, contains slightly atypical spindled tumor cells often staining positively for CD34, and lacks an amplification of *MDM2* and/or *CDK4* in most of the cases analyzed. We studied a series of well-differentiated spindle cell liposarcomas arising in two female and four male patients (age of the patients ranged from 59 to 85 years). The neoplasms arose on the shoulder, the chest wall, the thigh, the lower leg, the back of the hand, and in paratesticular location. The size of the neoplasms ranged from 1.5 to 10 cm (mean: 6.0 cm). All neoplasms were completely excised. The neoplasms were confined to the subcutis in three cases, and in three cases, an infiltration of skeletal muscle was seen. Histologically, the variably cellular neoplasms were composed of atypical lipogenic cells showing variations in size and shape, and spindled tumor cells with slightly enlarged, often hyperchromatic nuclei. Multivacuolated lipoblasts were present in three neoplasms. Focal myxoid stromal changes were seen in three cases. Immunohistochemically, CD34 was at least focally positive in all cases, whereas scattered tumor cells only showed a nuclear expression of MDM2 in two neoplasms. FISH analysis revealed a deletion of the *Rb-1* gene in all six cases, whereas no *MDM2/CDK4* amplification was identified in all cases tested. Follow-up information was available in four cases (range from 4 to 24 months), and revealed a local recurrence in one case. Although well-differentiated spindle cell liposarcoma and atypical lipomatous tumor behave clinically similar, it can be speculated on the basis of clinicopathologic and molecular findings that well-differentiated spindle cell liposarcoma may constitute an independent entity rather than a morphologic variant of atypical lipomatous tumor, and may represent the atypical/low-grade counterpart of spindle cell lipoma.
Modern Pathology (2010) **23,** 729–736; doi:10.1038/modpathol.2010.66; published online 12 March 2010

Keywords: liposarcoma; atypical lipomatous tumor; spindle cell liposarcoma; spindle cell lipoma; immunohistochemistry; cytogenetics

Atypical and malignant lipogenic neoplasms represent the most common soft tissue sarcoma in adults, accounting for approximately 20% of all sarcomas. Liposarcoma is currently subclassified into five main subtypes, including atypical lipomatous tumor/well-differentiated liposarcoma, dedifferentiated liposarcoma, myxoid liposarcoma,

Correspondence: Dr T Mentzel, MD, Department of Dermatopathology, Siemensstrasse 6/1, Friedrichshafen D-88048, Germany.
E-mail: mentzel@dermpath.de, http://www.dermpath.de
Received 27 October 2009; revised 16 January 2010; accepted 19 January 2010; published online 12 March 2010

including high-grade round cell liposarcoma, pleomorphic liposarcoma, and rare mixed-type liposarcoma.[1] Cytogenetic and molecular genetic studies contributed substantially to this classification, and specific chromosomal abnormalities have been detected for most types of liposarcoma. Atypical lipomatous tumors/well-differentiated liposarcomas and dedifferentiated liposarcomas are characterized by supernumery ring and/or giant marker chromosomes containing amplified material of the q13–15 regions of chromosome 12. Myxoid/round cell liposarcomas show a specific reciprocal chromosome translocation t(12;16)(q13.3;p11.2) with fusion of the *CHOP* and *FUS* genes as the primary chromosomal aberration, and pleomorphic liposarcomas often have multiple, complex structural rearrangements without consistent and specific abnormalities.

Atypical lipomatous tumor/well-differentiated liposarcoma has been subclassified morphologically into lipomatous, sclerosing, and inflammatory subtypes. However, combinations of these variants may occur and there are no significant clinicopathologic, molecular, and prognostic differences.[2] In 1994, well-differentiated spindle cell liposarcoma has been first described[3] and later further characterized[4,5] as an atypical lipogenic neoplasm composed of atypical adipocytes showing striking variation in size and shape with scattered enlarged and hyperchromatic nuclei associated with slightly atypical spindle-shaped neoplastic cells. Well-differentiated spindle cell liposarcoma is characterized clinically by a locally aggressive growth and may recur, whereas metastases do not occur and dedifferentiation has been reported only very rarely.[3,5] Given the comparable clinical and prognostic features, well-differentiated spindle cell liposarcoma has been originally placed under the heading of atypical lipomatous tumor. However, over the years, we and others (Prof. Fletcher, Boston, MA, USA, personal communication) became aware that well-differentiated spindle cell liposarcoma has important clinicopathologic differences to atypical lipomatous tumor, and, most importantly, does not show an amplification of the *MDM2* and/or *CDK4* genes or an immunohistochemically detectable expression of MDM2 and/or CDK4 in most cases, which is characteristic for atypical lipomatous tumor. On the other hand, a monosomy of chromosome 7 and absence of 12q amplification has been reported in two cases of well-differentiated spindle cell liposarcoma most recently, suggesting that different genetic changes are found in these neoplasms.[6] We studied six cases of well-differentiated spindle cell liposarcoma and discuss the relationship of these neoplasms to spindle cell lipoma.

Materials and methods

The cases were retrieved from the referral files of two of the authors (TM, CK), and clinical and follow-up informations were obtained from the referring pathologists (see Acknowledgements). The tissue in all cases was fixed in 4% buffered formalin, routinely processed, and embedded in paraffin; 2–4 μm thick sections were stained with hematoxylin and eosin. In addition, representative sections were stained immunohistochemically by the labeled Streptavidin Biotin technique using commercially available antibodies; antigen retrieval was used for all antibodies.

Stainings for MDM2 (IF2; 1:200; Invitrogen), CDK4 (DC9-31; 1:400; Biosource), CD34 (HPCA-1; 1:100, Becton and Dickinson), and S-100 protein (polyclonal, 1:4000; DAKO, Glostrup, Denmark) were performed. Appropriate positive and negative controls were used. Fluorescence *in situ* hybridization for the amplification of the *CDK4* and *MDM2* genes was performed by hybridization of DIG-labeled BACs followed by binding to FITC anti-DIG. FISH analysis for the detection of the deletion of the *Rb-1* gene, located on the long arm of chromosome 13, was performed with a direct spectrum orange-labeled probe (Abbott, Bergisch Gladbach, Germany). FISH analysis was performed on 3 μm sections of formalin-fixed, paraffin-embedded tissue after baking at 65°C for 16 h, deparaffinization with xylene, and dehydration with ethanol. All tissue sections were pretreated with a 30% solution of Oncor pretreatment solution and digested with Proteinase K following the instructions of the suppliers (Q-Biogene, Heidelberg, Germany). Digestion times were optimized on a case-by-case basis. After a second dehydration step, the probes were applied to the sections and the covered slides were sealed with rubber cement, heat denatured, and hybridized at 37°C for 16 h. One positive and one negative control were included in each FISH series. After stringent washing with 50% formamide in $2 \times$ SSC and treating with FITC anti-DIG in case of the indirectly labeled probes, the sections were counterstained with DAPI II in mounting medium (125 ng/ml, Abbott Bergisch Gladbach, Germany) and visualized under a Zeiss Axioplan 2 microscope using an HBO103 lamp and the appropriate filters for three fluorescence dyes.

Results

The clinical details are summarized in Table 1. Briefly, the neoplasms arose in two female and four male patients (the age of the patients ranged from 59 to 85 years) and were seen on the right shoulder, the chest wall, the thigh, the lower leg, the back of the hand, and in paratesticular location. All neoplasms were excised as well as re-excised with tumor-free margins and adjuvant treatment was not performed. The size of the neoplasms ranged from 1.5 to 10 cm in largest diameter (mean: 6.0 cm). A local recurrence was seen at 6 months in Case 5 and excised completely. No metastasis was noted, and all patients are alive and tumor free (follow-up

Table 1 Clinical data in six cases of well-differentiated spindle cell liposarcoma

Case no.	*Age (years)*	*Sex*	*Site*	*Size (cm)*	*Follow-up*
1	75	M	Right shoulder	1.5	NSR at 4 months
2	59	M	Paratesticular	10.0	NSR at 24 months
3	85	F	Lower leg	2.8	NSR at 24 months
4	70	M	Chest wall	10.0	NA
5	60	F	Back of hand	3.5	R at 6 months; NSR 9 months later
6	62	M	Left thigh	9.1	Recent case

NA, data not available; NSR, no sign of recurrence; R, local recurrence; F, female; M, male.

informations were available in four cases and ranged from 4 to 24 months).

Whereas three neoplasms arose predominantly in the subcutis and showed a nodular or multinodular growth, an infiltration of the skeletal muscle was noted in Cases 3, 5, and 6 that were characterized by a more infiltrative growth pattern. None of the neoplasms was completely encapsulated. All neoplasms were composed of lipogenic cells and a varying number of spindle-shaped tumor cells. The lipogenic tumor cells were characterized by variations in cell size and shape and scattered enlarged and hyperchromatic nuclei were noted. Lipoblasts, showing a mono- and/or multivacuolated cytoplasm, and scalloped, hyperchromatic nuclei were detected in Cases 3, 5, and 6 (Figure 1). In all cases, associated spindled tumor cells with slightly enlarged and often hyperchromatic nuclei were seen, and although the cellularity was relatively low in Cases 2 and 4, an increased number of these spindled cells was present in the remaining cases (Figure 2). Mitotic figures were scanty, ranging from 1 to 2 mitoses per 30 high power fields in all lesions. Focal myxoid stromal changes were seen in Cases 1, 2, and 5, whereas a rather collagenous stroma was present in Case 4. A focal inflammatory infiltrate was present in Case 5, and scattered mast cells were seen in the cases showing focal myxoid stromal changes. Long, thin collagenous bundles were noted in Case 4, but hyalinized, ropy-like collagen fibers were not present.

The results of the immunohistochemical and molecular studies are summarized in Table 2. Immunohistochemically, spindled tumor cells stained positively for CD34 in Cases 2, 3, 4, 5, and 6, and a focal expression of this marker was seen in Case 1. Scattered tumor cells in Cases 3 and 5 showed a nuclear expression of MDM2 (Figure 3). Whereas none of the cases tested showed an amplification of *MDM2* and/or *CDK4* by FISH analysis, a deletion of the *Rb-1* gene was noted in all six cases (Figure 4).

Discussion

Well-differentiated spindle cell liposarcoma represents a distinct lipogenic neoplasm composed of atypical lipogenic cells associated with a variable number of slightly atypical spindle-shaped neoplastic cells. In contrast to all morphologic variants of atypical lipomatous tumor/well-differentiated liposarcoma, well-differentiated spindle cell liposarcoma tends to occur in the subcutis or in superficial soft tissues. The trunk, especially the shoulder region, the extremities, and the head and neck region are the preferred anatomic sites, whereas these neoplasms are seen only rarely in the retroperitoneum or intraabdominal. Histologically, spindled tumor cells in well-differentiated spindle cell liposarcoma contain slightly enlarged, fusiform nuclei that are sometimes hyperchromatic and irregularly shaped. Spindled tumor cells are set in a collagenous stroma that may show hyalinization or myxoid changes. Immunohistochemically, an expression of CD34 by the spindled tumor cells has been reported in many cases, and also in our small series, all neoplasms showed at least focally an expression of this marker. In addition, a focal expression of desmin by spindled tumor cell has been reported in few cases.[3] In striking contrast to all morphologic variants of atypical lipomatous tumor, an expression and/or amplification of MDM2 and/or CDK4 that is characteristic for atypical lipomatous tumor, is seen only in the minority of analyzed cases of well-differentiated spindle cell liposarcoma. In our series, only few tumor cells in Cases 3 and 5 showed a nuclear expression of MDM2, but in none of the analyzed cases, an amplification of *MDM2* and *CDK4* has been detected by FISH analysis.

Interestingly, we found a deletion of material of the long arm of chromosome 13 by using an Rb-1 FISH probe in all analyzed cases. This *Rb-1* deletion is a characteristic finding in spindle cell lipoma and seen in the majority of analyzed cases. Further changes in spindle cell lipomas include loss of 16q13, 6p23, 6q15-21, 10p15, 10q23, and 17p13.[7] Spindle cell lipoma has been first described by Enzinger in 1975 and arises predominantly as an encapsulated subcutaneous neoplasm in the neck, shoulder, or upper back of elderly male patients.[8] However, superficially located, purely dermal cases show a wider anatomic distribution and affect female patients more frequently.[9] Spindle cell lipoma is composed of mature lipogenic cells

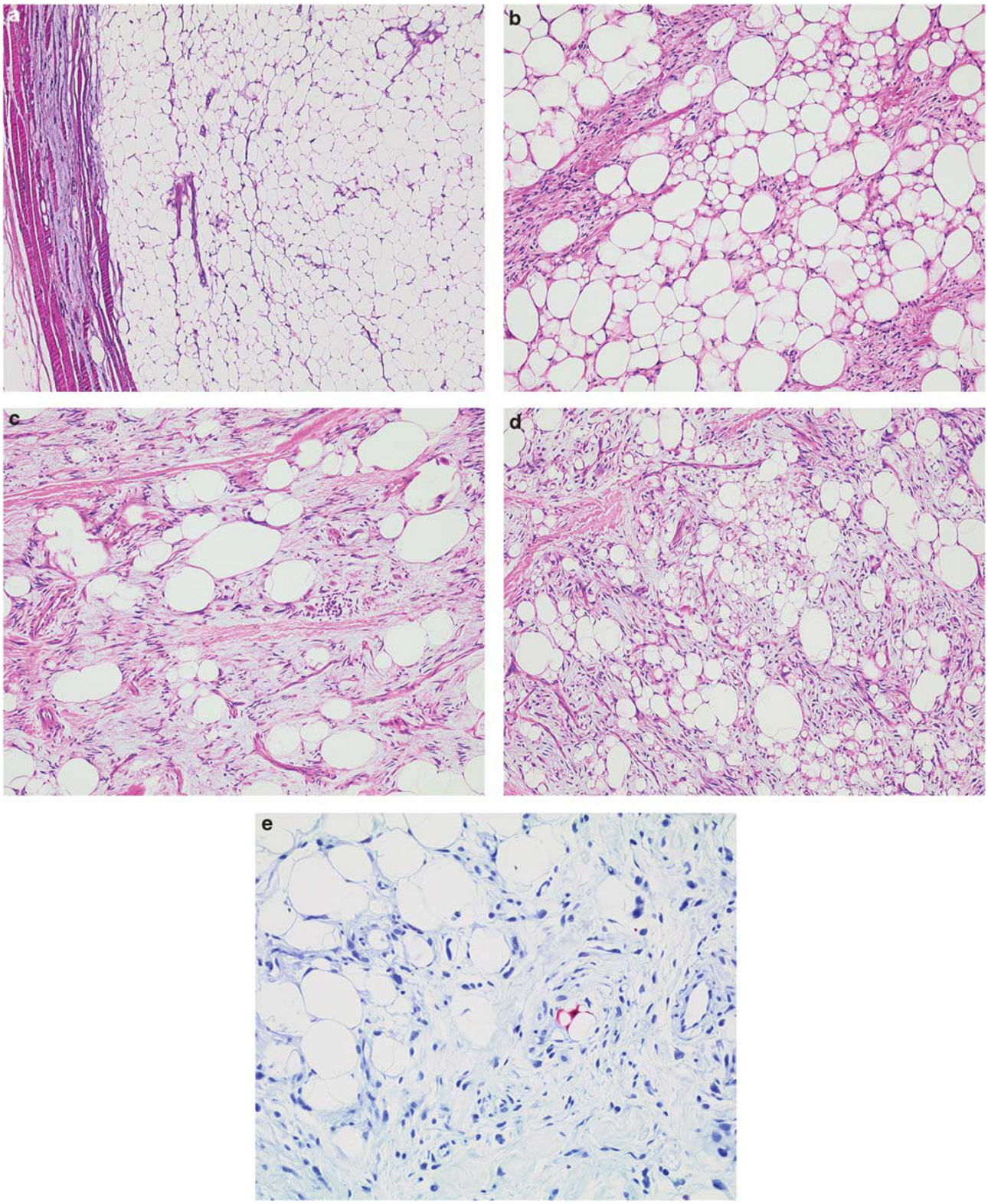

Figure 1 A deep-seated lipogenic neoplasm extending to the skeletal muscle is seen in Case 6 (**a**). Higher power view shows atypical lipogenic tumor cells with striking variations in size and shape, scattered enlarged and hyperchromatic nuclei, vacuolated lipoblasts, and associated spindled tumor cells (**b**). Lipogenic tumor cells with variations in size and shape that are associated with spindled tumor cells containing slightly enlarged and hyperchromatic nuclei are seen in Case 4. Note elongated collagenous fibers (**c**). Focally, lipoblasts associated with spindled tumor cells are noted in Case 5 (**d**). S-100 immunohistochemical antibodies help to highlight scattered lipoblasts in Case 3 (**e**).

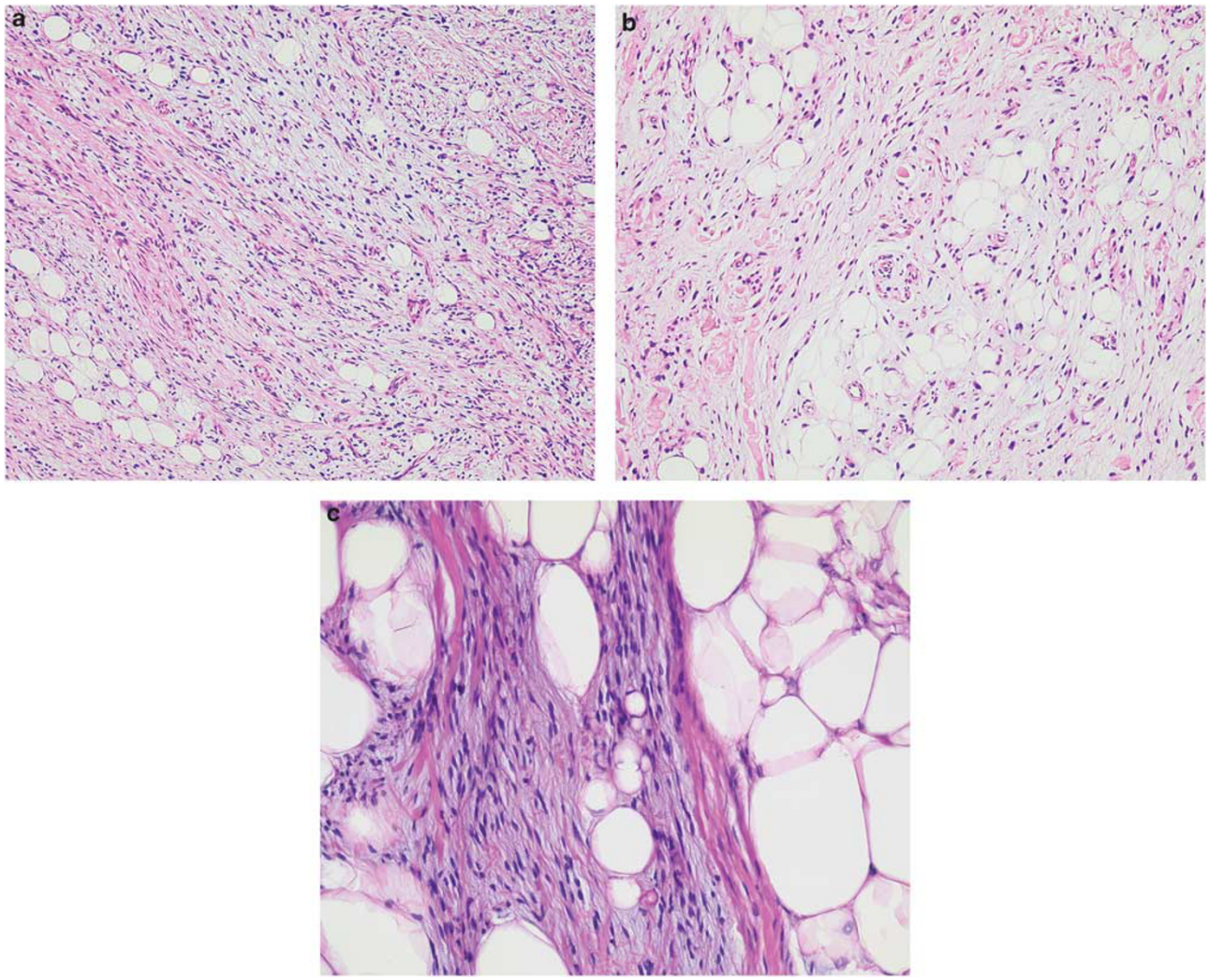

Figure 2 Numerous spindled tumor cells containing hyperchromatic nuclei are irregularly admixed with lipogenic tumor cells. The stroma shows focal myxoid changes (Case 1) (**a**). Spindled tumor cells have an ill-defined, pale eosinophilic cytoplasm and slightly enlarged, hyperchromatic nuclei (Case 3) (**b**). Vacuolated lipoblastic cells are associated with spindled tumor cells containing elongated spindled nuclei in Case 6 (**c**).

Table 2 Immunohistochemical and molecular findings in six cases of well-differentiated spindle cell liposarcoma

Case no.	*CD34*	*MDM2*	*CDK4*	*FISH-MDM2*	*FISH-CDK4*	*FISH-Rb1*
1	−/+	−	−	NAMP	NAMP	D in 35/40 nuclei
2	+	−	−	NA	NAMP	D in 41/52 nuclei
3	+	Few cells +	−	NAMP	NAMP	D in 19/52 nuclei
4	+	−	−	NA	NAMP	D in 11/46 nuclei
5	+	Few cells +	−	NAMP	NAMP	D in 14/36 nuclei
6	+	−	−	NAMP	NANP	D in 34/49 nuclei

NA, data not available; NAMP, no amplification; D, deletion in out of nuclei counted.

associated with a varying number of bland, CD34 positive spindled cells that are set in a collagenous stroma with characteristic ropy-like collagen bundles, and often associated mast cells are seen. A coexpression of desmin by spindled cells has been reported rarely.[10] Rare morphologic variants include pseudoangiomatous spindle cell lipoma,[11] intramuscular spindle cell lipoma,[12] 'low-fat' or 'fat-free' spindle cell lipoma,[13] and multicentric spindle cell lipoma.[14] Comparable as well as identical clinical, immunohistochemical, and cytogenetic findings confirmed that spindle cell lipoma and pleomorphic lipoma belong to a spectrum of a single clinicopathologic entity.

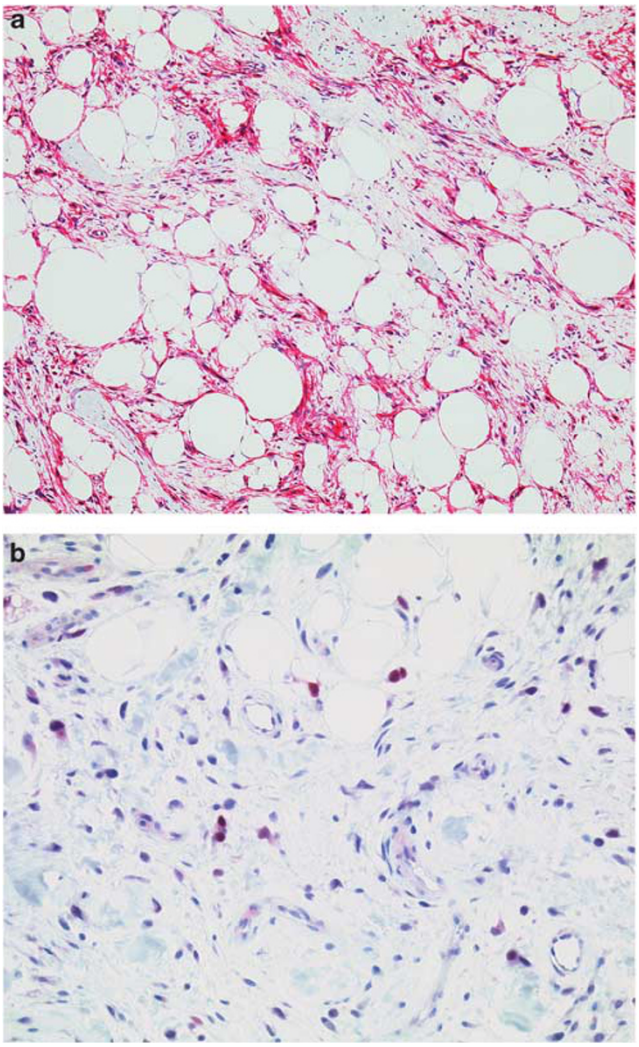

Figure 3 Spindled tumor cells in Case 5 stain positively for CD 34 (**a**). Scattered tumor cells show a nuclear expression of MDM2 in Case 3 (**b**).

The six neoplasms enclosed in the reported series showed considerable clinicopathologic differences to classical spindle cell lipoma. They were characterized by a broader anatomic distribution (two neoplasms arose on the lower extremities and one each on the back of the hand and in paratesticular location), three neoplasms were larger than 9 cm in largest diameter, and one neoplasm recurred locally. In addition, none of the neoplasms was completely encapsulated. Histologically, the neoplasms were composed of atypical lipogenic cells showing striking variations in size and shape and contained scattered enlarged and hyperchromatic nuclei. In addition, the associated spindled tumor cells contained slightly enlarged and hyperchromatic nuclei. Although lipoblasts or lipoblast-like cells may be seen very rarely in spindle cell and pleomorphic lipoma as well, the presence of mono- and multivacuolated lipoblasts with enlarged and hyperchromatic nuclei, as it has been seen in three of our cases, is more in keeping with the diagnosis of well-differentiated spindle cell liposarcoma.

The reported[6] and discussed findings strongly suggest that well-differentiated spindle cell liposarcoma does not belong to the morphological spectrum of atypical lipomatous tumor, and that different genetic changes are involved in these neoplasms. On the other hand, dedifferentiated liposarcoma may show rarely a diffuse transition from the atypical lipomatous tumor component to a non-lipogenic sarcomatous tissue that may show a low-grade, spindle cell, fibroblastic morphology,[15] and has to be distinguished from well-differentiated spindle cell liposarcoma. However, well-differentiated spindle cell liposarcoma represents an atypical lipogenic neoplasm containing slightly atypical spindled cells, and both cell types do not show an amplification of *MDM2* and/or *CDK4*,

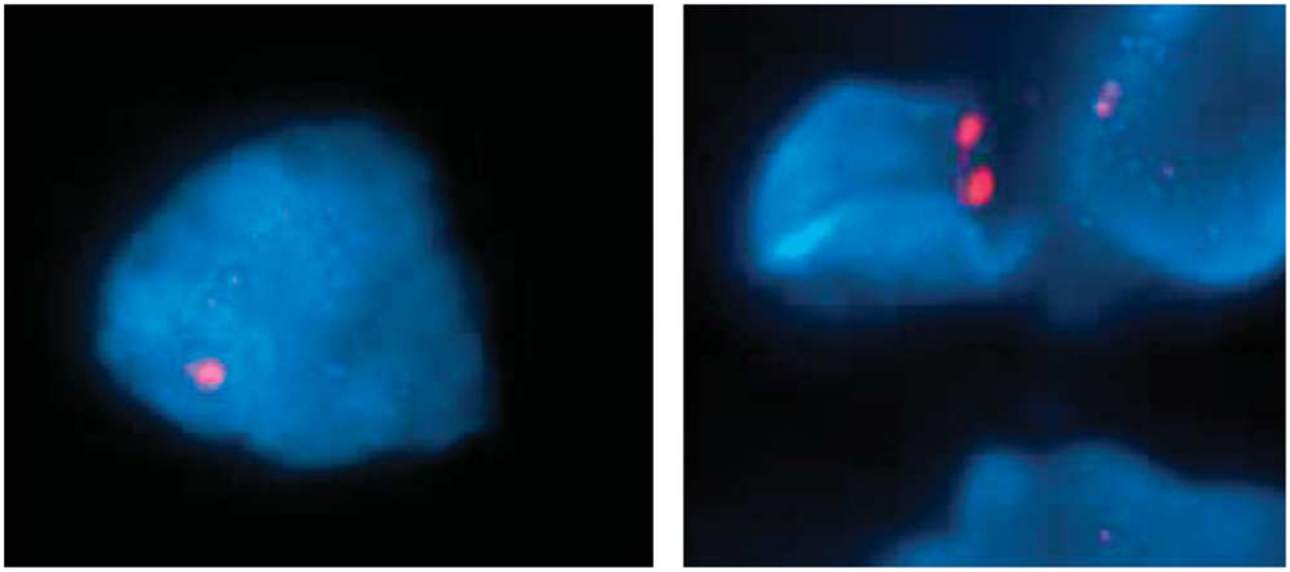

Figure 4 FISH analysis shows deletion of the *Rb-1* gene in Case 3 (left), whereas two signals are present in the control (right).

which is in striking contrast to cases of dedifferentiated liposarcoma. In addition, cases of low-grade dedifferentiated liposarcoma have a significant metastatic potential (15–20%), and it has been shown convincingly that the amount and the morphological grade of the non-lipogenic component in dedifferentiated liposarcoma has no prognostic significance.[15] Rarely, cases of myxoid liposarcoma may contain spindled tumor cells ('spindle cell myxoid liposarcoma'); however, the reported cases of 'spindle cell myxoid liposarcoma' arose predominantly in young patients, contained characteristic thin-walled, branching vessels, and were characterized by different molecular findings.[16]

Given the similarities of clinical, histologic, immunohistochemical, and molecular findings in spindle cell lipoma and well-differentiated spindle cell liposarcoma, it can be speculated that well-differentiated spindle cell liposarcoma represents the atypical/low-grade counterpart of spindle cell lipoma, that the *Rb-1* deletion represents an early event in the development of both neoplasms, and that additional genetic changes are necessary for the development of well-differentiated spindle cell liposarcoma. Another hypothesis is the transformation of a preexisting spindle cell lipoma to a well-differentiated spindle cell liposarcoma, and in some cases of well-differentiated spindle cell liposarcoma, a recent enlargement of a long-standing neoplasm has been reported.[3] In striking contrast to epithelial neoplasms, a malignant transformation of a preexisting benign mesenchymal neoplasm has been questioned for a long time with the exception of the transformation of a neurofibroma to a malignant peripheral nerve sheath tumor in the setting of a neurofibromatosis. However, it has been shown nicely that a biologic continuum of benign, atypical, and malignant lipogenic neoplasms exists,[17,18] and probably some cases of well-differentiated spindle cell liposarcoma arise in a long-standing spindle cell lipoma similarly to cases of malignant peripheral nerve sheath tumors arising in preexisting neurofibromas; however, this hypothesis has to be substantiated in further studies.

In summary, the reported findings emphasize that well-differentiated spindle cell liposarcoma most likely represents an independent entity rather than a morphologic variant of atypical lipomatous tumor/well-differentiated liposarcoma, and may represent the atypical/low-grade counterpart of spindle cell lipoma. Further studies of more cases with longer follow-up are necessary to confirm this hypothesis and to detect additional cytogenetic changes responsible for the development or progression to an infiltrative, locally aggressive lipogenic neoplasm with an increased risk for local recurrence, and a minimal risk undergoing dedifferentiation to a lipogenic neoplasm with metastatic potential.

Acknowledgements

We are very grateful to the following pathologists for providing case material and follow-up informations: Dr A Schneider, Jena, Germany (Case 1), Prof. Dr J Rüschoff and Dr W Meyer, Kassel, Germany (Case 2), Dr J Schneider, Mönchengladbach, Germany (Case 3), Dr U Oehler, Singen, Germany (Case 4), and Dr WJ Hofmann, Memmingen, Germany (Case 5).

Disclosure/conflict of interest

The authors declare no conflict of interest.

References

1 World Health Organization Classification of Tumours. Pathology and genetics. In: Fletcher CDM, Unni KK, Mertens F (eds). Tumours of Soft Tissue and Bone. IARC Press: Lyon, 2002.
2 Rosai J, Akerman M, Dal Cin P, *et al.* Combined morphologic and karyotypic study of 59 atypical lipomatous tumors. Evaluation of their relationship and differential diagnosis with other adipose tissue tumors (a report from the CHAMP study group). Am J Surg Pathol 1996;20:1182–1189.
3 Dei Tos AP, Mentzel T, Newman PL, *et al.* Spindle cell liposarcoma, a hitherto unrecognized variant of liposarcoma. Analysis of six cases. Am J Surg Pathol 1994;18:913–921.
4 Nascimento AF, McMenamin ME, Fletcher CDM. Liposarcoma/atypical lipomatous tumors of the oral cavity: a clinicopathologic study of 23 cases. Ann Diagn Pathol 2002;6:83–93.
5 Nascimento AF, Fletcher CDM. Spindle cell liposarcoma/atypical lipomatous tumor. A clinicopathologic study of 120 cases. Mod Pathol 2005;18:70A.
6 Italiano A, Chambonniere ML, Attias R, *et al.* Monosomy 7 and absence of 12q amplification in two cases of spindle cell liposarcomas. Cancer Genet Cytogenet 2008;15:99–104.
7 Dal Cin P, Sciot R, Polito P, *et al.* Lesions of 13q may occur independently of deletion of 16q in spindle cell/pleomorphic lipomas. Histopathology 1997;31:222–225.
8 Enzinger FM, Harvey DA. Spindle cell lipoma. Cancer 1975;36:1852–1859.
9 French CA, Mentzel T, Kutzner H, *et al.* Intradermal spindle cell/pleomorphic lipoma: a distinct subset. Am J Dermatopathol 2000;22:496–502.
10 Tardio JC, Aramburu JA, Santonja C. Desmin expression in spindle cell lipomas: a potential diagnostic pitfall. Virchows Arch 2004;445:354–358.
11 Hawley IC, Krausz T, Evans DJ, *et al.* Spindle cell lipoma—a pseudoangiomatous variant. Histopathology 1994;24:565–569.
12 Horiuchi K, Yabe H, Nishimoto K, *et al.* Intramuscular spindle cell lipoma: case report and review of the literature. Pathol Int 2001;51:301–304.
13 Billings SD, Folpe AL. Diagnostically challenging spindle cell lipomas: a report of 34 'low-fat' and 'fat-free' variants. Am J Dermatopathol 2007;29:437–442.

14 Fanburg-Smith JC, Devaney KO, Miettinen M, *et al.* Multiple spindle cell lipomas: a report of 7 familial and 11 nonfamilial cases. Am J Surg Pathol 1998;22:40–48.
15 Henricks WH, Chu YC, Goldblum JR, *et al.* Dedifferentiated liposarcoma: a clinicopathological analysis of 155 cases with a proposal for an expanded definition of dedifferentiation. Am J Surg Pathol 1997;21:271–281.
16 Alaggio R, Coffin CM, Weiss SW, *et al.* Liposarcomas in young patients: a study of 82 cases occurring in patients younger than 22 years of age. Am J Surg Pathol 2009;33:645–658.
17 Dei Tos AP, Doglioni C, Piccinin S, *et al.* Coordinated expression and amplification of the MDM2, CDK, and HMGI-C genes in atypical lipomatous tumours. J Pathol 2000;190:531–536.
18 Mentzel T. Biological continuum of benign, atypical, and malignant mesenchymal neoplasms—does it exist? J Pathol 2000;190:523–525.