

Ophthalmic

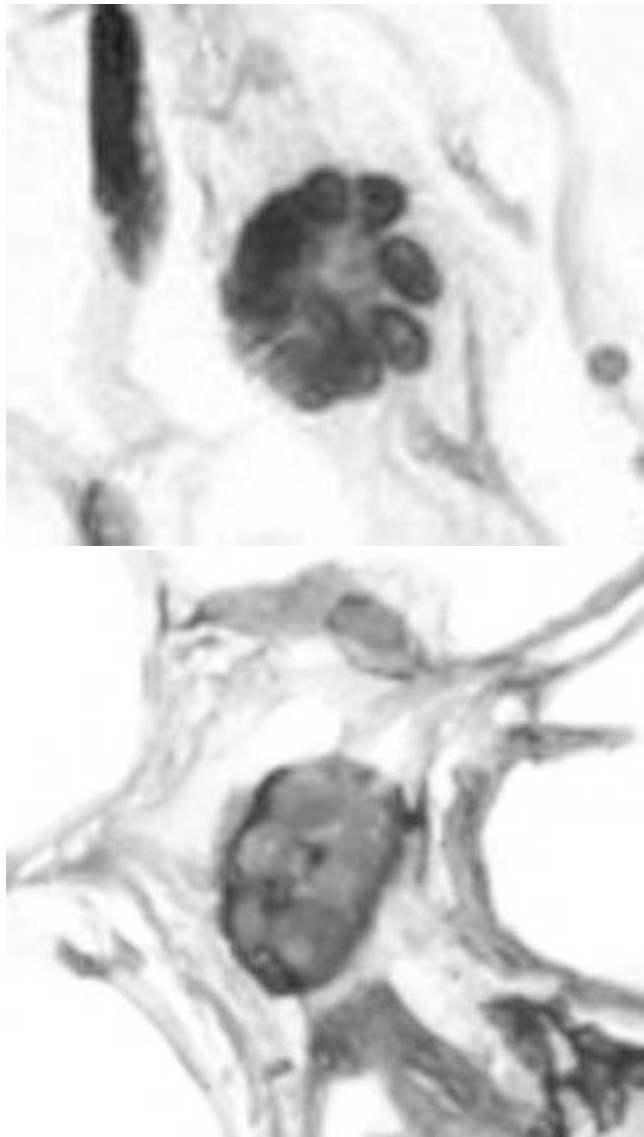
1521 Floret Cells in Lipomatous Lesions of Orbit

HZ Amer, NM Mirani. UMDNJ-NJMS, Newark, NJ.

Background: Lipomatous lesions of the orbit include pleomorphic lipoma (PL) and subconjunctival prolapsed fat (SPF). These lesions consist of mature fat and multinucleated giant cells with a floret-like pattern, which are CD34 +, S-100 -, and CD68 -. It has been reported that floret cells in SPF are an age related degenerative process. In this study we assess the presence of floret cells and dense collagen in orbital PL and SPF.

Design: We identified 18 lipomatous orbital lesions from 1990 to 2008. 8 were clinically called "orbital mass" and diagnosed as lipoma, however upon further inquiry were confirmed to be SPF. 10 were diagnosed as PL based on clinical and morphological ground. All 18 cases were assessed for the presence of floret cells and collagen. CD34, S-100, and CD68 was performed on 17 of 18 cases (1 case of SPF was excluded in absence of floret cells).

Results: In our study, both SPF and PL affected males more than females (14/18, 77%), non-whites more than whites (11/13, 84.6%), and mainly occurred over the age of 55 (14/18, 77%). The majority of lesions measured 1-2 cm (15/18, 83%). 7 of 8 SPF cases had infrequent floret cells (>15 in 2/7, 28.5%). 3 of 8 cases showed dense collagen. All floret cells stained for CD34.



All 10 cases of PL had numerous floret cells (>15 floret cells in 6/10, 60%), that stained for CD34, and dense collagen was seen in 8 of 10 cases. The mature adipocytes stained for S-100, and CD68 stained histiocytes.

	N	Results	
		DENSE COLLAGEN	>15 FLORET CELLS
PL	10	8/10	6/10
SPF	8	3/8	2/7
TOTAL	18	11/18	8/17

Conclusions: In our study SPF and PL is mainly seen in non-white males over the age of 55, and measure 1-2 cm. Floret cells and dense collagen, features suggestive of PL, can also be seen in SPF, but are relatively less numerous. Floret cells and dense collagen are therefore not pathognomonic for PL but rather reflect a degenerative process. Floret cells of these lesions stain for CD34, and do not stain for CD68 or S-100.

1522 Utility of E-Cadherin and ProEx C Immunohistochemistry in the Differential Diagnosis of Benign and Malignant Eccrine Lesions

H Ashby-Richardson, PA Phadke, A Shephard-Barry, NM Laver. Tufts Medical Center, Boston, MA.

Background: Endocrine mucin-producing sweat gland carcinoma (EMPSGC) is a rare, eccrine neoplasm with a predilection for the eyelid of elderly females. The frequent coexistence of EMPSGC with benign eccrine ducts as well as invasive carcinoma, suggests it is a part of a multistage progression from benign eccrine ducts to invasive carcinoma. This study explores two molecules, E-cadherin and ProEx C, which have been linked in tumor progression. E-cadherin, a transmembrane glycoprotein, has a critical role in calcium-dependent cell-cell adhesion in epithelial tissues and is vital to the formation and maintenance of an epithelial monolayer. Loss or aberrant expression of E-cadherin has been associated with tumor invasion and metastatic potential in a variety of human cancers. Additionally, re-expression of E-cadherin in highly tumorigenic human cancer cell lines confers a less invasive phenotype. ProEx C is an antibody reagent that detects minichromosome maintenance (MCM) and topoisomerase II alpha (TOP2A) proteins, both of which play an important regulatory role in eukaryotic DNA replication and have been shown to be over-expressed in a number of different dysplastic and malignant tissues.

Design: 3 cases of eccrine hidrocystoma, 4 cases of EMPSGC and 3 cases of eccrine carcinoma were studied. Immunohistochemical staining for E-cadherin and ProEx C was performed on formalin-fixed paraffin-embedded tissue. Expression of E-cadherin was deemed positive if diffuse, complete membrane staining and negative if absent or incomplete membrane staining was observed. In addition, the intensity of staining was graded from 0 to 3+. Cases were evaluated for expression of ProEx C based on the percentage of tumor cells showing nuclear staining.

Results: The results are listed in Table 1.

	E-Cadherin Expression	ProEx C Expression
Eccrine Hidrocystoma (n=3)	3+	<1%
EMPSGC (n=4)	2-3+	5-20%
Eccrine Carcinoma (n=3)	0	>35%

Conclusions: The decreased E-cadherin and increased ProEx C expression in EMPSGC and eccrine carcinoma as compared to benign eccrine hidrocystomas further support the hypothesis that this tumor is part of a multistage progression from benign eccrine lesions to invasive carcinoma. Immunostaining with these two molecules may aid in distinguishing benign from malignant eccrine lesions.

1523 The Spectrum of Ophthalmic Pathologic Manifestations of the Histiocytoses

AM Bartlett, CT Welsh, A Duong. Medical University of South Carolina, Charleston, SC.

Background: Ophthalmic involvement by the histiocytoses most commonly include Langerhans cell histiocytosis (LCH) and non-LCH proliferations such as juvenile xanthogranuloma (JXG) and extranodal Rosai-Dorfman disease (RDD). There are many parallels between these histiocytic lesions other than just the obvious overlaps in histology. Many of the cranial lesions in all three diseases will be solitary and will regress. All may affect skin and soft tissue. Cranial lesions in both LCH and RDD are frequently associated with bone. The differential diagnosis for all three includes many other inflammatory, reactive, and neoplastic lesions. They may be distinguished from each other by their immunohistochemical (IHC) staining patterns. All three have the potential for more widespread involvement which may require more than the minimal intervention typical for these cranial lesions, and the patterns of involvement vary among them, so the specific diagnosis will lead to the correct clinical investigation.

Design: Cases during the years 1995-2008 were searched for histiocytic lesions confined to the orbit/periorbit. The clinical aspects and histologic as well as immunohistochemical features that distinguished among the different types of histiocytoses were evaluated.

Results: Sixteen cases of orbital/periorbital histiocytoses were reviewed. There were six patients with LCH, six with JXG, two with RDD, and two patients with granuloma annulare. The age range was from 4 to 47 years. The granuloma annulare and JXG cases involved only skin. The LCH involved skin and bone. The patients in all three cases of RDD were female, African-American, and demonstrated entirely extranodal disease with multifocal and/or penetrating bone involvement.

Conclusions: Solitary bone lesions in LCH may be simply curetted out and rarely recur. JXG usually regresses spontaneously. Extranodal RDD may be seen in addition to nodal disease, or less often (as in our cases) is exclusively extranodal. There is controversy in the literature regarding cranial cases of RDD as to whether they are considered "high risk, which we will discuss. While the literature suggests that LCH in the orbit is rare in adults, our six cases include two adults, which will expand the clinical spectrum. Clinical decision-making regarding treatment, followup and the value of staging require biopsy of these lesions. We will discuss the morphologic and immunohistochemical differentiation between these entities, and development of a definitive diagnosis.

1524 Activation of AMPK by AICAR Inhibits Palmitate-Induced Increases in Ceramide Mass, Endoplasmic Reticulum (ER) Stress, NF-kappaB, and Apoptosis in Cultured Bovine Retinal Pericytes (BRPC)

JM Cacicado, E Chou, NB Ruderman, Y Ido. Boston University School of Medicine, Boston, MA.

Background: We have previously shown that moderately high levels of the saturated fatty acid palmitate, but not the monounsaturated fatty acid oleate, induces apoptosis in cultured bovine retinal pericytes. An important observation as high levels of saturated fatty acids, in addition to high sugar, may be a causal factor leading to retinal pericyte loss, the hallmark of diabetic retinopathy (DR). In developed countries worldwide, DR is one of the leading causes of blindness to which there is no current preventative therapy. Finding a way to prevent, inhibit, or improve DR is therefore a worthy aim.

Design: Retinal pericytes were cultured from bovine retinas. These cultured cells were greater than 95% pure and only used from passages 3-6. Both palmitate and oleate were conjugated with bovine serum albumin at a 2:1 molar ratio. The cells were incubated in DMEM media with the indicated fatty acid and/or chemical agent for 24 hr and then tested for accumulation of ceramide mass, ER stress markers, NF-kappa B activity, and apoptosis (TUNEL and caspase assays).

Results: We discovered that activation of the stress activated kinase, AMP-activated protein kinase (AMPK), by the cell permeable AMPK activator AICAR (5-amino-4-imidazolecarboxamide riboside) or use of a constitutively active AMPK can prevent retinal pericytes from undergoing palmitate-induced cell death. Though the exact mechanism of palmitate-induced apoptosis is not currently known, we found that it may be brought on by several processes that cause cell death in the context of diabetes. We found that 1) ceramide mass was increased dose dependently by palmitate; 2) ER stress was upregulated as witnessed by a 2-4-fold increase in the ER stress markers BiP and CHOP at both the mRNA and protein levels; 3) NF-kappaB activity was increased as measured by reporter gene assay; and 4) that inhibition of any one of these processes was sufficient to rescue the BRPC from palmitate-induced cell death.

Conclusions: Activation of AMPK with AICAR was able to prevent all the processes studied herein, including apoptosis itself, therefore providing a potential therapeutic option for improving vascular homeostasis in diabetic retinopathy.

1525 Hypermethylation of the *p16^{INK4a}* Gene Promoter Seems To Be a Frequent Epigenetic Change in the Eyelid Sebaceous Carcinoma

K-C Chen, H-C Chang, S-L Liao, C-H Hsiao, C-H Lin, L-T Kuo, Y-T Lin, M-C Lin, K-T Kuo. National Taiwan University Hospital, Taipei, Taiwan; Taipei Hospital, Department of Health, Taipei County, Taiwan.

Background: Eyelid sebaceous carcinoma is an ocular malignancy with possible life-threatening consequences. Some Asian reports suggest that the human papillomavirus (HPV) may play a role in the development of this malignancy by disrupting the function of *p53*. Overexpression of *p16^{INK4a}*, which is also associated with the HPV's oncogenic mechanism, has also been reported in cases of eyelid sebaceous carcinoma. The authors wish to explore the molecular and epigenetic basis of HPV and the *p16^{INK4a}* status in the development of eyelid sebaceous carcinoma.

Design: Twenty-four cases of eyelid sebaceous carcinoma were analysed for the expression of *p16^{INK4a}* via immunohistochemistry. Nested polymerase chain reaction (PCR) and genechip HPV typing were used to detect HPV infection and decide its genotype in our samples. The methylation status of *p16^{INK4a}* promoter region was studied by methylation-specific PCR.

Results: HPV-positivity was demonstrated in only one of our cases, while another case was immunoreactive for *p16^{INK4a}*. *P16^{INK4a}* promoter hypermethylation was noted in nearly half of our cases (11/24) and was also associated with younger patient age ($p=0.013$).

Conclusions: Higher frequency of *p16^{INK4a}* promoter hypermethylation in eyelid sebaceous carcinoma may imply a significant epigenetic role in tumor development, more so than the presence of HPV.

1526 Pathological Review of 50 Intraorbital Meningiomas Using WHO 2007 Criteria

D Jain, CG Eberhart. Johns Hopkins Medical Institutions, Baltimore, MD.

Background: Meningiomas represent 2 to 4% of all intraorbital tumors. In clinical series, they are approximately equally divided between those arising from the optic nerve, and those extending into the orbit from adjacent structures, usually the sphenoid wing. Although the grading and subclassification of intracranial meningiomas has been relatively well studied, no large series of intraorbital meningioma has been reported using the grading scheme introduced by the WHO in 2000. Herein, we describe the histopathologic features and WHO grades of 50 intraorbital meningiomas.

Design: Intraorbital meningiomas diagnosed between 1968 and 2008 were retrieved from the archives of the Neuropathology and Eye Pathology Laboratories at our institution. Clinical data were also retrieved from the hospital archives, including patient age, sex, and intraorbital location of the tumor. Hematoxylin and eosin stained slides from all cases were reviewed according to the WHO 2007 classification scheme.

Results: A total of 50 intraorbital meningiomas were reviewed. The mean age at presentation was 45 years (range, 8 to 96 years), and four tumors arose in children, ages 8 to 15 years. Two patients were known to have neurofibromatosis type 2 (NF2). Intraorbital meningiomas were more frequently encountered in females (30 cases) than in males (20 cases). In 21 patients (13 females, 8 males), the tumor was associated with the optic nerve. In the remaining 29, the optic nerve was not known to be involved. The most common histopathologic subtype (28/50 tumors, 56%) was meningothelial. An additional 20 tumors (40%) were classified as transitional, and 2 (4%) were predominantly angiomatous. Focal microcystic change was present in 2 tumors. Most of the tumors (46/50, 92%) were WHO grade I, with less than 4 mitotic figures per 10 high power fields (hpf). Four tumors (8%) were WHO grade II (2 males and 2 females), with more than 4 mitotic figures per 10 hpf. One of these grade II tumors also exhibited brain invasion, and a second showed optic nerve invasion. Invasion of either dura, bone, muscle, orbital fat, lacrimal gland, choroid or sclera was observed in 19 cases.

Conclusions: In our series, intraorbital meningiomas were most frequently of the meningothelial or transitional subtypes, and WHO grade I. One relatively common intracranial subtype, fibrous meningioma, was not encountered. The percentage of WHO grade II tumors in the orbit (8%) is similar to that reported for intracranial tumors using the current grading scheme.

1527 Identification of IgG4 Positive Plasma Cells in Recurrent Idiopathic Orbital Inflammation but Not in Non-Recurrent Lesions

GR Kolar, GJ Harocopos, ME Smith, SK El Mofly. Washington University School of Medicine, St. Louis, MO.

Background: Idiopathic orbital inflammation (IOI) (inflammatory pseudotumor) is a rare entity that consists of chronic inflammatory cells with myofibroblasts in variable proportions that results in a variety of ocular manifestations including decreased and even loss of vision. IOI is typically steroid responsive but some require surgery. Recurrence is common; however, specific histopathologic features predictive of recurrence have not yet been identified. IgG4+ plasma cells have been detected in IOI and in some pseudotumors in various other locations, and high serum levels of IgG4 are associated with systemic syndromes. The purpose of this investigation was to evaluate the prevalence of IgG4 positive plasma cells in IOI and to identify its clinical significance.

Design: 25 cases diagnosed as IOI or orbital inflammatory pseudotumor from 1988 to 2008 comprising 16 patients were retrieved from departmental files. Sections were cut and stained with a mouse anti-human monoclonal antibody to IgG4. Normal human tonsils were used as positive control. If any cells with cytoplasmic/plasma membrane reactivity for IgG4 in 10 high powered fields (HPF; 40X) were found, the specimen was considered positive for IgG4. Statistics were performed using a Fisher two tailed t test.

Results: Among the 25 unique biopsies with a histological diagnosis of IOI, 16 (in 10 out of 16 patients) had IgG4+ plasma cells. Of these 10 patients with an IgG4+ biopsy at any time during their series, 6 patients had recurrent lesions (sensitivity=100%, specificity=60%, $p=0.03$). None of the IgG4 negative cases recurred (negative predictive value (NPV)=1, $p=0.03$, 95% CI= 0.52 to 1). A positive predictive value of 0.73 was obtained when the threshold was raised to ≥ 20 IgG4+ cells/10 HPF ($p=0.04$). Only one patient with recurrent IOI presented with an IgG4 negative biopsy on the first specimen (sensitivity=83%, specificity=60%, NPV=0.86, $p=0.15$).

Conclusions: The absence of IgG4+ plasma cells is a strong predictor of the lack of future recurrence of IOI requiring surgical treatment. This finding may have potential implications for clinical diagnostics and pathophysiology of IOI.

1528 Autotaxin Expression in Ocular Tissues and Uveal Melanoma

L Schoenfield, A Singh. Cleveland Clinic Foundation, Cleveland, OH.

Background: Uveal melanoma is the most common primary intraocular malignancy. In spite of advancements in diagnosis and treatment, mortality rates have not improved. Efforts to stratify patients for possible systemic treatment have looked at various histopathologic and molecular features, including monosomy 3. Microarray gene profiling has revealed two classes: class 1 (low grade) and class 2 (high grade), the latter more predictive of liver metastasis. In a recent study, gene expression profiling also demonstrated that overexpression of an enzyme called autotaxin could predict the class 2 tumors. It has been found to be upregulated in some other malignancies, such as breast and prostate carcinoma. Autotaxin expression in the eye and in particular in uveal melanoma has not previously been described.

Design: This study undertook to assess the staining patterns of this enzyme by immunoperoxidase in 15 eyes with uveal melanomas treated by enucleation. Stains were performed alone (12 cases) or as a double stain with a macrophage marker (CD68) along with autotaxin (3 cases). The results were correlated with FISH results for monosomy 3 (available in 14 of the 15 cases).

Results: Positive staining for autotaxin (positive control: prostatic adenocarcinoma) consisted of a cytoplasmic blush and/or punctate cytoplasmic granules. Strong positivity was found uniformly in all layers of the retina in all 15 eyes. The non-pigmented ciliary epithelial cells, retinal pigment epithelial cells, corneal epithelium and smooth muscle of the ciliary body were also variably positive. The corneal stroma and sclera were uniformly negative. Of the 15 cases of uveal melanoma, 3 were completely negative (0% of cells) for autotaxin. In another case, there was scant staining (5% of cells). Of these 4 cases, 3 showed monosomy 3 by FISH (no FISH results for fourth). In 11 cases, there was staining for autotaxin in variably 10% to 100% of cells. Of these 11 cases, only 3 had monosomy 3. Staining was variable within the tumors, presumably due to variable fixation.

Conclusions: 1) Autotaxin is overexpressed in some malignancies but appears to be downregulated in uveal melanomas. 2) Immunoperoxidase staining for autotaxin may offer an economical way to stratify patients for aggressive treatment in an effort to prevent liver metastasis. 3) Additional work is needed to further classify the patterns of staining of this antibody, as experience is so far limited.

Pathobiology

1529 Cancer-Promoting and Initiating Stem Cells Can Be Derived from Ectopic Locations in Breast Cancer

SH Barsky, Y Xiao, Y Ye, K Yearsley. The Ohio State University College of Medicine, Columbus, OH.

Background: Although human breast cancer is all too common, circumstantial evidence exists to suggest that cancer transformation is a rare event. Even in the setting of inherited breast cancer, eg. BRCA1 when all the cells of the breast contain the inherited BRCA1 mutations, transformation on a cellular level is still rare. This suggests that only certain cells are capable of cancer initiation and promotion. Cancer-promoting and cancer-initiating stem cells, while mainly residing in the organ of cancer origin, can also be derived from ectopic locations. In a previous study of human transplant recipients who had received sex-mismatched bone marrow and other organ transplants for various diseases and later developed secondary solid cancers including breast cancer, cancer-promoting stem cells of donor origin giving rise to lymphocytes, fibroblasts,