

**325 Increased Histopathology in Marfan Syndrome Compared to Loays-Dietz Syndrome and Non-Syndromic Aortas**

Kevin Waters, Andrew Guajardo, Marc Halushka. Johns Hopkins University SOM, Baltimore, MD.

**Background:** In 2016, the Society for Cardiovascular Pathology (SCVP) and the Association for European Cardiovascular Pathology (AECVP) developed a new set of nomenclature and definitions for histopathology of the ascending aorta. We specifically investigated Marfan Syndrome (MS), Loays-Dietz Syndrome (LDS) and non-syndromic aortas to see how our understanding of these diseases is impacted by these new criteria. **Design:** Aortic specimens from patients with MS (n=39), LDS (n=21), and non-syndromic patients (n=53) were selected from our surgical archives along with basic phenotypic information. Each case was independently scored by 2+ observers in a blinded fashion for 13 features using H&E and Movat stained slides. Disagreements were adjudicated by a cardiovascular pathologist. All data was categorized, converted into numbers, tabulated, and analyzed using a Mann Whitney U test.

**Results:** The average age of resection was lower in both MS (30±14) and LDS (20±16) cases than in non-syndromic cases (63±15), but no differences were noted in the sex/ racial distribution of the groups. The total medial degeneration score was higher in MS cases (2.2±0.8 in a 0-3 scale) than in LDS cases (1.7±1, p=4.4x10<sup>-2</sup>) or non-syndromic cases (1.7±0.8, p=2.6x10<sup>-3</sup>). Among patients with MS, the average score for mucoid extracellular matrix accumulation (MEMA) was higher for both extent (3.4±1.7 in a 0-6 scale) and severity (3.2±1.9) than that seen in non-syndromic cases (2.4±1.9 p=3.6x10<sup>-3</sup> and 2.2±1.9 p=3.7x10<sup>-3</sup>, respectively). The average score was not significantly different in patients from non-syndromic cases or from LDS patients for either extent (2.6±1.8) or severity (2.4±1.8). Average elastic fiber loss was pronounced for both extent and severity in both MS (2.2±0.9 and 2.2±1, respectively; 0-3 scale) and LDS (1.7±1.1 and 1.7±1.2) compared to non-syndromic cases (1.0±1.2 and 0.9±1.1; all p values < 0.02). Conversely, the average extent and severity of smooth muscle cell nuclei loss was greater in non-syndromic cases (1.8±1.0 and 1.4±0.7) compared to MS (0.6±0.9 and 0.6±0.8) and LDS (0.5±0.9 and 0.3±0.6; all p values <10<sup>-4</sup>).

**Conclusions:** This is the first evaluation of the new AECVP/SCVP aorta nomenclature and definitions in MS and LDS aortas. We clearly demonstrate that, in general, MS has more significant medial degeneration at the time of surgery compared to LDS or non-syndromic cases. There is also significantly more elastic fiber loss and less smooth muscle cell loss in these syndromic diseases compared to non-syndromic diseases.

**326 Sudden Death in Hypertrophic Cardiomyopathy. Data from a Large Pathology Registry**

Joseph Westaby, Mary N Sheppard. St George's University of London, London, United Kingdom.

**Background:** Hypertrophic cardiomyopathy (HCM) is reported as a common cause of sudden cardiac death (SCD) in young people. Exercise is considered a trigger to fatal arrhythmias and International recommendations advise to avoid competitive sports in individuals with HCM. It is unclear however if SCD occurs more frequently at rest or during exercise in these patients. The aim of the study was to investigate the demographics and circumstances of SCD in a large cohort of HCM patients.

**Design:** Between 1994 and 2014, 184 consecutive cases of HCM patients who died suddenly (mean age 39±17 years, 70% males) were referred to our cardiac pathology centre. All subjects underwent detailed post-mortem evaluation including histological analysis by an expert cardiac pathologist. Clinical information was obtained from referring coroners.

**Results:** Only thirty-seven (20%) patients had an established ante-mortem diagnosis of HCM. Forty (22%) patients exhibited cardiac symptoms (16 palpitations, 11 dyspnoea, 7 syncope and 6 chest pain). Maximal wall thickness was 21.4±6.1 mm with a mean heart weight of 548 ± 197 g. Left ventricular (LV) fibrosis was present in 109 patients (59%). Twenty (11%) patients were recreational or competitive athletes (> 3 hours per week of exercise). Thirty-five patients (19%) died during exertion. Of the 149 patients died at rest, 22 (12%) died during sleep. At multivariate analysis, the predictors of death during exertion were age (for older age HR 0.94 (0.92 to 0.97), p<0.001) and gender (for male gender 3.47 (1.04 to 10.19), p=0.03).

**Conclusions:** Sudden death victims with a diagnosis of HCM were often male, asymptomatic and lacked a diagnosis during life. Sudden death occurred relatively rarely during sport activity. Young age and male gender were the main predictors of death during exercise.

**327 Incidence of Psychiatric Illnesses in Sudden Cardiac Deaths**

Joseph Westaby, Chandroth Navin Pankajakhan, Mary N Sheppard. St George's University of London, London, United Kingdom.

**Background:** A retrospective study of the incidence of psychiatric illnesses among 1613 sudden cardiac death cases referred to the Cardiac Risk in Young Cardiovascular Pathology Unit at St. Georges' University of London between 2013-2016. A total of 170 (10.4%) cases with a psychiatric history were found.

**Design:** The frequency of cases with psychiatric history increased from 13 in 2013, to 56 cases in 2014 and 93 cases in 2015.

**Results:** The majority were males (61%). Highest incidence was found in 30-39 year group (31%). The mean age was 40 years, the median age was 38 years and the mode for age was 35 years. Psychiatric illnesses reported, depression (47%), non-specified (19%), schizophrenia (11%), anxiety (7%), learning difficulties (6%), psychoses (2%) and others (8%). 95% died either at rest or sleep, 4% died during stress including 4 in police custody. Use of psychiatric medication was reported in 47%. Non-toxic levels of drugs were found in 24.7% of cases, alcohol in 30%. The commonest cause of death was sudden adult death syndrome with morphologically normal heart (68%), followed by idiopathic left ventricular hypertrophy (8%), cardiomyopathies (8%), ischaemic heart disease (6%), valvular heart disease (2%), hypertensive heart disease (2%) and other causes (6%).

**Conclusions:** There is disproportionate number of sudden cardiac deaths with psychiatric illnesses and the role of stress and drugs which may effect the electrical activity of the heart must be considered. Medicolegal issues such as death in police custody are important considerations also. Autopsy with detailed cardiac examination is essential in all these cases.

**328 Histopathologic and Immunohistochemical Features of Cardiac Myxoma: Review of 28 Cases at a Cardiac Center in Eight Years**

Ya Xu, Betye Cox, Mary R Schwartz, Alberto Ayala, Jae Ro. Baylor College of Medicine, Houston, TX; Houston Methodist Hospital, Houston, TX.

**Background:** Cardiac myxoma may exhibit focal increased cellularity and lymphoplasmacytic infiltration. The purpose of this study was to analyze the histopathologic features of cardiac myxoma, and to explore the significance of increased cellularity and lymphoplasmacytic infiltration using S-100 and IgG4 immunohistochemical stains.

**Design:** 28 cases of cardiac myxoma were seen over an 8-year period at an academic tertiary referral hospital with a cardiac center. All the cases were reviewed for clinical and histopathological features. Immunohistochemical stains for calretinin, S-100 protein and Ki-67 were performed on 25 cases with paraffin blocks available, and IgG4 on 13 cases with focal intense lymphoplasmacytic infiltrates.

**Results:** The age of 28 patients ranged between 24 and 83 years; 20 were women and eight men. The average tumor size was 4.4 cm (range 2.0-10.0 cm) with the largest tumor in the right ventricle. 25 tumors were located in the left atrium. All of the tumors had characteristic stellate cells in a myxoid background. 11 cases had focal increased cellularity, and 13 had focal intense lymphoplasmacytic infiltrates. A unique histologic feature of a palisading growth pattern was seen in 9 of the 11 cases with increased cellularity. No atypia and only rare mitotic activity (<1/10HPFs) was found. Calretinin was strongly positive in all 25 cases. S-100 was expressed in the cellular areas of 9 cases, most prominently in the tumor cells arranged in a palisading pattern. No S-100 expression was identified in the remainder of the cases. None of the cases had increased Ki-67 proliferative fractions (Ki-67 <5% in all cases). Increased IgG4 expression (> 50% plasma cells stained with IgG4) was seen in 2 of 13 cases with focal intense lymphoplasmacytic infiltrates.

**Conclusions:** Although increased cellularity was seen in 39% of tumors, no increased Ki-67 proliferative fraction was found. Increased IgG4 positive plasma cells were seen in rare cardiac myxomas with focal intense lymphoplasmacytic infiltrates. The significance of increased cellularity with S-100 expression and increased IgG4 expression in tumor pathogenesis, prognosis and therapy remains unclear. Our findings may provide insight for further research work on cardiac myxoma.

**Cytopathology**

**329 Pancreatic Surgical Resections with False-Positive Cytology Results: A Ten-Year Single Institution Retrospective Review**

Daniel W Abbott, Bryan Hunt, Tamar Giorgadze, Kiyoko Oshima. Medical College of Wisconsin, Milwaukee, WI.

**Background:** Pancreatic cytology (PC), including fine needle aspiration (FNA), is an important tool used for the diagnosis of pancreatic lesions and subsequent treatment decisions. This study evaluates the accuracy of PC at a single institution and investigates cases with false positive (FP) malignant PC diagnoses.

**Design:** 726 pancreas surgical resections (SR) at a single institution received between 2006-2016 were retrospectively reviewed, including 425 SR with corresponding PC. PC was compared to SR results and classified based on agreement of the diagnoses. Slides from SR cases with FP PC diagnoses were reviewed by two cytopathologists in a blinded manner.

**Results:** The cases selected for analysis included 227 (53.4%) men and 218 (51.3%) women with a mean age of 64.4 years. The corresponding PC cases included 355 (83.7%) pancreatic FNA, 41 (9.7%) bile duct brushings, 18 (4.2%) combined FNA and bile duct brushings, and 31 (7.3%) cases with an unspecified procedure. PC diagnoses included 322 (75.9%) malignant, 18 (4.2%) suspicious for malignancy, 35 (8.3%) atypical, 35 (8.3%) benign, and 14 (3.3%) with another type of diagnosis. PC results agreed with subsequent SR results in 362 (85.4%) cases. False negative PC results were seen in 46 cases (10.8%) and FP PC results were seen in 11 (2.6%) cases. FP cases included 8 (1.9%) cases with documented complete response to neoadjuvant therapy, leaving 3 (0.7%) PC cases that were true FP and are summarized below:

Age/ Sex	PC diagnosis (procedure)	SR diagnosis	Radiology	Elevated markers	Agree/Disagree with original diagnosis
84/F	Malignant, adenocarcinoma (bile duct brush)	Ductal hyperplasia, cholangitis	Common bile duct filling defect, stone vs. neoplasm	CA19.9	1 Agree 1 Disagree
59/F	Suspicious for malignancy, carcinoma (FNA)	Benign mucinous cystic neoplasm	C/W pancreatic pseudocyst	None	2 Disagree
80/F	Malignant, favor endocrine neoplasm	Lymphoplasmacytic sclerosing pancreatitis	Common bile duct mass, favor cholangiocarcinoma	CA19.9 CA125	2 Disagree

**Conclusions:** FP cytology results were uncommon, with the majority accounted for by complete response following chemotherapy. The discrepancy was resolved in 2 of the 3 cases in which both reviewing cytopathologists agreed that the prior PC result was

overcalled. In 1 of 3 cases there was disagreement among the reviewing cytopathologists as to whether the prior PC was overcalled. These cases highlight potential diagnostic pitfalls that should be considered in the review of PC specimens.

### 330 Follow-Up of Nondiagnostic Thyroid Fine Needle Aspiration: An Institutional Review

Rita Abi Raad, Susan Fernandez, Kevin Schofield, Guoping Cai, Adebowale Adeniran. Yale University School of Medicine, New Haven, CT.

**Background:** Nondiagnostic category in thyroid fine needle aspiration (FNA) is a heterogeneous group and it applies to specimens that are unsatisfactory for a wide variety of reasons. Adequacy criteria have been defined and repeat aspiration with ultrasound guidance is recommended for specimens that fall short of the criteria. Excision is considered for persistently nondiagnostic nodules. The aim of this study was to review our follow-up experience of these nondiagnostic thyroid nodules at a large academic center.

**Design:** We performed a retrospective analysis of patients with nondiagnostic FNA results over a 6-year period (2008-2013). Information including demographics, ultrasound features and FNA diagnosis were recorded. Follow-up information such as repeat FNA diagnosis and surgical follow-up information were also recorded.

**Results:** A total of 1735 nondiagnostic thyroid FNA cases were identified, representing 8.7% of the 19893 thyroid FNA cases evaluated at our institution during the period under review. The most common reason for nondiagnostic aspirate was inadequate cellularity. Repeat aspiration was performed in 30% of cases, yielding diagnostic material in 74% of the cases while 36% remained persistently nondiagnostic. 209 (12%) of the original non-diagnostic cases had surgical resection, 51 of which were found to be malignant. Classic variant of papillary thyroid carcinoma (PTC) accounted for 67% of the malignant cases while follicular variant of PTC accounted for 22%. Median tumor size was 0.9 cm. Lymph node metastasis was identified in 17 cases while extrathyroidal extension was identified in 11 cases. Tumor stage was T1 in the majority of the malignant cases (35/51). Hyperplastic nodules and cystic degeneration accounted for 76% of the benign nodules. The most common reason for surgical intervention in nondiagnostic cases were sonographically worrisome nodules, followed by symptomatic nodules.

**Conclusions:** Our institutional nondiagnostic rate is within the value suggested by the Bethesda system for reporting thyroid cytopathology. The overall malignancy rate is 3% in nondiagnostic cases. Although the overall malignancy rate is low, a nondiagnostic thyroid FNA does not exclude cancer with certainty. Surgical decision should be made in conjunction with clinical and radiologic features.

### 331 Prognostic Assessment of BRAF Mutational Testing in Preoperative Thyroid FNA Specimens

Rita Abi Raad, Susan Fernandez, Pei Hui, Kevin Schofield, Manju L Prasad, Guoping Cai, Adebowale Adeniran. Yale University School of Medicine, New Haven, CT.

**Background:** BRAF mutational testing is a useful adjunct in the evaluation of thyroid nodules for papillary thyroid carcinoma (PTC). It has been suggested that BRAF positivity may be associated with adverse prognostic features such as lymph node metastasis, increased risk of recurrence and resistance to radioiodine treatment. The goal of this study was to assess whether BRAF mutation status could predict the extent of extrathyroidal and lymph node (LN) involvement.

**Design:** A search through the cytology files at our institution from 2009 to 2014 was made for cases with BRAF testing. Cases with follow-up thyroidectomy for papillary thyroid carcinoma (PTC) formed the cohort of this study. Surgical pathology findings were reviewed and correlated with BRAF mutation testing results.

**Results:** A total of 436 cases with corresponding surgical follow-up were identified, including 349 cases of histologically confirmed PTC. Among the PTC cases 168 cases (48%) were BRAF mutated while 181 cases (52%) were BRAF wild type. Of the BRAF mutated cases, central lymph node metastasis was found in 68 (40%), lateral lymph node metastasis in 22 (17%) and extrathyroidal extension in 16 (10%) of cases. Of the BRAF wild type cases, central lymph node metastasis was found in 52 (29%), lateral lymph node metastasis in 18 (10%) and extrathyroidal extension in 8 (4%) of cases.

**Conclusions:** Our study demonstrates that PTC with BRAF mutation has a higher risk of central and lateral lymph node metastasis and extrathyroidal extension, hence preoperative BRAF testing on FNA specimens may be helpful in guiding the initial surgical extent.

### 332 Urovysion® FISH Test, It Is Not for Fishing

Schuharazad Abro, Stefan Pambuccian, Guliz Barkan. Loyola University Medical Center, Maywood, IL.

**Background:** Urovysion® FISH test is used as a tool for further management of patients carrying a diagnosis of atypical urothelial cells (AUC). In our experience and others, the Urovysion® FISH test is plagued by high false positive rate. Although the fraction of such false positive cases are thought to be "anticipatory positive" results, most remain false positive even after long follow up period. The exact cause of false positive is currently unknown. The aim of our study was to investigate if any cytological features correlate with false positive FISH test.

**Design:** Cases with a diagnosis of atypical urothelial cells (AUC) with concurrent FISH diagnosis were identified from January 2008 to December 2014. A 12 month follow-up period from the index was used to determine the performance of the Urovysion® FISH test. This follow-up period was selected to account for "anticipatory" positive results, surgical follow up of the patients were recorded during this time period. A mixed group of true negative (TN) and false positive (FP) diagnosis were randomly selected and each slide was reviewed for following features: inflammation, presence of squamous cells, lubricant, blood or debris. Umbrella cells and intermediate cells were counted in 100 HPF. The reviewer was blinded for any clinical information, diagnosis and outcomes. Unpaired t-test was performed for statistical analysis.

**Results:** From a total of 543 AUC cases with concordant Urovysion FISH testing of 53 UCyto were selected for review. There was no significant difference in inflammation or presence of squamous cells, lubricant, blood and debris in two groups. However, the number of umbrella cells were significantly different in the 2 groups.

		FP (n=26)	TN (n=27)	Significant
FISH test	Aneusomy	11 ±8.6	0.55 ± 0.7	-
	Total cells counted on FISH	177.6 ±213	76 ± 99	-
Cytologic features:	Intermediate/basal cells	513.5 ±529.3	624.4 ±519.5	p=0.102, 95% CI [-943.6, 88.1]
	Number of Umbrella cells	306.3 ±414.11	623.1 ±663.4	p=0.042, 95% CI [-621.5, -13.1]

**Conclusions:** The presence of numerous umbrella cells may contribute to the false positive FISH test. It is therefore suggested that the FISH test should be interpreted within the context of cytology and other diagnostic laboratory results.

### 333 The Diagnostic Concordance Among Cytopathologists Interpreting Urine Cytology Using Paris System Improves with Experience

Schuharazad Abro, Ozlem Fidan-Ozbilgin, Stefan Pambuccian, Guliz Barkan, Eva M Wojcik. Loyola Medical Center, Maywood, IL.

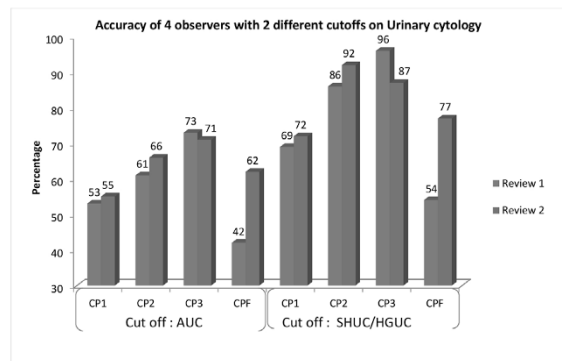
**Background:** The standardized reporting system for urinary cytopathology, the Paris system (TPS) was introduced in 2015 in our institution. The aim of our study was to review the interobserver agreement of the TPS diagnostic categories at the introduction of TPS and 12 months later in clinical practice.

**Design:** 119 random ThinPrep® urine cytology slides from 01/01/2007-04/30/2015 with follow-up histologic diagnosis within 6 months were reviewed by three board-certified cytopathologists (CP) with over 10 years of experience and a cytopathology fellow (CPF). The review was done at the introduction of TPS (R1) and 12 months later (R2). Diagnoses were rendered according to TPS: negative for high grade urothelial carcinoma (HGUC), or NHGUC, atypical urothelial cells (AUC), suspicious for HGUC (SHGUC) and HGUC. The observers were blinded to the reported diagnosis, outcome, their own initial results and results of other observers. Accuracy for predicting urothelial carcinoma using either AUC or SHGUC as a cutoff for positivity, interobserver agreements and intraobserver agreements between R1 and R2 were calculated by kappa statistics.

**Results:** Total 952 (2x4x119) individual diagnoses made by the 4 observers in R1 and R2, the percentage equivocal diagnoses (AUC+SHGUC) decreased from 34% in R1 to 24% in R2. However, there were few 3-way and no 4-way agreements for AUC and SHGUC diagnoses.

# of cases	NHGUC	AUC	SHGUC	HGUC
R1 Range(Median)	48-87 (67.5)	9-41 (30)	7-17 (12)	6-16 (11.5)
R2-Range(Median)	65-84 (76.5)	6-31 (21)	9-11 (8.5)	9-23 (14.3)

The intraobserver Weighted kappa values ranged from 0.34-0.70. All measures of interobserver reliability improved from R1 to R2; the intraclass correlation 0.56 to 0.66, Fleiss kappa from 0.25 to 0.36 and the range of Cohen's pairwise kappa values from 0.29-0.58 to 0.44-0.60. The individual accuracy rates increased from R1 to R2; the highest improvement was in the CPF's rates.



**Conclusions:** 1. The interobserver agreement of the PS diagnostic categories was fair to moderate, and improved after using TPS for 12 months, with the most substantial improvements seen in the least experienced observer.

2. The frequency of equivocal diagnoses decreased and diagnostic accuracy increased with experience in TPS use.

### 334 Follow Up Outcomes of hrHPV Positive Women with Negative versus ASC-US Cytology

Josephine S Aguilar-Jakthong, Opal L Reddy, Jill Borer, Po Chu Fung, Jianyu Rao. University of California, Los Angeles, Los Angeles, CA.

**Background:** Since cervical cytology was first implemented as a screening tool, the incidence and mortality rate of cervical cancer has drastically decreased. High-risk human papillomavirus (hrHPV) testing has been incorporated as a reflex test after diagnoses of Atypical Squamous Cells of Undetermined Significance (ASC-US), as a co-test with Pap smears, and as a primary screening tool. Guidelines of American Society for Colposcopy and Cervical Cytology (ASCCP) currently recommend for

women with positive HPV and negative cytology repeat co-testing in one year or HPV typing. The recommendation for positive HPV and ASC-US cytology is colposcopy. This study aims to evaluate these management approaches.

**Design:** Using our pathology case database, we identified women that underwent co-testing of both Pap smear and hrHPV testing with a diagnosis of either negative for intraepithelial lesion or malignancy (NILM) or ASC-US cytology between January 2010 and December 2015. We included only those women with surgical follow-up within 3 years. Findings were correlated with age, HPV type and follow-up diagnosis.

**Results:** We identified 292 hrHPV positive women with negative cytology and 893 hrHPV positive women with ASC-US cytology who had surgical follow-up within 3 years. 309 (83%) women with ASC-US compared to 63 (17%) women with negative cytology developed cervical intraepithelial neoplasia (CIN I to III lesions;  $p < 0.001$ ).

Surgical Follow-Up	Pap Smear Results		
		Negative (%)	ASC-US (%)
	Benign/Atypia	229(78%)	584(65%)
CINI, II, III	63(17%)	309(83%)	
Total	292	893	

Interestingly, for women with negative cytology, significantly more CIN lesions were seen in women <40 than women ≥40 years of age (26% versus 16%, respectively,  $p < 0.05$ ).

Age Group	Surgical Follow-Up with Negative Cytology			
		Benign/Atypia	CINI, II, III	Total
	<40	115	41	156
≥40	114	22	136	

89 (66%) women who were <40 years of age were HPV positive for type 16 or 18 compared to 46 (34%) women who were ≥40 years of age.

**Conclusions:** Women who are hrHPV positive but have ASC-US cytology have significantly higher likelihood for developing CIN lesions compared to hrHPV positive women with negative cytology. Women <40 years of age are more likely to be positive for HPV type 16 and 18, which may place them at higher risk for developing CIN lesions. Overall, our findings support ASCCP management recommendations for women with positive HPV with either negative or ASC-US cytology. Further studies are warranted to confirm our findings.

**335 The Association of “Positive” and “Suspicious” Urinary Cytology with Subsequent Histological Diagnoses**

Jeffrey Ahlstedt, Laleh Hakima, Samer N Khader. Montefiore Medical Center/Albert Einstein College of Medicine, Bronx, NY.

**Background:** Urine cytology is a cornerstone in the detection and surveillance of high-grade urothelial carcinoma (HGUC). The cytological categories “positive for HGUC” (PHGUC) and “suspicious for HGUC” (SHGUC) have similar clinical management; however, their respective association with subsequent histologic malignancies requires further investigation. The objective of this study is to determine the risk of malignancy associated with “positive” and “suspicious” urine cytology diagnoses.

**Design:** Urine cytology cases diagnosed as “suspicious” and “positive” were obtained from the archives from 05/2014 to 09/2016. All cases were correlated with biopsy obtained within 6 months of cytology specimen and cases without subsequent biopsy were excluded. Only the most recent urine collected was included when multiple urines were collected prior to biopsy.

**Results:** Of 73 cases, 49 were diagnosed as “suspicious” and 24 were diagnosed as “positive”. Of 24 “positive” cases, 21 (88%) showed HGUC on biopsy, 1 urothelial carcinoma in situ (CIS), 1 metastatic cervical squamous cell carcinoma, and 1 was negative on biopsy (at 1 month). Of 49 “suspicious” cases, 32 (65%) showed HGUC on subsequent biopsy and 3 showed CIS. There was also a high, but not statistically significant, association with metastatic malignancies among “suspicious” cases versus “positive” cases (16.3% versus 4.2%;  $p=0.14$ ): 2 lymphomas, 1 plasmacytoma, and 5 metastatic carcinomas (2 unknown primaries, 2 prostate, 1 cervix). The remaining 6 cases were negative (1 low grade papillary urothelial neoplasm and 5 inflammatory.) The overall positive predictive value for PHGUC was 95.8% (95% CI, 0.769-0.998) compared with 87.8% (95% CI, 0.745-0.949) for SHGUC ( $p=0.41$ ).

**Conclusions:** Diagnosis of SHGUC and PHGUC were both associated with a high risk of malignancy. While the differences between these two categories did not achieve statistical significance, it was interesting to note the makeup of the malignancies associated with each of these cytologic diagnoses. PHGUC was almost exclusively associated with HGUC on biopsy with only one case associated with a metastatic disease of non-urologic origin. SHGUC, on the other hand, had a much higher association with metastatic disease but was not statistically different. These results demonstrate that both SHGUC and PHGUC need to be managed aggressively and that further investigation may be required to determine the source of suspicious cells in the SHGUC diagnostic category.

**336 Inter-Institutional Variability for Malignancy in “Suspicious” Salivary Gland Fine Needle Aspiration: A Multi-Institutional Study**

Seydeh Elham Arab, Zahra Maleki, Huaqing Zhao, Esther Diana Rossi, Ping Bo, Ashish Chandra, Aatika Malik, Nirag Jhala, Syed Z Ali, Guido Fadda, Viren Patel, Jindong Wang, He Wang. Temple University Hospital, Philadelphia, PA; The Johns Hopkins Hospital, Baltimore, MD; The Catholic University of Rome, Rome, Italy; Fudan University Cancer Hospital, Shanghai, China; Guy’s & St Thomas’s Hospital NHSFT, London, United Kingdom.

**Background:** Fine needle aspiration (FNA) cytology is well accepted as a safe, reliable, minimally invasive and cost-effective method for diagnosis of salivary gland lesions. Most salivary gland neoplasms are difficult to diagnose because of morphologic heterogeneity and a variety of epithelial metaplastic changes. Hence, a significant number of salivary gland FNAs yield indeterminate results.

**Design:** The indeterminate FNAs are classified into “atypical” and “suspicious for malignancy” categories. This study was designed to evaluate risk of malignancy (ROM) of the suspicious group among 5 tertiary medical centers worldwide. Among the 12,732 salivary gland FNAs between 1997 and 2014, 276 (2.2%) were reported as “suspicious for malignancy”. 114 suspicious cases (42%) had histological follow-up. Pearson chi-squared test was used to compare malignant rates for suspicious cases among five institutions.

**Results:** “Suspicious for malignancy” refers to cases with certain features of malignancy, but the findings are not sufficient to make a conclusive diagnosis. Histological follow-up of 114 suspicious cases shows 96 (84%) malignant tumors and percentages for individual institutions are 73.91%, 84.62%, 85.71%, 87.04%, and 88.24%. When comparing different institutions, Pearson chisquared=2.38 and  $P = 0.67$ , indicates no statistically significant variability among institutions. Actually the highest and lowest ROM are 88.24% and 73.91% ( $P = 0.2$ ).

**Conclusions:** Overall, 84.21% of suspicious for malignancy salivary gland FNAs turns out to be malignant. There is no significant inter-institutional variability in ROM. The suspicious for malignancy category of salivary gland FNAs is very identical and ROM is quite high and similar among 5 tertiary medical centers worldwide.

**337 Comparison of Aptima, Cervista and Hybrid Capture 2 HPV Detection and Follow Up Results in Patients with HSIL Paps in a Large Academic Women Center**

Dayne Ashman, Chengquan Zhao. University of Pittsburgh Medical Center, Pittsburgh, PA.

**Background:** New cervical cancer screening guidelines recommend cotesting for women 30 to 65 years. Data remain very limited comparing high risk (hr) HPV detection rates and varying cytology results from the same collection vial when HPV testing is performed using different FDA-approved HPV tests.

**Design:** A retrospective database search was conducted at a large academic Women hospital to identify cases with HSIL ThinPrep cytology results and concurrent hrHPV test from July 2010 to June 2016. HrHPV testing was performed in the laboratory by the Hybrid Capture 2 (HC2) method from July 2010 to June 2013, by the Cervista method from July 2013 to May 2015 and by the Aptima method since June 2015. Histopathologic follow-up results were obtained for the cases with Cervista and Aptima method within 9 months after the Pap/HPV testing.

**Results:** A total of 642 cases with HSIL Pap and concurrent hrHPV testing were identified from July 2010 to June 2016-6. Overall HPV positive rate was 93.0%, with 94.4%, 90.8%, and 94.1%, by HC2, Cervista, and Aptima, respectively. The hrHPV positive rates among the different testing methods and different age groups showed no statistical significance ( $p=0.23$ ). Histological follow-up findings were compared by HPV detecting methods. The average follow-up period was 1.9 months (0.2-9 months). Total CIN2+ lesions were identified in 455/585 (77.8%) HSIL cases, including 17 (2.9%) squamous cell carcinomas (SCC). CIN2+ lesion rates among three HPV testing methods were not statistically different in both HPV positive and HPV negative groups. 18 of 40 (45%) women with HSIL Pap/negative HPV testing had CIN2+ lesions including 1 case of squamous cell carcinoma detected.

**Histological Follow-Up Results**

	HPV Positive			HPV Negative		
	Case No	CIN2+ (%)	CIN1 (%)	Case No	CIN2+ (%)	CIN1 (%)
Cervista	170	133 (78.2)	29 (17.1)	20	12 (60)	1 (5)
Aptima	142	107 (75.4)	26 (18.3)	8	2 (25)	2 (25)
HC2	273	197 (72.2)	52 (19.1)	12	4 (33.3)	3 (25)
Total	585	437 (74.7)	107 (18.3)	40	18 (45)	16 (40)

**Conclusions:** This study demonstrates hrHPV positive rates for women with HSIL Paps had not statistical significances among HC2, Cervista, and Aptima methods. Overall HPV negative rate was 7% for women with HSIL Pap. CIN2+ lesion was found in 45% women with HSIL Pap and negative HPV testing result, which would challenge the approach to use hrHPV as primary cervical cancer screening.

**338 Performance of Papanicolaou Society of Cytopathology (PSC) Guidelines with EUS Correlation in Resected IPMNs**

Bridget S Banach, Tatjana Antic, Mary Buschmann, Ricardo R Lastra, Jeffrey Mueller, Uzma Siddiqui, Ward Reeves, Kevin Roggin, Irving Waxman, Shu-Yuan Xiao, Namrata Setia. University of Chicago, Chicago, IL.

**Background:** Diagnosis of IPMN can be challenging on cytology, often yielding a “Non-diagnostic” or “Atypical” result leading to treatment uncertainty. PSC guidelines aim to address the issue by introducing a 6-tier system where in-situ IPMNs are classified as Category IV: “Neoplastic, other” with a narrative diagnosis which grades the degree

of dysplasia. The adenocarcinomas arising in IPMN are included in Category V and VI: "Suspicious for malignancy" and "Malignant", respectively. Performance of PSC guidelines in a subset of resected IPMNs was evaluated.

**Design:** 41 patients with confirmed diagnosis of IPMN on surgical resection (+/- AdCa, 2000-2015), for whom EUS, FNA & surgical pathology data was available, were included. Four groups were identified based on the resection diagnosis: IPMN-LG, -IG, -HG and -AdCa. Clinical data, EUS findings and cytologic features on Thinprep slides & direct smears were evaluated. Statistical analysis was performed using Prism & VassarStats.

**Results:** Clinical and EUS features were comparable in IPMN-HG and IPMN-AdCa; these lesions tended to be larger (p=0.09) with main pancreatic duct dilation (p=0.004) & aspiration of viscous fluid (p=0.01) in comparison with IPMN-LG and IPMN-IG. There was no significant difference in EUS appearance of the lesion (cystic+/-solid), presence of mural nodule & CEA levels (p=0.06, p=0.59, p=0.92) between the groups. Figure 1 represents performance of PSC classification and summary of cytologic features. A decline in % of "Non-diagnostic" diagnoses (33% to 13%) and "Atypical" diagnoses (40% to 7%) was observed after application of PSC guidelines. IPMN-AdCa were classified as colloid carcinoma (CC, n=8) and tubular/conventional adenocarcinoma (T AdCa, n=8). CCs were likely to be categorized as Category IV: "Neoplastic other: Mucinous cyst with high-grade dysplasia" (p=0.02) and T AdCas as Category VI: "Malignant" (p=0.06).

	Accuracy of PSC classification	PPV	NPV	Thin Mucin (p=0.67)	Thick Mucin (p=0.076)	Cyst Debris (p=0.99)	Mod/Severe Atypical Grrps (p=0.063)	Micro/Papillary Clusters (p=0.053)	Necrosis (p=0.85)	Tombstoning Cells (p=0.001)
Low Grade (LG) IPMN (n=14)	Neoplastic other (Mucinous cyst, LG) 3/14 (21%)	60%	69%							
Intermediate Grade (IG) IPMN (n=5)	Neoplastic other (Mucinous cyst, IG) 1/5 (20%)	17%	83%							
High Grade (HG) IPMN (n=5)	Neoplastic other (Mucinous cyst, HG) 2/5 (40%)	28%	91%							
Adenocarcinoma (n=17)	Suspicious for AdCa/AdCa 7/17 (41%)	88%	70%							

**Conclusions:** While % of "Non-diagnostic" and "Atypical" diagnoses decreased after application of PSC guidelines, cytologic evaluation was inaccurate in predicting the grade of dysplasia and presence of invasive carcinoma in a subset of cases. Aspiration of exfoliated cells and increased association of IPMNs with colloid carcinoma may account for these discrepancies.

**339 The Role of miRNA Expression Analysis in Needle Aspirate Cytology of Indeterminate Thyroid Nodules**

Anna Banizs, Joseph F Annunziata, Christina M Narick, Sara Jackson, Jan F Silverman, Sydney Finkelstein. Allegheny General Hospital, Pittsburgh, PA; Interpace Diagnostics, Pittsburgh, PA.

**Background:** Fine needle aspirate indeterminate cytologic diagnosis of thyroid nodule is a management challenge. Three approaches have been used: 1) cytology (Bethesda Diagnostic Categories BDC-I to VI), 2) search for accumulated mutational change and 3) RNA expression classifier status based on panels of messengerRNA (mRNA)/microRNA (miRNA). Using a large database (n=3341), we compared each modality for diagnostic performance and to better understand their role in cancer risk assessment.

**Design:** Cytology diagnosis was based on submitted cytology reports sorted into BDC-I to VI. Separate needle passes were used for molecular testing on two distinct platforms. Mutational analysis encompassed common mutations (BRAF, RAS, PIK3CA, PAX8/PPAR and RET/PTC translocations) on next generation sequencing (NGS; Illumina). Classifier utilized a 10 miRNA panel trained on 257 thyroid reactive, benign, malignant specimens. Three modalities underwent statistical comparison using ANOVA on Ranks and Rank Sum Test.

**Results:** miRNA classifier yielded a quantitative measure across the benign/malignant continuum assigned to four cancer risk categories: very low (n=830) with 99+% NPV, low (n=1962) with 94% NPV, moderate (n=372) with 74% PPV and high (n=177) with 99+% PPV. BDC-V (n=119) showed significant differences in malignant prediction by miRNA classifier (p<0.05) compared to BDC-III (n=1734) and BDC-IV (n=637). Cytology classification showed no statistical difference in benign vs. malignant prediction between BDC III and IV (p=0.138). BRAFV600E point mutation was present 31.93% (BDC V) vs 2.88% (BDC III) and 3.92% (BDC IV). Mutation analysis, using miRNA classifier as gold standard, revealed clear differences between specific mutational genotypes with strong driver (BRAFV600E) and weak drivers (RAS and others). Presence of multiple mutations within one specimen was rare, representing 1.27% of total mutated cases.

**Conclusions:** Cytology can separate BDC IV and V; however, it appears to be less discriminating in earlier neoplasia stages (BDC III and IV). miRNA classifiers demonstrate the ability to assess risk in earlier stages of neoplastic changes. Therefore, combined diagnostic approach (cytology/mutation/classifier) predicts more reliably the neoplastic potential of thyroid nodules. Oncogene mutation types, while diverse, tend to be mutually exclusive conferring varying degrees of driver mutation strength.

**340 Assessment of PD-L1 Status by Immunohistochemistry in Cytological Specimens of Non-Small Cell Lung Cancers: Correlation with the Results of Concurrent Surgical Specimens**

Cameron Beech, David L Rimm, Veronique Neumeister, Guoping Cai. Yale University School of Medicine, New Haven, CT.

**Background:** The use of biomarkers to guide therapy decisions in oncology is becoming increasingly prevalent. Immunotherapeutic approaches to target the PD-L1/PD-1 have recently shown great promise in treating patients with non-small cell lung cancers (NSCLCs). The efficacy of anti-PD-L1/PD-1 therapy is largely related to expression of PD-L1 on tumor cells. Thus, PD-L1 expression status, often evaluated on surgical

specimens, is crucial for solicitation of patients for PD-L1 immunotherapy. In this study we assessed PD-L1 expression in cytological specimens of NSCLCs as compared to the results of concurrent surgical specimens.

**Design:** We searched for positive cytology cases in which PD-L1 immunostain had been performed on the concurrent surgical biopsy or resection specimens. PD-L1 immunostain was retrospectively performed on the cytology cases using 22c3 anti-PD-L1 antibody on Dako Link48 platform as did for the concurrent surgical specimens. PD-L1 status was semi-quantitatively evaluated based on the percentage of tumor cells stained positive for PD-L1, <1%, 1-50%, and >50%. The staining results were compared between cytology and surgical specimens.

**Results:** A total of 24 cases including 14 adenocarcinomas, 9 squamous cell carcinomas, and 1 NSCLC NOS were reviewed. PD-L1 expression in <1%, 1-50% and >50% of tumor cells was seen in 6, 7 and 11 cytology cases and 4, 9 and 11 surgical cases, respectively. Of the cases with >50% of tumor cells expressing PD-L1, two cases showed significantly different staining results between cytology and surgical specimens. One cytology case had <1% PD-L1 expression while the concurrent surgical specimen showed >50% positive cells. In another case, PD-L1 was expressed in >50% of tumor cells in cytology and 1-50% in the concurrent surgical specimen. Interestingly, for those two cases surgical specimens were primary lung tumors while the cytology cases were metastatic tumors.

**Conclusions:** Our result demonstrates the feasibility to use cytological specimens for assessment of PD-L1 status in NSCLCs, which largely correlates with the results of surgical specimens. There is a possibility that the PD-L1 status may be altered when tumor metastasizes.

**341 The Paris System of Urinary Cytopathology Outperforms Unclassified Diagnostic Nomenclature and Correlates with the Surgical Pathology Biopsy Diagnosis of the Lower Urinary Tract**

Elizabeth C Bertsch, Momin T Siddiqui, Carla Ellis. Emory University, Atlanta, GA.

**Background:** The authors of The Paris System estimate that up to 30% of reports are misinterpreted by clinicians due to variability in reporting. The current study seeks to compare both the original diagnoses (OD) and the updated Paris system diagnoses (PD) of urine cytology to the corresponding surgical biopsy diagnoses (SD) to determine which diagnostic paradigm has a stronger correlation.

**Design:** 25 cases with a malignant SD that was associated with a corresponding urinary cytology specimen from the same location within up to four days of the biopsy procedure were selected. Locations included: renal pelvis (n=8), ureter (n=4) and bladder (n=13). We reviewed the cytology specimens and assigned a PD to each. We abbreviated the OD to one of the following: "negative, atypical, reactive, suspicious, low grade neoplasm, or malignant/carcinoma". We then compared each OD and each PD to the corresponding SD to determine which ("Paris", "Both [original and Paris]" or "Neither") corresponded best. Correspondence was defined as when the SD had the same result or equal weight as either cytopathologic diagnosis (see Table).

PD	SD
- for HGUroCa	Benign
Atypical	Reactive/Atypical/Dysplasia
LGUN	LGPapUroCa
Suspicious	HGPapUroCa/CIS
HGUroCa	HGPapUroCa/CIS

**Results:** 11/13 (85%) SD from the bladder corresponded to the PD. Of the remaining two cases, one corresponded to "both" and the other corresponded to "neither". Of the 4 ureter SD, 2/4 (50%) showed correspondence with "both" and "neither" of the remaining two corresponded. 2/8 (25%) renal pelvis SD corresponded to the PD. Of the remaining 6, in 4 "neither" corresponded and in 2 "both" corresponded. The "LGUN" category correctly identified 2/6 cases of LGPapUroCa. No cases showed an isolated correlation between the OD and the SD as compared to the 13 cases that showed an isolated correlation between PD and SD (p=.00003).

**Conclusions:** When applied, the PD has a stronger correlation to the SD, particularly when the biopsies are from the urinary bladder. The LGUN category was successful in the diagnosis of LGPapUroCa which prior to the Paris system was a challenging cytopathologic diagnosis. The decreased degree of correlation between the PD and SD from the upper urothelial tract may be associated with the decreased incidence of high grade lesions (3/12) as compared to that seen in the urinary bladder (9/13). Further study with more cases is required to support this significant association.

**342 Fluorescence In-Situ Hybridization of Thyroid Fine Needle Aspiration Biopsy Distinguishes Neoplastic and Non-Neoplastic Hurthle Cells**

Scott Bibbey, Brian Collins. Washington University in St. Louis, St. Louis, MO.

**Background:** Hurthle cell neoplasms (HCN) of the thyroid constitute a unique group of neoplasms. Defining cytogenetic alterations have not been reported in HCN. Molecular methodologies have been developed for risk stratification of thyroid FNA biopsy and are helpful in follicular and papillary neoplasms. These have had less success in stratifying risk for HCNs. Studies have shown HCNs often demonstrate gains in chromosomes 5, 7, and 12. By thyroid FNA biopsy, Hurthle cell proliferations can be difficult to distinguish based purely on morphologic features. This study examined fluorescence in-situ hybridization (FISH) performance characteristics in non-neoplastic and neoplastic Hurthle cell proliferations sampled by thyroid FNA biopsy in order to assess chromosome patterns.

**Design:** Cases with a Hurthle cell proliferation by FNA biopsy were selected and included nodular hyperplasia (NH), Hurthle cell adenoma (HCA) and Hurthle cell carcinoma (HCC) over a ten year period. Those with both an initial FNA biopsy and

subsequent surgical excision were selected. FNA biopsy slides (modified Wright-Giemsa stained) were reviewed and Hurthle cell regions delineated. FISH was performed on a single air dried direct aspirate smear from each case. FNA biopsy slides were destained and FISH performed for a three color panel which consisted of one subtelomeric and two centromeric probes for chromosomes 5, 7 and 12 (myProbes by CytoCell).

**Results:** 25 FNA direct aspirate smears had FISH testing and included NH, HCA and HCC. Chromosomal probe patterns were recorded in up to 50 cells. A positive result was >15% of cells showing polysomy in 2 or more chromosomes (5, 7 or 12). None of the NH cases were positive (0/4). Scattered cells with polysomy were identified, but were below 15%. 7 of 9 (78%) HCAs were categorized as positive. 2 of the 7 (29%) positive HCAs showed >50% of cells harboring polysomy. 8 of 12 (67%) HCCs were positive and 5 of the 8 (63%) positive cases showed polysomy in >50% of cells.

**Conclusions:** Thyroid FNA biopsy can identify Hurthle cell proliferation; however, risk stratification based on morphology is difficult. In this study, FNA thyroid biopsies of Hurthle cell neoplasms evaluated by FISH demonstrated polysomy involving chromosomes 5, 7 and 12. Cases of NH with Hurthle cell morphology had a normal chromosome pattern. 71% of Hurthle cell neoplasms (15/21) showed polysomy. FISH chromosomal evaluation of thyroid FNA biopsy is useful to distinguish neoplastic from non-neoplastic Hurthle cell proliferations.

**343 Can Noninvasive Follicular Thyroid Neoplasm with Papillary-Like Nuclear Features (NIFTP) and Classical Papillary Thyroid Carcinoma (PTC) Be Distinguished by Fine Needle Aspiration (FNA)?**

*Tamar C Brandler, Fang Zhou, Margaret Cho, Ryan P Lau, Cheng Liu, Aylin Simsir, Kopal N Patel, Wei Sun.* New York University Langone Medical Center, NY, NY.

**Background:** Encapsulated follicular variant of papillary carcinoma (EFVPTC), formerly a malignant diagnosis and variant of PTC, has recently been reclassified to NIFTP on surgical pathology. It is therefore imperative that we explore whether or not there are cytomorphologic differences at the FNA stage of patient care between PTC and NIFTP in order to gain a better understanding of how to properly classify these cases by FNA. In this study, we reviewed FNA cases that preceded surgical resection diagnoses of PTC and NIFTP (or EFVPTC) to determine if cytology can distinguish NIFTP from PTC.

**Design:** Cytology slides from subjects with a surgical pathology resection diagnosis of NIFTP/EFVPTC and PTC between 1/1/13-8/26/16 were assessed. Cytomorphologic features and pre-operative cytology diagnoses were tabulated. Statistical analysis was performed using PPSPP for 64-bit Windows.

**Results:** NIFTP and PTC groups were found to be significantly different in preceding cytology diagnosis (P<0.01) (table 1) and in all but one of the cytomorphologic categories (table 2).

Bethesda Cytology Diagnoses:	PTC (n=47) n(%)	NIFTP (n=51) n(%)
II Benign	0 (0)	6 (11.8)
III AUS/FLUS	3 (6.4)	16 (31.4)
IV Follicular neoplasm	0 (0)	13 (25.5)
V Suspicious for malignancy	4 (8.5)	10 (19.6)
IV Positive for malignancy	40 (85.1)	6 (11.7)

Cytologic Features (present vs absent):	PTC (n=47) n(%)	NIFTP (n=51) n(%)	Fisher Exact, 2-tailed p value (statistical significance p<0.05)
Nuclear pseudoinclusions	41 (87)	5 (10)	<0.01
Papillae	34 (72)	3 (6)	<0.01
Nuclear grooves	43 (92)	21 (41)	<0.01
Nuclear crowding	47 (100)	45 (88)	0.03
Nuclear enlargement	47 (100)	46 (90)	0.057
Nuclear irregularities	23 (49)	8 (16)	<0.01
Nuclear clearing	47 (100)	42 (82)	<0.01
Psammoma bodies	15 (32)	2 (4)	<0.01
Microfollicles	2 (4)	37 (73)	<0.01
Abundant Colloid	5 (11)	15 (29)	0.03
Giant cells	19 (40)	3 (6)	<0.01

**Conclusions:** NIFTP and PTC are not only differentiated at the surgical level but also have distinguishing features on FNA- with significant differences in cytology diagnoses and cytomorphology. The ramifications of being able to distinguish these two entities at the cytology level are great in that a more conservative management approach can be initiated with avoidance of excessive treatment at this earlier stage of patient care.

**344 Cytologic Evaluation of p16 Staining in Head and Neck Squamous Cell Carcinoma in Cytolyt vs Formalin-Fixed Material**

*Darren Buonocore, Jean-Marc Cohen.* Memorial Sloan Kettering Cancer Center, New York, NY.

**Background:** Human papilloma virus (HPV) related head & neck squamous cell carcinoma (HNSCC) is distinct from HNSCC linked to smoking/alcohol use. HPV+ HNSCC often presents as an occult oropharyngeal primary with enlarged lymph node metastases. As such, fine needle aspiration (FNA) is significant in the initial diagnosis and patient management. Testing for HPV using p16 immunohistochemistry (IHC) (>70% strong nuclear/cytoplasmic staining) as a surrogate in surgical specimens is well established. Evaluation of p16 IHC in FNA specimens is inconsistent; some authors

report p16 positivity in >10% or 15% of cells correlates with HPV+ status while others observe a dichotomous (diffuse or none) staining pattern. We theorize this discrepancy is due to different fixatives.

**Design:** From Sept. 2015 to Sept. 2016, cytopathologists performed 15 FNAs of neck lymph nodes positive for HNSCC and suspicious for being HPV associated. Initial passes were used for smears, Cytolyt and on-site evaluation. Additional passes were performed for formalin fixation. A Cytolyt cell block (CCB) and a formalin-fixed cell block (FFCB) were prepared and p16 expression was evaluated on each using p16 IHC.

**Results:** In 14 of 15 cases, the FFCB had diffuse (>70% of cells) moderate-strong nuclear/cytoplasmic p16 staining. 11 of the corresponding CCB had weak-moderate p16 staining in ≤50% of the cells (range 5-50%), 2 were acellular and 1 had weak diffuse staining. In 5 of the 14 cases which the FFCB diffusely expressed p16, the patient's surgical specimen demonstrated HPV by p16 IHC and in situ hybridization. All were treated as HPV+ HNSCC with 7 currently having no evidence of disease (NED). The remaining 7 are still being treated. 1 FFCB did not express p16. That patient was also treated as being HPV+ and currently has NED.

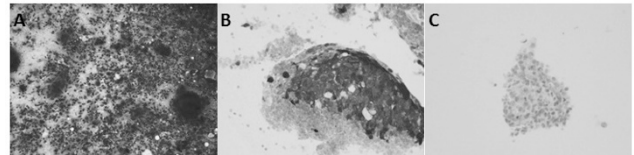


Figure 1: A) At on-site evaluation, Diff-Quik slides shows HNSCC prompting cytopathologist to perform dedicated passes for formalin (200x) B) FFCB is diffusely positive for p16 (400x) C) CCB show scant cells positive with p16 (400x)

**Conclusions:** In our cytology specimens, the fixative used had a drastic impact on p16 staining and we believe this explains the staining variability reported in the literature. P16 expression in cytologic material collected for FFCBs should be interpreted with the same criteria as surgical specimens while CCBs show a weaker and inconsistent staining pattern difficult to interpret. As such, we recommend FNA material be collected in formalin when evaluating HPV status.

**345 Expression of NKX3.1, Prostatic Specific Antigen and Androgen Receptor in Cytological Specimens Submitted for Metastatic Prostatic Carcinoma Workup**

*Guoping Cai, Rita Abi Raad, Adebowale Adeniran.* Yale University School of Medicine, New Haven, CT.

**Background:** Immunohistochemical studies have widely been used for identification of tumor origin. Prostatic specific antigen (PSA), prostatic specific alkaline phosphatase (PASP) and androgen receptor (AR) are often included in the metastatic workup for prostatic primary. NKX3.1, a recently identified prostatic-specific, androgen-regulated homeobox gene product, has been shown in surgical specimens to have high sensitivity and specificity as a prostatic marker. In the current study, we evaluated expression of NKX3.1, PSA and AR in cytological specimens submitted for metastatic workup.

**Design:** We searched our pathology electronic database for the cytology cases that had been evaluated to include or exclude metastatic prostatic carcinoma. The workup was performed either due to patients' known prior history of prostate cancer or presence of cytomorphologic features suggestive of possible prostatic origin. The results of NKX3.1, PSA and AR were classified as negative, focally positive (≤20% cells staining), and positive (>20% cells staining).

**Results:** A total of 20 cases, from patients with ages ranging from 56 to 90 years old, were included. The cases were fine needle aspirates or body cavity fluids (pleural effusion/ascites) with the final diagnosis being metastatic prostatic carcinoma in 12 cases and non-prostatic origin in 8 cases. The results of NKX3.1, PSA and AR expression were shown in [Table 1].

Table 1. Expression of NKX3.1, PSA and AR in metastatic prostatic carcinomas and non-prostatic cells

	Cases (n)	Metastatic Prostate			Non-Prostate		
		Positive	F. Positive	Negative	Positive	F. Positive	Negative
NKX3.1	20	10	0	2	0	0	8
PSA	20	7	5	0	0	0	8
AR	16	6	3	2	0	0	5

**Conclusions:** Our results showed that as compared to PSA and AR, NKX3.1 appears more often to have a diffuse expression pattern with a reasonable sensitivity, and should be included in metastatic workup for prostatic carcinoma.

**346 Morphologic Variation in Low Grade Squamous Intraepithelial Lesions (LSIL) Is Independently Correlated with Subsequent High-Grade SIL (HSIL) at Cervical Biopsy and High-Risk Human Papilloma Virus (HR-HPV) Positivity**

*Sarah Carroll, Christopher Hartley, Suzanne Selvaggi, Aparna Mahajan.* University of Wisconsin Hospital and Clinics, Madison, WI.

**Background:** The morphology of LSIL on pap tests ranges from classic koilocytosis to cellular dysplasia that raises the differential of HSIL. To date, it is unclear if more dysplastic appearing cells denote a greater likelihood of HR-HPV or HSIL on biopsy.

**Design:** The study included review of 199 Thin Prep® Pap Tests (PAP) diagnosed LSIL (2012-2015) blinded to cervical biopsy (CBX) and HR-HPV follow-up. LSIL was morphologically categorized as follows: LSIL1 - classic koilocytosis; LSIL3 - borderline N:C ratio, syncytial groups, and/or atypical squamous metaplastic or keratinized cells; and LSIL2 - intermediate to LSIL1 and LSIL3. Clinicopathologic data gathered included

age, history of HSIL on prior PAP or CBX, HR-HPV results, and CBX findings. Logistic regression was used to explore the relationship between LSIL categories and two outcomes: HR-HPV positivity and HSIL at CBX.

**Results:** All LSIL categories showed a high rate of HR-HPV positivity, and a variable rate of HSIL on CBX (Table 1). On multivariate analysis, only LSIL category correlated significantly with HSIL at CBX. (Table 2). A second multivariate model showed that age and LSIL category correlated significantly with HR-HPV positivity.

	N	Age in years mean(range)	HR-HPV positive	HSIL at CBX
LSIL1	90(45%)	35.4(21-68)	78%	5.5%
LSIL2	81(41%)	36.2(19-72)	90%	8.6%
LSIL3	28(14%)	35.7(21-59)	96%	21%
Total	199	35.8(19-72)	85%	7.5%

		p-value	OR	lower	upper
Multivariate Model 1: Outcome = HSIL at CBX	LSIL category	0.03	2.17	1.08	4.36
	Age	0.055	0.94	0.88	1.00
	HR-HPV status	0.60	1.76	0.21	14.6
	Hx of HSIL	0.65	1.46	0.28	7.62
Multivariate Model 2: Outcome = HR-HPV positive	LSIL category	0.01	2.84	1.37	5.91
	Age	0.02	0.96	0.92	0.99
	Hx of HSIL	0.84	0.84	0.17	4.25

Legend: OR = odds ratio; lower/upper = lower/upper bound of 95% confidence interval

**Conclusions:** LSIL with features beyond classic koilocytosis may be a reliable predictor of HR-HPV status and HSIL. Closer or more aggressive follow-up in patients may be indicated in a subset of patients diagnosed with LSIL.

### 347 Urine Cytology in Patients with Interstitial Cystitis/Bladder Pain Syndrome Classified According to the Paris System for Reporting Urinary Cytology

Carla Caruso, Erik R Washburn, Catherine S Abendroth. Penn State Health Hershey Medical Center, Hershey, PA.

**Background:** Interstitial cystitis/bladder pain syndrome (IC/BPS) is a chronic condition characterized by bladder/pelvic pain and urinary storage symptoms of frequency, urgency, and nocturia. The disease is female predominant but is not exclusive to females and is increasing in incidence. While the etiology is not fully understood, it is known to be associated with inflammatory mediators, loss of glycosaminoglycans with increased mucosal permeability, upregulated antiproliferative factor which limits epithelial repair, and mast cell activation. The classic ulcerative form demonstrates ulceration and chronic inflammation on biopsy. We undertook to determine whether patients with IC/BPS demonstrated cytologic atypia on urine cytology, and if so, whether this atypia was significant (i.e. predictive of high grade urothelial carcinoma) according to The Paris System (TPS) for reporting urinary cytology.

**Design:** We searched the database of the Penn State Health Hershey Medical Center electronic medical record to identify patients with a clinical diagnosis of IC/BPS between 8/22/11 and 8/21/15, cross-referencing with the pathology information system to identify the subset of patients with IC/BPS who also had urine cytology during that interval. The clinical diagnosis of IC/BPS was contingent on the exclusion criteria of prior genitourinary neoplasia, urinary retention, endometriosis, etc. Slides were reviewed and reclassified according to TPS as negative for high grade urothelial carcinoma (NGHUC), atypical urothelial cells (AUC), suspicious for high grade urothelial carcinoma (SHGUC), high grade urothelial carcinoma (HGUC), or low grade urothelial neoplasia (LGUN). Slides were reviewed independently by two of the authors (CC and CSA) with joint review of discordant interpretations.

**Results:** The search yielded 25 patients (23 females, 2 males) and a total of 42 urine cytologies (range 1 to 6 per patient). 8/42 (19%), all from different patients, were originally interpreted as atypical. All patients had benign follow up (range 13-53 months). Review and reclassification was concordant for 6/8 interpretations with consensus after joint review of the remaining 2 cases. 6/8 were reclassified as NHGUC; 2/8 were reclassified as AUC. No cases were reclassified as showing significant atypia (SHGUC or HGUC).

**Conclusions:** This study confirms the value of TPS in minimizing over-reporting of minor cytologic alterations that are frequently observed in this benign chronic inflammatory disease.

### 348 A "Paris System-Like" Approach and Cell Block Utilization in Urine Cytology

Emily Chan, Z Laura Tabatabai, Poonam Vohra. UCSF, San Francisco, CA.

**Background:** The Paris System for Reporting Urinary Cytology (PS) published in 2016 provides a standardized approach to evaluating urine cytology. The PS recommendations focus on diagnosing high grade urothelial carcinoma (HGUC), in part by improving the equivocal category of "atypia" using defined cytologic criteria, while recognizing the difficulty in diagnosing low-grade urothelial carcinoma (LGUC). In our practice, we adopted a similar Paris System-like approach in 2011 by reserving the "atypical urothelial cells" (AUC) diagnosis to cases with similarly defined cytologic atypia (increased nuclear to cytoplasmic ratio; nuclear hyperchromasia; irregular nuclear

membranes; and irregular, coarse, clumped chromatin). Correlation with cystoscopic findings and cell-blocks (CB) on difficult cases was also performed. This study was undertaken to assess if this Paris System-like approach and use of CB improves diagnostic yield and lowers AUC rate.

**Design:** Retrospective analysis of all 184 urine cytology specimens from 2010-2016 with either concurrent or subsequent histologic specimens was performed for diagnostic correlation. The rate of AUC diagnosis was compared between 2010-2011 and 2012-2016 using a standard test of proportions. Additionally, we performed slide review of 27 specimens with and without histologic specimens, in which CB were utilized and assessed their contribution to the final diagnosis.

**Results:** Overall, cytological and surgical specimens correlated in 78% of cases and sensitivity/specificity for HGUC was 93%/94%. When Benign and Low grade lesions were combined into a "Negative for HGUC" category according to PS recommendations, the overall correlation increased to 92%. The AUC diagnosis rate dropped significantly from 53% to 27% from 2010-2011 to 2012-2016 (p<0.001). CB evaluation led to definitive diagnoses in 17/27 cases (8 HGUC, 2 LGUC, 4 benign, 1 tumor of non-urothelial origin). Two atypical cases remained unchanged after CB review (1 with history of LGUC, 1 case had no surgical specimen). In the remaining 10 cases, CB was noncontributory due to scant material. The contributory CBs provided diagnostic architectural features (i.e. fibrovascular cores for LGUC, not present on Thin-Prep) and material for immunostaining.

**Conclusions:** In support of the new PS recommendations, our application of stringent "Paris-system-like" cytologic criteria and correlation with cystoscopic findings helped to significantly lower the AUC rate, thus providing better accuracy to clinicians and patients. In addition, utilization of CB can help resolve problematic cases for more definitive diagnostic categorization.

### 349 Characteristic Cytology of Non-Invasive Follicular Thyroid Neoplasm with Papillary-Like Nuclear Features (NIFTP): Implications for Patient Management in the Wake of a Nomenclature Change

Jocelyn B Chandler, Glenda G Callender, Courtney E Quinn, Manju L Prasad, Adebowale Adeniran. Yale School of Medicine, New Haven, CT.

**Background:** A major reclassification occurred with the redesignation of non-invasive encapsulated follicular variant of papillary thyroid carcinoma (EFVPTC) to non-invasive follicular thyroid neoplasm with papillary-like nuclear features (NIFTP) due to the indolent nature of these lesions. The impact of this change on the cytology diagnosis and subsequent surgical management has yet to be fully elucidated. We hypothesize that when compared to invasive follicular lesions, cytology of NIFTP cases will show fewer nuclear features resulting in a small percentage of cases classified in suspicious or positive for PTC categories where total thyroidectomy is the standard of care for these diagnostic categories at our institution.

**Design:** Surgical cases (125 total) over a four-year period (June 2012 – June 2016) with "follicular variant of papillary thyroid carcinoma (FVPTC)" in the diagnostic line were collected and the surgical pathology was retrospectively reviewed. Relevant exclusion criteria were applied, resulting in a study population of 94 cases including 52 cases of NIFTP, 21 cases of invasive EFVPTC, and 21 cases of invasive non-encapsulated FVPTC. Clinical and cytologic characteristics were collected. A cytological scoring system was devised to compare the statistical significance between the groups (student's t-test, p-value <0.05)

**Results:** Study patients across all groups were similar in age, gender distribution and tumor size. Nuclear features including chromatin clearing, enlargement, elongation, grooves, irregular contours and pseudoinclusions were less evident in non-invasive (NIFTP) cases compared to the invasive cases (p-value < 0.0034). Of the NIFTP cases, 21.2% (11/52) were classified as suspicious for PTC. Interestingly, none of the NIFTP cases were diagnosed as positive for PTC on cytology. In contrast, 38.1% (8/21) of invasive EFVPTC and 52.4% (11/21) of invasive FVPTC were categorized as either suspicious or positive for PTC. Overall, total thyroidectomy was performed less often for NIFTP cases (48.1%; 25/52) as compared to the invasive cases (73.8%; 31/42).

**Conclusions:** Our study demonstrates that nuclear features on cytology are less apparent in cases eventually confirmed to be NIFTP in comparison to invasive follicular lesions. Improved characterization of the cytologic diagnosis of NIFTPs will help reduce unnecessary total thyroidectomies.

### 350 Cytological Features of a Spectrum of Gastric Type Glandular Lesions of the Uterine Cervix in Pap Smear

Koping Chang, Chih-Fen Tan, Tsui-Lien Mao. National Taiwan University Hospital, Taipei, Taiwan; College of Medicine, National Taiwan University, Taipei, Taiwan.

**Background:** Endocervical glandular neoplasms, like its squamous counterpart, are usually associated with high-risk type HPV. Cervical glandular lesions unrelated to HPV are relatively rare. Gastric type glandular lesions of the uterine cervix are unrelated to HPV, and comprise a spectrum of lesions ranging from benign, premalignant to malignant. Due to its low incidence, recognition of these lesions in Pap smear is difficult and sometimes impossible.

**Design:** We retrospectively retrieved and reviewed Pap smears diagnosed as atypical glandular cells, adenocarcinoma in situ (AIS), or adenocarcinoma with prior or subsequent histological diagnosis of gastric type cervical glandular lesions. Comparison of the cytological features and correlation with the histological sections were performed.

**Results:** Totally 6 cases were found, including two atypical lobular endocervical glandular hyperplasia (LEGH), two gastric type AIS, one minimal deviation adenocarcinoma (MDA) with co-existing LEGH, and one gastric type mucinous adenocarcinoma. All slides were conventional Pap smears. These glandular cells appeared as single cells, small groups or large branching sheets, with more single cells in lesions having higher degree of nuclear atypia. Background mucin was sparse in all cases. Necrotic debris was noted in mucinous adenocarcinoma. Drunken honeycomb

pattern with variable degree of nuclear crowding were found in all cases, whereas feathering or pseudostratified strips were only seen in AIS. Intracytoplasmic yellow to orange mucin was noted in one atypical LEGH and the two AIS. The nuclear chromatin was finely granular in all cases. Prominent nucleoli were present in mucinous adenocarcinoma, one atypical LEGH and one AIS, while the nucleoli were small distinctive in the other three cases. Mitosis or apoptosis was only occasionally found. **Conclusions:** Our cases demonstrated overlapping cytological features between premalignant and malignant gastric type glandular lesions, and share some similarities with usual type AIS/adenocarcinoma. Cytoplasmic yellowish orange mucin, a feature of gastric pyloric gland, may provide clues for gastric differentiation, but may not present in all gastric type glandular lesions.

### 351 A Proposed Scoring System to Increase the Specificity of the Diagnosis of Positive for Papillary Thyroid Carcinoma in Fine Needle Aspiration Specimens

Hannah H Chen, Hui Zhang, Gamez G Roberto, Stefan Pambuccian, Swati Mehrotra. Loyola University Medical Center, Maywood, IL.

**Background:** In fine needle aspiration (FNA) specimens, the cytologic features for papillary thyroid carcinoma (PTC) have been well defined. Recently, a subset of follicular tumors formerly included in the follicular variant of papillary thyroid carcinoma (FVPTC), have been reclassified as "noninvasive follicular thyroid neoplasm with papillary-like nuclear features" (NIFTP). NIFTP could show similar cytologic features and be diagnosed as PTC on cytology, leading to potential overtreatment. The aim of this study was to define the cytologic features that would minimize the inclusion of cases of NIFTP amongst positive or suspicious thyroid FNA diagnoses.

**Design:** We included a total of 48 cases (FVPTC, 19; classic PTC, 29) from 01/01/2011 to 9/01/2016. The slides from all cases of FVPTC were reviewed to identify cases of NIFTP. Two cytopathologists with more than 10-year experience each, reviewed all available cytology slides blinded to the original diagnosis and outcome and semiquantitatively evaluated the presence of 26 cytologic features. Regression analysis was done to find the features that were most useful; these features were then used to develop a scoring system for the cytologic diagnosis of PTC.

**Results:** Five of 19 FVPTC were reclassified as NIFTP; 43/48 cases were considered PTC. The 5 cases of NIFTP had prior cytology diagnosis of positive (n=4) or suspicious (n=1). 8 cytologic features were potentially useful to discriminate between classic PTC and FVPTC: psammoma bodies (any), swirls ( $\geq 3$ ), papillae (any), squamoid cytoplasm (present in  $\geq 10\%$  of cells), nuclear size ( $\geq 3 \times \text{RBC}$ ), nuclear shape (irregular in  $\geq 50\%$  of cells), nuclear grooves (present in  $\geq 50\%$  of cells) and nuclear pseudoinclusions ( $\geq 3$ ). When 1 point was given to each cytologic feature, the cases could be classified as positive for PTC (score  $\geq 4$ , 30 cases), suspicious for PTC (score of 3, 8 cases) or atypical (score of 1 or 2, 10 cases). Cases classified as positive, suspicious, and atypical by this method had an underlying risk of malignancy of 96.7%, 87.5% and 70%. Only 1 case reclassified as NIFTP was positive by this method, while the remaining 4 were atypical (n=3) or suspicious (n=1).

**Conclusions:** We propose a simple scoring method that allows a relatively good discrimination between cases of classic PTC and invasive FVPTC on one hand and NIFTP on the other, and minimizes the risk of classifying NIFTP as positive or even as suspicious. However, this increase in specificity occurs at the cost of increasing the rate of equivocal diagnoses.

### 352 Diagnosis of Solid Parathyroid Lesions Presenting as Intrathyroidal/Exophytic Thyroid Nodules on Aspiration Biopsy: A Correlation of Clinical Data, Ancillary Studies, and Molecular Analysis

Margaret Cho, Thaira Oweity, Tamar C Brandler, Karen Fried, Pascale Levine. New York University School of Medicine, New York, NY; Lenox Hill, New York, NY.

**Background:** Although cytologic features of parathyroid lesions have been reported, we sought to identify characteristic morphologic patterns and useful adjunct tests, including the novel molecular test (ThyroSeq®), to establish their diagnosis.

**Design:** We retrieved 27 out of 137 cases (20%) of intrathyroidal or exophytic thyroid nodules clinically indeterminate in their nature (thyroid vs. parathyroid) from 2000-2016. Pathology reports, slides, cell block, ancillary studies, molecular analysis, clinical, and radiologic (ultrasound and Sestamibi scan) data were retrieved.

**Results:** We identified three cytologic patterns: an oncocytic cell pattern in 7 cases (26%), a FLUS (follicular lesion of undetermined significance)-like/papillary pattern in 11 cases (41%), and nonspecific endocrine cell clusters in 9 cases (33%). Among the cases, consistent features included bare oval nuclei (100%), nuclear overlap (89%), crowded sheets (89%), and cytoplasmic vacuoles (74%). Papillary structures were seen in 8 cases (30%). The confounding feature of colloid-like material was seen in 14 cases (52%). Eleven cases (41%) were positive for PTH immunostain, 2 cases (7.4%) for PTH assay, and 7 cases (26%) had PTH genes detected by ThyroSeq®. In the remaining 7 cases (26%), the diagnosis, based on morphology alone, was either indeterminate or only suggestive of parathyroid origin. The cytologic diagnosis was confirmed clinically in 15 cases (56%) (with medical management) and surgically in 12 cases (44%). Based on cytology alone, 8 cases (30%) were initially incorrectly diagnosed as thyroid tissue and amended to parathyroid lesion after ancillary studies were performed, including 5 cases (18.5%) based on ThyroSeq® results alone.

**Conclusions:** Although we have identified distinct cytologic patterns in parathyroid lesions, which may help identify their true nature, these findings are by no means diagnostic. Colloid laden lesions and oncocytic nodules are prone to misdiagnosis. Additional studies such as PTH immunostains or assay, Sestamibi scan, or molecular studies (ThyroSeq®) are needed to confirm the diagnosis. The latter, which has not been evaluated in prior parathyroid cytology reports, is particularly useful when the atypical FLUS-like or oncocytic categories are encountered.

### 353 Fine-Needle Aspiration Cytology of Histology-Confirmed Pancreatic Cystic Lesions

Euna Choi, Harvey Cramer, Howard Wu. Indiana University, Indianapolis, IN.

**Background:** Cystic lesions of the pancreas are increasing in prevalence due to the widespread use of advanced imaging techniques, including endoscopic ultrasound (EUS). Most pancreatic cystic lesions are either benign or show low--grade dysplasia (LGD). The identification by fine needle aspiration (FNA) cytology of high-grade dysplasia (HGD) in pancreatic mucinous cysts is one of the key factors that may prompt surgical intervention. The aim of this study is to evaluate the sensitivity and specificity of EUS--guided FNA cytology in identifying high-risk pancreatic cystic lesions harboring intermediate grade dysplasia (IGD) or more severe lesions.

**Design:** A search of the laboratory information system that spanned the 12 year period from 2003 to 2015 was performed to identify cases of cystic lesions of the pancreas that were subsequently resected. All preoperative EUS-guided FNAs that correlated with those resected pancreatic cystic lesions were identified. For the purpose of analysis, cases diagnosed by FNA as negative, nondiagnostic, or negative for HGD were categorized as negative while cases diagnosed as atypical, suspicious for malignancy or adenocarcinoma were categorized as positive. Resected specimens that contained IGD, HGD, or adenocarcinoma were categorized as positive and those that showed cysts with LGD or were diagnosed as serous cystadenoma were categorized as negative.

**Results:** The search revealed a total of 104 cases, 68 of which had a preoperative EUS-guided FNA. There were 39 females and 29 males. The age at diagnosis ranged from 28 to 83 with a median age of 68. There were 61 histologic diagnoses of IPMN, including 9 with coexisting adenocarcinoma, 5 with HGD, 15 with IGD, and 32 with LGD. Five mucinous cystic neoplasms with LGD and two serous cystadenomas were also noted. Of the 68 FNA cases, there were 11 cases categorized as positive and 57 cases categorized as negative. Discrepant results were seen in 24 cases including 3 false positive and 21 false negative cases. The sensitivity of EUS--guided FNA was 28% and the specificity was 92%. The positive predictive value was 73% and the negative predictive value was 63%.

**Conclusions:** EUS--guided FNA is a relatively specific but insensitive diagnostic modality for identifying high--risk pancreatic cystic lesions harboring intermediate to high--grade dysplasia or carcinoma.

### 354 Correlation of Cytopathology with Flow Cytometry and/or Histopathology for Diagnosis of Cervical Lymphadenopathy in Young Adults

Bonnie Choy, Ricardo R Lastra, Jeffrey Mueller, Namrata Setia, Ward Reeves, Tatjana Antic. University of Chicago, Chicago, IL.

**Background:** Lymph node (LN) fine needle aspiration (FNA) is a minimally invasive procedure that can potentially differentiate benign reactive processes from malignant hematologic neoplasms. Our aim was to evaluate the correlation of cytopathology with either flow cytometry and/or histopathology diagnosis of LN biopsy, and assess prevalence of specific malignancies in young adults with cervical lymphadenopathy.

**Design:** The cytopathology database was searched for all neck LN FNAs performed by a cytopathologist, with concurrent flow cytometry and/or subsequent tissue biopsy in patients age 18-30 yrs, for the period of 2005 to date. Patients with a previous history of any malignancy were excluded.

**Results:** A total of 48 patients underwent neck LN FNAs. 19 patients (11 females and 8 males; median age=23 yrs) had only cytopathology diagnosis, of which all were found to be benign reactive LNs. 3 patients were lost to follow up. None of the remaining patients developed subsequent malignancies (mean follow-up=34.2 mos). 29 patients (12 females and 17 males; median age=27 yrs) had FNAs with concurrent flow cytometry and/or subsequent tissue biopsy. 18 (62%) patients had a benign reactive diagnosis, of which 16 (89%) had concordant diagnosis on flow cytometry (11 cases), tissue biopsy (2 cases), or both flow cytometry and tissue biopsy (3 cases). The 2 discordant cases were diagnosed as abscess and hypocellular specimen consisting of lymphocytes and colloid on cytopathology, respectively, but were later diagnosed as Hodgkin lymphoma (HL) on histologic examination. Both FNA specimens were not entirely satisfactory due to limited cells. 11 (38%) patients had a diagnosis suggesting hematologic malignancy, of which 10 (91%) were confirmed by tissue biopsy (7 cases) or by both flow cytometry and tissue biopsy (3 cases). 3 patients were diagnosed with diffuse large B cell lymphoma, and 7 with HL. The single discordant case was determined to be reactive follicular and paracortical hyperplasia on subsequent tissue biopsy.

**Conclusions:** There is high concordance between cytopathology and flow cytometry/histopathology examination in both benign reactive and malignant hematologic diagnoses on neck LNs. In our cohort of young adults age 18-30 years, HL is the most common hematologic malignancy diagnosed. When an adequate sample is taken, cytopathologic examination of the FNA specimen alone can provide a reliable diagnosis of a reactive process. When cytopathologic examination yields a diagnosis suggesting hematologic malignancy, flow cytometry and/or tissue biopsy should be promptly pursued.

### 355 Cytological Screening for Anal Lesions and Correlation with Histology and HPV Status. A Hospital Series

Adrià L Dagà, Maria Teresa R Calvo, Natalia F Papaleo, Javier G Beltrán, Mar Iglesias Coma, Belen L Rubio, Francesc A Quítillet. Hospital del Mar. Parc de Salut Mar, Barcelona, Spain; Autonomous University of Barcelona, Barcelona, Spain.

**Background:** Human papillomavirus (HPV) causes anogenital lesions and it is an important etiologic agent for anal intraepithelial neoplasia (AIN) and anal cancer. HIV infection is frequently associated to HPV infection in anal mucosa. There is controversy about the role of cytology and HPV detection as screening tools for these lesions, especially in HIV positive population.

**Design:** We have studied 122 consecutive cases of anal cytology specimens obtained over a period of 2 years (2014-2015). Data collected included cytological and histological diagnosis, HPV detection and typing, HIV status, and previously diagnosed anogenital lesions (CIN, VIN, genital warts).

On the other hand, we collected 58 anal biopsies accessioned during the same period. The diagnoses included verruca vulgaris (n=4), fibroepithelial polyp (n=6), LSIL (n=24), HSIL (n=10), and carcinoma (n=11).

**Results:** The male-female ratio in the cytology series was 1.4-1. Fifty-three (43%) patients were HIV+ and 18 cases (14%) had a history of previous anogenital lesions. Twenty-three cases (19%) had a subsequent biopsy. The prevalence of squamous intraepithelial lesions (LSIL / HSIL) in anal cytology smears was 51% (54 LSIL and 9 HSIL). Among the biopsied LSIL cytology cases (13), the biopsy diagnoses were: condyloma (n=7; 54%), AIN2 (n=2; 15%), and AIN3 (n=1; 8%). Three cases (23%) were negative. Five HSIL cytological cases showed AIN1 (n=1; 20%), AIN3 (n=3, 60%), and one invasive squamous cell carcinoma in the subsequent biopsy.

Regarding HPV infection, 89 cases (80%) were positive, 77 (87%) of these were high-risk types and 22 cases (13%) low-risk. Multiple HPV types were detected frequently, both in general population (87%) and in HIV+ patients (93%). All HSIL cases in cytology had high-risk HPV types, in comparison to the percentage of LSIL cases (85%). Among HPV-negative cases (23), only 4 (17%) showed LSIL in cytology. In 23 cases of the biopsy series there was a previous cytology. HPV was determined in 46 biopsy cases and high-risk HPV types were detected in 27 of them. Almost all (n= 11, 91%) the HSIL cases were high-risk HPV-positive.

**Conclusions:** Although cytological diagnoses of anal and cervical samples are similar, patient characteristics are different, with a larger prevalence of HIV infection in the former. This fact is probably related to the higher frequency of multiple HPV infections. The results emphasize the need for establishing a comprehensive clinical management protocol in anal cancer screening.

**356 Utility of Cell Block Preparation in Urine Cytology**

*Kossivi Dantey, Jackie Cuda, Rick Nestler, Sara E Monaco, Juan Xing, Liron Pantanowitz.* University of Pittsburgh Medical Center- Shadyside Hospital, Pittsburgh, PA; University of Pittsburgh Medical Center, Pittsburgh, PA.

**Background:** Urine cytology samples are a common non-invasive test to screen for urothelial carcinoma. Urine cell blocks may sometimes be prepared as a diagnostic aid. The aim of this study was to determine if routinely preparing cell blocks on urine specimens improves diagnostic sensitivity.

**Design:** Three eras were compared: period 1 (pre-Nov. 2009; 1437 consecutive cases) where cell blocks were rarely prepared; period 2 (Nov. 2009 to May 2010; 1230 cases) when cell blocks were prepared on all cases; and period 3 (after May 2010; 1499 consecutive cases) during which cell blocks were made only when indicated.

**Results:** Table 1 compares patient, specimen, adequacy and diagnostic data for all 3 cell block eras. Patient demographics and the type of specimens received were similar during the 3 time periods. Increased preparation of cell blocks was not accompanied by a notable improvement in specimen adequacy rate. Only the proportion of atypical cases differed during the time periods, being highest when cell blocks were rarely made (23%) but not markedly lowered when cell blocks were prepared on all (14%) or select cases (16%).

Study Period	1 (Rare blocks)	2 (All blocks)	3 (Selected blocks)
Total urine samples	1437	1230	1499
Numbers of cell blocks	161 (11%)	1230 (100%)	864 (58%)
Patient age (average)	64.6 years	64.2 years	64.4 years
Patient gender (M:F)	1.5:1	1.5:1	1.4:1
Sample adequacy	Unsatisfactory	6 (<1%)	19 (2%)
	Less than optimal	84 (6%)	185 (15%)
	Satisfactory	1347 (93%)	1026 (83%)
Cytology diagnosis	Negative	1030 (72%)	994 (81%)
	Atypical cells	333 (23%)	176 (14%)
	Suspicious for neoplasia	35 (2%)	22 (2%)
	Positive for neoplasia	32 (2%)	26 (2%)
	Non-diagnostic	7 (<1%)	12 (1%)

**Conclusions:** These data show that routinely preparing cell blocks for urine samples did not improve our laboratory's specimen adequacy rate. However, cell block preparation on urine samples did help lower the percentage of atypical cases when routinely or selectively prepared. Preparing cell blocks on all urine cases is costly and provides minimal added clinical benefit. Our recommendation is to rather judiciously utilize cell blocks when screening urine cytology samples.

**357 Follow Up Outcome in Patients with LSIL Pap Cytology and Aptima HR-HPV Testing Results**

*Kossivi Dantey, Xin Li, Xin Zhao, Jonee Matsko, Chengquan Zhao.* University of Pittsburgh Medical Center, Pittsburgh, PA.

**Background:** Cotesting is now recommended for patients aged 30 years and older with a cervical screening pap test result of low grade squamous intraepithelial lesion (LSIL) within one year of diagnosis. Only limited follow up data on patients for Aptima High-risk human papillomavirus (HR-HPV) test sensitivity and specificity are available.

**Design:** Patients with LSIL Pap tests and Aptima HR-HPV testing results were retrospectively identified from June 2015 to June 2016. Histological follow-up results within 6 months after LSIL Pap tests were analyzed.

**Results:** 1103 cases with LSIL and Aptima HR-HPV testing results were identified. Overall the HR-HPV positive rate was 75.2%, with the highest positive rate in patients aged 30-39 year-group. Histological follow up in the patients with LSIL and Aptima HR-HPV negative test (n=135) revealed 7(5.2%) CIN2/3 and 75(55.6%) CIN1. In the patients with LSIL and Aptima HR-HPV positive test (N=540), 75 (13.9%) had follow up of CIN2/3 while 347 (64.3%) had follow up of CIN1. The average follow-up period was 1.7 months (0.1-6 months). Only 1 of 37 patients (2.7%) aged 50 years and above with LSIL Pap/Aptima HR-HPV negative results had CIN2/3. No diagnoses of cervical carcinoma were documented in each group. Our previous study demonstrated that 80.2% of LSIL Paps tested positive for HR-HPV by Digene Hybrid Capture 2 HR-HPV DNA test (HC2) and CIN2/3 was found in 14.5% of LSIL/HC2 positive patients and 3.7% of LSIL/HC2-negative patients.

Age	Case No	Positive No	%
20-29	197	148	75.1
30-39	426	348	81.7
40-49	217	153	70.5
50-59	169	118	69.8
>=60	94	63	67.0
Total	1103	830	75.2

Age	HR-HPV Positive			HR-HPV negative		
	F/u No	CIN2/3(%)	CIN1(%)	F/u No	CIN2/3(%)	CIN1(%)
20-29	94	16(17.0%)	62(66.0%)	25	2(8.0%)	14(56.0%)
30-39	227	36(15.9%)	141(62.1%)	34	3(8.8%)	17(50.0%)
40-49	112	11(9.8%)	73(65.2%)	39	1(2.6%)	26(66.7%)
50-59	79	9(11.4%)	54(68.4%)	24	1(4.2%)	12(50.0%)
>=60	28	3(10.7%)	17(60.7%)	13	0(0.0%)	6(46.2%)
Total	540	75(13.9%)	347(64.3%)	135	7(5.2%)	75(55.6%)

**Conclusions:** The Aptima HR-HPV and HC2 tests share similar sensitivity and specificity for the detection of cervical precancerous lesions. HR-HPV test results stratified women with LSIL cytology findings into lower- and higher-risk groups for follow-up for histopathologic CIN 2/3 outcomes.

**358 ThyroSeq Testing for Indeterminate Thyroid Nodules: An Institutional Experience**

*Natasha Darras, Shweta Agarwal, William C Faquin, Helen H Wang, Barry A Sacks, Michiya Nishino.* Beth Israel Deaconess Medical Center, Boston, MA; Massachusetts General Hospital, Boston, MA.

**Background:** ThyroSeq is a next-generation sequencing-based test that assays for a broad panel of mutations and gene fusions that occur in thyroid cancer. Single-institution validation studies have shown ThyroSeq to have high negative (~96%) and positive (~80%) predictive values for malignancy among cytologically indeterminate aspirates. Data regarding the usage and performance characteristics of ThyroSeq outside the validation setting are limited.

**Design:** FNAs from 55 thyroid nodules (52 patients) were sent for ThyroSeq testing from an interventional radiology practice between 12/2014 and 6/2016. Indications for testing included prior indeterminate cytology (n=53) and clinical concern (n=2). Demographic, ultrasound, cytology, and ThyroSeq results were reviewed for all cases. Histopathologic classification was reviewed for resected nodules.

**Results:** ThyroSeq was negative in 64% (35/55, Mutation[-]) and positive for mutation in 35% (19/55, Mutation[+]) of nodules (Table 1). Testing was nondiagnostic in 1 case. No gene fusions were found. To date, 2 of 35 Mutation[-] nodules have been resected, neither of which was histologically malignant. Of 19 Mutation[+] cases, 6 elected clinical monitoring, due in part to the low malignancy risks indicated in the ThyroSeq report for certain mutations and/or low levels at which mutations were detected. Of 8 Mutation[+] nodules that were resected, 7 were histologically benign (6 RAS & 1 EIF1AX mutations), and 1 was papillary carcinoma (BRAF K601E-mutated). Two Mutation[+] nodules are scheduled for surgery at this time. Follow-up data was not available for 3 Mutation[+] nodules.

**Conclusions:** Most resected Mutation[+] nodules were histologically benign in our cohort, in contrast to the ~80% risk of malignancy predicted by ThyroSeq. However, many of the mutations in our cohort were those that the test associates with low-grade tumor behavior (RAS, EIF1AX). For nodules with these mutations, further risk stratification based on ultrasonographic and clinical features may be necessary to guide management (e.g., close clinical/ultrasound monitoring, lobectomy, or total thyroidectomy).



Table 1. Frequency of mutations, resections, and malignancy among ThyroSeq-tested thyroid nodules.

ThyroSeq Result	Resections N (% of ThyroSeq-tested)	Malignant Histology N (% of resected)
Non-diagnostic (N=1)	0	-
Mutation-Neg (N=35)	2 (6%)	0
Mutation-Pos (N=19)	8 (42%)	1 (12.5%)
NRAS (N=9)	5	0
EIF1AX (N=3)	1	0
KRAS (N=2)	1	0
BRAF K601E (N=1)	1	1
TERT (N=2)	0	-
HRAS (N=1)	0	-
TSHR (N=1)	0	-

**359 Usefulness of Liquid-Based Oral/Oropharyngeal Cytology and HPV-Detection for Squamous Cell Carcinoma and Monitoring Treatment Response**

Jorge de la Oliva, Silvia Alos, Rania Kilzieh, Paula Mackers, Carla Fuster, Francisco Perez, Leonardo Rodriguez, Isabel Vilaseca, Carles Marti, Lucia Alos. Hospital Clinic, Barcelona, Spain.

**Background:** Due to the high recurrence rates of squamous cell carcinoma (SCC) of head and neck and de-novo secondary tumours development, a close monitoring of patients is required. The aim of this study is the assessment of the usefulness of cytology and molecular human papillomavirus (HPV) detection of oral and oropharyngeal cytobushing, to early detect de-novo SCC and monitoring the recurrences and response after treatment.

**Design:** Thirty-nine liquid-based cytology on cytobushing specimens from 34 patients with SCC (26 oropharyngeal and 8 oral cavity) were collected previously to tissue biopsy carrying out (29 samples were collected previously to the initial histological diagnosis of SCC; and 10 samples were collected in post-treatment period, after radio and/or chemotherapy). Real-time-PCR based HPV DNA testing, Roche Cobas 4800 High Risk-HPV (HR-HPV) Test was performed in all cases.

**Results:** Thirty-two cytology specimens showed atypical squamous cells consistent with SCC (26 in the initial diagnosis and 5 in the post-treatment period). The diagnosis of SCC was confirmed by subsequent biopsy in all but one case from oral cavity treated with radio and chemotherapy that showed a highly-reactive epithelium (false positive cytology). The negative cytological diagnosis was rendered in 9 cases; 3 of them from oropharynx were false negative cytology. The cytology test yielded a sensitivity of 91,2 % and specificity of 85,7 %.

Nine out of the 26 oropharyngeal SCC (35%) were SCC associated with HPV, confirmed by histological and immunohistochemical study. In all but one case HR-HPV was detected by HPV-DNA Cobas Test. No false positive cases were detected. The HPV-DNA Cobas system gave a sensitivity of 87,5 % and specificity of 100%.

**Conclusions:** Oral/oropharyngeal cytology is a useful non-invasive and cost-effective method to early detect SCC and monitoring patients for recurrences detection after treatment. The Cobas HPV-DNA detection system is a useful method for HPV – associated oropharyngeal SCC.

**360 Rare and Multi-Viral High-Risk HPV Infection in Cervical Glandular Lesions: What Did the ThinPrep Pap Test Diagnoses Show?**

Berly L Diaz-Gomez, Whitney A McCarthy, Joyce Ou, Cherie Paquette, Katrine Hansen, C James Sung, M Ruhul Qudus. Women & Infants Hospital/Alpert Medical School of Brown University, Providence, RI; Clinica Universitaria Colombia-Grupo de Investigación INPAC, Bogota DC, Cundinamarca, Colombia.

**Background:** The worldwide incidence of cervical carcinoma is increasing in unvaccinated countries. A perception exists that the glandular lesions are increasing in recent years in USA. High-risk HPV (hrHPV) 16 and 18 are common in cervical glandular lesions. Genotyping of hrHPV however, has shown frequent infection by multi-viral and rare subtype hrHPV infections. This study documents ThinPrep Pap Test diagnoses in glandular lesions caused by multi-viral and rare subtype hrHPV infection.

**Design:** A retrospective search identified 66 cervical glandular lesions including invasive and in-situ adenocarcinoma from January 2007 to December 2015. DNA extracted from paraffin blocks using QIAam DNA FFPE Kit and tested using GenomeMe™’s GeneNav™ HPV One qPCR Kit (GenomeMe, Richmond, BC, Canada) to detect HPV 16 and HPV 18 and non-specifically other 12 hrHPVs. Subsequently the non-specific hrHPV positive samples were tested by GenomeMe™’s GeneNav™ HPV Genotyping qPCR Kit (GenomeMe, Richmond, BC, Canada) to identify 14 hrHPV individually. The Pap test diagnoses of all cases within prior 24 months were recorded.

**Results:** Genotyping of all 14 hrHPV revealed 14% of cases of glandular lesions had rare subtypes and 20% cases had multi-viral hrHPV infection. hrHPV 45 was identified in 5 (7.5%) cases. Figure 1 shows various rare subtypes of hrHPV found in this study.

Distribution of hrHPV subtypes in our study.

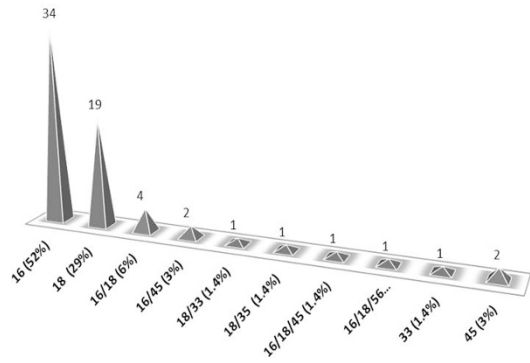
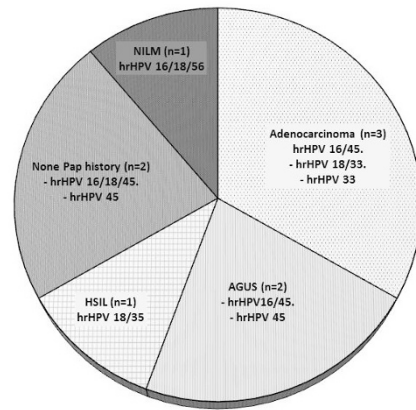


Figure 2 shows the various Pap Test diagnoses and the associated rare/multiviral subtypes of hrHPV.

Pap Test Diagnoses Associated With Rare And Multiviral hrHPV Infection.



**Conclusions:** The spectrum of Pap Test diagnoses in rare and multi-viral subtype hrHPV induced glandular lesions are found to be comparable with lesions caused by more common strains of hrHPV 16/18. We emphasize that Pap Test diagnoses is similar and equally effective in rare and multi-viral hrHPV subtype induced glandular lesions.

**361 Cytomorphologic and Molecular Evolution of EGFR-Mutated Lung Adenocarcinomas with Acquired Resistance to Tyrosine Kinase Inhibitors**

Erika E Doxtader, Jennifer A Brainard, Charles D Sturgis, Vamsidar Velcheti, Yaxia Zhang. Cleveland Clinic, Cleveland, OH.

**Background:** Most lung adenocarcinomas with EGFR mutations initially respond to tyrosine kinase inhibitors (TKIs). However, the majority eventually acquire resistance to TKIs and begin to progress. The aim of our study was to describe the cytologic and molecular findings of TKI-resistant lung adenocarcinomas.

**Design:** We conducted a retrospective search of our laboratory information system to identify EGFR-mutated lung adenocarcinomas diagnosed on cytology from 2012-2016. Clinical information was obtained from the electronic medical record. Patients who developed progressive disease after initial response to TKI treatment and had a cytology specimen at the time of progression were included in the study. Progressive disease was defined as enlargement of primary tumor or metastases, and/or new metastasis.

**Results:** We identified 24 patients with EGFR-mutated lung adenocarcinoma with progressive disease after TKI therapy. There were 16 women (67%) and 8 men (33%), ranging from 32 to 74 years (mean 57, median 56). All patients had a diagnosis of adenocarcinoma prior to TKI therapy. 17 patients had exon 19 mutations, 6 had exon 21 mutations, and 1 had exon 18 and 20 mutations. 21 patients were treated with erlotinib and 3 were treated with either afatinib or gefitinib; all patients had an initial clinical response to TKI therapy. The average interval between initiation of TKI therapy and development of progressive disease was 9 months. Cytology and molecular evaluation was performed after development of progressive disease. The cytologic diagnosis at the time of progression was adenocarcinoma in 21 (88%) and small cell carcinoma in 3 (13%). The small cell carcinomas showed a predominance of malignant cells with scant cytoplasm, nuclear moulding, and finely granular chromatin. Two cases additionally showed a minor component of non-small cell carcinoma, with abundant cytoplasm and prominent nucleoli. The initial EGFR driver mutation was confirmed in 24/24 (100%). 13/24 (54%) were additionally found to have a T790M resistance mutation. None of the 3 patients with small cell transformation had T790M mutations.

**Conclusions:** Lung adenocarcinomas with EGFR mutations and acquired TKI resistance may show cytomorphologic and/or genetic changes at the time of progression. While the majority of patients retain adenocarcinoma cytomorphology, a portion show small cell transformation. More than half of TKI resistant patients acquire T790M mutations.

**362 Orthopedia Homeobox (OTP) Is Preferentially Expressed in Typical Carcinoids of the Lung**

Zachary Dureau, Gabriel Sica, Cynthia Cohen, Taofeek K Owonikoko, Krisztina Z Hanley. Emory University School of Medicine, Atlanta, GA.

**Background:** It is estimated that 27% of neuroendocrine tumors (NET) are associated with distant metastasis. In a significant number of these cases the primary site is unknown or uncertain. OTP has been described as a potentially useful diagnostic marker for lung carcinoid (LC) and for its possible grading implications with regard to separating low grade typical carcinoid (TC) from intermediate grade atypical carcinoid (AC) in surgically resected samples. The goal of our study is to evaluate OTP expression in fine needle aspiration (FNA) samples of NET from various locations, and to correlate TTF1 and MIB-1 expression to determine its utility in the FNA samples for separating LC from other non-lung NET and further separating TC from AC.

**Design:** Anatomic Pathology database was searched for patients diagnosed with NET by FNA samples with subsequent surgical resection. Formalin-fixed paraffin embedded cell block sections from each FNA were stained for OTP, TTF1, and MIB-1. Nuclear expression for OTP and TTF1 were considered positive. Nuclear MIB-1 staining was reported as a percentage. Results were correlated with diagnoses, grade, and primary site on resection specimens.

**Results:** 63 FNA samples of NET with follow up resection specimens were identified. FNA biopsy sites were as follows: 14 liver, 14 pancreas, 13 lymph nodes (LN), 12 lung, 3 retroperitoneum, 2 small intestines, and 5 other. OTP was positive in 12/63 (19%) of NET from the following sites: 8 lung, 2 liver (lung primary), 1 skin (Merkel cell), 1 LN (lung primary). When only well differentiated NET were evaluated, only LC were OTP positive while TTF1 was positive in 67% of LC and 7% of non-lung NET. Within the LC category, OTP was positive in 100% of the TC vs 17% of the AC (Table 1).

	Extrapulmonary (n=44)	Pulmonary (n=15)	AC (n=6)	TC (n=9)
OTP	0% (0)	67% (10)	17% (1)	100% (9)
TTF1	7% (3)	67% (10)	83% (5)	56% (5)
MIB-1			<1-50%	<3%

\*includes undetermined primary site

**Conclusions:** OTP is specific for LC, while well differentiated non-lung NETs are negative for OTP. In addition, OTP preferentially stains low grade TC rather than intermediate grade AC. When diagnosing a well differentiated NET, OTP staining is highly specific for LC, and the combination of OTP staining with low (<3%) MIB-1 index would be highly suggestive for a low grade TC.

**363 Correlation of Unsatisfactory Liquid-Based Papanicolaou Tests with HPV Positive Status: Retrospective Study in a Large Community-Based Clinical Practice**

Elena Enbom, Evan Yung, Juan Felix. LAC+USC Medical Center, Los Angeles, CA.

**Background:** Unsatisfactory Papanicolaou (Pap) tests (UPT) are associated with increased risk for high-grade dysplasia (CIN II-III). The current recommendation of American Society for Colposcopy and Cervical Pathology (ASCCP) on UPT management is to repeat the test within 2 to 4 months. However, this recommendation was based on conventional preparations and was established prior to the 2001 Bethesda System classification. Data concerning UPT in liquid-based preparations is limited. The objective of this study was to evaluate the utility of HPV testing in our patient population for stratification and guidance on management of unsatisfactory Pap results.

**Design:** A retrospective search of LAC+USC Medical Center Institutional Pathology electronic database was performed over a period of 15 months in female patients of ages between 30 and 65 for cases diagnosed as unsatisfactory, ASCUS, LSIL, ASC-H, and HSIL, and compared to that of NILM category. The HPV positive rate was calculated in each category. Inclusion criteria comprised of available Pap test diagnosis and corresponding HPV co-test result. For statistical analysis Fisher's exact test was used, with  $p < 0.05$  being considered as statistically significant.

**Results:** Within 15 months period 166 women had unsatisfactory Pap tests. The mean age was 48.6 years. HPV positive rate in this group was 5.4%. NILM category had 225 cases with mean patient age of 48.0, and 5.3% of those were HPV positive. The HPV positive rates in ASCUS (46.5%), LSIL (67.7%), HSIL (89.6%), and ASC-H (71.4%) were similar to rate, previously reported in the literature. There was no statistically significant difference between HPV positive rates in Pap tests diagnosed as unsatisfactory versus NILM ( $p=0.8226$ ) in our patient population.

Pap test categories	Unsatisfactory (UPT)	NILM	LSIL	HSIL	ASCUS	ASC-H
Mean age, yrs	48.6 ±10.8	48.0 ±11.1	46.3 ±11.3	45.2 ±11.7	47.0 ±9.9	51.3 ±4.8
Total number, n	166	225	62	29	316	7
HPV positive, n (%)	9 (5.4)	12 (5.3)	42 (67.7)	26 (89.6)	147 (46.5)	5 (71.4)

**Conclusions:** Our study shows that the rate of HPV positivity in unsatisfactory tests is no different of that in women with NILM result. This rate of HPV detection appears historically appropriate for women in this age group in our study population. Utilizing HPV positivity for directing triage of women with unsatisfactory Pap test can be reasonably considered.

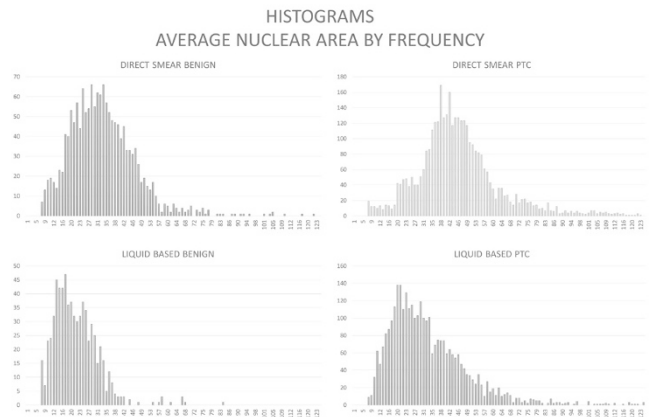
**364 Use of Novel Image Analysis to Characterize and Quantify Nuclear Features of Papillary Thyroid Carcinoma**

George Eng, Rema A Rao, Ivan Chebib. Massachusetts General Hospital, Boston, MA; 2New York-Presbyterian Hospital and Weill Cornell Medical College, New York, NY.

**Background:** Image analysis is a powerful emerging tool used in cytology, though has had limited use in the diagnosis and characterization of papillary thyroid carcinoma (PTC). This is partly due to differences in practice specific preparation methods, either direct smear or liquid based preparation. We endeavored to develop a novel image segmentation program to aid and characterize the nuclear features produced by the two preparation methods.

**Design:** Cases collected from two separate institutions with both direct smears and liquid based preparations were studied. Color images were photographed using the same camera and microscope to minimize variability. A novel imaging algorithm was written as a JavaScript for the ImageJ software. Briefly, it consists of transformation of the images into CIE Lab color space, thresholding along the primary color axes (Red,Blue) binary thresholding and watershed transformation. This yielded high fidelity nuclear segmentation and various image features, such as size, anisotropy and nuclear contours were then extracted.

**Results:** Robust nuclear morphometric data was obtained across all four case types direct smear, benign and PTC, and liquid based cytology benign and PTC, with a total of 22,337 nuclei characterized. Due to the statistical power of the number of nuclei characterized, there were significant differences identified in multiple morphometric features: area, perimeter, and anisonucleosis ( $p<0.005$ ). To demonstrate the overall sizes of the nuclei, histograms for average nuclear area are shown in the figure.



Interestingly, the average size of a PTC nucleus shrunk to the average size of a benign nucleus on direct smear, which may explain diagnostic challenges when comparing the two preparation methods.

**Conclusions:** Image processing can robustly characterize nuclear changes in PTC or in benign thyroid cells, in either liquid based preparation or by direct smears, providing new tools to create and provide improved granularity of characterizing biologic phenomenon.

**365 Double Staining: The Diagnostic Utility in Non-Small Cell Lung Carcinoma in an Era of Tissue Conservation**

Abdulwahab Ewaz, Cynthia Cohen, Momin T Siddiqui. Emory University School of Medicine, Atlanta, GA.

**Background:** In an era of targeted therapy and its impact on patient therapy, distinguishing pulmonary squamous cell carcinoma (SQCC) from adenocarcinoma (ADC) is imperative. Immunohistochemical (IHC) staining for p40, p63 and Cytokeratin 5 (CK5) are useful for SQCC, while TTF-1 and Napsin-A are used for confirming ADC. Fine needle aspiration cell blocks (CB) have limited tissue for IHC and molecular testing. Hence double IHC staining is helpful for tissue conservation for molecular analysis.

**Design:** Twenty six confirmed lung SQCC and 35 ADC CB were selected for IHC analysis. Double staining with p40/CK5 and p63/CK5 was performed on all SQCC, and TTF-1/Napsin-A double stain was performed on all ADC. P40, p63 and TTF-1 were interpreted as positive if brown nuclear staining was detected. CK5 and Napsin-A were interpreted as positive if red cytoplasmic staining was detected. The result was rendered positive if at least 5% of neoplastic cells were immunoreactive for the double staining of tumor cells. Follow-up molecular testing was performed on all ADC.

**Results:** In our study, p40/CK5 double stain was as sensitive (88%) as p63/CK5 double stain in detecting SQCC of the lung, it showed higher specificity (100%), PPV (100%), NPV (91%), and overall diagnostic accuracy (95%) in comparison to p63/CK5 double stain, which were 80%, 79%, 89%, and 84% respectively.

IHC	SQCC (26)	ADC (35)
P40/CK5	23 (88%)	
P63/CK5	23 (88%)	
TTF-1/Napsin A		26 (74%)

	Stain	Sensitivity, %	Specificity, %	PPV, %	NPV, %	Accuracy, %
SQCC	P40/CK5	88	100	100	91	95
SQCC	P63/CK5	88	80	79	89	84
ADC	TTF-1/Napsin-A	74	96	96	71	83

**Conclusions:** P40/CK5 double stain has higher specificity, Positive Predictive Value (PPV), Negative Predictive Value (NPV), and overall accuracy compared to p63/CK5 combined stain in diagnosis of lung SQCC. TTF-1/Napsin A double stain is a valuable marker with high specificity, PPV, and diagnostic accuracy in diagnosing lung ADC. The usage of P40/CK5 and TTF-1/Napsin-A as a panel can be advocated for confirming and further characterizing non-small cell carcinoma of the lung. Double staining with these stains utilizes only 3 microns (2 ribbons) each, of tissue from the CB. This can successfully conserve tissue for molecular analysis from CB samples. In our cohort, all diagnosed ADC yielded adequate tissue from CB for additional molecular testing, thus confirming the usefulness of double staining IHC panels for tissue conservation.

### 366 Efficacy of Immediate Assessment (IA) Telepathology for Ultrasound-Guided Fine Needle Aspirations (US-FNAs) at a Remote Facility

Jessica M Farrell, Gregg A Staerckel, Michael W Riben, Olivia Saavedra, Nancy P Caraway. MD Anderson, Houston, TX.

**Background:** The need for real time anatomic pathology services has grown as healthcare systems, traditionally found at large medical centers, expand into small communities. Telepathology can provide IA of cytology tissues. This study determines the accuracy rate of IA telepathology of US-FNAs for an offsite facility by comparing IA to the final diagnoses.

**Design:** The pathology database was searched for IA telepathology US-FNAs performed at a regional care center from 8/2014 to 6/2016 (IRB approved study). 674 consecutive US-FNAs from 444 patients (352 women/92 men; age range, 21-92 years) were obtained. FNA sites included lymph node (345), breast (178), thyroid (71), and others (80). FNAs were evaluated for ancillary studies and subsequent patient management.

**Results:** FNA IA diagnoses included 275 (41%) benign, 182 (27%) malignant, 162 (24%) further review needed, 37 (5%) indeterminate/borderline cellularity, and 18 (3%) non-diagnostic cases. Final FNA diagnoses rendered included 391 (58%) negative for malignancy, 205 (30%) malignant, 34 (5%) atypical/suspicious for malignancy, and 18 (3%) non-diagnostic specimens. Concurrent core biopsy was recommended in 42 cases and 83 cases had ancillary studies. The majority (99%) of US-FNAs demonstrated concordant preliminary and final diagnoses. A major discrepancy occurred in 1 case, while 8 cases had minor discrepancies.

**Conclusions:** Telepathology at an offsite facility can be utilized for IA to provide accurate diagnoses and guide additional on-site tissue acquisition, as needed.

### 367 Fine Needle Aspiration of Lipoblastoma: Clinical, Cytological and Molecular Features

Joana Ferreira, Ricardo Fonseca, Maria M Lemos, Saudade Andre. IPO Lisboa Francisco Gentil, Lisboa, Portugal.

**Background:** Lipoblastomas are rare, benign adipocytic tumors that present during infancy and early adulthood. In FNA material, the differential diagnosis includes both benign and malignant neoplasms namely myxoid liposarcoma which can have identical morphology but usually occurs in a different clinical setting. In a few cases, especially in adolescents and young adults, this can be problematic. In about 70% of cases, these tumors carry abnormalities in chromosome 8, leading to rearrangements of the PLAG1 gene although other genetic abnormalities have been described involving mostly chromosome 8.

**Design:** We report a series of histologically proven lipoblastomas, with previous FNA cytology, from 9 patients (10 samples), and describe its cytological and molecular features.

**Results:** Nine patients (5 males, 4 females, median age: 2.5years (10months-13 years)) presented with soft tissue masses in the thorax (3), abdomen (2), axilla (2) and thigh (2). In two patients, the FNA diagnosis was inconclusive due to hypocellularity and in one other patient a diagnosis of 'benign lipomatous tumor' was rendered due to the inexistence of lipoblastoma diagnostic features. In one case, FNA confirmed disease relapse. In the remaining 6 samples, a correct preoperative FNA diagnosis was done. The smears were hypo or moderately cellular and contained fragments of mature adipose tissue with thin branching vessels, admixed with some lipoblasts in a myxoid matrix. Spindle cells and naked fusiform nuclei with no cytological atypia were observed in the background. No necrosis or mitotic figures were present. Three out of the four cases tested for PLAG1 rearrangement using FISH break apart probes harbored this alteration. In one case, this was done using the FNA smears and the result was positive. Analysis by aCGH was conducted in one patient with no amplification of the 8q region. Excision was complete in all but three cases, two of which recurred. One of the patients which recurred (who had a PLAG1 negative tumor) underwent re-surgery and adjuvant chemo and radiotherapy with no success and died from local progression of the disease. All remaining patients are alive and well (median follow-up: 5years).

**Conclusions:** The treatment of lipoblastoma requires complete excision and surveillance for recurrence. FNA, especially if used together with molecular biology techniques (PLAG1 FISH analysis), is a reliable, accurate and useful tool both for primary and relapse diagnoses.

### 368 The Value of Cytological Examination in Cervical High Grade Squamous Lesions Undetected by Human Papillomavirus (HPV) Molecular Testing

Evan J Fowle, Priscila Andrade, Rajmohan Murali. Memorial Sloan Kettering Cancer Center, New York, NY.

**Background:** Primary cervical cancer screening has traditionally been based on cytological examination of cervical smears. In 2014, the US Food and Drug Administration approved high-risk human papillomavirus HPV (HR-HPV) molecular testing for primary cervical cancer screening. The aim of this study was to investigate the frequency of high-grade squamous intraepithelial lesion (HSIL) that would be missed by HPV testing alone (in the absence of cytological examination).

**Design:** We identified patients who had cervical or vaginal smears with a diagnosis of negative or squamous abnormality, who underwent concurrent HR-HPV testing at Memorial Sloan Kettering Cancer Center between January 2013 and December 2015. HR-HPV genotyping was performed by a polymerase chain reaction-based assay (Cobas® HPV Test, Roche Diagnostics, Indianapolis IN) and results were reported as being negative or positive for types 16, 18 and/or Other (types 31/33/35/39/45/51/52/56/58/59/66/68). We analyzed associations of HR-HPV test results with the cytology findings, and histopathology findings when available, in cases in which the cytology was negative or showed a squamous abnormality.

**Results:** Cytology was negative or showed a squamous abnormality in 3252 patients. Cytological diagnoses were: negative (2748, 84.5%); atypical squamous cells of uncertain significance, ASC-US (344, 10.6%); atypical squamous cells, high-grade lesion cannot be excluded, ASC-H (37, 1.1%); low-grade squamous intraepithelial lesion, LSIL (84, 2.6%); and HSIL/SCC (39, 1.2%). HR-HPV test was negative in 23 (27.4%), 10 (27.0%) and 5 (12.8%) cases diagnosed as LSIL, ASC-H and HSIL, respectively. Surgical biopsy/resection was performed in 3 of the 5 HSIL cases, and showed HSIL in 2 cases and squamous cell carcinoma (SCC) in one case.

**Conclusions:** 12.8% of high-grade squamous lesions (HSIL/SCC) would have been undetected by HR-HPV testing alone without concurrent cytological examination. Though our patient cohort (which is high-risk and is derived from a major cancer center) is not representative of a general screening population, our findings nevertheless stress the importance of cytological examination in conjunction with HR-HPV molecular testing to maximize the likelihood of detection of high-grade cervical squamous lesions.

### 369 Investigating Molecular Profiles in Residual Needle Rinses from Thyroid FNA Specimens

Maren Fuller, Dina Mody, April M Hull, Kristi Pepper, Heather Hendrickson, Randall Olsen. Houston Methodist, Houston, TX.

**Background:** Thyroid nodules have a high prevalence in the general population. Fine needle aspiration (FNA) biopsy is a minimally invasive, cost-effective, standard method to collect tissue from thyroid nodules for cytologic examination. However, approximately 15% of thyroid FNA specimens cannot be unambiguously diagnosed as benign or malignant. Since the risk of malignancy in these indeterminate cases is not insignificant (approximately 5-30%), they present a clinical dilemma to the pathologist and endocrinologist. A molecular test that could predict indeterminate thyroid FNA biopsies as being benign or malignant could improve patient care by decreasing the number of repeat procedures and unnecessary surgeries.

**Design:** We hypothesized that next generation sequencing of residual needle rinse specimens from indeterminate thyroid FNA biopsies is feasible and may predict a benign or malignant diagnosis. 24 residual needle rinse specimens from 23 patients with indeterminate (n=9), benign (n=9) or malignant (n=6) thyroid FNAs were selected for molecular analysis, including 22 samples collected in CytoLyt solution and 2 samples collected in RPMI media. The molecular genetic signature of each nodule was determined using two assays performed in our clinical molecular diagnostics laboratory. First, next generation sequencing was performed on DNA to detect mutations in 50 genes commonly associated with human malignancy. Then, next generation sequencing was performed on RNA to detect gene rearrangements, splice site variants and copy number variants associated with endocrine tumors.

**Results:** Interpretable data were generated from 24/24 residual needle rinse specimens. Gene mutations were detected in 2/7 indeterminate cases. KRAS G60R was detected in one case, and KDR K286N and APC I1557Y was detected in the other. Of the 5 indeterminate cases without a gene mutation detected, 1 had follow-up and was found to be benign. Consistent with its known role in thyroid malignancy, BRAF V600E was detected in 4/6 of malignant cases. NRAS Q61R was detected in 1/9 benign cases. No gene rearrangements were detected.

**Conclusions:** Residual thyroid FNA needle rinses are an adequate source of material for molecular diagnostics testing. In this modestly sized study, gene mutations were identified in specimens with indeterminate cytology. This has the distinct advantage of potentially eliminating the need for additional FNA passes into dedicated media or the need for an additional procedure. Additional investigation with a larger sample size and additional follow-up is needed to confirm the clinical utility of our proposed strategy.

### 370 Performance of the Aptima and Cobas HPV Testing Platforms in Detecting High Grade Cervical Dysplasia and Cancer

Yimin Ge, Paul Christensen, Eric Luna, Donna Armylagos, Mary R Schwartz, Dina Mody. Houston Methodist Hospital, Houston, TX; Weill Medical College of Cornell University, New York, NY; BioReference Laboratories, Houston, TX.

**Background:** HPV tests and genotyping have been used in clinical risk assessment. The purpose of this study was to analyze the performance of two common HPV testing platforms in detecting high-grade cervical lesions.

**Design:** From January 1 to December 31, 2015, 2241 Pap tests with follow-up biopsies were analyzed along with results of HPV tests performed on Aptima and Cobas platforms. A biopsy diagnosis of CIN2 was confirmed with p16/Ki-67 immunohistochemistry. Endometrial lesions were excluded from the study.

**Results:** Table 1 summarizes the HPV testing and follow-up biopsy results. There were 2052 cases tested on the Cobas platform and 189 on the Aptima platform. Both HPV testing platforms were highly sensitive (98% for Cobas, 97% for Aptima) for high grade squamous intraepithelial lesion and carcinoma (HSIL+). Compared with Aptima HPV testing, the Cobas HPV testing showed higher positive rates in follow-up biopsies with diagnoses of benign (78% vs 48%) and LSIL (89% vs 66%). The Aptima HPV testing had a significantly higher specificity for HSIL+ lesions (42%) in biopsy than Cobas HPV testing (16%, p<0.0001). Overall, the performance of Aptima HPV testing was superior to Cobas HPV testing in detecting HSIL+ lesions in biopsy by providing significantly higher positive predictive accuracy (24% vs. 16%, p<0.03) and overall accuracy (51% vs. 28%, p<0.0001).

HPV test results		Biopsy results n (%)			Total
		Benign	LSIL	HSIL+	
Cobas	+	662 (78)	817 (89)	281 (98)	1760
	-	187 (22)	99 (11)	6 (2)	292
Aptima	+	30 (48)	62 (66)	29 (97)	121
	-	33 (52)	34 (34)	1 (3)	68
Total		912	1012	317	2241

**Conclusions:** While both Cobas and Aptima platforms offer highly sensitive tests for high-grade cervical lesions, Aptima HPV testing demonstrated significantly higher specificity and positive predictive accuracy for HSIL+ lesions in follow-up biopsies than Cobas HPV testing. The considerable difference in detecting high-grade cervical lesions may be related to the significant increase in E6/E7 expression following HPV DNA integration into host genome in high-grade cervical lesions. The significantly higher specificity and overall accuracy of Aptima HPV testing for high-grade cervical lesions may prove useful in clinical risk stratification by identifying high risk populations who need immediate treatment and close follow-up.

**371 Detection of Mismatch Repair Protein Expression by Immunohistochemistry on Cytopathology Specimens: Implications for PD-1 Blockade Therapy**

*Adam J Gomez, Soo-Ryum Yang, Steven Long, Teri Longacre, Christina Kong.* Stanford Health Care, Stanford, CA.

**Background:** Determining mismatch-repair (MMR) status on cytology and core biopsy specimens has become important for clinical management since MMR-deficient tumors have an improved response to PD-1 blockade as compared with MMR-proficient tumors. In this study, we evaluated the advantages and limitations of detecting MMR deficiency on small specimens.

**Design:** The pathology database was searched for body fluid, fine needle aspiration (FNA), and core biopsy specimens that had undergone immunohistochemical (IHC) staining for MMR proteins MLH1, PMS2, MSH2, and MSH6 at our institution. Slides were reviewed to assess tumor cellularity: <20 cells, 20-40 cells, and >40 cells. Medical records were reviewed to determine clinical implications of detecting MMR deficiency. **Results:** MMR IHC slides from 24 FNA and/or core biopsy and 2 body fluid specimens were available for review (Table 1). PD-1 blockade therapy was initiated for 1 patient with pancreatic adenocarcinoma after confirmation of known Lynch syndrome (pancreas FNA with MSH6 loss). Follow-up was not available on the remaining cases with MMR loss. 3 cases showed lack of staining for some (1-MSH6, 1-MLH1/MSH2/MSH6) or all MMR markers (1) but were scored as equivocal due to the absence of positive internal (+) control (1 fluid, 2 FNA/core).

MMR Status	Total Cases (n)	<20 tumor cells (n)	20-40 tumor cells (n)	>40 tumor cells (n)	Diagnosis (n)
Intact	20*	1	3	16	Metastatic colorectal adenocarcinoma (7) Metastatic esophageal adenocarcinoma (1) Pancreatobiliary tract adenocarcinoma (6: 4 primary, 2 metastatic)Mucinous neoplasm of the pancreas (1)Metastatic adenocarcinoma consistent with Müllerian primary (4)
Loss of MSH6	2	N/A	1	1	Pancreatobiliary tract adenocarcinomaMetastatic adenocarcinoma consistent with Müllerian primary (fluid)
	1	N/A	N/A	1	Metastatic colorectal adenocarcinoma
Equivocal	3	1	1	1	Pancreatobiliary tract adenocarcinoma (3)

**Conclusions:** MMR status can be successfully assessed on FNA, body fluid and core biopsy samples of a variety of neoplastic tissues. Detection of MMR deficiency is possible with as few as 20-40 tumor cells in FNA cell block sections and may allow for initiation of PD-1 blockade therapy prior to tumor resection. Intact MMR expression can be detected even when <20 cells are present. Equivocal MMR IHC was due to absence of an internal (+) control and can be seen over a range of cellularity.

**372 Panther Aptima HPV Assay Performance on FNA SurePath Samples of the Head and Neck: Validation and Early Experience at a Large Academic Center**

*Christopher C Griffith, Charles E Hill, Mihir Patel, Alessandra Schmitt, Melinda Lewis, Heather H Jones, Momin T Siddiqui.* Emory University, Atlanta, GA.

**Background:** Human Papillomavirus (HPV) status is an increasingly important feature of head and neck squamous cell carcinoma and this is especially true in cases of neck metastasis of unknown primary which are frequently diagnosed on fine needle aspiration (FNA). HPV status as determined by p16 immunostain and/or HPV in situ hybridization (ISH) on cell block material is often accurate but interpretation of results in this setting is challenging. Molecular assays on liquid based cytology samples identical to those used for cervicovaginal cytology samples is a potential alternative that requires independent laboratory validation.

**Design:** Samples were collected in SurePath (Becton Dickinson) media at the time of aspiration and HPV testing was performed from this suspension using the Panther Aptima HPV assay kit (Hologic). A total of 19 samples (6 clinical FNAs, 13 aspirates from excised node dissection) from 18 patients were included in the initial validation set. Aptima HPV results were correlated with tumor HPV status as determined by p16/ISH. **Results:** 11 tumors were determined to be HPV positive by p16/ISH and all were positive with the Aptima HPV assay. Of 8 cases in which HPV status was determined

to be negative by p16/ISH, 7 were negative with the Aptima HPV assay but one case tested positive. The overall correlation between p16/ISH and the Aptima Assay was 94.7% (18/19) with 100% sensitivity (11/11) and 87.5% specificity (7/8) for detection of HPV. The single false positive case was a keratinizing laryngeal squamous cell carcinoma which was p16 and ISH negative.

**Conclusions:** The Panther Aptima HPV assay is highly accurate and sensitive for determining HPV status on head and neck aspirate specimens. Based on the initial validation set, HPV testing of aspirate material collected in SurePath media using Panther Aptima HPV assay is now available as a clinical test at our institution. This new assay is expected to be an improvement over the current practice of determining HPV status using p16 as a surrogate marker sometimes with the addition of HPV ISH on cell block. Additional prospective results following the recent validation of this test at our institution will also be presented.

**373 Cytologic Diagnosis of Lymphoma and Leukemia in Effusion Fluids: A Series of 88 Cases**

*Fatima T Hamadeh, Aman Ramella, Olaronke Oshilaja, Jordan P Reynolds.* Cleveland Clinic, Cleveland, OH; St. Vincent Medical Center, Cleveland, OH.

**Background:** Lymphomas and leukemias are among the most common causes of malignant effusion. We wanted to evaluate the effectiveness of fluid cytology together with the commonly used ancillary studies in making precise lymphoma/leukemia diagnosis and classification, and to study the spectrum of lymphomas that can be detected.

**Design:** The institution’s pathology database was searched for all cytologic cases of pleural, peritoneal and pericardial fluids positive or suspicious for lymphoma or leukemia from 1/2000-12/2014 (15 year period). Cases signed out as “cannot exclude low grade lymphoma” were excluded. Clinical data was collected from patient medical records.

**Results:** 112 samples from 88 patients fulfilled the study criteria. Of those, 68 cases were “positive” and 20 cases “suspicious for malignancy”. 33 cases (37.5%) did not have a prior diagnosis of lymphoma/leukemia, and were confirmed to be positive, either with a biopsy or ancillary testing on the cytology sample itself.

Ancillary studies performed	No. of cases
Flow cytometry only	45 (51.1%)
Immunohistochemistry (IHC) only	10 (11.4%)
Flow cytometry+ IHC	7 (8%)
None (known history)	26 (29.5%)

Of the 68 positive cases, 38 (56%) were signed out with a general diagnosis “lymphoma/large cell lymphoma/leukemia”. In 16 (23.5%) cases, a specific WHO diagnosis was rendered, and 14 (20.5%) cases had a semi-qualitative diagnosis “B cell lymphoma, large/small”. Patient age ranged 5-88y (median:61.5y), with 55 males and 33 females. Fluid sources were: pleural 70.4%, peritoneal 22.7% and pericardial 6.8%. Table 2 shows the final classification of the cases studied.

WHO 2008 / 2016 Revised Classification	No. of Cases
Acute myeloid leukemia	5
T lymphoblasticleukemia/lymphoma (T-LBL)	8
Peripheral T cell lymphoma, NOS	1
Anaplasticlarge cell lymphoma	2
Classical Hodgkin lymphoma	2
Plasma cell myeloma	1
Lymphoplasmacyticlymphoma	1
Chronic lymphocytic leukemia/ small lymphocyticlymphoma	4
B-cell prolymphocyticleukemia	2
Mantle cell lymphoma	5
Marginal zone lymphoma	2
Follicular lymphoma	7
Diffuselarge B-cell lymphoma (DLBCL)	32
Large B cell lymphoma*	9
Primary mediastinal (thymic) large B-cell lymphoma	2
Plasmablasticlymphoma	1
Burkitt lymphoma	3
B cell lymphoma, undifferentiable (DLBCL/Burkitt)**	1
Total	88

\* Some cases of large B cell lymphoma had insufficient tissue material for further classification.  
\*\* 2016 revised WHO classification: High grade B cell lymphoma, NOS.

**Conclusions:** Cytologic evaluation of serous effusion samples is useful in making the primary diagnosis of hematology malignancies as well as detecting disease relapse and extent. Flow cytometry and IHC not only help confirm the diagnosis and rule out reactive processes, but also allow for a more precise lymphoma/leukemia classification, and should be attempted when possible. Almost any type of lymphoma can involve the serous cavities, the most common in our study being DLBCL followed by T-LBL.

**374 Diagnostic Accuracy of Fine Needle Aspiration in Thyroid Nodules Arising in Patients with Graves’ Disease**

*Jen-Fan Hang, Mohammed T Lilo, Justin A Bishop, Syed Z Ali.* The Johns Hopkins Hospital, Baltimore, MD; Taipei Veterans General Hospital, Taipei, Taiwan.

**Background:** Graves’ disease (GD) is generally diagnosed based on clinical manifestations and serology testing. Fine needle aspiration (FNA) is only used for evaluating solitary nodules in selective cases. However, cytopathologic interpretation in GD is considered challenging due to diffuse hypercellularity, extensive papillary hyperplasia and significant cellular and nuclear atypia, especially in cases that previously underwent radioactive iodine (RAI) therapy. The aim of this study is to evaluate the diagnostic accuracy of FNA in thyroid nodules arising in GD.

**Design:** We retrospectively identified 55 FNAs from 43 patients with GD that underwent thyroidectomy at a major tertiary care center from 1995 to 2016 (22 years). There were

41 females and 2 males with age ranged 23-77 years (mean: 44.4 years). Forty-one patients had available clinical information regarding treatment prior to the surgery (5 with RAI and 36 with anti-thyroid medications).

**Results:** Of the 43 patients, 9 had neoplastic nodules (5 had papillary thyroid carcinomas (PTCs) and 4 had follicular adenomas (FAs)) while 34 had only diffuse hyperplasia in the thyroidectomy. Of the 5 patients with PTCs, FNA was interpreted as PTC in 3, atypia of undetermined significance (AUS) in 1, and adenomatoid nodule (AN) in 1 (a 0.5 cm microcarcinoma was found incidentally). Of the 4 patients with FAs, FNA was interpreted as follicular neoplasm (FN) in 2, AUS in 1, and AN in 1. The neoplastic nodules were successfully detected in 7/8 (87.5%) and correctly categorized in 5/8 (62.5%). Of the 42 nodules from the 34 patients without neoplastic nodules, FNA was interpreted as non-diagnostic in 2, AN in 23, AUS in 14, FN in 1, and suspicious for PTC in 2. The rate for FNA overinterpretation (AUS or above) in hyperplastic nodules was 17/42 (40.5%). Among the 40 hyperplastic nodules in 32 patients with prior treatment information, the correlation between patients with RAI and cytologic diagnosis of AUS or above was higher than patients with only anti-thyroid medications but does not reach statistical significance due to limited case number (3/3(100%) vs 14/37(37.8%),  $p = 0.0688$ ).

**Conclusions:** FNA is a useful diagnostic tool for identifying neoplastic nodules arising in GD. The rate of indeterminate diagnoses in hyperplastic nodules is significantly high (40.5%). Cytological atypia is common in nodules arising in GD. Awareness of clinical information regarding prior treatment for GD may be helpful to reduce the rate of indeterminate diagnoses.

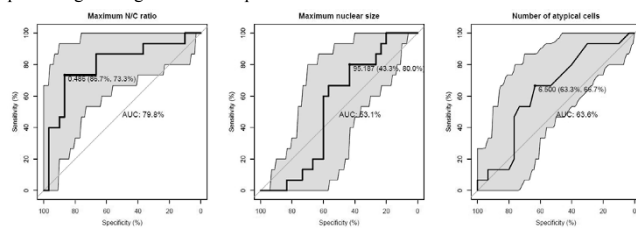
**375 Maximum N/C Ratio in the “Atypical Urothelial Cells” Category Correlates with Follow-Up Malignant Results in Liquid-Based Voided Urine Specimens**

*Jen-Fan Hang, Vivek Charu, Mingjuan L Zhang, Christopher Vandebussche.* The Johns Hopkins University School of Medicine, Baltimore, MD; Massachusetts General Hospital, Boston, MA.

**Background:** An elevated nuclear/cytoplasmic (N/C) ratio of at least 0.5 is a strict but required criterion for the diagnosis of “Atypical Urothelial Cells (AUC)” in the Paris System for Reporting Urinary Cytology (TPS). This criterion has not been validated in terms of predicting malignant results on follow-up surgical pathology.

**Design:** To validate the N/C ratio cut-off value and its predictive power of a follow-up malignant result, we retrospectively retrieved voided urine specimens diagnosed with “AUC” from 2010 to 2012, a period prior to applying TPS criteria. Fifteen AUC cases with a follow-up malignant result (AUC-M), which was defined by biopsy-proven high-grade urothelial carcinoma within a 6-month period following cytologic examination, were included. For comparison, 30 AUC cases with follow-up benign result (AUC-B), which was defined by negative follow-up cytology or histology for at least 3 years, were used. A total of 324 atypical cells were photographed and digitally evaluated using Adobe Illustrator.

**Results:** There were no significant differences in age, sex, and race between the two groups. On average, maximum N/C ratios were significantly different between AUC-M and AUC-B groups (0.52 vs 0.43,  $p=0.0058$ ), while maximum nuclear sizes (153.43 vs 209.43  $\mu\text{m}^2$ ,  $p=0.2305$ ) and the number of atypical cells (10.13 vs 8.10,  $p=0.3766$ ) were not. Receiver operating characteristic analysis showed that the maximum N/C ratio had the highest discriminatory capacity of predicting a follow-up malignant result (area under the curve: 79.8%; 95% CI: 64.7-94.9). The optimal maximum N/C ratio threshold was 0.486, giving a sensitivity of 73.3% and a specificity of 86.7% for predicting a malignant follow-up result.



**Conclusions:** The identification of atypical urothelial cells with an N/C of 0.486 or above has a high positive predictive value for a follow-up malignant result. It justifies using this N/C ratio as a criterion in the AUC category. Given that small changes in the N/C ratio cutoff result in dramatic changes in sensitivity and specificity, digital imaging analysis might play a role in future practice.

**376 PELP1 Immunostaining in Metastatic Breast Carcinoma in Fine Needle Aspiration and Effusion Specimens: A Comparison with GATA3 Antibody Staining**

*Lakshmi Harinath, Shweta Patel, Edward Lynch, William Thompson, Jan F Silverman.* Allegheny General Hospital, Pittsburgh, PA.

**Background:** PELP1 is a novel nuclear hormone co-regulator that has recently been identified to have diagnostic utility in the detection of metastatic breast carcinoma, especially when the primary tumor is negative for GATA3 in surgical pathology specimens. There are no studies focusing on the efficacy of PELP1 immunostaining in metastatic breast carcinoma in cytology specimens. The goal of this study is to evaluate the efficacy of PELP1 protein expression as compared to GATA3 immunostaining of metastatic breast carcinoma in cytology specimens.

**Design:** We examined 45 previously diagnosed cases of metastatic breast carcinoma in cytology specimens, that included fine needle aspiration and effusion cytology specimens. Some of the cytology specimens also included core needle biopsies. We

stained all of the slides with GATA3 and PELP1 antibody. The intensity of staining and the percentage of stained tumor cells by both the antibodies in each case were graded and the ER, PR and HER2 status was noted. The staining intensity was graded from weak (1+) to strong (3+). The percentage of cells staining with the antibody was calculated as less than 25%, 25-75% and above 75%.

**Results:** We found that 71.1% (32/45) of the cases showed equivalent staining with both the antibodies. The PELP1 antibody had a characteristic delicate, punctate intranuclear staining, in contrast to the GATA3 antibody which uniformly stained the entire nucleus. In 26.6% (12/45) of the cases, GATA3 showed stronger and more extensive staining as compared to PELP1 antibody. However, in 4.44% (2/45) of the cases, PELP1 showed more extensive staining when compared to GATA3.

**Conclusions:** This is the first cytology study reporting the use of the immunohistochemical stain PELP1 for the diagnosis of metastatic breast carcinoma in cytology specimens. Although most of the cases showed similar staining with PELP1 and GATA3, a small percentage stained better with each antibody. Therefore, we believe that concomitant use of both GATA3 and PELP1 antibody staining can potentially increase the detection of metastatic breast carcinoma in cytology specimens.

**377 Targeted KRAS Amplification in Matched Fine-Needle Aspirates (FNA) and Resections of Pancreatic Ductal Adenocarcinoma (PDAC): A Model for Comparing Tumor Source and Tumor Area to DNA Yield**

*Christopher Hartley, Aparna Mahajan, Suzanne Selvaggi, William Rehrauer.* University of Wisconsin Hospital and Clinics, Madison, WI.

**Background:** Molecular testing is often limited by DNA yield from formalin-fixed paraffin embedded (FFPE), or FNA material, and few guidelines exist to aid adequacy. KRAS amplification in PDAC is a model for comparing FNA and FFPE DNA yield and adequacy as KRAS mutation prevalence is near 90%.

**Design:** We studied 15 PDACs with matched FNA and FFPE from 2011 to 2015. Our aims were to compare: (1) DNA yield by NanoDrop® Spectrophotometry and Quantus™ Fluorometry per tumor area in FNA vs. FFPE; (2) Functionality of FNA vs. FFPE DNA for KRAS amplification, normalized to DNA per tumor area. Single FNA smears and H&E slides were imaged with Leica ScanScope. Single FNA smears and 2 FFPE curls (5  $\mu\text{m}$ ) underwent KRAS screening on the Roche LightCycler® 480 in 2 PCR reactions for codons 12 and 13 (K12/13) and codon 61 (K61). Tumor area was calculated with ImageJ software. To compare DNA amplification functionality in FNA vs. FFPE, normalized to area of tumor, we devised a metric: (PCR threshold cycles ( $C_T$ ))\*DNA ng/( $\mu\text{L} \cdot \text{mm}^2$ ). Non-parametric statistics were used.

**Results:** Patient demographics from chart review were as follows: Mean age=64.3 and range=44-75 years; Male:Female ratio=1.67:1. FNAs had more tumor area (median 5.2 vs 1.6  $\text{mm}^2$ ;  $p=0.01$ ) and comparable DNA ng/ $\mu\text{L} \cdot \text{mm}^2$  tumor: Nanodrop  $p=0.19$ ; Quantus  $p=0.66$ , (Figure 1). FNA DNA showed non-significantly fewer ( $C_T$ )\*DNA ng/( $\mu\text{L} \cdot \text{mm}^2$ ) for KRAS amplification (Table 1). All specimens were adequate for KRAS amplification (melt curve results pending sequencing confirmation).

Figure 1: Fluorometric and Nanodrop DNA yields per Tumor Area by Specimen Type

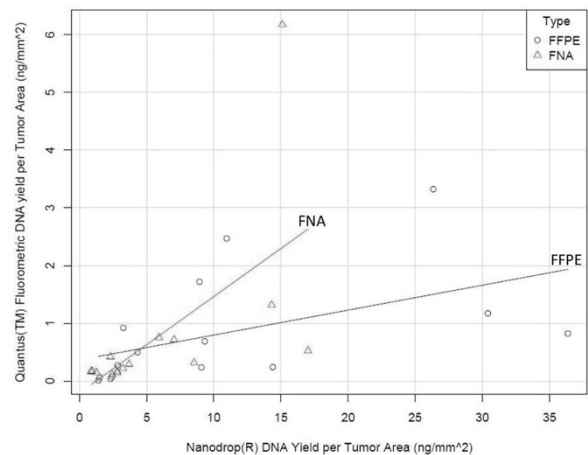


Table 1: KRAS Amplification Functionality by DNA Quantification Method and Specimen Type				
	Q12/13	N12/13	Q61	N61
Median cycle threshold seconds*DNA ng/ $\mu\text{L} \cdot \text{mm}^2$ (FNA, FFPE)**	3.36, 4.70 (p=0.63)	50.6, 77.6 (p=0.41)	3.98, 87.24 (p=0.55)	51.2, 103.4 (p=0.18)
Legend: “12/13” and “61”=KRAS codons 12/13 or 61; “Q”=Quantus; “N”=Nanodrop. **Lower value corresponds to greater DNA amplifiability.				

**Conclusions:** FNA smears may be a more optimal source of DNA for several reasons: (1) intact cells with nuclei are maintained, with less processing (2) tumor has been aspirated from stromal fibrosis (3) greater tumor fraction vs. FFPE.

**378 Risk of Malignancy in Pancreatic Cysts with High-Grade Atypical Cytology**

Raza S Hoda, Ronald Arpin, Matthew W Rosenbaum, Martha B Pitman. Massachusetts General Hospital, Boston, MA.

**Background:** Cytologic criteria for high-grade atypia (HGA) of intraductal papillary mucinous neoplasms (IPMN) were recently reported by the Papanicolaou Society of Cytopathology (Table 1). HGA represents high-grade dysplasia (HGD) or invasive adenocarcinoma (ACA). HGA is classified as Neoplastic:Other category, unless the cytology allows for diagnosis of ACA. HGA is an indication for surgical resection. We reviewed a 1-year cohort of patients (pts) with pancreatic cyst fluid (PCF) cytology to assess the risk of malignancy with HGA and overall ability of PCF cytology to predict high-risk (HR) or malignant cysts.

**Design:** All pts from 6/2015-7/2016 who underwent endoscopic ultrasound guided fine needle aspiration biopsy for a pancreatic cyst at Massachusetts General Hospital were evaluated. Clinical data, cytologic diagnosis and surgical outcomes were documented. Cytology considered high-risk (HR) for malignancy included HGA, neuroendocrine tumor (NET) and ACA. Malignant histology included mucinous cyst with HGD, ACA or NET. Risk of malignancy was determined by histologic outcomes.

**Results:** 90 PCF from 80 pts [54% women; ages 20 to 91 years (mean:66)] were evaluated. 10 PCF (11%) were diagnosed as HR on cytology [6 HGA, 3 ACA and 1 NET], of which 9 had follow-up histology. The absence of HGA or worse was noted in 80 PCF from 70 pts, of which 5 had follow-up histology, none HR. Overall 14 pts had histology (Table 2). HR cytology was 100% sensitive and 83% specific for malignancy. All cysts with HGA were resected with one false-positive of an IPMN with intermediate-grade dysplasia (IGD). The risk of malignancy with HGA cytology was 89%.

**Conclusions:** HR cytology is sensitive and specific for malignant pancreatic cysts. HGA is associated with a high-risk of malignancy (89%) warranting surgical resection.

**Table 1.** Cytologic criteria for HGA for IPMN

Abnormal chromatin pattern
Increased N:C
Background cellular necrosis
Nuclear membrane irregularities
Small cell size

**Table 2.** Cysts with histologic follow-up

Imaging Classification	Cytologic Diagnosis	Histologic Diagnosis
ACA	ACA	ACA
ACA	ACA	ACA
IPMN	ACA	Invasive IPMN
IPMN	Mucinous cyst,HGA	ACA
NS	IPMN,HGA	Invasive IPMN
IPMN	IPMN,HGA	IPMN,HGD
NS	IPMN,HGA	IPMN,HGD
MCN	Mucinous cyst,HGA	IPMN,IGD
NS	NET	NET
IPMN	Mucinous cyst,no HGA	IPMN,IGD
IPMN	Mucinous cyst,no HGA	IPMN,LGD
MCN	Non-mucinous cyst	MCN,LGD
SC	SC	SC
MCN	Non-mucinous cyst	Endometriotic cyst

LGD,low-grade dysplasia;MCN,mucinous cystic neoplasm;NS,not specified;SC,serous cystadenoma

**379 The Prognostic Significance of a Few Cells: Anti-PD-L1 Testing in FNA Samples of Non-Small Cell Lung Adenocarcinoma**

Johnathan Hollyfield, Avani Pendse, Leslie Dodd. The University of North Carolina, Chapel Hill, NC.

**Background:** Programmed death receptor 1 (PD-1) is a protein normally expressed on the surface of T cells and NK cells and is involved in the regulation of T cells. Activation of PD-1 leads to T cell inactivation. Programmed death receptor ligand 1 (PD-L1) has been shown to be up-regulated on the surface of non-small cell lung carcinoma (NSCLC) cells likely due to ALK gene rearrangements, ultimately leading to a decreased host versus tumor response. Treatment with anti-PD-L1 therapy in cases with increased PD-L1 expression improves progression free survival and overall survival when compared to conventional chemotherapy regimens. Currently immunohistochemical (IHC) testing for PD-L1 overexpression, performed on formalin fixed paraffin embedded (FFPE) tissue is the diagnostic procedure of choice and is predominantly performed on core biopsies or resection specimens. The goal of this study was to determine whether fine needle aspiration (FNA) biopsy samples are sufficient to reliably determine PD-L1 status in primary and metastatic lung adenocarcinomas.

**Design:** The electronic medical record (EMR) was searched for lung adenocarcinoma diagnosed by FNA of primary lung and metastatic sites. 39 cases of FNA with cell blocks prepared from aspirated material were identified. H&E stained slides for cell blocks were reviewed for the presence of tumor cells, and IHC for PD-L1 was performed at Clariant Diagnostics. Of note, one block with exhausted tissue and one block with blood only were included as negative controls for the experiment, while positive controls were present on each slide provided by Clariant.

**Results:** 15 cases showed positive expression of PD-L1 on tumor cells in cell blocks from FNA specimens (8 from lung and 7 from metastatic sites). 22 cases were negative for PD-L1 expression on tumor cells. 2 cases did not contain adequate residual tumor cells for evaluation, and both control cases were negative for PD-L1.

**Conclusions:** In this study we have shown that FNA biopsy is an appropriate option for use in PD-L1 testing. Positivity for PD-L1 may be seen at primary tumor sites as well as metastatic sites. Initial sampling of tumors by FNA may be successfully used for diagnostic, prognostic, and therapeutic purposes. Prognostic and therapeutic targets may be identified as early as the time of initial diagnosis

**380 Cytology-Histology Correlation of Atypical Glandular Cells on Routine Pap Test and the Role of HPV Testing**

Heidi Holtorf, Isabella Luna, Dina Mody, Donna Arnylagos, Eric Luna, Mary R Schwartz, Yimin Ge. Houston Methodist Hospital, Houston, TX; Texas Tech University, Lubbock, TX; BioReference Laboratories, Houston, TX; Weill Medical College of Cornell University, New York, NY.

**Background:** Atypical glandular cells (AGC) is an uncommon diagnostic category in routine Pap tests, representing less than 1% of all cases. This diagnostic category represents a unique challenge in that it encompasses a variety of benign, low grade, and high grade lesions of both the cervix and endometrium. Our goal was to correlate follow-up biopsy histology with AGC cytologic findings and determine whether HPV reflex testing is clinically useful in this diagnostic category.

**Design:** A total of 491 AGC cases were identified from 336,064 Pap tests interpreted between March 1, 2013 and July 12, 2016. Follow-up biopsies were available for 251 cases, of which 149 had cytology-HPV testing.

**Results:** The most common histologic diagnosis associated with AGC Pap tests was normal/ benign or low grade lesions (LSIL, DPEm, EmH), accounting for 55% and 24% of all cervical and endometrial biopsies, respectively. High grade cervical or endometrial lesions (HSIL, AIS, or carcinoma) were identified in 21% of biopsies. There was no statistical difference between SurePath and ThinPrep liquid based Pap tests in the detection rate of high grade cervical or endometrial lesions (p=0.21). When HPV testing was combined with Pap test, the likelihood of finding a high grade cervical lesion on biopsy was 26.4 times greater with a positive HPV test (OR = 26.4, 95% CI: 5.84-119.37, p<0.0001). HPV genotyping positive for HPV 16 dramatically increases the likelihood of finding a high grade cervical lesion on biopsy (OR=84, 95% CI: 11.95-590.54, p<0.0001). However, cases with positive HPV 18 or 18/45 had a risk of a high grade cervical lesion similar to those with positive cocktail hrHPV. A negative HPV test had a negative predictive value of 97% (CI: 85-100%).

**Conclusions:** SurePath and ThinPrep liquid based Pap tests are associated with similar histologic findings after a cytology diagnosis of AGC. In both platforms, a diagnosis of AGC correlates with low and high grade lesions that require additional clinical follow-up in about half of the cases. With a diagnosis of AGC on Pap test, HPV testing and genotyping may help in triaging patients for further management.

**381 A Comparative Analysis of the Paris System and Institutional Reporting System for Urine Cytology in Upper Tract Urothelial Specimens**

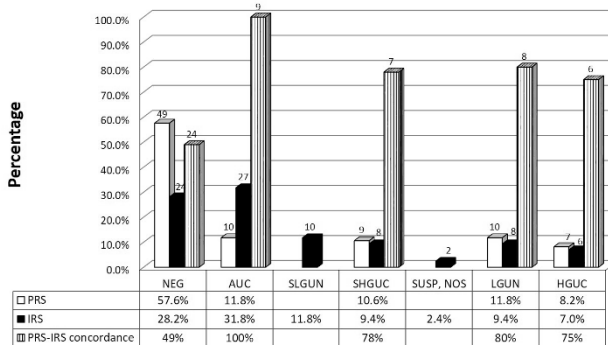
Kim HooKim, James Casey, Rossitza Draganova-Tacheva, Marluce Bibbo, Charlambo Simolidis. Thomas Jefferson University, Philadelphia, PA.

**Background:** Cytology is integral in the assessment of urothelial carcinoma (UC). However, upper urinary tract (UUT) specimens are cytologically challenging due to limited tissue and reactive atypia. At our institution UUT biopsies are processed as cell blocks (BX). We compared our institution's reporting system (IRS) with the recently proposed Paris System for Reporting Urine Cytology (PRS) in UUT specimens and correlated the findings with BX and follow-up resections.

**Design:** 85 UUT TP slides were randomly selected from 64 patients for double-blinded group consensus review. BX and resections were separately reviewed and compared using 1973 and 2004 WHO Classification of Tumors of the Urinary System (LGUC, low grade 1, 2; HGUC, grades 2,3). Cytologic concordance and cyto-histologic correlation using BX and resections as the gold standard was also examined.

**Results:** IRS and PRS had similar rate of high grade urothelial carcinoma (HGUC) (7%, 8.2%, respectively) and cytologic concordance for HGUC was 75%.

**Figure 1. Upper Urothelial Tract Cytology Assessment**



PRS, Paris System for Reporting Urinary Cytology; IRS, Institutional Reporting System; NEG, negative for high grade urothelial carcinoma; AUC, atypical urothelial cells; SLGUN, suspicious for low grade urothelial neoplasia; SHGUC, suspicious for high grade urothelial carcinoma; SUSP\_NOS, suspicious for urothelial carcinoma, not otherwise specified; LGUN, low grade urothelial neoplasia; HGUC, high grade urothelial carcinoma.

Diagnostic yield of BX specimens was 87%. BX interpreted with TP specimens increased neoplastic rate in 27% (n=18) of negative, indeterminate (AUC) and suspicious (SUSP) cases. Thirty-one percent of BX (n=26) had follow-up resections. All IRS and PRS positive cases were confirmed on biopsy and resection (100% positive predictive value). However, 64% of LGUC BX was upgraded to HGUC, and 8 PRS and 2 BX cases were falsely negative for HGUC. Of the 24 HGUC Bx and resection cases, PRS

and IRS correlation was only 21% (PRS reported 32% (n=8) as negative and IRS reported 40% (n=10) as AUC). The overall sensitivity of IRS and PRS for HGUC was 83% and 38%, respectively.

**Conclusions:** The PPV of IRS, PRS and BX for HGUC was 100%. PRS had more false negative cases than IRS, which had a higher sensitivity for HGUC. UUT biopsies processed as cell blocks had 87% diagnostic rate and improved the neoplastic rate of TP cases. However, small biopsies may be falsely negative or under sample high grade areas.

**382 Cytologic Features of Undifferentiated Carcinoma with Osteoclast-Like Giant Cells (U-OGCa) of Pancreas; a Multi-Institutional Clinicopathologic Review of 14 Cases**

*Kim HooKim, Takashi Muraki, Bahar Memis, Rondell Graham, Jiaqi Shi, Daniela Allende, David Schaeffer, Volkan Adsay, Michelle D Reid.* T. Jefferson Uni, Philadelphia, PA; Emory Uni, Atlanta, GA; Mayo Clin, Rochester, MN; Clev Clin, Cleveland, OH; U of Michigan, Ann Arbor, MI; Vancouver Gen Hosp, Vancouver, Canada.

**Background:** U-OGCa has been recently shown to have a protracted course relative to pancreatic ductal adenocarcinoma (PDAC). Its cytologic features have only rarely been described.

**Design:** Cytology material in 14 FNAs from 13 patients with U-OGCa were analyzed for: osteoclastic giant cells (OGCs), spindled tumor cells (SCs), mononuclear tumor giant cells (TGCs), PDAC component, necrosis and acute inflammation.

**Results:** There were 8 F and 5 M, mean age 63 (range 35-75); 8 had cystic component on imaging (1 called "IPMN" and 1 "pseudocyst"). The remainder were solid. TGCs, SCs and OGCs were seen in 12/14 (86%); TGCs were most frequent, followed by SCs then OGCs. Of the 2 cases that lacked these 3 cell types 1 was a 25cm MCN with a 2cm U-OGCa focus that was likely unsampled by FNA. PDAC component was identifiable in 10 (71%). 11 tumors were necrotic and 5 showed background neutrophils. A definitive cytologic diagnosis of U-OGCa was rendered in 6 (43%) FNAs, 4 (29%) were called PDAC, 1 (7%) suspicious for neoplasm, 1 (7%) negative and 2 (14%) poorly differentiated carcinoma. IHC revealed: CD68(+) in OGCs (n=5). Epithelial markers were positive in TGCs and SCs but not OGCs [AE1/3(+) in 6/7, CAM5.2(+) in 2/3 and EMA(+) in 2, p53(+) in 1/2]. Ki67 index was 12%, 18% and 40% in 3 cases. 12(86%) tumors were resected, of mean size 5.3cm (range 1-11) and showed pure U-OGCa (n=3) or mixed U-OGCa and PDAC (n=9) with PDAC ranging from focal (10%) to extensive (40%); 3/8 mixed tumors arose from IPMN (n=1) and MCN (n=2); 5 resected tumors were pT2, 5 pT3 and 1 pT1. All but 1 had negative margins and LNs, but LVI and PNI were identified in 3 cases. 10 had F/U, mean 7.5 mths (0.4-21), 5 died of disease and 5 were alive at last F/U.

**Conclusions:** The 3 classical cell types of U-OGCa are identifiable on FNA in the majority of cases, making cytologic diagnosis possible if considered in the differential. CD68, AE1/3, EMA and Ki67 index are helpful diagnostic stains. A PDAC component is often present in tumors and should be reported. Although 5 patients in this cohort died within a year, U-OGCa has been shown to have a more protracted clinical course and distinct molecular biology from conventional PDAC or "undifferentiated" carcinoma, making its accurate diagnosis on FNA important.

**383 Impact of Biopsy on Management of Renal Lesions**

*Xiao Huang, Xiaoqi Lin.* Northwestern University, Chicago, IL.

**Background:** Previously renal biopsy was used to exclude lymphoma and metastatic malignancy (MM). Currently, renal biopsy is recommended and increasingly being used before ablation and systemic therapy (non-surgery) without previous pathology; and in patients in whom active surveillance is pursued (EAU Guidelines). However, benefits of renal biopsy in patients with prior malignancy history (PMH) is still unclear. **Design:** 235 renal lesions with fine needle aspirate and/or needle core biopsy with touch prep were retrieved. Cytology diagnosis, follow-up surgical diagnosis, flow cytometry, PMH, and therapy were recorded.

**Results:** Table 1. Management of renal lesions based on cytology diagnosis.

Lesion	No.	*Accuracy(%)	PMH(%)	*FU(%)	Surgery(%)	Non-Surgery(%)
*PRCa	156	123/156(79)	56(36)	27(17)	95(61)	34(22)
Lymphoma	10	10/10(100)	4(40)	0(0)	0(0)	10(100)
MM	12	11/12(92)	12(100)	0(0)	0(0)	12(100)
Benign Tumor	24	22/24(92)	18(75)	19(79)	4(17)	1(4)
	33	33/33(100)	12(36)	29(88)	3(9)	1(3)
Total	235	199/235(85)	103(43)	75(32)	102(43)	58(25)

\*PRCa: Primary renal carcinoma including RCC and urothelial carcinoma; I&I: infection and inflammation; Accuracy: Cytology diagnosis accuracy; FU: Follow up. Table 2. Impact of biopsy on management of renal lesions.

Lesion	No.	PMH(%)	FU(%)	Surgery(%)	Non-Surgery(%)
PRM	178	72(40)	27(15)	95(53)	56(31)
Benign	57	30(53)	48(84)	7(12)	2(4)
P value	235	>0.05	<0.01	<0.01	<0.01

Chi-Square test. PRM: Primary renal malignancy.

**Conclusions:** 1. Among patients with PMH, only 15/102 (15%) were MM. Majority were primary renal tumor (PRT) including PRCa, lymphoma and benign tumor (75/102, 74%), and I&I (12/102, 12%). This resulted in suitable treatment for PRT or I&I, and avoidance of unnecessary treatment as stage 4 MM. PMH does not increase incidence of PRT.

2. 57/235 (24%) of renal lesions were benign, which were predominantly successfully managed by active surveillance and significantly reduced unnecessary more aggressive treatments for malignancy, although 53% of them had PMH.

3. 3/10(30%) lymphoma patients had prior lymphoma and 1 (10%) had hepatic cell carcinoma, which leads to suitable chemotherapy.

4. MM includes 3 lung carcinoma, 3 lymphoma, 2 melanoma, 2 esophageal carcinoma, 2 adenoid cystic carcinoma, 2 breast carcinoma and 1 myxoid leiomyosarcoma of uterus.

5. Therefore, it is critical to perform renal biopsy before management of most renal lesions no matter if patient has PMH.

**384 Detection of Gene Fusions Using Cytology Smears and a Next-Generation Sequencing-Based Assay**

*Omar Jaber, Natalya Guseva, Aaron A Stence, Aaron Bossler, Chris Jensen, Deqin Ma.* University of Iowa, Iowa City, IA.

**Background:** Molecular testing for *EGFR* mutation, *ALK* and *ROS1* fusion is routinely performed in patients with stage IV lung adenocarcinoma for assessing the eligibility for targeted therapy. Fine needle aspirate (FNA)-derived material is frequently the only pathologic material available for both morphologic and molecular diagnosis in these patients. In patients with thyroid nodules, the identification of gene aberrations from FNA smears may save the patients from a second surgery. We and other laboratories have shown that cytologic preparations were a reliable source of DNA for mutational analysis. In this study, we tested RNA extracted from cytology smears for detection of gene fusions in lung and thyroid carcinomas by a next generation sequencing (NGS)-based assay.

**Design:** Twelve FNA cases including 5 lung adenocarcinomas, 5 papillary thyroid carcinomas (PTC) and 2 follicular carcinomas (FC) were tested. Areas of interest were scrapped from stained smears using a scalpel. Total nucleic acid was extracted using the Qiagen AllPrep DNA/RNA Kit. Gene fusion and mutational analysis was performed using the Comprehensive Thyroid and Lung Panel (ArcherDx), a NGS-based panel that can detect mutations and gene fusions from the same specimen. Data was analyzed using the analysis pipeline provided by the company.

**Results:** The yields of DNA and RNA ranged from 25 ng to 1.9 µg and 88 ng to 2.2 µg per slide, respectively. Two of 5 lung adenocarcinomas were positive for *ELM4-ALK* fusion, the third one had p.L858R and p.T790M double mutations. One patient with PTC had prior radiation therapy and the tumor was positive for *CCD6-RET* fusion which is commonly seen in patients with radiation exposure, and 1 patient with FC had a *KRAS* p.Q61R mutation. No mutation or gene fusions were identified in the remaining cases (2 lung adenocarcinomas, 4 PTCs and 1 FC). The presence of *ELM4-ALK* fusions and *EGFR* mutations was confirmed by fluorescence in situ hybridization and a different NGS assay (Ion AmpliSeq Cancer Hotspot Panel v2 from Thermo Fisher Scientific), respectively, using corresponding formalin-fixed, paraffin-embedded tissues.

**Conclusions:** Our pilot study showed that cytology smears could be used not only for detection of DNA aberrations but also for gene fusions in lung and thyroid carcinomas, which maximizes the utility of FNA-derived materials and may save patient from additional procedures.

**385 Comparison of Different Prostate Immunohistochemistry Markers in the Cytological Diagnosis of Metastatic Prostatic Adenocarcinoma**

*Liveli Jia, Yiyang Jiang, Amad Awadallah, Claire W Michael.* University Hospitals Cleveland Medical Center/Case Western Reserve University, Cleveland, OH.

**Background:** Diagnosis of metastatic prostatic adenocarcinoma (metPA) in cytology specimens is challenging and frequently requires the use of immunohistochemical (IHC) adjuncts. Recently, prostate specific membrane antigen (PSMA) and NKX3.1 have been shown to be promising adjuncts to determine prostatic origin in surgical specimens. However, the sensitivity and specificity for these two antibodies in cytology specimens were not well established. In our study, we aim to investigate the performance of PSMA and NKX3.1 in the cytological diagnosis of metPA.

**Design:** A retrospective search was performed to identify cytology cases from patients with a past history of prostate adenocarcinoma at our institution from 01/01/2005 to 12/31/2015. Cytology specimens, including fine needle aspiration and body fluid, were routinely processed according to our institutional protocol. Cytology slides including IHC studies, were reviewed along with correlating histopathologic specimens. IHC stains were performed on cell blocks. In addition to staining pattern and intensity, the sensitivity and specificity of two markers were assessed and compared to those of PSA and PSAP markers.

**Results:** A total of 56 cytology cases were retrieved with the following diagnoses: metPA (13), metastatic carcinomas from other or unspecified origins (37), rare atypical cells (4) and benign (2). Additional 9 cases were re-classified as metPA based on positive PSMA and/or NKX3.1 IHC stains. In our cohort of 22 cases of metPA, 18 were positive for PSMA (82%), 15 for NKX3.1 (71%), compared to 9 for PSA (41%) and 11 for PSAP (50%).

IHC Staining	PSMA	NKX3.1	PSA	PSAP
Positive cases	18	15	9	11
Negative cases	4	6	13	11
Sensitivity	18/22 (82%)	15/21 (71%)	9/22 (41%)	11/20 (50%)

PSMA and NKX3.1 were negative in all 6 cases of metastatic carcinoma of other origins evaluated (specificity 100%). PSMA demonstrated strong membranous staining pattern, and NKX3.1 showed moderate nuclear staining, whereas PSA and PSAP frequently presented as weak or focal cytoplasmic staining in metPA cancer cells.

**Conclusions:** Due to the higher sensitivity (82% and 71%, respectively) and specificity (100%), PSMA and NKX3.1 are valuable surrogate markers for metPA in cytology

specimens, with unique and intense staining patterns, when compared with PSA and PSAP markers. Because of their different staining patterns, a dual stain can be performed to increase the efficiency, particularly in specimens with limited cellularity.

**386 FNA Diagnosis of Deep-Seated Lymphoma: An Institutional Experience**

*Ming Jin, Paul E Wakely.* The Ohio State University Wexner Medical Center, Columbus, OH.

**Background:** The evaluation of deep-seated lymphomas can be challenging. It often requires the balancing of diagnostic requirements against the patient's general condition. The deep location makes it uniquely challenging. Controversy remains as to whether image-guided FNA coupled with appropriate ancillary techniques can be used to diagnose deep-seated lymphomas reliably for clinical management.

**Design:** A retrospective search (20 years) was performed to identify image-guided (including EUS, EBUS and CT) FNA cases with definitive or indeterminate (atypical, suspicious) lymphoma diagnoses for intra-thoracic and intra-abdominal deep-seated locations. FNA diagnosis was compared with corresponding surgical pathology (SP) and clinical follow-up. The application of ancillary tests on FNA specimens was also evaluated.

**Results:** 121 cases from 118 patients (M: F=1.1:1, mean age=62) were recovered. Among 95/121 (79%) aspirates that had a definitive lymphoma diagnosis, 50 lacked SP follow-up. Most of these (82%) were examples of recurrent disease, and therapy proceeded based on the FNA diagnosis alone. 44/95 had a FNA diagnosis concordant with corresponding SP diagnosis and 1 case was discordant. Of 44 with concordant SP diagnosis, 25 had further lymphoma subclassification that was concordant with SP. The single discordant case was large cell non-Hodgkin B cell lymphoma on FNA and poorly differentiated neuroendocrine carcinoma on SP in a patient with history of non-Hodgkin B cell lymphoma. No ancillary testing was performed on that FNA specimen. 26/121 (21%) had an indeterminate diagnosis on FNA specimens. Of these, SP confirmed a diagnosis of lymphoma in 21/26 (81%). Indeterminate cytologic diagnosis was due to either an absence of flow cytometry analysis (11/21), or Hodgkin lymphoma (10/21). Of 121 cases, 53 utilized cell-block immunohistochemical stains, 93 flow cytometry, and 29 molecular testing as part of the FNA work-up.

**Conclusions:** FNA plays an important role in the diagnosis and clinical management of deep-seated lymphomas, particularly for recurrent disease. The addition of ancillary techniques, particularly flow cytometry, markedly increases diagnostic accuracy and non-Hodgkin B cell lymphoma subclassification. This study is one of the few large series examining the clinical utility of FNA in the setting of deep-seated lymphomas.

**387 Microfollicular Pattern and Absence of Pseudoinclusions Are Common Cytologic Characteristics in Noninvasive Follicular Thyroid Neoplasms with Papillary-Like Nuclear Features**

*Andrew D Jones, Yanhong Zhang, Alaa Afify, Eric C Huang.* University of California Davis Medical Center, Sacramento, CA.

**Background:** Noninvasive encapsulated follicular variant of papillary thyroid carcinoma was recently revised to noninvasive follicular thyroid neoplasm with papillary-like nuclear features (NIFTP) due to the indolent nature of this tumor. The impact of this paradigm shift on the Bethesda System for Reporting Thyroid Cytopathology (TBSRTC) is uncertain. This study addresses the significance of this reclassification on TBSRTC, and evaluates whether there are cytologic features that can differentiate NIFTP from papillary thyroid carcinoma (PTC).

**Design:** Retrospective review of all thyroidectomies for PTC from 2014-2015 was performed. All cases with prior fine-needle aspirations (FNAs) were reviewed jointly by 3 pathologists to categorize PTCs into classical (cPTC), infiltrative/invasive follicular variant (IFVPTC), or NIFTP. The consensus diagnoses were correlated to the corresponding FNAs according to TBSRTC. All FNAs were blindly evaluated concurrently by 2 cytologists for nuclear, cytoplasmic, architectural, and background features.

**Results:** 47 PTC thyroidectomies (28 cPTC, 10 IFVPTC, and 9 NIFTP) with 51 FNAs were identified. Suspicious for malignancy and malignant cytology were more frequently diagnosed in cPTC (86%) and IFVPTC (67%) when compared to NIFTP (36%). In contrast, a majority of NIFTP were commonly diagnosed as atypia/follicular lesion of undetermined significance (AUS/FLUS; 55%) or follicular neoplasm (FN; 9%) (Table 1). The features most frequently observed in all entities were nuclear grooves (100%) and nuclear crowding (>90%). Microfollicular pattern (82%) and lack of pseudoinclusions (73%) were more commonly encountered in NIFTP. Psammoma bodies were only identified in cPTC.

	cPTC		IFVPTC		NIFTP	
	n	%	n	%	n	%
FNA Diagnosis						
Nondiagnostic / Benign	0	0	0	0	0	0
AUS/FLUS	3	10.7	3	25.0	6	54.5
FN	1	3.6	1	8.3	1	9.1
Suspicious for Malignancy	4	14.3	3	25.0	2	18.2
Malignant	20	71.4	5	41.7	2	18.2
Total FNAs	28		12		11	

**Conclusions:** While NIFTP is more often diagnosed as AUS/FLUS or FN, approximately one third of these lesions can have suspicious or malignant FNA diagnoses. However, the presence of microfollicles and absence of pseudoinclusions are frequently associated with NIFTP and may be helpful features suggesting caution when rendering a suspicious or malignant FNA diagnosis.

**388 Noninvasive Follicular Thyroid Neoplasm with Papillary-Like Nuclear Features (NIFT-P): A Retrospective Institutional Analysis**

*Thomas Joyal, Darcy A Kerr, Jenna Lewis, Monica Garcia-Buitrago, Merce Jordá, Claudia Rojas, Carmen Gomez-Fernandez.* Jackson Memorial Hospital, Miami, FL; University of Miami Hospital, Miami, FL.

**Background:** Due to indolent biologic behavior, encapsulated/noninvasive follicular variant of papillary thyroid carcinoma (EFVPTC) has been recently redefined and reclassified to NIFT-P. Strict histologic criteria has been defined by Nikiforov YE et al, JAMA Oncol 2016. The recommended management for NIFT-P is a hemilobectomy without further treatment (ie. completion thyroidectomy, node dissection (LND), or radioactive iodine (RAI). This shift in categorization will have an impact on preoperative diagnosis of thyroid nodules by FNA. Additionally, the currently accepted malignancy rates, according to the Thyroid Bethesda System, will be impacted by this new classification, as the risk of malignancy is expected to decrease in most, if not all, categories.

**Design:** University of Miami Hospital and Jackson Memorial Hospital department of pathology, sought to review previously diagnosed EFVPTC (between 2010-2016), determine which qualified for NIFT-P reclassification, and retrospectively analyze the preoperative cytology with surgical management (total, hemi, and/or completion thyroidectomy), LND status, and RAI administration.

**Results:** 14 total NIFT-Ps identified [Table 1]. 6/14 received hemilobectomy followed by completion thyroidectomy, 4/14 total thyroidectomy, 4/14 hemilobectomy, 9/14 partial LND and 5/14 RAI. Cytology Bethesda category: BI 1/14; BII 4/14; BIII 5/14; BIV 1/14; BV 1/14; BVI 2/14.

Sex	Cyto dx	Surgical MGMT	LND	RAI
M	IV	Hemi->completion	Y	N/A
M	II	Hemi->completion	Y	N/A
F	III	Hemi->completion	N	Y
F	III	Hemi->completion	N	Y
F	II	Hemi->completion	N	Y
F	III	Hemi	Y	N/A
F	V	Total	Y	N
F	III	Hemi	N	N/A
F	II	Hemi	Y	N
F	III	Total	Y	N
M	I	Hemi->completion	Y	Y
F	II	Hemi	N	N
F	VI	Total	Y	Y
M	VI	Total	Y	N

**Conclusions:** All patients diagnosed with Bethesda category V/VI had a total thyroidectomy and LND. Reclassification requires reevaluation of pre-operative cytology to ensure the best management for patients. Careful review of the cytologic features of NIFT-P will be the subject of a larger multi-institutional study. Previously, a diagnosis of EFVPTC in a hemilobectomy resulted in a completion thyroidectomy 60% of the time accompanied by lymph node dissection and/or RAI. This shift in categorization, will likely result in management changes.

**389 Mutational Panel Performance in Cytologically-Indeterminate Thyroid Nodules**

*Rachel Jug, Grant Harrison, Michael Datto, Xiaoyin "Sara" Jiang.* Duke Health, Durham, NC.

**Background:** Molecular testing is increasingly used to guide treatment for patients with cytologically-indeterminate nodules. Mutational panels such as ThyroSeq allow detection of mutations associated with thyroid neoplasia, however there is a dearth of independent data on performance of these panels from clinical practice.

**Design:** We performed a retrospective study of thyroid nodule cytology cases tested at our institution using UPMC mutational analysis panels (7-gene, ThyroSeq, and ThyroSeq V2). We generally reserve molecular testing for repeat-indeterminate nodules. Surgical pathology results were reviewed for resected nodules.

**Results:** 86 thyroid nodules were tested. Over the study period the methodology shifted from a 7-gene panel to Thyroseq V1 and V2. High-risk (HR) mutations were found in 16 (19%), no HR mutations in 69 (80%), and one sample was insufficient. Of nodules with no HR mutations detected, 32 were treated surgically and resection diagnoses were benign in 31 (97%) nodules and malignant in 1 (3%) nodule, which was a minimally-invasive follicular carcinoma tested with the 7-gene panel. Of nodules found to have HR mutations, 13 were treated surgically and resection diagnoses were malignant in 6 (46%) nodules and benign in 8 (62%) nodules.



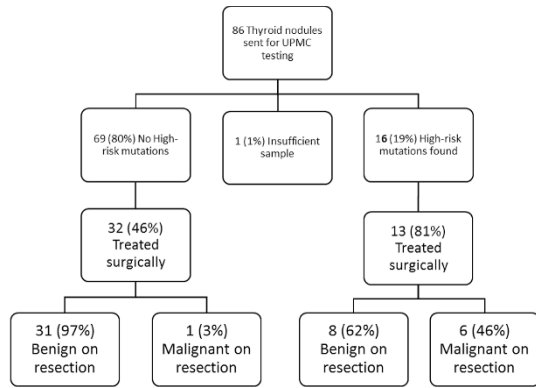


Table 1: Diagnoses at resection of HR mutation-positive nodules

Benign	n (%)	Malignant	n (%)
Follicular adenoma	3(38)	Follicular variant of PTC	4(66)
Nodular hyperplasia	4(50)	Encapsulated FVPTC	1(17)
Chronic lymphocytic thyroiditis	1(12)	Classic papillary thyroid carcinoma	1(17)
Total	8(100)		6(100)

Benign tumors were mostly found to harbor RAS mutations with 1 PTEN mutation and one PAX8/PPARY mutation. The negative predictive value for nodules that went to surgery was 97%, and positive predictive value for nodules that went to surgery was 46%. **Conclusions:** Our experience supports that a negative Thyroseq panel in the context of a cytologically-indefinite nodule is associated with benign disease at surgery. However, the finding of RAS and other mutations associated with follicular-patterned lesions should not be taken as evidence of carcinoma. These findings independently characterize real-world performance of this test modality.

**390 Fine Needle Aspiration Detection of High Grade Dysplasia in Neoplastic Mucinous Cysts of the Pancreas**

Jason Kern, Roghayah Fazeli, Lames Lee, Anne Marie O'Broin, Syed Z.Ali, Christopher Vandenbussche. Johns Hopkins University School of Medicine, Baltimore, MD; Boston University SOM, Boston, MA; Banner University Medical Center Tucson, Tucson, AZ. **Background:** Pancreatic cysts are a common and often incidental finding. The neoplastic mucinous cysts (NMCs), intraductal papillary mucinous neoplasm (IPMN) and mucinous cystic neoplasm (MCN), are the most common and are of particular concern due to their potential for malignancy. These lesions may have varying degrees of dysplasia, and are sometimes associated with invasive adenocarcinoma. This distinction is important in determining management. Fine needle aspiration (FNA) has become an increasingly utilized tool to assess presence of high grade dysplasia (HGD) or invasive carcinoma.

**Design:** This is a retrospective study evaluating cytology-histology correlation of degree of dysplasia within pancreas NMCs. The Johns Hopkins Pathology Data Services database was searched for all cases of pancreas FNA which had corresponding surgical pathology. The presence of at least HGD (including suspicious or positive for adenocarcinoma), designated ≥HGD, was noted in each of the paired surgical and cytology specimens.

**Results:** 1752 pancreatic FNA specimens with corresponding surgical pathology were identified between 1996 and 2015. 292 surgical resections revealed either IPMN or MCN. Overall, the sensitivity of identifying ≥HGD by FNA was 46% and the specificity 91.6% (see figure below). However, when cases were partitioned by time, sensitivity improved from 33.3% from 1996-2005 to 52.3% from 2006-2015.

Results Summary				
<b>ALL DATA</b>				
Surgical Specimen				
	≥HGD	No HGD		
Cyto	58	14	72	Sensitivity: 0.460
	68	152	220	Specificity: 0.916
	126	166		PPV: 0.806
				NPV: 0.691
<b>1996-2005</b>				
Surgical Specimen				
	≥HGD	No HGD		
Cyto	14	4	18	Sensitivity: 0.333
	28	39	67	Specificity: 0.907
	42	43		PPV: 0.778
				NPV: 0.582
<b>2006-2015</b>				
Surgical Specimen				
	≥HGD	No HGD		
Cyto	44	10	54	Sensitivity: 0.524
	40	113	153	Specificity: 0.919
	84	123		PPV: 0.815
				NPV: 0.739

HGD: high grade dysplasia; ≥HGD: HGD or invasive adenocarcinoma; PPV: positive predictive value; NPV: negative predictive value

**Conclusions:** FNA is an important tool for the diagnosis and management of pancreatic MNs. While the diagnosis of cystic lesions by FNA is challenging, the sensitivity of detection of ≥HGD has improved over time. This is likely due to improved FNA

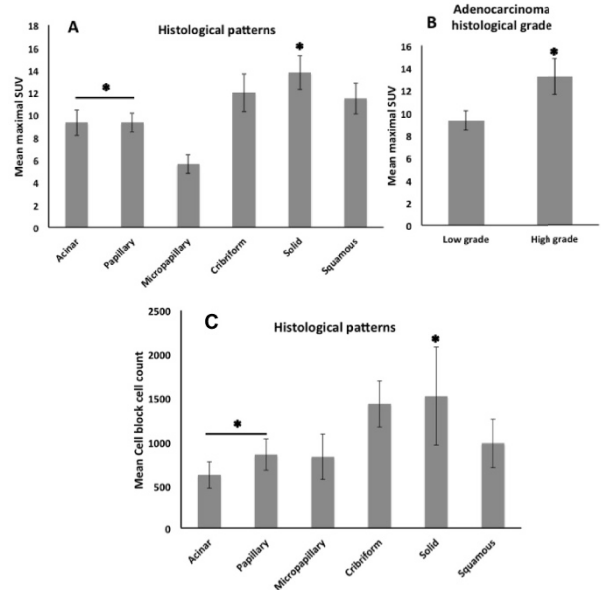
techniques and increased cytopathologist experience as the demand for pancreas FNA has increased. With improved FNA technique, additional cytopathologist experience, and the development of cyst fluid molecular analysis, the sensitivity of detecting these lesions is likely to continue to improve.

**391 EBUS-TBNA in Metastatic NSCLC: Do Cytomorphological Features Correlate with Standardized Uptake Value of PET Scan?**

Kianoosh Keyhanian, Harman S Sekhon. University of Ottawa, Ottawa, ON, Canada. **Background:** Positron emission tomography (PET) and/or CT scan followed by endobronchial ultrasound guided transbronchial needle aspiration (EBUS-TBNA) of the suspicious lymph nodes (LNs) is a standard procedure for pre-operative staging of lung cancer. The objective of this study is to correlate cytomorphological features of metastatic non-small cell lung carcinoma (mNSCLC) with maximal standardized uptake value (mSUV) of PET scan in LNs.

**Design:** Positive EBUS-TBNA cytology slides were reviewed from patients with mNSCLC. Fifty-seven LNs were selected from 49 patients who had undergone PET study. Student t-test was used for statistical comparisons.

**Results:** Mean patients' age: 68.7, 67% male. LNs locations were as follows: mediastinum: 48 (24 subcarinal, 24 para-tracheal), lung hilum: 8, axilla: 1. Final diagnoses were: Adenocarcinoma (AdCa): 41 LNs, squamous cell carcinoma: 13 LNs and NSCLC: 3 LNs. Within the AdCa subgroup, we observed that histological patterns correlate with mSUV, with acinar and papillary (both mean values (Mv): 9.3) patterns associating with significantly lower mSUVs than solid pattern (Mv: 13.8) (both P values (Pv)<0.05). Similar difference exists between low and high grade AdCa (Mvs: 9.4 and 13.2, respectively. Pv<0.01). Interestingly, micropapillary pattern was associated with the lowest mSUV (Mv: 4.7) [figure1A, B]. Other features that correlated with higher mSUV: LN size (correlation coefficient: 0.51, Pv: 0.006), presence of necrosis and moderate/severe nuclear atypia (both Pvs<0.01), as well as lower lymphoid tissue yield (Mv: 7.7 vs. 11.4, Pv: 0.04). Besides, presence of solid pattern was linked with significantly higher cell-block yield than acinar/papillary patterns (Pvs: 0.02/0.03) [figure1C].



**Conclusions:** In LNs with mNSCLC, certain cytomorphological features including histological pattern, grade, necrosis and moderate/severe nuclear atypia are associated with higher mSUV. These results are consistent with the prior studies examining primary lung tumours. Interestingly, more aggressive metastatic micropapillary carcinomas express lower SUV values; hence, a lower threshold should raise concerns for metastasis. Finally, Pet mSUV along with LNs' cytomorphological features could be valuable in tailoring targeted therapeutic management.

**392 Unsatisfactory Exfoliative Anal Cytology Samples: A 15-Year Experience with Histologic, Cytologic, and Molecular Follow-Up**

Ruba Khattab, Emily McMeeken, Alan Taege, James Hekman, Jennifer A Brainard, Dawn Underwood, Charles D Sturgis. Cleveland Clinic, Cleveland, OH.

**Background:** The incidence of anal carcinoma has risen in recent decades in association with lengthened survivorships for high risk patients with immunocompromise. Screening of selected high risk patients is performed in many centers. Exfoliative anal cytology is a method that allows for early detection of cancer precursors. Unsatisfactory cytology results are frustrating to patients, clinicians and laboratorians. The aim of this study is to ascertain outcomes of patients with non-diagnostic anal cytology testing.

**Design:** A retrospective review of anal cytology testing performed at the Cleveland Clinic between 01/01/2001 and 12/31/2015 (15 year interval) was performed. Results were retrieved from the CoPathPlus laboratory information system. Unsatisfactory cases were organized in a spreadsheet. Co-testing for HR-HPV DNA was performed using Hybrid Capture 2® (Digene, Gaithersburg, MD) in the majority of patients. HR-HPV DNA co-test results, histopathologic diagnoses and repeat cytologic diagnoses were recorded.

**Results:** A total of 1276 ThinPrep anal cytology samples were received during the study period. Of these, 130 (10%) were deemed unsatisfactory. 77 % of patients were HIV positive. 111 patients (85%) were male and 19 (15%) were female. Of the unsatisfactory cases, 116 (89%) were co-tested for HR-HPV DNA. Of those, 40 patients (34%) had a simultaneous positive HR-HPV DNA result.

Anal Pap Results	Number (% of 1276)	% HR-HPV DNA Positive (89% Cotested)
Unsatisfactory	130 (10%)	34%
NILM	421 (33%)	42%
ASC-US	309 (24%)	45%
ASC-H	70 (5%)	78%
LSIL	229 (18%)	86%
HSIL	114 (9%)	100%
Carcinoma	3 (<1%)	100%

Adequate follow up cytology within a two year period revealed that 26/130 (20%) of patients had ASC or SIL. Histologic follow-up within 2 years showed 8 patients (6%) with anal intraepithelial neoplasia II or worse.

**Conclusions:** High risk patients with unsatisfactory anal cytology are not “negative” for disease. At least one-third of patients with unsatisfactory samples prove to be concomitantly HR-HPV DNA positive, with one-fifth showing subsequent cytologic squamous abnormalities and with more than 5% being diagnosed with a high grade cancer precursor within two years. Prompt repeat testing for high risk patients with non-diagnostic cytology is recommended.

**393 Utility and Reliability of Cell Block Sections in Predicting HPV Status on Metastatic HNSCC to Neck Nodes**

*Laila Khazai, Jasreman Dhillon.* Moffitt Cancer Center, Tampa, FL.

**Background:** Head and neck squamous cell carcinomas (HNSCC) not uncommonly present as lymph node metastases in the neck. Fine needle aspiration (FNA) is usually done to get a diagnosis and if positive is further tested for immunohistochemical stain p16 and HPV ISH. We report our experience in utilizing FNA for assessment of HPV status in these lesions.

**Design:** 30 cases of metastatic SCC to the neck diagnosed with FNA were identified from the pathology files of our Tertiary Cancer Center. The slides were reviewed by two Cytopathologists and consensus obtained on cellularity (<20, 20-50 and > 50 cells); necrosis; p16 staining (percentage of cells staining and intensity) and HPV-ISH on cell block (CB) sections.

**Results:** Primary sites included 17 oropharyngeal, 5 others (floor of mouth 3, anterior 2/3 of tongue 1, pyriform sinus 1) and 8 unknown. The gold standard for HPV status was either HPV ISH/HPV RNA on CB or HPV ISH on the resection specimen. Details about HPV status with corresponding site of origin are in Table 1. Performance of p16 and HPV ISH testing is shown in Table 2. There was 1 false negative case for both p16 and HPV ISH, which on review of CB slide was extremely hypocellular (<20 cells). HPV-ISH testing failed/was equivocal in 3 cases (1 HPV positive; 1 HPV negative; 1 HPV unknown). Upon review of the slides, two of these cases had necrosis constituting >70% of the sections and one had fixation issues. There were no false positive results. Of the 3 cases, where HPV status was unknown, 2 were p16 +ve and HPV-ISH -ve; 1 was p16 -ve with equivocal HPV ISH.

Site	HPV positive cases	HPV negative cases	HPV status not known
Oropharynx (n=17)	13	3	1
Other sites (n=5) Floor of mouth 3; anterior tongue 1; pyriform sinus 1	0	5	0
Unknown (n=8)	3	3	2

Test	HPV positive (n=16)	HPV negative (n=11)	HPV status not known
p16 positive	15	0	2
p16 negative	1	11	1
HPV ISH positive	14	0	0
HPV ISH negative	1	10	2
HPV ISH equivocal/ failed	1	1	1

**Conclusions:** 1. Cell block sections are a reliable source for determining HPV status for HNSCC.

2. Negative results must be interpreted with caution especially in cases with low cellularity, abundant necrosis and fixation issues.

3. Unlike tissue sections, a cutoff value of >70% cannot always be applied in CB sections for determining p16 positivity.

**394 Endobronchial Ultrasound – Guided Fine Needle Aspiration (EBUS-FNA): A Cytologic Histologic Correlation with Emphasis on Discrepant Cases**

*Peter J Kobalka, Yaxia Zhang, Jennifer A Brainard.* The Cleveland Clinic, Cleveland, OH.

**Background:** EBUS-FNA is an accepted technique for pre-operative mediastinal lymph node staging. In some cases, cytology and subsequent histology diagnoses are discordant. The reasons for discordant diagnoses have not been well-characterized. The goals of our study were to determine concordance between cytology and histology diagnoses and to elucidate reasons for diagnostic discrepancies.

**Design:** Patients who underwent EBUS-FNA for staging of a primary lung carcinoma with surgical resection between 9/6/11 and 8/15/16 comprised our study population. The cytologic and surgical pathology diagnoses for each lymph node station were compared. Patients who received neoadjuvant chemoradiation between procedures were excluded. Discrepant cases were reviewed. A lymph node sample was considered adequate on retrospective review if it met published numeric criteria for adequacy.

**Results:** 174 patients underwent EBUS-FNA prior to tumor resection in the study period. The final tumor subtypes for our cases are listed.

Diagnosis	Number of cases
Small cell carcinoma	4
Squamous cell carcinoma (SCC)	40
Adenocarcinoma	113
Carcinoid tumor	9
Atypical carcinoid tumor	2
Adenosquamous carcinoma	3
Poorly differentiated non-small cell carcinoma	3

In total, 578 nodal stations were sampled by EBUS-FNA and 330 were subsequently resected. Concordant and discordant diagnoses are summarized.

Pathology interpretation		Total
Cytology specimen	Surgical specimen	Nodal stations
negative	negative	286
positive	positive	25
negative	positive	18
positive	negative	1

Discrepancies between cytologic and histologic diagnoses were seen in 19 lymph nodes from 18 patients. Review of discrepant cases showed sampling error as a cause of all discrepancies. Discordant FNA’s reviewed retrospectively had an adequate lymphoid sample in the majority (15/18; 83%). Using 2mm as a size cutoff, “micrometastases” were noted in 10 discrepant lymph nodes and macrometastases in 8.

**Conclusions:** EBUS-FNA is an accurate method for staging of primary lung carcinomas. Of 330 lymph node stations in our study, the cytology and histology diagnoses were concordant in 94%. Our discrepant cases were related to sampling error, though approximately 17% of the cytologically benign but discordant lymph nodes had a less than adequate lymphoid sample on review. The size of the metastatic deposits in the discrepant samples was roughly equally divided between those measuring <2mm and those >2mm.

**395 Diagnostic Implication of ThyroSeq Sequencing Assay on Thyroid Nodules with FNA Cytology Diagnosis of Bethesda III: Atypia of Undetermined Significance versus Follicular Lesion of Undetermined Significance**

*Israa Klaklout, Mahmoud L Soliman, Dhay Kamel, Huihong Xu, Sandra Cerda.* Boston University Medical Center, Boston, MA.

**Background:** Next generation sequencing (NGS) ThyroSeq v.2 molecular testing is recently showed to improve classification accuracy of thyroid nodules with Bethesda III cytology into benign or malignant nodules with high predictive value. In our study, we evaluated whether using ThyroSeq v.2 panel improves the accuracy of the diagnosis among nodules diagnosed as Bethesda class III with atypia of undetermined significance (AUS) compared to follicular lesion of undetermined significance (FLUS) cytology.

**Design:** We reviewed a cohort of 158 thyroid nodules fine needle aspiration (FNA) diagnosed as Bethesda III and corresponding ThyroSeq v.2 results between Jan 2015 and July 2016 in our institute. NGS ThyroSeq v.2 analyzed point mutations in 14 genes and 42 gene fusion types associated with thyroid cancer. The endpoint was the histological evaluation based on the surgical resection as gold standard. Nodules with no ThyroSeq v.2 testing results (insufficient or no dedicated sampling) and patients having other malignant nodules were excluded from the analysis. There are 137 Bethesda class III thyroid nodules of which 87 (63.50 %) were diagnosed as AUS and 50 (36.50%) diagnosed as FLUS. A logistic regression analysis was used to evaluate the impact of ThyroSeq v.2 on AUS compared with FLUS. Statistical analysis was conducted using STATA 13 software.

**Results:** Of 137 nodules, 35 (25.6%) nodules had positive ThyroSeq v.2 testing, of which 26 (30%) showed AUS and 9 (18%) FLUS (p=0.13). Of 23 nodules (16 AUS and 7 FLUS) that had definitive histological diagnosis, 8 (34.8%) were malignant. Among AUS nodules, positive ThyroSeq v.2 testing correctly identified 6/7 malignant nodules, showing an 85.7% negative predictive value (P=0.036); however, in FLUS nodules, positive molecular testing identified 1 malignant nodule and 2 benign nodules with a 66.7% negative predictive value (P= 0.21).

**Conclusions:** The results of this prospective cross-sectional study show that ThyroSeq v2.1 panel significantly improves accurate classification of AUS thyroid nodules with

high specificity. However, the results are statistically insignificant among FLUS nodules, potentially attributed to the small sample size for this group. Our findings can possibly have an implication on the triage and management of AUS versus FLUS cases.

**396 Combined Fine Needle Aspiration Cytology and Flow Cytometric Immunophenotyping Is an Effective Method for Diagnosis of Hematolymphoid Disease**

Hubert Lau, Sharon Wu, Steven Long, Dita Gratzinger. Stanford University, Stanford, CA.

**Background:** Fine needle aspiration cytology (FNA) is an effective, minimally-invasive technique for obtaining tissue for morphologic examination, and flow cytometric immunophenotyping (FCI) is a rapid, quantitative, and objective method for characterizing cell antigen expression. Often, FNA and FCI are analyzed independently, and the widespread use of FNA in the diagnosis of hematolymphoid diseases is still limited. As such, the diagnostic utility of combined FNA/FCI specimens has not been extensively studied.

**Design:** 125 consecutive cases with concurrent FNA and FCI performed at our institution from January to May 2016 were identified. All cases were reviewed by at least one cytopathologist and one hematopathologist. Of these cases, 51 had a concurrent or subsequent core or excisional biopsy for diagnostic confirmation. The sensitivities and specificities of combined FNA/FCI and FCI alone were determined.

**Results:** The majority of the 125 FNA/FCI cases were initially categorized as positive (n=64, 51.2%), with the remaining categorized as atypical (n=8, 6.4%), negative/reactive (n=49, 39.2%), or limited (n=4, 3.2%). Analysis of the 51 cases with confirmatory histopathology revealed only one false negative FNA/FCI diagnosis of necrotizing lymphadenitis, with subsequent excisional biopsy showing angioimmunoblastic T cell lymphoma associated with EBV-positive large B cell lymphoma. No false positive cases were identified. As a result, combined FNA/FCI had a sensitivity of 97.6% and a specificity of 100%. Sensitivity and specificity of FCI alone were 78.6% and 100%, respectively. A first-time diagnosis of malignancy was made in 27 total cases, and only 8 of these cases required a follow-up biopsy to further sample the lesion.

**Conclusions:** The findings of this study support the use of combined FNA and FCI for the diagnosis of hematolymphoid diseases, as it has high sensitivity and specificity and often results in a diagnosis that does not require additional biopsy or surgery. Of note, the close collaboration between cytopathologists and hematopathologists is paramount, as proper correlation between FNA and FCI findings improves diagnostic sensitivity.

**397 Impact of the Reclassification of Noninvasive Encapsulated Follicular Variant of Papillary Thyroid Carcinoma (EFVPTC) to Noninvasive Follicular Thyroid Neoplasm with Papillary-Like Nuclear Features (NIFTP) on the Current Management Guidelines of the Bethesda System for Reporting Thyroid Cytopathology**

Ryan P Lau, John D Paulsen, Tamar C Brandler, Aylin Simsir, Fang Zhou. New York University School of Medicine, New York, NY.

**Background:** Recently, the entity “noninvasive encapsulated follicular variant of papillary thyroid carcinoma” (EFVPTC) was reclassified as “noninvasive follicular thyroid neoplasm with papillary-like nuclear features” (NIFTP). A tumor once considered malignant is no longer regarded a “carcinoma” based on this reclassification. Before surgical resection, most thyroid nodules undergo FNA and are risk-stratified using the Bethesda System for Reporting Thyroid Cytopathology (BSRTC). Each BSRTC category is associated with a risk of malignancy based on previously published percentages of carcinoma diagnoses in subsequent surgical resections. The reclassification of a malignancy to a non-malignant neoplasm will ultimately alter the established risk of malignancy, which has the potential to change management guidelines.

**Design:** We reviewed pathology reports of all thyroid FNAs with subsequent surgical resection among adults over a 12 month period. The size, location, FNA biopsy diagnosis, and surgical resection diagnosis were correlated. The malignancy rate was calculated twice for each BSRTC category: first while categorizing EFVPTC/NIFTP cases as “malignant,” and then while categorizing EFVPTC/NIFTP cases as “benign.”

**Results:** 287 cases were identified. The malignancy rate for each BSRTC category is shown in Table 1. 32 cases had a surgical diagnosis of EFVPTC that met updated criteria for NIFTP. Of the 32, 69% were called Bethesda III or IV on FNA. The changes in the risk of malignancy for each category were as follows: 1: no change, 2: 5% to 0%, 3: 36% to 20%, 4: 42% to 6%, 5: 95% to 63%, 6: 100% to 99%.

Bethesda Category	Malignancy Rate (%)			
	Established BSRTC data	NYU Data		
		EFVPTC/NIFTP is counted as malignant	EFVPTC/NIFTP is counted as benign	p-value<0.05 defined as statistically significant (McNemar test for paired proportions)
I	1-4	0	0	n/a
II	0-3	5	0	0.25
III	~5-15	36	20	0.001
IV	15-30	42	6	0.001
V	60-75	95	63	0.031
VI	97-99	100	99	1

**Conclusions:** 1. A decrease in malignancy rate was seen in all BSRTC categories except for category I.  
2. The most notable decrease was in category IV.

3. The decreased malignancy rate has major implications on the management of thyroid nodules, which is currently based on outdated BSRTC risk of malignancy data.

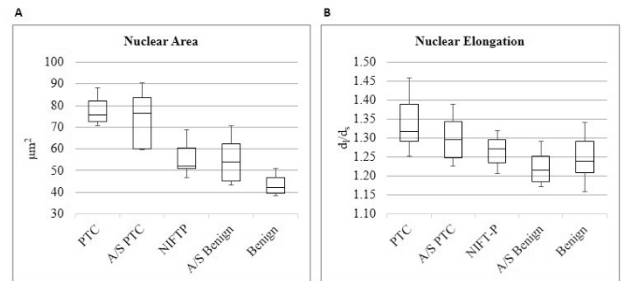
**398 Digital Image-Assisted Quantitative Nuclear Analysis Improves Diagnostic Accuracy of Thyroid Fine-Needle Aspiration Cytology**

Teklu Legesse, Krista Chain, Paul Staats. University of Maryland Medical Center, Baltimore, MD.

**Background:** The Bethesda System for Reporting Thyroid Cytopathology standardized thyroid fine-needle aspiration (FNA) reporting; yet many cases are assigned to indeterminate categories that have high interobserver variability, resulting in further workup including surgical resection. The newly coined “noninvasive follicular thyroid neoplasm with papillary-like features” (NIFTP) complicates reporting of cytology with nuclei suggestive of papillary thyroid carcinoma (PTC). We hypothesized that digital image-derived morphologic features might objectively distinguish cytologically indeterminate classical PTC (cPTC) from benign nodules, including NIFTP.

**Design:** Thyroid FNAs from 2012 to present were reviewed; all cases of atypia of undetermined significance (A; n=8, histology benign in 5, cPTC in 3) and suspicious for malignancy (S; n=2, histology cPTC) with sufficient cellularity and surgical follow-up, all FNAs preceding histology reclassified as NIFTP (n=6), and a random sample of cPTC (n=9) and benign (n=10) cytology were included. A single air-dried, Romanowsky-stained slide from each case was scanned using the Aperio imaging system and long (d<sub>l</sub>) and short (d<sub>s</sub>) axis diameters were measured for 125 nuclei in each case. Nuclear area (A=πd<sub>l</sub>d<sub>s</sub>/4) and elongation (E= d<sub>l</sub>/d<sub>s</sub>) were calculated. Pairwise T-tests were conducted among diagnostic groups.

**Results:** Nuclear area was larger in cPTC (mean 77.2, range 70.6-86.0 μm<sup>2</sup>) compared to benign (mean 43.3, range 38.252.2 μm<sup>2</sup>) (p<0.001). Nuclear areas from indeterminate FNAs (A/S) segregated according to their final histologic categories (A/S PTC mean 72.7μm<sup>2</sup>, A/S benign mean 53.7μm<sup>2</sup>; p=0.004; Fig. 1A). NIFTP nuclear area was smaller than cPTC (mean 54.8, range 46.7-66.1 μm<sup>2</sup>; p<0.001). Nuclear elongation mirrored nuclear area, but with greater group overlap (Fig. 1B).



**Figure 1**  
Box and whisker plots of nuclear area (A) and elongation (B) distributions among diagnostic categories. Median thyroid FNA cytology nuclear area (A) and nuclear elongation (B) for each of 5 diagnostic categories. Box = 25<sup>th</sup> and 75<sup>th</sup> percentiles; bars = min and max values.

**Conclusions:** Nuclear area and nuclear elongation can be calculated using a commercial digital imaging platform; both are predictive of the final surgical pathology diagnosis of cPTC vs. benign nodule, including NIFTP. Nuclear area discriminates better than elongation. This technique could be used in practice to resolve indeterminate cytologic findings in which cPTC is considered.

**399 Validation of a New Methanol Based Fixative for Cervical Cytology**

Katia RM Leite, Thais Silva, Bruna Naum, Flavio C Canavez, Juliana MS Canavez, Luiz Heraldo A Camara-Lopes. Laboratório Genoa, Sao Paulo, Brazil; University of Sao Paulo Medical School, Sao Paulo, Brazil.

**Background:** Cervical cytology is the most important preventive test for cervical cancer. Liquid-based cytology is considered superior than traditional smears in reducing the number of unsatisfactory results related to artifacts or insufficient cellularity. Another advantage of this technology is the possibility to search for pathogens and HPV in the same specimen using molecular techniques. There are 2 main commercially available fixatives that have been used worldwide, but they are expensive limiting their use by the health system from underdeveloped or in developing countries. Our aim is to test a new fixative for pap smear collection, methanol based, Cellpreserv®, comparing with the fixative produced by Thinprep® regarding the cytology and HPV results.

**Design:** 724 women participated on this study after signing an informed consent. The specimens were collected using a traditional device, vigorously agitated in PBS and divided equally in Thinprep® and in the new fixative in test. The slides were prepared routinely using the Hologic® equipment, and the usual membrane and slides from Thinprep®. The slides were stained by Papanicolaou and examined by two certified cytologists and reviewed by one experimented pathologist. Before processing the slides, 1 ml were taken from the fixatives and processed by PCR to search for HPV.

**Results:** The specimens were considered satisfactory, satisfactory but limited and unsatisfactory by both fixative in 408(56.4%), 235(32.5%), 22(3.0%) respectively. The cytology results are exposed in [Table 1]. The accuracy of the new fixative was 98.6% taken Thinprep® as the gold standard. The sensitivity was 90.7% and specificity 99.1%. The results of HPV detection was 100% concordant between the two fixatives.

**Conclusions:** The new methanol based fixative, Cellpreserv®, is cheaper and equally efficient in the maintenance of quality of cervical cells for diagnosis and detection of HPV and can be safely used by the health system from underdeveloped or in developing countries.

Results	Thinprep® fixative						Total
	Negative	ASC-US	AGC	LSIL	HSIL	ASC-H	
New fixative							
Negative	675	3	0	1	0	0	679
ASC-US	6	18	0	2	0	0	26
AGC	0	0	5	0	0	0	5
LSIL	0	0	0	10	0	0	10
HSIL	0	0	0	0	3	0	3
ASC-H	0	1	0	0	0	0	1
Total	681	22	5	13	3	0	724

#### 400 Malignancy Risk Associated with the Diagnostic Categories Proposed by the Papanicolaou Society of Cytopathology for Pancreatobiliary Specimens: An Institutional Experience

Jenna Lewis, Thomas Joyal, Claudia Rojas, Carmen Gomez, Darcy A Kerr, Merce Jorda, Monica Garcia-Buitrago. University of Miami/Jackson Memorial Hospital, Miami, FL.

**Background:** Pancreatic cancer is a leading cause of cancer-related mortality worldwide and has the lowest survival rate of any solid malignancy. According to the literature, endoscopic ultrasound-guided fine needle aspiration (EUS-FNA) for the diagnosis of solid pancreatic masses has 78-95% sensitivity and 75-100% specificity. In 2014, the Papanicolaou Society of Cytopathology Guidelines developed a standardized terminology and nomenclature for pancreatobiliary specimens. Though the diagnostic sensitivity and specificity of EUS-FNA are well documented, the malignancy risk associated with the newly proposed diagnostic categories is poorly defined.

**Design:** A retrospective cohort of 511 pancreatic FNAs performed from 2010 to 2015 was selected from the study files and relevant information was recorded and analyzed. Utilizing the 2014 guidelines, these aspirates were reclassified as non-diagnostic (I), negative for malignancy (II), atypical cells (III), neoplastic (IVA- neoplastic, benign; IVB-neoplastic, other), suspicious for malignancy (V), or malignant (VI; reserved for high-grade and aggressive malignancies). Tissue biopsies and resection specimens were available for 115 cases; surgical diagnoses were correlated with FNA results and risk of malignancy was calculated for each category.

**Results:** In accordance with the new criteria, the 511 FNAs were reclassified as follows: 6 non-diagnostic (1.2%), 7 negative (1.4%), 20 atypical (3.9%), 57 neoplasm (IVB; 11.1%), 48 suspicious (9.4%), and 373 malignant (73%). The 115 cases with available surgical follow-up were classified as follows: 2 non-diagnostic (1.7%), 1 negative (0.9%), 3 atypical (2.6%), 18 neoplasm (IVB; 15.7%), 18 suspicious (15.7%), and 73 malignant (63.4%). Risk of malignancy for non-diagnostic specimens was 50%, negative specimens 0%, atypical cases 33%, the neoplasm category 5.6%, suspicious for malignancy 83.3%, and the malignant category 90.4%. Our institutional sensitivity was 96% and specificity was 75%.

**Conclusions:** The cytologic categories developed by the Papanicolaou Society of Cytopathology stratify risk of malignancy; aspirates designated benign entail the lowest risk of malignancy (0%) and those designated malignant have the highest risk (90.4%). This scheme provides useful information to clinicians treating patients with pancreatic lesions.

#### 401 Implementing NIFTP May Potentially Impact the Risk of Malignancy for Thyroid Nodules Categorized as FLUS and SFN

Weihong Li, Brian Smola, Judy Pang, Madelyn Lew, Andrew Sciallis, Xin Jing. The University of Michigan, Ann Arbor, MI.

**Background:** Noninvasive encapsulated follicular variant of papillary thyroid carcinoma (FVPTC) has recently been reclassified as noninvasive follicular thyroid neoplasm with papillary-like nuclear features (NIFTP). This new terminology may alter the risk of malignancy (ROM) across the six categories of the Bethesda System for Reporting Thyroid Cytopathology.

**Design:** FNAs of thyroid lesions with surgical follow-up between 01/2010 and 06/2016 were retrieved. ROM was assessed for each diagnostic category with or without the exclusion of NIFTP from the malignant category.

**Results:** A total of 908 FNAs were retrieved, 252 of which were diagnosed as papillary thyroid carcinoma (PTC) on resection. 29 of 252 (11.5%) were FVPTC, 17 (58.6%) of which were diagnosed as NIFTP. The majority of NIFTP were interpreted as AUS/FLUS or SFN in cytology. When NIFTP was not considered a malignant diagnosis, the relative decrease of ROM is 25.8% and 22.3% in AUS/FLUS and SFN, respectively.

Diagnostic Categories	All PTC	FVPTC	NIFTP	ROM when NIFTP Was Considered Malignant (%)	ROM when NIFTP Was not Considered Malignant (%)	Relative Decrease of ROM (%)
Nondiagnostic	10	1	0	9.8	9.8	0
Benign	14	5	3	5.6	4.4	21.4
AUS/FLUS	28	11	8	12.8	9.5	25.8
SFN	12	5	4	26.5	20.6	22.3
SFM	34	1	1	81.4	79.1	2.8
Malignant	154	6	1	97.7	97.1	0.6
Total	252	29	17			

AUS/FLUS: Atypia of Undetermined Significance/Follicular Lesion of Undetermined Significance; SFN: Suspicious for a Follicular Neoplasm; SFM: Suspicious for Malignancy

**Conclusions:** 1. The majority of histology-proven NIFTP was cytologically interpreted as AUS/FLUS or SFN and subsequently resulted in a marked reduction of ROM in both categories when NIFTP was not considered malignant. This finding differs from the other institutional studies that revealed the most significantly decreased ROM in the SFM category. The difference may be attributed to the variation in threshold levels and the stringency in applying the diagnostic criteria for indeterminate cytologic categories among institutions.

2. Given the fact that thyroid nodules interpreted as AUS/FLUS or SFN are usually managed by lobectomy rather than total thyroidectomy in our institution, overtreatment for NIFTP may be avoided.

3. It is important for practitioners to have a clear understanding of their own institution's practice patterns in order to be able to triage appropriate management.

#### 402 Noninvasive Follicular Thyroid Neoplasm with Papillary-Like Nuclear Features: Can an Accurate Diagnosis Be Made on Fine Needle Aspiration (FNA)?

Mohammed T Lilo, Christopher J VandenBusche, Neda Rezaee, James Lee, Derek Allison, Amy G Zhou, Sara Mustafa, Barbara Rosenthal, Juliana DeLuca, Jen-Fan Hang, Justin A Bishop, Syed Z Ali. Johns Hopkins Medical Institutions, Baltimore, MD.

**Background:** The noninvasive follicular thyroid neoplasm with papillary-like nuclear features (NIFTP) was recently introduced to describe a distinct thyroid tumor with indolent behavior previously known as non-invasive encapsulated follicular variant of papillary thyroid carcinoma (EFVPTC). This new tumor reclassification has impacted the risk of malignancy (ROM) for the various TBSRTC categories. Herein, we investigate if an accurate cytopathologic diagnosis of NIFTP is possible on FNA.

**Design:** We selected 45 cases of thyroid FNAs with histological confirmation from the pathology archives of a major tertiary university hospital over a 4-year period. Three diagnostic groups were identified: 11-NIFTP, 13-Malignant (invasive follicular variant of papillary thyroid carcinoma [FVPTC] and classic papillary thyroid carcinoma [PTC]), and 21-Benign (control cases of follicular adenoma [FA] and adenomatoid nodule [AN]). The FNA material from these cases was independently and blindly reviewed by 8 individuals with varying levels of experience (cytotechnologists, pathology residents, fellows and attendings). Cases were assigned a TBSRTC category and scored semi-quantitatively for the amount of nuclear atypia (mild, moderate or severe) and microfollicular architecture.

**Results:** NIFTP cases were assigned an "indeterminate" category in 78% of cases (31% AUS, 25% SFN, 22% SFM), "malignant" in 13% of cases and "benign" in 9% of cases. "Indeterminate" categories were favored when microfollicular architecture was present with absent or mild nuclear atypia ( $P < 0.001$ ), while the malignant category (PTC) was favored when moderate to severe nuclear atypia regardless of microfollicular architecture was present ( $P < 0.001$ ). The "benign" category was favored in the absence of microfollicular architecture with absent or mild nuclear atypia ( $P < 0.001$ ). The agreement among the reviewers was good in "benign" and "indeterminate" categories and fair in the "malignant" category.

**Conclusions:** The majority of NIFTP nodules were diagnosed with an "indeterminate" TBSRTC categories. Nuclear atypia was the key cytological feature used to categorize the thyroid FNA. Microfollicular architecture appears to help further subcategorize and decrease the amount of NIFTP cases being diagnosed as malignant. Applying semi-quantitative criteria for both nuclear atypia and microfollicular architecture may increase the diagnostic accuracy for FVPTC and NIFTP.

#### 403 Implementation of Cell Block and Small Core Biopsy in Molecular Profiling of Metastatic Malignant Melanoma: A Comparison Study

Mohammed T Lilo, Neda Rezaee, Derek Allison, Emily M Adams, Zahra Maleki. Johns Hopkins Medical Institutions, Baltimore, MD.

**Background:** In the era of precision medicine, molecular analysis for the detection of targeted mutations has become crucial. BRAF mutations are commonly encountered in advanced stage of malignant melanoma and confer a response to BRAF inhibitors. Additionally, C-KIT mutated melanomas may benefit from tyrosin kinase inhibitors. Further, anti-PD1/PD-L1 immunotherapy has remarkable anti-tumor activity, which is linked in part to PD-L1 expression in tumor cells and tumor infiltrating lymphocytes—an assessment that requires tissue architecture, such as core biopsy. Gene mutations can be detected in cell block as well as core biopsy. Consequently, cytopathology specimens have become potential sources for molecular testing, and their proper utilization is imperative. Herein, we study the feasibility of cell block for next-generation sequencing (NGS) compared to core biopsy.

**Design:** The pathology database was searched to identify fine needle aspirations (FNA) and small core biopsies from different body sites, which diagnosed as metastatic melanoma and underwent subsequent molecular analysis at a major tertiary academic hospital over a 4-year period. Fifty-eight cases were identified. Targeted NGS for BRAF, C-KIT, NRAS and PIK3CA was performed on cell blocks in 12 cases and on core biopsies in 46 cases. Clinical data were collected and FNA, cell block, and core biopsy specimens were reviewed.

**Results:** The patients' average age was 64.3 years; 72% were male. Total rate of detection for mutated genes was 56% (33/58). The rate on core biopsy was 59% (27/46); and on cell block was 50% (6/12). BRAF V600E was detected in 37% and 33% of core biopsy and cell block samples, respectively; while other BRAF variants including V600K, V600R, G446V, and the rare S467L were detected in 15% and 17% of core biopsy samples and cell blocks respectively. Total rate of identification for non-mutated genes was 34% (20/58):33% (15/46) for core biopsy and 42% (5/12) for cell block. Total rate of insufficient samples for conducting molecular analysis was 8.6%: 8.7% on core biopsy and 8.3% on cell block.

**Conclusions:** Cell block, is similar to core biopsy in providing sufficient material for targeted NGS studies in advanced metastatic melanoma. Cell blocks tend to be underutilized when core biopsies are available ( $p < 0.001$ ). With gradually increasing demand for PD-L1 testing in daily practice, it is compelling to perform molecular studies on cell blocks when sufficient material is provided and to salvage core biopsy for further analysis requiring intact architecture.

**404 Telectology and Hands-Free Digital Voice Communication for High Volume Rapid On-Site Evaluation: An Workflow Optimization**

Oscar Lin, Dorota Rudomina, Rusmir Feratovic, Joe Sirintrapun. Memorial Sloan Kettering Cancer Center, New York, NY.

**Background:** Minimally invasive procedures used to obtain material for diagnostic purposes have become more prevalent in recent years. As such, there is an increased demand for rapid on-site adequacy assessment (ROSE). These procedures are often performed in different locations, requiring increasing personnel to provide support for ROSE. Individual support for each site by a cytopathologist is not cost effective due to the time spent and low reimbursement. We evaluated the effectiveness and accuracy of an integrated workflow using telectology (TC) and a hands-free digital voice communication (DVC) to provide ROSE in a large volume setting including multiple sites with only one cytopathologist.

**Design:** We performed a retrospective analysis of the workflow for ROSE performed in a single institution through TC and DVC using a single cytopathologist and on-site cytochemists (CT(s)) during a period of 14 months. In this high volume setting, TC and DVC were used to provide ROSE in 6 different sites. Remote access to the on-site camera was made through a dedicated telectology system provided by Remote Medical Technologies (RMT)® and Vocera® was used for DVC. The CT prepared slides on-site and selected the appropriate region of interest (ROI).

The preliminary adequacy assessment was compared to the final diagnosis. Concordance was obtained if the preliminary adequacy assessment matches the final cytopathologist-rendered diagnosis. An adequacy upgrade occurred when the preliminary adequacy assessment was considered inadequate but the final diagnosis was determined to be adequate. An adequacy downgrade occurred when preliminary adequacy assessment was deemed adequate but the final diagnosis is considered to be inadequate.

**Results:** Our study shows that TC and DVC-assisted ROSE was highly efficient and enabled ROSE support in multiple sites by a single cytopathologist. There were no or minimal delays in the procedures workflow. The ROSE analysis showed a high rate of concordance with the final cytopathologist-rendered adequacy assessment. Perfect concordance was 93% (6175/6643). The adequacy upgrade rate (inadequate specimen became adequate) was 6.7% (447/6643) and the adequacy downgrade (adequate specimen became insufficient) was at only 0.3% (21/6643)

**Conclusions:** Efficient and accurate ROSE support for minimally invasive procedures is possible with integrated TC and DVC. This integration optimizes the use of the resources such as cytopathologist time, while not interfering with cytotechnology on-site assessment or accuracy.

**405 Characterization of PD-L1 Immunohistochemical Expression in Cell Block Preparations with Different Fixatives**

Isaac E Lloyd, Wenhua Zhou, Benjamin L Witt, Barbara E Chadwick. University of Utah and ARUP Laboratories, Salt Lake City, UT; ARUP Laboratories, Salt Lake City, UT.

**Background:** Immunohistochemistry (IHC) is widely used to identify patients with overexpression of the biomarker PD-L1 who may benefit from targeted therapies. Interpretation of PD-L1 IHC has been largely based on data from formalin-fixed, paraffin-embedded tissue, despite the fact that cytologic specimens, especially cell blocks, are often the only available tissue for testing in clinical practice. Unlike biopsy specimens that are nearly universally fixed in formalin, cytology collection and fixation methods can vary markedly. The purpose of this study is to evaluate the effects of these pre-analytic variables on PD-L1 immunohistochemistry.

**Design:** Two cell lines with strong expression of PD-L1 (H441) and no expression (MCF7) were cultured *in vitro*. Harvested cells were suspended in several common cytologic sample media/fixatives including PreservCyt®, Cytolyt®, cell culture media (RPMI), saline, and formalin. Cell blocks were prepared within 24-48 hours by the plasma-thromboplastin method or Cellient® automated system and stained with the FDA-approved 28-8 PD-L1 antibody per protocol. PD-L1 expression was scored manually on duplicate blinded samples by two pathologists and compared for each processing method based on stain intensity and localization. Cell preservation and H&E staining quality were also assessed.

**Results:** Several IHC staining patterns were observed: complete membranous, partial membranous, globular, and cytoplasmic, with some overlap. Cellient® blocks had the highest proportion of strong complete membranous staining (82%) and least amount of cytoplasmic staining (12%). Stain intensity was weaker in PreservCyt® samples compared with others (47% vs 20%). Globular staining was a prominent pattern in all fixatives, accounting for 9-36% of all stained cells, second only to strong complete membranous staining (32-82%). The negative control blocks were consistently and completely negative for PD-L1, regardless of processing method. In addition, distinct cytomorphologic differences were observed on H&E staining, including improved nuclear and cytoplasmic detail in the formalin-fixed and Cellient® samples, marked cell shrinkage in Cytolyt®, and no significant differences in cell lysis.

**Conclusions:** Interpretation of PD-L1 IHC on cell blocks is feasible for all methods examined, but may require modification of standard PD-L1 interpretation parameters to account for differences in processing method and accept cytoplasmic and globular staining patterns.

**406 Impact of Transformation Zone Component on the Efficacy of Anal Cytology**

Dan Lu, David Chhieng, Michael Gaisa, Keith Sigel, Qiusheng Si. Icahn School of Medicine at Mount Sinai, New York, NY.

**Background:** Even though transformation zone (TZ) is considered as the “hot spot” of squamous intraepithelial lesion in the anal canal, little is known regarding the value of TZ component (TZC) in anal cytology. We herein review our experience with a high risk population to assess whether the absence of TZC negatively affects the efficacy of anal cytology in detecting HSIL.

**Design:** Cytology diagnosis and status of TZC were classified using the 2001 Bethesda System Terminology. 3190 cases with adequate specimen of anal Pap test (APT) were identified from 8/2012 to 9/2015; 2482 cases had TZC present (group 1) and 708 did not (group 2); 1495 cases had biopsy within 3 months of APT. Clinical risk factors (HIV-infection (HIV), HIV negative men who have sex with men (MSM), and HIV positive MSM (HIV-MSM)), hrHPV status, cytology diagnosis, and biopsy histology were compared between the groups. The efficacy of cytology to detect biopsy-proven HSIL was also analyzed.

**Results:** The two groups showed no difference in risk factors (table 1,  $p=0.26$ ), biopsy outcome (table 1,  $p=0.93$ ), and hrHPV positivity (76.1% vs 79.2%,  $p=0.09$ ). Interestingly, TZC absent group had statistically significant higher rate of abnormal cytology (table 1,  $p<0.001$ ). Using ASCUS as a cutoff, TZC absent group showed lower specificity to detect biopsy-proven HSIL (table 2).

		Group 1 (TZC Present)	Group 2 (TZC Absent)
Risk factors (n=3063 with known data)	HIV	55.9%	56.2%
	MSM	6.2%	6.2%
	HIV-MSM	34.3%	34.2%
	Total	2364 (100%)	699 (100%)
Biopsy (n=1495)	Benign	21.9%	21.6%
	LSIL	34.1%	35.2%
	HSIL	44.0%	43.2%
	Total	1143 (100%)	352 (100%)
Cytology (n=3190)	NILM	29.5%	21.6%
	ASCUS	42.1%	45.3%
	LSIL	19.3%	24.0%
	ASC-H	5.9%	6.2%
	HSIL	3.1%	2.8%
Total		2482 (100%)	708 (100%)

	Group 1 (TZC Present)	Group 2 (TZC Absent)
Sensitivity (95% CI)	91.8 (89.5-94.2)	91.4 (87.0-95.9)
Specificity (95% CI)	28.9 (25.4-32.4)	19.5 (14.0-25.0)
PPV (95% CI)	50.4 (47.1-53.6)	46.3 (40.7-52.0)
NPV (95% CI)	81.9 (76.8-86.9)	75.0 (63.2-86.8)

**Conclusions:** Our experience suggests absence of TZC on APT has no significant negative impact on the detection of cytologic abnormalities and hrHPV. Using histology as the gold standard, the operative performances between the two groups are similar except for a lower specificity for anal Pap lacking TZC.

**407 Anal High Risk HPV Genotyping and Correlation with Biopsy Outcomes**

Dan Lu, David Chhieng, Michael Gaisa, Keith Sigel, Qiusheng Si. Icahn School of Medicine at Mount Sinai, New York, NY.

**Background:** Little is known about the role of hrHPV genotyping in anal cancer screening. The objective of our study is to correlate hrHPV genotypes and biopsy outcomes.

**Design:** 3191 anal Pap tests with hrHPV cotesting were retrieved over a period of 37-months; 86.9% were HIV-seropositive, 1491 (46.7%) had high-resolution anoscopy-guided biopsy concurrently or within 3 months of testing. hrHPV genotyping was performed using PCR (cobas®, Roche) and hrHPV status was reported as negative, 16, 18, and non 16/18; the latter included one or more of the following subtypes 31, 33, 35, 39, 45, 51, 52, 56, 58, 59, 66, and 68.

**Results:** Overall, the hrHPV results were: 0.7% unsatisfactory, 23.0% negative, 3.0% positive for 16 only, 1.5% 18 only, 38.6% non 16/18 only, 0.2% coinfection of 16 and 18, 18.9% 16 and non 16/18, 8.7% 18 and non 16/18, 5.4% 16, 18 and non 16/18. Table 1 correlates HPV genotyping results and biopsy outcomes. Sensitivity, specificity, PPV, and NPV of presence of hrHPV for detecting HSIL on biopsy were 97.9%, 21.6%, 49.5%, and 92.8%, respectively. Table 2A and 2B correlate presence of HPV 16 infection and presence of multiple hrHPV coinfection with 16 and/or 18 with biopsy outcomes.

HPV/Bx	Non-HSIL	HSIL	Total
Negative hrHPV	180 (92.8%)	14 (7.2%)	194
Positive hrHPV	655 (50.5%)	642 (49.5%)	1297
16 only	24 (54.5%)	20 (45.5%)	44
18 only	21 (91.3%)	2 (8.7%)	23
Non 16/18 only	389 (62.6%)	232 (37.4%)	621
16+18	2 (66.7%)	1 (33.3%)	3
16+non 16/18	132 (37.6%)	219 (62.4%)	351
18+non 16/18	64 (44.1%)	81 (55.9%)	145
16+18+non 16/18	23 (20.9%)	87 (79.1%)	110

HPV/Bx	Non-HSIL	HSIL	Total	p value
16 only or coinfection with 18 and/or non 16/18	181 (35.6%)	327 (64.4%)	508	<0.0001
Negative for 16 but positive for 18 and/or non 16/18	474 (60.1%)	315 (39.9%)	789	

HPV/Bx	Non-HSIL	HSIL	Total	p value
16 only, 18 only, or non 16/18 only	434 (63.1%)	254 (36.9%)	688	<0.0001
16+18, 16+non 16/18, 18+non 16/18	198 (39.7%)	301 (60.3%)	499	
16+18+non 16/18	23 (20.9%)	87 (79.1%)	110	

**Conclusions:** We concluded that hrHPV testing had high sensitivity and NPV for predicting the presence of HSIL on biopsy in high risk population; detection of HPV16 alone or in combination with other hrHPV genotypes was associated with higher risk for biopsy proven HSIL; and coinfection of multiple hrHPVs with 16 and/or 18 was associated with increased incidence of biopsy proven HSIL.

**408 Polyoma (BK) Virus Cytopathic Effect in Urine Cytology Is Not Associated with High Risk of Developing Urothelial Carcinoma**

Haiyan Lu, Tarik M Elsheikh, Yaxia Zhang. Cleveland Clinic Foundation, Cleveland, OH.

**Background:** According to the Paris System for Reporting Urinary Cytology (TPS), the main purpose of urine cytology is to detect high grade urothelial carcinoma (HGUC). TPS recommended polyoma virus cytopathic effect (BK) to be classified as “negative for HGUC (neg)”. However, recent published report from a major academic institution had suggested that BK should be classified as “atypical urothelial cells (AUC)”, because of its reported associated high risk of HGUC amongst non-surveillance patients (those without history of UC). The goal of our study was to examine the validity and reproducibility of this recent publication, and investigate the relationship of BK to subsequent risk of developing HGUC in a large tertiary care center.

**Design:** The pathology database of our institution was searched from January 2009 to December 2011 for all neg and AUC urine diagnoses associated with BK (+BK). All cases had a follow-up of at least 5-years, and rates of subsequent HGUC were calculated for all BK cases, including non-surveillance patients. This data was further compared to control group of 150 consecutive cases with neg and AUC unassociated with BK.

**Results:** 17,771 urine specimens were identified, including 15712 neg (88.4%), 277 neg + BK (1.6%), 1087 AUC (6.1%), and 68 AUC + BK (0.4%). Surgical follow-up showed an overall risk of developing HGUC of 6.6%, 5.1%, 25%, and 10.1%, for neg, neg +BK, AUC, AUC+BK, respectively. HGUC follow-up rates in non-surveillance patients were 4.6%, 1.7%, 16.4%, and 4.9%, respectively. There was no statistical difference in HGUC follow-up rate for neg cases whether or not they were associated with BK, including non-surveillance patients ( $p>0.05$ ). However, there was increased risk for HGUC in AUC patients unassociated with BK compared to AUC+BK ( $p<0.05$ ).

Patients	Risk of HGUC on 5-year follow-up (%)					
	Neg	Neg + BK	P value	AUC	AUC + BK	P value
All patients	6.6	5.1	>0.05	25	10.1	<0.05
Non-surveillance	4.6	1.7	>0.05	16.4	4.9	<0.05

**Conclusions:** The presence of BK associated with neg or AUC urine cytology does not increase the overall risk of developing HGUC, including non-surveillance patients. Furthermore, HGUC risk in AUC+BK is significantly lower than AUC unassociated with BK, suggesting that pathologists tend to over-diagnose AUC when BK changes are observed. Our results support TPS’s recommendation to place neg+BK in the neg category.

**409 Lymphoid Enhancer Binding Factor 1 (LEF1) and Paired Box Gene 8 (PAX8): A Limited Immunocytochemistry Panel to Distinguish Solid Pseudopapillary Neoplasms and Pancreatic Neuroendocrine Tumors on Endoscopic Ultrasound-Guided Fine-Needle Aspirates of the Pancreas**

Haiyan Lu, Jennifer A Brainard, Daniela Allende, Xuli Liu, Yaxia Zhang. Cleveland Clinic Foundation, Cleveland, OH; University of Florida, Gainesville, FL.

**Background:** Endoscopic ultrasound-guided fine needle aspiration (EUS-FNA) has been proven to be the most effective procedure for sampling and diagnosing the pancreatic lesions. Solid-pseudopapillary neoplasms (SPNs) and pancreatic neuroendocrine tumors (PNETs) are distinctive pancreatic entities. However, the distinction between these two entities still remains challenging due to overlapping cytomorphologic features. The nuclear b-catenin (CTNNB1) immunoreactivity has been used as a diagnostic marker for SPN. However, sometimes it is difficult to interpret due to its diffuse cytoplasmic staining. The goal of our study is to investigate the utility of immunocytochemical stains of nuclear lymphoid enhancer binding factor 1 (LEF1) and paired box gene 8 (PAX8) in differentiating these two entities on EUS-FNA samples. **Design:** The pathology database of our institution was searched from January 2007 to August 2016 for all the patients with diagnosis of SPN and PNET. The clinical and pathologic report for each patient was reviewed. The cytology slides were retrieved and reviewed. The immunohistochemistry stains of LEF1 and PAX8 were performed on the cell blocks. The frequencies of positive stain in each group were compared using Fisher’s exact test in IBM SPSS Statistics 19. A P value less than 0.05 was considered statistically significant.

**Results:** 8 SPN cases and 25 of PNET cases were used in the study. Both LEF1 and PAX8 stains showed strong nuclear staining and were easy to interpret. 7/ 8 SPN were LEF1 positive (87.5%), while 2 / 25 PNET showed LEF1 immunoreactivity (8.0%) ( $P<0.001$ ). By contrast, PAX8 was positive in 19 / 25 PNET (76.0%) and 2 / 8 SPN (25.0%) ( $P<0.05$ ). The combined LEF1(+)-PAX8(-) phenotype was only present in SPN cases (5/8, 62.5%), whereas this immunoprofile was not seen in any PNET ( $P<0.001$ ). The combined LEF1(-)-PAX8(+) phenotype was only present in PNET cases (16/25, 64.0%), but not in SPN cases ( $P<0.01$ ).

**Conclusions:** SPN and PNET exhibit opposite immunophenotypic profiles with LEF1 positivity in SPN and PAX8 positivity in PNET. The combination of these two stains renders a useful and effective ancillary test in distinguishing these two disease entities on EUS-FNA specimen.

**410 Cytologic Study of Atypical Squamous Cells of Unknown Significance (ASCUS) on ThinPrep Liquid Based Cytology and Relationship to High Risk HPV (HRHPV) Status**

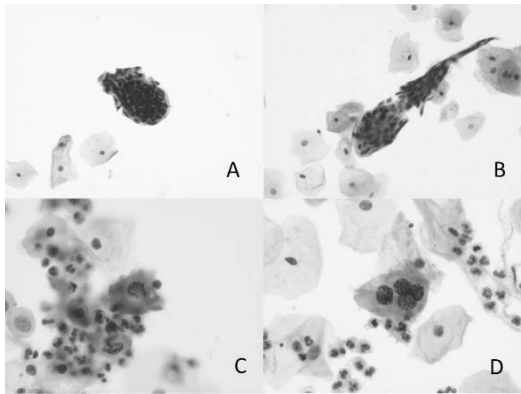
Zhichun Lu, Lauren Noyes, Gary Cole, Daniel Schultz, Gaba Arthur, Ziyang Zhang. Henry Ford Health System, Detroit, MI.

**Background:** ASCUS is the most commonly-reported Pap abnormality. Since most cases of ASCUS prove to be HRHPV negative, we undertook this study to determine whether cytologic parameters on Pap smears with a diagnosis of ASCUS could be useful in predicting HRHPV status.

**Design:** We conducted a retrospective study and selected all cases from a 2-month period that were diagnosed as ASCUS on ThinPrep liquid based cytology with concurrent HRHPV assay. We categorized identified cases into HRHPV+ and HRHPV- groups. The following cytologic parameters were evaluated in all cases: 2x nuclear enlargement, nuclear membrane irregularity, hyperchromasia, coarse chromatin, nuclear halo, squamous pearls (defined as keratin fragments containing small, pyknotic nuclei with an orderly stratified pattern) in an otherwise normal smear, and dyskeratosis (defined as keratin fragments containing small nuclei with a disorganized growth pattern and variability in nuclear size, shape and chromaticity). Chi-square test was used to test the relationships.

**Results:** 209 patients were retrieved, age ranging from 20 to 75, 92/209 (44%) were HRHPV+. Ninety of 170 patients aged <50 (53%) were HRHPV+. Cytologic parameters and HRHPV status are listed in table 1. Of particular interest, HRHPV was negative in all cases with squamous pearls in otherwise normal smears (figure A&B). Coarse chromatin was exhibited to a much larger degree in HRHPV+ group (figure C&D).

	HRHPV+	HRHPV-	Total
Total case number	92	117	209
Nuclear membrane irregularity	68	54	122
2x nuclear enlargement	57	56	113
Hyperchromasia	62	42	104
Coarse chromatin	50	22	72
Dyskeratosis	19	43	62
Squamous pearls	0	24	24
Nuclear halo	4	5	9



**Conclusions:** In our study, nuclear enlargement, membrane irregularity, and hyperchromasia characterized ASCUS, regardless of HRHPV status. Coarse chromatin was more likely an indicator of HRHPV infection ( $p < 0.001$ ); likelihood HRHPV+ 74%. Dyskeratoses were more predominant in the HRHPV- group ( $p = 0.011$ ), while presence of squamous pearls in an otherwise normal smear appeared to have no association with HRHPV status.

#### 411 Inter-Institutional Variability of “Atypical” Salivary Gland Fine Needle Aspiration: A Multi-Institutional Study

*Aatika Malik, Zahra Maleki, Huaqing Zhao, Esther Diana Rossi, Ping Bo, Ashish Chandra, Seyede Elham Arab, Nirag Jhala, Syed Z Ali, Guido Fadda, Jindong Wang, Viren Patel, He Wang.* Temple University Hospital, Philadelphia, PA; The Johns Hopkins Hospital, Baltimore, MD; The Catholic University of Rome, Rome, Italy; Fudan University Cancer Hospital, Shanghai, China; Guy’s & St Thomas’s Hospital NHSFT, London, United Kingdom.

**Background:** Fine needle aspiration (FNA) cytology is a well-accepted, innocuous, reliable, minimally invasive and cost effective method for preoperative diagnosis of salivary gland lesions. Most salivary gland neoplasms are often difficult to diagnose because of morphologic heterogeneity and a variety of epithelial metaplastic changes. Hence, a significant number of salivary gland FNAs yield indeterminate results. It’s imperative to develop guidelines for evaluation and management of these ambiguous diagnoses.

**Design:** The indeterminate FNAs are classified into “atypical” and “suspicious for malignancy” categories. Current diagnostic category of “atypical” refers to cases where unambiguous cellular atypia is present. This study was designed to evaluate risk of neoplasia (RON) and risk of malignancy (ROM) of atypical category among 5 tertiary medical centers worldwide. Among the 12,732 salivary gland FNAs between 1997 and 2014, 510 (4%) cases were reported as “atypical”. 154 atypical cases (36%) had histological follow-up.

**Results:** Histological follow-up of 154 atypical cases showed 128 (83.12%) neoplastic and 26 (16.88%) non-neoplastic lesions, and percentages for individual institutions were 41.67%, 72.00%, 84.75%, 94.23%, and 100.00%. When comparing different institutions, Pearson  $\chi^2 = 22.80$ ,  $P < 0.001$ , indicated a significant difference of RON among different institutions. We then further analyze difference of ROM among institutions, 97 out of 154 atypical cases were malignant (62.99%), and percentages for individual institutions were 0.00%, 16.67%, 67.80%, 68.00%, 73.08%. Pearson  $\chi^2 = 24.38$ ,  $P < 0.001$ , again indicated a significant difference ROM among atypical diagnoses from different institutions.

**Conclusions:** This study demonstrated that the ROM and RON in “atypical” category amongst different institutions vary considerably. Frequency of salivary gland FNA and variable practices at each individual institution appears to impact the ROM and RON. Our study supports further sub-classification and guidelines for this diagnostic category of Salivary gland lesions.

#### 412 Rhabdoid Glioblastoma: Cytologic Characteristics and Diagnostic Pitfalls

*David C Marbury, Israh Akhtar, Kim R Geisinger, Maria Gonzalez, Dianne E Grunes, Steven Raab, Ali G Saad.* University of Mississippi Medical Center, Jackson, MS.

**Background:** Rhabdoid glioblastoma (RGBM), a highly aggressive form of glioblastoma (GBM), is a recently recognized variant of GBM. In this era of stereotactic brain biopsies often yielding limited material for histopathologic examination, cytologic preparations have become an integral component of intraoperative diagnosis (frozen section) and familiarity with the cytologic features of primary brain tumors is crucial for diagnosis accuracy. The cytologic features of RGBM are poorly characterized. Here we describe the features of 6 cases of RGBM.

**Design:** RGBM on which intraoperative cytological smear preparations were available are included in this study. Smears were made of the fresh tissue and stained with H&E. The final diagnosis of RGBM is confirmed with permanent sections and ancillary studies.

**Results:** The smears were hypercellular with marked cellular pleomorphism. Tissue fragments and isolated tumor cells were present within a necrotic background. In many foci, fibrillary background was noted in all 6 cases. To qualify as a fibrillary background, the processes must emerge from the cytoplasm and not a crush artifact of the cytoplasm. This is aided by the fact that the former shows smooth contours and transition between the cytoplasm proper and the processes. The cohesive clusters consisted of neoplastic cells with pleomorphic, hyperchromatic nuclei anchored around blood vessels. Scattered

in between were large polygonal rhabdoid-like cells with abundant pink granular cytoplasm, eccentric round hyperchromatic nuclei, and small but conspicuous nucleoli. Although variable in prevalence, rhabdoid cells were identifiable in all 6 cases. Vascular proliferation was identified in 2 cases and tumor necrosis in 4 cases. The main differential diagnosis is with rhabdoid tumor (RT). While both RGBM and RT share the presence of rhabdoid cells with significant cytologic atypia/pleomorphism and tumor necrosis, RT does not show fibrillary background or vascular proliferation. In addition, it is not uncommon to identify in RGBM foci displaying classical cytologic features of GBM such as neoplastic astrocytes with scant cytoplasm.

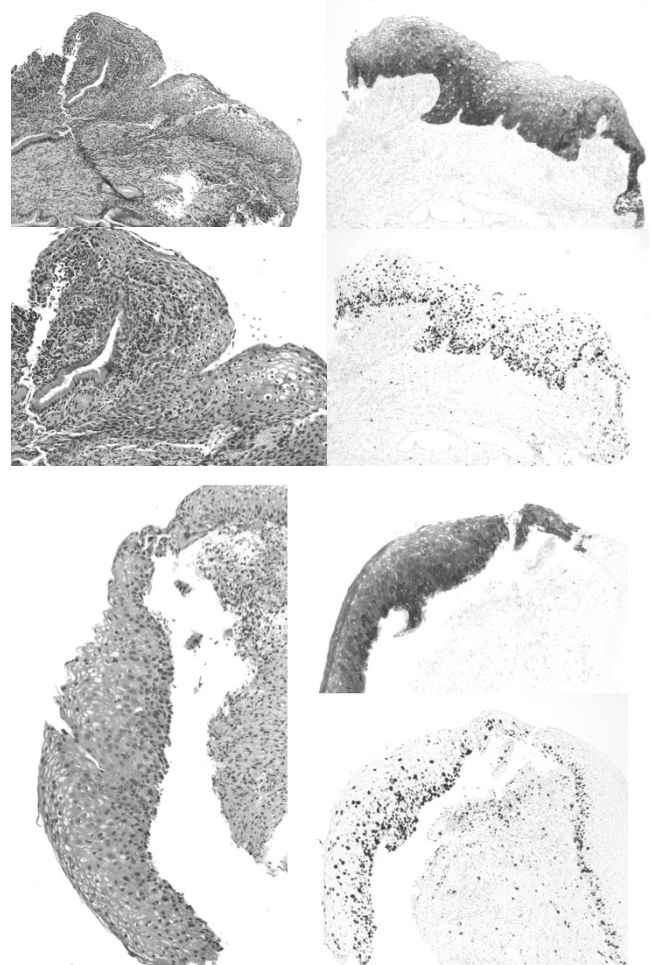
**Conclusions:** Intraoperative smear preparation is a reliable and accurate tool for the diagnosis of RGBM. The presence of, at least focally, a fibrillary background and scattered large rhabdoid cells with globular cytoplasmic inclusions are characteristic. Familiarity with the cytologic features of this recently described variant of GBM and awareness of the potential cytologic pitfalls is important for all pathologists who are involved with neuropathologic specimens.

#### 413 Underdiagnosis of HSIL on PAP Smears Due to Variant LSIL-Like Morphology in Non 16/18 HPV Infections

*Ramya Masand, Barrett Lawson, Derek Danner, Matthew Anderson, Vijayalakshmi Padmanabhan, Ninad M Patil.* Baylor College of Medicine, Houston, TX.

**Background:** High-risk Human Papillomavirus (HRHPV) 16 or 18 genotypes are the most common etiologies of high-grade squamous intraepithelial lesion (HSIL) and carcinomas. The spectrum of non-16, non-18 HRHPV associated lesions has not been well-characterized. Some HSILs have variant morphology that we refer to as low-grade-like high-grade squamous intraepithelial lesion (LLHSIL), and in our GYN pathology practice, we found this predominantly in non-16, non-18 HRHPV lesions. We aim to correlate pap diagnoses in cases with LLHSIL on histology.

**Design:** Inclusion criteria: all cases with differential of LSIL vs HSIL, received for GYN pathology review & stained for p16 & Ki67 from Jan. 2015 through Sept. 2016. Criteria for LLHSIL: cytomegaly with preservation of nucleocytoplasmic (N/C) ratio, anisonucleosis, bi- and multinucleation throughout the epithelial thickness giving the appearance of full-thickness koilocytosis, increased eosinophilia and/or glycogenation of superficial layers, usually uncommon superficial layer mitoses, less nuclear crowding or elongation than in typical HSIL, with block p16 and high Ki67 staining. Prior cytology reports of all patients with LLHSIL morphology were reviewed. HPV genotyping was performed by APTIMA assays.



**Results:** 31 cases with LLHSIL morphology; 29(93.5%) had non-16/non-18 HRHPV, 1(3.2%) had HPV16 and 1(3.2%) had HPV18. On the PAPs, 1 case called as HSIL, 4 as ASC-H, 15 as LSIL, 9 as ASCUS and 2 as negative.

INTERPRETIVE DIFFERENCE	Cases(%)
1-Step	15(48.4%)
2-Step	9(29%)
3-Step	2(6.5)
Total	26/31 (83.9%)

**Conclusions:** Traditional cytology criteria for HSIL rely on increased nuclear-cytoplasmic ratio of superficially sampled cervical cells. We found a high percentage of HSIL cases called LSIL on retrospective correlation of LLHSIL cases with corresponding cytology smears. This can be explained by the relatively low nuclear-cytoplasmic ratio in this variant and the need for staining with P16 and Ki67 for definite diagnosis.

#### 414 Molecular Testing in Small Metastatic Colorectal Carcinoma Samples

*Kelsey McHugh, Laila Nomani, Lani K Clinton, Yu-wei Cheng, Thomas Plesec, Jordan P Reynolds.* Cleveland Clinic Foundation, Cleveland, OH.

**Background:** Metastatic colorectal carcinoma (CRC) represents advanced stage disease requiring cytoreductive therapy. Mutational status for genes *KRAS*, *NRAS*, and *BRAF* on (CRC) specimens may guide clinical decision-making regarding selection of targeted therapy. Knowledge of their status confers susceptibility/resistance to tyrosine kinase inhibitors. Polymerase chain reaction (PCR) or next generation sequencing (NGS) on formalin-fixed paraffin-embedded tissue (FFPET) is performed to assess their status. In situations in which metastatic CRCs are assessed via minimally invasive methodologies, the cell pellet from cytology specimens obtained at fine needle aspiration (FNA) may be used.

**Design:** The electronic medical record was searched for all FNA and core needle biopsies (CNB) with metastatic CRC from 1/1/1995 to 8/31/2016. Cases on which NGS was performed were identified. NGS for *KRAS*, *NRAS* and *BRAF* using the AmpliSeq Cancer Hotspot Panel v2.0 kit (Thermo Fisher Scientific, Waltham, MA) was performed on cytology cell pellets and on surgical pathology FFPET.

**Results:** During the 21 year 9 month interval, metastatic CRC was diagnosed in 306 non-resection anatomic pathology specimens. 125 cases were diagnosed on FNA versus 181 cases diagnosed on CNB (41% v 59%). We began NGS of CRC specimens in 2015; of the 125 FNAs, mutational analysis was performed on the cell pellets of 17 metastatic CRCs (17/125; 14%). Sixteen of 17 specimens (94%) were adequate for molecular testing. Of those adequate, the percent of malignant cells in each sample ranged from 10 to 90% (mean 53%). Eleven of 16 cases (69%) were positive for clinically relevant mutations. *KRAS* mutations were found in 10/16 cases (63%). Codon 12 mutations were the most frequent (10/11 cases, 91%). NGS was previously performed on a prior surgical pathology specimen associated with 1 of these 10 cases (10%), with concordant results. One of 16 FNA cases (6%) was positive for a *BRAF* mutation involving codon 594. Of the 181 biopsies, mutational analysis was performed on the FFPE tissue of 2 CRCs (2/181; 1%). Both specimens (2/2; 100%) were adequate for molecular testing with cellularities higher than 50% (range 50-70%). One of 2 cases (1/2; 50%) was positive for a clinically relevant *BRAF* mutation involving codon 600.

**Conclusions:** Nearly half of metastatic CRCs are diagnosed via FNA. The cytology specimen cell pellet serves as a useful source of material on which NGS mutational analysis can be performed. Thus, without FFPET, clinically actionable information on tumor mutation status in metastatic CRC can still be gathered.

#### 415 Outcomes of Discordant and Equivocal Cytology and FISH in Biliary Brushing

*Lily Mei, Ghazal Khan, Tatjana Antic, Ricardo R Lastra, Jeffrey Mueller, Ward Reeves, Irving Waxman, Uzma Siddiqui, Christopher Chapman, John Hart, Namrata Setia.* The University of Chicago, Chicago, IL.

**Background:** Biliary brushing during endoscopic retrograde cholangiopancreatography (ERCP) is the standard approach for diagnosing pancreaticobiliary malignancy. While a positive brushing cytology is highly predicative of malignancy, equivocal cytologic results occur frequently and present a management dilemma for clinicians. A recent adjunct to biliary cytology, fluorescence in situ hybridization (FISH), reportedly increases the diagnostic sensitivity. However, false negative and false positive FISH may further confound the overall diagnostic accuracy. This study aims to examine cases with equivocal as well as discordant cytology and FISH results, and correlate with their clinicopathologic features and outcomes.

**Design:** A retrospective query of our archives was performed for biliary brushing that had both cytologic and FISH diagnoses. Cytologic diagnoses were divided into 3 categories: negative (reactive changes, atypical, or atypical favor reactive), positive (suspicious or adenocarcinoma), or equivocal (atypical-neoplasm not excluded). FISH (Mayo Clinic, Rochester, MN) was interpreted as negative, positive or equivocal. Clinical data was obtained from electronic medical records. Malignant outcome was determined by pathologic evidence of cancer (biopsy, resection or autopsy), administration of adjuvant therapy or hospice care.

**Results:** 107 ERCP brushing specimens were identified between 2011 and 2016 with concurrent cytologic and FISH evaluation; 18 were excluded for insufficient material. Of the remaining 89 cases, 31 cases had malignant outcomes. Cytology and FISH were comparable in terms of sensitivity (58.3% vs 57.7%  $P=1.00$ ), specificity (98.1% vs 96.1%;  $P=.98$ ), positive predictive value (0.93 vs 0.88;  $P=.97$ ), and negative predictive value (0.84 vs 0.82;  $P=.99$ ). Results are schematically summarized.

Schematic Summary:  
Cytology and FISH results with their corresponding outcome and clinical factors

Cytology	FISH	n	Outcome		Clinical Factors	
			Malignant	Benign	Mass or malignant stricture	PSC
+	+	9	■	■	■	■
+	- / equivocal	4	■	■	■	■
+	- / equivocal	2	■	■	■	■
-	-	5	■	■	■	■
-	-	50	■	■	■	■
-	equivocal	1*	■	■	■	■
-	+ / equivocal	6	■	■	■	■
equivocal	- / + / equivocal	7	■	■	■	■
equivocal	- / + / equivocal	5	■	■	■	■

\*Patient s/p cholecystectomy with complications prior to ERCP

■ Malignant Outcome  
■ Benign Outcome  
■ Mass present  
■ History of PSC  
■ Mass variably present  
■ Variable history of PSC

**Conclusions:** While no standard algorithm is available for triaging patients with discordant cytology and FISH, adding certain clinical criteria such as the presence of a mass or history of PSC may help predict their clinical outcome.

#### 416 Clinical Outcomes in Patients with 'Atrophic' Pap Smears and Concurrent Positive HPV Testing

*Zhen W Mei, Tatjana Antic, Ward Reeves, Ricardo R Lastra.* University of Chicago Medical Center, Chicago, IL.

**Background:** The current United States Preventative Services Task Force (USPSTF) guidelines recommend cytology combined with HPV-testing every five years for women between the ages of 30-65. One of the acknowledged consequences that result from co-testing is that women may continue to be screened beyond age 65 if their HPV-testing comes back positive even though there is no cytologic abnormality. The objective of this study is to identify this cohort of women who have atrophic Pap smears with concurrent positive HPV-testing in order to assess the clinical significance of this result.

**Design:** The electronic archive of the Department of Pathology at our institution was queried for women 30 years of age or older who had Pap smear results, from 2002 and beyond, that were interpreted as atrophic. Patients with both an atrophic Pap smear and positive HPV co-testing were followed as long as the medical record would allow to determine if the patients progressed to any sort of epithelial lesion.

**Results:** Seven hundred women were selected from January 2002 - July 2016 who had findings consistent with 'atrophy' on Pap smear. Within this cohort, 317 (45.3%) had concurrent HPV testing and 389 did not. Of the 317 patients with concurrent HPV testing, 19 (6%) had a positive result. These patients were all between the ages of 47 to 78 (average: 62). Within these 19 patients, only one patient (5%), a 63-year old female had progressed to HSIL within 3 years (average follow up time = 3.1 years). The original ThinPrep® slides were pulled from the archives and re-examined to ensure that our current opinion continued to match the original diagnosis.

**Conclusions:** In our current institutional review, it seems that positive HPV testing resulting from this recommended co-testing did not have significant clinical impact in women who had atrophic Pap smears. It appears to be clinically safe and financially sound to recommend that the HPV-test be deferred for patients whose Pap smears only reveal atrophic changes.

#### 417 Improved Interpretation of Bile Duct Brushings Requires Intensive Exposure and Familiarity with Diagnostic Criteria

*Bahar Memis, Vaidehi Avadhani, Krisztina Z Hanley, Egi Hachisanoglu, Uma Krishnamurti, Adeboye O Osunkoya, Alyssa Krasinskas, Michael M Goodman, Rebecca Nash, Volkan Adsay, Michelle D Reid.* Emory Uni, Atlanta, GA.

**Background:** The diagnosis of malignancy in BDB is a well-known challenge with need for improvement in applicable diagnostic criteria.

**Design:** 60 BDBs (30 with malignant outcome, and 30 benign, as determined by resection/>2 yrs uneventful F/U) were blindly evaluated by 7 observers with variable cytology experience, using a log questionnaire of potential criteria; 11 useful criteria consistently led to accurate diagnosis of malignancy for the majority of reviewers (3-D clusters, 2-cell population, chromatin change, high N/C, cell discohesion, hypercellularity, pleomorphism, prominent nucleoli and nuclear irregularity, molding and vacuoles); 3 reviewers then routinely reviewed dozens of BDBs using these 11 criteria while the remaining 4 received a 10-minute tutorial followed by 50 min multithreaded microscope slide review session, mostly focused on identifying malignant criteria. The 60 BDBs were then re-labeled and re-reviewed by the same observers (again blinded to outcome and previous/others' diagnoses).

**Results:** After training, the overall group sensitivity increased from 66% to 74% ( $p=0.029$ ), but group specificity dropped slightly from 90% to 84% ( $p=0.052$ ) and accuracy did not change (78% v. 79%,  $p=0.828$ ). However, for the 3 observers who were subjected to intense practice-based education (and used these criteria extensively by analyzing prospective and retrospective cases), there was across-the-board improvement, with average sensitivity increasing from 68 to 81%, specificity, 92 to 96%, and accuracy 80 to 89%. The only trainee in the study (a cytopathology fellow) had a statistically significant increase in sensitivity from 60 to 83% ( $p=0.039$ ), and accuracy from 78 to 92% ( $p=0.022$ ). The number of ambiguous diagnoses (atypical/suspicious) dropped significantly for all 7 reviewers (from 42% to 30%,  $p<0.001$ ).

**Conclusions:** Intense exposure and application of the elucidated criteria with correlated feedback from followup information can achieve significant improvement in the overall accuracy of cytopathologic evaluation of BDBs. This improvement may be especially striking in trainees (without any pre-conceived notions or bias). Limited exposure to, and use of, BDB cytology as well as distinguishing malignant criteria, while indeed



accomplishing improvement in the diagnosis of malignancy, may at the same time lead to over-interpretation of reactive changes as malignancy. Therefore, education should be sustained and focused with emphasis on discrimination from mimickers.

**418 Efficacy of Endoscopic-Guided Fine Needle Aspiration in the Diagnosis of Gastrointestinal Spindle Cell Tumors**

*Ioana Moisini, Khalid Amin, Jimmie Stewart, Tetyana N Mettler.* University of Minnesota, Minneapolis, MN.

**Background:** Spindle cell neoplasms of the gastrointestinal (GI) tract constitute a wide group of lesions that may raise diagnostic difficulties on hematoxylin-eosin-stained slides and therefore, benefit most from immunohistochemistry (IHC). Appropriate endoscopic ultrasound-guided fine needle aspiration (EUS FNA) technique with sufficient cell block material for IHC can lead to an accurate diagnosis.

**Design:** This is a retrospective study of twenty-seven cases obtained from our institution's records over a five-year period (2011-2015). Cytomorphology, histology (when available), IHC, FNA procedure details (including type of needle and number of passes), imaging characteristics and clinical history were reviewed. Rapid onsite evaluation (ROSE) was used in all cases. Cytologic samples were correlated with surgical pathology resection specimens when available.

**Results:** Spindle cell neoplasms of the GI tract included eighteen GI stromal tumors (GIST) among which two with epithelioid morphology, six leiomyomas, two schwannomas and one granular cell tumor. Most neoplasms were located in the stomach (18), followed by esophagus (6), duodenum (2) and colon (1). EUS FNA was performed with different gauge needles, ranging from 19 to 25, rarely with stylet and/or Shark needle. The total number of passes ranged between two and nine. We found no evidence that larger size needles are superior in procuring adequate lesional tissue compared to smaller gauge needles. The cell block material was stained with antibodies against KIT (CD117), CD34, smooth muscle actin (SMA), S-100, and DOG-1. Fourteen surgical resection specimens were available, with 100% correlation between cytology and histology. None of the neoplasms recurred until now, except for one patient who succumbed to a previously known esophageal squamous cell carcinoma.

**Conclusions:** We analyzed twenty-seven cases of various GI spindle cell neoplasms for yield of pathologic tissue depending on needle used and ability to establish a definitive diagnosis based on IHC. In our experience, FNA is a pivotal and inexpensive method for rapid evaluation of GI spindle cell tumors and should be used widely in the attempt to avoid unnecessary surgery. Size of needle used for EUS FNA does not seem to influence the yield of lesional tissue; rather, ROSE can guide the number of passes and subsequently lead to an adequate cell block.

**419 Endoscopic Ultrasound Guided Fine Needle Aspiration vs Fine Needle Biopsy of Pancreatic Lesions: A Retrospective Review Comparing Diagnostic Accuracy and Outcomes**

*Elizabeth Morency, Jamie Slade, John Sir Philip, Ritu Nayar.* Northwestern Memorial Hospital, Chicago, IL.

**Background:** Historically, endoscopic ultrasound guided fine needle aspiration (EUS-FNA) has been utilized for biopsy of pancreatic lesions but more recently, EUS-guided fine needle biopsy (EUS-FNB) has emerged. Studies comparing the diagnostic yield of the two for pancreatic and non-pancreatic masses found that the diagnostic yield was significantly higher for EUS-FNB compared to EUS-FNA (primarily in biopsy of non-pancreatic lesions). At our institution, while we were successful using EUS-FNA with rapid onsite assessment (ROSE) followed by ProCore biopsy with touch preparation when FNA was unsatisfactory, endoscopists have begun to transition to EUS-FNB in the interest of improving time efficiency.

**Design:** All diagnostic reports for pancreatic FNAs done between 1/1/2015 and 6/30/2016 (when ProCore biopsies began to predominate) and FNAs done between 1/1/2013 and 6/30/2014 (when FNAs with ROSE predominated) at NMH were retrieved and correlated with clinical history and available concurrent cytology and histology specimens to determine accuracy and patient impact.

**Results:** Of the 134 patients that underwent EUS-FNA, 73 (54%) were males and 61 (45%) were females; age range 19-94. Of the 83 patients that underwent EUS-FNB, 47 (56%) were males and 36 (43%) were females; age range 29-83. Diagnostic (dx) categories per biopsy (bx) type were as follows with (%):

Bx type/Dx category	Non-diagnostic	Negative	Atypical	Neoplastic	Suspicious	Malignant
EUS-FNA	10 (7)	20 (15)	4 (3)	15 (11)	6 (4)	79 (59)
EUS-FNB	1 (1)	33 (40)	1 (1)	16 (19)	1 (1)	31 (37)

Definitive diagnoses on EUS-FNA material were made in 120 out of 134 (90%) cases and for EUS-FNB 81 out of 83 (97%). Similar rates of follow up biopsy were seen in FNA and FNB cases, totaling 43 (32%) and 19 (23%), respectively.

**Conclusions:** 1) FNB had a more accurate diagnostic yield overall the FNA (97% vs 90%, respectively) and this difference was found to be statistically significant (p = 0.032). 2) Conversely, FNA has a higher non-diagnostic rate than FNB (7% vs 1%, respectively) which while not statistically significant (p = 0.0546) very closely approaches it. 3) Both modalities had a negligible post-procedure complication rate (<1%). 4) Given the additional time required for ROSE and lower overall diagnostic yield for FNA biopsy of pancreatic masses it appears FNB is a viable alternative to FNA and more appropriate for use in practices that lack resources for ROSE and cytopathology interpretation expertise.

**420 Squamous Cells with Atypia/HPV Changes in Urine Cytology: Cytology-Histology Correlation**

*Elizabeth Morency, John Sir Philip, Samah Saharti, Ayse I Kilic, Guliz Barkan, Ritu Nayar.* Northwestern Memorial Hospital, Chicago, IL; Loyola University Medical Center, Chicago, IL.

**Background:** While human papillomavirus (HPV) infection has been implicated as an etiologic factor in the development of squamous cell carcinoma (SCC), the role of HPV infection and significance of HPV-like changes in the pathogenesis of carcinoma in the genitourinary (GU) tract has yet to be elucidated. The goal is to examine a series of urine cytology cases (UCyt) with squamous atypia/HPV changes and correlate with histology.

**Design:** All UCyt reports with a diagnosis of "atypical squamous cells" or "HPV changes" from 01/01/2010 to 12/31/2015 were identified through an electronic medical record search in the two institutions. Relevant clinical history, indication for testing, cytologic features and histologic follow up (f/u) were tabulated.

**Results:** A total of 101 (0.002%) of UCyt from 98 patients showed atypical squamous cells at the combined institutions. Patients ranged from 20-97 years (mean=61) with a slight female predominance (51%). The majority presented with hematuria (40.8%) followed by (22.4%) for surveillance for history of carcinoma in GU tract. 68% were voided, 31% washings and 1% catheterized specimens. A total of 43/101 (42.5%) had a f/u biopsy. The table outlines the surgical f/u, with (%):

Diagnosis/Site	Bladder	Urethra	Ureter	Penis	Anus	Gyn tract	Kidney
SCC	4 (9.3)	4 (9.3)	1 (2.3)	3 (7)	2 (4.6)	2 (4.6)	0
HGUC	3 (7)	0	0	-	-	-	0
LGUC	5 (11.6)	0	0	-	-	-	0
Low grade squamous dysplasia	2 (4.6)	0	0	1 (2.3)	0	2 (4.6)	0
Benign	10 (23)	0	0	2 (4.6)	0	0	2 (4.6)

HGUC, high grade urothelial carcinoma; LGUC, low grade urothelial carcinoma  
Twenty-four (55.8%) of the f/u biopsy diagnoses were carcinoma representing a significant proportion and the majority were squamous cell type 16/24 (66.6%) arising in a variety of sites.

**Conclusions:** While the incidence of squamous atypia is rare in UCyt, they can be associated with a significant risk of malignancy and can arise anywhere in the GU or gynecologic (GYN) tracts. It is important to designate any squamous atypia noted on cytology under the category of "Atypical", i.e. "Negative for High Grade Urothelial Carcinoma. Atypical Squamous cells present." with a comment outlining the possible etiologies of squamous atypia, in order to convey to the urologists this potential risk. We recommend a thorough evaluation of the GU and GYN tracts to identify the site of origin of the squamous atypia in these instances.

**421 A Case for Coning the Cervix in Hysterectomies Performed for Benign Conditions in Patients with a Prior ASCUS Pap Test**

*Shima Mousavi, Neda Zarrin-Khameh, Ramya Masand, Vijayalakshmi Padmanabhan.* Baylor College of Medicine, Houston, TX.

**Background:** Up to 30% of patients with an ASCUS Pap test (PT) diagnosis have been associated with high-grade squamous intraepithelial lesion (HSIL). In some patients with a history of ASCUS PT hysterectomy may be performed for other conditions. Practice varies among pathologists on how to examine the cervix in these patients and includes representative sampling of the cervix. Coning the entire cervix is costly and time consuming. This study aims to evaluate the practice of studying the entire cervix in hysterectomy specimens for otherwise benign conditions in patients with a history of ASCUS who did not have other follow up in our system.

**Design:** Data was extracted from the pathology and cytology reports of all patients with a history of ASCUS who underwent hysterectomy at our institution between 2001 and 2016.

**Results:** In 79 cases the entire cervix was examined due to a history of ASCUS PT. Dysplasia was identified in 8 patients (10.1%) and 71 had no dysplasia (90%). Among the 8 patients with dysplasia, 5 had LSIL (62%), and three (37.5%) had HSIL. No invasive carcinoma was detected.

**Conclusions:** Ten percent (8/79) of patients showed dysplasia in the hysterectomy specimen. HSIL was seen in 3.8% (3/79) of cases and constituted 37.5% of the abnormal diagnosis. Studying the entire cervix in patients with history of indeterminate PT increases disease detection. These patients will need increased surveillance and follow up.

**422 Anal Pap Smears: Five- Year Retrospective Review**

*Rochelle Nagales Nagamos, Melissa Stemmer, Cindy Steele, Kamal K Khurana.* SUNY Upstate Medical University, Syracuse, NY.

**Background:** CLIA ' 88 mandates that a five year retrospective review of all negative or normal gynecological specimen be performed whenever a current HSIL is detected. However no such regulations are mandated for anal pap smears. As a part of quality improvement, we decided to perform similar five-year retrospective review of anal pap tests.

**Design:** A retrospective computer search was performed to find all anal Pap smear cases with a diagnosis of high grade squamous intraepithelial lesion (HSIL) from January 01, 2012 up to July 31, 2016. For each patient with a current HSIL, adenocarcinoma, or other malignant neoplasm, review of all normal or negative anal pap tests received within the previous 5 years, if available in our laboratory (either on-site or in storage) was performed.

**Results:** A total of 1,107 anal pap tests were performed during the study period. 279 (25.2%) were interpreted as having ECA. Among the ECA cases, 34 patients (12.2% of

ECA) had interpretation of HSIL. No case with malignant neoplasm was identified. Of the 34 HSIL cases 12 (35.2%) had no previous anal Pap and 15 (44.1%) with total of 20 smears had previous ECA. Seven patients with first time diagnosis of HSIL had 11 slides that were initially reported as negative. Rescreening of these 11 slides revealed LSIL (1) HSIL (1), ASCUS (3) and no change in diagnosis in remaining 6 slides rendering a discordance rate of 45.5%. Retrospective review helped in identifying 2 (29%) missed cases of SIL which showed very few diagnostic cells.

**Conclusions:** Five-year retrospective review of anal pap smears provides a mechanism to review negative cases at high risk for harboring true abnormalities. It also aids in enhancing diagnostic acumen of cytotechnologists and cytopathologists and can be used to improve laboratory performance as part of overall quality assurance program.

**423 Clinical Significance of LSIL-H (LSIL with Coexistent ASC-H) in Pap Smears; a Two-Year Analysis of the Positive Predictive Value for Histological High-Grade Lesions Among LSIL, LSIL-H and ASC-H**

*Shuang Niu, Kyle Molberg, Elena Lucas.* University of Texas Southwestern Medical Center, Dallas, TX; Parkland Health and Hospital System, Dallas, TX.

**Background:** Specimens with LSIL-H, defined as low-grade squamous intraepithelial lesion (LSIL) containing cells suspicious but not definitive for high-grade squamous intraepithelial lesion (HSIL), comprise a heterogeneous group of lesions including both histological LSIL and HSIL. LSIL-H is not a defined diagnostic category in the 2015 Bethesda System for Reporting Cervical Cytology (TBS-15), and there is a high inter-observer variability among pathologists in categorizing these cases as ASC-H or LSIL. The goal of this study was to assess the positive predictive value for histological HSIL in follow-up cervical biopsies for these cases.

**Design:** We reviewed all available ASC-H and LSIL cases for a two-year period (2009 and 2012) and reclassified them as LSIL-H, LSIL or ASC-H. Follow-up biopsies within 12 months post the pap test were retrieved from the computer database, and the numbers of cases with histological HSIL or a greater lesion were compared among LSIL-H, LSIL and ASC-H groups.

**Results:** 184 cases of ASC-H and 581 cases of LSIL were reviewed. A total of 147 cases were reclassified as LSIL-H (68 cases from the ASC-H group, and 79 from the LSIL group). 116 cases were pure ASC-H, and 502 were pure LSIL. The positive predictive value for histological HSIL was 45.7% for the ASC-H group, 30.6% for the LSIL-H group, and 5% for the pure LSIL group (100 randomly selected cases among the 502 LSIL cases). There was a statistically significant difference between pure ASC-H and LSIL-H groups ( $p < 0.05$ ), pure ASC-H and pure LSIL groups ( $p < 0.01$ ) and LSIL-H and pure LSIL groups ( $p < 0.01$ ).

**Conclusions:** We believe that the addition of the LSIL-H category would provide a clinically significant intermediate category between ASC-H and LSIL. However, since TBS-15 does not include the LSIL-H category, we believe these cases should be diagnosed as both LSIL and ASC-H to indicate the intermediate risk of a high-grade histologic lesion between LSIL and ASC-H while still staying within the guidelines of TBS-15.

**424 Feasibility and Utility of Cytology Based Next Generation Sequencing for Metastatic Melanoma**

*Laila Nomani, Kelsey McHugh, Yu Wei Cheng, Jordan P Reynolds, Jennifer Ko.* Cleveland Clinic, Cleveland, OH.

**Background:** Currently actionable driver mutations in melanoma include *BRAF*, *NRAS* and *cKIT*. When they recur, melanomas often present at an advanced stage and require immediate cytoreductive therapy such as that achievable with *BRAF*, *MEK* or *cKIT* kinase inhibitors. Recurrence is often confirmed with minimally invasive procedures--either fine needle aspirate (FNA) or core needle biopsy (CNB), necessitating their use for molecular profiling. Cytology based next generation sequencing (NGS) has been particularly challenging.

**Design:** All cases of malignant melanoma diagnosed on FNA or CNB were analyzed (1/2015-9/2016). Cases where NGS was performed were compared by biopsy technique. Tumor DNA was extracted from the FNA cell pellet (PreservCyt) after slide/block preparation. DNA sequencing was performed on an Ion Torrent PGM instrument (Life Technologies, Grand Island, NY) and data analyzed using Torrent Suite (Life Technologies, Grand Island, NY) and NextGENe (Softgenetics).

**Results:** 31 cases were diagnosed by FNA and 9 by CNB, of which 10/31 (32%) and 5/9(55%) had NGS testing ordered respectively. NGS was successful in 10 /10 (100%) of attempts in FNA specimens, of which actionable mutations were detected in 8/10(80%) cases: 5 (63%) *BRAF* (2 from back, 1 flank, 2 lymph nodes), 3(37%) *NRAS* (1 groin, 2 arm), and 1 (13%) *cKIT* (axillary lymph node). NGS was successful in 100% of attempts in CNB biopsy specimens, of which actionable mutations were found in 2 /5(40%) cases: 1 (20%) *BRAF* (lung), and 1 (20%) *NRAS* (chest wall).

Sample No	Type	Site	Mutation
1	FNA	Flank	BRAFV600E
2	FNA	Groin	NRAS
3	FNA	Back	BRAFV600E
4	FNA	Arm	NRAS
5	FNA	Back	BRAFV600E
6	FNA	Arm	NRAS
7	FNA	Preauricular lymph node	NRAS
8	FNA	Axillary lymph node	BRAFV600E, cKIT
9	CNB	Lung	BRAFV600E
10	CNB	Chest wall	NRAS

Of the total 15 NGS tests resulted, 3 had somewhat overlapping testing performed on other tumor specimens, which served to verify results (2 NGS and 1 PCR on surgical specimens).

**Conclusions:** Clinical need exists to detect driver mutations with known therapeutic implications in relatively small tumor samples, the majority of which represent cytology specimens. Therefore, an accurate and reliable detection method for gene mutations is warranted. This study demonstrates the feasibility and utility of NGS from cytology specimens as a tool for gene mutation analysis in malignant melanoma.

**425 Noninvasive Follicular Thyroid Neoplasm with Papillary-Like Nuclear Features (NIFTP) and Its Influence on the False Positive Rate in Thyroid Cytopathology**

*N Paul Ohori, Jenna Wolfe, Linwah Yip, Shane O LeBeau, Sally E Carty, Aaron N Berg, Karen E Schoedel, Yuri Nikiforov, Raja R Seethala.* University of Pittsburgh Medical Center, Pittsburgh, PA.

**Background:** Noninvasive Follicular Thyroid Neoplasm with Papillary-like Nuclear Features (NIFTP) is a newly defined nonmalignant entity that most closely translates to noninvasive follicular variant papillary thyroid carcinoma (FVPTC) by previous classification. Recent studies have suggested a ~5% decrease in the rate of malignancy (ROM) for the positive for malignancy (PFM) cytology category as a result of NIFTP implementation. However, the distinction between a PFM and a suspicious for malignancy (SFM) diagnosis may vary depending on the threshold of individual cytopathologists and institutional perspectives on false positive diagnoses. In this study, we investigated the ROM for the PFM and SFM diagnoses in our series before and after NIFTP reclassification.

**Design:** Cytology cases with PFM and SFM diagnoses with subsequent surgical pathology resection specimens were searched in our files for the time period of 9/2008 to 12/2015. The surgical pathology cases of FVPTC were re-examined to determine if they qualified as NIFTP. Although a surgical disease, NIFTP is no longer considered malignant; therefore, the ROM for the PFM and SFM cases before and after reclassification were calculated accordingly.

**Results:** Our search identified 321 cases of PFM and 135 cases of SFM with resection outcome. For the PFM cases prior to NIFTP reclassification, 319 of 321 cases were confirmed to be malignant (ROM – 99.4%). The two false positive cases consisted of a case of Hyalinizing Trabecular Tumor and a case of multinodular thyroid. Following NIFTP reclassification, 1 case of NIFTP and 1 potential case of NIFTP (which could not be verified due insufficient sampling) were identified. Therefore, 317 of 320 verifiable PFM cases had malignant outcome (ROM – 99.1%). The difference in the ROMs was not statistically significant ( $p = 0.686$ ). In contrast, the ROM of SFM cases decreased from 75.6% (102/135) prior to NIFTP reclassification to 63.0% (85/133) after NIFTP reclassification ( $p = 0.046$ ). Two cases could not be verified due to insufficient sampling.

**Conclusions:** In our series, NIFTP reclassification did not appear to alter the ROM for the PFM cytology diagnosis significantly, although a significant drop was noticed for the SFM diagnosis. We suspect that our stricter, more conservative approach to the PFM category may have contributed to these findings.

**426 Utilization of Transthoracic Ultrasound Guided Fine Needle Aspiration in the Diagnosis and Molecular Profiling of Lung Masses**

*Lais Osmani, Mark Hopkins, Zahra Maleki.* The Johns Hopkins Hospital, Baltimore, MD.

**Background:** Lung cancer is the leading cause of cancer related death in both males and females worldwide. Furthermore, the lung is the most common site for metastasis of malignant neoplasms. Endobronchial ultrasound guided (EBUS) fine needle aspiration (FNA) is routinely used to obtain material for tumor diagnosis, staging and molecular profiling of lung cancer in particular and other malignant neoplasms. Transthoracic ultrasound guided FNA is used when EBUS FNA is not feasible. Herein, the utility of transthoracic ultrasound guided FNA is evaluated.

**Design:** Transthoracic FNA specimens were identified using the pathology database system at our institutions over a 5 year period. The diagnoses were compiled and separated into two main categories including diagnostic and non-diagnostic. The diagnostic specimens were then further categorized into benign, diagnostic for primary lung malignancy, diagnostic for metastatic malignancy, and diagnostic but requiring further studies or samples.

**Results:** 153 Transthoracic FNA specimens were identified. The patients' ages ranged from 8 to 94 years (average age of 62.7 years) and the male to female ratio was 1.25. Of these, 14 specimens were acquired for clinical trial studies and additional molecular studies, and were not included in our analysis. Of the 139 specimens collected for diagnostic purposes, 123 specimens (approximately 88%) were sufficient for diagnosis. Of the diagnostic specimens, 35 (approximately 28%) were diagnostic of primary lung malignancies and 47 (approximately 38%) were diagnostic of metastatic malignancies. 29 (approximately 24%) specimens were diagnostic but further studies or additional material were recommended. 13 (approximately 11%) cases were benign. No patient developed symptomatic pneumothorax or other complications.

**Conclusions:** Transthoracic ultrasound guided FNA is a minimally invasive, cost effective procedure that provides diagnostic material in the significant majority of cases and it might be considered as an alternative to CT-guided transthoracic FNA or wedge biopsy to prevent radiation exposure or a more invasive surgical procedure, respectively.

**427 Using the Rate of Positive UroVysion FISH Test Results Together with the Atypical Urothelial Cells (AUC)/High Grade Urothelial Carcinoma (HGUC) Ratio in Evaluating the Performance of Cytopathologists**

*Stefan Pambuccian, Guliz Barkan, Eva M Wojcik. Loyola University, Maywood, IL.*  
**Background:** The introduction of standardized criteria for the diagnosis of “atypical urothelial cells” (AUC) in the Paris System (TPS) will hopefully result in both a reduction of the AUC diagnostic rate and its variation between pathologists and institutions. However, it is still uncertain how to best monitor AUC rates and provide timely feedback to pathologists. Taking a cue from the experience with the use of high risk HPV rates to compare pathologists’ atypia rates, we aimed to determine the potential use of UroVysion(r) FISH-positivity rate to determine the cause of high AUC rates.  
**Design:** We identified all AUC cases and concurrent UroVysion FISH diagnoses from 2008-2014, and calculated the frequency of AUC diagnosis, AUC/HGUC ratio, FISH positivity rate in AUC, and the underlying risk of malignancy (ROM) of AUC diagnosis for each pathologist, using surgical pathology follow up acquired within 12 months of the index cytologic diagnosis.  
**Results:** We found a high variation in individual CP AUC rates, 7.47-18.88%, which correlated with AUC/HGUC rates. However, the risk of malignancy and FISH+ in AUC did not correlate with AUC rates or AUC/HGUC ratios.

	No cases (Cases with FISH)	AUC rate (%)	AUC/HGUC ratio	FISH + in AUC (%)	Risk of Malignancy in AUC (%)
CP1	3267 (103)	8.23	1.23	23.8	37.8
CP2	1183 (90)	15.55	3.23	8.5	18.2
CP3	757 (16)	8.45	2.06	16.7	53.9
CP4	2515 (66)	7.63	1.54	18.6	30.6
CP5	3373 (77)	7.47	1.42	30	31.2
CP6	1748 (43)	7.84	1.69	22.5	32
CP7	1356 (77)	12.02	2.47	24.2	12.1
CP8	1356 (54)	18.88	3.41	30	35
Total	15555 (526)	9.75	1.83	21.6	28.8

For example while CP2 has both high AUC rate and AUC/HGUC ratio and has low FISH+ and ROM rates, CP 8 has a high AUC rate, AUC/HGUC ratio, FISH+, and ROM rate. The most likely explanation is that these cytopathologists thresholds for AUC and HGUC are different; CP2 has a low threshold for AUC but an average threshold for HGUC while CP8 has a low threshold for AUC and a high threshold for HGUC. Knowledge of FISH positivity may be used as a surrogate marker for underlying ROM, to give real-time feedback to pathologists to modify their thresholds. The laboratory average can be used as a metric to compare individual CP rates.  
**Conclusions:** Used together, both indicators (FISH+ in AUC, and AUC/HGUC ratio) together provide useful feedback to the cytopathologists, so that they can adjust their threshold.

**428 Atypical Urothelial Cells (AUC) Diagnosis Rates and AUC/High Grade Urothelial Carcinoma (AUC/HGUC) Ratios Vary in Different Urinary Cytology (UCy) Specimen Types**

*Stefan Pambuccian, Guliz Barkan, Eva M Wojcik. Loyola University, Maywood, IL.*  
**Background:** The Paris System of reporting urine cytology (TPS) has defined the criteria for the atypical urothelial cell (AUC) category. This standardized definition is likely to lead to a reduction in both the use of this category and in the wide variation that currently exists in its use. To compare AUC rates between institutions and account for differences in disease prevalence in different practices, one of the proposed measurements is the AUC/HGUC ratio, which is similar to the ASC/SIL ratio used in gynecologic cytopathology. However, it is currently unknown if the AUC/HGUC ratios vary for different specimen types. Differences in AUC/HGUC ratios by specimen type may represent a factor that should be taken into account when comparing AUC rates between institutions that have different mixes of UCy specimen types. The aim of this study is to determine the rates of AUC diagnosis and AUC/HGUC ratios for the entire institution and for each pathologists for each specimen type and site (i.e. voided urine (VU), bladder washing (BW), and upper urinary tract specimen (UUT))  
**Design:** Our institution’s electronic medical records were searched for UCy cases with a diagnosis of AUC made from 2008 to 2016. The patient demographic information, specimen site and type, and signout pathologist were tabulated. A p value<0.05 was considered statistically significant.  
**Results:** A total of 15,555 UCy cases (3813 VU, 10312 BW, 1208 UUT, 222 others) were reviewed during the study interval. The diagnosis of AUC was slightly more common in VU (10.32%) than in BW (8.68%) for the whole group (p=0.003), while the diagnosis of AUC in UUT specimens was almost as twice as common as in VU and BW specimens (p<0.0001). The individual pathologists’ AUC rates varied by specimen type, 6.8-18.8% for VU, 6.5-17.4% for BW and 12.8-38.6% for UUT specimens. VU, BW and UUT have dramatically different HGUC rates (2.1% vs. 5%, vs. 18.8%, respectively), resulting in a large difference in AUC/HGUC ratios (4.9, 1.7 and 0.9 respectively).  
**Conclusions:** 1. We found that there is a large variation of AUC rates by specimen type and site  
 2. This was accompanied by an even larger AUC/HGUC ratio variation.  
 3. The variation of the rates of AUC and AUC/HGUC by site for individual pathologists suggests the impact of specimen type related factors and would indicate the need for more site specific studies.  
 4. The large variation of AUC/HGUC rates by specimen type/site suggests that this metric should be used with caution when comparing AUC rates between institutions and setting goals for reporting

**429 The Correlation of Afirma® Gene Expression Classifier Results with Follow-Up Findings for Thyroid Fine Needle Aspiration Specimens**

*Yelena Piazza, Fan Lin, Haiyan Liu. Geisinger Medical Center, Danville, PA.*  
**Background:** Fine needle aspiration (FNA) biopsy of thyroid nodules has resulted in a significant reduction of unnecessary surgeries; however, atypia of undetermined significance/follicular lesion of undetermined significance (AUS/FLUS), remains a “gray zone” for clinicians. The Afirma® Gene Expression Classifier is designed to further analyze and classify AUS/FLUS and suspicious for follicular/Hurthle cell neoplasm (SFN) specimens. There are limited studies reporting the correlation between Afirma studies and follow-up surgical resections. We performed a retrospective review of 142 cases of AUS/FLUS and SFN with Afirma testing. Correlation with surgical or cytological follow-up was available in 58 cases.  
**Design:** One-hundred and forty-two FNAs with Afirma testing, including 117 AUS/FLUS and 25 SFN cases, dating from 2013-2016 were identified from the archives at our institution. Among those, 58 cases had follow-up, either a surgical resection (N=50) or a repeat FNA (N=8). Forty-six of the 58 cases were AUS/FLUS, including 27 atypical follicular cells (AFC) and 19 follicular lesions (FL); 12 of the 58 cases were SFN.  
**Results:** The overall “benign” Afirma results represented 55% (78/142), and “suspicious” results were 44% (62/142). A total of 58 cases, including 23% (18/78) of “benign” and 65% (40/62) of “suspicious” Afirma cases had follow-up. The results are summarized in Table 1. All 18 cases (18/58, 31%) with “benign” Afirma result were benign on follow-up. Among the remaining 40 cases (40/58, 69%) with “suspicious” Afirma results, 20 were benign and 20 were malignant on follow-up. The AFC group had the most “suspicious” results (21/27, 78%) and the most malignant diagnoses on follow-up (12/21, 57%). In contrast, the FL group had 63% (12/19) “suspicious” and only 3 (3/12, 25%) cases with a malignancy on follow-up.

Table 1. Correlation of Afirma Results with Follow-Up in 58 Cases

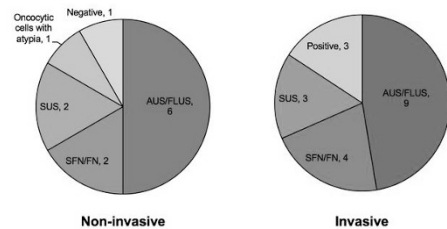
Afirma/FU (N=58)	AFC (N=27)	FL (N=19)	SFN (N=12)	Total %
Bn/Bn (N=18)	6 (22%)	7 (37%)	5 (42%)	31% (18/58)
Susp/Bn (N=20)	9 (33%)	9 (47%)	2 (17%)	34% (20/58)
Susp/Malig (N=20)	12 (44%)	3 (16%)	5 (42%)	34% (20/58)

FU: follow-up; N: number of cases; Bn: benign; Susp: suspicious; Malig: malignant

**Conclusions:** Our data demonstrate an excellent negative predictive value of the Afirma test (benign category) with a 100% correlation on follow-up. However, caution should be taken when there is a “suspicious” Afirma result because a significant number of cases were benign on follow-up.

**430 Predicting Follicular Variant Papillary Thyroid Carcinoma: A 5-Year Retrospective Study at a Single Institution**

*Kirsten Pierce, Louis J Vaickus, Xiaoying Liu. Dartmouth-Hitchcock Medical Center, Lebanon, NH.*  
**Background:** The recently established diagnostic terminology of noninvasive follicular thyroid neoplasm with papillary-like nuclear features (NIFTP) has redefined the categorization of follicular variant of papillary thyroid carcinoma (FVPTC). Cases of encapsulated FVPTC without invasion are now appropriately recognized as benign neoplasms under the diagnosis of NIFTP. This has important implications for prediction of malignancy risk using the Bethesda System for Reporting Thyroid Cytopathology. In this study we wanted to investigate cases diagnosed as FVPTC over the past 5 years at our institution, to find trends among initial fine-needle aspirate (FNA) screening results for invasive and non-invasive lesions.  
**Design:** We searched the electronic hospital database for cases of PTC diagnosed as “follicular variant” in the past 5 years. Then, we compared preceding FNA diagnoses, focusing on invasive versus non-invasive lesions. A chi-square test was used to investigate the relationship between FNA results and presence of invasion.  
**Results:** 28 female and 10 male patients ranging in age from 16-75 were diagnosed with FVPTC at our institution in the past 5 years. 12 had FVPTC with no capsular invasion, 8 of which fell into indeterminate categories on FNA screening. 14 of 19 cases of encapsulated FVPTC with invasion were diagnostically indeterminate on FNA screening. The remaining cases were non-encapsulated. In 2 cases, FNA screening results were not available. 3 cases were diagnosed as positive on FNA, all of which were found to be invasive on surgical resection. The chi-square test, however, revealed that this relationship between positive FNA results and invasion was not significant (p=0.14).



**Conclusions:** As expected, the majority of cases of FVPTC that would now be classified as NIFTP fell into indeterminate categories on FNA screening. A proportionally similar number of invasive lesions also showed indeterminate cytology on screening. Although all cases diagnosed as positive on FNA showed capsular invasion on resection, this was not statistically significant. However, a larger study may yield different results. FNA screening diagnosis cannot be considered a reliable predictor of capsule invasion in FVPTC.

**431 The Prevalence and Distribution of Genotypes of High-Risk Human Papilloma Virus in Women Older Than 65 Years**

Michael A Prochaska, Katie Dennis, Rashna Madan, Ossama Tawfik, Fang Fan. University of Kansas Medical Center, Kansas City, KS.

**Background:** Persistent infection of the uterine cervix with high-risk types of human papilloma virus (hrHPV) is associated with precancerous lesions and the development of invasive cervical cancer. The current screening guideline states that for women older than 65 years, no screening is necessary after adequate negative prior screening results. In this study we retrospectively reviewed the screening results of this population focusing on the HPV prevalence and the distribution of hrHPV genotypes. It may help guiding cervical cancer prevention and clinical management of women in this age group.

**Design:** All cases of Pap smears with HPV testing in women > 65 years in our institution between January 1st, 2014 and January 1st, 2016 were retrieved from the pathology electronic record system (CoPath). The Pap smear interpretation and the corresponding HPV genotyping results were collected.

**Results:** Total of 191 Pap smears with concurrent HPV testing were identified in this age group (mean age 71 years). The Pap smear and HPV testing results are shown in the following table.

Pap smear interpretation (n=191)	HPV results				
	Negative	(+) HPV 16	(+) HPV 18	(+) HPV other <sup>a</sup>	(+) HPV 16 and HPV other
Unsatisfactory (11)	11	0	0	0	0
Negative (128)	113	8	0	10	3
ASCUS (28)	22	0	0	6	0
LSIL (11)	8	1	0	3	1
HSIL or higher (8)	7	1	0	1	1
AGUS (5)	5	0	0	0	0
<b>Total</b>	<b>166 (87%)</b>	<b>10 (5.2%)</b>	<b>0 (0%)</b>	<b>20 (10.5%)</b>	<b>5 (2.6%)</b>

<sup>a</sup>Positive HPV other defined as positive for HPV 31, 33, 35, 39, 45, 51, 52, 56, 58, 59, 66, or 68

**Conclusions:** Among women older than 65 years, high-risk HPV non-16/18 type is the most prevalent subtype recognized in this study (10.5%). The second most prevalent subtype is HPV16 (5.2%), while positivity for two hrHPV subtypes accounts for 2.6%. None of the patients in this study were positive for HPV18. This distribution pattern is different from that in younger women and may help guiding prevention and management of cervical cancer in this age group.

**432 Poor Performance of Bile Duct Brushings (BDBs) is Mostly Attributable to Suboptimal Sampling but Interpretative Challenges Are Also a Factor: A Comparative Analysis of Specimens Procured by Gastroenterologists vs Those Obtained from Surgical Resection Specimens**

Michelle D Reid, Bahar Memis, Ezgi Hachisanoglu, Vaidehi Avadhani, Uma Krishnamurti, Adeboye O Osunkoya, Alyssa Krasinskas, Krisztina Z Hanley, Rebecca Nash, Michael M Goodman, Volkan Adsay. Emory Uni., Atlanta, GA.

**Background:** The relative contributions of procedural shortcomings versus the microscopic misinterpretation to BDB's low sensitivity in diagnosing malignancy are unknown.

**Design:** Identification of malignancy by pathologists was tested in 3 ways: (1) Control group consisting of 247 retrospective BDBs (2000-2015) with followup (each with confirmed carcinoma/benignity) signed out in routine practice by 14 department pathologists, (2) Standardized blinded review by 6 pathologists of 60 select gastroenterologist-generated BDBs (30 benign [with >18 mths of "benign" F/U] and 30 malignant [with biopsy/resection confirmation]) including only adequate samples. (3) Blind review by 6 pathologists of 52 BDBs obtained by brushing the bile ducts during grossing of benign and malignant surgical resection specimens (SR-BDB) with confirmatory matching histology of the brushed area.

**Results:** Test sensitivity in the "real-life" 247 BDBs was 44% but specificity was 97%. In contrast, in the 60 gastroenterologist-generated BDBs (with adequate material) reviewed by 6 pathologists in a "study setting", sensitivity was 66% (range for pathologists, 52-79%) but specificity dropped to 90% (range 76-97%). In the SR-BDBs obtained from surgical specimens in the pathology lab, pathologist sensitivity improved significantly to 86% (vs 66% in gastroenterologist-generated-BDB group; p<0.001) (range of 6 pathologists, 72-97%), but the specificity dropped further to 86% (range for pathologists 70-100%), though not significantly (p=0.21). Ambiguous diagnoses (atypical/suspicious) showed a statistically significant drop from 42% for gastroenterologist-generated-BDBs to 22% in the BDBs obtained from surgical specimens (p<0.001).

**Conclusions:** The low sensitivity of BDBs in detecting malignancy is significantly attributable to procedural undersampling by gastroenterologists, as evidenced by significantly improved sensitivity (p<0.001) and accuracy (p=0.007) rates in BDBs obtained from surgical specimens in the pathology lab vs gastroenterologist-generated ones. This is partly due to elimination of quantitatively suboptimal samples. However, poor performance is also attributable to pathologists' general reluctance to give a definitive malignant diagnosis, as evidenced by their markedly improved sensitivity and accuracy rates in both study setting environments, situations that remove actionable consequences, but at the expense of overall specificity.

**433 Successful Utilization of Pre-Stained Cytology Smears as a Source of Material for Targeted Next Generation Sequencing (NGS) in Clinical Practice: An Institutional Experience**

Rongqin Ren, Nabil Ashraf, Catherine I Dumur, Jorge A Almenara, Michael O Idowu, Celeste N Powers, Adele O Kraft. Virginia Commonwealth University Health System, Richmond, VA.

**Background:** Endobronchial-ultrasound with fine needle aspiration (EBUS-FNA), ultrasound-guided fine needle aspiration/needle core biopsy (US-FNA/US-NCB), palpation-guided fine needle aspiration (PG-FNA) or computerized tomography-guided needle core biopsy (CT-NCB) allow sampling of malignant tumors for diagnosis and staging of patients presenting with unresectable advanced disease. Cytology smears are routinely utilized for rapid-on-site evaluation, the remaining material prepared as formalin-fixed, paraffin embedded (FPPE) cell block. The cells and/or tissue acquired in these procedures are often the only available source for molecular testing essential for therapy selection. FPPE tissue is the most widely utilized source for NGS in clinical settings but alternate sources may need to be utilized when FPPE is inadequate.

**Design:** Cytology smears from 36 individual patients collected between November 2015 and September 2016 were submitted for the Ion AmpliSeq™ Cancer Hotspot Panel v2 (CHP2) assay. Samples were collected by CT-NCB (N=15), EBUS-FNA (N=11), US-FNA (N=7), PG-FNA (N=2) and US-NCB (N=1). Biopsy sites included lung (N=16), lymph node (N=13), bone/soft tissue (N=4) and thyroid (N=3). Reasons for not using cell block/needle core biopsy: limited cellularity (N=28), attempted but failed established quality control parameters (N=6) or unavailable (N=2). Tumor percentage on smears of at least moderate cellularity and no appreciable necrosis as estimated by experienced cytopathologists was: 15-40% (N=7), 50-75% (N=10), and 80-100% (N=19). Cytology smears underwent digital scanning, 72-hour xylene immersion, coverslip removal, pre-wetting with ATL buffer (Qiagen) and scrapping off the glass slide with sterile scalpel blade. The use of pre-stained smears for CHP2 assay was previously validated. Variant annotations were determined using our institutional knowledge base system.

**Results:** The total yield of double-stranded (ds) DNA from smear slides was 0.1-0.5 µg (N=13), 0.5-1 µg (N=7), to ≥1 µg (N=16). All materials submitted for testing were sufficient for sequencing. Pathogenic/Likely Pathogenic variants were detected in over 72% of cases (N=26).

**Conclusions:** Pre-stained cytology smears are a reliable source of good quality material for NGS assays and can be routinely utilized for the detection of somatic variants in solid tumors, preventing more expensive repeat procedures.

**434 GATA3 Can Be Positive in Serous Carcinoma of Fluid Specimen (Failfalls of Immunohistochemical Stain Markers Analysis)**

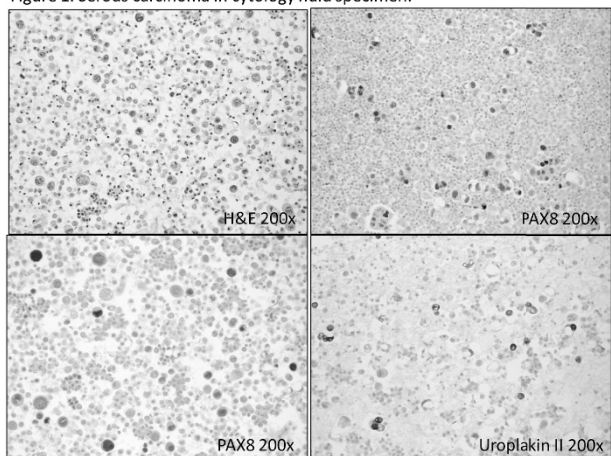
Shuyue Ren, William Klump. Cooper University Hospital, Camden, NJ.

**Background:** Immunohistochemical studies are widely used in cytology fluid specimen to identify the tumor source. High grade serous carcinoma is an aggressive tumor of gynecological system. Diagnosis is often delayed because symptoms are non-specific. 75-80% of cases present with advanced stage and can involve peritoneal and pleura. GATA3 is a transcription factor important in the differentiation of breast epithelia, urothelia, and subsets of T lymphocytes. It has been suggested to be useful in the evaluation of carcinomas of mammary or urothelial origin, and less likely in other origins. The aim of the study is to evaluate GATA3 and some other markers in the diagnosis of serous carcinoma in cytology fluid specimen.

**Design:** We examined 19 fluid cases positive for serous carcinoma of uterine or ovarian primary, including 16 ascites fluid and 3 pleural fluid. Immunohistochemical (IHC) markers include GATA3 (Clone L50-823, Cell Marque, 1:10), PAX8 (Clone MRQ-50, Roche, 1:15), uroplakin II (Clone BC21, BioCare, 1:50), and SALL4 (Clone 6E3, Cell Marque, 1:20). IHC staining was performed on cell blocks. IHC staining was evaluated by 2 pathologists separately and scored on a three tiered scale (negative, weak, strong). **Results:** The results are shown in table 1 and figure 1.

Markers	Weak positive	Strong positive	Negative
GATA3	1	4	14
PAX8	1	15	3
SALL4	1	0	18
uroplakin II	0	2	17

Figure 1. Serous carcinoma in cytology fluid specimen.



**Conclusions:** GATA3 can be expressed in serous carcinoma of gynecological system (5/19, 26%) predominantly with focal reactivity. Uroplakin II antibody is another specific marker for urothelial carcinoma. Our 2 out of 19 cases showed focal Uroplakin II staining. SALL4 has been shown as a useful immunohistochemical marker for germ cell tumors and is focally and weakly expressed only in 1 of 19 cases. PAX8 is a highly sensitive marker for thyroid, renal, Müllerian, and thymic tumors. In our 19 cases, 16 tumors showed PAX 8 expression (84%). In conclusion, to avoid misdiagnosis of cytologic fluid specimens, multiple combined IHC markers are necessary for evaluation of tumor primary in fluid specimen.

#### 435 Comparison of HPV DNA and HPV mRNA Testing in a Cervical Primary Screening Population

*Stephen Reynolds, Christine White, Padmaja Naik, Roisin O'Brien, Trinh Pham, Imogen Sharkey Ochoa, Carrie Powles, Noel Bolger, Jacqui Barry O'Crowley, Prerna Tewari, Sharon O'Toole, Charles Normand, Linda Sharp, Grainne Flannelly, John J O'Leary, Cara M Martin.* Trinity College Dublin, Dublin, Ireland; Coombe Women & Infants University, Dublin, Ireland; Newcastle University, Newcastle on Tyne, United Kingdom; National Screening Service, Dublin, Ireland.

**Background:** This study aims to evaluate cervical screening strategies including cytology and two different HPV tests; the Cobas HPV test (Roche) which detects DNA from 14 HR-HPV types including genotyping for HPV16 and 18 and the Aptima HPV assay which detects HPV E6/E7 mRNA from the same 14 HR-HPV types.

**Design:** This longitudinal study is being conducted in partnership with the National Cervical Screening Programme. 13,000 women attending for their routine smear test are currently being recruited into the study with informed consent. HPV testing is performed on all samples.

**Results:** To date, 5000 women, with a median age of 38 years, have been enrolled in the study. HPV DNA was detected in 14% and HPV mRNA was detected in 13%. The rate of HPV DNA and mRNA positivity was almost three times higher in women under the age of 30 years compared to women over 30 years. Agreement between the two assays was good ( $Kappa=0.692$ ) and no significant differences was seen across cytology grades. Findings from the first 1000 women enrolled showed 12.4% ( $n=124/1000$ ) were HPV DNA positive, 35.5% ( $n=44/124$ ) of these had abnormal cytology (ASCUS+). 11.5% ( $n=115$ ) were HPV mRNA positive of which 34.8% ( $n=40/115$ ) had abnormal cytology (ASCUS+). Overall 93% ( $n=931/1000$ ) of samples had NAD (No Abnormality Detected) on cytology, 8% ( $n=74$ ) were positive HPV DNA and 8% ( $n=75$ ) positive for HPV mRNA.

**Conclusions:** HPV primary screening is believed to be more accurate than cytology based screening. Preliminary results from this study have shown that HPV DNA and mRNA based tests detect a similar rate of HPV. Follow up data will provide information to determine the clinical performance of each test for detecting high grade cervical lesions.

#### 436 Performing Core Biopsy Alongside Fine Needle Aspiration of Metastatic Head and Neck Squamous Cell Carcinoma Improves Tissue Yield for Ancillary Studies without Increased Complications or Tissue Seeding

*Lisa M Rooper, Mohammed T Lilo, William H Westra, Zahra Maleki.* Johns Hopkins Hospital, Baltimore, MD.

**Background:** Historical concerns about tumor seeding and procedural complications have limited the use of core biopsy in the workup of neck metastases. However, the growing importance of obtaining sufficient tissue for ancillary testing, particularly HPV studies, warrants reconsideration of this practice. At our institution, small-gauge core biopsies are frequently performed alongside fine-needle aspirations (FNAs) of neck masses and cervical lymph nodes at the discretion of the performing physician. This study evaluates how core biopsy influences diagnostic yield and patient outcomes in the FNA workup of metastatic head and neck squamous cell carcinoma.

**Design:** We identified all neck FNAs between July 2006 and July 2016 that carried a diagnosis of metastatic squamous cell carcinoma, including 148 with FNA only and 150 with FNA and core biopsy. All FNAs were performed using 22 to 25 gauge needles, while core biopsies employed 20 gauge biopsy devices. For each case, we documented the availability of tissue for ancillary testing as well as the number and results of stains performed. We reviewed the electronic medical record for any complications associated with the procedures and, if available, evaluated follow-up resection specimens for dermal and subcutaneous tumor seeding.

**Results:** Among FNA-only cases, just 79 (53.4%) had sufficient material to create a cell block for ancillary studies, while all 150 (100%) FNA/core cases allowed for histologic preparations. Stains were attempted on 27 FNA-only cases (18.2%) compared to 108 FNA/core cases (72.0%), and produced definitive results in 18 FNA-only cases (12.0%) versus 106 FNA/core cases (70.7%). Only 1 (0.7%) FNA-only patient and 1 (0.7%) FNA/core patient experienced swelling and drainage, and no patients in either group developed bleeding or infection. In cases with follow-up resections, there was no evidence of dermal or subcutaneous tumor deposits along the needle tract after either procedure.

**Conclusions:** These findings suggest that performing core biopsy in conjunction with neck and cervical lymph node FNA provides more tissue for ancillary studies and produces more definitive staining results than FNA alone. Moreover, core biopsy is not associated with a significant increase in procedural complications or evidence of tumor seeding compared to FNA. Small-gauge core biopsy should be considered as a useful adjunct to FNA evaluation for the workup of metastatic head and neck squamous cell carcinoma.

#### 437 Negative UroVysion FISH Cases with Sub-Threshold Chromosomal Abnormalities Carry a Higher Risk of Developing High-Grade Urothelial Carcinoma Compared to True Negatives

*Matthew Root, Sandhya Dasaraju, Jimmie Stewart, Badrinath Konety, Paari Murugan, Khalid Amin.* University of Minnesota Medical Center, Minneapolis, MN.

**Background:** Since 2001 the FDA has approved fluorescence in situ hybridization (UroVysion FISH) test for the detection of high-grade urothelial carcinoma (HGUC) in urine specimens. This assay utilizes three centromeric enumeration (CEP) probes for chromosomes 3, 7, and 17 to detect polysomy and one locus specific (LSI) probe for detection of 9p21 deletion. A positive test is denoted as having either 4 cells with polysomy of chromosomes 3, 7, and 17, or 10 cells with deletion of 9p21. Cases that do not meet this threshold are designated as negative. However, a significant number of negative FISH do exhibit sub-threshold chromosomal abnormalities. This study was undertaken to compare the risk of malignancy between the true negative and abnormal negative (atypical) cases as determined by follow-up biopsies.

**Design:** 1509 UroVysion FISH tests performed at our institution from 2010-16 read as negative were reviewed and categorized into negative (no chromosomal abnormalities) and atypical (at least one cell with chromosomal abnormalities), and followed up (one-year) for development of biopsy proven urothelial carcinoma. Based on the follow up results, relative risk of developing malignancy for both categories was determined.

**Results:** Of the 1509 FISH screens performed, there were 1172 (78%) negative and 337 (22%) atypical results. Of these, 333 cases received follow-up histologic diagnosis with 244 (20.8%) cases belonging to negative category, while 89 (26.4%) constituted atypical category. 56 (22.9%) of the 244 negatives, had HGUC diagnosis on follow-up while 43 (17.6%) had low-grade urothelial carcinoma (LGUC) and 145 (59.4%) benign diagnosis. In the atypical category, 42 (47.2%) were diagnosed as HGUC, 13 (14.6%) as LGUC and 34 (38.2%) as benign. The sensitivity and specificity of atypical FISH in predicting HGUC were 42.8% and 80% respectively. Overall, for individuals who had a negative FISH screen, the incidence of HGUC was 4.7%, compared to 12.4% for atypical group, a 2.6 x relative risk increase (chi-square test,  $p$  value=0.000017). In contrast, the incidence of LGUC was 3.6% and 3.8% for the negative and the atypical groups respectively.

**Conclusions:** The results show a significantly higher risk of developing HGUC in the atypical category compared to the negative category. Reporting atypical results alerts clinicians for more rigorous follow-up and early detection of HGUC.

#### 438 Next Generation Sequencing Adds Value to Cytology and Fluorescence In Situ Hybridization in the Diagnosis of Bile Duct Brushing Specimens

*Matthew W Rosenbaum, Jonathan S England, Raza S Hoda, Ronald Arpin, Long Le, David G Forcione, Anthony Iafrate, Martha B Pitman.* Massachusetts General Hospital, Boston, MA.

**Background:** Bile duct brushing (BDB) cytology is challenging with poor sensitivity for the detection of high-risk lesions (HRLs; e.g. high-grade dysplasia and malignancy). We recently reported that NGS was comparable to FISH in the detection of HRLs. Here we report on the subsequent prospective application of NGS and FISH as ancillary tests to BDB cytology.

**Design:** BDB cytology with FISH and/or NGS performed between 08/2015 and 04/2016 were reviewed with clinicopathologic follow up. NGS was performed via a multiplex PCR platform that sequences areas of 39 oncogenes. Performance of cytology, FISH, and NGS were calculated based on clinicopathologic follow-up.

**Results:** 84 BDB specimens from 67 patients were reviewed. There were 6 positive, 5 suspicious, 25 atypical, and 48 negative for malignancy samples by cytology. Of the 67 with FISH, 11 were positive (16.4%), and of the 76 with NGS, 21 revealed oncogenic mutations (27.6%), including *KRAS* ( $n=14$ ), *TP53* ( $n=10$ ), *GNAS* ( $n=4$ ), *APC* ( $n=3$ ), *SMAD4*, *PIK3CA*, and *FGFR2* ( $n=2$  each), and *ERBB2*, *ESR1*, *FBXW7*, *STK11*, and *PIK3R1* ( $n=1$  each). 65 patients had follow-up (30 histologic, 35 clinical follow-up), that supported a benign or malignant diagnosis (Table 1). Sensitivity and specificity of cytology was 37% and 100%, increasing to 59% and 96% with FISH, and improving to 85% and 93% with the addition of NGS (Table 2).

**Conclusions:** NGS analysis of BDB is a useful adjunct to biliary cytology. The addition of NGS resulted in dramatically improved sensitivity in the detection of neoplasia compared to cytology and/or FISH. The routine use of NGS for BDB specimens adds significant value to cytology even with FISH.

Cytology	Benign (n=55)	HRL (n=27)
Benign (%)	76	22
Atypical (%)	24	41
Suspicious (%)	0	15
Carcinoma (%)	0	22
FISH		
Negative (%)	86	61
Positive (%)	5	39
Insufficient (%)	9	
NGS		
Negative (%)	96	37
Positive (%)	4	63
FISH or NGS		
Negative (%)	93	22
Positive (%)	7	78
Cytology or FISH		
Negative (%)	96	41
Positive (%)	4	59
Cytology or NGS		
Negative (%)	96	26
Positive (%)	4	74
FISH, NGS, or Cytology		
Negative (%)	93	15
Positive (%)	7	85

	Sensitivity	Specificity
FISH	39%	95%
NGS	62%	96%
Cytology	37%	100%
Cytology+FISH	59%	96%
Cytology+NGS	74%	96%
Cytology+FISH+NGS	85%	93%

**439 miR-375 Expression in the Cytological Algorithm Approach for Identification of Non-Invasive Follicular Thyroid Neoplasms with Papillary-Like Nuclear Features**

*Esther Rossi, Maurizio Martini, Sara Capodimonti, Tonia Cenci, Mirna Bilotta, Tommaso Bizzarro, Alfredo Pontecorvi, Celestino P Lombardi, Luigi M Larocca.* Catholic University, Rome, Italy; Catholic University, Rome, Italy.

**Background:** Non-invasive follicular thyroid neoplasm with papillary-like nuclear features (NIFTP) represents a challenging insight for the diagnosis and management of thyroid carcinoma. Some authors proposed histological criteria able to distinguish NIFTPs from invasive follicular variant of PTC (I-FVPTC). Hence, NIFTPs may have repercussions on the diagnostic categories on fine needle aspiration (FNAC). Although few authors identified these NIFTPs on FNAC based on morphological criteria, this discrimination is not always easy and possible. The additional role of the expression profiling of miR-375, was tested in order to discriminate NIFTPs on FNAC.

**Design:** We recorded all the 13LBC samples diagnosed as indeterminate lesions (atypia of undetermined significance-AUS/FLUS or Follicular neoplasm-FN) proved to be histological FVPC between January 2014 and March 2015. In an algorithm approach, we analyzed the architectural, cytoplasm, nuclear parameters and miR-375 expression. We also evaluated a cohort of 16 PTCs and 11 follicular adenomas (FA) in the same period

**Results:** We reported 8 NIFTP and 5 I-FVPTC at histology. Their cytological diagnoses included 2AS/FLUS for NIFTPs whilst all the remaining cases were FNs (6 NIFTPs and 5 I-FVPCs). FAs included 9AUS/FLUS and 2FNs, while all 16PTCs were PMs at FNACs. Whilst a microfollicular pattern was recognized in both NIFTPs and I-FVPTCs, the morphological analysis demonstrated that NIFTPs had nuclear size smaller than 20µm, lack of any nuclear irregularities and 100% wild type *BRAF<sup>V600E</sup>* gene when compared with I-FVPCs (12.5%) and PTCs (31%). MiR-375 discriminated among FA, NIFTPs, I-FVPCs and PTCs with high significance. The quantitative PCR analysis to assess the expression levels of miR-375 demonstrated an increasing and statistically significant up-regulation among the 4 categories with higher expression levels in I-FVPCs and PTCs, intermediate for NIFTPs and low value for FAs

**Conclusions:** A tree algorithm approach with the evaluation of the morphological features (including also nuclear size and grooves), *BRAF<sup>V600E</sup>* analysis and the application of miR-375 may support and favor the cytological identification of NIFTPs among the FNAC diagnostic categories, mostly in the indeterminate lesions.

**440 Cervical Biopsy Rates Before and After the Introduction of HPV Type Reporting in Co-Tests with Negative Cytology**

*Heather Ruff, Dina Mody, Eric Luna, Donna Arnylagos, Michael J Thrall.* Houston Methodist Hospital, Houston, TX; BioReference Laboratories, Houston, TX.

**Background:** In 2013 our laboratory introduced Roche cobas High Risk Human Papilloma Virus (HR-HPV) testing with routine HPV type reporting. The shift from Hybrid Capture II HPV testing to Roche led to an observed increase in biopsies for patients with negative Pap tests with positive HR-HPV.

**Design:** We conducted a retrospective review of data from our facility to examine biopsies conducted on patients with negative Pap tests and positive HR-HPV. We compared data from when we used Hybrid Capture for HR-HPV testing in 2012 to data from 2015 after we had implemented Roche testing for HR-HPV.

**Results:** In 2012, 38 biopsies were performed on patients with negative Pap test and positive HR-HPV, out of 82,721 Pap tests (0.046%). In 2015 the number of biopsies performed on patients with negative Pap test and positive HR-HPV test was 367, out of 115,104 Pap tests (0.319%; p<.001). Of these, 134 had HPV type 16, 48 type 18, and 189 only had “other” HR-HPV types. Very few requests for primary HPV screening were received in 2015; these results reflect co-testing. We observed an increased detection rate of HSIL or greater lesions (5.3% in 2012 to 7.9% in 2015), but it was not statistically significant (p=0.75); the introduction of LAST guidelines is also a confounding factor. 17 HSIL or greater lesions were found in women with types 16 or 18 (9.3%) and 12 were found in women with “other” HR-HPV types (6.3%).

**Conclusions:** The introduction of HR-HPV testing with type reporting is associated with a marked increase in the number of women undergoing biopsy for HR-HPV despite negative cytology. More than half of these have a HR-HPV type other than type 16 or 18, despite recommendations to repeat co-testing instead.

**441 Cytologic-Histologic Correlation of PD-L1 Immunohistochemistry in Lung Carcinomas**

*Eleanor Russell-Goldman, Lynette M Sholl, Marina Vivero.* Brigham and Women’s Hospital, Boston, MA.

**Background:** PD-L1 inhibitors are increasingly used as second-line treatment for patients with advanced NSCLC, with a potential role as first-line treatment. PD-L1 immunohistochemistry (IHC) in tumor cells (TC) and tumor-associated immune cells (IC) is used to identify patients who may respond to PD-L1 inhibition. Studies evaluating the performance of PD-L1 IHC in cytology specimens are lacking. Our aim is to compare PD-L1 IHC in cytology cell blocks and surgical specimens.

**Design:** 40 surgical specimens obtained between 2013 and 2016 with matching cytology specimens were stained with anti-PD-L1 (E1L3N, Cell Signaling Technologies, Danvers, MA). Membranous positivity was scored as percentage of TC and IC by two pathologists. Results were compared between cytology and surgical specimens, and interobserver concordance assessed using Spearman’s correlations.

**Results:** Average PD-L1 positivity was 24% in TC and 9% in IC in cytology specimens (range 0-90% and 0-50%, respectively), and 30% in TC and 6% in IC in surgical specimens (range 0-95% and 0-50%, respectively). There was a strong positive correlation between PD-L1 positivity in TC in cytology and surgical specimens (spearman’s rho = 0.70; p<0.0001), but not between PD-L1 positivity in IC in cytology and surgical specimens (r=0.13, p=0.4). Interobserver concordance was strong for TC in cytology and surgical specimens (r=0.94 and r=0.91, respectively; p<0.0001 each), and between IC in cytology and surgical specimens (r=0.60 and r=0.67; p<0.0001 each).

**Conclusions:** TC PD-L1 IHC positivity in cytology specimens correlates strongly with results obtained from matching surgical specimens, with excellent interobserver agreement. PD-L1 IHC in IC within cytology specimens do not correlate with matched surgical specimens, and thus these samples may not fully reflect the tumor microenvironment.

**442 Fine Needle Aspiration Cytology of Hepatic Metastases of Neuroendocrine Tumors: A 20-Year Retrospective, Single Institutional Study**

*Omer Saeed, Harvey Cramer, Xiaoyan Wang, Howard Wu.* Indiana University School of Medicine, Indianapolis, IN.

**Background:** By definition, neuroendocrine tumors (NETs) exhibit predominant neuroendocrine differentiation. The liver is the most common metastatic site of these tumors. Fine needle aspiration (FNA) is considered an excellent technique for documenting these lesions. The aim of this study is to evaluate the diagnostic accuracy of FNA in metastatic NETs to the liver and to determine the grade and origin of these metastases.

**Design:** Our laboratory information system was searched from 1997 to 2016 to identify all cases of metastatic NETs to the liver that were sampled by FNA. The cytopathology and correlating surgical pathology reports as well as the patients’ electronic medical records were reviewed. The cytohistologic type and grade of the metastatic NETs, and site of the patient’s primary were recorded.

**Results:** Of the 271 patients included in the study, 160 were males (59%) and 111 were females (41%) with ages that ranged from 7 to 88 years. High-grade NETs, including small cell and poorly differentiated neuroendocrine carcinomas, constituted 60% (164/271) of the cases, while low grade NETs, including well differentiated pancreatic and gastrointestinal NET (grade1 and grade 2), pheochromocytoma, paraganglioma and carcinoid tumor of lung, constituted 40% (107/271). The most common diagnosis was metastatic small cell carcinoma accounting for 45% (122/271) of the cases, while pheochromocytoma and paraganglioma represented only 1.1% (3/271) and 0.4% (1/271) respectively. The most common primary sites were lung (44%; 119/271), followed by pancreas (19%; 51/271) and small intestine (8%; 21/271).

Primary site	No.
Lung	119
Pancreas	51
Unknown	32
Small bowel	21
Colorectal	9
Prostate	5
Adrenal	3
Bladder	2
Stomach	2
Appendix	1
Esophagus	1
Liver	1
Soft palate	1
Data unavailable	8
Total	271

The FNA diagnosis was confirmed by histopathology in 121 cases that have a concurrent biopsies or resection specimens.

**Conclusions:** FNA is an accurate method for diagnosis of metastatic NETs to the liver. There were no discrepancies between the FNA diagnosis and the follow-up histology. There were significantly more high-grade (60%) than low-grade (40%) metastatic NETs to the liver. In our practice, lung (44%), pancreas (19%) and small intestine (8%) were the most common primary sites of metastatic NETs. In a significant number of patients (12%), a primary site could not be established.

**443 Are There Cytomorphological Alterations in Exfoliated Urothelial Cells Induced by Systemic Gemcitabine-Cisplatin (GC) Treatment?**

*Samah Saharti, Kimberly R Kruczek, Lu Wang, Eva M Wojcik, Elizabeth Henry, Stefan Pambuccian, Guliz Barkan.* Loyola University Health System, Maywood, IL.

**Background:** One of the management options for muscle invasive high grade urothelial carcinoma is neoadjuvant/adjuvant chemotherapy, specifically GC regimen. Previous studies have outlined the morphological changes induced by systemic therapy agents such as cyclophosphamide, but to date cytomorphologic changes in urine cytology caused by GC treatment have not been reported.

**Design:** Electronic medical records were reviewed to identify patients who received at least one cycle of systemic GC for urothelial carcinoma from 1/1/2007-9/30/2014. Demographics, clinical characteristics, treatment settings, number of cycles, specimen type were noted. Urine cytology cases from age-matched patients with history of urothelial carcinoma, treated with modalities other than GC were identified as control cases. Urine cytology slides were assessed by two independent pathologists who were blinded to the patients' treatment history and reclassified according to the Paris System (TPS) of reporting urine cytology as Negative for High Grade Urothelial Carcinoma (NHGUC), Atypical Urothelial Cells (AUC), Suspicious for High Grade Urothelial Carcinoma (SHGUC) and High Grade Urothelial Carcinoma (HGUC).

**Results:** 74 patients treated with GC were identified. Median age at treatment was 65 (range 42-80); 58 (78%) patients were male. Median number of cycles was 4 (range 1-9). Treatment settings included: 15 (20%) neoadjuvant, 38 (51%) adjuvant, and 21 (28%) metastatic. 10 (14%) patients were previously treated with intravesical therapy (9 BCG, 1 mitomycin). 36 (49%) patients had urine cytology available. 56 cytology specimens within 12 months post-chemotherapy were reassessed in parallel with their matched control cases. 67% of the originally diagnosed AUC cases had been downgraded to NHGUC after applying TPS criteria. Follow-up of all AUC cases showed either benign biopsies or negative cytology. None of the control cases were diagnosed as AUC or higher on review.

**Conclusions:** The changes induced by chemotherapeutic GC does not pose a diagnostic problem as it appears to morphologically not influence urothelial changes. Thus, pathologists must be aware that, following these types of treatment, if atypia seen in urothelial cells, the cause should be investigated. Applying TPS criteria is of valuable practical implication in order to eliminate atypical call for atypia produced by known etiology.

**444 Stone-Related Atypia in Urinary Tract Cytology Revisited**

*Samah Saharti, Guliz Barkan, Eva M Wojcik, Stefan Pambuccian.* Loyola University Health System, Maywood, IL.

**Background:** Urolithiasis induces changes in urothelial cells, which may be interpreted as atypical and therefore result in an increase the "atypical urothelial cells" (AUC) rate. The aim of this study was to revisit the contribution of the "stone artifact" on the rates of AUC in a contemporary series of urine cytology (UCy) cases. As the Paris system (TPS) emphasizes strict criteria for AUC diagnosis and recommends the exclusion of any case with a known cause of reactive atypia from this category, we have also examined the potential reclassification utilizing TPS.

**Design:** A search of our pathology database from 1/1/2006 to 9/15/2016 identified all patients with UCy samples collected within a 30 day-period of the extraction or passage of urinary tract stones. Demographics, specimen type, stone location and follow-up surgical biopsy diagnoses were recorded. A number of background and cytologic features were assessed semi-quantitatively and UCy slides were reclassified according to TPS criteria.

**Results:** We identified 336 UCy (25 voided urines, 249 bladder washings/barbotages, 50 upper urinary tract specimens, and 12 neobladder) specimens from 279 patients collected within 30 days of a urinary tract stone passage or extraction. 184 (66%) patients were male and the median age was 62 (range 18-93). Locations of stones included: 199 (59%) kidney, 82 (24%) bladder, 41 (12%) ureter, 9 (2.7%) unspecified and 5 (1.5%) urethra. 29 specimens were diagnosed as AUC (8.6%), 19 as suspicious (SUS, 2.4%) or positive (POS) for urothelial carcinoma (3%). AUC cases were associated with kidney (n=18, 72%), bladder (n=7, 24%) or ureter (n=4, 14%) stones. There were only 2 patients with AUC who had a diagnosis of HGUC or CIS during a median 5 year follow-up. All cases diagnosed with either POS or SUS showed urothelial carcinoma eventually. Cytologic features in AUC slides included cytoplasmic collarettes (45%), squamous metaplasia (55%), small nucleoli (59%) and N/C ratio > 0.5 (68%). Applying TPS criteria, we were able to downgrade 20/22 (91%) of AUC cases to negative for high grade urothelial carcinoma.

**Conclusions:** The urolithiasis-related cytologic changes seen in Thinprep® slides are similar to those described in conventional UCy. Changes caused by urinary tract calculi can be diagnostically challenging and have frequently resulted in AUC diagnoses before the implementation of TPS. The use of TPS criteria can markedly reduce but not eliminate AUC diagnoses. The fact that urinary tract stones may rarely be associated with urothelial carcinoma should be considered before attributing more severe cytologic changes seen in UCy to "stone artifact".

**445 Does the Fear of "Overcalling" Noninvasive Follicular Thyroid Neoplasm with Papillary-Like Nuclear Features (NIFTP) Result in Changes in the Cytopathologists' Use of the Positive (POS) and Suspicious (SUS) for Papillary Carcinoma Diagnostic Categories in Thyroid Fine Needle Aspiration (FNA)? Observations from an Academic Medical Center**

*Samah Saharti, Stefan Pambuccian, Mohammad Atieh, Guliz Barkan, Eva M Wojcik, Swati Mehrotra.* Loyola University Health System, Maywood, IL.

**Background:** Humans are driven more strongly to avoid losses than to achieve gains. Pathologists in general would rather undercall than overcall. After the recent proposal to remove some cases previously classified as follicular variant of papillary thyroid carcinoma (FVPTC) from the malignant category, by reclassifying them as NIFTP, some pathologists have decided not to use the malignant category for thyroid FNA's. The aim of this study was to determine if the "NIFTP conundrum" led to any changes in the use of thyroid Bethesda (TB) diagnostic categories, specifically on the positive predictive value (PPV) of the categories suspicious (SUS) and positive (POS) for papillary carcinoma in thyroid FNAs.

**Design:** We compared the frequency of thyroid FNA diagnoses made according to the 6 TB categories (Unsatisfactory [UNSAT], Benign, Atypical [ATY], Suspicious for follicular neoplasm (SFN), SUS and POS) from 01/01/2014 to 9/15/2016 by 5 board certified cytopathologists (CP) before (P1) and after (P2) our group became aware and concerned about NIFTP (6/30/2015). After reclassifying all FVPTC, we used the histopathology diagnosis to determine the PPV of POS and SUS+POS diagnoses for the two periods.

**Results:** During the study period, the 5 CP diagnosed 2889 cases.

	CP1		CP2		CP3		CP4		CP5		Total	
	P1 (N=102)	P2 (N=300)	P1 (N=198)	P2 (N=108)	P1 (N=213)	P2 (N=234)	P1 (N=356)	P2 (N=416)	P1 (N=299)	P2 (N=253)	P1 (N=1468)	P2 (N=1421)
UNSAT	1.7%	2.50%	0.51%	5.56%	0.9%	4.72%	4.78%	7.17%	2.9%	5.1%	2.92%	5.07%
BENIGN	82.84%	81.1%	89.81%	81.48%	83.57%	80.71%	81.18%	83.41%	85.62%	84.58%	82.83%	83.18%
ATY	10.45%	6.35%	7.58%	2.78%	6.57%	6.30%	5.62%	3.36%	6.35%	4.35%	7.40%	4.79%
SFN	0.75%	0.28%	2.53%	2.78%	2.35%	1.57%	2.25%	1.12%	1.67%	0.75%	1.77%	1.00%
SUS	0.50%	1.11%	1.01%	0.93%	0.94%	1.18%	1.12%	0.90%	0.67%	0.75%	0.82%	0.95%
POS	1.7%	5.56%	7.58%	6.48%	5.63%	5.91%	5.08%	4.04%	3.9%	4.35%	4.7%	4.92%

Apart from a slight decrease in ATY percentage and increase in UNSAT percentage there were no significant differences between the diagnostic rates for any of the other TB categories, either for the group or for individual CP. After reviewing and reclassifying all cases originally diagnosed as FVPTC, we only found 2 cases of NIFTP diagnosed as suspicious (n=1) or positive (n=1).

**Conclusions:** Awareness of the potential negative impact of the reclassification of some cases of FVPTC as NIFTP (and not malignant) did not lead the cytopathologists in our institution to change their thyroid FNA diagnostic behavior. The loss of PPV caused by the reclassification of NIFTP was minor.

**446 A System for Automated Adequacy Assessment of Thyroid Fine Needle Aspiration Samples**

*Daniel Schmolze, Andrew Fischer.* City of Hope, Duarte, CA; UMass Memorial Medical Center, Worcester, MA.

**Background:** Thyroid fine needle aspiration (FNA) biopsies have a high rate of insufficient cells, often more than 10%. Rapid on-site evaluation (ROSE) can help assure adequate samples, but only a portion of the sample is able to be evaluated by ROSE. Material prepared for ROSE is generally unavailable for ancillary testing. Finally, ROSE is time-consuming and poorly reimbursed. We addressed these issues by developing an automated imaging algorithm that can be applied to the FNA using non-destructive fluorescence microscopy.

**Design:** Cases consisted of excess, (non-"dilute") residual thyroid FNA material in ThinPrep vials (Hologic) that had been previously diagnosed. Twelve cases served as a training set for the development of an image analysis algorithm, while eleven cases were used for testing of the algorithm. For each case, the entire sample was labeled with a fluorescent nuclear stain without washing, placed into a 4 mm circular well on a specialized glass microscope slide, and imaged by conventional epifluorescent microscopy. Following imaging, the entire sample was returned to a ThinPrep vial and

a single ThinPrep slide was prepared and blindly scored for adequacy using standard Bethesda criteria. The fluorescent images were assessed by an image analysis algorithm. The standard and computer derived results were then compared.

**Results:** The image analysis algorithm was developed in R (R Core Team) using segmentation techniques to identify groups of cells and nuclei within each group. The algorithm was optimized using the twelve cases in the training set, and then applied to the eleven test cases. 8 of 8 adequate samples in the test group were correctly scored as adequate, and 2 of 3 cases that were inadequate were correctly scored as inadequate by the algorithm. One case, diagnosed as adequate on the ThinPrep slide, was erroneously designated as not adequate by the algorithm.

**Conclusions:** Our results demonstrate the feasibility of automating thyroid adequacy assessment using a fluorescent labeling technique followed by computer image analysis. Unlike traditional ROSE, the entire sample is imaged and assessed for adequacy, precluding error due to non-representative sampling. The staining can be performed within a physiologic media such as RPMI to enable recovery of material for any application and the imaging is non-destructive, enabling the entire sample to be recovered or triaged. Finally, the technique eliminates the need for cytopathology expertise.

#### 447 Noninvasive Follicular Thyroid Neoplasm with Papillary-Like Nuclear Features (NIFTP): Cytomorphologic and Molecular Correlates

*Christopher Sebastiano, Bin Xu, Ronald Ghossein, Oscar Lin, Jean-Marc Cohen.* Memorial Sloan Kettering Cancer Center, New York, NY; Sunnybrook Health Sciences Center, Toronto, Canada.

**Background:** The emergence of NIFTP as a diagnostic entity requires evaluation of its cytomorphology and molecular features to avoid overdiagnosis of malignancy on cytologic material.

**Design:** We reviewed cases diagnosed as follicular variant of papillary thyroid carcinoma (FVPTC) from 2002-2016 at our institution. Cases were classified using current criteria as infiltrative FVPTC, encapsulated FVPTC with invasion (EFVPTC) or NIFTP. All cases which had prior in house thyroid FNA cytology were correlated with surgical pathology results, as well as molecular (Afirma) results. All available cytologic material was re-reviewed.

**Results:** A total of 139 cases were identified; 25 infiltrative FVPTC, 29 EFVPTC, and 85 NIFTP. Patient median age was 47 (range 16 – 85). 93 patients were female and 46 were male. The distribution of cytologic diagnoses by Bethesda category is summarized in Table 1. Most cases were classified as follicular neoplasm/suspicious for follicular neoplasm in all three groups. A total of 11 (13%) NIFTP cases (6 classified as atypical and 5 as follicular neoplasm/suspicious for follicular neoplasm) had available Afirma results, all of which were reported as suspicious for malignancy. 7 (8%) NIFTP cases were classified as malignant; cytomorphologic review revealed foci of clear cut papillary nuclear features in all 7 cases, including enlarged and angulated nuclei, overlapping, and intranuclear grooves and inclusions. However, papillary architecture was not observed in any cases.

**Conclusions:** All NIFTP cases in our series with Afirma results would be classified as suspicious for malignancy based on molecular features. A small but significant percentage of NIFTP were classified as malignant on cytology. Thyroid cytology specimens showing papillary nuclear features but no papillary architecture should be classified as Bethesda Category V (suspicious for malignancy). This may decrease the amount of unnecessary total thyroidectomies and associated sequelae.

Table 1. Bethesda Categories of NIFTP and FVPTC

	NIFTP	EFVPTC	Infiltrative FVPTC
II. Benign	11(13%)	5(17%)	3(12%)
III. Atypical/Follicular Lesion of Undetermined Significance	27(32%)	6(21%)	2(8%)
IV. Follicular Neoplasm/Suspicious For Follicular Neoplasm	30(35%)	7(24%)	9(36%)
V. Suspicious for Malignancy	10(12%)	6(21%)	5(20%)
VI. Malignant	7(8%)	5(17%)	6(24%)
Total	85	29	25

#### 448 Is Reporting of Normal Endometrial Cells in Women Greater Than 45 Years on Papanicolaou Test Necessary?

*Shenon Sethi, Christine Rucpich, Ji-Weon Park.* Rush University Medical Center, Chicago, IL.

**Background:** The newest Bethesda System 2014 raised the age threshold of reporting endometrial cells from 40 years to 45 years due to the low positive predictive value of benign endometrial cells on cervical Papanicolaou (Pap) test for endometrial malignancy. The reporting of endometrial cells is meant for postmenopausal women so they may undergo histological assessment of the endometrium to rule out an endometrial pathology. The purpose of this study was to evaluate the impact of the revised recommendation on the clinical outcome in terms of management and histological correlation.

**Design:** A retrospective review of endometrial cells reported on cervical Pap tests in women  $\geq 45$  years of age from July 2015 to July 2016 and women  $\geq 40$  years of age from July 2014 to June 2015 was performed. Clinical and pathological data, such as age and histological diagnosis on follow up, were recorded and compared in the two groups.

**Results:** There were 36 cases of endometrial cells in women  $\geq 45$  years of age (E45) (age range: 45-65 years) and 86 cases of endometrial cells in women  $\geq 40$  years (E40) (age range: 40-89 years). Only 10 E45 cases (28%) had a subsequent endometrial biopsy. Out of these 10 cases, 2 had complex hyperplasia without atypia, one had

simple hyperplasia without atypia, one had an endometrial polyp, and 5 (50%) had no endometrial pathology. Of the 86 cases of E40, 21 patients (24%) had an endometrial biopsy, 2 had simple hyperplasia without atypia, 3 had endometrial polyp, one had concurrent endometrial polyp and complex hyperplasia without atypia, and 13 (62%) had no endometrial pathology.

**Conclusions:** Our data indicates little significance of reporting normal endometrial cells on cervical Pap test, despite the raise in age threshold to 45 years, as majority of these women had no endometrial pathology (50% of E45 and 62% of E40). There was no considerable difference in the clinical management as only a minority of these women underwent endometrial biopsy (28% of E45 vs 24% of E40). None of such women had complex atypical hyperplasia or endometrial carcinoma. These findings suggest that reporting of benign-appearing endometrial cells is not necessary in cervical/vaginal Pap test.

#### 449 Impact of New Nomenclature “Non-Invasive Follicular Neoplasm with Papillary Like Nuclear Features” on the Bethesda System for Reporting Thyroid Cytopathology (TBSRTC). An Institutional Experience

*Maryam Shahi, Hira Yousaf, Khalid Amin, Faqian Li.* University of Minnesota, Minneapolis, MN.

**Background:** The highly indolent nature of encapsulated follicular variant of papillary thyroid carcinoma compared to conventional papillary thyroid carcinoma has led to a recent nomenclature revision of this category to Non-Invasive Follicular Neoplasm with Papillary like nuclear features (NIFTP). Exclusion of this category from malignant group may necessitate the modification of various diagnostic categories of TBSRTC.

**Design:** The cytologic diagnosis based on TBSRTC of all thyroid FNA cases performed during mid 2010-mid 2015 were retrieved along with histologic material of cases that underwent subsequent resection. These cases are reviewed and reclassified based on the diagnostic criteria of NIFTP. The difference in rate of malignancy for each TBSRTC category was calculated.

**Results:** Of the 2613 thyroid FNA cases in our cohort, 486 had corresponding surgical resections. All these cases were reviewed and reclassified considering NIFTP diagnostic criteria. Based on this review, 33 cases that qualified for NIFTP, were originally diagnosed as follow: follicular adenoma: 7 (21.2%), nodular hyperplasia: 2 (6%), Lymphocytic thyroiditis: 1 (3%), Follicular variant of Papillary thyroid carcinoma: 23 (69.7%). Cytologic diagnosis of these cases were as follow: Benign: 7 (21.2%); Atypia of Uncertain Significance (AUS): 15 (45.45%); Suspicious for Follicular Neoplasm (SFN): 6 (18.2%); Suspicious for malignancy (SUSP): 4 (12.1%); Positive for malignancy (Pos): 1 (3.0%). Based on original review of surgical resections, the rate of malignancy for each TBSRTC category were as follow: Non-Diagnostic: 5.0%; Benign: 9.6%; AUS: 33.9%; SFN: 28.2%; Susp: 84.1%; Pos: 93.9%. With reclassification, the rate of malignancy for each TBSRTC category changed as follow: Benign: 7.95%; AUS: 23.8%; SFN: 20.5%; Susp: 75%; Pos: 92.8%. The overall rate of malignancy for all the 486 FNAs with surgical resection was 40.5%, which dropped to 33.7% after reclassification. The overall rate of malignancy for all TBSRTC categories decreased by 16.8% (Benign, 17.9%; AUS, 29.8%; SFN 25.4%; Susp 10.8%; and Pos 1.2%) after excluding NIFTP from the malignant category.

**Conclusions:** Our results show that emergence of NIFTP entity in vocabulary of thyroid pathology significantly impacts the rate of malignancy based on TBSRTC with AUS, SFN and Susp categories having most changes. This calls for possible revision in the TBSRTC to accommodate the impact of this new entity.

#### 450 Correlation of Cytomorphologic Features and Mutational Profile of Thyroid Nodules with Indeterminate Cytologic Diagnosis

*Maryam Shahi, Rupendra Shrestha, Rachel I Vogel, Maria Evasovich, Lynn A Burmeister, Khalid Amin.* University of Minnesota, Minneapolis, MN.

**Background:** A number of molecular diagnostics have emerged in recent years aimed at streamlining the management of thyroid nodules with indeterminate cytologic diagnosis. This has provided an opportunity to further refine the cytomorphologic criteria by correlating with molecular profile of indeterminate cases which can be helpful in developing an institutional threshold, potentially decreasing the number of indeterminate thyroid diagnoses.

**Design:** All thyroid fine needle aspirations (FNAs) performed between 2013-2015 with indeterminate diagnosis (atypia of undetermined significance, suspicious for follicular lesion, and suspicious for malignancy) that were submitted to an outside academic institution for targeted mutation detection by PCR or by next generation sequencing were selected. Two pathologists blinded from the mutational status or surgical resection diagnosis, reevaluated various cytomorphologic features semi-quantitatively (cellularity, Hurthle cell changes, microfollicle, nuclear atypia and colloid). Each case was also assigned an overall atypia score on an ascending scale of 1-4. The correlation of mutational status with each aforementioned parameters and atypia scores were determined by multivariate logistic regression.

**Results:** Of the 1172 thyroid FNAs performed, 250 cases had an indeterminate diagnosis. 228 of these aspirates were submitted for molecular studies. 39 had indeterminate molecular results due to lack of material leaving a total of 189 FNAs for review. RAS mutations were found in 32 cases and BRAF found 12 cases. Both BRAF and RAS mutations showed a strong correlation with higher atypia score ( $P < 0.0001$  and  $p < 0.003$  respectively). Additionally, RAS mutational status was found to have a statistically significant association with the overall cellularity and microfollicle scores ( $p < 0.002$ ,  $p < 0.01$ , respectively).

**Conclusions:** Based on these results we conclude that indeterminate thyroid cytology cases with higher degree of cytologic atypia and presence of microfollicles have significantly greater incidence BRAF and RAS mutations. Further refining the cytomorphologic criteria by utilizing a scoring system can potentially decrease the number of cases that receive an indeterminate diagnosis.



#### 451 Cytologic Processing of Microbiopsies Is Associated with Higher Sensitivity for Detection of Urothelial Carcinoma Compared to Surgical Processing

Todd B Sheridan, Jennifer Yates, Christopher L Owens, Bruce A Woda, Andrew Fischer. University of Massachusetts Medical School, Worcester, MA.

**Background:** Due to high rates of non-diagnostic or insufficient ureteral piranha microbiopsies, we proposed to process these by cytology, with a combination Cellient™ cell block and a ThinPrep™.

**Design:** Two cohorts included 44 consecutive piranha microbiopsies processed from formalin as a standard surgical biopsy, and 22 microbiopsies processed by cytology. All samples were from the ureter or renal pelvis/calix. Cytology samples were collected in alcohol-based media to enable monolayer preparations, visible particles were pipetted directly to a Cellient cellblock cassette, and residual cell suspensions were prepared as a ThinPrep slide.

**Results:** Of 22 biopsies processed cytologically, definitive high grade UC (HGUC) diagnoses were made in 17 (77%) including one case with invasion shown in the cell block and supported with keratin IHC, benign diagnoses in 2 (9%), 2 (9%) non-diagnostic, and 1 suspicious for low-grade papillary UC (LGUC). 44 biopsies processed by surgical pathology had 8 (18%) malignant diagnoses (6 HGUC and 2 LGUC), 20 benign (45%), 8 non-diagnostic (18%), 6 suspicious (14%), and 2 atypical cases (5%). The difference in the rate of malignant diagnoses was highly significant ( $p=0.004$ ). FISH testing later confirmed two positive cytologic diagnoses, supporting that false positives did not account for increased cancer detection. To rule out selection bias, we identified 19 site-matched biopsies from 2 patients in which both cytologic and surgical processing were performed within 12 months of each other. Cytology biopsies showed 8/8 malignant diagnoses, whereas 1/11 surgical biopsies were diagnosed as malignant, 2/11 were suspicious, and 8/11 were benign. Increased sensitivity may relate to increased cell recovery: There was a trend toward increased urothelium (defined as >200 cells per profile) in cellblocks compared to histologic biopsies (25/44 = 57%, 15/22 = 68%), but not statistically significant. Large numbers of well-preserved urothelial cells were identified in the ThinPrep (average = 21,500 cells/slide).

**Conclusions:** Cytologic processing of ureteral microbiopsies appears to have superior sensitivity for detection of HGUC, likely due to increased numbers of recovered cells. These results may have general validity for using smaller biopsies, and a planned clinical trial will compare sensitivity of cytologically processed bladder microbiopsies to conventionally processed large size bladder biopsies for detecting HGUC.

#### 452 Best Practice: High Risk HPV Test Alone or in Combination with Cervicovaginal Pap Test for Cervical Cancer Screening

Anwer Siddiqi, Rohit Sharma, Sania Shuja. University of Florida, Jacksonville, Jacksonville, FL; University of Washington, Seattle, WA.

**Background:** Current cervical cancer screening is based on detection of cervical intraepithelial neoplasia (CIN) by Cervico-Vaginal Pap Test (CVPT) combined with High-Risk Human Papilloma Virus (HR-HPV) test. The increased sensitivity of HR-HPV test (>85%) over CVPT (~53%) has led some groups to propose HR-HPV test as an effective screening measure for (CIN) without CVPT. Our data analyzes potential impact on management of North Florida (NF) women, if both CVPT and HR-HPV test are performed vs HR-HPV test alone.

**Design:** We retrospectively analyzed our database of NF women who underwent CVPT and HR-HPV test between 2006 and 2014, by sorting them into 3 ethnic and 3 age groups. **Results:** 16,003 study patients included 8,612 African Americans (AA), 5,529 European Americans (EA), and 1,862 All Other Ethnic Groups (AOEG), the prevalence of HR-HPV in CVPT category Negative was 19%, 15.5% and 13.5% respectively. However, in CVPT category HSIL the prevalence of HR-HPV was dramatically increased to 91.2%, 90% and 100% respectively. When the same 16,003 NF women were sorted into 3 age groups; 14 to <20, 20 to <30 and 30 to <70 years, the prevalence of HR-HPV in CVPT category Negative was 53.5%, 27.5% and 13%, in 934, 4,551 and 10,518 patients respectively. However, in CVPT category HSIL the prevalence was dramatically increased to 100%, 87.2% and 92.6% respectively. In ethnic groups AA and AOEG, and age groups 14 to <20 years and 20 to <30 years, the greatest increase in prevalence of HR-HPV was between CVPT categories Negative and ASC-US. In ethnic group EA it was between ASC-US and ASC-H, and in age group 30 to <70 years it was between LSIL and HSIL.

**Conclusions:** Our data reveals that if HR-HPV testing is used as the sole screening test for management of patients in our 3 ethnic groups, then patients in CVPT category Negative who test HR-HPV positive, e.g. 19% of AA, 15.5% of EA and 13.5% of AOEG patients will be over-treated. Similarly, CVPT Negative, but HR-HPV positive patients among our 3 age groups will potentially be over treated by 53.5%, 27.5% and 13% in age groups 14 to <20 years, 20 to <30 years and 30-<70 years respectively. In addition, a proportion of patients in each of the CVPT categories ASC-US, ASC-H, LSIL and HSIL, who test HR-HPV Negative irrespective of ethnic or age group will be potentially under-treated. Thus, combined CVPT and HR-HPV testing appears to be the most effective way of screening for CIN.

#### 453 The Use of a Tissue-Saving Multiplex Antibody (ADH5) with TTF-1 to Subtype Non-Small Cell Lung Cancer on Cytology Specimens

Jordan Sim, Shahid Islam. The Ottawa Hospital, Ottawa, ON, Canada.

**Background:** 70% of lung cancers present at an advanced stage, and subtyping of non-small cell lung cancers must therefore be done on cytologic specimens and small biopsies when possible. Many antibodies have been investigated for the subtyping of non-small cell lung carcinomas. Although the combination of p40 and TTF-1 is commonly used, this is not always sufficient and more markers must be used. Entering the era of personalized medicine, conservation of cell blocks for molecular studies is

vital, and minimizing the number of immunohistochemical stains is important. The multiplex antibody ADH5 is frequently used in breast pathology, but to date has not been investigated for its use in lung cancer. ADH5 includes a panel of antibodies (CK5/14, CK7/18 and p63) all of which have been proven to aid in the subtyping of non-small cell lung carcinomas. The aim of this study is to assess the efficacy of the ADH5 multiplex antibody in combination with TTF-1 in subtyping non-small cell carcinomas.

**Design:** A database search from January 2014 onwards was conducted for cases of cytologically diagnosed non-small cell lung cancer with subsequent surgical resection specimens. A total of 175 consecutive cases were retrieved, 83 of which had adequate cell blocks fixed in formalin. Immunohistochemistry for TTF-1 and ADH5 was performed on all 83 cases.

**Results:** Of the 83 cases used in this study, final diagnoses on surgical resection included squamous cell carcinoma (25.3%), adenocarcinoma (71.1%) and adenosquamous carcinoma (3.6%). On cytology, 17 (20.5%) cases could not be subtyped. At the time of original cytologic diagnosis, immunohistochemistry was used to subclassify NSCLC in 32 (38.6%) cases. The number of stains performed ranged from 2 to 5 (mean 3.38). With the use of immunohistochemistry, 9 (11%) remained not subtyped. Using the combination of TTF-1 and ADH5 multiplex antibody, 80/83 (96%) cases were classified accurately, including 17 cases that were previously not subtyped and 1 case that was misdiagnosed. 3 (3.6%) cases of adenosquamous carcinoma could not be accurately subtyped using this panel.

**Conclusions:** A multiplex antibody for CK5/14, CK7/18 and p63 in combination with TTF-1 is an effective combination for subtyping NSCLC on cytology specimens. This combination requires only 2 sections, therefore saving tissue for further ancillary studies.

#### 454 Preoperative Fine Needle Aspiration (FNA) Diagnosis of Non-Invasive Follicular Thyroid Neoplasm with Papillary-Like Nuclear Features (NIFTP) and Invasive Follicular Variant Papillary Thyroid Carcinoma (IFVPTC): The Experience in a Large Academic Center

Jamie Slade, John Sir Philip, Julia Samolczyk, Ritu Nayyar, Haijun Zhou. Northwestern University, Chicago, IL.

**Background:** NIFTP was recently reclassified as a distinct histopathology entity, separating it from IFVPTC and PTC with mixed classic and FV features. Implementation of this terminology will change the management of this non-invasive entity from its invasive counterpart however, preoperative diagnoses of these two entities as benign or malignant is unlikely to be made on preoperative FNA. Our objective was to review the preoperative FNA diagnosis of IFVPTC and NIFTP at our institution to identify any significant difference in the cytologic categories preceding NIFTP and IFVPTC.

**Design:** Thyroid FNA cases with corresponding histologic resection follow up from January 2013 to December 2015 were retrospectively reviewed. NIFTP cases were identified according to the published criteria.

**Results:** Among 334 surgically resected PTC cases with preceding in house FNA cytology, 18 cases were classified as IFVPTC and 10 as NIFTP. For the 18 IFVPTC cases, 12 (66.7%) were categorized as PTC/malignant, one (5.6%) as suspicious for PTC, 4 as follicular neoplasm (FN) and 5 as atypia of undetermined significance (AUS) on preoperative FNA. For the 10 NIFTP cases, only one case (10%) was diagnosed as PTC on FNA, 4 as FN and 5 as AUS. None of the FNA biopsies preceding IFVPTC and NIFTP cases were classified in the benign/negative Bethesda cytologic category.

**Conclusions:** The low rate of NIFTP only minimally affects the rate of malignancy (ROM) for each TBSRTC category in our institution. Preoperative FNA triaged the majority of IFVPTC cases (72.2%) and only one NIFTP case (10%) into suspicious or malignant FNA categories ( $P=0.004$ ). With appropriate recognition of cytomorphic features of IFVPTC, both IFVPTC and NIFTP can be potentially triaged appropriately by preoperative FNA biopsy.

#### 455 Utility of BRAF V600E Immunoperoxidase Stain in Cytology Preparations of Cell Block and Aspirate Smears in Thyroid Cancers

Amber L Smith, Michelle D Williams, Maria E Cabanillas, John Stewart, Wei-Lien Wang, Savitri Krishnamurthy, Sinchita Roy-Chowdhuri. MD Anderson Cancer Center, Houston, TX.

**Background:** BRAF V600E mutation is common in thyroid cancers, predominantly in papillary thyroid carcinoma (PTC). Targeted therapy utilizing BRAF inhibitors is considered in advanced thyroid cancers based on the presence of the BRAF V600E mutation, either by mutational analysis or by immunoperoxidase (IPIX) staining. A fine needle aspiration (FNA) is the first choice for the diagnosis of thyroid nodules. In advanced patients, the ability to perform BRAF V600E on FNA of recurrent tumors facilitates triaging patients to treatment options. However, no studies have validated the BRAF V600E IPIX stain for molecular correlation in FNAs of known thyroid carcinoma.

**Design:** The pathology database was searched for thyroid carcinoma FNA specimens with available material from smears and cell block sections and prior BRAF mutational status by molecular testing. An anti-BRAF V600E (clone VE1, 1:50; Spring Bioscience) was used. Positive IPIX staining was cytoplasmic, and scored as positive (strong 2-3+), equivocal (1+), or negative (0). The results of the BRAF IPIX in cytology preparations were compared with the mutational analysis of the corresponding surgical pathology material and used to calculate the sensitivity and specificity. Cytology preparations with equivocal results were excluded from the statistical analysis.

**Results:** Twenty-three cases were included in our study. Cases consisted of: both smears and cell blocks (n=9), smears only (n=8), and cell block only (n=6). The tumors were: PTC (n=14), poorly differentiated carcinoma (n=6), and anaplastic thyroid carcinoma (n=3). Fourteen cases were metastasis. Three cases were recurrences in the thyroid bed. All 23 cases had BRAF mutational analysis by sequencing; 4 cases also had prior BRAF IPIX on surgical pathology material. 5 of 23 (21%) cases were equivocal or discordant. 1 of 14 (7.1%) cell blocks were equivocal with corresponding positive molecular

assessment, none were discordant; whereas, 2 of 20 (10%) smears were equivocal and 3 of 20 (15%) were discordant with positive IPOX on cytology and negative molecular evaluations. The overall sensitivity was 100% with a specificity of 70% (3 of 21 cases). **Conclusions:** BRAF IPOX staining can be performed reliably on cell block cytology preparations; however, false positive results by BRAF IPOX on smears limit their utility in thyroid for treatment related BRAF assessment. Thus, our study supports FNA assessment in recurrent thyroid carcinomas with cell block preparations specifically providing another tool for expedited molecular assessment of BRAF V600E.

#### 456 Fine Needle Aspiration Cytology of a Large Series of Anaplastic Thyroid Carcinoma

Amber L Smith, Beth S Edeiken-Monroe, Sinchita Roy-Chowdhuri, Savitri Krishnamurthy. MD Anderson Cancer Center, Houston, TX.

**Background:** Anaplastic thyroid carcinoma (ATC) is a highly aggressive malignant neoplasm notable for rapid progression and metastasis. The majorities of ATC patients are selected for neoadjuvant chemotherapy and targeted therapy. Fine needle aspiration (FNA) is commonly used for the diagnosis of this tumor. Recognition of the cytology of ATC is important for early diagnosis. The primary objective of our study included a detailed evaluation of the cytologic features of a large series of ATC to determine the key features which can be useful for the accurate diagnosis of these tumors.

**Design:** We searched our pathology files for all FNA cases of ATC with diagnostic material from 1995 until present. Demographic information including age, sex, site, tumor size, and radiologic findings were collected. The cases were independently reviewed for cytologic features including tumor cellularity, necrosis, inflammation, fibroconnective tissue, characteristics of tumor cells, nuclear/cytoplasmic ratio; nuclear features: nuclear shape, nuclear pleomorphism, prominent nucleoli, mitosis, intranuclear inclusions; cytoplasmic features, nature of cytoplasm (firm vs delicate), and for the presence of inclusions. The results of ancillary TTF1/PAX8 immunostaining performed in selected cases were also reviewed.

**Results:** We studied 35 cases including 19 primary tumors, 11 metastases, and 5 recurrences. Patients ranged in age from 44-79 years (mean 62 years), with a male to female ratio of 16:19, and mean primary tumor size of 5.6 cm. The most common radiologic finding of the primary thyroid tumor was a large mass involving the entire gland with infiltration and/or shifting of adjacent structures. Cytologic features most commonly exhibited by the tumors included high tumor cellularity (97%), nuclear pleomorphism (91%), single cells (74%), and plasmacytoid cells (49%). Immunostains which were performed during diagnosis were more commonly positive for PAX8 (6 of 7 cases stained) than TTF-1 (2 of 9 cases stained).

**Conclusions:** Recognition of the key cytologic features (high tumor cellularity, abundant single plasmacytoid cells with significant nuclear pleomorphism) in conjunction with the characteristic imaging findings can be useful for the distinction of ATC from other mimickers including metastatic and medullary thyroid carcinomas. Immunostaining for PAX8 may be useful to establish thyroid origin.

#### 457 NY-ESO-1 Expression Is Highly Sensitive and Specific in the Diagnosis of Myxoid Liposarcoma Using Cytology Cell Blocks

Stephen M Smith, Ming Jin, Paul E Wakely, O Hans Iwenofu. The Ohio State University, Columbus, OH.

**Background:** The diagnosis of myxoid liposarcomas (MLPS) is dependent on classic histomorphology and/or identification of t(12;16)(q13;p11) translocation by conventional cytogenetics or *DDIT3* gene rearrangements by fluorescence in situ hybridization. The differential diagnosis of myxoid soft tissue lesions is broad with differing implications for prognosis and therapeutics. Until recently, there was no diagnostic immunohistochemical (IHC) marker for MLPS.

NY-ESO-1 is the most immunogenic of all cancer-testis antigens, inducing both cellular and humoral immunity. Immunotherapy has shown promise in clinical trials involving NY-ESO-1-expressing tumors. Recent studies have shown NY-ESO-1 to be highly specific and sensitive for MLPS. The utility of NY-ESO-1 in fine needle aspirations (FNA) as a diagnostic tool is unknown. Prompted by previous findings in surgical resected specimens, this study explores the utility of NY-ESO-1 in the diagnosis of MLPS amongst myxoid neoplasms from specimens derived from cytology cell block materials.

**Design:** Formalin-fixed paraffin embedded cell blocks from 70 myxoid soft tissue tumors were selected, including: MLPS (n=10), extraskeletal myxoid chondrosarcoma (n=9), myxofibrosarcoma (n=25), myxoma (n=9), synovial sarcoma (n=2), undifferentiated pleomorphic sarcoma (n=7), other benign tumors NOS (n=3), other malignant tumors NOS (n=4), other liposarcoma (n=1). Using standard IHC protocols, sections were stained with anti-NY-ESO-1 (clone E978; Santa Cruz Biotechnology). Tissues were assessed for intensity (0-3+), percentage of expression and cellular localization.

**Results:** 9/10 cases of MLPS (all molecularly confirmed) demonstrated positive staining for NY-ESO-1. The majority of the positive cases (8/9, 88.9%) showed moderate to strong homogenous reactivity (>50% tumor positivity). 1 case showed weak staining (1+ intensity) with 10% tumor positivity. Staining distributions in MLPS were predominantly nuclear with minimal cytoplasmic staining. 3 cases of undifferentiated pleomorphic sarcoma and 1 case each of extraskeletal myxoid chondrosarcoma and synovial sarcoma tested positive; remaining non-MLPS cases were negative. The overall sensitivity and specificity is approximately 75% and 95%, respectively.

**Conclusions:** NY-ESO-1 is a highly sensitive and specific marker in MLPS with demonstrable utility in cytology cell block materials. This antibody in the appropriate context provides a cheap, fast and reliable assessment particularly in low resource settings and may be utilized as a diagnostic marker in advance of confirmatory molecular testing.

#### 458 Sharkcore Needles for Pancreatic EUS-FNAB - A Comparison of Cytologic and Histologic Preparations

Philippe Stephenson, Gary May, Christopher Teshima, Jeffrey D Mosko, Catherine Streulker. St-Michael's Hospital, Toronto, ON, Canada.

**Background:** Endoscopic ultrasound-guided fine needle aspiration/biopsy (EUS-FNAB) of the pancreas allows for relatively non-invasive sampling of pancreatic lesions. Sharkcore needles, with 6 cutting edges and an opposing bevel, are designed to sample intact cores by EUS-FNAB. Published experiences reported with Sharkcore needles are limited, but show excellent diagnostic yield. It is not known to what extent the histologic preparation, with intact architecture, facilitates diagnosis as compared to traditional cytologic preparations.

**Design:** All cases of EUS-FNAB with both cytologic and histologic preparations available were retrieved from a 3-month period after the introduction of Sharkcore needles at our institution. Specimens were obtained using only Sharkcore needles, with apportioning of material by the endoscopists into CytoLyt fluid, alcohol-fixed direct smears and formalin. The CytoLyt fluid was used to produce ThinPrep slides. The formalin-fixed tissue was used to produce H & E slides according to standard protocol. Three passes were performed for all cases. No on-site assessment was performed.

Cytologic and histologic material was reviewed separately and blindly. Cytologic material was reviewed by a cytopathologist and histologic material by a specialized gastrointestinal pathologist. Cases were evaluated for the presence or absence of evaluable tissue, and a review diagnosis was given. Diagnoses followed the Papanicolaou Society of Cytopathology classification for pancreatic cytology.

**Results:** Among the 26 cases reviewed, only benign pancreatic tissue was seen in 9, and insufficient well-preserved material was seen in 5. Only one case showed a discordance in terms of presence/absence of material, with diagnostic material present in the histologic preparation, but not the cytologic preparations, likely due to apportioning of material. Where diagnostic material was present in both types of preparations, there were no major differences in diagnosis upon review. The diagnoses included adenocarcinoma, metastatic renal cell carcinoma, pancreatic neuroendocrine tumour and cystic mucinous lesions. In one case, the histologic preparation was deemed suspicious for adenocarcinoma, and the cytologic preparation was considered diagnostic of adenocarcinoma. In cases requiring immunohistochemistry, the differential diagnosis included the ultimate diagnosis in all cases, with both preparations.

**Conclusions:** In cases with material in both cytologic and histologic preparations, no major difference in diagnosis was seen in this series.

#### 459 Comparing the Histologic Follow-Up Results for Women with Negative Cytology and High Risk HPV Positive Pap Smears Using the Hybrid Capture II, Cervista and Aptima hrHPV Assays in a Large Academic Women's Hospital

Michelle Stram, Jansen Seheult, Dinesh Pradhan, Chengquan Zhao. UPMC Magee Women's Hospital, Pittsburgh, PA.

**Background:** In 2011, the FDA approved the Aptima HPV assay as an adjunctive screening method to cytology to identify high risk HPV (hrHPV) in women over 30. Unlike the prior HPV assays Hybrid Capture II (HC2) and Cervista which detect hrHPV DNA, the Aptima HPV Assay detects mRNA of active virus. Data evaluating histologic follow-up results for women with negative cytology and a concomitant hrHPV result using the different FDA approved methods remain limited.

**Design:** A database search at a large women's hospital was used to retrieve ThinPrep Pap tests with negative cytology and positive HPV results using HC2 (5/12-5/13), Cervista (5/13-4/15) and Aptima (4/15-8/16) assays. Histologic follow-up, genotyping and demographic data were analyzed.

**Results:** A total of 2711 hrHPV positive cases with negative cytology were identified; 495 had histologic follow-up with a median time to biopsy of 42 days (IQR 27-68 days). The median age at biopsy was 42 years. Of the 252 HC2, 1820 Cervista, and 515 Aptima hrHPV positive cases, 77%, 94%, and 89% underwent genotyping, respectively. Of patients with hrHPV positive cytology negative Pap smears who underwent biopsy, 10 HC2, 17 Cervista, and 8 Aptima Assays did not have genotyping performed. The rate of follow-up surgical diagnosis of CIN I or higher for the three assays was 26.6% (HC2), 25.5% (Cervista) and 31.4% (Aptima).

HPV Genotype Result	Hybrid Capture II		Cervista		Aptima	
	Non-16/18	16 and/or 18	Non-16/18	16 and/or 18	Non-16/18/45	16 and/or 18/45
Total Cases	173	22	1508	312	372	88
Number with Biopsy	39	11	149	183	44	34
Median Age (Range)	51 (34-79)	51 (35-64)	51 (27-74)	53 (29-79)	43.5 (30-72)	38.5 (26-64)
CIN2/3	0	0	0	7	1	2
CIN1	5	11	25	51	10	11
Suggestive of CIN1	4	6	34	49	11	7
Negative	29	3	88	72	22	13
Median Days to Biopsy (Interquartile Range)	35 (24-67)	35 (28-48)	40(25-76)	44 (28-63)	40 (25.5-61)	44 (35-71)

**Conclusions:** This is one of the largest studies to compare the histological follow-up results for different methods of hrHPV detection for women with negative cytology. The Aptima HPV Assay had a marginally higher sensitivity for detecting CIN within a two year follow-up. Further experience with the Aptima HPV Assay and analysis of an increased sample number will determine if this difference is statistically significant.

**460 High Grade Intraepithelial Lesion on High-Risk HPV Negative Patients: Why We Still Need the Pap Test!**

Hongxia Sun, Ramya Masand, Shobhanaben J Patel, Vijayalakshmi Padmanabhan. Baylor College of Medicine, Houston, TX.

**Background:** Cervical dysplasia and carcinoma are caused by subtypes of high-risk HPV (hrHPV). Historically, they have been detected by the Pap test (PT). Recently, there is data suggesting that hrHPV testing can replace PT for screening. This study was performed to determine the rate of high grade intraepithelial lesion (HSIL) in hrHPV negative patients in a high-risk population, and correlate with subsequent biopsy/LEEP results.

**Design:** Two hundred and thirty patients with HSIL PT and hrHPV testing including genotyping, detected with the FDA approved platform Aptima®, were identified within one-and-a-half year period. Histologic correlation was available in 175 patients. Patient age distribution, and frequency of HSIL (CIN2/3) and invasive squamous cell carcinoma on histology were compared between hrHPV positive and hrHPV negative groups. In addition, the hrHPV genotypes were also evaluated.

**Results:** Two hundred and ten of the 230 (91.3%) patients with HSIL Pap test were hrHPV positive, and twenty patients (8.7%) were hrHPV negative. See table 1 for histology correlation results and hrHPV subtypes.

		Age (years)	Number of patients (%)	p value
HrHPV status	Positive	40.7 (21-81)	210 (91.3)	0.0015
	Negative	49.3 (23-74)	20 (8.7)	
Histology with CIN2/3 or carcinoma	hrHPV positive (161)	40.4 (21-81)	135 (83.9)	
	hrHPV negative (14)	51.3 (30-62)	7 (50)	
HrHPV subtypes	HPV16	38.9 (21-69)	84 (40)	
	HPV18/45	40.5 (26-56)	20 (9.5)	
	HPV16/18/45	52.7 (46-61)	3 (1.4)	
	non-HPV16/18/45	41.9 (23-81)	103 (49.1)	

**Conclusions:** Our studied population has higher rate (8.7%) of hrHPV negative HSIL compared with that reported in the literature (5%). HrHPV negative HSIL was more common in older women compared to hrHPV positive HSIL among whom, the uncommon hrHPV genotypes (non-HPV16 nor HPV18/45) accounted for the largest portion. Although the risk of dysplasia/ carcinoma is higher in hrHPV positive patients, the rate of hrHPV negative dysplastic lesions cannot be ignored. Seven of 14 (50%) of these women had high grade dysplasia/ carcinoma which would have otherwise been missed without the PT.

**461 A Comparative Study on the Diagnostic Value of Next Generation Sequencing in Urine Cytology and Bladder Tumor Specimens**

Tong Sun, Lloyd Hutchinson, Keith Tomaszewicz, Kathleen McCauley, Mandi-Lee Caporelli, Ediz F Cosar, Kristine Cornejo. University of Massachusetts Medical School, Worcester, MA.

**Background:** Urine cytology is a widely adopted method used in both the diagnosis and surveillance of patients with urothelial carcinoma (UC). Reactive urothelial cells may cytologically mimic low-grade (LG) UC, resulting in false positive or negative results. The diagnostic accuracy may be improved using ancillary tools such as fluorescent in situ hybridization (FISH). We designed a study to assess the diagnostic utility of next generation sequencing (NGS) in detecting gene mutations in urine cytology specimens in comparison to the subsequent formalin-fixed paraffin embedded (FFPE) bladder tumor specimens.

**Design:** Eleven urine cytology specimens diagnosed as positive for malignancy and their subsequent bladder tumor biopsy specimens were included in the study. Eight cases were diagnosed as high grade (HG) UC and 3 cases as LG UC. NGS analysis of 50 cancer “hotspot” mutations using Ampliseq Cancer Hotspot Panel v2 was performed.

**Results:** Five cases identified the same mutation(s) in both the urine cytology and corresponding bladder tumor specimens consisting of FGFR3 (N=2), TP53 (N=2), PIK3CA (N=2) and PTEN (N=1) mutation, yielding 100% concordance. One case in which the urine specimen was negative for mutation, was found to harbor an HRAS mutation in the bladder tumor. Three cases failed due to poor DNA quality and 2 cases were not found to harbor any hotspot mutations in both the urine cytology and bladder tumor specimens.

Case #	Diagnosis	Urine Cytology	FFPE Bladder Tumor
1	HG UC	No mutation detected	HRAS (p.Q61KQ)
2	HG UC	FGFR3 (p.S249SC)	FGFR3 (p.S249SC)
3	HG UC	TP53 (c.560-1G>A), PIK3CA (p.C901FC)	TP53 (c.560-1G>A), PIK3CA (p.C901FC)
4	LG UC	FGFR3 (p.S249SC), PIK3CA (p.E542KE)	FGFR3 (p.S249SC), PIK3CA (p.E542KE)
5	HG UC	PTEN (p.R130QR)	PTEN (p.R130QR)
6	HG UC	TP53 (p.D281YD)	TP53 (p.D281YD)
7	HG UC	Fail	TP53 (c.994-1G>GA)
8	LG UC	Fail	FGFR3 (p.Y375YC)
9	HG UC	Fail	TP53 (p.A161AT)
10	LG UC	No mutation detected	No mutation detected
11	CIS	No mutation detected	No mutation detected

**Conclusions:** NGS may have diagnostic utility in identifying both LG and HG UC in urine cytology specimens by identifying gene mutations. The creation of a bladder

specific hotspot mutation panel may aid in developing a sensitive diagnostic test for UC in urine specimens which are easily obtainable, as well as a non-invasive surveillance method for patients with UC harboring known mutations.

**462 For Diagnosis of Liver Masses, Fine Needle Aspiration versus Needle Core Biopsy: Which is Better?**

Liye Suo, Ruby Chang, Vijayalakshmi Padmanabhan, Shilpa Jain. Baylor College of Medicine, Houston, TX; Ben Taub General Hospital, Houston, TX.

**Background:** Both fine needle aspiration (FNA) and needle core biopsy (NCB) are widely accepted methods for obtaining diagnostic material. There is variability in how different institutions use these techniques in assessing liver masses. NCB has replaced FNA in many institutions for the diagnosis of liver masses. At our institution, FNA is followed by concurrent NCB. The aim of this study is to compare the diagnostic accuracy and tissue quality between FNA and NCB; and create a cost-effective algorithm for evaluating liver masses.

**Design:** A database search was performed to detect all liver FNA cases and their corresponding NCB between January 2014 and August 2016. A retrospective chart review was performed to gather pertinent information including age, race, gender, clinical history, lesion characteristics including unifocal versus multifocal, numbers of FNA passes and the pathologic diagnosis.

**Results:** Seventy-seven FNA and 68 corresponding NCB were reviewed from 74 patients. Diagnoses in the 74 patients included 36 hepatocellular carcinomas (HCC), 29 metastatic malignancies (MET), 5 poorly differentiated carcinomas (PDC), 2 cholangiocarcinomas (CHO) and 2 benign lesions. The mean age, number of FNA passes, number of slides stained with Diff-Quick and Pap were similar among the above five groups. More immunohistochemical studies (p<0.05) were performed on NCB tissues than FNA tissues in HCC (mean no. 2.1 vs 0.8), MET (2.5 vs 0.5), and PDC groups (11.2 vs 0.2). False negative rate (FNR) of NCB was lower (p<0.05) than that of FNA in HCC group; and FNR of NCB was higher (P<0.05) than that of FNA in MET group (Table 1).

Table 1.

Group	No.	Age*	Male/Female	Multiple lesion/Single Lesion*	# of FNA passes*	FNR of FNA	FNR of NCB	IHC on cell block*	IHC on NCB*
HCC	36	56.7 (17-86)	21/15	18/18	3.0 (1-8)	4/37	1/33	0.8(0-9)	2.1(0-14)
MET	29	55.4(41-79)	9/20	20/9	3.8(2-8)	0/30	4/27	0.5(0-4)	2.5(0-14)
PDC	5	52(43-62)	4/1	4/1	4.4(2-7)	0/5	0/5	0.2(0-1)	11.2(5-16)
BEN	2	57(56-58)	1/1	0/2	3.0(2-4)	N/A	N/A	0	2(0-4)
CHO	2	58	2/0	0/2	4.0(2-6)	0/2	0/2	2(0-6)	0

Clinical information and diagnostic accuracy of FNA and NCB in 74 patients with liver masses from Jan. 2014 to Aug. 2016. (\* mean (minimum-maximum); IHC: immunohistochemical stains; FNR: false negative rate)

**Conclusions:** For HCC, NCB usually has better tissue quality and diagnostic accuracy than FNA; however, for metastatic lesions in the liver, FNA has better diagnostic accuracy than NCB, although NCB can provide more tissues for ancillary testing and has better diagnostic quality.

**463 Analysis of the Atypia of Undetermined Significance/Follicular Lesion of Undetermined Significant (AUS/FLUS) Category – Experience from a Large Health System**

Rachel Swarrow, Fan Lin, Haiyan Liu. Geisinger Medical Center, Danville, PA.

**Background:** The AUS/FLUS category for thyroid fine needle aspiration (FNA) specimens is an indeterminate diagnosis posing challenges to clinicians. There is only limited follow up reports. In this study, we reviewed and identified the AUS/FLUS cases with available follow-up. The aim of the study is to identify possible pitfalls for this diagnosis and thereby reduce the diagnostic rate for this category.

**Design:** Two-hundred-ninety-five cases of AUS/FLUS with follow-up dating from 2010 were identified from over 3000 consecutive thyroid FNA cases, including 232 cases with thyroidectomy and 63 cases with repeat FNA. Those were subcategorized into 1) atypical follicular cells (AFC, n=182); 2) follicular (Hürthle cell) lesions (FL, n=88); and 3) atypia, not otherwise specified (Atyp. NOS, n=25).

**Results:** The 232 cases with follow-up thyroidectomy are summarized in Table 1; the 63 cases with repeat FNA in Table 2. Overall, 28% (82/295) of cases were malignant on follow-up, the majority (73/82, 89%) being PTC, including 30 cases (41% of microcarcinoma (microPTC)). The AFC group represented 62% (182/295) of cases, and 67% (55/82) of the follow up malignancies. Among the benign follow-ups (n=213), nodular goiter (NG) and thyroiditis represented the majority, 47% and 23%, respectively.

Table 1. Correlation of 232 AUS/FLUS cases with follow-up thyroidectomy

Categories	NG	Thyroiditis	FA	FCA	PTC
AFC (N=133)	39 (29%)	28 (21%)	12 (9%)	4 (3%)	50 (38%)
FL (N=79)	20 (25%)	11 (14%)	20 (25%)	3 (4%)	15 (19%)
Atyp NOS (N=20)	3 (15%)	7 (35%)	1 (5%)	2 (10%)	7 (35%)
Total (N=232)	62 (27%)	46 (20%)	33 (14%)	9 (4%)	72 (31%)

FA: follicular adenoma; FCA: follicular carcinoma

Table 2. Correlation of 63 AUS/FLUS cases with repeat FNA

Categories	NG	Thyroiditis	FA	PTC	Atyp
AFC (N=49)	32 (65%)	4 (8%)	4 (8%)	1 (2%)	9 (18%)
FL (N=9)	4 (44%)	0 (0%)	2 (22%)	0 (0%)	3 (33%)
Atyp NOS (N=5)	3 (60%)	0 (0%)	1 (20%)	0 (0%)	1 (20%)
Total (N=63)	39 (62%)	4 (6%)	7 (11%)	1 (2%)	13 (21%)

Atyp: atypical, NOS

**Conclusions:** The reactive changes in NG or thyroiditis may contribute to the diagnosis of AUS/FLUS. Attention should be paid to the reactive nature and the presence of lymphocytes, which may be clues for a correct diagnosis and reduce the rate of AUS/FLUS. In addition, significant numbers of PTC (including 41% microPTC) were diagnosed as AFC, suggesting possible sampling error. Further molecular testing may be helpful to clarify the diagnoses.

**464 Do Liquid-Based Preparations of Thyroid Fine Needle Aspiration Specimens Perform Differently Than Conventional Preparations in the Diagnosis of Thyroid Lesions? Observations from the College of American Pathologists Nongynecologic Cytopathology Education (CAP NGC) Program**

Z Laura Tabatabai, Daniel Kurtycz, Ritu Nayyar, Rhona J Souers, Guliz Barkan, Paul Staats, Benjamin L Witt, Andrew H Fischer. University of California-San Francisco, San Francisco, CA; University of Wisconsin, Madison, WI; Northwestern University, Chicago, IL; College of American Pathologists, Northfield, IL; Loyola University, Maywood, IL; University of Maryland, Baltimore, MD; University of Utah, Salt Lake City, UT; University of Massachusetts, Worcester, MA.

**Background:** Since the advent of liquid based preparation (LBP), there has been much controversy regarding whether LBP or conventional preparations (CP) should be used in the diagnosis of thyroid lesions. This study was undertaken to compare performance characteristics of LBP and CP in the CAP NGC program.

**Design:** 34,469 responses based on 682 slides evaluated in years 2011-2015 were analyzed for concordance to the general category and the specific reference diagnosis using two nonlinear mixed models. Three general categories included Benign, Suspicious (Hürthle/follicular cell neoplasm (FN)), and Malignant. Specific reference diagnoses included benign thyroid nodule (BTN), thyroiditis, FN, and papillary thyroid carcinoma (PTC).

**Results:** For concordance to the general category, there were significant differences between LBP and CP. In the Benign category, LBP performed better than CP (92.0% vs. 87.5%, *P*-value .007) while CP showed better performance than LBP in the Suspicious (74.8% vs. 61.9%, *P*-value < .001) and Malignant (95.2% vs. 91.1%, *P*-value .008) categories. Overall, CP showed better performance than LBP (89.1% vs. 83.8%, *P*-value .04). For concordance to the specific reference diagnoses, there were no significant differences between LBP and CP for benign diagnoses (BTN, thyroiditis). CP showed significantly higher concordance compared to LBP for specific diagnoses of FN (75.0% vs. 61.7%, *P*-value < .001) and PTC (93.5% vs. 88.0%, *P*-value .002). The specific reference diagnoses were misdiagnosed as follows: BTN as follicular neoplasm in 2.0% LBP vs. 5.3% CP, FN as BTN in 18.0% LBP vs. 4.3% CP, and PTC as BTN in 6.2% LBP vs. 3.1% CP.

**Conclusions:** LBP performed worse than CP for cases with a Suspicious (FN) or Malignant (PTC) diagnosis. While participants specifically diagnosed BTN and thyroiditis equally well on LBP and CP, at the level of the general Benign category, LBP performed better than CP.

**465 Histopathologic Follow-up and HC2 HPV Results in 2092 Patients with HSIL Pap Test in the Largest Women Hospital in China**

Xiang Tao, Faye Gao, Xianrong Zhou, Li Wang, Long Sui, Chengquan Zhao. Obstetrics and Gynecology Hospital of Fudan University, Shanghai, China; Washington Hospital Center, Washington, DC, DC; Magee-Women's Hospital of UPMC, Pittsburgh, PA.

**Background:** Cervical cancer is one of the leading cancers for women in China. The data of HPV positive rate and histological follow-up finding for the women with HSIL Pap is very limited in China.

**Design:** The patients with HSIL Pap tests and HPV testing results (HC2, Cervista and Roche) were retrospectively identified from 2011 to 2015. Histological follow-up results within 6 months after HSIL Pap tests were analyzed.

**Results:** 4269 HSIL Paps (0.48%) were reported. 2092 HSIL cases (49%) also had HPV testing. Overall HPV positive rate was 89.2%, with 88.1%, 90.7%, and 93.9%, in HC2, Cervista, and Roche, respectively. HPV positive rates showed statistical difference among age groups, lowest in women <30 years (86.5%). Of 292 Roche HPV positive cases, HPV 16 and 18 accounted for 57.9%, and 2.7%, respectively. Of the 2092 with dual testing, 1449 cases including 1312 HPV positive cases and 127 negative cases had histologic follow-up within 6 months. HSIL+ lesions were seen in 84.4% HPV positive cases, and 31.5% HPV negative cases, including 10 invasive cervical cancers (7.9%).

**Table 1.** Histopathologic follow-up for women with HSIL cytology

Age	F-u case	SCC	CIN2/3	CIN1	ADC	AIS	Neg
HPV positive cases:							
<30	112	2 (1.8)	80 (71.4)	15 (13.4)	1 (0.9)	0 (0)	14 (12.5)
30-49	907	70 (7.7)	702 (77.4)	53 (5.8)	2 (0.2)	1 (0.1)	79 (8.7)
>=50	293	45 (15.4)	201 (68.6)	16 (5.5)	3 (1)	0 (0)	28 (9.6)
Total	1312	117 (8.9)	983 (74.9)	84 (6.4)	6 (0.5)	1 (0.1)	121 (9.2)
HPV negative cases:							
<30	15	1 (6.7)	4 (26.7)	1 (6.7)	0 (0)	0 (0)	9 (60)
30-49	86	5 (5.8)	20 (23.3)	8 (9.3)	1 (1.2)	1 (1.2)	51 (59.3)
>=50	26	3 (11.5)	5 (19.2)	3 (11.5)	0 (0)	0 (0)	15 (57.7)
Total	127	9 (7.1)	29 (22.8)	12 (9.5)	1 (0.8)	1 (0.8)	75 (59.1)

**Conclusions:** Recent years, studies emphasize the importance of HPV testing for cervical malignancy detection. Our study shows the correlation of HSIL+ histology with HPV positivity. However, our study also shows that about 31.5% HSIL+ histology are HSIL/HPV negative, indicating that HPV testing alone is not sufficient for cervical cancer screening. The combination of cytology and HPV testing is essential.

**466 Performance of ALK and EGFR Testing on Cytological Specimens**

Tatjana Terzic, Gilda dC Santos, Hyang-Mi Ko, Scott MacDonald, Dana Pabedinskas, Nazleen C Lobo, Scott L Boerner, Suzanne Kamel-Reid. Laboratory Medicine Program, University Health Network, Toronto, ON, Canada.

**Background:** With the era of personalized medicine, the finding of *ALK* and *EGFR* mutations in lung cancer has revolutionized therapy for the affected patients. As some of least invasive procedures, fluid collections, fine needle aspiration biopsies (FNAs), endobronchial ultrasound guided transbronchial aspiration (EBUS-TBNA) and endoscopic guided aspiration (EUS) have become the mainstay of diagnosis and hence the cytology specimens obtained are also utilized for molecular testing. This study aimed to examine how efficiently *ALK* and *EGFR* mutations could be detected in cytological specimens.

**Design:** An electronic search retrieved consecutive cases of lung adenocarcinoma from 2011 to 2015 that had *ALK* and *EGFR* testing performed on FNAs, brushings, fluids (washings, lavages, pleural and pericardial effusions), EBUS-TBNA and EUS. The results of *ALK* immunohistochemistry (IHC), *ALK* fluorescence in situ hybridization (FISH) studies as well as *EGFR* mutation analysis were collated and descriptively analysed. In our institution, *ALK* IHC is performed reflexively and *ALK* FISH is done only if the *ALK* IHC is positive or equivocal. Both in-house and referral cases were included in the study.

**Results:** A total of 945 specimens, 533 referrals and 412 in-house were found, with a spread over the years of 8 (2011), 63 (2012), 307 (2013), 412 (2014) and 155 (2015) cases. There were 465 male and 480 female patients with median age of 61.5 (range 27-96). The overall detection of *ALK* rearrangement was 2.22% by IHC and 2.54% by FISH (total of 43 performed). Positivity for an *EGFR* mutation was detected in 196 out of 945 cases (20.74%) with deletion in exon 19 in 107 cases and L858R substitution in exon 21 in 81. Comparison of the performance for EBUS-TBNA, FNAs and pleural fluids showed that EBUS-TBNA (213) had the highest detection rate for *ALK* by FISH (2.82%) and both FNAs (336) and pleural fluids (320) had the highest rate for *EGFR* mutation (21.43% and 25% respectively). Overall, the pleural fluid had the best detection rate for both *ALK* rearrangement and *EGFR* mutations (*ALK* IHC 2.19%, *ALK* FISH 2.5%, *EGFR* 25%).

**Conclusions:** This largest series analyzing the performance rates for *ALK* and *EGFR* detection in cytological specimens confirms that those specimens can be utilized for molecular testing. Furthermore, there is an overall better detection rate for *EGFR* mutations in FNAs and pleural effusions and those specimens should be prioritized for molecular analysis.

**467 Alternative Lengthening of Telomeres and Loss of DAXX/ATRX Expression in Pancreatic Neuroendocrine Tumors from Endoscopic Ultrasound Guided Fine Needle Aspiration (EUS-FNA) Specimens Correlate with Poor Patient Survival**

Brian Theisen, Justin L Roncaioli, Roderick J O'Sullivan, Kevin McGrath, Randall E Brand, Herbert J Zeh, Jennifer S Chennat, Kenneth E Fasanella, Asif Khalid, Georgios I Papachristou, Adam Slivka, Marina N Nikiforova, Melissa Hogg, Aatur D Singh. University of Pittsburgh Medical Center, Pittsburgh, PA.

**Background:** Pancreatic neuroendocrine tumors (PanNETs) are often diagnosed on preoperative EUS-FNA specimens. However, these neoplasms are unpredictable in clinical behavior. Moreover, the application of current prognostic systems, such as WHO grade, for subsequent management decisions can be challenging due to limited material. Mutations in *DAXX* and *ATRX* are present in a subset of PanNETs and correlate with loss of corresponding protein expression and the presence of alternative lengthening of telomeres (ALT). Both *DAXX/ATRX* loss and ALT have been shown to be negatively associated with disease-free survival (DFS) and disease-specific survival (DSS). The aim of this study is to evaluate whether *DAXX/ATRX* loss and ALT can be evaluated on cytology specimens and whether similar clinicopathologic trends exist.

**Design:** Eighty-two EUS-FNA specimens with a diagnosis of PanNET, confirmed by surgical resection, were identified between 2002 and 2014. The presence of tumor cells within the cell block was also confirmed by H&E and immunohistochemistry (IHC) for neuroendocrine markers. Both *DAXX* and *ATRX* IHC, and telomere-specific fluorescence *in situ* hybridization were performed on tissue sections and corresponding surgical resection material. The results were correlated with other clinicopathologic findings including follow-up.

**Results:** The prevalence of ALT and loss of *DAXX/ATRX* expression in PanNET EUS-FNA specimens was 33% and 24%, respectively, and *DAXX/ATRX* loss was associated with ALT (*p* < 0.01). Overall correlation of *DAXX*, *ATRX* and ALT status between cytology and resection specimens was 98%, 100% and 98%, respectively. Discordant cases were seen in the setting of heterogeneous expression of *DAXX/ATRX*. ALT and *DAXX/ATRX* loss were associated with EUS size >2.0 cm, higher WHO grade, and the presence of synchronous and metachronous distant metastases (*p* < 0.01). Further, patients with ALT and *DAXX/ATRX* loss had shorter DFS and DSS (*p* < 0.02). By multivariate analysis, ALT and *DAXX/ATRX* loss in cytology specimens were negative, independent prognostic factors for DFS (*p* < 0.01), but not DSS (*p* > 0.05).

**Conclusions:** Although further studies are required, the identification of ALT and loss of *DAXX/ATRX* expression in PanNETs from EUS-FNA specimens may indicate an increased risk of developing metastatic disease, and, in turn, may affect future management decisions.

**468 Implementation of the Paris System for Reporting Urinary Cytology: A Single Institution's Experience**

*Vanda Torous, Dawn Brancely, Paul VanderLaan.* Beth Israel Deaconess Medical Center, Boston, MA.

**Background:** Urine cytology is a proven quick and minimally invasive modality for the diagnosis of urothelial carcinoma (UC). The recent introduction of the Paris System for Reporting Urinary Cytology (PSRUC) for the first time provided a standardized reporting schema for the evaluation of urine cytology with set cytologic criteria for each diagnostic category. An overriding principle in PSRUC is that urine cytology is intended to detect high-grade (HG) UC and diagnostic categories should reflect the risk of HGUC. Our institution adopted PSRUC in February 2016, and we herein report its impact on the frequency and distribution of urine cytology diagnoses compared to a period before PSRUC was introduced.

**Design:** As part of ongoing laboratory quality assurance measures, the cytology database of a large tertiary care medical center was queried for all urine cytology specimens evaluated during a 5 month period prior to the introduction of PSRUC (March-July 2015) as well as after its introduction (March-July 2016). There were 1387 urine cytology specimens from the pre-PSRUC period and 1384 from the post-PSRUC period. The cases were sub-classified according to specimen type (voided, catheterized, cystoscope, instrumented, renal/pelvic washing, and urine-NOS).

**Results:** In the pre-PSRUC period, 855 urine cytology specimens were diagnosed as negative for malignancy (61.6%), 435 atypical (31.4%), 58 suspicious for malignancy (4.2%), and 39 malignant cells present (2.8%). In the post-PSRUC period, 979 were called negative for HGUC (70.7%), 302 atypical urothelial cells (21.8%), 61 suspicious for HGUC (4.4%), and 42 HGUC (3.0%). The atypical call rate was significantly lower in the post- vs pre-PSRUC period ( $p < 0.001$ ). The decrease in atypical diagnoses was observed across all specimen types (33.8 vs 23.1% for voided, 25.0 vs 14.3% catheterized, 40.4 vs 23.9% cystoscope, 38.7 vs 27.3% instrumented, 50.0 vs 16.7% washings, and 26.0 vs 20.3% for urine NOS). Individual cytopathologist call rate was also examined and the atypical call rate range was lower post-PSRUC (range 10.2-30.8%) compared to pre-PSRUC (12.2-45.0%).

**Conclusions:** Adoption of the PSRUC diagnostic criteria and reporting scheme resulted in a significant decrease in the number of cases that were categorized as atypical with little change observed in the suspicious or malignant categories. Future studies will be needed to determine the effect of decreased atypical call rates on the sensitivity/specificity of urine cytopathology, as well as to see if other measures (such as cytopathologist feedback) can further reduce atypical call rates.

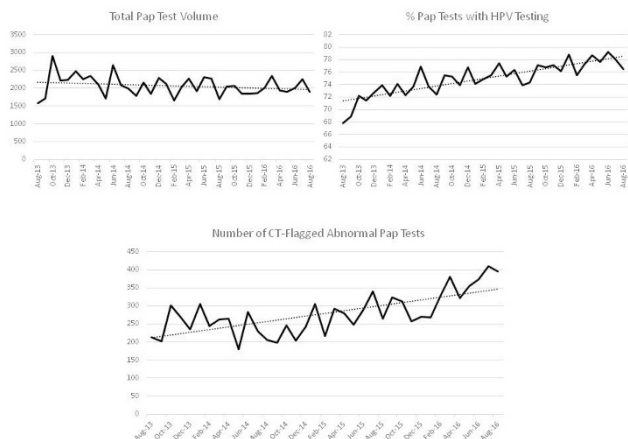
**469 Impact of High-Risk Human Papillomavirus Testing on Pap Test Screening Complexity**

*Vanda Torous, Dawn Brancely, Luis Carpio, Paul VanderLaan.* Beth Israel Deaconess Medical Center, Boston, MA.

**Background:** With the adoption of HPV co-testing for pap tests, lengthened screening intervals for low-risk women has led to decreasing pap test volumes for most cytology laboratories; however, it is not well documented how these changes have impacted the resulting pap test screening complexity and laboratory workflow.

**Design:** As part of ongoing laboratory QA measures, the cytology information system from a large tertiary care medical center was queried for all cervical pap tests from 8/2013 to 8/2016. Data extracted included the total number of pap tests evaluated ( $n=77,891$ ), the number of HPV tests performed, the frequency of abnormal cases flagged by a cytotechnologist (CT) requiring cytopathologist (CP) review, and the distribution of final diagnoses rendered.

**Results:** Over this time period, there was a decrease in monthly total pap test volume (averaging 2260/month in 2013 to 2010/month in 2016); however, the proportion of pap tests with HPV testing requested increased (monthly average 71.3% in 2013 to 77.8% in 2016). The decreasing pap test volume over time was mirrored by an increasing percentage of cases flagged as abnormal by the CT and passed along to the CP for review (monthly average of 11.2% in 2013 to 19.1% in 2016). As such, the monthly pap test volume workload for CPs increased from an average of 250/month in 2013 to 383/month in 2016.



**Conclusions:** HPV co-testing has resulted in overall lower pap test volume over time. This decrease is accounted for in the proportion of pap tests screened as negative by CTs, cases that are more quickly screened by CTs via computer-assisted screening with

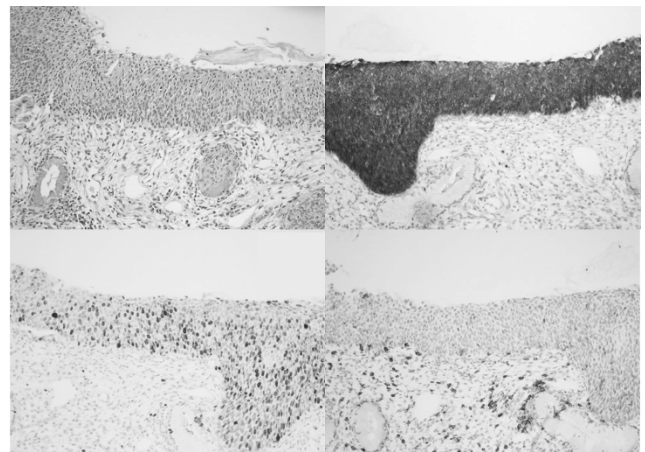
an automated microscope. With a higher proportion of abnormal paps, more time on a per-pap test basis is spent by the CT (who must manually screen the entire slide when an abnormality is identified in the initial imager-selected fields of view). This higher proportion of abnormal paps has a direct impact on CP workload. As such, it is important for cytology departments to consider more than just the total pap volume when making CT and CP staffing decisions. Over time, HPV co-testing appears to have altered the makeup of the tests received in laboratories, enriching for pap tests more likely to harbor an abnormality, requiring more labor intensive screening efforts by CTs and CPs.

**470 Comparison of Clinical, Histologic Features and Biomarkers of High Grade Cervical Intraepithelial Neoplasia (CIN3) False Negatives Missed by Either Human Papilloma Virus (HPV), Cytology or Both**

*Jessica Tracht, Isam-Eldin Eltoun.* University of Alabama at Birmingham, Birmingham, AL.

**Background:** Co-testing misses a small but significant number of squamous intraepithelial lesions, or false negative CIN3 (FN-CIN3). It is unknown if FN-CIN3 differ in biological or clinical behavior. Finding such differences may have implications regarding choice of primary screening method. This study compares clinical/histologic features and biomarker expression in CIN3 missed by HPV or cytology.

**Design:** FN-CIN3 were detected from 2010-2013 and classified as cytology-HPV+, cytology+HPV- or cytology-HPV-. Histology and cytology were reviewed and discrepancies classified as sampling or interpretation error. P16 was performed to confirm CIN3. Ki67 and CD4 stains (figure 1) were used as biomarkers of grade/progression/regression.



**Figure 1.** HR-HPV+/NILM CIN3 cervical biopsy A. On routine H&E stain B. Strong staining of p16 in the upper and lower portions of epithelium C. Ki-67 SI of 0.77 and D. CD4 highlighting cells in epithelium and stroma

NIH-Image J and Immunorator were used to extract Ki67 positive cell coordinates, basal and luminal edges; information was entered in Microsoft Excel to extract average and 90<sup>th</sup> centile stratification index, density of positive cells, total and percent positive cells in all epithelium and different thirds of epithelium. Data were analyzed using SPSS statistical program. Clinical and pathologic data were compared with Chi Square and Fisher exact tests. Biomarkers were compared using Kruskal-Wallis test.

**Results:** 15,173 women (25-95, 7.1% <30) had both HPV and cytological testing. 1184 (8.4%) had biopsies. 84 CIN3+ were detected with 11 Cyto+HPV+, 10 Cyto+HPV-, and 3 Cyto-HPV-. Of the 24 FN-CIN3 there was no significant difference in size, time to occurrence, presence of cytopathic effect, history of screening, race or age. On review, 6 of 11 (55%) discrepancies were classified as cytology interpreting error and 5/11 (45%) as sampling errors. P16 confirmed CIN3 in all but one case with insufficient tissue. Except for percent positive cells in the middle third all Ki67 indices were not statistically significant [table1].

**Conclusions:** Discordant co-testing results are problematic. As HPV only screening begins, understanding these lesions is essential. There are no significant clinical, pathologic, or biomarker differences between FN-CIN3. Discrepancies arise due to cytologic sampling or interpretation error not clinical parameters or indices of regression/progression.

**471 The Role of Repeat Endoscopic Ultrasound-Guided Fine Needle Aspiration for Suspected Pancreatic Malignancy**

*Ramona Untanu, Kamal K Khurana.* SUNY Upstate Medical University, Syracuse, NY.

**Background:** Endoscopic ultrasound-guided fine needle aspiration (EUS-FNA) has become an essential and safe tool in the diagnosis of pancreatic malignancy. The role of repeat EUS-FNA in patients with high clinical suspicion for pancreatic cancer after an unsuccessful initial attempt has not been well established. The goal of our study was to ascertain the additional yield and success of repeat EUS-FNA.

**Design:** We performed a retrospective review of our University center electronic database for pancreatic FNAs in patients with suspected pancreatic cancer from January 2009 to July 2016. All patients that had more than one pancreatic FNA procedure for evaluation of suspected neoplastic process were included in our study. Cytologic material was also reviewed to determine the cause of failed EUS-FNA.

**Results:** A total of 1115 patients underwent 1326 procedures. Repeat EUS-FNA was performed on 123 (11.03%) patients and included 299 (22.55%) repeat procedures. Initial FNA was reported as atypical/suspicious in 30 (24.4%) patients, benign in 81 (65.85 %) and nondiagnostic/insufficient in 12 (9.75%) patients. Repeat FNA revealed

a neoplastic process in 23 (18.7%) patients. Eight of 30 (26.66%) patients with atypical/suspicious cytology at the first FNA were diagnosed with adenocarcinoma on repeat FNA. Of the 81 patients with benign disease at the initial procedure, repeat diagnosis was adenocarcinoma in 10 (12.34%), atypical/suspicious in 7 (8.64%), insufficient in 8 (9.87%), hemangioma in 1 (1.23%), cystic mucinous neoplasm in 1 (1.23%), neuroendocrine tumor in 2 (2.46%) and the rest remained negative on follow up 52 (64.19%). Of the 12 initial nondiagnostic/insufficient samples, repeat FNA revealed benign findings in 9 (75%), adenocarcinoma in 1 (8.33%) and remained insufficient in 2 (16.66%). Reason for failed initial EUS was attributed to sampling error (n=15, 65.2%) and paucity of tumor cells precluding definitive diagnosis of neoplastic process (n=8, 34.8%).

**Conclusions:** Repeat EUS-FNA improves the yield of diagnosis in patients with continued suspicion of pancreatic cancer. Hence this procedure is warranted in such patients even if the initial EUS-FNA is benign or inconclusive.

#### 472 Ultrasonography-Guided Fine Needle Aspiration of Axillary Lymph Nodes for Identifying Metastatic Tumors and Monitoring Response to Neoadjuvant Chemotherapy in Patients with Breast Cancer

*Puneeta S Vasa, Abigail S Caudle, Wei Yang, Junsheng Ma, Roland Bassett, Henry M Kuerer, Savitri Krishnamurthy.* The University of Texas MD Anderson Cancer Center, Houston, TX.

**Background:** Breast cancer patients with limited metastatic tumor in axillary lymph nodes (ALNs) undergo ALN dissection following completion of neoadjuvant chemotherapy (NC). We evaluated the role of ultrasonography-guided fine needle aspiration (US-FNA) of ALNs for identifying and marking ALNs with metastatic tumors before initiation of NC, thereby facilitating the final evaluation of therapy response after completion of NC following surgery.

**Design:** We studied 230 breast cancer patients with limited disease burden in ALNs who underwent US-FNA. Immediate assessment of FNA allowed the radiologist to place a marker clip in the ALN with metastatic tumor. After completion of NC, patients underwent surgery, and the clipped ALN was removed separately and subjected to routine histopathological (HP) examination. The final HP status of the clipped and non-clipped ALNs was determined. We recorded tumor size, tumor type, and estrogen receptor (ER), progesterone receptor (PR) and human epidermal growth factor receptor (HER2) status and performed multivariate logistic regression analysis to determine possible predictors of response of the metastatic tumor in the clipped ALN. The sensitivity and specificity of the clipped ALN as a surrogate of the status of non-clipped ALNs was determined.

**Results:** Our patients had a mean age of 50 years (23–84 years). Primary invasive breast tumors were ductal in 214 patients (93.0%) and lobular in 9 patients (3.9%); tumor size was <2 cm in 140 patients (61.9%), 2–5 cm in 58 (25.7%), and >5 cm in 28 (12.4%); 4.8% of patients had grade 1 tumors, 39% had grade 2 tumors, and 56% had grade 3 tumors. Of the 230 patients, 168 were ER+, 62 were ER-, 127 were PR+, 101 were PR-, 56 were HER2+, and 174 were HER2-. Multivariate logistic regression analysis showed that tumor size (p=0.009) and PR status (p=0.003) were significant and HER2 status was marginally significant (p=0.103) for predicting response to NC in the clipped ALN. The sensitivity and specificity of the clipped ALN for predicting response in non-clipped ALNs were 94% and 65%, respectively.

**Conclusions:** In conclusion, immediate assessment of US-FNA of ALNs can help identify metastatic tumors and allow placement of a marker clip, which allows subsequent monitoring of response to NC. Tumor size and PR status were significant factors for predicting response of the metastatic tumor in the clipped ALN to NC. The clipped ALN was 94% sensitive and 65% specific as a surrogate to predict the status of non-clipped ALNs.

#### 473 High-Throughput Genome Analysis and Molecular Characterization Helps Differential Diagnosis Between Follicular Adenomas and Carcinomas: Results in a Cohort of 146 Patients

*Philippe Vielh, Zsofia Balogh, Catherine Richon, Guillaume Maurice, Bastien Job, Alexander Valent, Ludovic Lacroix, Virginie Marty, Nelly Motte, Philippe Dessen, Bernard Caillou, Abir Al Ghuzlan, Jean-Michel Bidart, Vladimir Lazar, Adel K El-Naggar, Martin Schlumberger.* National Laboratory of Health, Dudelange, Luxembourg; Gustave Roussy Cancer Campus, Villejuif, France; MD Anderson Cancer Center, Houston, TX.

**Background:** Although fine needle aspiration cytology (FNAC) is an efficient method for diagnosing the benign or malignant nature of thyroid nodules, this distinction may still represent a difficult task especially for follicular neoplasms. Identification of distinct genomic alterations between benign and malignant follicular tumors, potentially applicable to cytological specimens, would be therefore of major interest.

**Design:** A series of 146 tumors including 69 follicular adenomas and 77 follicular carcinomas were analysed by molecular methods. The study entailed an initial test set of 66 samples and a profile of significant alterations detected by array comparative genomic hybridization (aCGH) was characterized and validated by fluorescence *in situ* hybridization (FISH). Selected genetic alterations were further investigated in a second and independent validation set of 60 frozen samples and on a set of 20 archived cytological materials by FISH.

**Results:** Our study shows that gain of 17q is significantly associated with *KRAS*, *HRAS*, *NRAS*, *BRAF*, *CTNGB1* or *PIK3CA* mutations and is more frequent in males than in females. In addition, the combined analysis defined carcinoma-specific alterations consisting of a loss of 1p and 22q, and a gain of X. Using these alterations allowed for the identification of 50% of carcinomas both on frozen tissue and FNAC samples of the thyroid.

**Conclusions:** A significant proportion of follicular lesions can be defined as malignant by detecting at least one out of 3 distinct chromosomal abnormalities using FISH. These molecular markers may be used as an adjunct to the differential diagnosis between follicular adenomas and follicular carcinomas on cytological material obtained by FNAC.

#### 474 Adequacy Criteria for Thyroid Fine Needle Aspirates Evaluated by ThinPrep Slides Only

*Marina Vivero, Andrew Renshaw, Jeffrey F Krane.* Brigham and Women's Hospital, Boston, MA; Baptist Hospital, Miami, FL.

**Background:** Adequacy criteria for thyroid fine needle aspirates (FNA) recommended by The Bethesda System for Reporting Thyroid Cytopathology (TBS) require at least six groups of ten well-visualized follicular cells. These criteria were developed using smears, but are now commonly applied to liquid based preparations. We aim to evaluate TBS adequacy criteria in ThinPrep (TP) slides and determine FNA performance characteristics at different diagnostic cut-offs.

**Design:** All FNA performed between 2010-2015 with matched surgical specimens were analyzed. Cell count, nuclear enlargement, pallor, grooves, and pseudoinclusions, microfollicular architecture, hemosiderin-laden macrophages, colloid, giant cells, Hurthle cells, blood, lymphocytes, and histiocytoid cells were evaluated in initially non-diagnostic cases (ND). ND cases were reclassified into TBS diagnostic categories by two pathologists, and consensus reached in cases of disagreement. Reclassified TP and cytomorphologic features were compared with surgical outcomes.

**Results:** 151 of 1787 (8.4%) thyroid FNA with surgical follow-up were initially classified as ND. Of these, 146 were available for review, 8 with repeat TP slides, for a total of 154 separate TP. Mean cell count among ND thyroids was 58.9 (SD 70.2). Interobserver agreement on reclassification was moderate (k=0.57). Consensus reclassification of ND cases yielded 51 (33%) ND, 76 (49%) benign, 25 (16%) atypia of undetermined significance, and 2 (1%) suspicious for malignancy TP. Lowering the diagnostic cut-off to >1 cell resulted in a sensitivity of 92%, specificity of 60%, positive predictive value of 60%, negative predictive value of 40%, and false negative rate of 8% compared to 93%, 58%, 62%, 38%, and 8% in cases initially considered diagnostic. 37 cases with >60 cells were initially classified as ND due to the absence of at least 6 groups of cells or greater than 10 follicular cells per group; of these, 27 (82%) cases were benign, and re-classification yielded a false negative rate of 8%. Nuclear enlargement, pallor, grooves, and pseudoinclusions, and the presence of histiocytoid cells in paucicellular TP correlated with malignant surgical outcomes among initially ND FNA.

**Conclusions:** In ultrasound guided FNA performed at an academic medical center, reducing the diagnostic cut-off to >1 cell and eliminating the requirement of 6 groups of 10 cells in TP prepared from thyroid FNA does not significantly affect test performance characteristics, as long as cytologic features associated with papillary thyroid carcinoma are absent.

#### 475 Performance of Atypical Urothelial Cells (AUC) Group of the Paris System: Experience of a Single Institution

*Aram Vosoughi, Atousa Ordoobazari, John Ekladous, Carmen Gomez, Monica Garcia-Buitrago, Oleksandr N Kryvenko, Merce Jorda.* University of Miami / Jackson Memorial Hospital, Miami, FL.

**Background:** The Paris System (TPS) for reporting urine cytology was recently introduced with the purpose to improve risk association with high grade urothelial carcinoma (HGUC). Cytologic criteria for the diagnosis of "atypical urothelial cells" (AUC) is as follows: Nuclear/Cytoplasmic (N/C) ratio > 0.5 and one or more of the additional characteristics such as hyperchromasia (H), coarse chromatin (CC), and irregular nuclear membrane (INM). Prior to the TPS era, there was no consensus on definition of "atypia" with variable rates (up to 31%, 16% in our institution). This study was designed to explore AUC interobserver agreement (IA) and its risk association to HGUC.

**Design:** Cytology reports with AUC and negative for HGUC diagnosis from a 6 months period were reviewed along with the concomitant biopsies. The AUC diagnosis was reviewed by 4 cytopathologists. Additional 27 AUC cases (based on TPS) from a previous study were added to the AUC cohort. Five criteria including H, CC, INM, nuclear size (NS) and presence of nucleolus (N) were recorded for each case. NS was obtained by comparison with the nucleus of an intermediate urothelial cell (IUC). Nuclei were classified in 2 groups: small (1-2 time larger than IUC) and large (more than 2 time larger than IUC). The correlation of diagnostic criteria with final diagnosis was assessed by the Pearson correlation coefficient. Cohen's kappa was used to establish the IA for each diagnostic criterion among pathologists.

**Results:** Of the 604 urine cases diagnosed over a 6-month period, 56 (9.2%) cases were reported as AUC in comparison to the 16% prior to TPS, while keeping the rate of HGUC in the "negative for HGUC" group acceptable (47%, published rates: 32.2% -68.9%). The risk of detecting HGUC in the AUC group in follow up biopsies was 37.5% (21 cases) in comparison to 14.2% prior to TPS. Among AUC criteria, H and NS had the highest correlation with HGUC with a Pearson correlation coefficient of 0.6 and 0.5 (P<0.001) respectively. H had a higher IA than NS (Kappa 0.22 vs 0.39). INM had the lowest IA (Kappa: 0.18) and the N had the lowest correlation with HGUC (r: 0.26, P: 0.02).

**Conclusions:** Defined criteria for the AUC group in TPS reduced the rate of "atypia" diagnosis and increased the detection rate for HGUC. H and NS had the highest correlation with HGUC and H had the highest IA. Further studies are warranted to elucidate the impact of NS in TPS AUC group.

**476 Sox10 Expression of Metastatic Breast Carcinoma in Pleural Fluid Cytology**

*Christopher Vytlacil, Shweta Patel, Jan F Silverman.* Allegheny General Hospital, Pittsburgh, PA.

**Background:** Sox10 is a transcription factor found in cells of neural crest origin. Immunohistochemical staining for Sox10 is frequently used in the evaluation of melanoma, but has also recently shown expression in basal-like, triple negative, and metaplastic breast carcinomas. Determining site of origin in effusion cytology is often challenging. GATA3 is no longer a specific marker for breast carcinomas as it once was. The utility of Sox10 in metastatic breast cancer in cytology specimens has not been studied. The goal of this project was to examine Sox10 expression in breast cancer metastatic to pleural fluid.

**Design:** We retrospectively examined 28 cases of breast carcinomas metastatic to pleural fluid over a three year period, 6 of which were triple-negative in the pleural fluid specimen. In each case immunohistochemistry for Sox10 and Gata3 was performed and evaluated. The hormone receptor status of the prior surgical breast biopsy or resection was also recorded. The extent of nuclear staining for Sox10 and GATA3 were scored by percentages as follows: 0 (0%), 1+ (1-25%), 2+ (26-50%), 3+ (51-75%), and 4+ (76-100%). One of the six triple negative cases was eliminated due to inadequate material in cell block.

**Results:** Gata3 was 3+ or 4+ in (25/27) of cases and 2+ in 7% (2/27). Sox10 was 4+ in 4% (1/27) of total cases and 20% (1/5) of triple-negative cases. Sox10 labeled the one case previously reported as triple negative. The remaining four triple-negative pleural fluid cases had at least one positive predictive marker (ER, PR, HER2) in the corresponding prior surgical specimen. These cases were also negative for Sox10 in pleural fluid.

**Conclusions:** The percentage of Sox10 expression in triple-negative breast cancer is lower in our study than has been previously reported (66%)<sup>1</sup>. As loss of receptor expression in recurrent and metastatic breast cancer is a well-known phenomenon, and given that our only Sox10 positive case was previously reported as triple-negative we postulate that loss of receptor status in metastasis does not influence Sox10 expression. We believe that along with GATA3, Sox10 may be a valuable addition in the workup of metastases of unknown origin, especially if triple negative breast carcinoma is in the differential diagnosis.

**477 Evaluation of Noninvasive Follicular Neoplasms with Papillary-Like Nuclear Features, an Institutional Experience**

*Vivian Weiss, Carmen C Solorzano, Kim Eby, Mitra Mehrad.* Vanderbilt University Medical Center, Nashville, TN.

**Background:** Up to 25% of previously classified thyroid malignancies now fall under the category of noninvasive follicular thyroid neoplasm with papillary-like nuclear features (NIFTP). The challenge for cytopathologists is to reliably differentiate NIFTP from malignant lesions by fine needle aspiration (FNA). Our goal was to ascertain whether any cytological features could help predict malignancy versus NIFTP on fine needle aspiration (FNA).

**Design:** Files from 2008-2015 were searched for thyroids with indeterminate cytology (suspicious for papillary thyroid carcinoma (SUS), atypia of undetermined significance/follicular lesion of undetermined significance (AUS/FLUS), and follicular neoplasm/suspicious for follicular neoplasm (FN/SFN)) on FNA and subsequent diagnosis of follicular variant of papillary thyroid carcinoma (FVPTC) on resection (with entire nodule submitted for histologic evaluation). Surgical cases were reviewed by three pathologists to identify NIFTP applying the recently described criteria by Nikiforov et al (JAMA Oncol. 2016 Aug 1;2(8):1023-9.) Cytology cases were reviewed and assessed morphologically for presence of microfollicular architecture, colloid, nuclear grooves, pseudoinclusions, and atypia.

**Results:** Twenty cases were identified. Of these, 7 (35%) met criteria for NIFTP and the rest were invasive FVPTC (IFVPTC). The average size of the lesions was 15 mm for both NIFTPs (range 8-22 mm) and IFVPTCs (range 5-27 mm). On FNA, the NIFTPs were diagnosed as SUS (4/7, 57%), FN (2/7, 29%), and AUS/FLUS (1/7, 14%), whereas the IFVPTCs were diagnosed as SUS (5/13, 38%) and AUS/FLUS (8/13, 62%). On cytology, nuclear pseudoinclusions were more frequently identified in IFVPTC (5/13, 39%), compared to only 1/7 NIFTPs (14%). All cases demonstrated microfollicular growth pattern, scant colloid, nuclear grooves and atypia.

**Conclusions:** This is the first study to provide a cytologic comparison of indeterminate thyroid FNAs from NIFTPs and IFVPTCs. While the distinction between NIFTP and IFVPTC based on cytology remains challenging, in our experience, nuclear pseudoinclusions were more frequently identified on the FNAs from patients with IFVPTCs compared to NIFTPs. The nonspecific, but suspicious findings of nuclear grooves and rare/no nuclear inclusions on NIFTP FNAs, may lower the malignancy risk of indeterminate categories and require re-evaluation of clinical management algorithms.

**478 Prognostic Relevance of Pancreatic Neuroendocrine Tumor Grading on EUS-FNA**

*Birgit Weynand, Laure Boutsen, Ivan Borbath, Anne Jouret-Mourin.* UZ Leuven, Leuven, Belgium; Cliniques universitaires St Luc, Brussels, Belgium; Cliniques universitaires St Luc, Brussels, Belgium.

**Background:** In the WHO 2010 classification, resection specimen of pancreatic neuroendocrine tumors (pNETs) are graded using the Ki67-labeling index (Ki67-LI). EUS-FNA has become an important diagnostic tool of pNETs. Although many studies looked at diagnostic accuracy of EUS-FNA, only few deal with grading of pNETs on EUS-FNA. The aim of this study is to compare Ki67-LI on EUS-FNA with the ones

on corresponding surgical specimen. Influence of tumor size and number of counted cells is evaluated, as are overall survival (OS) and progression free survival (PFS) based on cytological grade.

**Design:** Between 1996 and 2013, 102 pNETs from 101 patients (57 required surgery) were retrospectively included in this multicenter study. All of them underwent EUS-FNA at time of diagnosis. Ki67-LI was evaluated on the 102 tumor FNAs and on the 57 resected specimens. In a subgroup of 29 FNAs, more than 2000 cells were counted (14 patients underwent surgery). All patients were followed-up until June 2016.

**Results:** Cytological grade was consistent with histological grade in 39/57 cases (68.4% with a 3% cut-off between G1 and G2). Agreement between FNA grade and surgical specimen was significant using the 3% cut-off (k=0.434, p<0.001). For Ki67-LI absolute values, correlation was significant (r=0.443, p=0.001) in the whole group and raised when more tumor cells were counted (r=0.824, p<0.001, 2000 counted cells). Mean tumor size was significantly smaller when cytological and histological grading was consistent (p=0.023, 5% cut-off). The median overall survival (OS) of the entire population is 235.30 months. OS is significantly different between tumors based on cytological Ki67-LI with a 3% cut-off (G1 235.30 months, G2 68.68 months and G3 10.95 months). The median progression free survival (PFS) is significantly greater for patients with a G1 tumor than for those with a G2 (39.80 months) or a G3 (10.07 months) tumor (HR vs. G1: 2.61 and 14.70).

**Conclusions:** pNETs cytological grading is especially accurate when tumor size is small (< 2 cm) and more tumor cells are counted. Discrepancies are most common among G2 tumors due to tumor heterogeneity. Nevertheless, EUS-FNA is a valuable tool to distinguish patients with a good (G1) or a poor (G3) prognosis, in terms of OS and PFS. Clinicians should base treatment decisions on absolute numbers of FNA Ki67-LI.

**479 Utility of a PLAG1, LEF1 and MYB Immunostain Panel in the Diagnosis of Basaloid Salivary Gland Neoplasms on Fine Needle Aspiration**

*Lucas Wiecek, Momin T Siddiqui, Cynthia Cohen, Alessandra Schmitt, Christopher C Griffith.* Emory University, Atlanta, GA.

**Background:** Fine needle aspiration diagnosis of basaloid salivary gland neoplasms represent a challenge in cytology with differentials ranging from benign pleomorphic adenoma (PA) to malignancies such as adenoid cystic carcinoma (AdCC). Some potentially useful immunostains have been reported. We studied a panel of PLAG1, LEF1, and MYB in order to differentiate PA, epithelialmyoepithelial carcinoma ex PA (EMCAexPA), basal cell adenoma (BCA), basal cell adenocarcinoma (BCAC) and AdCC on FNA cell blocks.

**Design:** 62 FNA cases were included, of which 38 cases had surgical followup. 24 cases were diagnosed as PA on FNA alone. The immunostain panel was performed on cell blocks and scored 0-3 (0=no staining, 1=focal weak, 2=focal strong/diffuse moderate and 3=strong and diffuse). Cases with insufficient material were excluded (8 PLAG1, 7 LEF1, and 7 MYB). Scores of 0 or 1 were considered negative (-) and 2 or 3 positive (+). Results were correlated with final surgical diagnosis when available.

**Results:** IHC results are shown in table 1. Of PLAG1+ cases, 91.3% (21/23) were PA or EMCAexPA with the remainder diagnosed as BCA and BCAC. No cases of AdCC were PLAG1+. 80% of AdCC were MYB+ and 80% of all MYB+ cases were AdCC on followup. All LEF1+ cases were benign (PA or BCA).

	PLAG1		LEF1		MYB	
	-	+	-	+	-	+
PA, Total	18 (47.4%)	20 (52.6%)	30 (78.9%)	8 (21.1%)	38 (100%)	0
PA w/ hist. F/U	6 (33.3%)	12 (66.7%)	12 (66.7%)	6 (33.3%)	18 (100%)	0
PA w/o hist. F/U	12 (60%)	8 (40%)	18 (90%)	2 (10%)	20 (100%)	0
EMCAexPA	0	1 (100%)	1 (100%)	0	1 (100%)	0
BCA	3 (75%)	1 (25%)	2 (50%)	2 (50%)	3 (60%)	2 (40%)
BCAC	0	1 (100%)	1 (100%)	0	1 (100%)	0
AdCC	10 (100%)	0	10 (100%)	0	2 (20%)	8 (80%)
Benign	21 (50%)	21 (50%)	32 (76.2%)	10 (23.8%)	41 (95.3%)	2 (4.7%)
Malignant	10 (83.3%)	1 (16.7%)	12 (100%)	0	4 (33.3%)	8 (66.7%)

**Conclusions:** PLAG1+ and MYB— favor a benign neoplasm but CAexPA cannot be entirely excluded. MYB+ and PLAG1— favor malignancy, specifically AdCC. LEF1+ cases were mostly benign in our study but only 1 case of BCAC was included. Due to the small number of cases other than PA and AdCC, the value of these stains in other basaloid neoplasms on FNA requires further study. Overall, this study suggests that a panel of PLAG1, LEF1 and MYB can be useful in evaluating basaloid salivary gland neoplasms on FNA.

**480 Percutaneous Image-Guided Biopsy of the Renal Masses: A Single Institution Study with Comparison of Fine Needle Aspiration and Core Biopsy**

*Howard Wu, Chi-Shun Yang, Muhammad Idrees, Shaoxiong Chen.* Indiana University School of Medicine, Indianapolis, IN; Taichung Veterans General Hospital, Taichung, Taiwan.

**Background:** In recent years, the increasing incidence of small renal masses, the development of conservative treatments for low-risk renal cell carcinomas, and the discovery of novel-targeted treatments have provided increasing indications for

percutaneous renal mass biopsy. Fine needle aspiration (FNA) with or without core biopsies (CB) has been increasingly used in the management of renal tumors in our institution. There are few studies comparing these two techniques for the diagnosis of the renal tumors.

**Design:** A computer search of our anatomic pathology file was conducted for cases of FNA of renal masses as well as correlating CB and/or nephrectomy specimens for a span of 10 years period between January 2006 and December 2015. The diagnoses of FNA and CB were correlated with followup nephrectomy specimens. The diagnoses were classified into 5 categories: malignancy (M), suspicious for malignancy (SM), neoplasm (N), atypical (A) and negative/non-diagnostic (ND). Based on the results of the nephrectomy specimens, the diagnostic rate, sensitivity and diagnostic accuracy were calculated among three groups: FNA only, CB only, and the combination of FNA and CB.

**Results:** A total of 247 cases of FNA with 123 correlating CB and 108 followup nephrectomy specimens were identified. The FNA diagnoses included M 132 (53%), SM 9 (4%), N 24 (10%), A 12 (5%) and ND 70 (28%). The CB diagnoses included M 83 (67%), SM 1 (1%), N 23 (19%), A 0, and ND 16 (13%). Combining both FNA and CB, the diagnoses included M 84 (68%), SM 2 (2%), N 26 (21%), A 1 (1%) and ND 10 (8%). The diagnostic rate, sensitivity and diagnostic accuracy were 72%, 80% and 96% for FNA; 87%, 94% and 94% for CB; and 92%, 94% and 94% for the combination group.

Procedure	Diagnostic rate	Sensitivity	Diagnostic Accuracy
FNA alone (n=247)	72%	80%	96%
Core alone (n=117)	86%	92%	94%
Combined FNA and Core (n=117)	92%	94%	94%

Renal cell carcinoma (RCC) and it variants were accounted for the most common histologic diagnoses (112/174, 64%). Significant diagnostic discrepancy was noted in one case: a malignant melanoma was misdiagnosed as RCC in both preoperative FNA and CB.

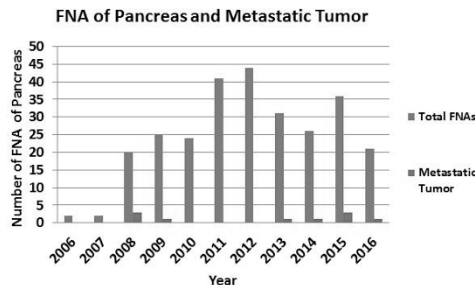
**Conclusions:** Both FNA and CB demonstrate excellent diagnostic accuracy (96% and 94%). The combination of FNA and CB significantly improves the diagnostic rate over FNA alone (92% vs 72%, p<0.05) and is also better than CB alone (92% vs 87%).

**481 Metastatic Neoplasms to the Pancreas Diagnosed by Fine Needle Aspiration: A 10-Year Experience from a Tertiary Medical Center**  
*Ya Xu, Rodolfo Laucirica, Neda Zarrin-Khameh.* Baylor College of Medicine, Houston, TX.

**Background:** Metastatic neoplasms to the pancreas are rare and often difficult to separate from primary tumors. Neoplasms that most often metastasize to the pancreas include carcinomas of lung, breast, kidney, and lymphoma. The data on metastatic tumors to the pancreas diagnosed by fine needle aspiration (FNA) biopsy is limited. We report our ten-year experience utilizing FNA biopsy in the evaluation of secondary pancreatic tumors.

**Design:** Total 275 cases of pancreatic fine needle aspiration (FNA) from 2006 – 2016 from a tertiary medical center were reviewed. Pertinent immunohistochemical stains were performed on cell block.

**Results:** The number of pancreatic FNA biopsies steadily increased from 2 cases in 2006 to a peak of 44 cases in 2012. A total of 150 cases (6.7%) were diagnosed as positive or suspicious for malignancy. Of these 150 cases, 10 (3.6%) were diagnosed as metastatic neoplasms to the pancreas. There were four cases of breast ductal carcinoma (one with unknown primary), one case of endocervical adenocarcinoma, one case of anal/rectal squamous cell carcinoma, one case of renal cell carcinoma, one case of hepatocellular carcinoma, one case of seminoma and one case of lung adenocarcinoma. Immunohistochemical stains were performed on nine cases to confirm the diagnosis of metastatic disease to the pancreas. The data is summarized.



**Conclusions:** FNA biopsy is a useful tool to diagnose metastatic lesions involving the pancreas. In our study, breast carcinoma was the most common secondary pancreatic neoplasm. The majority of metastatic tumors need immunohistochemical stains to confirm the diagnosis, especially in cases such as metastatic renal cell carcinoma which may mimic a primary pancreatic neoplasm.

**482 Molecular Testing in Patients with Indeterminate Cytology of Thyroid Fine Needle Aspiration: A Single Medical Institute Experience**

*Zhongbo Yang, Kristen M Scheitler, Jennifer N Woods, Magda Esebu.* University of Missouri, Columbia, MO.

**Background:** About 10 to 30% of thyroid fine needle aspiration (FNA) nodules have indeterminate cytology, including atypia of undetermined significance (AUS)/follicular lesion of undetermined significance (FLUS), (suspicious for)follicular neoplasm (FN) or Hurthle cell neoplasm (HCN), and suspicious for malignancy. Afirma Gene Expression

Classifier (GEC) measuring the expression of 167 mRNA was designed to classify the indeterminate thyroid nodules into benign and suspicious categories. This study aimed to evaluate the Afirma GEC testing in these indeterminate thyroid lesions.

**Design:** Medical records of patients with indeterminate thyroid FNA results and corresponding Afirma GEC results from November 2012 to July 2016 were retrieved. Subsequent surgical follow-up results were obtained. GEC results were compared to the histologic diagnoses.

**Results:** 1. Of 48 cases with indeterminate FNA results, 35 were female and 13 were male. The mean age was 52 years (14-81 years). Cytology diagnosis included 42 AUS and 6 FN/HCN. Afirma GEC results were benign for 25 cases (52%), suspicious for 21 cases (44%), and nondiagnostic for 2 cases (4%).

2. Among 48 cases, 20 (42%) had corresponding surgical follow-up reports and these included 11 benign (4 follicular adenoma, 4 Hurthle cell adenoma, 2 nodular hyperplasia, 1 Hashimoto thyroiditis) and 9 malignant (3 papillary thyroid carcinoma, 3 follicular carcinoma, 3 Hurthle cell carcinoma) results.

3. Three of 5 cases with benign GEC results were benign and 2 were malignant on histology. Seven of 15 cases with suspicious GEC results were malignant and 8 were benign on histology.

**Conclusions:** 1. We demonstrated in this study that 7 of 15 cases (47%) with suspicious GEC results were malignant on surgical follow-up diagnosis, including 5 follicular carcinoma (3 oncocytic variants) and 2 papillary thyroid carcinoma. This is similar to other studies.

2. Two of 5 cases with benign GEC results showed malignant histology, including 1 papillary thyroid carcinoma and 1 minimally invasive follicular carcinoma. These cases are most likely lacking a mutation of known genes.

3. Three of 4 cases of Hurthle cell adenoma were classified as suspicious by GEC testing, suggesting that the Afirma GEC testing was weak in differentiating malignant cells and oncocytic cells.

4. By reclassifying indeterminate thyroid nodules by Afirma GEC testing, about 40% of cases with benign GEC results avoided unnecessary surgical resections.

**483 Follow-Up of Unsatisfactory Pap Tests: Does High-Risk HPV Co-Testing Contribute to Disease Risk Stratification?**

*Lindsay Yassan, Tatjana Antic, Ward Reeves, Ricardo R Lastra.* University of Chicago, Chicago, IL.

**Background:** According to the ASCCP Consensus Guidelines on the Management of Abnormal Cervical Cancer Screening Tests, women with unsatisfactory Pap specimens are recommended to have repeat cytology within 2 to 4 months. High-risk HPV (hrHPV) triage testing and co-testing is not considered sufficient for disease risk stratification, particularly in the setting of HPV-testing platforms without robust internal control for epithelial cellularity.

**Design:** Unsatisfactory ThinPrep® Pap tests performed at an academic institution between January 2013 and December 2015 were reviewed. hrHPV results were collected when co-testing was performed. Follow-up data, including cytology results, hrHPV results, and available biopsy results, were then analyzed.

**Results:** Of the 21035 ThinPrep® Pap tests performed over the 36-month time interval, 691 (3.3%) were unsatisfactory for evaluation due to limited cellularity. The median patient age was 48 (range, 20-89). 451 patients had follow-up testing performed with an average follow-up time of 181 days. Of those with follow-up, 66 patients (27.5%) had an abnormality detected on follow-up testing (1 CIN III, 2 CIN II-III, 4 CIN I, 2 HPV change on biopsy; 4 LSIL, 4 ASC-H, 36 ASCUS, 7 atypical glandular cells, and 6 hrHPV positive). Of the patients with unsatisfactory ThinPrep® Pap testing, 293 had concurrent hrHPV co-testing. One case (0.3%) had insufficient residual sample. 16 cases (5.5%) were positive for hrHPV and 276 (94.2%) were negative. Of those that tested positive for hrHPV, 13 patients (81.2%) had follow-up studies performed (mean of 183 days), and 6 of the 13 (46.1%) patients had an abnormality detected on follow-up (1 CIN III, 1 CIN II-III, 1 CIN I, 2 ASCUS, and 1 hrHPV positive). Of those that tested negative for hrHPV, 170 patients (61.6%) had follow-up studies performed (mean of 202 days) and 20 of the 170 (11.8%) patients had an abnormality detected on follow-up (1 CIN II-III, 2 HPV change on biopsy, 2 ASC-H, 8 ASCUS, 4 atypical glandular cells, and 3 hrHPV positive).

**Conclusions:** Our data suggests that positive hrHPV, even in cases of unsatisfactory Pap smear due to limited cellularity, contributes to disease risk stratification. However, negative hrHPV co-testing should be interpreted with caution. Our results highlight the need for robust internal controls in hrHPV assays to account for epithelial cellularity in order to obviate the risk of false negatives. This is especially relevant as some clinicians are considering primary hrHPV testing as an alternative screening method.

**484 Oncocytic Features in Salivary Duct Carcinoma, a Potential Pitfall for Misdiagnosis as Warthin Tumor in Fine Needle Aspiration Samples: Cytomorphologic Analysis of Nine Cases**

*Amy J Zhang, Tetyana N Mettler, Jimmie Stewart, Khalid Amin.* University of Minnesota, Minneapolis, MN.

**Background:** Salivary duct carcinoma (SDC) is an uncommon and highly aggressive primary salivary gland neoplasm that resembles intraductal and infiltrating breast carcinoma. Commonly described features of SDC on fine needle aspiration cytology (FNAC) include: increased cellularity, nuclear atypia, prominent nucleoli, and background necrosis. The presence of oncocytic change, defined as abundant eosinophilic cytoplasm, is described but not adequately emphasized or characterized in the current literature.

**Design:** A seven-year (2010-2016) retrospective search was performed on the anatomic pathology case archives of our institution. Nine FNAC cases with histologically proven SDC were retrieved and various cytomorphologic features analyzed semi-quantitatively.



**Results:** Average patient age was 65 years and 7 of 9 (78%) were male. All SDCs were located in the parotid gland. Initial cytologic diagnoses were: SDC (2 cases), intermediate to high-grade carcinoma (3 cases), mucoepidermoid carcinoma (1 case), oncocytic neoplasm (1 case), and Warthin tumor (2 cases). FNAC features analyzed included: oncocytic change, noted in all cases (33% moderate, 56% marked), cellularity (22% moderate, 56% marked), nuclear atypia (22% moderate, 11% moderate to marked, 22% marked), prominent nucleoli (100%), cytoplasmic vacuolation (11% moderate, 0% marked), and background necrosis (11% moderate, 33% marked). 3 of 9 cases (33%) exhibited cribriform architecture. Foamy/cystic macrophages were noted in 5 of 9 cases (56%) and in none of the cases background lymphocytes were seen.

**Conclusions:** In our experience, precise diagnosis of SDC on cytomorphologic features alone can be challenging. Oncocytic change is one of the most consistent features observed in this case series and when associated with less pronounced cytologic atypia and background necrosis can potentially lead to misdiagnosis as Warthin tumor. We recommend that SDC should be considered in the differential diagnosis of all FNAC cases of oncocytic salivary gland neoplasms where precise diagnosis is not possible.

**485 Comparative Characterization of Genotype Profiles of High-Risk Human Papillomavirus (hrHPV) Infection in Male and Female HIV Positive Patients and Their Correlation with Anal Cytology and Biopsy**

*Xiaofei Zhang, David Chhieng, Michael Gaisa, Keith Sigel, Dan Lu, Yuxin Liu, Tamara Kalir, Qiusheng Si.* The Mount Sinai Hospital, Icahn School of Medicine, New York, NY.

**Background:** Recently many studies have demonstrated the increased susceptibility of high-risk HPV (hrHPV) infection in HIV+ males and its strong association with anal cancer. However, similar studies focusing on HIV+ females are still limited, and there is still a major gap in our knowledge on the gender differences in the clinicopathological features of hrHPV related anal lesions.

**Design:** We retrospectively analyzed all HIV+ patients (254 males, 323 females) who had anal smear at our hospital between 2012 to 2015. Anal HPV genotyping is performed by real time polymerase chain reaction. Student's t-test and one-way ANOVA was used to compare continuous variables and chi-square with Fisher exact test was used to compare categorical variables.

**Results:** The prevalence of hrHPV infection is significantly lower in HIV+ females than HIV+ males (67.5% vs 82.3%, p<0.05). In both genders, hrHPV infection is associated with higher risks of having abnormal anal smear in cytology or high grade lesion (HSIL) in biopsy. The prevalence of HPV16, HPV18 and other high risk HPV (ohrHPV) infection are 31.1%, 26.5%, and 92.7% overall; vs 26.6%, 27.5%, and 91.3% in HIV+ female; vs 35.9%, 24.9%, and 92.7% in HIV+ male. The prevalence of HPV16 infection is significantly lower in HIV+ female (26.6% in female vs 35.9% in male, p<0.05). There is no significant differences in the prevalence of HPV18 and ohrHPV. When patients are positive only for ohrHPV, the chance of having abnormal anal smear or HSIL are 75.1% and 1.8%; and they are increased to 83.2% (p=0.06) and 6.7% (p<0.05) if patients are co-infected with either HPV16 or 18. Similarly, when patients are positive only for either HPV16 or 18, the chances of having abnormal anal smear or HSIL are 66.7% and 0%, and they are increased to 83.3% (p<0.05) and 6.7% (p=0.222) if co-infected with ohrHPV.

**Conclusions:** Although HPV16 and 18 are two most commonly infected hrHPVs, they only account for a small percentage of hrHPV infection in HIV+ patients, among which >90% are positive for ohrHPV. When patients are co-infected with multiple types of hrHPVs, the risk of developing anal lesions is significantly increased, suggesting synergic effect. Our results suggest that male and female HIV+ patients have different hrHPV infection profile, and multivalent vaccines with more complete coverage of the ohrHPV groups are required for more effective protection.

**486 Comparing the Histologic Follow-Up Results of Positive HC2 HR HPV Test, Cervista HPV HR Assay and Aptima HR Assay for Women with ASC-US Cytology**

*Chengquan Zhao, Dinesh Pradhan, Michelle Stram.* UPMC, Pittsburgh, PA.

**Background:** Data remain very limited comparing histological follow-up results for women with ASC-US Pap/positive hrHPV testing by using different FDA-approved HPV testing methods.

**Design:** A computer-based search was carried out on our pathology database to retrieve the cases with ASC-US ThinPrep Pap and positive HC2 HPV (6/2012 to 5/2013), positive Cervista HPV (6/2013 to 5/2014), and positive Aptima HPV result (6/2015 to 5/2016). Histological follow-up results within 6 months since ASC-US Pap/positive HPV testing were analyzed.

**Results:** The first continuous 1500 cases with ASC-US/HPV positivity in each group were checked for the histological follow-up results in the database. Among the total 4500 ASC-US Pap/HPV positive cases, 2305 cases (51.2%) had histological follow-up within six months after ASC-US Pap/positive HPV tests. The average initial follow-up period was 1.2 months (0.1-6) and average age of these women was 35.6 years (16-84 years) Of these 2305 women, overall CIN2/3 was detected in 156 cases (6.8%) and CIN1 was detected in 916 cases (39.7%). CIN2/3 detection rates in positive HC2 HPV group (7.9%) and Aptima HPV group (8.7%) were significantly higher than that in positive Cervista HPV HR group (3.9%) (p<0.001), while there is no significant difference between HC2 and Aptima detection methods. Overall CIN2/3 and CIN1 detection rates were significantly higher in women <=30 years than that in women >30 years (p<0.01).

HPV tests	Age group	Case No	CIN2/3 (%)	CIN1
HC2	<30	370	37 (10)	185
	>=30	445	27 (6.1)	161
	Subtotal	815	64 (7.9)	346
Cervista	<30	183	12 (6.6)	82
	>=30	591	18 (3.0)	195
	Subtotal	774	30 (3.9)	277
Aptima	<30	172	18 (10.5)	76
	>=30	544	44 (8.0)	217
	Subtotal	716	62 (8.7)	293
Summary	<30	725	67 (9.2)	343
	>=30	1580	89 (5.6)	573
	Total	2305	156 (6.8)	916

**Conclusions:** This is one of the largest studies to compare the short histological follow-up results for women with ASC-US Pap/hrHPV positive by using three FDA approved HPV detection methods in a clinical laboratory. The results demonstrate that Aptima and HC2 share similar sensitivity to detect CIN lesions and Cervista had the lower sensitivity. Younger women with ASC-US/ positive hrHPV testing had higher risk of having cervical squamous lesions as compared to the older women. About 50% women with ASC-US pap/positive HPV testing had not colposcopy examination in a short period.

**487 Outcomes of Atypia of Undetermined Significance/Follicular Lesion of Undetermined Significance in Thyroid Fine Needle Aspiration**

*Cynthia Zhao, Guillermo A Herrera, Elba A Turbat-Herrera.* Louisiana State University Health Sciences Center, Shreveport, LA.

**Background:** The Bethesda System for Reporting Thyroid Cytopathology has been widely used by cytopathologists for interpreting thyroid fine needle aspiration (FNA). Bethesda Category III, atypia of undetermined significance/follicular lesion of undetermined significance (AUS/FLUS), has been reported a malignancy risk of 5-15%, but the actual rate of malignancy varies among institutions. Our objective was to report our experience of malignancy risk and clinical management of thyroid FNAs diagnosed with AUS/FLUS at LSUHSC-Shreveport.

**Design:** Thyroid FNA specimens diagnosed with AUS/FLUS at LSUHSC-Shreveport were identified in 2014 by using Copath data system. The patients' demographic information and their clinical management were analyzed. AUS/FLUS nodules were correlated with the surgical pathology specimens, which are considered as a gold standard.

**Results:** Among 217 thyroid FNAs, 60 nodules were diagnosed with AUS/FLUS (60/217, 28%). After exclusion of one case with simultaneous nodules in the same lobe that were suspicious for papillary carcinoma and 3 repeated FNAs, 56 cases were included in the study. There were 50 females (89%) and 6 males (11%). The average age for female was 47 years (age range 9-69 years). The average age for male was 60 years (age range 41-82 years). Of 56 AUS/FLUS cases, 35 (63%) underwent surgery, 4 (7%) had repeat FNA, and 17 (30%) were followed up with observation. With 4 repeat FNAs, 2 were benign, and 2 were AUS/FLUS. The FNA repeat interval was 3-9 months. Of 35 cases with surgery, 31 (89%) were benign and 4 (11%) were malignant with papillary thyroid carcinoma. Extrapolating for all AUS/FLUS nodules including those patients without surgeries, the risk of malignancy at our hospital was 7% (4/56), which was comparable with the malignancy risk of 5-15% in the Bethesda Category III.

**Conclusions:** Although repeat FNA is expected for Bethesda Category III, we found that our repeat FNA rate was only 7%. The majority (63%) had surgery without repeat FNAs. Correlation with these patients' clinical and sonographic information needs to be done to better understand the clinical selection criteria of surgical cases. The risk of malignancy at our hospital was 7%, which was comparable with the malignancy risk of 5-15% in the Bethesda Category III. Additional molecular testing may help decrease the number of unnecessary surgeries for the potential benign cases in this category, and so increase the malignancy detecting rate in surgical specimens.

**488 LSIL Cervical Cytology Report Rate and Histological Follow-Up Finding in China**

*BaoWen Zheng, Huaitao Uamg, Guijian Wei, Chengquan Zhao.* Guangzhou Kingmed Diagnostics, Guangzhou, China; University Cincinnati College of Medicine, Cincinnati, OH; University of Pittsburgh Medical Center, Pittsburgh, PA.

**Background:** Age-adjusted evaluations have explored the possible utility of HPV test results in women with LSIL Paps.

**Design:** A retrospective study identified LSIL Paps between 2011 and 2015 from the Cytology Laboratory. LSIL cases with hrHPV test and histological follow-up results were analyzed. The patients were divided into age groups.

**Results:** A total 2,206,588 Pap tests were performed, including 68.6% LBC Paps, and 31.4% conventional Pap test. Total LSIL report rate was 1.7%. LSIL rate was declined with age. Overall women with LSIL had hrHPV-positivity of 75.8%. As LSIL rate, HPV rate was the highest in younger women, gradually declined with increased age, except for an increased curve in women 60 years and above. 5987 patients had histological results within 6 months after LSIL. Overall CIN2/3 was identified in 15.2% patients. 1334 LSIL/HPV+ women and 393 LSIL/HPV- women had histological results. CIN2/3 lesion was detected in 17.8% LSIL/HPV+ women and 8.1% LSIL/HPV- women.

	Total Pap test No	LSIL No	%
<20	14343	517	3.6
20-29	336284	6902	2.05
30-39	656239	11346	1.73
40-49	705667	12651	1.79
50-59	265011	3542	1.34
≥60	70170	834	1.19
unknown	158874	2103	1.32
Total	2206588	37895	1.72

	HC2 HPV Positive			HC2 HPV Negative		
	Follow-up	CIN2+*(%)	CIN1	Follow-up	CIN2+*(%)	CIN1
<20	24	2 (8.3)	16	3	0 (0)	3
20-29	367	49 (13.4)	284	81	3 (3.7)	68
30-39	440	92 (20.9)	298	135	15 (11.1)	100
40-49	379	75 (19.8)	263	132	10 (7.6)	102
50-59	68	14 (20.6)	46	28	1 (3.6)	18
≥60	14	1 (7.1)	6	2	0 (0)	2
unknown	42	5 (11.9)	34	12	3 (25)	8
Total	1334	238 (17.8)	947	393	32 (8.1)	301

**Conclusions:** This is the largest case study in women with LSIL in China. The LSIL rate and HPV positive rate, and follow-up results were within the benchmark ranges for international cytology laboratories. A surprising finding is that 8.1% LSIL/HPV- women had histological CIN2/3, which is not supportive of HPV test as primary cervical cancer screening. These data may contribute to establishing a baseline for better understanding the status of cervical screening in China.

**489 ASCUS Cervical Cytology Report Rate and Histological Follow-Up Finding in China's Largest CAP-Certified Laboratory**

*BaoWen Zheng, Huaitao Yang, Jia You, Chengquan Zhao.* Guangzhou Kingmed Diagnostics, Guangzhou, China; University Cincinnati College of Medicine, Cincinnati, OH; University of Pittsburgh Medical Center, Pittsburgh, PA.

**Background:** Data about ASC-US women with hrHPV testing and the histological follow-up is very rare in China.

**Design:** A retrospective study identified Paps between 2011 and 2015 from the large cytology laboratory. ASC-US cases with hrHPV test and histological follow-up results were recorded.

**Results:** A total 2,206,588 Pap tests were performed during the study period. Overall ASC-US report rate was 3.8%, with 5.6% in SurePath, 4.6% in LITUO, 4.1% in ThinPrep, 3.8% in LPT, and 2.3% in conventional Paps. ASC-US report rate was highest for women aged 40-49 years and declined with age. Of 18,574 women with HC2 testing, 6498 were HPV positive (35.0%). HPV positive rate was the highest in younger women (60.1%, <20 years), gradually declined with increased age for women aged <50 years, except for an increased curve in women 60 years. 6012 patients had histological results within 6 months after ASC-US. Overall CIN2 and severe lesions (CIN2+) were identified in 7.9% patients. 887 ASC-US/HPV+ women and 1022 ASCUS/HPV- women had histological results with 6 months after Pap/HC2 testing. CIN2+ lesions were detected in 14.0% ASCUS/HPV+ women including 35 (4.0%) squamous cell carcinomas (SCC), and 2.8% ASCUS/HPV- women including one SCC. CIN2+ lesion rates were no statistically different among different age groups.

**Conclusions:** This is the largest case study in ASCUS in China. The ASCUS rate and HPV positive rate, and follow-up results were within the benchmark ranges for international cytology laboratories. 2.8% ASC-US/HPV-women had CIN2/3 detection within 6 months, which was higher than that from thereports in West countries. These data can contribute to establish a baseline for cervical screening in China.

	HC2 HPV positive			HC2 HPV negative		
	Follow-up No	CIN2+*(%)	CIN1(%)	Follow-up No	CIN2+*(%)	CIN1(%)
<30	205	28(13.7)	136(66.3)	138	4(2.9)	62(44.9)
30-49	588	83(14.1)	360(61.2)	743	22(3.0)	390(52.5)
≥50	71	10(14.1)	45(63.4)	118	3(2.5)	57(48.3)
Unknown	23	3(13.0)	15(62.5)	23	0	11(47.8)
Total	887	124(14.0)	556(62.7)	1022	29(2.8)	520(50.9)

**490 Diagnosis "Non-Invasive Follicular Thyroid Neoplasm with Papillary-Like Nuclear Fetaures" (NIFTP): Implications on the Risk of Malignancy (ROM) in the Bethesda System for Reporting Thyroid Cytopathology (TBSRTC)**

*Haijun Zhou, Zubair Baloch, Tommaso Bizzarro, Guido Fadda, Deepti Adhikari Guragain, Joseph Hatem, Luigi M Larocca, Ritu Nayar, Julia Samoleczyk, Jamie Slade, Esther Rossi.* Northwestern University, Chicago, IL; Hospital of the University of Pennsylvania, Philadelphia, PA; Catholic University, Rome, Italy.

**Background:** NIFTP was recently proposed as a specific histopathologic diagnosis based on a set of reproducible morphologic criteria. Retrospective analyses suggest that this diagnosis will affect the ROM mostly in indeterminate throid Bethesda categories. In this multi-institutional retrospective study we report the potential impact of NIFTP diagnosis on the associated ROM for each TBSRTC category.

**Design:** A retrospective analysis was carried out on thyroid FNA cases with histologic follow up in three academic center hospitals (Institution A, B, & C), from January 2014 to December2015. Slides for all cases diagnosed as follicular variant of papillary thyroid carcinoma (PTC) specimens were reviewed and cases qualifying as NIFTP were separated from other cases of PTC.

**Results:** The case cohort included a total of 2185 resected thyroid nodules diagnosed on FNA as: Non-diagnostic -3.1%, Benign-34%, atypia/follicular lesion of undetermined significance (AUS/FLUS)-18.8%, follicular Neoplasm / suspicious for follicular neoplasm (SFN/FN)-19.5%, suspicious for malignancy (SM)-8.1% and malignant (M)-16.8%. On the surgical pathology follow-up, 1464 (67%) cases were diagnosed as benign, 628(29%) as malignant and 93 (4%) can be classified on re-review as NIFTP. The number of NIFTP cases was highly variable among all three institutions; -institution A-9%, institution B-4% & institution C-1%. The average ROM for all TBSRTC categories with NIFTP for institution A-45%, B-44%, and C-34.5%; and without NIFTP was institution A-35%, B-43%, and C30.1%.

**Conclusions:** Adoption of NIFTP terminology and institutional frequency of this diagnosis, would largely affect the rate of malignancy associated with specific FNA diagnosis, especially among the TBSRTC indeterminate categories. Therefore, providing a range for risk of malignancy for each TBSRTC diagnostic category is very much reflective of inherent limitations of diagnostic thresholds and interobserver variability in the diagnosis of thyroid lesions.

**491 Abstract Withdrawn**

**Dermatopathology**

**492 Non-V600E BRAF Mutations Are More Common in Cutaneous Melanomas of Head and Neck and Upper Extremity**

*Michelle Afkhami, Laleh Melstrom, Kim Nguyen, Alexis B Terrones, Raju Pillai, Dongqing Gu, Milhan Telatar, Patricia A Aoun.* City of Hope Cancer Medical Center, Duarte, CA; Keck Graduate Institute, Claremont, CA; Meharry Medical College, Nashville, TN.

**Background:** Approximately 50% of cutaneous melanomas have activating BRAF mutations, with 90% of these harboring the V600E mutation. FDA-approved anti-BRAF therapies are mainly available to treat V600E mutations and currently have limited use for treatment of other variants. This study assessed the frequency and clinical presentation of V600E and non-V600E BRAF mutations in head and neck which reported to have poorer clinical outcome compare to cutaneous melanoma of the other anatomic site.

**Design:** A retrospective review of the molecular genomic pathology results was performed. 67 cutaneous melanoma cases were identified between 2013-2016. For 55 cases, BRAF mutation status was determined by a next generation sequencing based panel and 12 cases were tested by Sanger sequencing.

**Results:** Sites of involvement included the head and neck (21/67), upper extremity (14/67), lower extremity (15/67), and trunk (11/67) with BRAF mutations identified in 36/67 (54%) of cases. BRAF V600E/K/R, L597S, L584F, and S467L mutations were detected in these cases. The distribution of BRAF mutations differed by anatomic site as shown in table1.

Anatomic Site	Total BRAF Positive N (%)	V600EN (%)	V600K N (%)	V600RN (%)	L597SN (%)	L584FN (%)	S467LN (%)
Head and Neck	8/21 (38%)	2/8 (25%)	2/8 (25%)	1/8 (12.5%)	1/8 (12.5%)	1/8 (12.5%)	1/8 (12.5%)
Upper Extremity	9/14 (64%)	2/9 (22%)	6/9 (67%)	0	0	0	1/9 (11%)
Lower Extremity	4/15 (26%)	3/4 (75%)	0	1/4 (25%)	0	0	0
Truncal	11/17 (65%)	10/11 (91%)	1/11 (9%)	0	0	0	0

**Conclusions:** For the first time we are reporting that cutaneous melanomas of the head and neck harbor a wider variety of BRAF alterations other than the classic V600E mutation. In addition the majority of the upper extremity cases have a V600K mutation. The wide array of BRAF mutations present in the head and neck compared to the other three anatomic sites may result from greater UV exposure.

**493 Detection of Metastatic Melanoma Using Immunohistochemical Stains: How Many and Which Ones?**

*Mohammed A Alghamdi, Mostafa M Fraig, Zhenglong Wang, Ashley Mathew, Houa Alatassi.* University of Louisville, Louisville, KY.

**Background:** Despite the importance of the detection of metastasis in sentinel lymph nodes (SLNs) in cases of melanoma, there is no consensus regarding the markers that should be used. Protocols for histopathologic evaluation of SLNs vary among institutions. We present our experience in handling sentinel lymph nodes for the last 3 years in order to ascertain how many markers are sufficient for detection and which ones performed best. This has potential implications for the added cost and reimbursement patterns for SLN evaluation.

**Design:** A computer-based search of our files spanning the period from January 2013 to April 2016 revealed 228 cases of wide local excision of melanoma with biopsied SLNs. The protocol at our institution for handling formalin-fixed SLNs is to bisect the lymph node and section the entire node at 1 to 2 millimeter intervals. Three levels are stained with H&E and if found to be morphologically negative, all the sections are stained for S100, MART-1 and HMB45 by immunohistochemical (IHC) methods. The detection